ks, visit our website www.jaypeebrothers.com, for detailed information on dental books, visit our website www.jaypeebrothers.com, for detailed information on dental book

Essentials of
Oral Medicine



Complementary Poster of
'Modified Classification of
Clinical Impressions of
Oral Mucosal Lesions'

Freny Rashmiraj Karjodkar

Foreword
Sanjay M Mallya

JAYPEE

Contents

SECTION 1: INTRODUCTION

1. **Embryology and Development of Head and Face** 3
   - Early Embryology *3*
   - Dentition *27*
2. **Anatomy of Head and Face** 34
   - Descriptive Anatomic Terms *34*
   - Cellular Organization *34*
   - Osteology of Head and Neck *36*
   - Skull *36*
   - Maxilla *49*
   - Nasal Cavity *51*
   - Paranasal Sinuses *52*
   - Palate *55*
   - Pharynx *57*
   - Larynx *58*
   - Mandible *59*
   - Temporomandibular Joint *60*
   - Hyoid Bone *63*
   - Cervical Vertebrae *63*
   - Surface Anatomy of Face (Superficial Face) *64*
   - Muscles of Mastication *68*
   - Neck *69*
   - Submandibular Region and Floor of the Mouth *70*
   - Tongue Muscles *71*
   - Major Salivary Glands *72*
   - Cranial Nerves *74*
   - Vascular System of the Head and Neck *82*
   - Lymphatics of Head and Neck *84*

SECTION 2: GENERAL DIAGNOSTICS, INVESTIGATIONS AND THERAPEUTIC

3. **Investigation Protocols** 93
   - Fundamentals of Ordering a Test *93*
   - Approaches to Interpret Tests *94*
   - Parameters to Assess an Investigation *94*
   - Laboratory Tests *94*
   - Interpretation of Common Pathologies *98*
   - Radiographic Investigations *105*
4. **Therapeutics** 108
   - General Principles of Therapy *108*
   - Drug Pharmacokinetics and Pharmacodynamics *108*
   - Route of Administration and Drug Delivery *108*
   - Analgesics *109*
   - General Anesthetics *113*
   - Local Anesthetics *114*
   - Muscle Relaxant *115*
   - Sedative-Hypnotics *116*
   - Anticonvulsant/Antiepileptic Drugs *116*
   - Antidepressant Drugs *117*
   - Antianxiety Drugs *118*
   - Antimicrobial Drugs *118*
   - Phytotherapy for Oral Mucosal Lesions *154*
   - Equipment-assisted Therapeutics *154*
5. **Clinical Assessment and Process of Diagnosis** 169
   - Diagnosis *169*
   - Statistics *174*
   - Symptom *174*
   - Sign *175*
   - Components of History Format *175*
   - Summarize *178*
   - Signposting *178*
   - Classification of Diseases *216*

SECTION 3: PATHOLOGIES AFFECTING THE ORAL MUCOSA

6. **Periodontal Diseases** 223
   - Classification of Periodontal Diseases *223*
   - Genetic Disorders *224*
   - Acquired Disorders *230*
   - Advanced Clinical Diagnosis of Periodontal Disease *244*
7. **Pigmented Lesions** 246
   - Pigmented Lesions *246*
   - Classification of Pigmented Lesions *247*
   - Genetic Disorders *249*
   - Acquired Disorders *253*
   - Colored Lesions of Vascular Origin (Red/Purple/Blue) *257*
   - Exogenous Pigmentation *258*
   - Food, Habits, Heavy Metal and Drug-induced Hyperpigmentation *260*
   - Superficial Transient Discoloration *261*
   - Pigmentation due to Systemic Diseases *261*
   - Depigmentation *264*
8. **Infectious and Inflammatory Lesions** 266
   - Oral Manifestations of Generalized Inflammation of the Oral Cavity *267*
   - Bacterial Infections *271*

- Viral Infections *278*
- Fungal Infections *290*
- Protozoal Infestations *294*
- Parasitic Infection *294*

9. Vesiculobullous and Ulcerative Lesions 298
- Vesiculobullous Lesions *299*
- Ulcerative Lesions *316*

10. Potentially Malignant Disorders; Red and White Lesions 333
- Potentially Malignant Disorders *333*
- Classification of Oral Potentially Malignant Disorders *334*
- Red Lesions *349*
- White Lesions *354*

11. Soft Tissue Enlargements 361
- Genetic Disorders *363*
- Developmental Disorders *369*
- Inflammatory Lesions *371*
- Traumatic Lesions *374*
- Cystic Lesions *377*
- Benign Neoplasms *382*

12. Oral Cancer 390
- Historical Brief Review of Oral Cancer in India *390*
- Definition *391*
- Incidence *391*
- Age Distribution *392*
- Gender Differences *392*
- Religion *392*
- Etiopathogenesis *392*
- Epigenetic Factors *392*
- Carcinogenesis *396*
- Oral Cancer Classification *397*
- Staging of Oral Cancer *397*
- Biomarkers *398*
- Clinical Features *399*
- Lymph Nodes *407*
- Other Oral Cancer Types *408*
- Malignant Neoplasms of Bone and Connective Tissue *410*
- Examination of the Oral Cavity *415*
- Diagnostic Delay *421*
- Management *421*
- Prognosis Survival Rate *424*
- Toxicity *425*
- Oral and Dental Management *427*
- Psychological Aspects of Patient Care *428*
- Tobacco Cessation *429*

13. Diseases of Lip 434
- Genetic/Congenital Disorders *434*
- Acquired Disorders *440*

14. Diseases of Tongue 448
- Genetic/Congenital Disorders of Tongue Diseases *449*
- Acquired Lesions *456*
- Taste Disorders *469*

SECTION 4: ORAL MAXILLOFACIAL DISTURBANCES

15. Diseases of Teeth 477
- Types of Teeth, Structures, Location, and Functions *477*
- Types of Teeth and their Functions *478*
- Diseases of Teeth *479*
- Dental Anomalies *491*
- Dental Pulp *514*
- Acquired Anomalies *515*

16. Bone related Lesions of the Jaws 522
- Classification *522*
- Cysts of the Jaws *522*
- Odontogenic Tumors *531*
- Reactive Bone Lesions *541*
- Fibro-osseous Lesions *555*
- Giant Cell Lesions *557*
- Bone Tumors *562*
- Manifestation of Systemic Diseases in the Jaws *569*
- Craniofacial Anomalies *581*

17. Temporomandibular Joint Disorders 591
- Classification *591*
- General Clinical Considerations *592*
- Degenerative Joint Changes *595*
- Inflammatory (Diffuse Collagen Diseases) *597*
- Infection of TMJ *601*
- Developmental *603*
- Trauma *607*
- Metabolic Disorders *622*
- Biochemical Abnormalities *623*
- Neoplasia *623*
- Neuropathic Disorders *628*
- Drug-induced Disorders *629*
- Extracapsular Disorders *629*

18. Salivary Gland Disorders 632
- Saliva *633*
- Salivary Gland Dysfunction *635*
- Classification of Salivary Gland Disorders *637*
- Developmental Disorders *637*
- Obstructive Disorders *639*
- Cysts *640*
- Asymptomatic Enlargements *641*
- Infections *642*
- Autoimmune Disorders *646*
- Neurological Disorders *648*
- Vascular Disorders *648*
- Salivary Gland Tumors *648*
- Others *654*
- Diagnostics for Salivary Gland Disorders *655*

19. Orofacial Pain 657
- Definitions of Pain *657*
- Classification of Pain Disorders *657*
- Orofacial Pain *661*
- Evaluation of Orofacial Pain *662*

20. Systemic Disorders and Oral Health **698**
- Nutritional and Metabolic Disorders *698*
- Blood and Hematologic Disorders *703*
- Endocrinal Disorders *707*
- Autoimmune Disorders *710*
- Genetic Disorders *718*

SECTION 5: RECENT ADVANCES

21. Management of Medically Compromised Patients in Dental Practice **733**
- Patient Assessment Considerations *733*
- Form 1: Patient Assessment Form *734*
- Cardiovascular Disease *734*
- Hematologic Disorders *739*
- Neurologic Disorders *740*
- Gastrointestinal Diseases *741*
- Respiratory Tract Disease *742*
- Musculoskeletal Disease *743*
- Endocrine Disease *743*
- Genitourinary Tract Disease *744*
- Autoimmune Disease *744*
- Other Conditions and Factors *745*
- Risk Assessment *746*
- Treatment Modifications *746*
- The Geriatric Patient *746*
- Pediatric Care *748*

22. Breath Analysis and Halitosis **755**
- Diseases and Disorders Indicated by Important Biomarkers *757*
- Breath Analysis Benefits and Drawbacks *759*
- Halitosis (Bad Breath, Fetid Halitus, Mouth Odor, Bad Breath, Bad Mouth Odor, Malodor) *761*

23. Forensic Stomatology **771**
- Identification of Human Remains *771*
- Child Abuse *772*
- Cheiloscopy *775*
- Palatoscopy/Rugoscopy *784*
- Odontometry *789*
- Bite Mark Analysis *796*
- Tongue *801*
- Oral Microbiome (Mouth Bacteria) *802*
- Saliva *803*

24. Clinical Research **806**
- Research *806*
- What is a Research Design? *807*
- Health Research *810*
- Research Topics in Oral Medicine and Radiology *812*
- Biostatistics *812*
- Writing a Research Protocol *816*

25. Clinical Scenarios of Oral Facial Pathologies **820**

Index *839*

CHAPTER

5 Clinical Assessment and Process of Diagnosis

"Placing too much emphasis on a yes/no diagnosis, meaning you either have a disease or you do not, can lead even the most well-meaning physicians to miss underlying causes and early warning signs of illness"

— Mark Hyman

INTRODUCTION

The systemic health status is frequently mirrored in the oral cavity, which may be the disease's earliest manifestation. That disease could primarily be oral in nature (e.g., oral submucous fibrosis), or it may be present in the oral cavity as an indication or symptom of a more serious condition (e.g., glossitis related to anemia). The oral cavity makes certain diseases and systemic disorders more accessible for detection (e.g., Peutz–Jeghers syndrome/pemphigus).

The oral diseases encompass a wide range of problems that impact the general public, some have distinct signs and symptoms, while the others have shared characteristics that make clinical identification challenging. It is critical to have a thorough awareness of the disorders in order to provide adequate care.

DIAGNOSIS

The diagnosis of the oral lesions is crucial for their appropriate management. Generation of a list of likely diagnoses through a step-by-step process of making decisions by associating logic and knowledge constitutes clinical differential diagnosis.

A major challenge and the matter of paramount importance is to decide about the requirement of further investigations when an abnormality is detected in the oral cavity. If further investigations are needed, then, a systematic approach should be followed to evaluate the lesion which includes structured gathering of background information and a step-by-step clinical examination **(Table 1)**.

Appropriate documentation of the patient's history by the treating clinician is essential for proper management of the patient. Maintenance of dental/medical records is crucial for clinicians and institutions due to important reasons.

- It aids in the scientific evaluation of patient profile, in analyzing the treatment outcomes and planning treatment protocols.
- In cases of alleged medical/dental negligence, the legal system depends primarily on documentary evidence.
- The proper documentation of records is essential for proving the patient's demand for dental expenses as required by the insurance companies.

Another document of vital importance that most clinicians tend to take lightly is a properly obtained patient **informed consent (Form 1)** before any procedure is conducted. It is also essential for the **prescription to be legible** with the name of the patient, date, and the signature of the doctor **(Figs. 1A and B)**. An undated prescription can cause problem for the clinician if misused by the patient. Besides the main case record, the other records pertaining to patient management such as accounts records, service records of the staff, and administrative records, are also useful as evidences for litigation purposes. A coordinated effort of all the persons involved in patient care is necessary for proper medical/dental record keeping. Supervision of this process is done by the doctor who is chiefly responsible for history taking, physical examination, treatment plans, operative records, consent forms, medications used, referral papers, discharge records, and medical certificates. Proper recording of nursing care, laboratory data, reports of diagnostic evaluations, pharmacy records, and billing processes should also be done. The scene in India as regards record keeping in dentistry, certainly demands attention which extends from smaller clinics to large hospitals and is yet to develop into a proper process.

The traditional method of documentation of record is the **manual method** involving papers and books that is followed in most of the hospitals/clinics across India. This manual method of record is difficult to tamper without detection, hence, legally more acceptable as documentary evidence. Although, the **electronic medical/dental records** are neat and tidy and easy to store and retrieve, but owing to the probability of easy manipulation without detection they may not be universally accepted as documentary evidence in the court.

The classification given by the International Classification of Diseases (ICD) is one of the oldest and applicable to all the fields of medicine including all general epidemiological, health management purposes, and clinical use. It is useful for the evaluation of various factors such as general health situation of population groups and monitoring of the incidence, prevalence of diseases in relation to other variables such as the characteristics and circumstances of the individuals affected, reimbursement, resource allocation, quality, and guidelines. This classification is advantageous for statistical purpose and as a coding system in medical databases. Thus, most of the physicians utilize this classification in **Table 2**.

As previously stated, there are two approaches for documenting medical records. The old-fashioned technique involves the usage of **paper medical records** to retain all data

JAYPEE BROTHERS

TABLE 1: A step by step systematic approach to gather background information for the assessment of a suspicious oral mucosal lesion.

1.	History of current illness	Onset, location, intensity, frequency, and duration
		Aggravating and/or relieving variables
		Better, unchanged or worse over time
2.	Medical, tobacco, and alcohol history	Medical conditions
		Medications and allergies
		Tobacco and alcohol (type, frequency, and duration)
3.	Clinical examination	Extraoral examination
		Intraoral examination
		Lesion inspection (additional visual tools such as toluidine blue and direct fluorescence)
4.	Provisional diagnosis	It is also called *tentative diagnosis* or *working diagnosis* made by the treating physician from the information inferred after the initial interaction with the patient by way of history taking and clinical examination. For the final or exact diagnosis, the necessary investigation would have to be prescribed
5.	Differential diagnosis	If the findings are not conclusive for a definitive disease process, a list of probable diseases is recorded in the patient's case history called *differential diagnosis*. These diseases may have a similar course, progress, or signs and symptoms. Differential diagnosis should be approached on the basis of exclusion. All lesions that cannot be excluded, represent the initial differential diagnosis and should be the basis for ordering tests and procedures to narrow the diagnosis
6.	Diagnostic tests	Hematological and serum biochemistry investigations Complete hemogram, RBS, exfoliative cytology, FNAC, biopsy, ELISA, immunofluorescence, PCR, ESR, TB Gold, Rh factor, TSH, etc., (as indicated) Imaging/radiographic evaluation: intraoral, extraoral, advanced imaging (as indicated). (Refer Chapter 3: Investigation Protocols)
7.	Final or definitive diagnosis	It is usually reached by sequential organization and thorough evaluation of the information obtained from the patient's case history, physical examination and the result of radiological and laboratory examinations. It usually includes diagnosis of the chief complain first and then the subsidiary diagnosis of other problems
8.	Suggested management	The treatment plan for the chief complain, and also other subsidiary ailments diagnosed should be decided. Routinely, an ideal management protocol is to be followed, with priority to the chief complain. For the management of distressing symptoms, palliative treatment is to be advised first, followed by the therapeutic regimen

(ELISA: enzyme-linked immunosorbent assay; ESR: erythrocyte sedimentation rate; FNAC: fine needle aspiration cytology; PCR: polymerase chain reaction; RBS: random blood sugar; TB: tuberculosis; TSH: thyroid-stimulating hormone)

Form 1: Informed Consent Form for General Dental Procedures: *SAMPLE PROTOTYPE*

You the patient have the right to accept or reject dental treatment recommended by your dentist. Prior to consenting to treatment, you should consider the expected benefits and common risks of the recommended procedure, alternative treatments, or the option of no treatment.

Please do not consent to treatment unless and until you discuss potential benefits, risks, and complications with your dentist and all of your questions have been answered.

By consenting to treatment, you acknowledge your willingness to accept known risks and complications, no matter how slight the probability of occurrence.

It is equally important that you provide your dentist with accurate information before, during and after treatment and follow your dentist's advice and recommendations regarding medication, pre- and post-treatment instructions, referrals to other dentists or specialists, and return for scheduled appointments.

If you fail to follow the advice of your dentist, you may increase the chances of a poor outcome.

If you are a woman on oral birth control medication you must consider the fact that antibiotics might make oral birth control less effective. Please consult with your physician before relying on oral birth control medication if your dentist prescribes, or if you are taking antibiotics.

(At a given time consent should be taken for a single procedure, given below are sample information for various dental procedures which may be selected as per requirement, point nos. 1, 2, 3, 4, and 11 are common points, and point nos. 5 to 10 may be selected as required)

1. EXAMINATION AND X-RAYS; I understand that the initial visit may require radiographs in order to complete the examination, diagnosis, and treatment plan. _____ Please Initial
2. DRUGS, MEDICATION, AND SEDATION; I have been informed and understand that antibiotic, analgesics, and other medications can cause allergic reactions causing redness, swelling of tissues, pain, itching, vomiting, and/or anaphylactic shock (severe allergic reaction). They may cause drowsiness and a lack of awareness and coordination, which can be increased by the use of alcohol or other drugs. I understand and fully agree not to operate any vehicle or hazardous device for at least 12 hours or until fully recovered from the effects of the anesthetic medication and drugs that may have been given me in the office for my treatment. I understand that failure to take medications prescribed for me in the manner prescribed may offer risks of continued or aggravated infection, pain, and potential resistance to effect treatment of my condition. I understand that antibiotics can reduce the effectiveness of oral contraceptives. _____ Please Initial
3. CHANGES IN TREATMENT PLAN; I understand that during treatment, it may be necessary to change or add procedures because found while working on teeth that were not discovered during the initial examination, the most common being root canal therapy following routine restorative procedures. I give my permission to the dentist to make any or all changes and additions as necessary._____ Please Initial
4. TEMPOROMANDIBULAR JOINT (TMJ) DYSFUNCTIONS; I understand that symptoms of popping, clicking, locking, and pain can intensify or develop in the joint of the lower (near the ear) subsequent to routine dental treatment wherein the mouth is held in the open position. However, symptoms of TMJ associated with dental treatment are usually temporary in nature and well-tolerated by most patients. I understand that should the need for treatment arise, I will be referred to a specialist for treatment, the cost of which is my responsibility. _____ Please Initial

Contd...

JAYPEE BROTHERS

Contd...

5. FILLINGS AND RESTORATIONS; I understand that care must be exercised in chewing on the new filling during the first 24 hours to avoid breakage, and tooth sensitivity is a common after-effect of a newly placed filling._____ Please Initial
6. REMOVAL OF TEETH (EXTRACTION); An alternative to removal has been explained to me (root canal therapy, crowns, periodontal surgery, etc.) and I authorize the dentist to remove the following teeth and any others necessary for the reasons in point no. 3. I understand removing teeth does not always remove all infection if present and it may be necessary to have further treatment. I understand the risks involved in having teeth removed, some of which are pain, swelling, and spread of infection, dry socket, loss of feeling in my teeth, lips, tongue, and surrounding tissue (paresthesia) that can last for a period of time or a fractured jaw. I understand I may need further treatment by a specialist or even hospitalization if complications arise during or following treatment, the cost of which is my responsibility. _____ Please Initial
7. CROWNS, BRIDGES, VENEERS, AND BONDING; I understand that sometimes it is not possible to match the color of natural teeth exactly with artificial teeth. I further understand that I may be wearing temporary crowns, which may come off easily and that I must be careful to ensure that they are kept on until the permanent crowns are delivered. I realized that the final opportunity to make changes in my new crowns, bridge or veneer (including shape, fit, size, placement, and color) will be done before cementation. It is explained to me that, in very few cases, cosmetic procedures may result in the need for future root canal treatment, which cannot always be predicted or anticipated. I understand that cosmetic procedures may affect tooth surfaces and may require modification of daily cleaning procedures. _____ Please Initial
8. DENTURES—COMPLETE OR PARTIAL; I realize that full or partial dentures are artificial, constructed of plastic, metal, and or porcelain. The potential problems of wearing those appliances have been explained to me, including looseness, soreness, and possible breakage. I realize the final opportunity to make changes in my new denture (including shape, fit, size, placement, and color) will be "teeth in wax" try-in visit. I understand that most dentures require relining approximately 3–12 months after. The cost of this procedure is not the initial denture fee. _____ Please Initial
9. ENDODONTIC TREATMENT (ROOT CANAL); I realize there is no guarantee that root canal treatment will save my tooth and those complications can occur from the treatment and that occasionally posts are cemented in the tooth, or extend through the root, which does not necessarily affect the success of the treatment. I understand that occasionally additional surgical procedures may be necessary following root canal treatment (apicoectomy). _____ Please Initial
10. PERIODONTAL TREATMENT; I understand that I have a serious condition causing gum inflammation and/or bone loss and that it can lead to the loss of my teeth. Alternative treatment plans have been explained to me, including nonsurgical cleaning, gum surgery and/or extractions. I understand the success of treatment depends in part on my efforts to brush and floss daily, receive regular cleaning as directed, following a healthy diet, avoid tobacco products and follow other recommendations. _____ Please Initial
11. PRE- AND POST-TREATMENT PHOTOGRAPHS; I understand that the photos are taken for record purpose and to study the progress of the treatment. I have no objection if the same are used for scientific research or teaching purpose taking care that all confidentiality is maintained. _____ Please Initial

This form is intended to provide you with an overview of potential risks and complications. Do not sign this form or agree to treatment until you have read, understood, and accepted each paragraph stated above. Please discuss the potential benefits, risks, and complications of recommended treatment with your dentist. Be certain your dentist has addressed all of your concerns to your satisfaction before commencing treatment.

CONSENT: I declare that I am more than 18 years of age. I have been informed that there are inherent risks involved in the treatment/procedure. I have signed this consent voluntarily out of my free will without any pressure and in my full senses.

Place: _____ Date: _____ Time: _____

Signature (to be signed by parent/guardian in case of minor): _____

Witness Sign and Date: _____

NOTES:-
This Consent Form should be signed BEFORE the treatment is started. These formats may be modified as per the individual requirements.
These formats should be in local language and in certain cases, it would be prudent to have a proper witness to the consent signature.
Informed consent forms for various situations can be made for Nursing Homes/Hospitals. Help of lawyers may have to be taken. Detailed forms on medical history can also be maintained. Keep all records safely in order.
It is important to note that written consent should refer to one specific procedure. Obtaining a "blanket" consent on admission does not have legal validity.

on the patient in which the information is entered on paper and then archived but the record is not easily accessible. The **International Classification of Diseases (ICD)**, is a diagnostic tool that maintains information for health analyses, along with the patient details, the disease ICD code and diagnosis. *Computer databases* are the most current way of record keeping, utilizing comprehensive medical record keeping software, which aid in ICD categorization and allows for a faster search of the patient records.

Maintaining the **confidentiality** of the patient records is of utmost importance, as the clinician and the hospital/clinic can be accused by the patient for not preserving the confidentiality of his/her medical/dental records. Though the process of electronic medical/dental recording is continuously evolving, there are still numerous areas of concern requiring consideration, for example, the electronic signature of the patient, doctors, and witnesses on the informed consent forms.

Utilization of medical/dental records can be done as:

- **Personal document**—where information is confidential and cannot be revealed without patient's consent except in some specific conditions **(Box 1).**
- **Impersonal document**—here identity of the record is lost as a personal document and there is no need of patient's permission to use it like in case of research purposes.

In India, as no specific guidelines are yet established regarding the duration of time for which the records are retained, hospitals/clinics follow their own norms concerning retention

JAYPEE BROTHERS

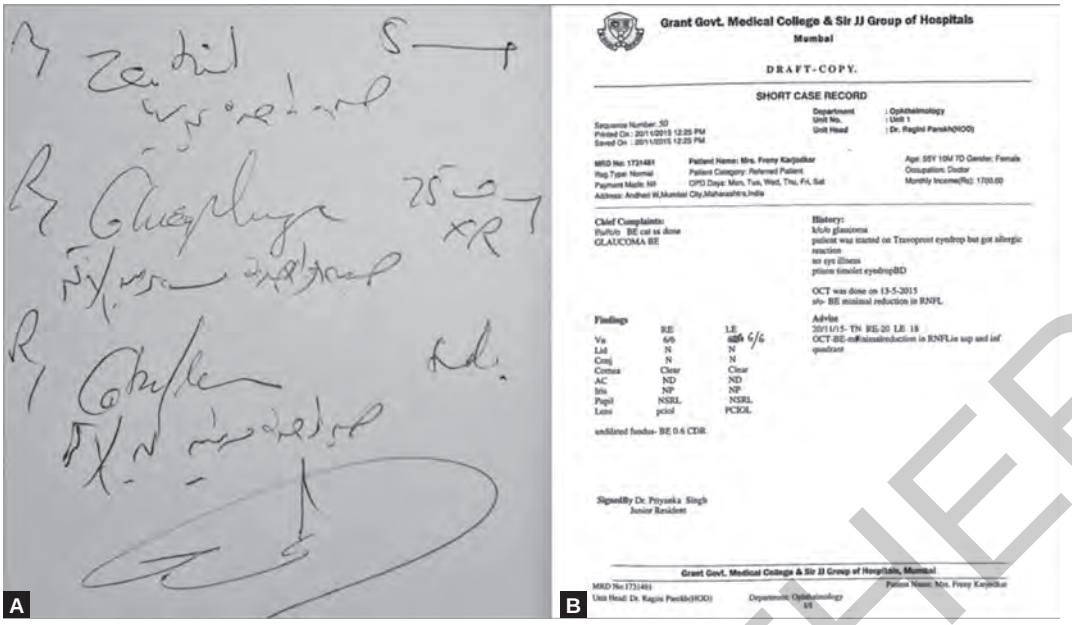

Figs. 1A and B: Prescription: (A) Handwritten; (B) Printed.

TABLE 2: International classification of the diseases and problems connected with the healthcare.

Chapter	*Group of diseases*	*Code*
I	Certain Infections and Parasitic diseases	AOO-B99
II	Neoplasm	COO-D48
III	Diseases of the Blood-forming Organs and certain Disorders involving the Immune Mechanism	D50-D89
IV	Endocrine, Nutritional and Metabolic Diseases	E00-E90
V	Mental and Behavioral Disorders	F00-F99
VI	Diseases of the Nervous System	G00-F99
VII	Diseases of the Eye and Adnexa	H00-H59
VIII	Diseases of the Ear and Mastoid process	H60-H99
IX	Diseases of the Circulatory System	100-199
X	Diseases of the Respiratory System	J00-J99
XI	Diseases of the Digestive System	K00-K93
XII	Diseases of the Skin and Subcutaneous Tissue	L00-L99
XIII	Diseases of the Musculoskeletal System and Connective Tissue	M00-M99
XIV	Diseases of the Genitourinary System	N00-N99
XV	Diseases or injuries complicating Pregnancy, Childbirth and the Puerperium	O00-99
XVI	Certain conditions originating in the Pre-natal Period	P00-P99
XVII	Congenital Malformations, Deformations and Chromosomal abnormalities	Q00-Q99
XVIII	Symptoms, signs and abnormal clinical and laboratory findings, not elsewhere classified	R00-R99
XIX	Injury, Poisoning and certain other consequences of external causes	S00-T98
XX	External causes of Morbidity and Morality	V01-Y98
XXI	Factors influencing Health status and contact with Health services	Z00-Z99
XXII	Codes for special purposes	U00-U99

Box 1: Specific conditions for disclosure of confidential information.

The clinician/hospital are legally bound to maintain the confidentiality of the personal medical records except in certain special conditions which are as follows:

- When the referral of patient is required.
- When asked by the court or police on a written requisition.
- When the insurance companies require the record in case the patient has relinquished his rights on taking the insurance.
- When needed for specific provisions of Workmen's Compensation cases, Consumer Protection cases, or for Income Tax Authorities.

period of medical records. The provisions of the Limitation Act 1963 and Section 24A of the Consumer Protection Act 1986 proclaim the time period for filing the complaint and hence a time of 2 years is recommended for maintaining outpatient records and 3–5 years for inpatient and surgical cases. It is pertinent to mention here that in pediatric cases, a child after acquiring the age of majority can file medical/dental negligence case. The Medical Council of India guidelines also insist that inpatient records should be maintained for 3 years in a standard format from the initiation of treatment however there is no directive from Dental Council of India (DCI). Recently, for the **impersonal documents** used for research purposes, there has been found a need to regulate. Now for using patient data in research, an **ethics review** is required and this restricts the way in which research is conducted.

Proper maintenance of the medical/dental records is the responsibility of the hospital/clinic. **A medical record is not legally valid if unsigned**. The copies of the treatment records have to be provided within 72 hours if asked by the patient or their legal heirs. A reasonable amount can be charged by the hospital for the administrative purposes.

Discharge notes (Form 2) though not a regular practice in dentistry, it is crucial evidence regarding the inpatient treatment received. The discharge notes should briefly include record of case details of the patient, pertinent investigations, and operative procedures. The admission and discharge dates with date of surgery are an important issue in litigations. Post discharge care and caution instructions to be followed by the patient, dietary guidelines and date of next follow-up also should be included in discharge notes. Clinician should sign or countersign the discharge summary. A case file should be maintained with a copy of discharge summary. In cases when patients get discharged against medical advice, it is necessary

JAYPEE BROTHERS

Form 2: Discharge summary template.

IP. Number: _____ **Admission Date:** _____ **Discharge Date:** _____
Bed No.: _____ **Admission Time:** _____ **Discharge Time:** _____
Name of Patient: _____ **Age:** _____years **Sex:** _____
Guardian's Name: _____
Address: _____
Telephone: _____ **Email:** _____
Consultant's Name: Dr. Gaurav Mukhi (Consultant Onco Surgeon)

Patient was also seen on referral by: Dr. Tipu Sutan (Consultant Physician) and Dr. V.S.Das (Consultant Cardiothoracic Surgeon)
Final Diagnosis: Squamous Cell Carcinoma Oesophagus (Middle 1/3)
Clinical Summary: This 35-year-old woman was admitted with history of gradually increasing dysphagia (solids >> liquids) since November 2010. Upper GI Endoscopy revealed ulceroproliferative growth in esophagus at 32 cm from the incision teeth. Endoscopic Biopsy showed Squamous Cell Carcinoma. CECT Thorax done showed locally advanced disease. The patient was given 3 cycles of neoadjuvant Chemotherapy with Injection Paclitaxel and Carboplatin. Follow-up PET-CT scan showed metabolically active mass in infracarinal region suggestive of residual disease with no evidence of metastatic or active disease anywhere else. Relevant investigations were done prior to surgery.
Operative Note: Total radical oesophagectomy (McKeown's) with oesophagogastrostomy and feeding jejunostomy done under General Anesthesia and Thoracic Epidural Anesthesia on _____.
Operative Findings:
– Right Thoracotomy through 5th ICS showed oesophageal growth extending from pulmonary vein
– To the carina and infiltrating into the aorta at one region of 2 cm x 2 cm when little bit of tumour
– Tissue was left behind during resection
– No obvious metastatic lymph nodes were seen.
– No evidence of metastatic disease was seen
The whole procedure took 7–8 hours to complete.
Postoperative recovery was gradual but uneventful. Contrast swallow study done on 12th Postoperative day did not show any anastomotic leak in the neck.
At present, patient is afebrile, haemodynamically stable, taking liquids orally and is being discharged with the following advice -
Condition of Patient at discharge:
The patient is discharged with: Feeding Jejunostomy tube in situ.
Advice on discharge:
1. REST: Restful life at home for 7 days.
2. DIET: Diet of liquid consistency orally of about 2 litres/day (2000Kcal/day) and Feeding Jejunostomy Tube feeds about 1 litre/day (water/clear liquids). Diet should be followed as per diet chart.
3. TOTAL ADVISED FLUID INTAKE: Liberal.
4. Syrup DIGENE 10 mL orally thrice daily to continue till further advice.
5. Syrup IBUGESIC 10 mL orally as and when necessary (in case of pain)
6. RESOURCE 4 scoops with 200 mL of water 4–5 times orally to continue till further advice.
7. Review with Dr. Gaurav Mukhi after 7 days with Histopathological Examination
Report at Nair Oncology Centre (9892123572) or even earlier if necessary with prior appointment.
8. Regarding any query about reports (biopsy) if applicable and hospital services please contact 9548451007.
9. Continue treatment under regular Supervision of surgeon/physician of choice.
10. Consult your house Physician or Emergency Department of Oncology, General Hospital or any other hospital if any medical problem arises.
11. Remain alert to any Drug Reaction–if any itching/rash/suffocation/any other distress appears after taking any of the above medicine. Put the MEDICINE on HOLD and consult your physician/local physician immediately.
Investigations-Reports enclosed/Please contact Front Office for reports pending if any.

_____
Signature of MO/Consultant
_____
Name of MO/Consultant
_____
Registration No. of MO/Consultant

Declaration by guardian of the patient:
Copy of the above mentioned instructions have been received and understood. Reports, old papers and other documents have been received and verified

_____	_____	_____	_____	_____
Signature	Name	Relationship	Date	Time

to record this fact on the discharge sheet along with signature of the clinician, patient and a witness.

Referral notes (Form 3) are also an essential part of patient records. It is important to include the date and time of issue, condition of patient's general health, and reason for referral and the plan of action to be followed, in duplicate for the future reference.

History taking though a brief history is recorded in the patient's record file by the clinician's associate in many clinics, this is seldom enough. Recording a full and extensive dental history allows the physician to establish a connection with the patient while also observing the patient in a more relaxed environment. It is critical to understand that as a clinician, you must approach and examine the patient as a whole, not simply the "tooth of chief complaint" or the "ulcerative lesion." When a patient is evaluated holistically, it is easier to generate a working diagnosis, provisional diagnosis, requirement for investigations, and final diagnosis along with the treatment plan. The growing body of research in the literature on medical/dental care quality and safety has revealed an unmistakable

JAYPEE BROTHERS

Form 3: Referral sample.

Date:
To:
From:
Patient Name: **Age:** **Sex:**

Summary and request:
62-year-old Hindu female patient presented to our dental office for multiple extractions. This is a very stressful procedure with anticipated bleeding from multiple intraoral sites. Local anesthesia will be used and include 3.5 to 8 mL of 2% lidocaine with 1:100,000 concentration of epinephrine. Examination revealed a slightly overweight female in no apparent distress. Her BP was 175/100 mm Hg with pulse of 70 beats/min with regular rate and rhythm.
Her medical history include hypertension since 23 years, two angina attacks, the last reported in May 2017, reported history of treated tuberculosis, renal disease and on multiple medications. Review of systems revealed polyuria, polydipsia and occasional shortness of breath at rest.
These co-morbid conditions are as follows:

	Duration:	Medication:
1. Hypertension	23 years	Norvasc/Tenormin
2. Obesity Related Depression	3 years	Prozac

Please advise precaution and medications for patient's hypertension control stable versus unstable angina, any other type of cardiovascular disease or target organ damage and suspected diabetes mellitus

Patients Signature and Date:
Oral Health Care Professional Signature and Date

benefit of good communication in terms of improved outcomes, as well as substantial associations between lack of communication and medical/dental error and negative patient experiences.

As a result, effective and personal communication in medicine and dentistry is critical for both professionals and patients. The doctor can address all the key elements while giving the patient time to talk and reassuring the patient by using a systematic approach.

A case history is a structured professional dialog in which a patient expresses his or her symptoms, feelings, and anxieties to a clinician in order help the clinician gain insight into the nature of the patient's condition and his or her attitude toward it.

In the last few decades, a slew of scientific breakthroughs and rapid technological advancements have changed the way diseases are identified and treated. Unfortunately, the one main premise of compassionate care, which is to listen to the patient, has been eclipsed by the findings of imaging investigations and laboratory tests. In this case, poor communication and connection with patients is caused by the fast-paced, output-based demands, shorter hospitalizations with more frequent medical team handoffs. When Sir William Osler said, "**The good physician treats the disease; the great physician treats the patient who has the disease**," he was referring to the importance of a physician's communication skills.

The physician should use patient-friendly language to clarify what the dental assessment will entail, rather than medical terms that can make the patient nervous or confused. Before beginning the history taking process, the patient's consent must be secured.

This should never be a rushed meeting; the initial history taking session should be set aside for at least 45 minutes to an hour. It is best if the clinician explains and asks the questions to the patient, and the patient is given a form on which he or she can tick what applies, as well as the opportunity to ask questions and clear any concerns. Diagnosis means "knowledge" in Greek, thus it is crucial for the physician to pay attention to the patient as he or she may be giving the diagnosis.

The main objectives of history taking are as follows:
- ❖ To establish rapport with the patient.
- ❖ A well-organized approach for the collection of relevant data which is critical for successful treatment.
- ❖ To gain sufficient information to arrive at a provisional diagnosis.
- ❖ To gain an understanding of the patient's wishes and expectations.

Recording the history will help to perform the following things:
- ❖ To establish a diagnosis.
- ❖ To detect any apparent or hidden medical problem.
- ❖ To help evaluate other systemic problems.
- ❖ To discover presence of the communicable diseases.
- ❖ To be prepared to manage any emergencies.
- ❖ To effectively make a treatment plan.

STATISTICS

Statistics is defined as a systemic approach to collect and compile numerical form from the information related to the vital events, births, death, social structure, and legislation. For example:
- ❖ *Patient registration number* will help in:
  1. Record maintenance
  2. Medicolegal aspects
  3. Billing records
- ❖ ***Date*** is important
  1. For reference of the disease, complaint, start of treatment, etc.
  2. Record maintenance

SYMPTOM

A **symptom (Fig. 2)** is defined as any bodily change perceptible to the patient. "Symptoms" are those "things" that the patient tells us, for example, pain would be a symptom (the clinician cannot see it, but the patient can tell that he/she has pain), sensitivity to hot and cold, altered taste, inability to speak or chew, and aesthetic complaint are all different types of symptoms that the patient puts forth.

JAYPEE BROTHERS



Fig. 2: Symptom—is what the patient perceives, it is abstract and cannot be quantified by the clinician.

(*Courtesy:* Dr Pradnya Jadhav, Professor and Head; Dr Rohit Gadda, Reader; Dr Neha Patil, Assistant Professor, Department of Oral Medicine and Radiology, MGM Dental College, Navi Mumbai, Maharashtra, India)

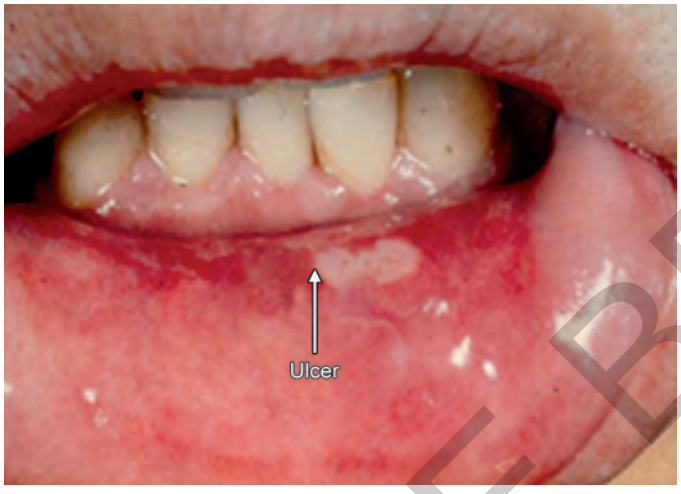

Fig. 3: Sign—is a bodily change which can be perceived both by the patient and clinician.

SIGN

A **sign (Fig. 3)** is defined as any bodily change that is perceptible to a trained observer. "Signs" are those "things" that the clinician can observe—redness, swelling, measurable fever, tenderness to palpation, crepitus, bad breath, and molar cross bite. For example, flinching or "guarding" by the patient when the clinician examines or touches a painful area would be a sign that the patient is experiencing pain. The signs of different diseases may be similar, for example, an ulcer due to sharp tooth, stress, or carcinoma.

COMPONENTS OF HISTORY FORMAT

- Demographic data
- Chief complaint
- History of present illness
- Past dental history
- Medical history
- Personal/social history
- General examination
- Extraoral examination
- Intraoral examination
- Provisional diagnosis
- Investigations
- Final diagnosis
- Treatment plan
- Informed consent

Demographic Data

It is information about the person according to certain attributes such as age, gender, race, place of residence, and socioeconomic factors such as occupation, family status, and income. The demographic, socioeconomic, and dental clinical predictors of oral health play a major role in determining the **oral health-related quality of life (OHRQoL)** of the patient. This data is important as each of its component adds to the patient's history and also may give the clinician a clue for diagnosis. The information included in the demographic data is as follows:

- ***Patient registration number***—used for maintaining records, billing purposes, and medicolegal aspects.
- ***Date***—records time of admission, reference during follow-up visits and record maintenance.
- ***Name***—addressing a patient by his or her first name builds up a rapport and better communication with the patient. It also helps in identification, record maintenance, psychological benefit, information about patient's social background, e.g., religion/race. Many inherited and genetic diseases are race-based. For example, glucose-6-phosphate dehydrogenase (G6PD) deficiency is common among the Zoroastrian community where the female is usually the carrier, but the disease is manifested in the males, certain drugs, like metronidazole commonly prescribed to treat periodontal disease, are restricted for these patients.
- ***Age***—plays an important role in the diagnosis:
  - There is a predilection of certain disease at differing age levels.
    - Birth—cleft lip and palate, ankyloglossia, teratoma, and hemophilia.
    - Children and young adults—papilloma, juvenile periodontitis, and scarlet fever.
    - Adults—attrition, abrasion, periodontitis, pulp stones and/or root resorption.
  - In treatment planning:
    - The comparison of chronological and dental age helps evaluation any endocrinal problems
    - Growth spurts
    - The calculation of medicine dosage
  - In behavioral management; different age groups require different types of management.
- ***Sex***—certain diseases are gender specific:
  - Female—iron deficiency anemia, Sjogren's syndrome, osteoporosis, myasthenia gravis, juvenile periodontitis, recurrent aphthous ulcers, and trigeminal neuralgia.
  - Male—attrition, leukoplakia, oral carcinoma, melanoma, Hodgkin's disease, and pernicious anemia.
  - Child abuse—exploitation more common in males, sexual abuse more common in females.
  - Drug interaction—in female's special consideration must be given to pregnancy and lactation.
- ***Height and weight***—measurements are used to calculate **the body mass index (BMI)**, a measure of healthy versus unhealthy weight. They are also important especially when tracking a child's growth. The height may give an insight into the growth and development as well as conditions such as

JAYPEE BROTHERS

osteoporosis. Accurate measurement of patient weight is an essential part of the nutritional assessment. It is also useful in maintaining fluid-balance management and **drug-dose calculations.** A rapid loss of weight may be a sign of chronic disorders such as malignancy, diabetes, tuberculosis, and other wasting disease. A rapid gain in weight can be a sign of heart failure, edema, hypothyroidism, or neoplasm. The obesity is a risk factor for many health problems, including heart disease and diabetes.

- ***Address***—it is important for communication and for future correspondence. It gives a view of the socioeconomic status to know about nourishment, hygiene, and payment capacity of the patient. Prevalence of disease are associated with certain regions, for example, increased fluoride levels in drinking water in Rajasthan result in dental fluorosis. Persons living in industrial areas are more prone to respiratory diseases due to air pollution.
- ***Occupation***—helps assess socioeconomic status. There is a predilection of disease in different occupations, for example, hepatitis B is common among dentists, lead poisoning amongst persons working with paints, notched incisors were a common finding amongst carpenters due to their habit of holding nails in the mouth whilst working.
- ***Marital status***—to check out history of consanguineous marriages. The high consanguinity rates, coupled by the large family size in some communities can induce the expression of autosomal recessive diseases. For example, chorea amongst Zoroastrians.
- ***Income***—the socioeconomic status and the paying capacity of the patient.
- ***Name, mobile number, and email of patient's current physician and/or medical consultant where the patient is under treatment for any medical problems***, this is an important communication tools to verify and discuss the patient's medical conditions, precautions for oral/dental treatments, and in case of emergencies.
- ***COVID-19-Vaccination Certificate*:** An essential government document stating that the patient has received both doses of vaccination. If not then RT-PCR report taken not more than 1 day before the appointment, which was necessary during the COVID peak period and remains a preferred option.
- ***Name and contact of medical insurance facility where the patient is registered.***

The demographic data may be recorded at the reception and forwarded to the clinician, before the patient enters the operatory **(Form 4)**.

Method of History Taking

Traditionally clinicians followed the "**clinician-centered**" interviewing for recording the case history, where they understand the patient's symptoms and complaints in a **biomedical model of health**, which categorizes patients strictly by disease. However, psychological or social factors that possibly are the primary determinants of the patient's health are not incorporated in this method. In "clinician-centered" case history taking, the clinician commands the communication to fulfill his/her own criteria, that is prompting relevant information to help make a diagnosis. Many closed-ended questions are there in this approach and patients are not allowed to express or explain about their requirements, as the clinician tends to interrupt after an interval of say 18 seconds as the time limit set and the patient may not be able to finish their explanation of complaint thus preventing the formation of a psychosocial history that may play an essential part in patient care.

The "**patient-centered**" interviewing in a **biopsychosocial model** of care which has been introduced to overcome the shortfalls of the above method, amalgamates three aspects of the patient, i.e., biological, psychological, and social. This technique incorporates a more humanistic and scientific approach where considerable attention is given to the patient as well as the disease. In patient-centered history taking, clinicians permit the patients to begin and direct the discussion. Patients are given sufficient time and encouraged to express their apprehension and personal distress and emotions, thus providing a distinctive and individualized perspective of their disease and associated symptoms. This method validates the concept that patient's field an expertise is their own symptomatology, and the physicians possess an ability for transforming patient complaints into diagnosis and suggestions for the treatment. This method also enables patient independence and a feeling of responsibility for his or her own care.

When the above two methods that is; clinician and patient centered are artfully combined complementing each other, by the expert clinician in his or her history taking regime, it has been associated with increased patient satisfaction, improved compliance and outcomes in the management of chronic diseases such as hypertension and diabetes, and decreased malpractice suits.

How to Frame the Questions when Taking History

Closed-ended Questions

These can be answered with "Yes" or "No," or they have a limited set of possible answers (such as: A, B, C, or All of the above).

To acquire extra information or more descriptive information from the patient, the query may be worded differently. The question should not imply a "correct" response to the patient, but rather allow the patient to express what is on his or her mind. The question should not be answered with a simple "yes" or "no."

Form 4: Demographic details format.

Health History Form

Name: Home phone: ( ) Business phone: ( )

Address: (Last First Middle) City: State: Pin code:

Occupation: (PO Box or Mailing Address) Height: Weight: Date of birth: Sex: M❑ F❑

Adhar No.: Emergency contact: Relationship: Phone: ( )

If you are competing this form for another person, what is your relationship to that person?

Name Relationship

JAYPEE BROTHERS

Open-ended Questions

These are questions that allow someone to give a free-form answer. They can be used to elicit further details about a specific condition. For example, instead of asking "is your tooth paining", the question, "How is your tooth?" can be utilized by the clinician to dig deeper and gather specific information that the patient is unaware of. Open-ended questions are a simple and informal technique to bring up a topic or an unexplored symptom.

Questions with Options

It is sometimes necessary to "pin down" exactly what a patient is attempting to communicate. If the information cannot be gathered by open inquiry, the patient should be provided certain alternatives to help him or her obtain the information needed. For example, if a patient complains of "passing blood," and it is difficult to figure out what they mean despite being given the opportunity to elaborate, the physician should be more specific and ask, "Is it in, when you pass urine or stools?" If the patient is a woman, the clinician should note whether the reference is to menstruation. This strategy should be used with caution because the patient may be referring to a "nose bleed or bleeding gums," and the physician may get the answer he wants rather than what the patient meant. Specific medical/dental words should be avoided, such as "ketone smell or polyuria" (one of the possibilities you may give if trying to determine if a patient has diabetes). "Does your urine have a sweet or fruity fragrance, or do you have to go to the toilet several times, especially at night?", is what the clinician can ask. Instead of making suggestions, the doctor is more likely to gain a true picture if the patient is allowed to express; occasionally questions with possible answers cannot be avoided and must be asked.

Leading Questions

If possible, the "leading questions" should be avoided. These inquiries lead the patient to respond to the clinician's point of view and preconceptions, which might result in biased responses and interpretation. A patient, for example, arrives to the clinic with complaint of burning and a white patch in his mouth. The clinician is aware that the patient is a tobacco user. So, he asks the patient how often he eats *paan*, if he puts it in the area where the patch is, and if he is now stressed. The patient is unsure of the answer, having not considered the impact of *paan* consumption frequency and stress on his present problem and may respond yes because stress is "in-style" in today's culture, the clinician may be on the wrong track as regards the white lesion. It is far preferable to ask a distinct open inquiry for each complaint, such as one for the white lesion and another for the mouth burning. When a clinician tries to connect the two and construct a joint diagnosis, it is often incorrect because they may be two different problems in close proximity.

Initial Patient-Clinician Evaluation

At instant the patient enters the operating room, history taking or recording should begin. Prior to conducting a verbal history, observing the patient as they enter the room can reveal numerous clues. The patient's walk, look, apparent age versus chronological age, smell (e.g., tobacco or cigarette smell), tone of speech, and degree of eye contact all provide information about their physical and mental condition.

The operatory should be clean, disinfected and well lite. The clinician and the attending staff should be appropriately dressed, dental coat, personal protective equipment (PPE), facemask, head cap, gloves, etc.

The clinician should watch the patient and take notes on what they see, but not categorize or draw conclusions. The doctor must keep an open mind that the patient is in unfamiliar territory and may act differently in clinical settings. At the same time, the patient is also evaluating the clinician's approach, body language (nonverbal communication), therefore, it is important to greet the patient with a smile and a cheery "hello, what can we do for you?"

If this is the patient's first visit, the clinician should welcome him or her by name and introduce himself or herself as well as the dental associates in the room by their names and positions. The patient should be urged to take a seat and the headrest and chair inclination should be adjusted to make him or her comfortable.

The clinician must verify the patient's name and demographic information before moving on to the reason for the patient's visit to the clinic.

The patient should be able to speak freely and share their tale. This can be aided by the clinician's active attentive listening.

Instead of bombarding the patient with questions, try eliciting information such as when and how the pain began, and whether it is worsened by hot or cold applications. The patient should be given the opportunity to relate their story. This allows for a greater understanding of the patient's genuine complaint, its progression, and the relative experience of the symptoms for which they have come to the clinician **not just to diagnose but also to cure**.

It is critical to be able to ask insightful, descriptive inquiries regarding specific symptoms in order to confirm their true nature and aid in the diagnostic procedure. It is critical to write down each of the primary symptoms in the sequence in which the patient presents them. The patient's description should not be interrupted, and the doctor can return to the notes and evaluate them piece by piece.

While listening to the patient, the doctor should also observe the patient's facial expression and body language to determine what is actually bothering them. There could be some very useful psychological origin for physical symptoms that the patient is unaware of, but the clinician can detect it if they pay attention when the patient is speaking and notice a change in expression or voice that appears to make the patient uncomfortable or hesitant while narrating. If the patient has a speech or language impairment, full use of communication tools including translators, sign-language interpreters, picture boards, and drawings drawn by the patient to explain where the pain is, should be encouraged. When a patient is unable to describe their disease, it is necessary to "**pull out**" the history through inquiry and clarification of details. If the prompting prompts a narrative, the doctor should listen to it without interruption if at all possible.

Chief Complaint

It is the statement formed by asking the patient about the problem and the reason for seeking help and medical care. It should be registered in the patient's own words and in chronological order of occurrence and severity of symptoms. It should be given prime importance as diagnosis and treatment planning are based mainly on it. Sometimes there may be multiple complaints, all should be recorded in order of patient narration.

History of Chief Complaint (Present Illness)

The chief complaint needs to be elaborated in detail, as regards:

- ❖ The mode and cause of onset of symptoms.
- ❖ The duration of the complaint.

JAYPEE BROTHERS

- ❖ The location—whether it is localized, diffuse, referred, or radiating
- ❖ The progression—continuous or intermittent
- ❖ The aggravating and relieving factors.
- ❖ The previously taken treatment.

The common presenting chief complaints for a patient presenting to oral medicine department include—pain, **(Box 2)** burning sensation, bleeding, loose teeth, recent occlusal problems, delayed tooth eruptions, xerostomia, swellings, bad taste, halitosis, paresthesia, limited mouth opening, etc.

SUMMARIZE

The clinician should summarize all that the patient said about their present complaint. This permits the clinician to check whether everything the patient has stated has been understood. It also gives chance to the patient to rectify any incorrect information, provide any missed detail and expand further. Before proceeding once again check with the patient whether he/she wants to add to the narrative. If the patient agrees with the summary, it means that the clinical has got all the information patient has to provide. If not, then the clinician needs to try another method, to avoid inaccurate presumptions. The clinician should continue to periodically summarize as an ongoing exercise throughout the history taking session. After history taking, it is helpful to give the patient an outline of what the clinician has understood regarding his/her problem.

SIGNPOSTING

During the history taking, it is essential for the clinician to inform the patient what has been already discussed and what is going to be discussed next, this prepares the patient for the next session. Examples of signposting; summarize the discussion up to this point, and finish by saying, "so we've discussed and noted your symptoms and your anxieties regarding them, now we will discuss about your previous dental treatment and the medications taken."

Past Dental History (Form 5)

It is a review of previous dental experiences as well as current dental issues. Any previous dental problems, dental therapy received, and the patient's responses to the therapies are all revealed in the patient's past dental history. The frequency of dental treatment received and the patients' views of previous care can be used to predict future behavior. If the patient is sensitive to specific treatments or has had problems in the past with dental care, alterations or modifications to the therapy or environment may help prevent future concerns. It is critical to understand and appreciate past experiences to provide the best possible treatment. It could be useful to know if local anesthetics were used on the patient before and if there had been any issues. If adverse occurrences, such as post-extraction bleeding (PEB), have not been noted earlier, this would be

Box 2: Pain history.

Orofacial pain is used to describe the pain in the region above the neck, in front of the ears and below the orbitomeatal ridge, as well as the oral cavity. For convenience of diagnosing and treatment planning, orofacial pain can be divided into three types—(1) pulpal, (2) periodontal, and (3) nonodontogenic.

- ✶ In case of pulpal pain, the most likely diagnosis is dentinal pain, reversible, or irreversible pulpitis.
- ✶ In case of periodontal pain, the most likely diagnosis is irreversible pulpitis extending into the periapex, periodontal abscess, and infection of bone.
- ✶ In case of nonodontogenic, refer classification at the end of this chapter and Chapter 19: Orofacial Pain.

To prevent nonessential treatment/extraction, establishing an accurate diagnosis is critical as certain conditions such as trigeminal neuralgia, post-traumatic neuralgia, and headache conditions can mimic odontogenic pain. SOCRATES is the mnemonic to remember details to ask while taking history:

- ✶ **Site:** The patient is asked to point to the source of the pain and outline the affected area. In case of pulpal pain as the pulp does not have any proprioceptive nerve fibers and hence patient will be unable to localize or point to the offending tooth.
- ✶ **Onset:** The patient is asked about the time of initiation of pain and was it sudden or gradual. Also ask for the duration, progression, frequency, any initiating factors
- ✶ **Character:** Nature of pain, is it sharp, a dull aching, throbbing, shock-like, stabbing, burning, constant, and paroxysmal in nature?
- ✶ **Radiation:** Does the pain travel to or from other locations?
- ✶ **Associations:** Ask about presence of other symptoms with the pain such as swelling or pus exudate, nausea, vomiting, fever, lacrimation, rhinorrhea, photophobia, and phonophobia.
- ✶ **Time course:** Ask about the pattern the pain follows whether episodic or it persists. Time distribution (day, night, and random).
- ✶ **Aggravating/relieving factors:** Factors that change the pain. For example, aggravating factors such as cold and hot foods/drinks, relieving factors like certain drugs such as paracetamol, ibuprofen, Tegretol, local anesthetics, and a warm compress.
- ✶ **Severity:** How bad is the pain? Inability to sleep at night due to pain can help to differentiate conditions like acute apical periodontitis, characterized by intense throbbing pain, and severe tenderness to percussion. There are certain scales and questionnaire available to comprehend the severity or degree of pain such as visual analog scale (VAS), numerical rating scale, verbal descriptor scale, faces scale, brief pain inventory, average pain index (API), and McGill Pain Questionnaire (MPQ).

The clinician also needs to ask for reports of any prior investigations, imaging or medications taken.

This history has to be supplemented with clinical findings and other required investigations.

Form 5: Dental information.

Dental Information

	Yes	No	Don't Know
Do your gums bleed when you brush?	❑	❑	❑
Have you ever had orthodontic (braces) treatment?	❑	❑	❑
Are your teeth sensitive to cold, hot, sweets or pressure?	❑	❑	❑
Do you have earaches or neck pains?	❑	❑	❑
Have you had any periodontal (gum) treatments?	❑	❑	❑
Do you wear removable dental appliances?	❑	❑	❑
Have you had a serious/difficult problem associated with any previous dental treatment? If yes, explain:	❑	❑	❑

How would you describe your current dental problem?

Date of your last dental exam:

Date of last dental X-rays:

What was done at that time?

How do you feel about the appearance of your teeth?

JAYPEE BROTHERS

the time to emphasize them. This interaction may disclose particular issues such as inability to floss, food impaction, pain, and fractured restorations or tooth structure, as well as complaints of recurrent ulcers and burning sensations, etc. Prior diagnostic records should be double-checked for accuracy with date. To determine whether additional radiographs are required, radiographs should be checked for diagnostic quality. It is also a good idea to keep track of any medications that the patient has been taking for dental issues.

Medical History

A detailed medical history is crucial and should be reconfirmed on each follow-up visit. The details should be dated and signed by the patient and clinician. Medical history is important as:

- ❖ It facilitates to categorize diseases which may affect oral/dental treatment.
- ❖ It makes the clinician aware of the possible risk of a medical emergency.
- ❖ It helps to discern oral manifestations of any systemic disease.

Most dental offices provide medical history questionnaire for patients to complete before the appointment, which the patient may do online or at the reception, this helps to save time **(Form 6A)**.

All body systems and other key conditions should be included in questionnaire along with a blank box to allow the patients to add anything else of relevance.

It is imperative that the clinician goes through the filled questionnaire at the time of history taking so that missing information, and any relevant medical history observed in the patient's notes can be verified and discussed as these may impact planned oral/dental care.

There is a need to check and verify the exact name, strength, and dosage of the medication the patient is currently taking. The same can be verified with the treating general physician/consultant/pharmacist over the phone and/or the patient should be requested to bring their medical file/prescription at the next appointment.

It is important for the clinician to update his/her knowledge regarding certain medical conditions which substantially impact dental treatment and patient safety and when needed, relevant specialists should be consulted (Refer Chapter 21: Management of Medically Compromised Patients in Dental Practice) **(Form 6B)**.

In case the patient is unable to give proper medical history, then the clinician needs to verify the same by asking relevant questions:

- ❖ For general medical conditions ask if the patient whether he/she is presently consulting a doctor or specialist on a regular basis.
- ❖ In case the patient replies in an affirmative then there is need to gather more details, about the condition, as given above.
- ❖ The clinician needs to enquire about **previous surgery or procedures**, e.g., heart valve replacements. If yes then there is a need to find out the time interval, before starting any oral/dental treatment.
- ❖ Need to record if the patient has **history of allergies**, if yes, then details about type of reaction to the substance (e.g., mild rash vs. anaphylaxis). In cases angioedema, widespread edema; there are two forms, hereditary type which occurs due to a lack of C1 esterase inhibitor can be managed by administration of preoperative fresh frozen plasma (FFP). The nonhereditary type, similar to urticaria, is an allergic response to certain food and drugs and for management opinion of an immunologist is important.
- ❖ In case of female patients, it is essential to know whether a patient is **pregnant** and which gestation period, as this will affect oral/dental treatment. Special considerations are required in the management of pregnant patients such as:
  - The best time for the treatment is second trimester.
  - Consult patient's gynecologist if there is a need to prescribe drugs which should be otherwise avoided.
  - Local anesthetic with adrenaline is acceptable.
  - Syncope should be treated in the left lateral position preventing pressure on the inferior vena cava thus minimizing risk of *supine hypotension syndrome*.
  - Avoid intravenous sedation in the first trimester and the last month of the third trimester and ideally best avoided completely.
  - Nitrous oxide should not be used in first trimester, if necessary; less than 30 minutes exposure should be made with 50% oxygen and repeated exposure must be avoided as it can interfere with vitamin B12 and folate metabolism.
  - Nonessential radiographs should be avoided.
- ❖ It is important to verify with the patient, whether currently he/she is taking any medications either prescribed or over-the-counter, recreational or homeopathy drugs such as follows:
  - Anticoagulants (such as warfarin and dabigatran) or antiplatelets as this increases risk of bleeding.
  - A combined oral contraceptive pill, as this may induce gingival disease and enlargements.
  - Inhalational steroid which can cause local immunosuppression leading to oral candidiasis. The clinician may also see lesions on the posterior palate.
  - Anticonvulsants—as these drugs cause gingival enlargement (e.g., phenytoin, topiramate, and lamotrigine).
  - Calcium channel blockers affect the gingiva and cause gingival enlargement (e.g., amlodipine).
  - Immunosuppressants, these drugs can lead to malignancy and infections (e.g., oral candidiasis and abscess).
  - Bisphosphonates used in postmenopausal women for osteoporosis, predispose to osteoradionecrosis, hence extraction should be avoided.
  - Use of "recreational" drugs such as follows:
    - ♦ Cannabis exacerbates the systemic effects of adrenaline in oral local anesthetics.
    - ♦ Oral methadone can cause rampant caries due to its high sugar content.
    - ♦ Carbamazepine decreases serum methadone levels and methadone enhances the effects of tricyclic antidepressants.
    - ♦ Heroin can cause thrombocytopenia and a low pain threshold. It also delays the absorption of paracetamol and orally administered diazepam.
    - ♦ Amphetamines and ecstasy may induce thrombocytopenia.
    - ♦ Monoaminoxidase inhibitors and tricyclic antidepressants when used concomitantly can trigger a hypertensive crisis.
    - ♦ Lysergic acid diethylamide (LSD) increases the incidence of bruxism and may cause temporomandibular disorder/dysfunction (TMD).

JAYPEE BROTHERS

Form 6A: Medical History

Medical History

It is important to know details about your medical history as these could affect the success of your dental treatment and how we can provide this treatment safely for you. The information you provide is confidential and will be handled in accordance with our privacy policy.

Are you receiving any medical treatment at present? YES/NO

If yes, please provide details: _____ _____

Name of your medical practitioner/specialist: _____

Contact number: _____

Have you been hospitalised in the last 12 months? YES/NO

If yes, please list why: _____ _____

Are you taking any medication or supplements? (these can include herbal preparations, vitamins, supplements, cold/flu treatments, sleeping pills, pain relievers, injections, implants, etc.)

We ask this so that we can take precautions to minimise risks and known negative interactions. YES/NO

If yes please list: _____

_____

PLEASE INDICATE IF YOU HAVE HAD OR ARE BEING TREATED FOR ANY OF THE FOLLOWING:

	Yes	No	Do not Know		Yes	No	Do not Know
Heart Condition/Heart Surgery				Blood Transfusion			
Blood Pressure (High/Low)				Blood or Bleeding Disorder			
Circulatory Problems				Anemia			
Valve Prolapse Heart Valve/Pacemaker				Bruise or Bleed Easily			
Stroke				Leukemia			
Rheumatic Fever				Cancer			
Polymyalgia				Tumor History			
Lupus (SLE)				Radiation/Chemotherapy			
Diet (Special/restricted)				Neurological Disorder			
Digestive Problems				Epilepsy or Seizures			
Gastroesophageal Reflux				Fainting or Dizzy Spells			
Gastric Ulcers				Anxiety			
Kidney/Renal Disease				Depression			
Liver Problems/Jaundice				Psychiatric Condition			
Diabetes				Osteoporosis			
Thyroid Disease				Arthritis/Rheumatism			
Emphysema				Bone Disorder or Disease			
Chronic Cough				Knee Reconstruction			
Lung Condition				Prosthetic Implant			
Bronchitis				Artificial Joints (hip, knee)			
Asthma				Jaw/Head/Neck Injury or Pain			
Sinus Trouble				Steroid Therapy			
Hay fever				Transplant (organ, marrow)			
Allergies (medicine, antibiotics, pain relievers,				Infectious Disease			
anesthetic, antibiotics, contact allergies)				Blood Borne Virus (AIDS/HIV, Hep B/C)			
Latex sensitivity				Alcoholism			
Snoring/Sleep Apnea Hepatitis				Drug Dependency			
				Any Other			

If you have answered yes or other, please provide details: _____

_____

Any other relevant information: _____

_____

JAYPEE BROTHERS

Form 6B: Modification of dental care as per medical complexity status (MCS) of the patient.

Modification of dental care as per medical complexity status (MCS) of the patient		
Three queries which may vary as per severity of the underlying conditions 1. Chances of patient experiencing an adverse event during dental procedure 2. Nature and severity of the adverse event 3. Is there an appropriate setting to treat the patient		
Four major concerns to be addressed 1. Underlying potential for compromised hemostasis from medication or disease 2. Increased susceptibility to infections 3. Drug interactions and reactions 4. Stress bearing capacity of the patient for planned dental treatment		
The designated MCS at the onset may be modified as the treatment progresses		
Major Categories	***Subcategories***	***Example***
MCS 0 Patients with no medical problems		Healthy patient
MCS 1 Patients with controlled or stable medical conditions	**MCS 1A**—No anticipated complications	Patient with controlled hypertension
	MCS 1B—Minor complications which may be addressed in the dental chair	Patient suffering from petit mal epilepsy which is controlled with medications
	MCS 1C—Major complications which need to be addressed by a medical provider and/or in hospital setting	A patient with known history of penicillin allergy
MCS 2 Patients with uncontrolled or unstable medical conditions	**MCS 2A**—No anticipated complications	A hypertensive patient with blood pressure reading of 150/95 mm Hg without any target organ disease
	MCS 2B—Minor complications which may be addressed in the dental chair	Patient with metabolic or endocrinal disorders like diabetes mellitus with a glycosylated hemoglobin of 11%
	MCS 2C—Major complications which need to be addressed by a medical provider and/or in hospital setting	Patient with uncontrolled congestive cardiac failure
MCS 3 Patient with medical conditions which may be associated with sudden acute exacerbation resulting in high risk of mortality		A patient with unstable angina

- ♦ Anabolic steroids may increase carbohydrate consumption with its unavoidable effects on the dentition and also may interfere with blood clotting.

As many patients do not consider inhaled or topical medicines as "drugs," it becomes important to ask them about such medicines specifically.

Many a times the patient may forget or intentionally omit certain medical conditions, so it is beneficial for the clinician do a quick review of the same.

- ❖ Clinician may causally enquire about history of some common symptoms which may highlight relevant conditions. They are as follows:
  - ■ Fevers, evening rise in fever could be diagnostic of tuberculosis.
  - ■ Reduced appetite could indicate upper respiratory tract infection, gastritis, and chronic liver disease.
  - ■ Weight loss could indicate diabetes, thyroid, and tuberculosis.
  - ■ Fatigue is commonly seen in anemia and malignancy.
  - ■ Skin rashes diagnostic of allergies, viral or fungal infections, and parasitic infections.
  - ■ New lumps/swelling, need to be investigated and biopsied for chronic microbial infections or malignancies.
  - ■ Bleeding/bruising can indicate blood dyscrasias.
  - ■ Long-term corticosteroid therapy; steroid supplementation in the form of an increased dose of corticosteroid is needed before treatment, to prevent acute adrenal insufficiency as surgical extractions and dental implants placement or treatment under general anesthesia presents a potential risk.
- ❖ Sometimes certain conditions which the patient might be unaware about are manifested in the oral cavity and the clinician should be able to spot them and advice investigations before starting any oral/dental treatment such as follows:
  - ■ Anemia and blood dyscrasias; oral manifestations of are seen as glossitis in cases of Vitamin B12 deficiency. These patients have an increased the risk of bleeding. Patients having sickle cell anemia are high risk patients for general anesthesia.
  - ■ Leukemias is presented in the oral cavity as gingival enlargement, the gingiva has a typical bluish hue, these patients have an increased bleeding risk and high susceptibility to oral infections.

The clinician on probing the patient for some specific symptoms can diagnosis that the patient may be suffering from certain systemic ailments, which either need to be treated or the patient may be on medications which they did not disclose. It is essential that the treating physician's consent and clearance be taken before starting any oral/dental treatment.

Cardiovascular System

The symptoms to be asked for are as follows:

- ❖ Chest pain involving differential diagnosis as myocardial infarction, angina, esophageal reflux, hyperventilation, musculoskeletal, pleuritic (for example, pulmonary

JAYPEE BROTHERS

embolism), referred pain from the abdomen. The patient is asked if pain starts at rest or after exertion and how much exertion.
- ❖ Dyspnea—if breathlessness starts at rest or after exertion. Paroxysmal nocturnal dyspnea (breathlessness during sleep) or orthopnea (breathlessness on lying down)
- ❖ The presence of palpitations.
- ❖ The history of rheumatic fever and/or infective endocarditis
- ❖ Claudication pains and what precipitates them.
- ❖ Syncope (loss of consciousness), etc.

In case the patient has:
- ❖ Valvular heart disease, antibiotic prophylaxis may be needed as there is an increased risk of infective endocarditis.
- ❖ Arrhythmias, angina, patients suffering from this disease have high risk of bleeding as most of them are on anti-coagulants/antiplatelets, hence certain local anesthetics could be contraindicated to reduce the risk of medical emergencies.

Respiratory System

The symptoms to be asked for are, dyspnea i.e., shortness of breath, wheezing, cough, hemoptysis (coughing up blood), etc.
In case the patient has:
- ❖ Asthma and chronic obstructive pulmonary disease, there is an increased risk of medical emergencies, oral adverse effects of incorrectly administered steroid inhalers and difficulties in dental chair positioning.

Gastrointestinal System

The symptoms to be asked for are nausea or vomiting, indigestion, change in bowel habit, dysphagia (difficulty swallowing), odynophagia (pain when swallowing), hematemesis (vomiting blood), spleen, or liver problems.
In case the patient has:
- ❖ Gastroesophageal reflux disease, acid reflux causes erosion of the lingual surface of mandibular anterior teeth.
- ❖ Inflammatory bowel disease, is manifested ulcers in the oral cavity as (e.g., Crohn's disease).
- ❖ Alcoholism and hepatitis, this patient will have an increased risk of bleeding, altered metabolism of drug and issues with infection control.

Neurological System

The symptoms to be asked for are seizures, headache, facial pain, motor or sensory disturbance i.e., weakness, tremor, numbness, problems related to coordination, confusion, muscle wasting, weakness, or fasciculations.
In case the patient has:
- ❖ Epilepsy, if the patient is under treatment, he/she may have fibrous enlargement of the gingiva. The most common medical emergencies risk, is that the patient may have a seizure when the oral/dental treatment is in progress.
- ❖ Parkinson's disease, the patient is compromised with reduced ability to perform oral hygiene measures, and hence there may be risk for secondary infections.

Musculoskeletal System

The symptoms to be asked for are joint pain/stiffness (including TMJ), swelling in the joint, gait (could also be due to neurological problems), locomotor and manual impairments secondary to musculoskeletal disorders.
In case the patient has:
- ❖ TMJ dysfunction, the patient may have pain and inability to open the mouth, so working on this patient will be under restricted access.

Genitourinary System

History of repeated or chronic urinary tract infections and patient taking antibiotics could be of significance.

Psychiatric History

The psychiatric history is not included as routine but may be relevant in some cases.

After this process, patients may be assigned an **American Society of Anesthesiologists (ASA) classification:**
- ❖ ASA I Healthy
- ❖ ASA II Mild systemic disease—no functional limitation
- ❖ ASA III Severe systemic disease—definite functional limitation
- ❖ ASA IV Severe disease—constant threat to life
- ❖ ASA V Moribund
- ❖ ASA VI Brain dead patient—organs to be removed for purpose of donation.

This classification facilitates communication between treating clinicians and is also referred to in some protocols. Especially relevant when the patient must be given general anaesthesia.

Personal/Social History

Social history is often neglected or not really probed into but it is an essential component of the complete evaluation of a patient. Treatment or the process in which it is to be provided is influenced by personal history. The patient's smoking and tobacco habits, gutkha chewing and alcohol consumption should be noted and quantified. Patient's dietary habits also need to be documented. The patient may need to be probed further regarding the use of "recreational" drugs or complementary therapies. It is important for clinicians to know when identifying patients who smoke that there is a need to counsel the patient and if he wishes to try and quit, information should be given about availability of smoking cessation services.

While recording the social history the clinician gets a chance to connect with the patient as an individual person, the social history can also disclose essential early clues to the existence of disease, and guide the physical examination and test-ordering policies, and simplify the establishment of cost-effective, evidence-based care. For example, a patient who was a regular golfer informed his physician that he no longer golfed due to dyspnea on exertion, this should be tip the clinician into diagnosing that the patient is developing the first signs of heart failure, lung disease, or anemia!

Disorders of inherited or of a genetic origin should be recorded, for example, diabetes, heart disease, cystic fibrosis, osteoporosis and several types of cancer. Although genetic components can enhance the risk of developing such afflictions, appropriate steps such as providing better medical advice and care to the patients at a younger age reduces their chances of developing the disease.

Family history can impact the way one looks, how one acts, and the health conditions from which one suffers and it can also impact oral health, for example, the tooth structure, shape and susceptibility to caries.

JAYPEE BROTHERS

Information regarding the patient's home circumstances such as presence of another *"competent"* adult is important for some cases like intravenous sedation or day care general anesthesia, where the patient needs to be accompanied for 24 hours after the procedure.

Clinical Examination

It is the process of evaluating the patient's extra oral and intra oral structures and detecting signs and symptoms of systemic disease to formulate diagnoses. During this process, any subtle sign, symptom, and variations from normal must be keenly observed and noted by the clinician to detect pathologic conditions and etiologic factors. The process includes the following:

Inspection (Visual Examination)

It is the initial step in clinical examination which means to look at the person or body part.

Palpation (Digital Examination)

It is a process of examining using fingers or hands. It is performed by the clinician by feeling the organ or body part to examine its shape, size, location, consistency, texture, and tenderness.

Percussion

It is a process of tapping body parts with short, sharp strikes of the fingers and/or instrument. It is done to ascertain the following:

- ❖ The size, consistency, position, and borders of the body organs.
- ❖ The presence or absence of fluid or air in various body parts.
- ❖ In the oral cavity, the tooth is percussed by the light tapping to elicit pain and determine whether there are periodontal or periapical infections.

Auscultation

It is process of listening to the sounds of the body during clinical examination which is done using stethoscope. During this process, clinician listen to the sounds from heart, lung, intestine, and temporomandibular joints to evaluate frequency, intensity, duration, number, and quality of sound.

Vital Signs

These are the assessment of the body's most basic functions. There are four routinely monitored vital signs which are helpful in detecting or monitoring medical problems. These include:

Blood Pressure

This is the force of the blood pushing against the artery walls as the heart contracts and relaxes. During contraction of heart, blood is pumped into the arteries which results in the highest blood pressure. When the heart relaxes (it gets filled with blood), the blood pressure reduces.

Blood pressure is measured as two numbers. The higher number, or **systolic pressure**, refers to the pressure inside the artery when the heart contracts. The lower number, or **diastolic pressure**, refers to the pressure inside the artery when the heart is at rest. The recording of blood pressure is done as "mm Hg" (millimeters of mercury). The instrument used is known as mercury manometer or sphygmomanometer, or a digital blood pressure machine.

Blood pressure is measured indirectly in the upper extremities using blood pressure cuff and stethoscope. The technique is as follows:

- ❖ The patient is seated comfortably without crossing the legs.
- ❖ Before cuff placement, brachial artery is detected.
- ❖ The placement of cuff is done on uncovered upper arm, with the lower border placed about an inch above the antecubital fossa.
- ❖ As the cuff inflates, radial pulse is palpated until its disappearance.
- ❖ Then cuff is inflated to an additional 20–30 mm Hg.
- ❖ Stethoscope is positioned over the brachial artery which was previously located in antecubital fossa.
- ❖ Pressure release valve is rotated gradually, permitting the needle to move at a rate of 2–3 mm Hg/s.
- ❖ As the needle descends, the pressure at the point when the beating sounds (Korotkoff sounds) first become audible is recorded as the systolic pressure.
- ❖ As the needle proceeds to descends, beating sounds first become louder, then diminish gradually and reach a point at which the weakened beats disappear completely.
- ❖ This point is the most reliable index of diastolic pressure.

Blood pressure is graded as follows:

- ❖ Normal blood pressure, systolic less than 120 and diastolic less than 80 (120/80)
- ❖ Elevated blood pressure, systolic 120–129 and diastolic less than 80
- ❖ Stage 1 high blood pressure, systolic 130–139 or diastolic 80–89
- ❖ Stage 2 high blood pressure, systolic 140 or higher or diastolic 90 or higher

In **hypertension**, i.e., high blood pressure, there is an elevated risk of heart failure and stroke as arteries may show additional resistance against the flow of blood which prompt the heart to pump stronger to circulate the blood.

Pulse Pressure

It is defined as the difference between the systolic and diastolic pressures.

Temperature

Various factors such as recent activity, time of day, food, and fluid consumption and in women, the stage of the menstrual cycle, cause body temperature to vary. The normal temperature of body ranges from 97.5° to 98.9°F (36.4°–37.2°C) for a healthy adult. It can be recorded as follows:

- ❖ Orally—recorded by mouth using the classic glass thermometer or digital thermometer which uses an electronic probe to measure body temperature.
- ❖ Rectally—measured using a glass or digital thermometer, it tends to be 0.5–0.7°F higher than when recorded orally.
- ❖ Axillary—taken under the arm using a glass or digital thermometer and it tends to be 0.3–0.4°F lower than temperature taken orally.
- ❖ By ear—a special thermometer is used to record the temperature of the ear drum that reflects core temperature of the body, i.e., the temperature of the internal organs.
- ❖ By skin—the temperature of the skin on the forehead is quickly measured by a special digital thermometer, now routinely used for COVID-19 screening.

Body temperature is considered abnormal when raised due to **fever** or lowered in **hypothermia**. When body temperature increases about 1° or more over the normal temperature of

JAYPEE BROTHERS

98.6°F, it indicates fever. A drop in the body temperature below 95°F is interpreted as hypothermia. During dental examination, temperature is recorded when a patient has febrile signs or symptoms with presence of an oral abscess, a mucosal or gingival infection, or fascial space infection.

Respiration Rate (Breathing)

It is the number of breaths per minute taken by a person. It is measured at rest by counting the number of times the chest rises in a minute, thus counting number of breaths for 1 minute. Fever, illness, and other medical conditions like cardiopulmonary disease can cause an increase in the respiration rate. Observation of any difficulty in breathing is also important along with checking respiration. Normal respiration rates at rest range from 12 to 16 breaths per minute for an adult.

Hyperventilation

A rapid, prolonged, deep breathing, or sighing may be shown by apprehensive patients, causing decrease in carbon dioxide levels resulting in disturbing symptoms and signs, including tingling in the fingers and toes, perioral numbness, nausea, and carpopedal spasms.

Pulse Rate

It is an estimation of the heart rate, or the number of times the heart beats per minute. The heart and pulse rate indicates the following:

- ❖ Rhythm of the heart
- ❖ Strength of the pulse

The carotid artery at the side of the trachea or the radial artery on the thumb side of the wrist are palpated to determine the pulse rate. It should be palpated for at least 1 minute to detect rhythm irregularities.

A healthy adult's pulse rate ranges from 60 to 100 beats per minute. **Tachycardia** is defined as a fast pulse rate of more than 100 beats per minute, whereas **Bradycardia** is defined as a slow pulse rate of fewer than 60 beats per minute. Exercise, illness, injury, and emotions can cause the pulse rate to rise and fall. Females beyond the age of 12 have a quicker heart rate than males. Athletes that perform a lot of cardiovascular fitness such as runners, may have heart rates near 40 beats per minute and have no difficulties.

The typical pulse is made up of a succession of rhythmic beats that happen at regular intervals. The pulse is called **irregular, dysrhythmic**, or **arrhythmic** when the beats occur at irregular intervals.

Oxygen Saturation

It is an estimate of amount of hemoglobin attached to the molecular oxygen at a given point of time. Percentage of oxyhemoglobin in blood is measured and is denoted as the arterial oxygen saturation (SaO_2) and venous oxygen saturation (SvO_2). This vital parameter defines the blood oxygen content and oxygen delivery. It is measured by an instrument called **pulse-oximeter**. Normal values for pulse oximeter range from 95 to 100%. **Hypoxemia** is considered when the readings are below 90%. Headache, coughing, shortness of breath, rapid heart rate, wheezing, confusion, and blueness of the skin and mucus membranes (cyanosis) are the most common symptoms of hypoxemia.

General Examination

The assessment and evaluation of the patient should commence the moment he/she walks into the operatory. The hints to the patient's medical history can be provided by his/her general and facial appearance, mobility, skin, even smell, and patient's personal appearance and overall cleanliness gives indication about patient's ability to perform routine self-care procedures and also about their emotional/mental health, sometimes socioeconomic status also. Evaluation of patient's general appearance, symmetry, gait, mobility, any facial asymmetries, lesions, or scars should be continued during history taking.

For example, for patient in wheelchair, the reason behind this condition should be mentioned in the medical history as it can affect the oral/dental treatment. For instance, if the patient has suffered from stroke, then starting from need of assistance to transfer the patient to the dental chair and also the medications the patient is taking would require modification in the oral/dental treatment, also due to physical limitations, it may be troublesome for the patient to maintain adequate oral hygiene. If mobility of the head and neck is reduced, it would be difficult for the clinician and the patient to sit through long oral/dental procedures.

The patient's exposed skin (head, face, neck, arms, and hands) also gives clues to the patient's medical status, for example, in case there are petechiae, ecchymosis, or hematoma, then the patient may be asked for any bleeding problems, or medications such as blood thinners. When yellowish discoloration of skin occurs, possible history of jaundice or liver problems may be elucidated. Before continuation, examination of the patient's hands should be done for evidence of habits such as tobacco use and signs such as pitting, human papillomavirus (HPV) infections, signs of arthritis and systemic diseases. Clubbing of the fingers may be a sign of heart or respiratory problems, so the clinician needs to enquire with the patient about relevant history and possible etiology and document the findings. The following categories can be considered and noted:

- ❖ Signs of distress or anxiety
- ❖ Orientation
- ❖ Posture, motor activity and coordination, and gait
- ❖ Dress, grooming, and personal hygiene
- ❖ Skin color and any obvious lesions
- ❖ Facial expressions
- ❖ Body build and asymmetries
- ❖ Odors (body or breath), e.g., smoker, alcohol, ketones, and renal disease
- ❖ Lesions or scars

Extraoral Examination

The head and neck and oral examination follows next. The findings relate to one of three categories:

- ❖ Normal—found in the majority of people
- ❖ Atypical—not found in all people, but still within acceptable limits (a variation of normal)
- ❖ Pathologic—includes infections, trauma, neoplastic growth, developmental abnormalities that result in functional issues, immune system disorders, and more.

It is best to follow the same examination sequence every time. Consistency allows the physician to conduct the examinations swiftly, efficiently, and with the maximum level of awareness possible in order to distinguish between abnormal and normal circumstances.

Head and Face (Asymmetry and Profile)

The doctor should stand in front of the patient and quietly begin by looking at the patient's head and neck, with special attention paid to the area around the jaws.

JAYPEE BROTHERS

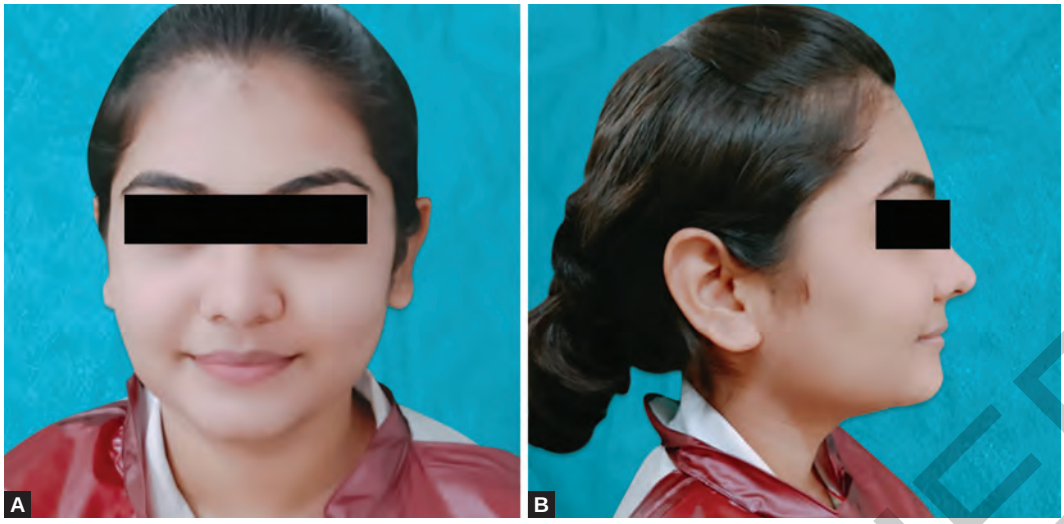

Figs. 4A and B: Facial symmetry and profile: (A) Frontal; (B) Lateral.

(*Courtesy:* Dr Pradnya Jadhav, Professor and Head; Dr Rohit Gadda, Reader; Dr Neha Patil, Assistant Professor, Department of Oral Medicine and Radiology, MGM Dental College, Navi Mumbai, Maharashtra, India)

The patient should be made to sit upright in the chair. Although some asymmetries are found in most patients, but detection of significant asymmetries on comparison of one side to the other are of vital importance **(Figs. 4A and B)**.

The asymmetry could be of bone or soft tissue, acute or chronic, or the result of a previous procedure. Swelling (inflammatory, infectious, traumatic, etc.), neoplastic growths, muscle atrophy or hypertrophy, agenesis or hyperplasia of a partial or entire piece of the unilateral facial skeleton, and neurological abnormalities can all cause asymmetry. Asymmetry has also been linked to malocclusions and temporomandibular joint dysfunction. It could be the result of an injury, such as a fall, in which the patient has a disturbed occlusion or a mandibular fracture. There are a variety of syndromes and illnesses that cause abnormalities in the form and symmetry of the face, (e.g., acromegaly's coarse and swollen features, Cushing syndrome's moon facies, and Bell's palsy unilateral paralysis).

Skin, Hair, and Nails

The doctor should evaluate the exposed skin of the head and neck region for any worrisome lesions.

When checking and palpating the occipital and cervical nodes, the doctor can inspect the skin of the neck and scalp. While palpating the auricular nodes, the area behind and surrounding the ear can be examined. Any lesions identified during the inspection should be discussed with the patient, as should any lesions on the covered region of the body.

Details regarding the patient's history, as well as symptoms including discomfort, pruritus, and unusual sensations, might help determine a differential diagnosis or whether the patient should be referred to a specialist. Actinic keratosis and basal cell carcinomas can be found on the dorsal surfaces of the hands, as well as the bridge of the nose, infraorbital regions, and ears. Melanoma can be identified by raised, darkly pigmented lesions with uneven borders. A suspicious nevus size and physical characteristics should be documented. These and other lesions that demonstrate the ABCDE's of malignant skin lesions (**asymmetry, border, color, diameter, and evolution**) should be referred for further investigation. The changes in nevi and other pigmented lesions should also be monitored by the patient.

Systemic disease may be linked to changes in the skin and nails. For example, cyanosis can suggest cardiac or pulmonary failure, pigmentation can indicate hormonal imbalances, and petechiae or ecchymoses can indicate a blood dyscrasia or bleeding disease.

Alterations in the fingernails (e.g., clubbing, indicative of cardiopulmonary insufficiency, white discoloration indicative of cirrhosis, splinter hemorrhages indicative of infective endocarditis).

Any evidence of physical abuse, especially in the case of children and women, should be noted and the patient should be referred for counseling and help.

Following that, the cutaneous findings should be compared to the intraoral findings **(Figs. 5A to F)**.

Eyes

A visual assessment can provide a clinician with insight into a variety of systemic disorders. The clinician should ask the patient to take off his or her glasses and examine his or her eyes and surrounding tissues for any abnormalities. The tissue around the eyes is usually detected with lesions related with ultraviolet (UV) exposure, such as basal cell carcinoma. Swelling in the orbital region due to a maxillary tooth infection. Some indicators to look for include lid lag and weak convergences, which signal systemic disorders such as hyperthyroidism. Xanthomas of the eyelids, as well as arcus senilis in the elderly, are linked to hypercholesterolemia.

The color of the sclera and the size of the pupils should be examined closely. Xerostomia and dryness of the conjunctiva and sclera may be linked. The sclera becomes yellowish in cases of jaundice, indicating an untreated case of hepatitis A or B, other liver failure, or a blood issue. When patients with osteogenesis imperfecta have blue sclera, the practitioner should be aware that the dentin structure may have changed. The sicca condition or an allergy can cause reddening of the conjunctiva. Pupil size **(Fig. 6)** will aid in the identification of people who are potentially addicted and at danger of medical emergencies. ***Symblepharon*** is a condition in which one or both eyelids are partially or completely adhered to the eyeball, is linked to the benign mucous membrane pemphigoid, lichen planus, and trauma such as burns. ***Pterygium*** is a condition in which the conjunctiva grows out of control and begins to cover areas of the sclera and obscuring vision. A reference to a specialist/ophthalmologist should be made in such circumstances. The corneal arcus or xanthelasma is a sign of ***dyslipidemia***, which can lead to

JAYPEE BROTHERS

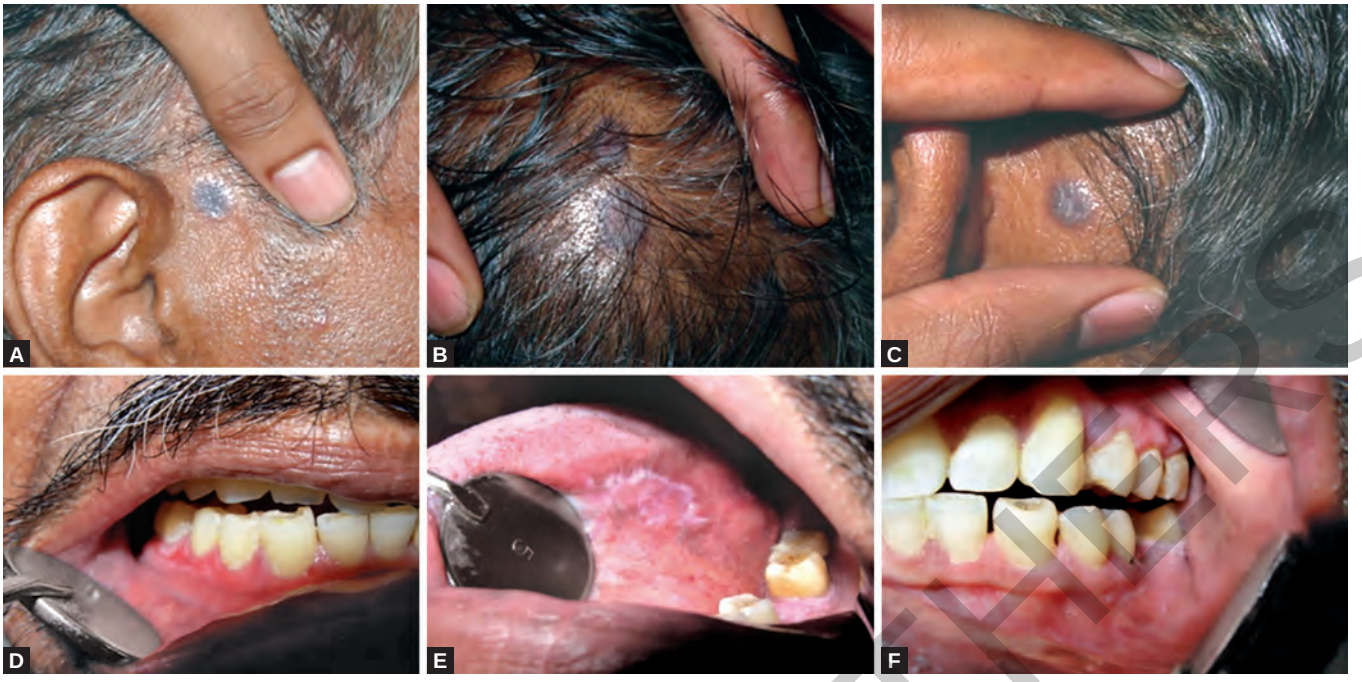

Figs. 5A to F: Examination of the skin, hair region during extraoral examination of the face helps detect skin lesions of lichen planus observed on the face and scalp. Lesions are also seen intraorally.

(*Courtesy:* Dr Kaustubh Sansare, Professor and Head; Dr Sonal Vahanwala, Associate Professor, Department of Oral Medicine and Radiology, Nair Hospital Dental College, Mumbai, Maharashtra, India)



Fig. 6: Eyes and surrounding tissues.

(*Courtesy:* Dr Pradnya Jadhav, Professor and Head; Dr Rohit Gadda, Reader; Dr Neha Patil, Assistant Professor, Department of Oral Medicine and Radiology, MGM Dental College, Navi Mumbai, Maharashtra, India)

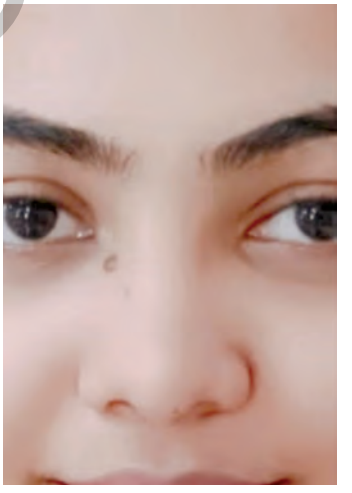

Fig. 7: Nose and sinus area should be carefully observed extraorally for swelling and/or asymmetry.

(*Courtesy:* Dr Pradnya Jadhav, Professor and Head; Dr Rohit Gadda, Reader; Dr Neha Patil, Assistant Professor, Department of Oral Medicine and Radiology, MGM Dental College, Navi Mumbai, Maharashtra, India)

heart disease, diabetes, or stroke. **Proptosis** is a symptom of an endocrine condition (Graves' disease) or potentially cancer. If you notice proptosis after a facial injury, it could be a sign of a retrobulbar hemorrhage.

Ears

A wrinkle/crease in the earlobe could indicate coronary artery disease. On and around the ears, malignant or possibly malignant lesions (e.g., skin cancer) can be discovered. Ramsay Hunt syndrome is characterized by a vesicular eruption in the area around the ear.

Nose and Para Nasal Sinuses (Fig. 7)

Asymmetry, deviation, or malformation of the nose, as well as the paranasal sinuses, should be observed and noted. Because of the frequent mouth breathing, chronic maxillary sinusitis it may have an impact on surgical and prosthetic operations. Tenderness in the frontal and maxillary sinuses should be palpated.

Lips

Symmetry, tissue consistency, and texture should all be checked.

Normal Clinical Appearance (Figs. 8A and B)

Skin, muscle, glands, and mucous membrane make up the lips, which are two incredibly sensitive, movable pleats. They establish the anterior limit of the oral cavity by circumscribing the mouth orifice. Lip skin has a sharp, often raised line at the end. The normal lip tissue is resilient, smooth, and soft, with

JAYPEE BROTHERS

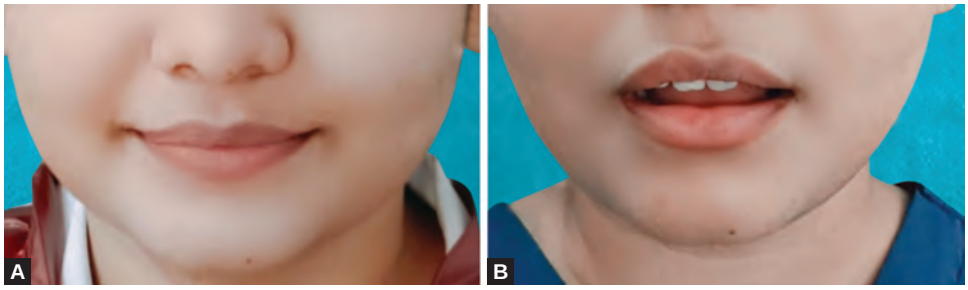

Figs. 8A and B: Lips are the anterior opening of the oral cavity: (A) Vermillion outline; (B) Corner of the Lips.

(*Courtesy:* Dr Pradnya Jadhav, Professor and Head; Dr Rohit Gadda, Reader; Dr Neha Patil, Assistant Professor, Department of Oral Medicine and Radiology, MGM Dental College, Navi Mumbai, Maharashtra, India)

a uniformly pink color with a noticeable and even vermillion border, which is the transitional zone between the skin and the mucous membrane and is known as the red zone, vermilion zone, or vermilion border. The vermilion zone of the lips ranges in color from pink to red. The lip's surface epithelium is nonkeratinized, making it transparent. The more melanin a person has in their skin, the more this pigment causes their lips to turn purple to brown in color.

Pathological Appearance

The color of the vermilion zone changes with age and environmental factors, fissuring, and thinning of the epithelium, and becomes more bluish to purple. A vague or fragmented vermillion border with white patches indicates significant sunlight exposure at the start. Indentations, pitting, and ulceration of the lip tissues are more advanced indicators of injury. The signals and consequences of continuing exposure should be explained to the patient.

The commissures of the lip should not be cracked or dry, as this could indicate angular cheilitis, ***Candida albicans***, nutritional inadequacies, or lesions caused by the human herpes virus 1 or 2. The contact dermatitis or allergic reactions to food, cosmetics, lip balms, dental goods such as toothpaste, and other environmental elements can cause sores on the lips. Lip chewing, biting the lips, and licking the lips can cause chapping and abrasion of the tissues around the lips (Refer Chapter 13: Diseases of Lip).

Neck

It should be inspected for scars which may indicate previous surgery such as thyroidectomy, tracheostomy, and neck dissection for head and neck cancer. The presence of masses in the neck should be assessed by **(Figs. 9A and B; Flowcharts 1 and 2)**.

- ❖ Site—this can help narrow the differential as per the location in the anterior triangle/posterior triangle mid-line.
- ❖ Size—the width, height, and depth of the mass should be noted.
- ❖ Shape—of the mass should be determined, whether it is well defined or irregular.
- ❖ Surface (overlying skin changes), it should be checked for erythema, ulceration, or punctum or whether it is smooth and shiny.
- ❖ Consistency of the mass should be palpated whether it is soft, rubbery, hard, nodular or irregular.
- ❖ Compressibility of the mass will help differentiate vascular lesions.
- ❖ Fluctuance—the presence suggests that the mass is a fluid-filled lesion, could be a cyst.
- ❖ Transillumination—this test helps to determine whether the mass is fluid-filled, for example, a cystic hygroma.
- ❖ Pulsatility of the mass will again confirm vascular origin and carotid body tumor/aneurysm.
- ❖ Temperature—a rise in temperature indicates an inflammatory or an infective cause.
- ❖ Relation to underlying and overlying structures need to be determined. Tissue tethering and mobility can be checked by asking the patient to turn his/her head.
- ❖ Auscultation—this helps to assess for bruits and confirming the presence of carotid aneurysms.

Lymph Nodes

Lymph nodes are not palpable under normal situations. These normal nodes are small (less than 1 cm), nontender, and movable



Figs. 9A and B: Neck: (A) Thyroid swelling; (B) Postoperative scar.

JAYPEE BROTHERS

Flowchart 1: Check lump in relation to site.

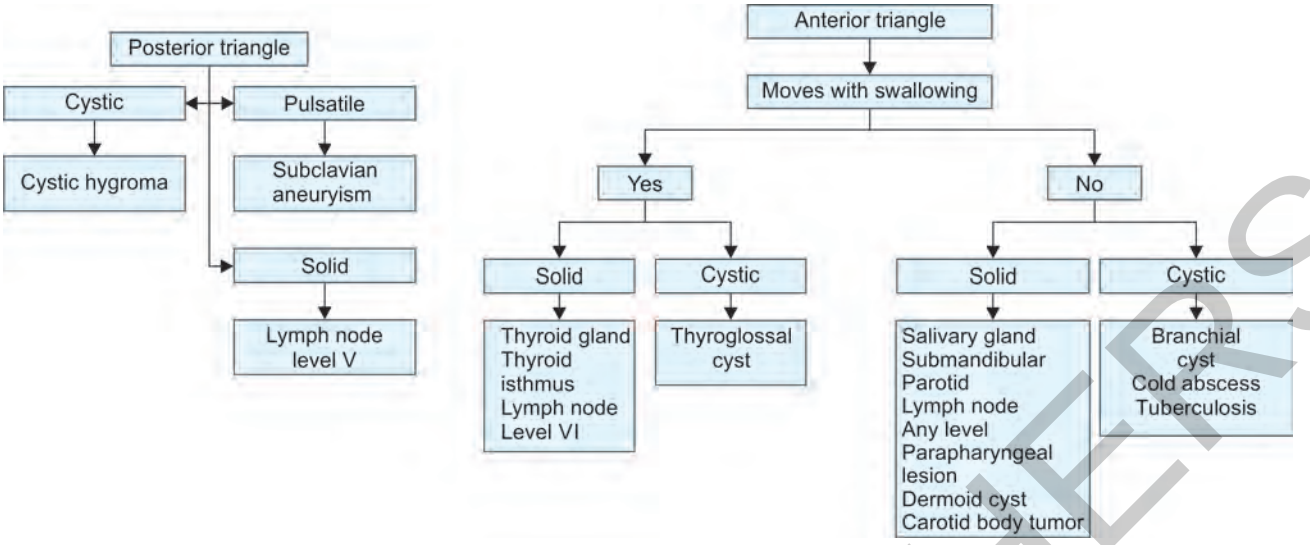

Flowchart 2: Neck lump in relation to site.

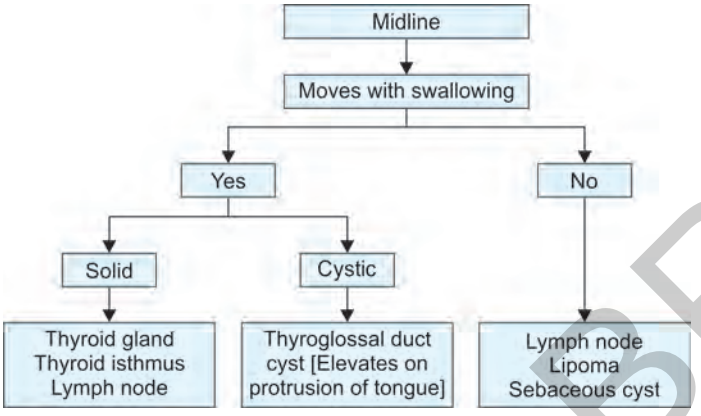

when probed (may feel like a pea or lentil). When the nodes are perceptible, the size, location, quantity, consistency, tenderness, and mobility of the nodes must be identified.

To palpate the cervical lymph nodes, the patient should be encouraged to relax and sit up in the dentist chair without extending the neck. The doctor should stand behind the patient and gently flex the neck. Each group of lymph nodes should be palpated with the pads of the fingertip in a small rolling motion.

The lymph node groups to be palpated are as follows:

- ❖ Submental **(Fig. 10A)** are palpated with tips of the fingers just posterior and below the anterior lower border of the mandible.
- ❖ Submandibular **(Fig. 10B)** these can be felt by tugging or moving the tissues under the chin up and over the mandible's inferior border. Request that the patient to use his or her tongue to press hard against the roof of the mouth. This will provide access to the muscles and any pathology connected with the lymph node locations beneath the mandible.
- ❖ Preauricular **(Fig. 10C)** palpated bilaterally in front of the ear with the pads of the index, middle and ring fingers.



Figs. 10A to H: Lymph node digital palpation: Submental lymph nodes (A); Palpation of the submandibular lymph nodes (B) are palpated using a cupped hand; The preauricular (C) and postauricular nodes (D); The occipital lymph nodes (E) are palpated using the pads of the index, middle and ring fingers, bilaterally, the clinician should simultaneously observe the surrounding skin in this area. The lymph nodes cervical chain, the nodes medial to the sternocleidomastoid muscle are palpated using a bi-digital technique for the anterior nodes (F) and the nodes posterior to the muscle are palpated using a bimanual technique (G); The supraclavicular lymph nodes (H) are examined bilaterally using digital compressions just superior to the clavicle.

(*Courtesy:* Dr Pradnya Jadhav, Professor and Head; Dr Rohit Gadda, Reader; Dr Neha Patil, Assistant Professor, Department of Oral Medicine and Radiology, MGM Dental College, Navi Mumbai, Maharashtra, India)

JAYPEE BROTHERS

- ❖ Postauricular **(Fig. 10D)** palpated bilaterally in behind the ear with the pads of the index, middle, and ring fingers.
- ❖ Occipital **(Fig. 10E)** are palpated about one inch above and below the hairline, on the posterior aspect of the neck.
- ❖ The cervical chain (upper, middle, and lower) **(Figs. 10F and G)** is palpated using a bidigital approach medial to the sternocleidomastoid muscle and the nodes posterior to the muscle using a bimanual technique.
- ❖ Supraclavicular **(Fig. 10H)** digital compressions slightly above the clavicle are used to assess them.

It is important to look for enlarged palpable nodes, fixed nodes, tender nodes, and if the palpable nodes are single or in groups. Malignancy is suspected in single or several nontender, fixed nodes. The tender nodes appear in clusters in the context of an acute infection or infection drainage. Even after an infection has cleared, some lymph nodes, particularly those in the submandibular group, may remain swollen and palpable.

In case there are palpable lymph nodes the clinician should look for signs of infection along the drainage pathway and systemic infection, and malignancy is always to be kept in mind. The patient's personal history should be checked for habits such as smoking and alcohol, with enquiry for weight loss, change of voice, dysphagia, otalgia, night sweats, to rule out oral cancer, especially if there is a unilateral enlarged lymph node.

Salivary Glands (Figs. 11A to D)

If a submandibular mass or swelling is present, a bimanual/bidigital palpation **(Figs. 11C and D)** should be performed to see if the mass is the submandibular gland. This is accomplished by gently placing one finger into the mouth to palpate the floor and pushing the submandibular mass upwards from the outside with the other hand. This method, a salivary stone can be palpated, which can be linked to a history of increased swelling or pain around mealtime. The normal gland will not be perceptible, thus infection, obstruction, immune system problem, or a neoplastic development should be suspected if there is induration and pain. Alcoholism, diabetes, Sjögren's syndrome, eating disorders, human immunodeficiency virus (HIV) infection, and numerous malignant/nonmalignant illnesses involving the salivary glands are all linked to nontender parotid enlargement (Refer Chapter 18: Salivary Gland Disorders).

Thyroid Gland (Figs. 12A and B)

On either side of the trachea, the thyroid gland is positioned inferior to the larynx and just superior to the clavicles. It is made up of two lobes that are connected by an isthmus. A bimanual approach is used to palpate the gland. The doctor should use one hand to support the tissue and the other to palpate the gland on one side before repeating the technique on the opposite side of the gland. The thyroid gland is not visible nor palpable in its natural state. The area surrounding the gland should rise smoothly and symmetrically during swallowing. The increased frequency of thyroid cancer necessitates a thorough examination of this area.

Temporomandibular Joint

Examination of joints should be done in the following pattern:

LOOK for redness or swelling over and around the TMJ area.



Figs. 11A to D: Palpation of salivary glands: (A) Submandibular glands; (B) Parotid glands, Bidigital palpation for submandibular duct; (C) Using fingers of both hands; or (D) Two fingers of the same hand.

(*Courtesy:* Figs. 11A and B, Dr Pradnya Jadhav, Professor and Head; Dr Rohit Gadda, Reader; Dr Neha Patil, Assistant Professor, Department of Oral Medicine and Radiology, MGM Dental College, Navi Mumbai, Maharashtra, India)

JAYPEE BROTHERS

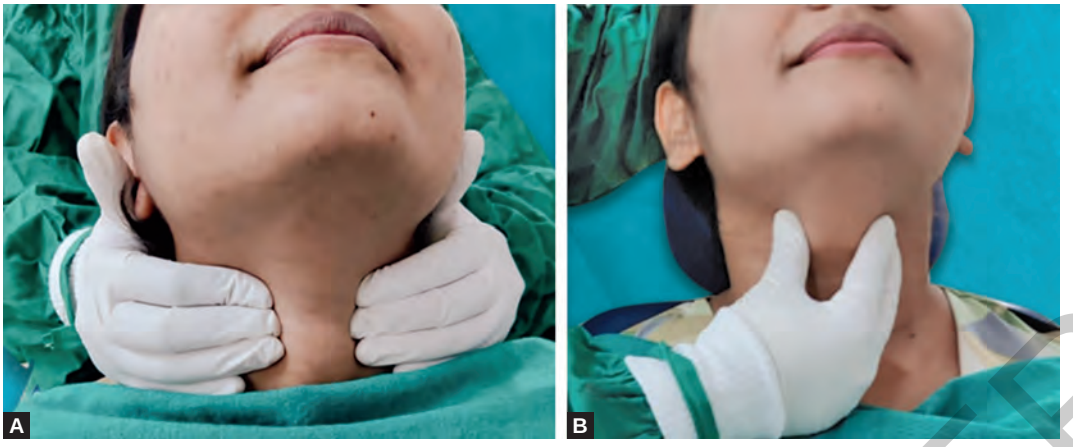

Figs. 12A and B: Thyroid Gland is palpated either: (A) Bimanually; (B) Bi-digitally while the patient is asked to swallow.

(*Courtesy:* Dr Pradnya Jadhav, Professor and Head; Dr Rohit Gadda, Reader; Dr Neha Patil, Assistant Professor, Department of Oral Medicine and Radiology, MGM Dental College, Navi Mumbai, Maharashtra, India)



Figs. 13A and B: Temporomandibular joint evaluation, by proper positioning of: (A) The fingers over the TMJ and asking the patient to; (B) Slowly open and close the mouth.

(*Courtesy:* Dr Pradnya Jadhav, Professor and Head; Dr Rohit Gadda, Reader; Dr Neha Patil, Assistant Professor, Department of Oral Medicine and Radiology, MGM Dental College, Navi Mumbai, Maharashtra, India)

FEEL press gently over the TMJ to check for tenderness.

MOVE evaluation of the TM joint functions should be done using the bilateral technique **(Figs. 13A and B)**. The clinician can either stand in front or behind the patient, make the patient sit upright and fingertips are rested over the joint while patient is requested to open and close the mouth slowly, move the jaw to the left and right and protrude the chin out.

The clinician needs to note any tenderness, joint sounds, and altered opening and closing path of the mandible. Altered opening path can be described in two basic ways **(Figs. 13C and D)**.

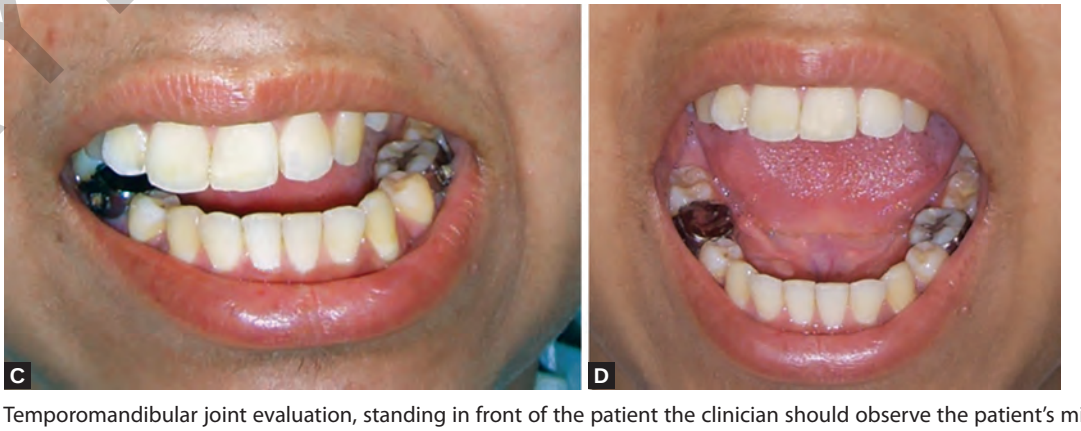

Figs. 13C and D: Temporomandibular joint evaluation, standing in front of the patient the clinician should observe the patient's midline as he/she slowly opens and closes the mouth, to note; (C) Deviation to one side due to hypomobility and internal derangement; (D) 'S'- shaped mouth opening indicates muscle imbalance.

JAYPEE BROTHERS

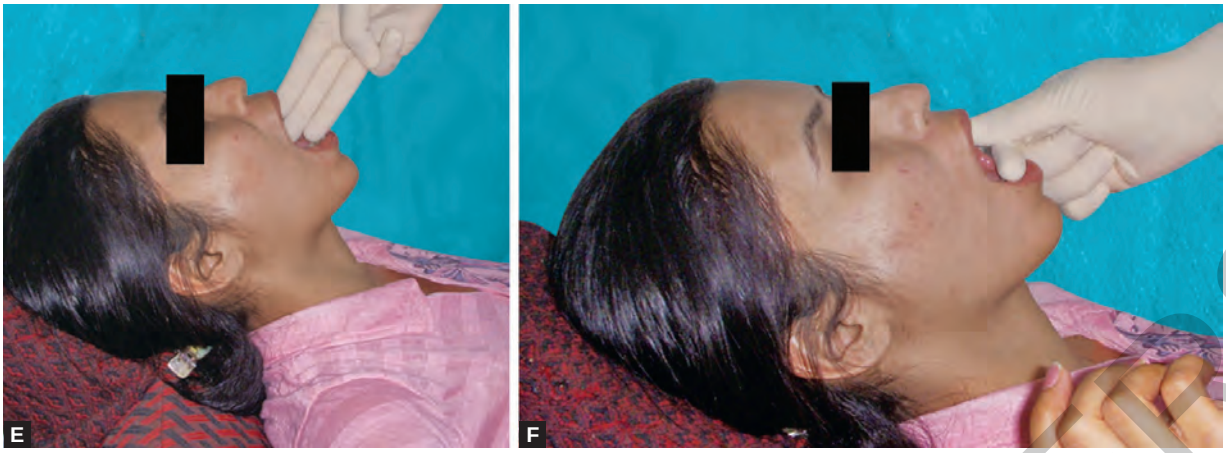

Figs. 13E and F: (E) The normal mouth opening should pass the 3-finger screening test; (F) The normal function of the joint and muscle activity is tested by the 'end-feel' test that is opening the mouth under finger pressure.

(*Courtesy:* Dr Neha Patil, Assistant Professor, Department of Oral Medicine and Radiology, MGM Dental College, Navi Mumbai, Maharashtra, India)

They are as follows:

- ❖ Deviation—it is an altered pathway on opening initially which returns back to the midline at the maximum opening.
- ❖ Deflection—it is the maximum distance from the midline at the maximum opening.

Deviation usually occurs toward the side of pathology. Check for limitation in mouth opening. Maximum mouth opening normally ranges from 40 to 50 mm **(Fig. 13E)**. Normal function of the TMJ is checked by performing the "**end feel'** test **(Fig. 13F)**. The patient should be asked to protrude the mandible to assess the extent of protrusion and lateral excursion on left and right side, and whether the protrusion is more limited on one side than the other.

There are three major categories of abnormal sounds heard or palpated over TMJ; clicks, pops and crepitus. *Clicks* and *pops* are indicative of articular disk derangement and crepitus is usually diagnostic of some form of arthritis.

Temporomandibular joint findings need to be correlated with patient's occlusion and dental findings like poorly fitting partial or full denture and missing teeth.

Tenderness on palpation over the TMJ, joint sounds, tenderness of the masticatory muscle, and mandibular deviation are all signs of temporomandibular disorder, as are signs of parafunction such as scalloping of the tongue, linea alba on the buccal mucosa, signs of tooth substance wear, and possible tooth fracture.

Masticatory Muscles (Figs. 14A to O)

The clinician should additionally assess for tenderness in the masticatory muscles (masseters, temporalis, and lateral pterygoid muscles) by having the patient clench their teeth and directly palpating the masseter and temporalis extra orally. The tenderness can be explained by the presence of trigger points within the muscles. Although the superficial fibers of the masseter muscle can be palpated extraorally, a finger should be softly passed into the mouth to intraorally palpate and assess the deeper fibers and bulk of the masseter muscle.

The inferior head of the lateral pterygoid muscles is palpated laterally behind the maxillary tuberosity intraorally.

Cranial Nerve Examination (Figs. 15A to D)

The trigeminal (V) and facial (VII) cranial nerves, as well as the Glossopharyngeal (IX) cranial nerves, are among the cranial nerves that a dental professional should be familiar with. Infection (osteomyelitis), iatrogenic trauma following surgery, and cancer are all possible causes of altered feeling and necessitate neurological recording and assessment.

A patient with a swelling in the parotid region may need a facial (VII) nerve evaluation, as facial nerve involvement may indicate cancer.

The ocular, maxillary, and mandibular branches of the trigeminal nerve (V) provide sensory and motor support to the facial muscles.

Visual examination and palpation of the masseter and temporalis muscles can be used to assess the motor supply. The patient is asked to open their mouth against pressure to determine its strength.

The motor nerve supply to the muscles of facial expression is provided by the facial nerve (VII). To gain access to this nerve, the patient must perform certain movements, such as:

- ❖ Lifting their eyebrows.
- ❖ Shutting their eyes and keeping them closed in the face of opposition.
- ❖ Showing off their teeth and puffing out their cheeks.

Facial nerve palsy is defined by the inability to perform the above functions. Other symptoms of palsy include the difficulty to blow and saliva dribbling.

Intraoral Examination

It should be performed with proper lighting, two dental mouth mirrors, two 2" × 2" gauze squares, and gloves. Any abnormality's dimensions can be measured with a periodontal probe. Tongue depressors and a headlamp or flashlight are useful in situations other than the dentist office, such as screening clinics or nursing homes **(Form 7)**.

A good knowledge of normal anatomy **(Boxes 3 and 4)** and anatomic variations **(Boxes 5 to 7)** is crucial to determine if a structure is within normal limits or abnormal. Intraoral examination should also be done sequentially with the clinician following the same sequence each time, so as to minimize the chances of an area not being assessed. With the development of technology, clinicians may also record any abnormal or unusual findings with a camera or intraoral camera and include them within the clinical record. The same may be reflected onto a screen, and enlarged so that it becomes easier for the patient to understand. The intraoral examination is divided into hard tissue and soft tissue examination.

JAYPEE BROTHERS



Figs. 14A to O: Evaluation of the masticatory muscles and other muscles of the neck; *Temporalis muscle*: Palpation of the (A) Anterior; (B) Middle; (C) Posterior regions; (D) Palpation of the ***tendon of the temporalis***. The clinician's finger is moved intraorally up the anterior border of the ramus until the coronoid process and the attachment of the tendon of the temporalis are felt; (E) Functional manipulation of the *superior lateral pterygoid* is achieved by asking the patient to bite on a tongue blade bilaterally; (F) Functional manipulation of the ***inferior lateral pterygoid***, the patient is protruding the mandible against resistance provided by the examiner, Palpation of ***medial pterygoid***; (G) To palpate from inside the mouth, the head is tilted slightly to access the muscle. Palpation with one finger locates trigger points on the inner surface of the mandible by pressing upward at its angle, Palpation of the ***masseter muscles***; (H) At their superior attachment to the zygomatic arches; (I) Palpation of the superficial masseter muscles near the lower border of the mandible, Palpation of the ***sternocleidomastoid***; (J) High near the mastoid process and (K) Low near the clavicle. Palpation of *muscular attachments in the occipital region* of the neck; (L and M) The clinician's fingers are brought inferiorly down the cervical area and the muscles are palpated for pain and tenderness; (N) The ***splenius capitis*** is palpated at its attachment to the skull just posterior to the attachment of the sternocleidomastoid; (O) The ***trapezius*** is palpated as it ascends into the neck structures.

(*Courtesy:* Dr Pradnya Jadhav, Professor and Head; Dr Rohit Gadda, Reader; Dr Neha Patil, Assistant Professor, Department of Oral Medicine and Radiology, MGM Dental College, Navi Mumbai, Maharashtra, India)

Box 3: Oral cavity.

The oral cavity is an oval-shaped region bounded on the front by the lips, on the side by the cheeks, on the back by the palate, on the bottom by the floor of the mouth, and on the back by the palatoglossal folds.

It links outwardly with the pharynx via the fauces and internally with the pharynx via the aperture between the lips.

The oral cavity is divided into the oral cavity proper and the oral vestibule by alveolar processes and teeth.

The outer vestibule is encompassed by the cheeks and lips and separated from the gingivae and teeth by a slit-like gap. Mucosal reflections from the lips and cheeks limit it above and below.

The oral cavity is the area enclosed by the teeth and gingivae. It is bordered on the inferior side by the tongue and floor of the mouth, and on the superior side by the hard palate.

The oral cavity is totally bordered by oral mucosa, except for the coronal area of the teeth, which varies in color, thickness, and attachment depending on the region covered.

1. Labial mucosa and vestibule
2. Buccal mucosa and vestibule
3. Alveolar mucosa and gingiva
4. Hard and soft palate
5. Oropharynx and pharynx
6. Tongue
7. Floor of the mouth

JAYPEE BROTHERS



Figs. 15A to D: Cranial nerve evaluation: (A) Cotton-tipped applicators are used to compare light touch ***discrimination between the right and left maxillary branches of the trigeminal nerve***. The ***ophthalmic and mandibular branches*** are also tested; (B) For checking the patient's **extraocular muscles**, the examiner asks the patient to follow the finger as it makes an X in front of her, without moving her head. Any variation in right or left eye movement is noted. For checking the patient's ***visual field (the optic nerve)***; (C) With the patient looking forward, the examiner's fingers are brought around to the front from behind. The initial position at which the fingers are seen marks the extent of the visual field. Right and left fields should be very similar, ***motor function of the trigeminal nerve*** is tested by evaluating the strength of masseter muscle contraction; (D) The patient is asked to clench the teeth together while the clinician feels for equal contraction of the right and left masseter muscles. This is also done for the ***temporalis muscles***.

(*Courtesy:* Figs. 15B and C. Dr Pradnya Jadhav, Professor and Head; Dr Rohit Gadda, Reader; Dr Neha Patil, Assistant Professor, Department of Oral Medicine and Radiology, MGM Dental College, Navi Mumbai, Maharashtra, India)

Box 4: Oral mucous membrane.

The mucous membrane is a moist lining of body cavities such as gastrointestinal tract and nasal passages which communicate with the exterior. In the oral cavity this lining is known as oral mucous membrane or oral mucosa.

Functions of the Oral Mucosa

1. *Protection*: By acting as a barrier, it protects the deeper tissues such as fat, muscle, nerve and blood supplies from mechanical insults, namely trauma during chewing, and also prevents the entry of microbes and toxic substances into the body.
2. *Sensation*: Its extensive innervation makes the mouth very receptive of sensations such as hot, cold, and touch. The taste buds located in oral mucosa are essential for perception of taste.
3. *Secretion*: Saliva is the major secretion associated with the oral mucosa and it is secreted by major salivary glands via ducts passing through the oral mucosa.
4. *Permeability*: There is a degree of permeability permitting rapid absorption of substances into the body in certain situations, e.g., use of sublingual glyceryl trinitrate in an angina attack.
5. *Thermal regulation*: It is applicable in dogs.

Organization of the Oral Mucosa

The oral mucosa is categorized into three types according to FUNCTION:

1. *Masticatory mucosa*: This accounts for 25% of the total mucosa.
   i. Gingiva (free, attached, and interdental)
   ii. Hard palate
   This is the primary mucosa which contacts with food during mastication. It is usually keratinized.
2. *Lining mucosa*: This accounts for 60% of the total mucosa. It covers the following:
   i. The floor of mouth
   ii. Ventral surface of tongue
   iii. Alveolar mucosa
   iv. Cheeks
   v. Lips
   vi. Soft palate
   This does not function in mastication and therefore has minimal "wear." This mucosa is usually nonkeratinized; soft and pliable.
3. *Specialized mucosa*: This accounts for 15% of total mucosa. It covers the following:
   i. Dorsal surface of the tongue and is composed of cornified epithelial papilla.

JAYPEE BROTHERS

Box 5: Normal anatomical features of the oral cavity which may be misinterpreted as pathology.

- The salivary duct of the parotid gland is Stenson's duct opens onto the oral cavity via the parotid papilla is located on the buccal mucosa adjacent to the maxillary second molar which can either be flat or polyp-shaped.
- The duct of the submandibular gland is called as Wharton's duct which opens on either side of the frenulum in the floor of the mouth.
- The opening of sublingual glands is in the floor of the mouth in tissue folds known as plica sublingualis.
- There are four types of papillae on the tongue:
  1. Filiform papillae are hair-like or thread-like projections on the anterior two-third of the dorsal surface of tongue, and are usually pink or white in color.
  2. Fungiform papillae are deep red, mushroom-shaped projections present near the tip of the tongue on the dorsal surface. They also contain a few taste buds. Fungiform refers to "shaped-like fungi or mushrooms."
  3. Circumvallate or vallate papillae are 8–12 mushroom-shaped projections, each surrounded with a circular groove. Circumvallate denotes "around a valley or trench." They are arranged in V pattern on the dorsal surface at the junction of anterior two-third and posterior one-third of tongue.
  4. Foliate papillae appear as 3–4 small folds on the lateral surface of posterior one-third of the tongue. They are pinkish red, soft, and contain taste buds. They may appear yellowish beige due to lymphoid tissue.
- The masses of lymphoid tissue are present in the oral cavity and throat (tonsils).
- Lingual tonsils are yellowish beige projections on dorsal surface of posterior one-third of the tongue, and also occasionally observed on the lateral surface of the tongue. These collections of lymphoid tissue can vary in size and may enlarge due to cold. Normally, they are soft, symmetrical in appearance and covered with intact mucosa. Further evaluation is required in case of their unilateral enlargement or ulceration.
- Pharyngeal tonsils are usually, soft, symmetrical, nonulcerated, and asymptomatic masses in the throat. They may be small or large, smooth or bumpy and slightly yellow to beige in color. Necrotic material made of dead mucosa, bacteria, and foreign material may get lodged in the tonsillar crypts resulting in bad breath. When calcified, this material is called *tonsillolith*. In case of a tonsillectomy, a scar in the form of a plain line may be seen in the area.

Box 6: Variations of normal mucosa.

Normal conditions that are observed in some patients only, are known as "variations of normal." Evaluation of these variations should be done accurately for correct diagnosis, however treatment is not required.

- Fordyce granules are heterotrophic collection of sebaceous glands found on the buccal mucosa or lip. They present as groups of slightly raised, yellowish-beige papules measuring 1–3 mm in diameter.
- Fissured tongue commonly presents as multiple grooves on the dorsal surface or occasionally on the lateral surface of the tongue and is reported in 2–5% of the population.
- Crenations are indentations formed due to teeth on the lateral surface of the tongue. These are more likely to be present in people with tongue thrusting habit.
- Varicosities are dilated veins purple in color often observed on the ventral surface of the tongue and may be seen on buccal mucosa or lips. They blanch on applying pressure.
- Plica fimbriata are the fringe-like mucosal folds on underside of the tongue on either side of the frenulum.
- Ankyloglossia, or tongue tie is an uncommon condition where lingual frenulum is shorter than average. The patient is unable to protrude or elevate the tongue.
- Leukoedema is a milky, white-gray translucent appearance on buccal mucosa at rest. White streaks may appear due to the folding of the mucosa. This is asymptomatic and disappears on stretching the mucosa. It is more commonly found in dark skinned people and trumpet players whose cheeks are stretched due to excessive blowing.
- A palatal torus is a bony over growth that develops in palatal midline. The treatment is not required for tori unless they interfere with denture or the overlying mucosa gets traumatized and ulcerated.
- Mandibular tori are seen bilaterally on lingual surfaces of the mandible in the premolar region. They are usually round in shape and covered by mucosa.
- Exostoses are rounded protuberances or swellings of bone that are often observed on the outer surfaces of the jaws.
- Retrocuspid papillae are firm, pink papules on the gingiva on lingual side of the mandibular canines. They are more common in children, and may regress with age.

Box 7: Minor oral pathologies.

The commonly seen minor oral pathologies are those that are categorized as pathology but are not problematic and do not need treatment. These lesions should be kept under observation and regular follow-up.

- Linea alba buccalis or white line, appears as a white horizontal line along the buccal mucosa at the level of the occlusal plane. This occurs due to frictional irritation or sucking trauma.
- Scars are often observed on labial mucosa of the lower lip caused due to trauma as a child. The scars can also result from tonsillectomy.
- Mucosal tags are small, soft, pink projections commonly seen on the buccal frenulum. It may be the result of healing after trauma to the frenulum.
- Papillitis, or transient lingual papillitis, is inflammation of one or several of the fungiform papillae on the dorsal surface of the tongue. The affected papillae appear slightly enlarged and may be painful. Its etiology is unknown and usually resolves in several days without treatment.
- Acute trauma from cheek biting is frequently seen along occlusal line on buccal mucosa. There may be areas of bruising corresponding to the indentation of the teeth along with ragged white area where the mucosa has been torn.
- Chronic cheek biting is called **morsicatio buccarum**. The area has a white, ragged slightly translucent appearance on the buccal mucosa.
- Geographic tongue represents a map-like pattern consisting of multiple circular or semicircular smooth red areas often surrounded by slightly raised white border "**serpiginous white lines**." The red areas may change location with time giving it a name "**erythema migrans**." It is seen in approximately 2% of the population, and is commonly associated with fissured tongue.
- Hairy tongue is a benign condition with unknown etiology which occurs due to elongation of filiform papillae. The various factors such as tobacco, coffee, tea or pigment-producing bacteria can cause discoloration of these areas on the tongue. Hairy tongue is more likely to be seen after oral radiation treatment and in smokers. The treatment involves gently scraping or brushing the tongue.

JAYPEE BROTHERS

Form 7: Dental Record.

Client dental record Date:

Name: Age/DOB: Gender.

Email: Mobile:

Services Required:

Brushing Habits:

Past Dental History: Yes/No Any Complication:_____

Extra Oral Examination

Face: Symmetrical/Asymmetrical Swelling: Present/Absent _____

Lips: Competent/Incompetent Ulcerations: Present/Absent_____

TMJ: Clicking present/Absent Pain: Present/Absent _____

Lymph Nodes: Non-Palpable/Palpable_____

Intra Oral Examintion

Mucosa: Cheek: Normal/Abnormal _____ Lip: Normal/Abnormal_____

Vestibule: Normal/Abnormal _____ Hard Palate: Normal/Abnormal_____

Soft Palate: Normal/Abnormal _____

Tongue: Normal/Coated/Bald

Frenal Attachment: Upper/Lower: Normal/Low Attachement

Gingiva: Healthy/Iflamed

Orla hygiene: Good/Fair/Poor Presence of plaque: Yes/No Calculus: Yes/No

Presence of Swelling/abscess/ulcer/white patches in the oral cavity

Teeth: Present:_____ Absent:_____ Filled:_____

Types of filling present: Silver Fillings/Tooth Colored Restorations_____

Crowns:_____ Dentures:_____ Implants:_____

Dental record chart

18	17	16	15	14	13	12	11	21	22	23	24	25	26	27	28
48	47	46	45	44	43	42	41	31	32	33	34	35	36	37	38

Signature of patient Signature of Clinician

Hard Tissue Examination (Figs. 16A and B)

A hard tissue intraoral examination is a complete documentation of conditions of all teeth performed tooth by tooth, and is recorded in a detailed tooth chart. The conditions of the teeth and mouth are documented, which are as follows:

- The number of teeth present.
- Existing work done on the teeth.
- Decay/caries—decay-missing-filled (DFMT) index
- Teeth with filling—types of fillings present
- Leakage and defective restorations
- Impactions, attrition, erosion, and abrasion
- Required treatments
- Positions of teeth
- Root stumps
- Fluorosis
- Trauma

Tooth Vitality

There is a need to check tooth vitality and also differentiate between, pulpitis, reversible pulpitis and irreversible pulpitis.

Distinction between vital and nonvital is of great importance as it aids in locating the offending tooth and dictates the treatment approach.

Vital

It indicates that nerve and blood supply to the pulp is intact and although the inflammation may be acute, the noxious stimuli (bacteria, toxins, etc.) are still being contained.

Nonvital

It indicates that the pulp has becomes necrotic and infection has gained a foothold.

Pulpitis

It is the inflammation of the dental pulp due to caries, trauma, or multiple restorations. The pain is its main symptom and its

JAYPEE BROTHERS

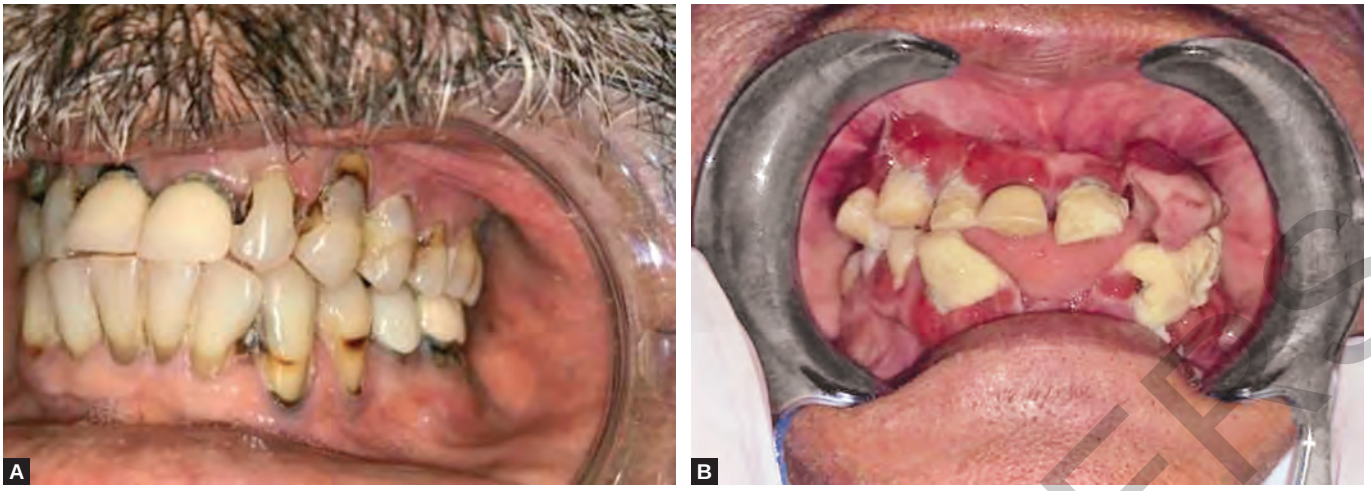

Figs. 16A and B: Hard tissue evaluation: (A) Clinical pictures of patient with teeth in occlusion, multiple carious lesions and recession; (B) Clinical pictures of patient showing missing teeth, very poor oral hygiene, gingival enlargement and periodontitis.

diagnosis depends on the clinical findings, radiological findings, and pulp vitality tests.

Reversible Pulpitis

It is a mild to moderate inflammation of the pulp due to noxious stimuli in which the pulp is capable of returning to the uninflamed state after removal of the stimuli.

Irreversible Pulpitis

It is of two types:

1. ***Symptomatic irreversible pulpitis***—is based on subjective and objective observations that the crucial inflamed pulp cannot heal and that root canal therapy is required. Sharp pain, lasting pain (typically 30 seconds or longer after stimulus removal), spontaneity (unprovoked pain), and referred pain will all affect the patient.
2. ***Asymptomatic irreversible pulpitis***—it is a clinical diagnosis based on subjective and objective indications that the essential inflamed pulp is unable to heal and that root canal therapy is necessary. These individuals usually have no clinical symptoms and respond properly to heat tests, but they may have a history of trauma or deep cavities, which could lead to exposure after removal. A deep cavity reaching to the pulp may be seen on inspection, and the pulp's surface may be eroded.

Occlusal Review

The molar relationship, overjet, over bite, crossbite, eruption sequence, crowding, and spaces/diastema.

The physician should look for old fillings, fracture lines, and fractured teeth, as well as developmental defects, congenitally absent teeth, and teeth with abnormal wear that could be caused by tooth migration or not. Checking for aberrant jaw bone growth is another part of the hard tissue intraoral exam.

Following the hard tissue examination, a soft tissue intraoral examination should be performed to obtain a thorough dental history.

Soft Tissue Examination

The process of examination of the different pathologies of the soft tissue varies as there are various types of lesions **(Table 3, Box 9)** which affect the oral mucosa. Ulcerative lesion **(Box 8)**, soft tissue enlargements and reactive lesions **(Boxes 10 and 11)** and neoplasms **(Table 4 and Box 12)**.

Labial Mucosa

The clinician can examine the labial mucosa by asking the patient to keep his or her mouth three-fourth closed, then softly grasping the lower lip between the thumb and index finger of each hand and gently everting the lip. The upper lip is evaluated after the lower lip. This is followed by a bidigital palpation of the lips tissues.

Normal Clinical Appearance (Figs. 17A and B)

The labial mucosa is the area extending from the vermilion border into the vestibule between imaginary lines drawn from the commissures to the distal surfaces of the maxillary and mandibular canines. The labial frenum is a fold of mucosa that runs from the labial mucosa to the alveolar mucosa in the midline of the upper and lower vestibule. It may expand onto the connected gingiva or interdental gingiva/papillae, bridging the alveolar ridge and contacting the palatine papillae; this is sometimes considered abnormal. It appears to be wet and gleaming. The labial mucosa is pink to purple pale pink to reddish pink in hue, with brown to black regions depending on the quantity of melanin pigment present. Stretching reveals several conspicuous veins and ductal orifices of the minor salivary glands in this location, which is rich in vascularity and minor salivary glands **(Fig. 17C)**. Due to these glands, the surface of the labial mucosa may seem nodular or granular at times. The mucosa of the labial mucosa is normally smooth, soft, and elastic, and it is attached to the muscular fascia beneath it.

Pathological Appearances

Polyps, scars, and ulcers are all common pathologic abnormalities. Scars inside the lower lip are common as a result of childhood trauma.

Buccal Mucosa and Vestibular Mucosa

The clinician can see by pulling back the buccal mucosa and looking via two mirrors on one side. The patient is asked to tilt his or her head to allow the light to reach the buccal mucosa. The buccal mucosa, as well as the maxillary and mandibular vestibules, are clinically evaluated by slowly moving from the posterior to the anterior buccal mucosa, while simultaneously examining the mandibular anterior vestibule. The examination

JAYPEE BROTHERS

TABLE 3: Clinical descriptions of lesions based on morphology.

Clinical appearance	*Morphology*	*Description*
	White	Appear so because they represent: 1. A pseudomembrane (intrinsic or extrinsic) 2. A thickening of one or more thickened layers of the epithelium (stratum corneum or spinosum) 3. Subepithelial inflammatory cell infiltrate 4. Dense fibrosis 5. Intracellular edema
	Red	It may represent erythema (increased vascularity) or a thinning of the layers of the epithelium (atrophy). Diascopy or blanching of the lesions may help to differentiate intravascular from extravascular blood. These lesions may also represent inflammation (vasodilation) but may be the earliest sign of epithelial potentially malignant lesion (dysplasia)
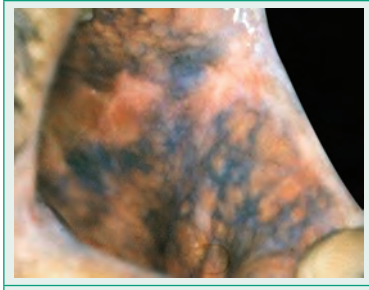	Pigmentation	It may present as black, brown, or blue may represent intrinsic or extrinsic pigments
Elevated blister like lesions		
	Vesicle	A small (<1 cm in diameter) loculation/blister of fluid on or under the epithelium. It is raised and well-defined (e.g., Herpes zoster)
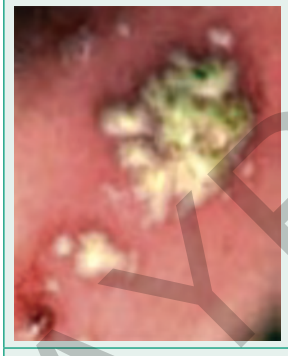	Pustule	A cloudy or white vesicle, the color of which results from the presence of polymorphonuclear leukocytes (pus) (e.g., chickenpox)
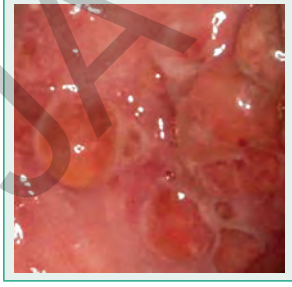	Bulla	A large blister, >1 cm in diameter. With compartmentalized fluid in or under the epithelium of skin or mucosa (e.g., pemphigus)

Contd...

JAYPEE BROTHERS

Contd...

Clinical appearance	*Morphology*	*Description*
	Elevated non-blister like lesions	
	Crusts	Dried or clotted serum protein on the surface of skin or mucosa (e.g., erythema multiforme)
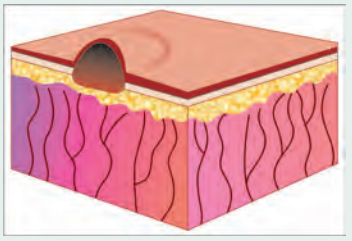	Polyp	It is a mass of tissue that projects outward from the surface of the mucous membrane
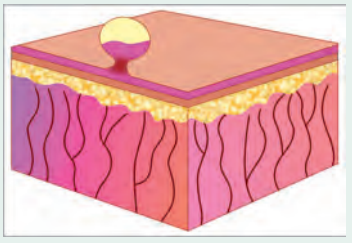	Papule	A small (<1 cm in diameter), palpable mass elevated above the epithelial surface. It may be pigmented or may be the same color as the surrounding tissue
	Nodule	A large (>1 cm in diameter), palpable mass elevated above the epithelial surface. It may be visible or it may only be detectable by palpation (e.g., leprosy)
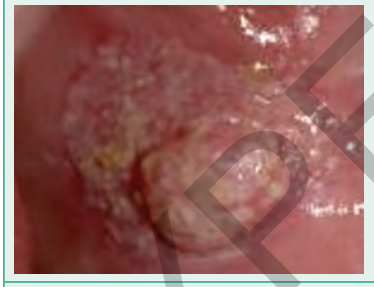	Tumor	It is similar to a nodule in that it consists of tissue, but it is >2 cm in its greatest diameter
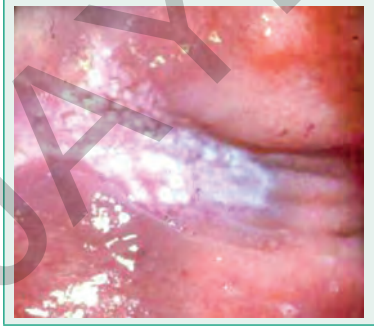	Plaque	A flat, slightly elevated plateau like lesion and can be pigmented or not. It is believed to be a confluence of papules (e.g., leukoplakia)

Contd...

JAYPEE BROTHERS

Contd...

Clinical appearance	*Morphology*	*Description*
	Hematoma	It is a localized collection of blood outside of a blood vessel that may appear as raised
	Sessile	A tumor or growth whose base is the widest part of the lesion
	Pedunculated	A tumor or growth whose base is narrower than the widest part of the lesion
	Separate lesions	These are usually few in number and relatively widely spaced, but not always. They usually remain individual, distinct lesions, even if they tend to enlarge after their initial appearance
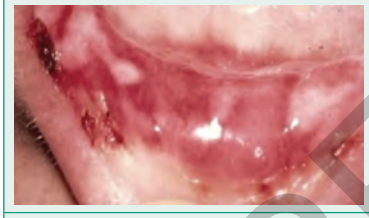	Coalescing lesions	These are numerous and in proximity to one another. Their margins may merge and leave a single lesion, even if they enlarge only slightly after their initial appearance
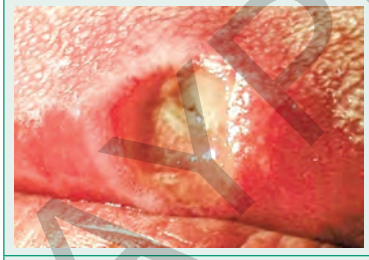	Ulcerations	It may be a result of a loss of the epithelium and may represent a primary lesion or occur secondary to rupture of a pre-existing lesion (vesiculobullous lesion)
	Depressed lesion	
	Erosion	Superficial ulceration (excoriation). It is a shallow ulcer where the epithelium may only be partially destroyed. These often are red in color

Contd...

JAYPEE BROTHERS

Contd...

Clinical appearance	Morphology	Description
	Fissure	A narrow, slit-like ulceration or groove
	Ulcer	Loss of epithelium. It is usually a depressed or crater-like area on the mucosa where there is a loss of the epithelium, which is the surface layer, and is often yellow white in color
	Atrophy or scarring	Some depressed lesions are the result of atrophy or scarring and have an intact epithelial surface
	Pits or blind "pouches"	It is caused by a failure of complete filling out during embryologic development
	Flat lesion	
	Scale	A macroscopic accumulation of keratin
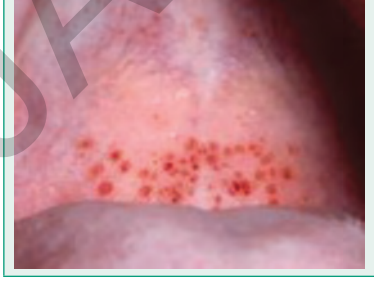	Petechia	A round, pinpoint area of hemorrhage. It is a spot approximately 1–2 mm in diameter where blood has leaked into the surrounding tissue. These are often found in multiples, and are called petechiae (e.g., thrombocytopenic purpura)

Contd...

JAYPEE BROTHERS

Contd...

Clinical appearance	Morphology	Description
	Ecchymosis	A nonelevated or flat bruised area of hemorrhage. More than 2 mm in diameter
	Macule	Circumscribed area of color change without elevation. It is a spot which is well-defined, flat, have a different color than the surrounding tissue and are usually <5 mm in diameter
	Patch	It is a larger spot. This is also a pigmented area that is generally >5 mm in diameter
	Other lesions	
	Swellings	These are a group of lesions and range from a smooth to roughened surface (papillary, verrucous, papular, or polypoid nature). The roughened surface lesions usually represent proliferations of the surface epithelium and are frequently of viral origin. The smooth surface lesions are due to a submucosal enlargement. The important parameters are the location, consistency, and presence or absence of pain.
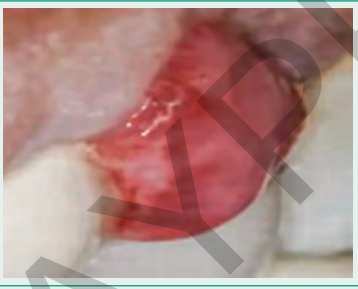	Granuloma	A focal area of chronic granulomatous inflammation composed of vascularized granulation tissue
	Papillary	A tumor or growth exhibiting numerous surface projections

Contd...

JAYPEE BROTHERS

Contd...

Clinical appearance	*Morphology*	*Description*
	Verrucous	A growth resembling a wart or having wart-like projections
	Cyst	A pathologic, epithelium-lined cavity often filled with liquid or semisolid contents
	Telangiectasia	A vascular lesion caused by dilatation of a small and superficial blood vessel
	Multilocular	A radiolucent lesion composed of multiple compartments

Box 8: Examination of an ulcer.

Inspection

- *Site/location*: Traumatic ulcers are most likely to occur on the lateral borders of the tongue and the buccal mucosa at the level of occlusal plane. Ulceration of the lower lip after surgical procedures is common due to lip biting as the effect of anesthesia wear off. Ulceration and sloughing necrosis of the tips of the interdental papillae, especially in the mandibular anterior region, is almost pathognomonic of ANUG. OSCC most frequently occurs in a "high risk oval" formed by the lower lip, floor of mouth, ventral and lateral borders of the tongue, retromolar areas, tonsillar pillars, and lateral soft palate. Unilateral ulceration may signify herpes zoster.
- *Number*: The ulcers may appear as a single ulcer (traumatic), single ulcers distributed in the mouth at various locations (major aphthous), multiple crops of ulcers at a single site (minor aphthae)
- *Size*: A differentiating feature in aphthous stomatitis is the size of ulcers, permitting the categorization into minor (<10 mm), major (>10 mm) or herpetiform (<1 mm).
- *Shape*: Presence of linear, fissure-like ulcers suggests Crohn's disease. Self-inflicted injury can be suspected when semilunar ulcer in the shape of fingernail is observed.
- *Base*: Healthy granulation tissue is observed in a healing ulcer.
- *Edge*: A raised, rolled margin is suspicious. Indurated margins suggest malignancy, undermined border suggests tuberculosis. A sharp knife edges (sloping edges) indicates a healing lesion.

Palpation

- *Hardness*: On palpation, malignant ulcers are often indurated (hard). Healing ulcers are usually soft on palpation.
- *Mobility*: The lesion is secured with one finger and using another finger, an attempt is made to move the surrounding tissues. The malignant ulcers tend to be fixed to the underlying structures.
- *Contact bleeding*: The malignant ulcer may be discerned by presence of this feature.
- *Pain*: Most ulcers are painful in the early stage. Whereas, early malignant ulcers tend to be painless, it may become painful later due to involvement of adjacent nerves.

(ANUG: acute necrotizing ulcerative gingivitis; OSCC: oral squamous cell carcinoma)

JAYPEE BROTHERS

Box 9: Difference between surface lesion and soft tissue enlargements.

When evaluating soft tissue lesions of the oral mucosa, determining whether the disease is a surface lesion or a soft tissue enlargement is critical.

Surface lesions of oral mucosa consist of lesions that involve the epithelium and superficial connective tissue of mucosa. They do not exceed 2–3 mm in thickness. Surface lesions are further divided into categories based on their clinical appearance, which are as follows:

i. White
ii. Red
iii. Pigmented
   - Brown
   - Blue
   - Black
iv. Erosive
v. Ulcerative
vi. Vesiculobullous

Or as per the morphology into three broad categories **(Table 2)**:

i. Elevated
   a. Blister—vesicle, pustule, or bulla
   b. Nonblister—papule, nodule, tumor, or plaque
ii. Depressed—ulcer, erosion
iii. Flat—macule

Box 10: Clinical differences between reactive soft tissue enlargements and soft tissue tumors.

Reactive soft tissue enlargements or swellings	***Soft tissue tumors or growths***
Regress or resolve after removal or treatment of etiological factor	Persistent and progressive, resolved only after surgical removal
Usually, symptomatic	Usually, asymptomatic
Growth rate: hours, days, and weeks	Growth rate: weeks, months, and years
It may be associated with soft tender lymph nodes	Normally lymph nodes are not affected, unless associated with metastatic tumors when they may be firm and nontender
It may be associated with systemic manifestation	Systemic manifestations may occur late in the course of malignant involvement/ secondary infection

Box 11: Examination of soft tissue enlargements in the oral cavity.

Soft tissue enlargements are swellings or masses may have a smooth surface and appear papillary or multi-polypoid, and are broadly divided into two categories, which are as follows:

1. **Reactive soft tissue enlargements or swellings** due to injuries, such as infections, chemical trauma, physical trauma, or allergic reactions, cause reactive soft tissue enlargements or swellings. They usually have a quick onset (short duration). After the etiology or risk factor has been removed, they may fluctuate in size and finally regress.
   These are frequently uncomfortable or unpleasant, and they grow quickly in comparison to tumors. Tender lymph nodes and systemic signs such as fever and malaise have been reported in the past.
2. **Soft tissue tumors or growths** are classified as persistent and progressive, with rates of growth ranging from weeks to years, and not resolving without treatment, such as surgical removal. The term tumor refers to an enlargement in the clinical sense, and it is not always a real neoplasm.
   If a soft tissue growth looks to be neoplastic, it must be differentiated between benign and malignant **(Table 4)**.

Examination of a growth/swelling/enlargement

- **Location/Position:** Anatomic landmarks, established reference points, and metric measurements collected with a probe should all be used to characterize the specific location of the aberration.
- **Size and shape:** A probe should be used to measure all of the dimensions of the lesions (length, width, height, and diameter). Information on the area's edges or borders, development direction, and style of attachment to the underlying tissues should all be included in the shape. The shape of lesions can be described using terms such as circular, oval, triangular, and linear. Regular or uneven, smooth or elevated, the edges or boundaries of the lesion might be described. The direction of their growth can be described as exophytic (outward growing) or endophytic (inward growing), and their mode of attachment to the underlying tissues can be described as sessile (attached by a base that is as broad as the overlying lesion) or pedunculated (attached by a base that is as broad as the overlying lesion) (attached to the underlying tissues by a thin stalk).
- **Color:** The area should be accurately defined in terms of color. An increase in keratin or the thickness of the mucosa is usually the cause of white-colored lesions (e.g., leukoplakia). A red lesion might be caused by thinning/atrophy of the mucosa or tissue inflammation (e.g., erythroplakia). Yellow could indicate the presence of purulent exudates and, as a result, an infection. Blue indicates a problem with the blood vessels, such as labial or lingual varices. Exogenous (external) or endogenous (internal) factors can induce brown, black, or blue coloring. Endogenous brown to black pigmentation is an example of normal physiologic pigmentation. Exogenous pigmentation includes both amalgam tattoos and deliberate tattoos. Changes in color, such as from brown to black or blue, can indicate the presence of a malignant activity.
- **Consistency:** It refers to the way something feels when you touch it. Firm, indurated, soft, fluctuant, resilient, and rubbery are all words that come to mind when describing it. Malignant lesions, such as lymphadenopathy associated with metastatic tumors, are more likely to be indurated, hard, and/or firm. Lymphangioma and other lymph or blood vessel neoplasms are frequently associated with fluctuant lesions.
- **Surface texture:** It describes how a surface or lesion feels when brushed softly with a fingertip. The surface texture of submucosal lesions is usually smooth. Papillary (finger-like projections), corrugated (washboard-like), fissured (deep fractures), and crusted are all terms for rough surface textures (covered by a scab or exudate).
- **Mobility:** This is determined by palpating the affected area. Moveable lesions are less likely to be cancerous than those that are fixed to the underlying tissues.
- **Type:** Lesions can be classified as flat, raised, or depressed depending on their type For terminology that can be used to better characterize each of these key categories (**Table 3**). The need for biopsy must be evaluated when the lesion has been detected and defined.

JAYPEE BROTHERS

TABLE 4: Clinical differences between benign and malignant neoplasms.

Benign	*Malignant*
Usually no pain, unless pressure induced or impinging on a vital structure no pain	They are more likely to be painful in the later stages
They are well defined or circumscribed, overlying mucosa is usually normal unless traumatized	They causes ulceration of the overlying epithelium
Some benign tumors are also fixed to surrounding structures, but others are surrounded by a fibrous connective tissue capsule, which may allow them to be moved within the tissue independent of surrounding structures	These neoplasms invade or infiltrate surrounding muscle, nerve, blood vessels, and connective tissue, they are fixed or adherent to the surrounding structures during palpation
They have a slower growth rate, measured in months and years	It has a faster growth rate measured in weeks and months
The benign tumors are more likely to move teeth, due to pressure effect	The malignant lesions loosen teeth, due to erosion and loss of supporting bone
They are not fixed to surrounding structures	They are fixed to the underlying structures
The lymph nodes may be normal and/or enlarged and tender	The lymph nodes are firm, hard, and sometimes fixed

Box 12: Clinical evaluation of benign neoplasms.

Benign tumors can be subdivided into four categories:
1. Epithelial
2. Mesenchymal
3. Salivary gland tumors
4. Cysts of soft tissue, soft tissue cysts are well circumscribed, slowly growing, persistent, and progressive, they have historical and clinical features resembling those of benign tumors.

All soft-tissue lesions, even those that appear benign, must be carefully watched to identify whether they have resolved or if they have progressed or changed. A biopsy or referral is required if the lesion does not resolve or progress.

It may be required to observe a lesion for 10–14 days after it is discovered, but decisive treatment should not be postponed. Many times, lesions that have been biopsied in the past and found to be noncancerous are not appropriately tracked, and can develop a malignant change over time. Oral cancer must be detected as soon as possible. When cancer is discovered late, the overall 5 year survival rate is around 50%.

It is important to note that the clinical descriptions provided above are only guidelines, and that deviations do occur. The only method to get a definitive diagnosis is to remove the lesion and examine the tissue under a microscope.

is then repeated on the opposite buccal mucosa and vestibules, before moving to the maxillary anterior vestibule. Bidigitally palpate the buccal mucosa by pushing the tissue between the index finger and thumb of one hand.

Normal Clinical Appearance

The buccal mucosa comprises the whole lining mucosa of the cheeks, which connects anteriorly to the labial mucosa and commissure and continues posteriorly to the pterygomandibular raphe. It extends onto the alveolar process from above and below.

The vestibular sulcus is a horseshoe-shaped indentation formed by the continuation of the buccal and labial mucosa superior and inferior borders. The mucobuccal fold, buccal gutter, and buccal corridor are all names for this location **(Fig. 18A)**.

The opening of Stensen's duct is denoted by the parotid papilla, which appears as a conspicuous elevation or a minor indentation about opposite the maxillary first/second tooth. **(Fig. 18B)**.

A long continuous fold of tissue called linea alba buccalis or occlusal line extends from near to the pterygomandibular raphe up to the commissures in the middle of the buccal mucosa, approximately opposing the occlusal plane of the posterior teeth **(Fig. 18C)**.

Muscles accommodated in buccal mucosa are buccinator and masseter with parotid gland and the buccal pad of fat

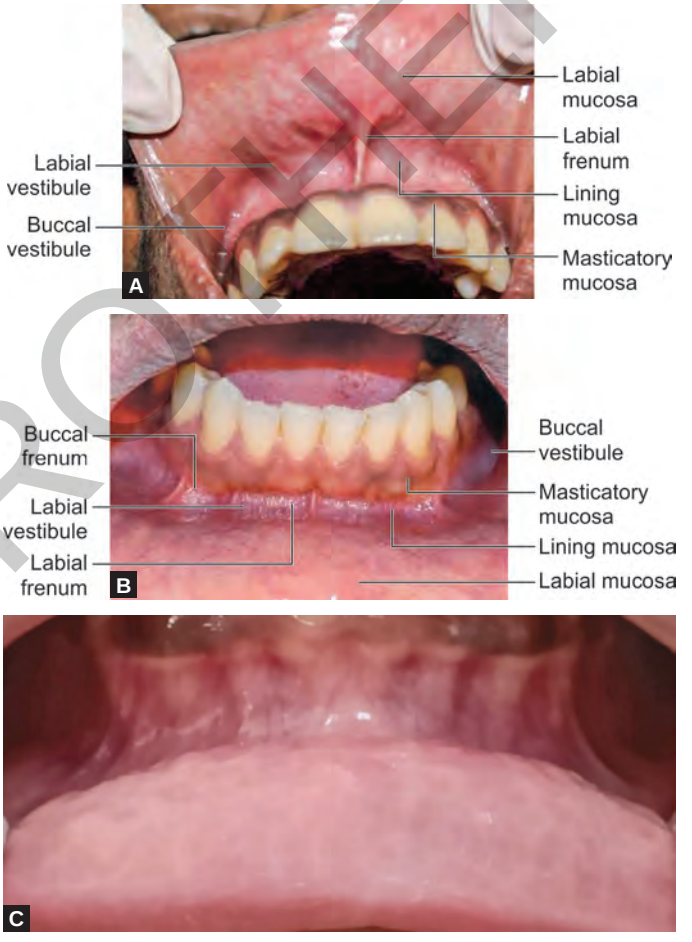

Figs. 17A to C: Labial mucosa: (A) Maxillary; (B) Mandibular; (C) Minor salivary glands on stretched lower labial mucosa.

(*Courtesy:* Dr Satyapal Johaley, Senior Lecturer, Department of OMR, New Horizon Dental College, Bilaspur, Chhattisgarh, India)

positioned posteriorly. Numerous minor salivary glands are also dispersed along the buccal mucosa.

The texture of the buccal mucosa resembles that of labial mucosa which may become granular because of the presence of various mucous and mixed glands in the submucosal tissue. The mucous membrane is soft and attached to the inner fascia of the buccinator muscle.

Fordyce's granules which are granular to touch; and are often observed extending from the commissures to the molar region **(Fig. 18D)**. These are believed to be ectopic sebaceous glands and appear as yellowish to orangish granules.

JAYPEE BROTHERS

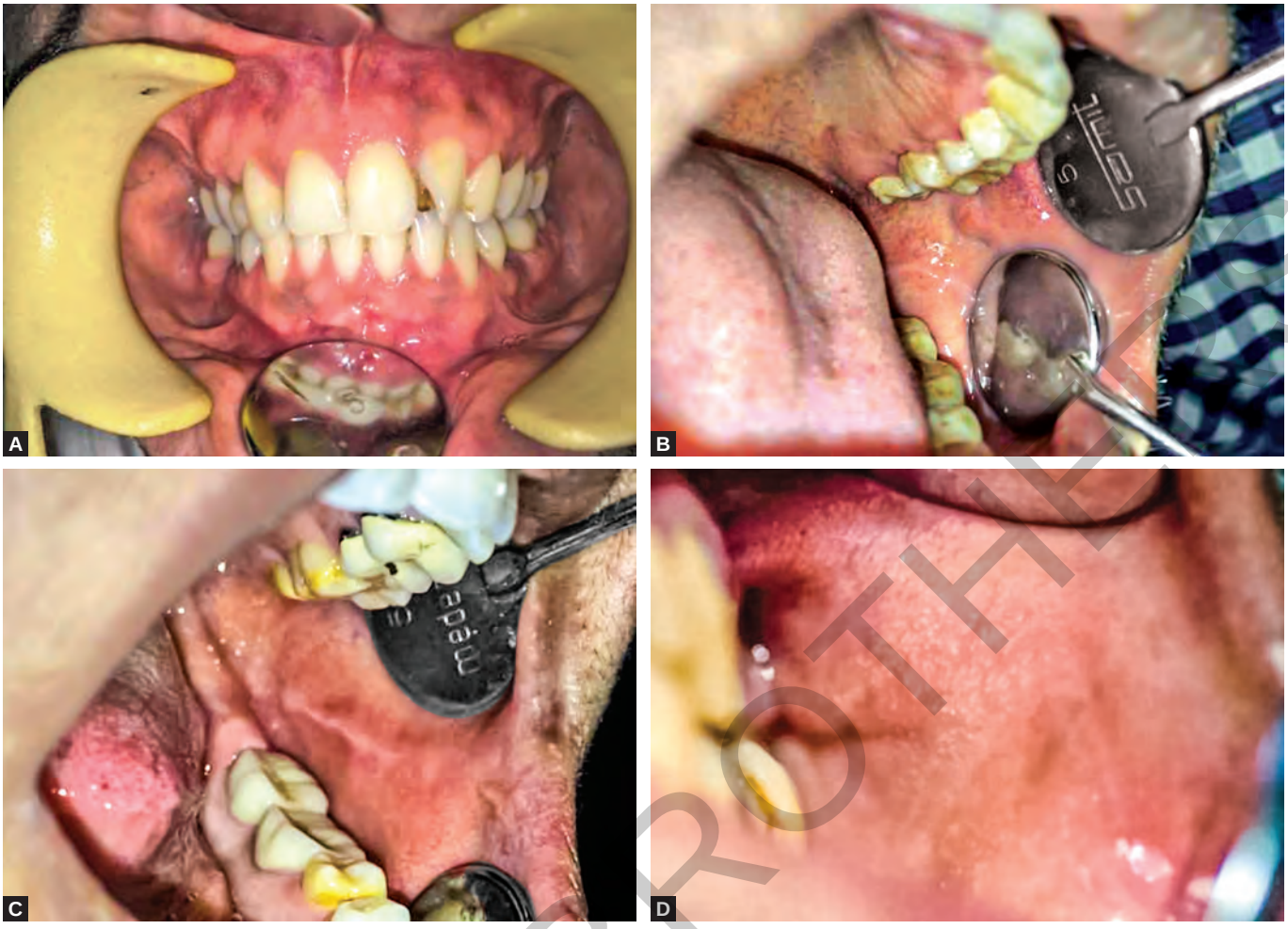

Figs. 18A to D: (A) Buccal gutter; (B) Parotid duct opening seen on the buccal mucosa, opposite the occlusal surface of maxillary first molar; (C) Linea alba, seen on the buccal mucosa, caused due to friction of the buccal cusps of the maxillary and mandibular posterior teeth against the mucosa; (D) Fordyce's granules appear as tiny orangish elevated lesions which feel rough to the tongue.

(*Courtesy:* Dr Kaustubh, Sansare, Professor and Head; Dr Sonal Vahanwala, Associate Professor, Department of Oral Medicine and Radiology, Nair Hospital Dental College, Mumbai, Maharashtra, India)

The buccal fat pad is located underneath and distal to the parotid papilla, is easily palpated and may vary considerably in the degree of prominence.

The lateral frenula or buccal frenula are numerous tissue folds extending laterally from alveolar mucosa to buccal mucosa, usually located in canine or premolar area in both maxillary and mandibular arch.

A thin mucous membrane with numerous small blood vessels is present in the vestibular sulcus.

The mucous membrane is attached to underlying muscles and bone with a very loose submucous tissue which permits increase in mobility of the lips and buccal mucosa that is reduced in the molar region.

Pathological Appearance

The normal mucosa is smooth, moist, and shiny. In case the mirror sticks to the mucosa, it indicates presence of dryness or xerostomia. In case of any abnormal findings the clinician should, note the following:

- ❖ Type of abnormality—swelling, growth, erosion, ulcer, and patch
- ❖ Size
- ❖ Color
- ❖ Location
- ❖ Texture
- ❖ Consistency

It is also pertinent to palpate the area and the surrounding tissue. While firm masses suggest a tumor, soft swellings are probably infections or cysts. The clinician should note that, linea alba can sometimes occur due to stress and as a result of bruxism.

Special attention needs to be given to the papilla on bilateral buccal mucosa adjacent to maxillary second molar, which is the opening of the parotid duct (or Stenson's duct). It may be normal or swollen, and saliva expressed from it (on milking the duct), may extrude pus in case of bacterial sialadenitis. There may be scanty or absent salivation in cases of Xerostomia.

Hard and Soft Palate

The illumination and both direct and indirect vision are utilized for examination of hard palate and maxillary tuberosity. This visual examination is followed by digital palpation of the entire area which should be done by applying firm pressure against the bone. The palatal tissue is homogenously pale pink in color, on palpation it is firm anteriorly and laterally in the midline

JAYPEE BROTHERS

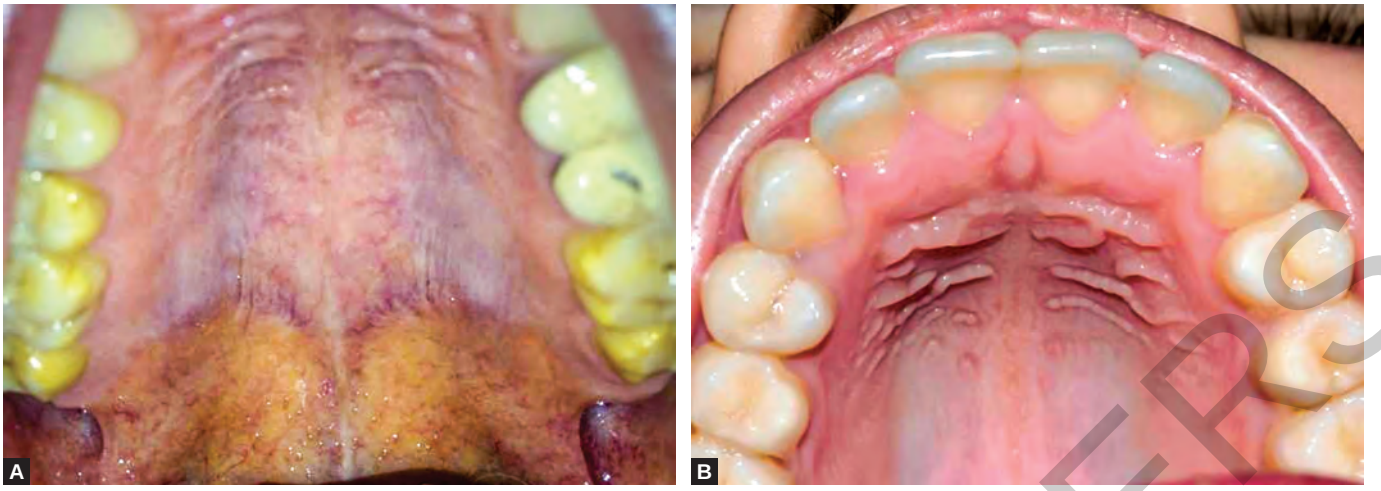

Figs. 19A and B: (A) Hard and soft palate; (B) Hard palate with rugae and incisive papilliae.
(*Courtesy:* Dr Satyapal Johaley, Senior Lecturer, Department of OMR, New Horizon Dental College, Bilaspur, Chhattisgarh, India)

whereas more compressible posteriorly and medially to the apices of the teeth. Examination of soft palate and uvula is done through direct vision and palpation is done when necessary. Their color is usually reddish pink owing to the less vascularity compared to the oropharynx. For proper inspection, the patient should be requested to say says "ah." During function, tissues appear symmetrical, loose and mobile and on palpation, their consistency is homogenous and spongy.

Normal Clinical Appearance

The hard palate **(Fig. 19A)** is confluent with the maxillary alveolar arches anteriorly and soft palate posteriorly. Median raphe extends in the center till the incisive fossa anteriorly where the nasopalatine foramen opens. The palatal gingiva is firm and resilient and it is the peripheral extension of the mucosa covering the hard palate.

The mucous membrane of anterior hard palate is keratinized and immovable as it is firmly bound to the underlying bone. Palatine rugae are irregular branching ridges radiating from the incisive papilla on the anterior hard palate **(Fig. 19B)**.

Posteriorly on the lateral portions of the hard palate there are various mucous glands, nerves, and blood vessels in the submucosa. This region is soft to palpation due to the presence of fat and mucous glands.

Posterior to the third molar the hard palate mucosa merges with the vestibular mucosa peripherally and pterygomandibular raphe posteriorly **(Fig. 20)**.

The soft palate mucosa is thin, nonkeratinized, and vascularized, giving it a slightly darker red appearance than the hard palate. It has a silky appearance with large mucous gland ductal orifices dispersed throughout. The soft palate originates posteriorly, near to the fovea palatinae, on an imaginary line that continues laterally. The soft palate stretches backwards and downwards until it reaches the uvula. It serves as a barrier between the nasal cavity, oral cavity, and oropharynx **(Figs. 19A and 21A)**. Laterally and below, the soft palate merges with the faucial pillars.

Pathological Appearance

Any deviations from the norm should be documented. Denture stomatitis frequently manifests itself as a red velvety patch on the palate mucosa beneath a denture. A palatine torus is a hard, bony bulge in the middle of the hard palate that is covered with smooth, normal-looking mucosa. An abscess or tumor on either side of the hard palate might cause soft tissue edema.



Fig. 20: Pterygomandibular raphe.
(*Courtesy:* Dr Satyapal Johaley, Senior Lecturer, Department of OMR, New Horizon Dental College, Bilaspur, Chhattisgarh, India)

Ulcerations/erosions, inflammatory swellings, soft tissue/bony growths, Oroantral/oronasal abnormalities, cleft, and other abnormal/pathological features on the hard palate are all important. The above-mentioned shape, position, consistency, color, and duration must all be recorded because they will help with the diagnosis. In circumstances, where palpation is required, the clinician should apply a topical anesthetic to the tissues and palpate them from the midline out to the lateral surfaces. On palpation, the tissue will have a homogeneous and spongy consistency.

A yellowish coloring due to increased adipose tissue (particularly in older patients), overly long or short or shrunken uvulas, and uvulas that appear somewhat asymmetrical at repose are all unusual findings in the soft palate and uvula region. A bifid (cleft) uvula is occasionally seen.

Oropharynx and Fauces

The clinician can visualize directly by asking the patient to hold his or her tongue in a resting position (not projecting) while simultaneously opening his or her mouth wide and repeating "ahhh." Otherwise, the clinician should place the mirror on the tongue and gently press inferiorly (down) and anteriorly (forward) while asking the patient to utter "ahhh." More of the

JAYPEE BROTHERS

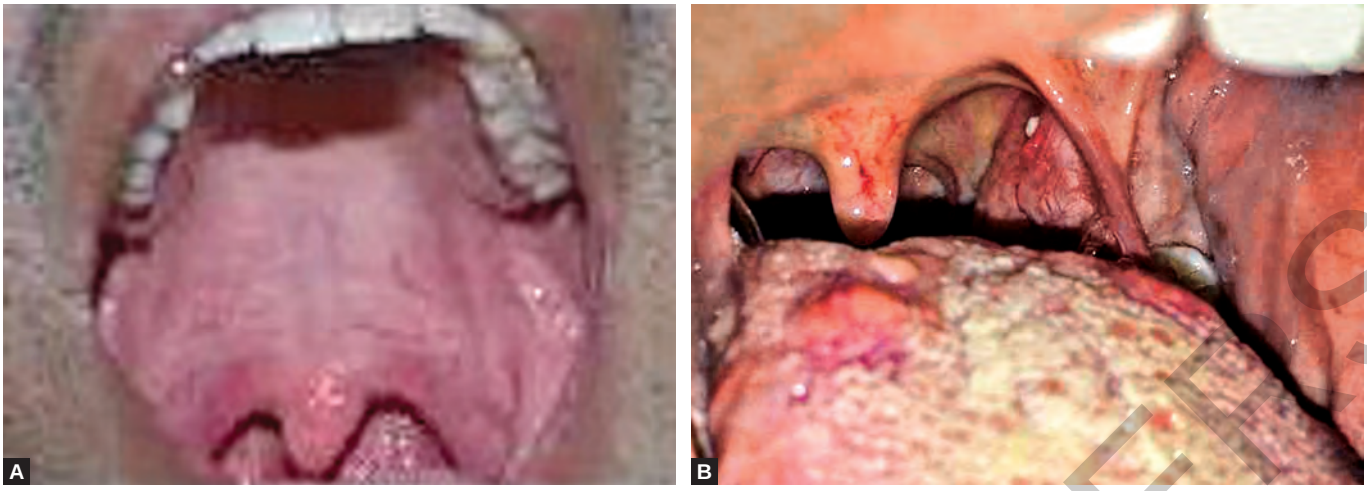

Figs. 21A and B: (A) Soft palate and uvula; (B) Uvula, fauces and tonsils.

oropharynx, posterior pharyngeal wall, anterior and posterior pillars, tonsillar crypt, tonsils, and uvula can be seen when the tongue is flattened. When a patient is particularly sensitive or has a gag reflex, the clinician must use greater care and precision with the tool and keep a close eye on the area to prevent repeating the process. Direct visualization can be used to evaluate the tonsils.

Normal Clinical Appearance

The oropharynx is located behind the mouth cavity and is bordered on the superior side by the soft palate and on the inferior side by a hypothetical horizontal line parallel to the epiglottis tip. The anterior boundary is formed by the isthmus of the fauces and the posterior portion of the tongue, while the lateral wall is formed by the palatopharyngeal arches and palatine tonsils **(Figs. 21A and B)**. The pharyngeal tonsils constitute the posterior wall.

The tissue in the posterior pharyngeal wall area seems extremely vascular trending toward reddish pink. The surface may be smooth or appear to have little coral pink to translucent, gelatin-like, and homogenous surface prominences somewhat yellow in color, with normal patches of distributed lymph tissues. The vascular, smooth, and symmetrical anterior and posterior pharyngeal pillars appear to be present.

The palatine tonsils are two rough, lobular, coral to light pink masses of lymphoid tissue (nodules or follicles) located between the anterior and posterior faucial pillars in the triangle depression (tonsillar sulcus). They run from the soft palate to the tongue's dorsum. They can be abnormally big or asymmetrical, with cratered and convoluted surfaces and deep clefts or crypts that can penetrate nearly the entire thickness without erythema or exudates. In the big crypts, food waste and germs may accumulate.

The pharynx is a mucous-membrane lined tubular region separated into three parts—(1) the nasopharynx (base of skull to upper surface of soft palate), (2) oropharynx (uvula to hyoid bone), and (3) laryngopharynx (uvula to hyoid bone) (hypopharynx, inferior to the epiglottis up to the opening of the esophagus). This area has a lot of vascularity, and vascular dilatation enhances the degree of redness. Small raised clusters of lymphoid tissue may be spread randomly over the oropharynx's soft, smooth surface mucosa.

Pathological Appearance

Oropharyngeal cancer is highly common in the oropharyngeal area, which has a pathological appearance (specifically HPV infection). Patients may present with complain of difficulty in swallowing, ear pain, the clinician needs to carefully inspect this area to rule out any pathology.

Pathologic findings in the posterior pharyngeal wall may include—appearance of homogeneous and nontender erythema associated with postnasal drip and/or smoking or erythema and purulent exudate associated with pharyngitis may cover sections of the pharyngeal wall. Ulcers, erosions, or visible enlargements or growths may be present at times.

Lymphocytic aggregates (on the posterior pharyngeal wall), patches of pale scarring in a radial or stellate pattern, possibly due to tonsillectomy remains, or torn or nonexistent pillars are all examples of unusual findings in the anterior and posterior pharyngeal pillars. Infection can cause swelling of the tonsils with asymmetry, erythema, and/or surface exudates. Dysphagia is a common complaint among patients (painful or difficult swallowing). Mouth breathing can also cause erythema and dysphagia, which can indicate a nasal obstruction. Tonsilloliths are often discovered embedded in the tonsils.

Tongue

The anterior two-thirds of the tongue is clearly visible. The posterior one-third cannot be seen on routine dental examination. The dorsum of the tongue should be examined first, followed by lateral borders and ventral surface. The clinician should request the patient to open his/her mouth and slightly protrude the tongue for examination of the dorsum. Then the patient should be requested to protrude more and the clinician should grasp the tip of the tongue with a 2 × 2 gauze, and gently stretch the tongue to one side and to visualize and examine the lateral border of the tongue. Multiple small vertical folds in the posterior lateral aspect of the tongue are the foliate papillae, alongside there may be some yellowish colored mass which could be accessory lymphoid tissue (lingual tonsils). Any abnormal swelling, or ulceration, observed needs to be palpated, normal tissue in this area is soft. The clinician needs to repeat the same examination process on the opposite side of the tongue. With the aid of a mouth mirror the far side of the tongue can be explored.

To check the ventral surface of the tongue the patient should be requested to lift their tongue. This surface has prominent veins. The clinician needs to inspect the lateral borders of the tongue and the floor of mouth, as these areas are most susceptible to malignant changes. The oral malignancies and potentially

JAYPEE BROTHERS

malignant lesions have a variety of clinical appearances including ulcers, masses, red areas, white areas, or a combination of these.

If there is any swelling or ulcers, then the area should be palpated. The tissue in this area should be soft. Particular attention should be paid to the sides of the tongue and the floor of the mouth.

Normal Clinical Appearance (Figs. 22A to C)

The **anterior two-thirds** (**oral part**) of the tongue are in front of the V-shaped sulcus terminalis. It is movable and is anteriorly linked to the mouth's floor by a median lingual frenum. Because of the existence of underlying lymphoid tissue creating the lingual tonsils, the **pharyngeal section** of the tongue **(the posterior one-third**) is immobile and has a bosselated surface. There are also a few minor salivary glands.

The **dorsum** of the tongue **(Fig. 22A)** has a roughened surface as the mucosa has numerous small elevations called *papillae*. There are four types of papillae **(Figs. 23A to C)**, which are as follows:

- ❖ The **filiform papillae** are many, slender, and conical structures that cover the dorsal surface and are pink in hue. The presence of chromogenic bacteria and the amount of keratinization are the main causes of color variation on the dorsal surface.
- ❖ The **fungiform papillae** are less in number and are dispersed across the tongue's sides and tip. They have the taste buds and are fashioned-like little mushrooms with a rounded surface and a richer red color.
- ❖ The **circumvallate papillae** are the largest and fewest in number, and they have a dark red tint. Just anterior and parallel to the terminal sulcus, they create a V-shaped line. On the surface and in a deep groove that surrounds each papilla, there are numerous taste buds. The ducts of minor serous salivary glands (von Ebner's glands) also open into the groove's base.
- ❖ The **foliate papillae** are present in the irregular, raised folds of mucosa in the posterior part of the lateral border. On the surface, these papillae may include taste buds, and the center of the papillae frequently contains lymphoid aggregates similar to those found in the rest of the **Waldeyer's ring**. In addition, the underlying lingual musculature contains small salivary glands.

Because of underlying lymphoid tissue prominences, the mucous membrane covering the base of the tongue is thick and has an uneven, rough surface. It extends into the oropharynx from the back.

The tongue's ventral surface **(Fig. 22C)** is smooth, with a thin mucous membrane securely attached to the musculature. Minor salivary glands **(Blandin and Nuhn glands**) are situated deep inside the tongue musculature on both sides of the midline. They can go all the way to the tip of the tongue.

In the midline, the lingual frenum is a raised fold of mucosa that connects the floor of the mouth to the ventral surface of the tongue. The color of the ventral surface varies from pink to red, although it is bluish due to the presence of strong veins.

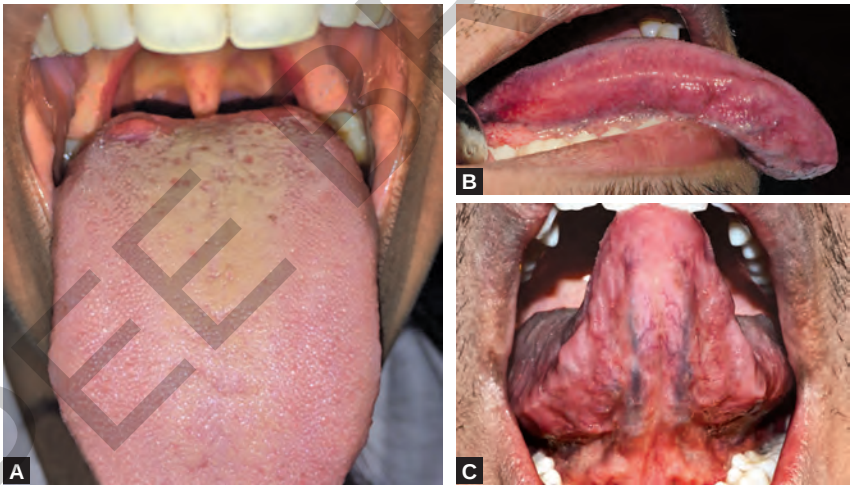

Figs. 22A to C: Tongue: (A) Dorsal surface; (B) Lateral border; (C) Ventral surface.

(*Courtesy:* Dr Kaustubh Sansare, Professor and Head; Dr Sonal Vahanwala, Associate Professor, Department of Oral Medicine and Radiology, Nair Hospital Dental College, Mumbai, Maharashtra, India)

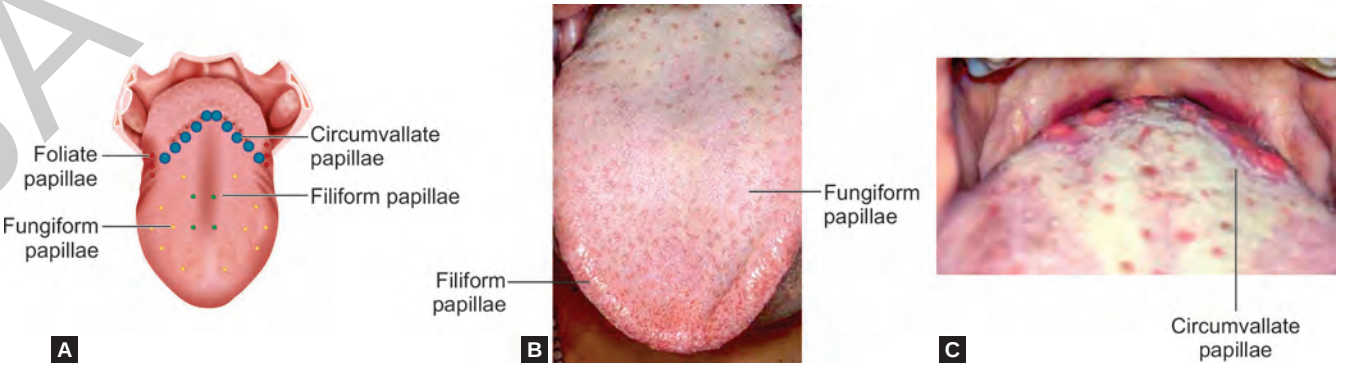

Figs. 23A to C: Papillae of the tongue: (A) Diagrammatic representation; (B) Filiform and fungiform; (C) Circumvallate.

JAYPEE BROTHERS

The tongue's **lateral borders (margins) (Fig. 22B)** divide the dorsal and ventral surfaces on each side before uniting at the apex. This section, where the papillae cease and the smooth ventral surface begins, has a stark difference in texture and color.

Pathological Appearance

Color changes, papillary distribution, and ulceration are all signs of systemic illnesses or infections. The tongue's lateral borders and the floor of the mouth are particularly vulnerable to cancer (Refer Chapter 14: Diseases of Tongue).

Floor of the Mouth

It is examined by the clinician under direct vision by using mouth mirror. After retracting the tongue with one mirror, other is used to inspect the areas near the inferior border of the mandible and midline of the floor. Openings of the submandibular ducts (Wharton's ducts) on each side of lingual frenum in the floor of mouth should be visualized. Bimanual palpation should be used to palpate the soft tissue structures in the floor of the mouth. Placing one index finger intraorally in the floor of the mouth lingual to the molars and the other extraorally on the skin medial to the patient's mandible and inferior to already placed intraoral index finger, the submandibular gland is palpated with a gentle up and down motion. Fingers are then moved forward to palpate the sublingual gland and floor of mouth. The salivary glands, usually feels lobulated on palpation. This examination though not painful, may give an awkward feeling to the patient and so the patient should be counseled before carrying out this procedure.

Normal Clinical Appearance (Figs. 24A and B)

Except for the sublingual ridges, the mouth's floor is covered by nonkeratinized, soft, and smooth mucosa. In this area, the vascular network is significant. It is a horseshoe-shaped region that wraps around the tongue's root medially and the mandibular teeth's gingivae anteriorly and laterally. It connects with the retromolar pad behind the lower third molar tooth and extends to the palatoglossal folds distally. The lingual frenulum divides it into two lateral areas. The genioglossus and geniohyoid muscles, the sublingual gland and its ducts, the upper portion of the submandibular glands and their ducts, nerves, lymph nodes, and a lot of adipose tissue are all found in each area. The sublingual folds or ridges are bilateral elevations generated by the sublingual glands and the ducts of the submandibular glands adjacent to the lingual frenulum. Each sublingual fold terminates anteriorly in the sublingual caruncle, a tiny spherical papilla with apertures for the flow of secretions from the submandibular and sublingual glands.

Pathological Appearance

Normally, the sublingual gland feels ropey or lobulated. It will feel hard if a salivary stone is present. On palpation, a salivary gland tumor is a firm oval or circular mass. This region is also vulnerable to cancer.

Mandible

Direct and indirect vision should be used to evaluate the mandible's body, followed by digital palpation of the entire anatomy. With a mouth mirror, the clinician should stretch the tissues of the floor of the mouth away from the inferior border of the mandible, and then digitally palpate the mandible's body along the lingual and facial surfaces. To check for lumps, palpate the area around the jaws as well. Tenderness, which could be the result of infection or inflammation, may be discovered during this examination.

Normal Clinical Appearance

Normal tissues are uniformly coral pink in color and firm in texture, with no visible or palpable lesions. Mandibular tori and exostoses are the most common unusual features in this area.

Pathological Appearance

Partially erupted third molars or scars from third molar extraction might be seen in the retromolar region. Because of the continual friction caused by masticatory activity, this area is also prone to hyperkeratosis.

Gingiva and Alveolar Mucosa

The gingiva and alveolar mucosa can be screened by the clinician by using two mouth mirrors to gently retract the labial and buccal mucosa starting from one end of the maxillary arch posteriorly gently moving forward, crossing the midline to the poster region and then repeating the same for the mandibular arch, to view the buccal and labial aspect of the gingiva. The palatal aspect can be viewed in indirect vision using the mouth mirror, the lingual gingiva can be viewed by gently pushing aside the lateral border of the tongue to view the right and left side. Gingival and periodontal pockets may be assessed by using the periodontal probe.

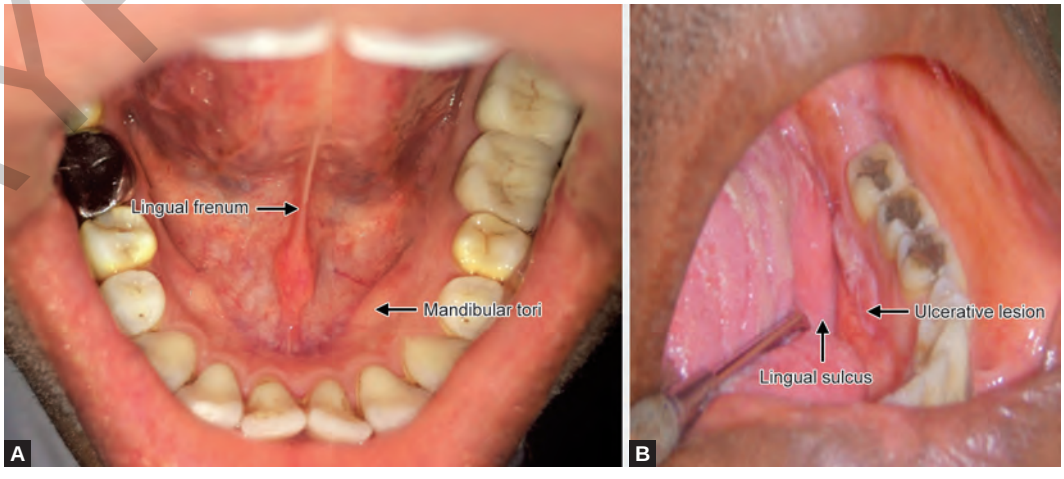

Figs. 24A and B: Floor of the mouth: (A) Showing the lingual frenum with submandibular gland openings, also seen are mandibular tori; (B) Lingual sulcus with ulcerative lesion on the lingual mucosa of the left mandible.

JAYPEE BROTHERS

Normal Clinical Appearance (Fig. 25)

Healthy gingiva is pink and stippled. The gingiva is firmly attached to the alveolar bone and is continuous with the movable alveolar mucosa at the mucogingival junction.

There are two subdivisions of gingiva, attached and the free gingiva. The free gingiva is unattached, forms a collar that is closely adapted around the tooth. Attached gingiva is keratinized, present adjacent to free gingiva and firmly attached to underlying bone.

The gingival sulcus is the crevice around the tooth formed by free marginal gingiva which is attached to tooth by epithelial attachment at or near the cementoenamel junction.

Minor salivary glands may be seen in the alveolar mucosa and occasionally the attached gingiva.

Pathological Appearance

Abnormalities include generalized or localized swelling, erythema, ulceration or bleeding. A gingival graft may appear as a pale, demarcated area of the attached gingiva (Refer Chapter 6: Periodontal Diseases).

Palpation of maxilla and mandible should be done as it may reveal enlargements such as exostoses/tori and tenderness which could indicate presence of infection or inflammation.

Salivary Flow and Consistency (Fig. 26)

It varies for each patient. A clinician should look for frothy or thick ropy saliva, as well as a decrease in salivation (xerostomia). To aid in seeing and diagnosing the Stenson's duct opening, the clinician can milk the salivary glands from the tail to the midline.

The clinician must first dry the floor of the mouth with cotton to visualize and assess the flow from the Wharton's duct opening and other ducts of both the sublingual and submandibular glands.



Fig. 25: Gingiva and alveolar mucosa.



Fig. 26: Parotid duct opening-testing for salivary flow.

Cancer Screening (Figs. 27A to D and Table 4)

The dental clinician has an added responsibility to screen the patient for early diagnosis of potentially malignant diseases and oral cancer. The special diagnostic aids and methods have been discussed in Chapter 12: Oral Cancer. When checking the oral cavity, the clinician should be vigilant to detect early signs of this disease which include the following:

- ❖ Early signs
  - Persistent red and/or white patches and unusual surface changes
  - Nonhealing ulcer
  - Unusual oral bleeding or epistaxis
  - Progressive swelling or enlargement
  - Sudden tooth mobility
  - Chronic hoarseness
- ❖ Late signs
  - Indurated areas
  - Paresthesia, dysesthesia of the tongue or lips
  - Chronic ear ache
  - Trismus with dysphagia
  - Cervical lymphadenopathy
  - Persistent pain or referred pain
  - Altered vision

Few oral squamous cell carcinomas (OSCCs) can be seen developing in seemingly normal mucosa, however, the majority of OSCCs are caused by potentially malignant disorders (PMDs), such as leukoplakia (white lesion), erythroplakia (red lesion), speckled leukoplakia (red and white lesion), or verrucous leukoplakia, and are often linked to a history of chronic irritation and/or tobacco. Any single ulcer, lump, red patch, or white patch (especially if it lasts



Figs. 27A to D: Clinical signs of malignancy: (A) Persistent swelling; (B) Persistent white patch; (C) Nonhealing ulcer; (D) Induration.

(*Courtesy:* Dr Kaustubh, Sansare, Professor and Head; Dr Sonal Vahanwala, Associate Professor, Department of Oral Medicine and Radiology, Nair Hospital Dental College, Mumbai, Maharashtra, India)

JAYPEE BROTHERS

ANNOTATE 1: Blood, lymphatic and nerve supply to the oral cavity.

Nerve Supply (Fig. 28)

Branches of several cranial nerves provide both sensory and motor nerve supply to the oral cavity:

- Greater and lesser palatine nerves and nasopalatine nerves (CN V2): It supply the roof and palate.
- Lingual nerve (CN V3): It serves the floor of the mouth and supplies touch and temperature sensation for the anterior two-thirds of the tongue.
- Chorda tympani nerve (CN VII): The branch of the facial nerve contains taste fibers from the anterior two-thirds of the tongue.
- Buccal nerve (CN V3): It provides sensory innervation to the skin and mucosa of the cheek.
- Dental plexuses: It is formed by branches of the superior (CN V2) and inferior alveolar nerves (CN V3); supply the teeth.
- Lingual, palatine, nasopalatine, and superior alveolar nerves: It supply the gingivae
- Hypoglossal nerve (CN XII): It innervates the muscles of the tongue (except for the palatoglossus).
- Glossopharyngeal nerve (CN IX): It supplies general sensory and taste for the posterior one-third of the tongue.
- Internal laryngeal nerve (CN X): Its branches supply general sensation to a small part of the posterior part of the tongue.
- Postsynaptic parasympathetic secretomotor fibers: It runs to the serous glands from the submandibular ganglion that suspends from the lingual nerve.
- Great auricular nerve: It innervates the parotid gland, and comes from the cervical plexus.
- Auriculotemporal nerve (CN V3): It provides sensory innervation to the parotid gland.
- Glossopharyngeal nerve (CN IX): It provides presynaptic parasympathetic fibers to the otic ganglion; postsynaptic parasympathetic fibers from the otic ganglion are secretomotor (stimulate the gland to secrete saliva) to the parotid gland.
- Presynaptic secretomotor fibers: Fibers from the chorda tympani synapse with postsynaptic fibers of the submandibular ganglion that innervate submandibular and sublingual salivary glands.

Blood Supply and Lymphatic Drainage (Figs. 29 and 30)

Branches of the external carotid artery (facial, maxillary, and lingual) supply blood to the oral cavity.

- Superior labial branches of the facial arteries and infraorbital arteries—supply blood to the upper lip.
- Inferior branches of the facial arteries and mental arteries—to the lower lip
- Superior alveolar arteries (branch of maxillary artery)—to the maxillary teeth
- Inferior alveolar arteries (branch of maxillary artery)—to mandibular teeth
- Greater and lesser palatine arteries—to the palate.
- Branches of the lingual artery—to the tongue.
- Dorsal lingual arteries—to the posterior part of the tongue.
- Deep lingual artery—supplies the anterior part of the tongue and communicates with the dorsal arteries at the apex.
- Sublingual artery—to the sublingual gland and the floor of the oral cavity.
- Branches of the external carotid and superficial temporal arteries—to the parotid gland.
- Submental arteries—to the submandibular glands and sublingual glands.

Veins of the oral cavity generally follow the arteries and have the same names. The veins of the palate drain into the pterygoid venous plexus. The lingual veins of the tongue drain into the internal jugular vein.

Contd...

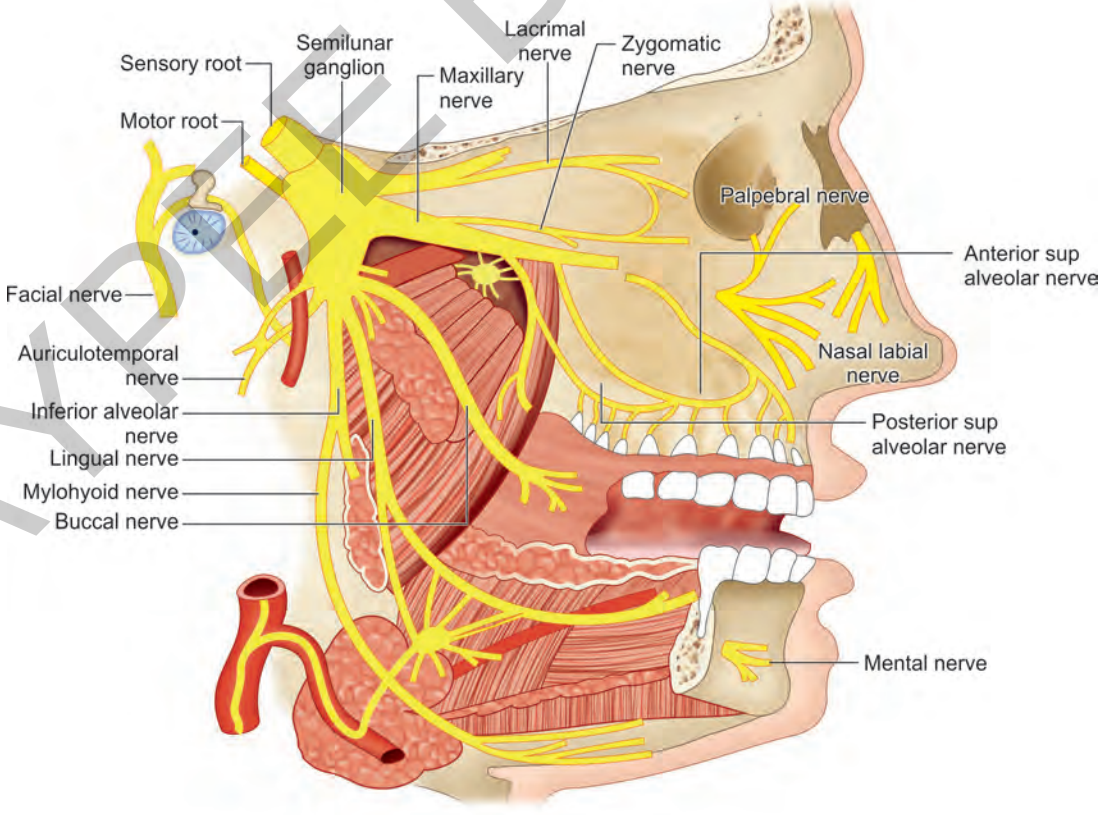

Fig. 28: Nerve supply to the oral cavity.

JAYPEE BROTHERS

Contd...

All lymphatics from the head and neck drain directly or indirectly into the deep cervical lymph nodes. Lymph from these nodes then drains into the jugular lymphatic trunk, which joins thoracic duct and internal jugular vein/brachiocephalic vein on the left and right side respectively.

- Lymph from the upper lip, teeth, lateral parts of the anterior part of the tongue, and gingivae drains into the submandibular lymph nodes.
- Lymph from the lower lip and apex of the tongue drains into the submental lymph nodes.
- Lymph from the medial anterior portion of the tongue drains into the inferior deep cervical lymph nodes, and the posterior portion of the tongue drains into the superior deep cervical lymph nodes.
- The parotid glands drain their lymph into the superficial and deep cervical lymph nodes. The submandibular glands drain lymph into the deep cervical lymph nodes.

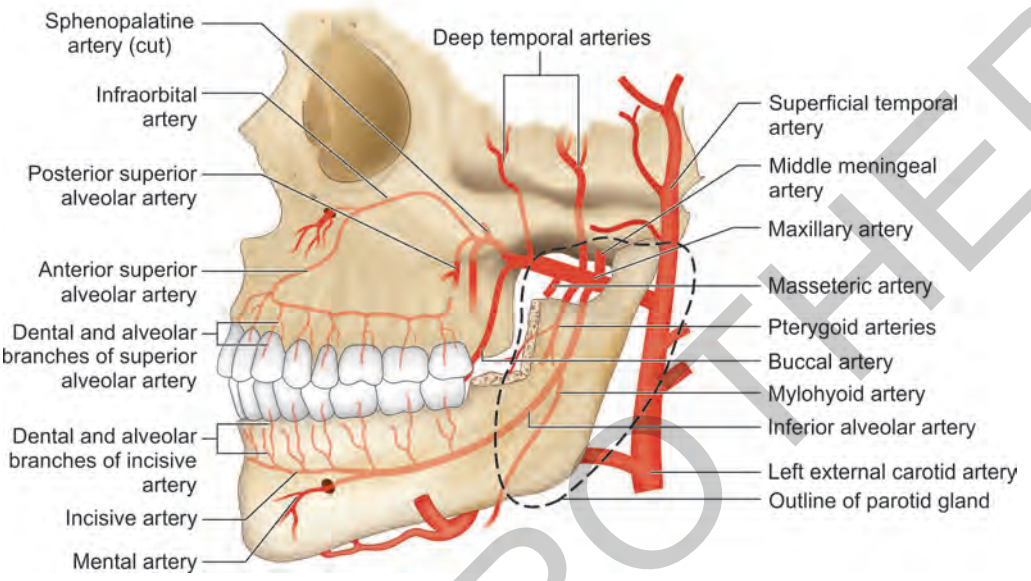

Fig. 29: Blood supply to the oral cavity.

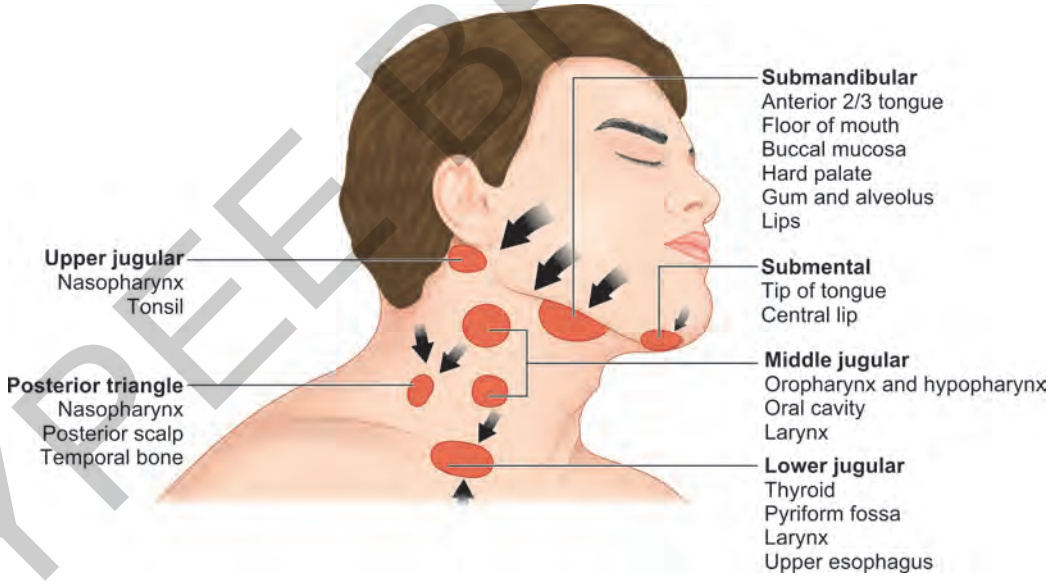

Fig. 30: Lymphatic drainage of the oral cavity.

longer than 3 weeks) should be considered cancerous. It is generally connected with hard and/or fixed cervical lymph node enlargements.

Diagnosis

In clinical practice, diagnosis, and diagnosis inference play a crucial role. It is the process of analyzing and interpreting clinical data in order to get a conclusion about a person's health state. Any of the following conclusions could be reached:

- ❖ Validation of person's normal health
- ❖ Deviation from health
- ❖ A disease entity with its relevant associated features.

Diagnosis, thus defines the needs of the patient, which forms the basis for deciding appropriate treatment of the case **(Box 13).**

The clinician has to interpret the collected data using following methods:

- ❖ Matching clinical presentation with clinician's own past experiences and known facts (evidence, criteria) about the diseases.

JAYPEE BROTHERS

- ❖ Infer the cause and effect in accordance with elementary scientific knowledge particularly physiology, anatomy, biochemistry, psychology, and pathology.

Following characteristics denotes a good diagnosis:

- ❖ Accuracy
- ❖ Completeness
- ❖ Precedence

There are two main levels of accuracy of diagnosis, which are as follows:

1. Provisional diagnosis (the interim, working, presumptive, or differential diagnosis)
2. Definitive diagnosis (post-investigation diagnosis, postoperative diagnosis, histopathological diagnosis, and postmortem diagnosis)

Differential Diagnosis

It is not conclusive in identifying a specific disease process, but it does provide a list of possibilities for the patient's case history **(Box 13)**. These disorders may have similar signs and symptoms, as well as a similar course and progression. When a diagnosis is unknown, the options are described as *differential diagnoses*, which can be expressed in two ways, but are either possibilities or hypotheses that have yet to be verified:

- ❖ Diseases that could be the cause of the current symptom complex or syndrome.
- ❖ A variety of different diseases.

A symptom complex is a collection of symptoms that occur at the same time and characterize a condition.

Syndrome: Cause a slew of symptoms that cannot be traced back to a single source.

The term "**disease**" refers to a pre-existing ailment.

Provisional Diagnosis

It is the diagnosis arrived upon after initial interaction with patient and history taking, clinical examination and basic investigations. As it is derived from cumulative but inadequate

Box 13: Working classification of oral lesions.

Oral mucosal lesions can be grouped into five categories, known as the 5 "I"s:

1. Inherent (congenital or hereditary, e.g., white sponge nevus)
2. Inflammatory (e.g., oral lichen planus and some variants of geographic tongue)
3. Infectious (e.g., oral candidiasis)
4. Iatrogenic (e.g., drug-induced lichenoid reaction)
   Iatrogenic disease is the result of diagnostic and therapeutic procedures undertaken on a patient. With the multitude of drugs prescribed to a single patient adverse drug reactions are bound to occur. For example, drug-induced gingival enlargement.
5. Idiopathic (e.g., oral potentially malignant lesion or neoplasm, and gingival enlargements).
   Idiopathic disease is any disease that is of uncertain or unknown origin may be termed idiopathic. For example, necrotizing sialometaplasia and mycosis fungoides.

Or they may be classified as per the etiopathogenic classifications.

The "MIND" paradigm.

1. ***Metabolic*** is a group of oral lesions occurring due to various systemic diseases. These diseases may either be of a hormonal or a nutritional nature. The oral cavity could be affected directly, as in Addison's disease, which produces changes in oral pigmentations of the tongue secondary to increased beta lipotropin or adrenocorticotropic hormone each of which stimulates production of melanocytes, amyloidosis which causes macroglossia secondary to the amyloid deposition.
2. ***Inflammatory*** lesions are common and have subcategories. These lesions sometimes manifest the cardinal signs of inflammation—redness, swelling, heat, and pain. The subcategories include trauma, reactive, infectious diseases (viral, bacterial, and fungal), and the immunologic lesions (allergic reactions, autoimmune, and immunodeficiency diseases). The most common inflammatory lesion in the oral cavity is parulis (gum boil).
3. ***Neoplastic*** lesions may represent a benign, potentially malignant or malignant process and therefore cover a large group of both epithelial and mesenchymal tissues that have uncontrolled growth. Adenomas a common occurrence.
4. ***Developmental*** could be of a genetic (heritable) or acquired nature. Either of these may be of a congenital nature (present at birth) or show an oral manifestation as the individual matures. These maldevelopments may manifest as a number of clinical presentations, e.g., clefts, cyst, and tori.
   Genetic disease is a disease whose underlying basis is due to action of a gene or several genes acting to produce the defect. It is caused by an abnormality in an individual's genome. Genes in general are the biological code for the production of different types of proteins.
   The abnormality can range from minuscule to major—from a discrete mutation in a single base in the DNA of a single gene to a gross chromosome abnormality involving the addition or subtraction of an entire chromosome or set of chromosomes. Some genetic disorders are inherited from the parents, while other genetic diseases are caused by acquired changes or mutations in a pre-existing gene or group of genes. Mutations can occur either randomly or due to some environmental exposure.
   The term "**Congenital**" means that it is present at birth but implies it is a development abnormality that occurred during the growth of the fetus at a specific time while in the uterus, rather than a hereditary defect or abnormality. At various stages of fetal development, the fetus may be sensitive or at risk for abnormalities and disabilities—such as congenital heart disease or cleft palate or other organ defects. Whether due to environmental factors, the health or condition of the mother, or for unknown reasons, a fetus may develop an illness, disease, condition or other abnormality that will be present when he or she is born. Some developmental abnormalities are not evident at birth, (for example, an inguinal hernia) and develop at a later stage. They are described as delayed developmental abnormalities. If a congenital defect occurs frequently and is related to a particular line or breed then it is likely to be hereditary. A **hereditary** condition is one that is genetically predetermined. It is dependent on the genetic material or chromosomes that a person inherits from one or both biological parents. Color blindness and sickle cell anemia are two hereditary conditions that are passed on to a fetus from the genes of the mother and father.
   A congenital condition cannot be passed on from parent to child. If a child is born with a congenital defect—even one that is rather severe—if he or she can otherwise procreate, the likelihood is that a normal child will result. With a hereditary or genetic abnormality, it may be passed on from generation to generation.

Diseases or lesions classified under the MIND paradigm may be acute or chronic.

Acute disease is a disease characterized by a relatively sudden onset of symptoms that are usually severe and worsen rapidly. An episode of acute oral disease results in recovery to a state comparable to the patient's condition of health and activity before the disease or in passage into a chronic phase. Examples are primary herpetic gingivostomatitis and acute necrotizing ulcerative gingivitis.

Chronic disease is a disease that persists over a long period. The symptoms of chronic disease are sometimes less severe than those of the acute phase of the same disease. Chronic disease may be progressive and result in complete or partial disability. Examples of chronic disease include pemphigus vulgaris and major aphthous ulcers.

JAYPEE BROTHERS

details, it is referred to as "interim" or "temporary." When used for the primary management of a patient, it is termed as the ***working diagnosis***.

Presumptive Diagnosis

The clinician initiates definitive treatment based on this diagnosis before establishing a definitive diagnosis. This definite treatment is started keeping in mind the possibility that the diagnosis may ultimately be correct, particularly when the treatment is comparatively safe and deferring may cause complications. The patient needs to be informed about risks involved. The treatment plan is considered as preliminary, which can be altered the moment a definitive diagnosis is ascertained.

Definitive Diagnosis

This phrase refers to the one diagnosis that has a high degree of probability/accuracy and from which further precise data can be collected or obtained.

- ❖ The findings of investigations and diagnostic procedures, imaging studies, specific biochemical or immunological tests, evidence of the presence of a specific microorganism, and cytological or histological study of sick tissues.
- ❖ A better view or access, such as by endoscopy, anesthesia-assisted examination, or surgical exposure.
- ❖ During observation, the establishment of recognizable patterns of symptoms or signals.
- ❖ The patient's reaction to a specific treatment.

Diagnostic Testing

It has become an important part of routine medical and dental treatment. It could happen in a succession of information gathering, integration, and interpretation sessions, with each new piece of information improving the working diagnosis.

- ❖ Pathology is typically divided into two disciplines:
  1. Laboratory medicine, often known as clinical pathology, which s concerned with the analysis of fluid specimens such as blood and urine.
     It is a medical specialism that examines the following:
     - ♦ Specific analytes in body fluids (e.g., cholesterol in serum, protein in urine, or glucose in cerebrospinal fluid), and microbe identification (e.g., disease-causing bacteria in sputum, HIV in blood, or parasites in stool).
     - ♦ The examination of bone marrow samples (e.g., the identification of a specific of type of leukemia).
     - ♦ The administration of transfusion treatment (e.g., crossmatching blood products, or plasmapheresis).
  2. Anatomic pathology examines tissues, cells, and other solid specimens under a microscope. It is a medical subspecialty that involves anatomic pathologists examining tissue specimens or physiological fluids, then interpreting the results and diagnosing diseases or health issues. They may also do postmortem investigations. Anatomic pathologists also do not interface with patients directly, with the exception of tiny needle aspiration biopsies.
     Clinical pathologists, with the exception of those with competence in blood banking and coagulation, rarely engage directly with patients.
     Laboratory scientists (medical technologists) help with the procedure by preparing and collecting samples as well as conducting tests.
- ❖ Medical imaging, also known as radiology, is the application of imaging technologies [such as X-rays, ultrasounds, computed tomography (CT), magnetic resonance imaging (MRI), and positron emission tomography (PET), panoramic radiographs, and cone beam computed tomography] to diagnose diseases and health conditions. It is also used to select and schedule treatments, track treatment effectiveness, and offer long-term follow-up in many cases. The radiologists or nuclear medicine professionals perform image interpretation for certain examinations using radioactive nuclides.
- ❖ Molecular imaging is a new field in radiology that uses functional MRI techniques as well as MRI, PET/CT, or PET/MRI with molecular imaging probes. Several new molecular imaging probes have recently been approved for clinical use, and a rising number of them are currently being tested in clinical trials. Interventional radiology, which encompasses image-guided biopsy and diagnostic procedures as well as image-guided, minimally invasive therapies, is part of the field of radiology.

Final Diagnosis

If the physician finds more than one condition, the diagnosis for the chief complaint (the problem for which the patient came to the dentist office) should be given first. Subsidiary diagnoses should be noted for any other findings or secondary concerns. The tags "by history," "previously diagnosed," or "treated" should be used to reflect the current status of previously diagnosed issues that still need to be addressed. Any complaint or problem that is observed but not diagnosed during this evaluation may be noted as "to be ruled out." Because oral medicine encompasses a wide range of regional issues that may or may not be influenced by concomitant systemic disease, it is a good idea to construct a diagnosis list that includes both oral lesions and systemic issues, even if they are unrelated to the patient's current major complaint. For instance, the final diagnostic summary could be as follows:

1. Alveolar abscess, mandibular right second molar
2. Rampant generalized dental caries secondary to radiation-induced salivary hypofunction.
3. Burning mouth complain due to xerostomia, with multiple ulcers on the right buccal mucosa
4. Carcinoma of the right tonsil, by history, excised and treated with 65 Gy 2 years ago
5. The patient is also medically compromised with diabetes and hypertension.

Treatment Plan

It is the blueprint for case management. It is broadly divided into four phases, which are as follows:

Preliminary Phase/Emergency Phase

This includes the chief complaint **(Box 14)** along with those dental problems producing acute symptoms and their potential sources. Emergency treatments may include soft tissue lesions due to local or systemic causes, painful, and infected tooth/teeth, bleeding gums with bad breath (halitosis), oral lesions or growths due to habits such as *paan* and *gutkha* chewing, maxillofacial trauma, severe pain due to unknown origin, and acute swelling in the oral cavity.

JAYPEE BROTHERS

Box 14: Types of oral medicine consultations.

1. Diagnosis and nonsurgical treatment of orofacial complaints such as oral mucosal lesions and diseases, disorders of the temporomandibular joint and myofascial dysfunction, orofacial pain involving the jaw and facial pain, dental, and jaw bone developmental anomalies, bone lesions involving the jaws, salivary gland disorders and hypofunction, disorders of oral sensation, such as dysgeusia, dysesthesia, and burning mouth syndrome.
2. Dental treatment of medically compromised patients for whom the routine dental procedures will be required to be modified, in order to reduce the risk of adverse effects or reactions.
3. Consultation on the management and treatment of dental/oral disease that does not respond to standard treatment procedures, such as in cases of periodontal disease in which there is a likelihood that systemic disease is an etiologic cofactor.

Phase I—Nonsurgical Phase

This includes oral prophylaxis, removal of calculus and root planning, correction restorations or appliances with are causing chronic irritation to the local tissues. Occlusal rehabilitation, minor orthodontic corrections, antimicrobial therapy for any local or systemic infections having oral manifestations. This phase also includes patient education, counseling and awareness; regarding the importance of oral hygiene, tooth brushing, use of fluorides and consequences of bad habits such as tobacco, *paan*, and *gutkha*, along with instructions on balanced diet.

Phase II—Surgical Phase

This includes root canal treatments, and implants, surgical treatment of gums and pockets, required gingivectomies, frenectomies, surgical extractions, etc. This may also include planned surgeries for cosmetic enhancement or improved occlusal function.

Phase III—Restorative Phase

This includes, cosmetic fillings, prosthetic rehabilitation which includes dentures; fixed and removal, implants loading, and orthodontic corrections.

ANNOTATE 2: SOAP.

These notes are a highly structured approach for documenting and recording a patient's progress throughout treatment. It is one of the various formats that a doctor can utilize. The clinician enters these notes into the patient's medical record to disseminate information to other health providers and to document patient contact.
SOAP is an acronym for:
Subjective: The patient's perspective on the problem or intervention.
Objective: The objective observations and therapy efforts of the therapists [e.g., routine outcome measurement (ROM) and outcome measures].
Assessment: The therapist's study of the various components of the assessment is referred to as assessment.
Plan: The method by which the therapy will be established in order to achieve the aims or objectives.
Modified Template for Clinical SOAP Note Format
A. Subjective – assessment based on the History
- HPI: this should include the severity of symptoms in chronological order of patient's complains, information obtained from other sources (the source of this additional information if not the patient should be identified).
- Relevant past medical history.
- Relevant appraisal of systems, for example, "Patient has not had lesions on the skin along with the mucosal lesions."
- List and dosage of medications which the patient is currently taking.

B. Objective – assessment based on the physical/clinical exam and laboratory investigations
- All the vital signs
- Clinical examination
- All required and relevant laboratory and imaging investigation should be completed at the visit.

C. Assessment/Problem list – the treating clinician's assessment of the patient's problems
- Assessment: A single sentence description of the patient and his/her chief complain
- Problem list: A list of all problems other than chief complain identified
- All listed problems must be supported by findings in subjective and objective areas. The clinician should try to take the assessment of the major problem/chief complain to the highest level of diagnosis, for example, "right side pain and swelling of the face with partial trismus due to erupting and impacted right side third molar
- The clinician also provide at least 2 differential diagnoses for the major new problem identified.

D. Plan – The clinicians treatment plan for the patient based on the problems identified
- The clinician needs to diagnose and develop a treatment plan for each differential diagnosis.
- The diagnostic plan should include all or any of the tests, procedures, other laboratory and imaging investigations, cross consultations, etc. The treatment plan should also include: patient education, pharmacotherapy, other therapeutic procedures.
- The patient should be informed about the follow-up and next scheduled visit.

The main benefit of the SOAP documentation format is that it is widely utilized and thus well-known in the healthcare industry. It emphasizes clear and well-organized documenting of discoveries, which leads to the collection of relevant data for assessment, which aids in the formulation of a plan of action.

However, many healthcare professionals believe that the paperwork is too brief, has too many abbreviations and acronyms, and is sometimes difficult to interpret for nonprofessionals.

The problem-oriented medical record (POMR) is a system for storing and retrieving patient's medical information. The problem-oriented record (POR) focuses on problems that need to be addressed rather than typical diagnoses. It stresses the importance of collecting thorough and accurate clinical data, with an emphasis on capturing abnormal findings rather than just gathering and enumerating lengthy lists of normal and abnormal data, such as narration, checklists, questionnaires, and analysis summaries. Instead, the POMR collects data from the patient's entire care team in order to make a diagnosis and develop a treatment plan.

The POMR usually contains the patient's medical history, a list of symptoms, test findings, a treatment plan for each condition, progress notes, and a discharge summary, which includes any necessary follow-up procedures.

POMRs are useful for tracking chronic illnesses that require a variety of treatment options and must be altered over time. This tool is also useful in circumstances where patients with complex medical conditions consult multiple doctors. When the medicines for numerous conditions interact, such documentation is very critical.

The SOAP note in the POMR contains not only the patient's history, test results, and other relevant health information, but also the physician's observations, a list of issues prioritized in order of importance, and remarks on why the problems are grouped in a specific way. It is also broken down into three sections for diagnostic, therapeutic, and patient-education plans. POMR is becoming more common in hospitals and at home, where physicians may spend more time assessing and working with patients. It is less likely to be employed in an outpatient situation where individuals are only seen for a few minutes and the turnaround is quick.

JAYPEE BROTHERS

Phase IV—Maintenance/Recall Phase

in this phase, the patient is recalled usually on 6 monthly bases, for a check-up, prophylaxis, evaluation of any treatment, medical or surgical.

Sharing understanding—at the conclusion of a consultation, it is usually a good idea to ask the patient if they have any questions. This might assist you transmit further information if they do not understand anything, and it can also disclose something that has been bothering them that has not been addressed or resolved. It is an opportunity to check that the doctor and the patient have established a mutual agreement.

CLASSIFICATION OF DISEASES

Classification of disease/lesions is a systematic method of arranging them into different groups and subgroups, based on their similarities and their differences. The most widely used classifications of disease are as follows:

- ❖ Topographic, by bodily region or system
- ❖ Anatomic, by organ or tissue
- ❖ Physiological, by function or effect
- ❖ Pathological, by the nature of the disease process
- ❖ Etiologic (causal)
- ❖ Juristic, by speed of advent of death
- ❖ Epidemiological
- ❖ Statistical

A single disease may fit under several of these categories. Any damage or aberrant change in an organism's tissue, usually caused by disease or trauma, is referred to as a lesion. Lesions are generally categorized according to their patterns, sizes, locations, or causes. The person who found the lesion is occasionally given a name.

A classification with coding would help the clinician to adherent the following:

- ❖ Logically reach a differential or working diagnosis.
- ❖ Facilitate an international/common language for the clinical communication.
- ❖ Enable proper diagnosis and prognostication for patient communication and education.
- ❖ Ensure implementation of appropriate treatment.
- ❖ Facilitate population surveys of disease prevalence.
- ❖ Enable research into the etiology, pathogenesis, natural history, and treatment strategies.

The correct management and treatment of patients necessitates the accurate diagnosis of oral cavity abnormalities. The clinical differential diagnosis is a cognitive process that involves the use of reasoning and knowledge in a succession of step-by-step judgments to generate a list of possible diagnoses.

The initial differential diagnosis and the basis for ordering tests and procedures to narrow the diagnosis should be approached on the basis of exclusion. Lesions that cannot be excluded are the initial differential diagnosis and are the basis for ordering tests and procedures to narrow the diagnosis. It might be dangerous for a patient to guess what the appropriate diagnosis for an oral lesion is since serious problems can be neglected.

Different diseases have a wide range of symptoms. The underlying disease process may manifest itself as a lesion on a single site in the oral cavity, or it may manifest itself as a lesion on multiple sites with equal or variable predilection. In terms of size, color, or surface characteristics, the lesion itself may have multiple aberrant features. Similar oral lesions may be covered in more detail elsewhere in this textbook depending on the frequency with which they affect a particular region or their most significant pathologic characteristic. The entities, on the other hand, must be considered in the differential diagnosis of more than one category of lesions, and each chapter has a full classification. In this chapter, the author discusses three major classifications that are significant to oral medicine.

1. Classification of oral mucosal lesions
2. Classification of bony lesions of the jaws
3. Classification of orofacial pain

Classification of Oral Mucosal Lesions

The most accepted and read classification is Decision Tree for Oral Mucosa Lesions; A Guide to Clinical Differential Diagnosis of Oral Mucosal Lesions **(Flowchart 3)**, which has been modified with explanation; *refer* **Poster Table** on inside the back cover.

Classification of Bony Lesions of the Jaws

The World Health Organization (WHO) classification of odontogenic and maxillofacial bone tumors, last published in 2017, is a subset of the WHO classification of head and neck tumors (4th edition), which lays out a histological classification system for neoplasms and other tumors related to the odontogenic apparatus which has been modified by this author to include inflammatory lesions of the jaws, and removed the modified point 3 given as odontogenic cysts to "cyst" as odontogenic and nonodontogenic cysts are subclassified under it:

- ❖ *Classification*:
  1. Malignant odontogenic tumors
     - i. Odontogenic carcinomas
       - ❍ Ameloblastic carcinoma
       - ❍ Primary intraosseous carcinoma, not otherwise specified
       - ❍ Sclerosing odontogenic carcinoma
       - ❍ Clear cell odontogenic carcinoma
       - ❍ Ghost cell odontogenic carcinoma
     - ii. Odontogenic carcinosarcoma
     - iii. Odontogenic sarcomas
  2. Benign odontogenic tumors
     - i. Benign epithelial odontogenic tumors
       - ❍ Ameloblastoma
         - Ameloblastoma—unicystic type
         - Ameloblastoma—extraosseous/peripheral type
         - Metastasizing ameloblastoma
       - ❍ Squamous odontogenic tumor
       - ❍ Calcifying epithelial odontogenic tumor
       - ❍ Adenomatoid odontogenic tumor
     - ii. Benign mixed epithelial and mesenchymal odontogenic tumors
       - ❍ Ameloblastic fibroma
       - ❍ Primordial odontogenic tumor
       - ❍ Odontoma
       - ❍ Dentinogenic ghost cell tumor
     - iii. Benign mesenchymal odontogenic tumors
       - ❍ Odontogenic fibroma
       - ❍ Odontogenic myxoma/myxofibroma
       - ❍ Cementoblastoma
       - ❍ Cemento-ossifying fibroma

JAYPEE BROTHERS

Flowchart 3: Decision tree for oral mucosal lesions.

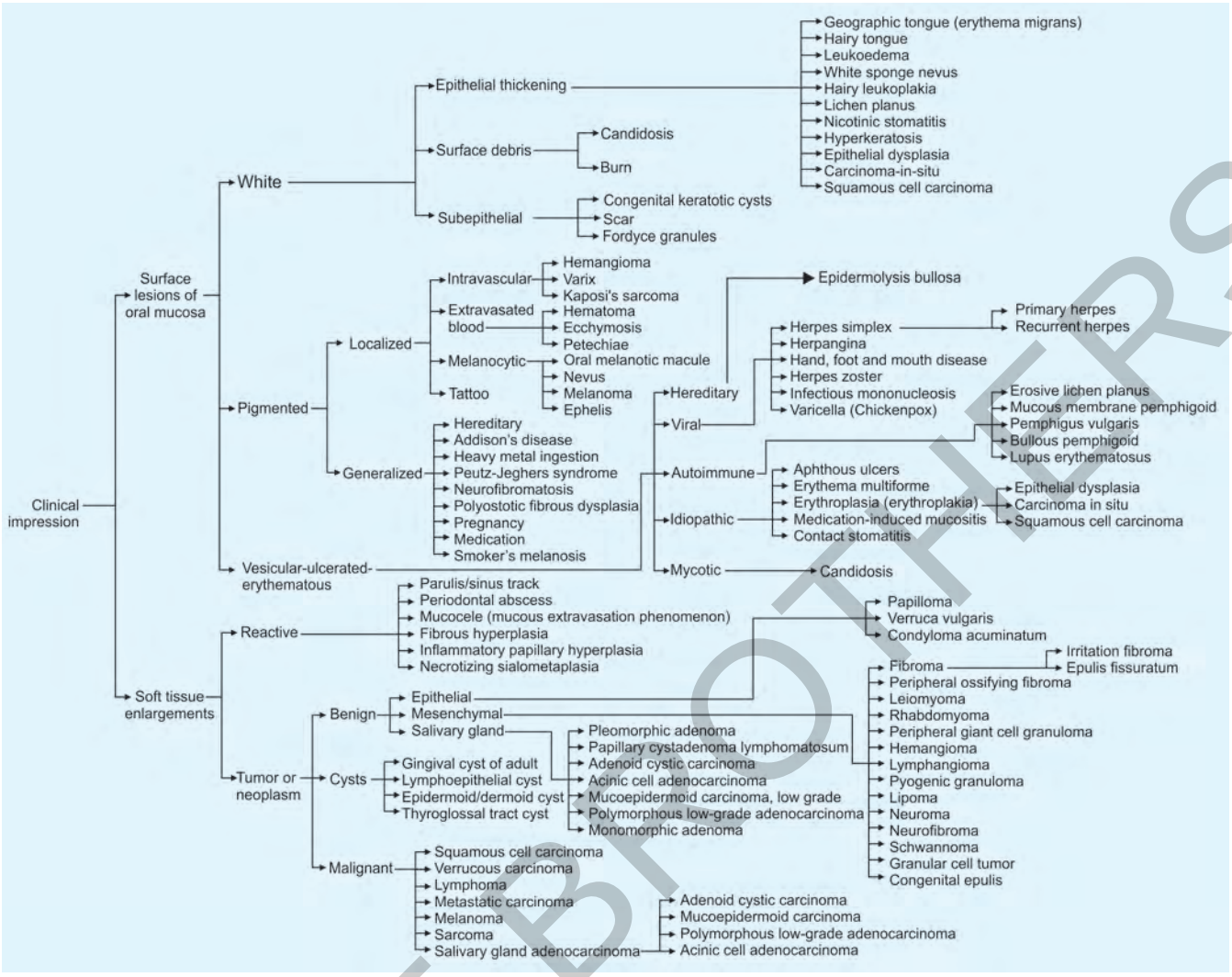

3. Cysts
   - i. Odontogenic cysts of inflammatory origin
     - ❍ Radicular cyst
     - ❍ Inflammatory collateral cysts
   - ii. Odontogenic and nonodontogenic developmental cysts
     - ❍ Dentigerous cyst
     - ❍ Odontogenic keratocyst
     - ❍ Lateral periodontal and botryoid odontogenic cysts
     - ❍ Gingival cysts
     - ❍ Glandular odontogenic cyst
     - ❍ Calcifying odontogenic cyst
     - ❍ Orthokeratinized odontogenic cyst
     - ❍ Nasopalatine duct cyst
4. Malignant maxillofacial bone and cartilage tumors
   - i. Chondrosarcoma
   - ii. Mesenchymal chondrosarcoma
   - iii. Osteosarcoma
5. Benign maxillofacial bone and cartilage tumors
   - i. Chondroma
   - ii. Osteoma
   - iii. Melanotic neuroectodermal tumor of infancy
   - iv. Chondroblastoma
   - v. Chondromyxoid fibroma
   - vi. Osteoid osteoma
   - vii. Osteoblastoma
   - viii. Desmoplastic fibroma
6. Fibro-osseous and osteochondromatous lesions
   - i. Ossifying fibroma
   - ii. Familial gigantiform cementoma
   - iii. Fibrous dysplasia
   - iv. Cemento-osseous dysplasia
   - v. Osteochondroma
7. Giant cell lesions and simple bone cyst
   - i. Central giant cell granuloma
   - ii. Peripheral giant cell granuloma
   - iii. Cherubism
   - iv. Aneurysmal bone cyst
   - v. Simple bone cyst
8. Hematolymphoid tumors
   - i. Solitary plasmacytoma of bone
9. Inflammatory lesions of the jaws
   - i. Periapical inflammatory lesions
   - ii. Pericoronitis
   - iii. Osteomyelitis: *acute *chronic
   - iv. Osteoradionecrosis
   - v. Bisphosphonate-related osteonecrosis of the jaws (BRONJ)
   - vi. Medication-related osteonecrosis of the jaws (MRONJ)

JAYPEE BROTHERS

Pain categories are helpful in the assessment and diagnosis of pain patients, as well as in clinical decision-making when physicians are deciding on the best treatment approach. Pain is classified not only by duration, but also by anatomical area, cause, intensity, and pathophysiology. To accurately assess a patient's pain, different pain classifications must be combined. It is crucial to remember that these distinct classifications are one-dimensional, and in order to provide the best care, a thorough assessment and multimodal treatment strategy are required. This means that numerous pain classifications may need to be addressed at the same time. The new International Classification of Orofacial Pain (ICOP) is the first comprehensive classification that addresses orofacial pain alone. It is a detailed classification that covers pain in dentoalveolar and anatomically related tissues, muscle pain, temporomandibular joint pain, neuropathic pain affecting cranial nerves, pain resembling primary headaches, and idiopathic pain in the orofacial region, and is based on the International Classification of Headache Disorders. The author puts forth a comprehensive summary of the same with a modification.

Summarized Classification of Orofacial Pain

- ❖ Orofacial pain attributed to disorders of dentoalveolar and anatomically related structures (1)
  - Dental pain (1.1)
    - ♦ Pulpal pain (1.1.1)
    - ♦ Periodontal pain (1.1.2)
    - ♦ Gingival pain (1.1.3)
  - Oral mucosal, salivary gland and jaw bone pains (1.2)
    - ♦ Oral mucosal pain (1.2.1)
    - ♦ Salivary gland pain (1.2.2)
    - ♦ Jaw bone pain (1.2.3)
- ❖ Myofascial orofacial pain (2)
  - Primary myofascial orofacial pain (2.1)
    - ♦ Acute primary myofascial orofacial pain (2.1.1)
    - ♦ Chronic primary myofascial orofacial pain (2.1.2)
  - Secondary myofascial orofacial pain (2.2)
    - ♦ Myofascial orofacial pain attributed to tendonitis (2.2.1)
    - ♦ Myofascial orofacial pain attributed to myositis (2.2.2)
    - ♦ Myofascial orofacial pain attributed to muscle spasm (2.2.3)
- ❖ Temporomandibular joint (TMJ) pain (3)
  - Primary temporomandibular joint pain (3.1)
    - ♦ Acute primary temporomandibular joint pain (3.1.1)
    - ♦ Chronic primary temporomandibular joint pain (3.1.2)
  - Secondary temporomandibular joint pain (3.2)
    - ♦ Temporomandibular joint pain attributed to arthritis (3.2.1)
    - ♦ Temporomandibular joint pain attributed to disc displacement (3.2.2)
    - ♦ Temporomandibular joint pain attributed to degenerative joint disease (3.2.3)
    - ♦ Temporomandibular joint pain attributed to subluxation (3.2.4)
- ❖ Orofacial pain attributed to lesion or disease of the cranial nerves (4)
  - Pain attributed to lesion or disease of the trigeminal nerve (4.1)
  - Pain attributed to lesion or disease of the glossopharyngeal nerve (4.2)
- ❖ Orofacial pains resembling presentations of primary headaches (5)
  - Orofacial migraine (5.1)
  - Tension-type orofacial pain (5.2)
  - Trigeminal autonomic orofacial pain (5.3)
  - Neurovascular orofacial pain (5.4)
- ❖ Idiopathic orofacial pain (6)
  - Burning mouth syndrome (BMS) (6.1)
  - Persistent idiopathic facial pain (PIFP) (6.2)
  - Persistent idiopathic dentoalveolar pain (6.3)
  - Constant unilateral facial pain with additional attacks (CUFPA) (6.4)
- ❖ Psychosocial assessment of patients with orofacial pain (7)
- ❖ Referred pain*

*(*added by the author as this pain is often felt in the lower jaw indicative of cardiac failure)*

SUGGESTED READING

1. American Academy of Periodontology. (2015). More than a quarter of U.S. adults are dishonest with dentists about how often they floss their teeth. [online] Available from https://www.oralhealthgroup.com/oral-health/american-academy-of-periodontology-more-than-a-quarter-of-us-adults-are-dishonest-with-dentists-1003703355/#:~:text=As%20part%20of%20its%20national,often%20they%20floss%20their%20teeth.
2. Axell T, Pindborg JJ, Smith CJ, Waal van der I. Oral white lesions with special reference to precancerous and tobacco-related lesions: conclusions of an international symposium held in Uppsala, Sweden, May 18-21 1994. International Collaborative Group on Oral White Lesions. J Oral Pathol Med. 1986; 25(2):49-54.
3. BC Cancer Agency Government agency. (2008). Lesion-tracking sheet. [online] Available from www.orcanet.ca/clinical (click Clinical Services, then Downloadable Forms).
4. British Columbia Oral Cancer Prevention Program, BC Cancer Agency, College of Dental Surgeons of British Columbia. Guideline for the early detection of oral cancer in British Columbia 2008. 2008;74(3):245.
5. Carpenter WM, Jacobsen PL, Eversole LR. Two approaches to the diagnosis of lesions of the oral mucosa. J Calif Dent Assoc. 1999;27(8):619-24.
6. Desai VD, Phore S, Vardhamanaiha SM. Nonsyndromic congenital lip pits: A rare entity. Arch Med Health Sci. 2015;3(2):279-81.
7. Field A, Longman L, Tyldesley WA. Tyldesley's Oral Medicine, 5th edition. Oxford: Oxford University Press; 2003.
8. Gandhi JS. William Osler: A Life in Medicine. BMJ. 2000;321(7268):1087.
9. Greenwood M. Essentials of Medical History-Taking in Dental Patients. Dent Update. 2015;42(4): 308-10, 313-5.
10. Hadden AM. In: Ormond C, Eaton K, Holt V, Ladwa R (Eds). Clinical Examination & Record Keeping-Good Practice Guidelines, 3rd edition. United Kingdom: Faculty of General Dental Practice; 2016.
11. https://fcm.unm.edu/education/images/docs/template_clin_soap_note.pdf.
12. Humphris GM, Morrison T, Lindsay SJ. The Modified Dental Anxiety Scale: validation and United Kingdom norms. Community Dent Health. 1995;12(3):143-50.

JAYPEE BROTHERS

13. International Collaborative Group on Oral White Lesions. J Oral Pathol Med. 1996; 25(2):49-54.
14. Kurtz SM, Silverman JD. The Calgary-Cambridge Referenced Observation Guides: an aid to defining the curriculum and organizing the teaching in communication training programmes. Med Educ. 1996;30(2):83-9.
15. Lane PM, Gilhuly T, Whitehead PD, Zeng H, Poh CF, Ng S, et al. Simple device for the direct visualization of oral-cavity tissue fluorescence. J Biomed Opt. 2006;11(2):024006.
16. Laronde DM, Hislop TG, Elwood JM, Rosin MP. Oral cancer: just the facts. J Can Dent Assoc. 2008;74(3):269-72.
17. Nanci A. Ten Cate's Oral Histology: Development, Structure, and Function, 6th edition. United States: Mosby; 2003.
18. National Centre for Smoking Cessation and Training. (2018). Very Brief Advice for Smoking Cessation for Dental Patients. [online] Available from https://www.ncsct.co.uk/publication_dental_vba.php [Last accessed August, 2022].
19. Neville BW, Damm DD, Allen CM, Bouquot JE. Allergic mucosal reactions to systemic drug administration. Oral and maxillofacial pathology, 3rd edition. Philadelphia: Saunders Company Ltd; 2002. pp. 300-2.
20. Neville BW, Damm DD, White DK. Color Atlas of Clinical Oral Pathology, 2nd edition. Philadelphia: Lippincott Williams and Wilkins; 1999.
21. Pigg M, Nixdorf DR, Law AS, Renton T, Sharav Y, Baad-Hansen L, et al. New International Classification of Orofacial Pain: What is in it for Endodontists? J Endod. 2021;47(3):345-57.
22. Poh CF, Ng SP, Williams PM, Zhang L, Laronde DM, Lane P, et al. Direct fluorescence visualization of clinically occult high-risk oral premalignant disease using a simple hand-held device. Head Neck. 2007;29(1):71-6.
23. Poh CF, Ng SP, Williams PM, Zhang L, Rosin MP. Heads up! A call for dentists to screen for oral cancer. J Can Dent Assoc 2006;72(5):413-6.
24. Poh CF, Zhang L, Anderson DW, Durham JS, Williams PM, Priddy RW, and others. Fluorescence visualization detection of field alterations in tumor margins of oral cancer patients. Clin Cancer Res 2006;15(22):6716-22.
25. Regezi JA, Sciubba JJ, Jordon RCK. Oral Pathology: Clinical Pathologic Correlations, 4th edition. Philadelphia: Saunders Co.; 2003.
26. Roestamadji RI, Nastiti NI, Surboyo MDC, Irmawati A. The Risk of Night Shift Workers to the Glucose Blood Levels, Saliva, and Dental Caries. Eur J Dent. 2019;13(3):323-9.
27. Rosin MP, Poh CF, Elwood JM, Williams PM, Gallagher R, MacAulay C, et al. New hope for an oral cancer solution: together we can make a difference. J Can Dent Assoc. 2008;74(3):261-6.
28. Sapp JP, Eversole LR, Wysocki GW. Contemporary Oral and Maxillofacial Pathology, 2nd edition. St. Louis: Mosby; 2003.
29. Scully C, Felix DH. Oral Medicine–Update for the dental practitioner. Oral white patches. Br Dent J. 2005;199(9):565-72.
30. United States Department of Veterans Affair. (2017). Alcohol Use Disorders Identification Test. Available from https://www.hepatitis.va.gov/alcohol/treatment/audit-c.asp#:~:text=The%20AUDIT%2DC%20is%20scored,his%2Fher%20health%20and%20safety [Last accessed August, 2022].
31. Walsh T, Liu JL, Brocklehurst P, Glenny AM, Lingen M, Kerr AR, et al. Clinical assessment to screen for the detection of oral cavity cancer and potentially malignant disorders in apparently healthy adults. Cochrane Database Syst Rev. 2013;11:CD010173.
32. Zhang L, Williams M, Poh CF, Laronde D, Epstein JB, Durham S, et aL. Toluidine blue staining identifies high-risk primary oral premalignant lesions with poor outcome. Cancer Res. 2005;65(17):8017-21.

JAYPEE BROTHERS

for detailed information on dental books, visit our website www.jaypeebrothers.com, for detailed information on dental books, visit our website www.jaypeebrothers.c

Essentials of Oral Medicine

Salient Features

- *Essentials of Oral Medicine* by Dr Freny Rashmiraj Karjodkar is a clinically comprehensive, well-illustrated and concise textbook covering all aspects of diagnostics, investigations, and therapeutics in Oral Medicine, making it a ready-reckoner resource and reference for undergraduate and postgraduate students as well as the practicing dentist and physician. The author has incorporated many recent topics which till date have not been included in any textbook on Oral Medicine.
- The chapters on maxillofacial anatomy, embryology and investigations makes for holistic medical information, and are a steppingstone to understanding the pathology of this region. In today's world of emerging technology, medical treatment is not limited to prescribing drugs, but is inclusive of applications of alternative therapy and chairside use of various therapeutic instruments, whose selections and applications have been discussed. Record maintenance and case history taking are an integral component of oral medicine practice, which has been explicitly deliberated.
- Diagnosis of oral mucosal lesions is not only a science but also an art, which gets perfected with experience. For the students and learning clinicians, the oral lesions have been compiled in separate chapters, under newer headings and classifications, along with different treatment modalities. Dental management of patients with complex medical disorders have also been showcased in this book.
- Oral Medicine is an ever-expanding field, opening new vistas of medical pathologies and treatment, keeping in mind the future, chapters on oral cancer along with tobacco cessation information, orofacial pain, breath analysis, forensic stomatology and clinical research have been embraced, so that the reader has all-encompassing information at their fingertips.
- Chapters on diseases of the teeth, lesions of jaw bones and temporomandibular disorders, where radiology plays an important diagnostic role have been conferred to give robust knowledge. An entire chapter has been devoted to case reports for the reader to experience step-by-step procedure for case recording, differential diagnosis, and treatment planning.
- The text and clinical photographs are assimilated with the help and support of some of the finest Oral and Maxillofacial Physicians of our country.
- Summarizing the above, this is a one-stop resource book for Oral Medicine, intended to augment the knowledge, skills, and attitudes of potential oral physicians.

Freny Rashmiraj Karjodkar BDS MDS in Oral Medicine and Radiology, has been undergraduate, postgraduate and PhD teacher in the subject for the last 40 years and is one of the senior most oral and maxillofacial physicians in Maharashtra, India. Her greatest achievement is that she has gained vast clinical expertise working and teaching in Nair Hospital Dental College, which exposed her to a variety of clinical data of oral mucosal lesions, orofacial pain, temporomandibular disorders, etc. Her hands-on experience in diagnosing and applying different modalities of treatment for the oral maladies, opened vistas of avenues for research. She has more than 250 publications in national and international journals, authored three books on maxillofacial radiology and contributed to various dental textbooks. As HOD, she introduced various protocols for clinical and chairside diagnosis of potentially malignant lesions and oral cancer, treatment of soft tissue lesions with lasers, treatment of TMD and orofacial pain with medication, TENS, and therapeutic ultrasound. She is the first President for the Maharashtra Branch-Indian Academy of Oral Medicine and Radiology (2023-2025). Presently, she practices in her private clinic and is a visiting and on-line oral-medicine and radiology consultant.

Her motto is, "Don't just preach, reach out to teach and treat".

Printed in India

Available at all medical bookstores
or buy online at www.jaypeebrothers.com

JAYPEE BROTHERS
Medical Publishers (P) Ltd.
EMCA House, 23/23-B, Ansari Road,
Daryaganj, New Delhi - 110 002, INDIA
www.jaypeebrothers.com

Join us on facebook.com/JaypeeMedicalPublishers

Shelving Recommendation
DENTAL

ISBN 978-93-5696-173-9