on on cardiology books, visit our website www.jaypeebrothers.com, for detailed information on cardiology books, visit our website www.jaypeebrothers.com

Cardiac Catheterization and Imaging

(From Pediatrics to Geriatrics)



IB Vijayalakshmi

2nd Edition

Foreword
Charles E Mullins

JAYPEE

Contents

SECTION 1: HISTORY AND BASICS OF CATHETERIZATION

1. **History of Transcatheter Interventions in Pediatric Cardiology** 3
   P Syamasundar Rao

2. **History of Transcatheter Interventions in Adult Cardiology** 21
   IB Vijayalakshmi, Chitra Narasimhan

3. **Radiation Safety and Contrast Agents** 32
   Nagamani AC

4. **Preparation for Cardiac Catheterization** 48
   Maria C Yates, Duraisamy Balaguru

5. **Percutaneous Vascular Access for Cardiac Catheterization** 55
   Tharakanatha R Yarrabolu, Prakash Balan, Duraisamy Balaguru

6. **Hardware in Catheterization Laboratory** 70
   Shishu Shankar Mishra, Satyavir Yadav, Biswaranjan Mishra, Satyanarayan Routray, Amar Narayan Patnaik, Sundip Mishra

SECTION 2: HEMODYNAMICS

7. **Right and Left Heart Catheterization** 91
   Ravi S Math

8. **Cardiac Output and Vascular Resistance** 106
   Reeta Varyani, Prayaag Kini, Srikanth Sola

9. **Shunt Calculations** 121
   Duraisamy Balaguru

10. **Hemodynamic Pressure Traces Recordings** 132
    Kothandam Sivakumar

SECTION 3: INTERVENTIONAL TECHNIQUES FOR VALVULAR HEART DISEASES

11. Balloon Valvuloplasty for Pulmonary Stenosis 147
P Syamasundar Rao

12. Balloon Valvuloplasty for Aortic Stenosis 173
IB Vijayalakshmi, Chitra Narasimhan

13. Percutaneous Balloon Valvuloplasty for Mitral Stenosis 194
Harikrishnan S, Sanjay G, Krishna Kumar M

14. Percutaneous Balloon Valvuloplasty for Tricuspid Valve Stenosis 210
Ramesh Arora, Ankur Handa, Sivasubramanian Ramakrishnan

SECTION 4: INTERVENTIONAL TECHNIQUES FOR SHUNT LESIONS

15. Transcatheter Closure of Atrial Septal Defects 219
Hussam Suradi, Nidhi Madan, Ziyad M Hijazi

16. Transcatheter Closure of Patent Foramen Ovale 250
Hussam Suradi, Nidhi Madan, Ziyad M Hijazi

17. Device Closure of Ventricular Septal Defect 265
Eiméar McGovern, Kevin P Walsh, IB Vijayalakshmi, Barry O'Callaghan

18. Interventions in Patent Ductus Arteriosus 291
IB Vijayalakshmi, Amitabha Chattopadhyay

19. Device Closure of Coronary Cameral Fistula 329
Gareth J Morgan, Shakeel Ahmed Qureshi

20. Closure of Unusual Defects: Tunnels and Leaks 336
Kothandam Sivakumar, IB Vijayalakshmi

21. Patent Ductus Arteriosus Stenting in Cyanotic Congenital Heart Disease with Duct-dependent Pulmonary Circulation 361
Ming Chern Leong, Mazeni Alwi

SECTION 5: INTERVENTIONAL TECHNIQUES FOR FETUS AND NEONATES

22. Intrauterine Cardiac Interventions 379
Carlos AC Pedra, Shweta Bakhru

23. Neonatal Catheter Interventions 387
P Syamasundar Rao

SECTION 6: INTERVENTIONS IN VESSELS

24. Percutaneous Management of Aortic Coarctation 431
P Syamasundar Rao

25. Catheter Interventions for Pulmonary Artery Stenosis 466
R Suresh Kumar, Saileela Rajan

26. Peripheral Vascular Intervention 474
Monica Kher, BC Srinivas

27. Interventions in Superior and Inferior Vena Cava 490
Amitabha Chattopadhyay, Indira Banerjee

28. Endovascular Management of Inferior Vena Cava and Central Venous Obstruction 497
BC Srinivas, Vijaykumar JR, CM Nagesh, Babu Reddy, Dattatreya PV, CN Manjunath

29. Carotid Artery Interventions 513
Atul Mathur, Amit Kumar

30. Interventions for Renal Artery Stenosis 525
J Cecily Mary Majella, Girish B Ramteke

31. Challenges of Interventions in Takayasu's Arteritis 538
J Ezhilan, J Cecily Mary Majella

32. Interventions in Deep Vein Thrombosis and Pulmonary Thromboembolism 544
Muralikrishna Nekkanti, Sravan CPS

33. Transcatheter Management of Congenital and Acquired Pulmonary Vein Stenosis in Children and Adults 560
Sujata S Alawani, Navaneetha Sasikumar

34. Stents in the Management of Vascular Obstructive Lesions Associated with Congenital Heart Disease 570
P Syamasundar Rao

SECTION 7: CORONARY INTERVENTIONS

35. Coronary Angiography 599
Geetha Subramanian, Srinivasan Narayanan, J Ezhilan, Gnanavelu Ganesan, J Cecily Mary Majella

36. Basics of Percutaneous Coronary Intervention 611
Rajiv Bajaj

37. Transcatheter Treatment of Non-ST-elevation and ST-elevation Myocardial Infarction 624
Surpreet Chopra, Dev B Pahlajani, Akshay Mehta

38. Bifurcation Stenting **647**
Raghav Bansal, Hemant Bareth, Sheeshkaran Singh Charan, Sundeep Mishra

39. Primary Coronary Angioplasty in Acute Myocardial Infarction **666**
Vineet Bhatia, Upendra Kaul

40. Percutaneous Coronary Intervention in Chronic Total Occlusion **678**
Suryaprakasa Rao Vithala, Ashwin B Mehta, Vivek Mandurke, Nihar P Mehta

41. Left Main Coronary Artery Interventions **694**
Kunal Kumar Singh, Aditya Kapoor

42. Intervention in Calcific Coronary Artery: Cracking the Hard Nut **705**
Hetan C Shah, Tamagna Ghosh

43. Percutaneous Coronary Intervention for Saphenous Vein Grafts **715**
Geetha Subramanian, Gnanavelu Ganesan, Venkatesan Sangareddi, J Cecily Mary Majella

44. Interventions in Cardiogenic Shock **722**
Hetan C Shah, Amit Singh

SECTION 8: IMAGING

45. Computed Tomography Angiogram and Magnetic Resonance Imaging in Cardiovascular Practice **737**
Madhav Hegde, Mary Varunya Jehendran

46. Role of Nuclear Medicine in Coronary Artery Disease **770**
KG Kallur

47. Advanced Coronary Artery Imaging Modalities **778**
Shikhar Agarwal, Ravi Nair

48. Echocardiography for Interventions in Structural Heart Disease **799**
Joseph J Vettukattil, Abhinav Sood, Harikrishnan KN, Sruti Rao

SECTION 9: RECENT TECHNIQUES IN VALVULAR AND AORTIC DISEASES

49. Transcatheter Aortic Valve Implantation **815**
Praveen Chandra, Saakshi Sarin

50. Percutaneous Treatment of Mitral Regurgitation **830**
Ganesh Athappan, Tilak Pasala, Samir R Kapadia, J Cecily Mary Majella

51. Left Atrial Appendage Closure **847**
Asha Moorthy, Jain T Kallarakkal

52. Percutaneous Pulmonary Valve Implantation **855**
Hussam Suradi, Nidhi Madan, Laith A Derbas, Ziyad M Hijazi

53. Transcatheter Closure of Paravalvar Leaks **867**
Kothandam Sivakumar

54. Endovascular Management of Aortic Aneurysm and Dissection **875**
Rajendra Kumar Jain, Tammi Raju, Anil Dhall

SECTION 10: INTERVENTIONS IN GROWN-UP CONGENITAL HEART DISEASE

55. Current Indications for Cardiac Catheterization and Interventions in Adults with Congenital Heart Disease **899**
Reema Chugh, Morris Salem, Rishika Mehta, Amitabha Chattopadhya

56. Cardiac Catheterization and Interventions in Adults with Congenital Heart Disease **911**
Morris Salem, Reema Chugh, Jayitri Mazumdar, Amitabha Chattopadhyay

57. Postinterventional Follow-up in Adults with Congenital Heart Disease **936**
Reema Chugh, Debasree Gangopadhyay

SECTION 11: ELECTROPHYSIOLOGY

58. Vascular Access and Catheters in Electrophysiology **947**
Maneesh Rai K, Anurakti Dev Singla

59. Electrophysiology: Basic Protocols and Study **951**
Anindya Ghosh, Ulhas M Pandurangi, Anurakti Dev Singla

60. Interventions for Supraventricular Tachyarrhythmias **962**
Narayanan Namboodiri KK, Shunmuga Sundaram P, Abhilash SP

61. Catheter-based Interventions for Ventricular Tachyarrhythmias **974**
Jayaprakash Shenthar, Darshan Krishnappa

62. Conventional Permanent Pacemaker Implantation Techniques **986**
Abhilash SP, Narayanan Namboodiri KK

63. Implantation of Implantable Cardioverter-defibrillators **994**
Jayaprakash Shenthar, Darshan Krishnappa

64. Catheter Ablations of Cardiac Arrhythmias in Children **1003**
John Roshan

SECTION 12: MISCELLANEOUS

65. Alcohol Septal Ablation for Obstructive Hypertrophic Cardiomyopathy **1021**
B Ramesh

66. Anesthesia for Pediatric Cardiac Catheterization and Intervention **1032**
Keshava Murthy Shankariah, Muralidhar Kanchi

67. Intra-aortic Balloon Pump **1038**
Muralidhar Kanchi

68. Pediatric Endomyocardial Biopsy **1046**
Toby Rockefeller, Ryan Romans

69. Left Ventricular Assist Devices in Heart Failure: Current Status **1054**
Bagirath Raghuraman, Blessvin Jino

70. Recanalization of Occluded Vessels (Including Thrombectomy) in Children and Adults with Congenital Heart Disease **1073**
Athar M Qureshi, J Cecily Mary Majella, Henri Justino

71. Contrast-induced Acute Kidney Injury **1079**
Geetha Subramanian, Gnanavelu Ganesan, Venkatesan Sangareddi, J Cecily Mary Majella

Index **1089**

CHAPTER

16

Transcatheter Closure of Patent Foramen Ovale

Hussam Suradi, Nidhi Madan, Ziyad M Hijazi

INTRODUCTION

Patent foramen ovale (PFO) represents a congenital abnormality that is highly prevalent in the general population. Observational studies have found associations between PFO and several clinical disease states including cryptogenic stroke,[1,2] migraine headache,[3] platypnea-orthodeoxia,[4] sleep apnea, and decompression illness.[5] In the past, surgery was the only means for PFO closure. With the advent of transcatheter therapies, percutaneous closure of PFO is now commonplace and has been shown to be a safe alternative to surgical closure.[6,7] The frequency of PFO closure has increased dramatically worldwide as implantation techniques have become more refined with high procedural success and low complication rates. This chapter reviews the technical details of percutaneous closure of PFO, including clinical indications, patient selection, as well as potential pitfalls and their solutions.

ANATOMICAL CONSIDERATIONS FOR THE INTERVENTIONALIST

A clear understanding of the atrial anatomy is very important to comprehend the principles of device closure of PFO. The atrial septum is formed from two overlapping structures; the left-sided partially fibrous septum primum, and the right-sided muscular septum secundum. The foramen ovale is an opening in the fossa ovalis created by the overlap of these two structures, with the septum primum serving as a one-way slit allowing right-to-left shunt during in utero development. During fetal development, resistance in the pulmonary circulation leads to higher pressure in the right atrium relative to the left, allowing oxygenated blood arriving from the umbilical vein to cross through this opening to the systemic circulation. Following birth, establishment of the pulmonary circulation leads to a relative increase in left atrial pressure resulting in pushing the septum primum against the septum secundum and functional closure of the foramen ovale. This is usually followed in the ensuing months by anatomical closure by means of fibrous adhesions resulting in permanent closure of the opening.[8] However, in 25–30% of the population,[9] adhesions fail to completely seal the septum resulting in persistent communication between the right and left atria. Prevalence of the PFO declines with age, suggesting that smaller PFOs may spontaneously close later in life.[9] The PFO is located caudally in the septum secundum and cranially in the septum primum forming a slit-valve that opens when the right atrial pressure overrides the left atrial pressure, carrying the risk of paradoxical embolism. Although the communication is a flap-type opening, its shape is dependent upon the length of overlap between the edges of the septum primum and secundum. The opening may increase in dimension and becomes lacunar type if the septum primum remains separated from the secundum. Furthermore, the degree of overlap between the two septa determines whether the PFO is simple or tunnel-like **(Fig. 1)**. In the tunnel type PFO, the direction of the tunnel is inferosuperiorly and the extent to which the septum primum overlaps the septum secundum determines the length of the tunnel. This ranges from 3 to 18 mm with mean of 8 mm.[9] Similarly, the distance of nonfusion between the septa determines its width which ranges from 1 to 19 mm with a mean of 4.9 mm.[10] Both, tunnel length and width increase with age.[11] Another important consideration when evaluating PFOs is the consistency of the septum primum. If it is thin and its excursion is >15 mm, it is termed aneurysmal PFO. The aneurysmal nature of the tunnel adds complexity as device closure of the PFO is more challenging.

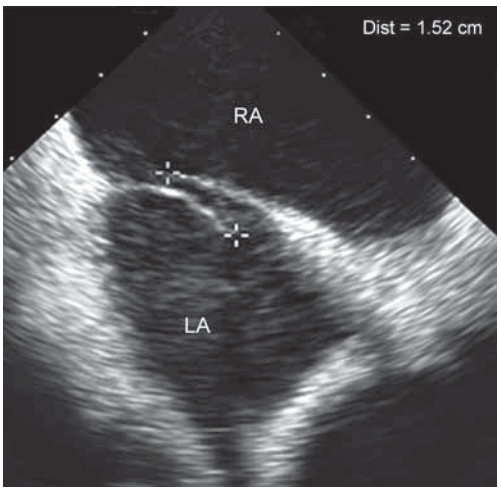

Fig. 1: Intracardiac echocardiography (ICE) long-axis view image showing significant overlap of septa forming a long tunnel with left to right shunting on color Doppler.
(LA: left atrium; RA: right atrium)

Variations in the atrial septal morphology of the PFO are frequent and have important technical implications on the success of the transcatheter PFO closure. Anatomic features of the interatrial septum, the morphology and size of the PFO opening, and the degree of mobility of the septum primum are all variables and require careful evaluation by the operator in order to minimize the rate of complications of percutaneous closure of PFO. PFO anatomy is considered complex in the presence of any of the features listed in **Box 1**. These unique characteristics and others can be evaluated by different imaging modalities including transthoracic echocardiography (TTE), transesophageal echocardiography (TEE), intracardiac echocardiography (ICE), computed tomography (CT), and cardiac magnetic resonance imaging (cMRI).

Structures adjacent to the atrial septum are of important considerations as well to understand the issues of device placement **(Fig. 2)**.[12] The superior vena cava (SVC) is located posterosuperiorly and the inferior vena cava (IVC) is located posteroinferiorly. The tricuspid valve lies anteriorly. The anterosuperior border is related to the aortic root, as the aortic valve and root lie centrally in the heart, wedged between the two atria, and resting on the atrial septum.

BOX 1 Anatomical characteristics of complex PFO.

- Long tunnel (≥8 mm)
- Multiple fenestrations in the atrial septum
- Atrial septal aneurysm
- Additional defects (ASDs)
- Thick septum secundum (≥10 mm)
- Prominent Eustachian valve or Chiari network
- Distorted anatomy due to aortic root enlargement

(ASDs: atrial septal defects; PFO: patent foramen ovale)

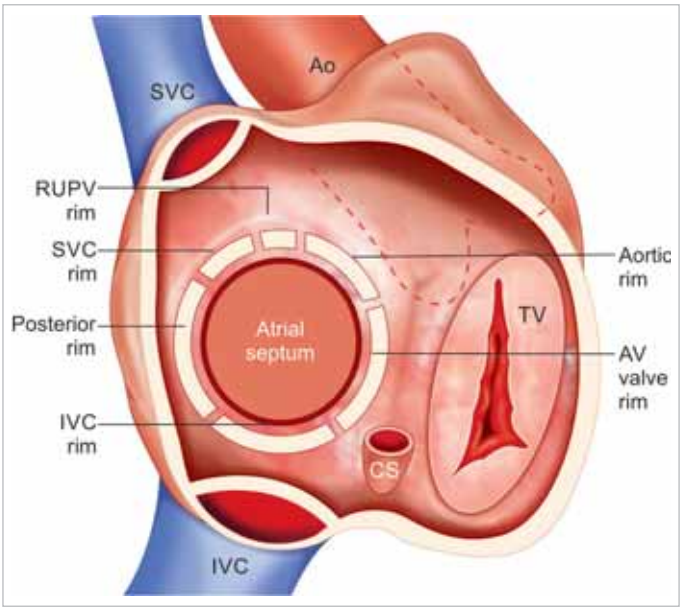

Fig. 2: Atrial septum as seen from the right atrium with rims depicted.
(Ao: aorta; AV: aortic valve; CS: coronary sinus; IVC: inferior vena cava; RUPV: right upper pulmonary vein; SVC: superior vena cava; TV; tricuspid valve)

DIAGNOSIS OF PATENT FORAMEN OVALE

Several echocardiographic techniques can be utilized to diagnose a PFO, including TTE, TEE, and transcranial Doppler (TCD) ultrasound. During the diagnostic workup in patients with cryptogenic stroke and presumed paradoxical embolism, there are three possible stages to the echocardiographic assessment: (1) Standard TTE, (2) transthoracic contrast echocardiogram, and (3) TEE. TEE is the most commonly used modality for PFO diagnosis due to its superior image resolution and ability to differentiate the location of shunting. TEE also identifies morphometrical features of PFO that are of more likely to be associated with stroke. Recent meta-analysis showed that greater PFO height during a Valsalva, large right-to-left shunt, septal excursion distance and atrial septal aneurysm (ASA) are associated with stroke related PFOs.[13] Distinguishing a pulmonary-level shunt from a cardiac-level shunt is important. Contrast from a cardiac shunt usually appears within three cardiac cycles. If TTE bubble contrast is positive for right-left shunt, TEE is necessary to confirm its presence and define the anatomy of the PFO. TCD is a technique that uses Doppler ultrasound to quantify the number of bubbles that reach the cerebral circulation. It is a good screening tool given its high sensitivity for the detection of right-to-left shunting but it is less specific than transesophageal contrast echocardiography as it does not provide anatomic information.[14,15] CT and MRI are likely as specific as TEE for PFO diagnosis; however, they are less sensitive due to the fact that these imaging techniques are dependent on imaging plane and timing because PFO flow is transient in nature. Finally, a recent trial showed that ICE-guided PFO closures had similar procedural outcomes and length of hospital stay when compared with TEE-guided PFO closures.[16]

CLINICAL IMPLICATIONS

Cryptogenic Stroke

The most common indication for PFO closure in practice today is for prevention of recurrent stroke or transient ischemic attack (TIA) in patients with a first or second neurologic event. Paradoxical embolism is proposed as a mechanism for cryptogenic stroke and occurs when a thrombus from the systemic venous circulation passes to the systemic arterial circulation via a right-to-left shunt, usually a PFO. A stroke is considered "cryptogenic" when no etiology is detected. This is the case in up to 40% of strokes in young adults. PFO is more prevalent in stroke patients who are under 55 years of age as compared to older patients.

Up to date, six clinical trials (CLOSURE I, RESPECT, PC, CLOSE, REDUCE, and DEFENCE-PFO) consisting about 3,500 patients have been completed to determine the effect of PFO closure for the prevention of cryptogenic stroke and/or TIA. The CLOSURE I trial (Evaluation of the STARFlex Septal Closure System in Patients With a Stroke or TIA Due to the Possible Passage of a Clot of Unknown Origin Through a Patent Foramen Ovale) was the first randomized clinical trial evaluating the effects of PFO closure on recurrent cryptogenic stroke and TIA versus medical therapy. 909 patients with history of cryptogenic

stroke were randomized to percutaneous PFO closure using STARFlex device versus medical therapy with warfarin, aspirin, or aspirin and warfarin.[17] The results did not demonstrate a benefit of PFO closure with the STARFlex device compared with medical therapy. The primary composite endpoint of a reduction in stroke, TIA, and mortality at 2 years was reached in 5.9% of patients in the device arm and 7.7% of patients in the medical treatment arm ($p < 0.30$). The CLOSURE I trial has been extensively criticized due to several reasons. Concern has been raised regarding the predilection for thrombus formation (approximately 10%); the high residual shunt associated with the CardioSEAL-STARFlex device compared to other devices (closure rate was 86.5% in this trial) and high incidences of frame wire fractures which points toward inadequate mechanical closure. In addition, the inclusion of patients with TIA may have confused the issue of stroke because TIA could not be clinically distinguished from a complex migraine with transient neurologic dysfunction. Furthermore, the risk of atrial fibrillation with the STARFlex device was higher compared to the other devices. In the CLOSURE I trial, postimplantation atrial fibrillation was found in 5.7% of patients, in contrary to the rate with the Amplatzer device (2.9%) or the HELEX device (1.8%).[18]

In both RESPECT (Randomized Evaluation of Recurrent Stroke Comparing PFO Closure to Established Current Standard of Care Treatment)[19] and PC trials,[20] the patients were randomly assigned to medical therapy or to closure of the PFO with the use of the Amplatzer PFO occluder for secondary prevention of stroke. The PC trial investigators randomly assigned 414 patients to closure or to medical therapy and followed them for an average of approximately 4 years. PC included not only clinical TIA with positive diffusion weighted MRI, but also patients with peripheral embolism. A total of seven patients in the closure group (3.4%) and 11 in the medical therapy group (5.2%) died or had a TIA, nonfatal stroke, or peripheral embolism [hazard ratio (HR) with closure: 0.63; 95% confidence interval (CI)[21] 0.24–1.62; $p = 0.34$]. Nonfatal stroke occurred in one patient (0.5%) in the closure group and five patients (2.4%) in the medical therapy group (HR 0.20; 95% CI 0.02–1.72; $p = 0.14$).

The RESPECT trial had more strict inclusion criteria and randomized only patients with cryptogenic stroke. Total of 980 patients underwent randomization. Initial results published in 2013 were similar to those of the CLOSURE I and PC trials and showed nonsignificant reduction in primary endpoint at median follow-up 2.1 years. In the intention-to-treat analysis, nine patients in the closure group and 16 in the medical therapy group had a recurrence of stroke (HR 0.49; 95% CI 0.22–1.11; $p = 0.08$).[19] However, the long-term results of the RESPECT trial published in 2017 showed that PFO closure was associated with a lower rate of recurrent ischemic strokes than medical therapy alone during median follow-up of 5.9 years (HR 0.55; 95% CI 0.31–0.99; $p = 0.046$).[22]

The CLOSE (Patent Foramen Ovale Closure or Anticoagulants versus Antiplatelet Therapy to Prevent Stroke Recurrence) trial[23] assigned 663 patients (16–60 years of age who had had a recent stroke attributed to PFO, with an associated ASA or large interatrial shunt) in a 1:1:1 ratio to transcatheter PFO closure plus long-term antiplatelet therapy (PFO closure group with any approved closure device), antiplatelet therapy alone (antiplatelet-only group), or oral anticoagulation (anticoagulation group). Mean follow-up was 5.3 years. The rate of stroke recurrence was lower among those assigned to PFO closure combined with antiplatelet therapy than among those receiving antiplatelet therapy alone (HR 0.03; 95% CI 0–0.26; $p < 0.001$). However, an increased risk of atrial fibrillation was noted with PFO closure.

Gore REDUCE trial[24] included patients 664 patients with cryptogenic stroke, randomized in a 2:1 ratio, to undergo PFO closure plus antiplatelet therapy (PFO closure group with HELEX or GSO device) or to receive antiplatelet therapy alone. Only PFO presence was necessary for inclusion and ASA was not screened before randomization. Brain imaging was performed at baseline and at 24 months. The endpoints included freedom from clinical evidence of ischemic stroke through at least 24 months after randomization and the 24-month incidence of new brain infarction, which was a composite of clinical ischemic stroke or silent brain infarction detected on imaging. Median follow-up duration was 3.2 years. In these patients with a PFO and prior cryptogenic stroke, the risk of subsequent ischemic stroke was lower among those assigned to PFO closure combined with antiplatelet therapy than among those receiving antiplatelet therapy alone (1.4% vs. 5.4%; HR 0.23; 95% CI 0.09–0.62; $p = 0.002$); however, PFO closure was associated with higher rates of device complications and atrial fibrillation. The 5-year outcomes of Gore REDUCE trial were published very recently and show continued benefit of PFO closure in these patients in reducing stroke compared to antiplatelet therapy alone while no new device or procedure-related serious adverse events.[25]

The DEFENSE-PFO (Device Closure Versus Medical Therapy for Cryptogenic Stroke Patients With High-Risk Patent Foramen Ovale) trial[26] was aimed at investigating whether the benefits of PFO closure can be determined on the basis of the morphologic characteristics of the PFO, as assessed by TEE to guide appropriate patient selection. PFO was considered high risk if it was associated with ASA, hypermobility (phasic septal excursion into either atrium ≥10 mm), or PFO size (maximum separation of the septum primum from the secundum) ≥2 mm. After evaluating the morphological characteristics of the PFO, patients with cryptogenic stroke and high-risk PFO were divided between a transcatheter PFO closure and a medication-only group (consisting of antiplatelet and/or anticoagulation). There were 60 patients in each arm with median follow-up of 2.8 years. The primary endpoint was a composite of stroke, vascular death, or thrombolysis in myocardial infarction-defined major bleeding. PFO closure in patients with high-risk PFO characteristics resulted in a lower rate of the primary endpoint and stroke recurrence (2-year event rate 12.9%; 95% CI 3.2–22.6%).

In a pooled analysis of these six RCTs, PFO closure was associated with significant reduction in recurrent stroke compared with medical therapy alone.[27] This was consistent irrespective of the type of medical therapy, i.e., antiplatelet use only or antiplatelet and anticoagulant use. Large-sized PFO shunts appeared to derive more benefit from PFO closure

compared with small to moderate sized PFOs, however, the presence or absence of ASA did not appear to affect this association. PFO closure can be attained with high rate of success (>85% for all studies). However, there appeared to be an increased incidence of new onset atrial fibrillation postprocedure.

A recently published network meta-analysis comprising all the six abovementioned trials with a total of 3,560 patients also reiterated that device closure of PFO is better than medical therapy in cryptogenic stroke patients, albeit also with an increased risk of atrial fibrillation.[28]

Platypnea-orthodeoxia Syndrome

This is a rare disorder characterized by both dyspnea (platypnea) and arterial desaturation (orthodeoxia) in the upright position with improvement in the supine position.[29] In addition to PFO, this syndrome has also been described with intrapulmonary shunting and with disorders such as pericardial effusion, constrictive pericarditis, emphysema, amiodarone-induced pulmonary toxicity, pneumonectomy, and cirrhosis. Two components must coexist to create this syndrome, anatomical, and functional.[30] The anatomical component must consist of an interatrial or intrapulmonary shunt. The functional component is mediated by a deformity in the atrial septum that promotes abnormal shunting when the patient rises from a recumbent to an upright position. Typically, right atrial pressure is elevated causing right-to-left shunting; however, shunting may occur even when right atrial pressure is normal, as typically occurs with persistent Eustachian valves. Diagnosis should be by tilt table testing, measuring arterial saturation in different positions along with contrast echocardiography to show the intracardiac shunting. It is important to note that the majority of right-to-left shunting in this syndrome is derived from IVC blood flow, where injection from the antecubital vein with return via the SVC may show less prominent shunting. The definitive treatment for platypnea-orthodeoxia syndrome is closure of the shunt.[31] In a single-center series, 52 patients were treated with percutaneous closure showed acute improvements in oxygen saturation (preprocedure: 81 ± 8%; postprocedure: 95.1 ± 0.5% on room air).[32]

Decompression Sickness

Decompression sickness in scuba divers can result in air embolism through a PFO. It is caused by the presence of nitrogen bubbles that come out of solution in the blood as the ambient pressure decreases during ascent from a dive. The amount of nitrogen bubbles generated depends on the total time spent in the dive, the speed of ascent, compliance with decompression stops, and individual factors such as cardiac output. Generally, the nitrogen bubbles stay in the venous circulation and dissolve in the lungs. However, in the presence of PFO, the bubbles may enter the systemic circulation and travel toward the brain, occluding a small arterial branch. Cerebral or vestibular symptoms may occur such as limb tingling, loss of consciousness, severe headache with mental confusion, and audiovestibular symptoms.[33] The risk is further increased with larger PFOs and in patients who travel by air within 12–48 hours after diving. Currently, it is unclear whether PFO closure may be indicated in these patients, as avoidance of diving would prevent further episodes; decision to proceed should be based on best clinical judgment.

Migraine

The prevalence of PFO in migraine with aura ranges between 41 and 89%, whereas it is between 7 and 34% in migraineurs without aura and between 20 and 25% in nonmigraineur controls.[34] The basic hypothesis is that migraine may be triggered by chemicals that ordinarily are metabolized during passage through the lungs. This hypothesis evolved from observations that closure of a PFO for other reasons, such as decompression illness or cryptogenic stroke, resulted in relief of migraine headaches.

In addition to the close association of PFO and migraine with aura, there is also a higher risk of stroke in patients with a history of migraine. A meta-analysis of 14 studies revealed a twofold increased risk of ischemic stroke in migraine patients, compared with people without migraine.[35]

The MIST (Migraine Intervention with STARFlex Technology)[36] trial was one of the first to evaluate PFO closure for migraine. This trial enrolled 147 patients with a PFO who had frequent migraine with aura that was refractory to two types of preventive medication. Enrolled patients were randomly assigned under general anesthesia to either PFO closure or sham treatment. During a 3-month healing phase, patients in both treatment groups received aspirin plus clopidogrel. After 6 months, the primary endpoint of complete cessation of migraine headaches after device closure was not reached, because only three patients in each group reported no further migraine headaches. The MIST trial has been extensively criticized due to several factors. The patient population enrolled included those with chronic headaches, a subgroup that might not respond to conventional therapies. The follow-up period of 3–6 months was believed to be too short since percutaneous PFO closure devices might require more time to endothelialize and eliminate shunting through a PFO. Only contrast transthoracic echocardiograms were obtained at follow-up, which is less sensitive than TEE or TCD detection of right-to-left shunting. Furthermore, the true incidence of residual shunting was significantly controversial, damaging the credibility of the study. Although the MIST I trial reported a 5% residual shunt in the device arm at 6 months, one of the principal investigators alleges that 35% of device-treated patients had a large residual shunt. More recently, the Percutaneous Closure of PFO in Migraine with Aura (PRIMA)[37] and Prospective Randomized Investigation to Evaluate Incidence of Headache Reduction in Subjects With Migraine and PFO Using the Amplatzer PFO Occluder Compared With Medical Management (PREMIUM)[38] trials showed negative results. A recently published pooled analysis of patient level data from these two randomized trials (the PRIMA and PREMIUM) showed that complete migraine cessation was nine times greater in the PFO closure group and this effect was more prominent in migraine with aura.

At this time, screening for PFO in patients with migraine is not recommended, and PFO closure in this setting remains

controversial. To address this further, RELIEF migraine trial (GORE® CARDIOFORM Septal Occluder Migraine Clinical Study: A Study to Evaluate the Safety and Efficacy of Transcatheter Closure of Patent Foramen Ovale for Relief of Migraine Headaches, sponsored by WL Gore and Associates) will begin enrollment in US aiming to enroll 150 patients (https://clinicaltrials.gov/ct2/show/NCT04100135). This blinded sham-controlled trial, will use migraine responsiveness to P2Y12 platelet inhibition as inclusion criterion. Primary endpoint will be reduction in migraine headache days at 40 weeks follow-up.

INDICATIONS FOR PFO CLOSURE

In the United States, percutaneous device closure of PFO in patients with cryptogenic stroke due to presumed paradoxical embolism received Food and Drug Administration (FDA) approval in 2016 for closure using Amplatzer PFO Occluder and in 2018 for closure using the Gore Cardioform Septal Occluder (GSO). In addition, off-label percutaneous PFO closures have been performed in patients with migraine headaches, decompression illness, platypnea-orthodeoxia, and myocardial infarction with normal coronary arteries. In Europe, there are multiple devices that have been granted CE mark for PFO closure, and physicians are able to use their judgment as to appropriate criteria for therapy.

DEVICES (TABLE 1)

Amplatzer PFO and Septal Occluder (St Jude Medical, St Paul, MN)

The Amplatzer family of devices includes the Amplatzer PFO occluder **(Fig. 3A)**, the Amplatzer Septal Occluder **(Fig. 3B)**, and the multifenestrated "Cribriform" septal occluder **(Fig. 3C)**. Although the atrial septal occluder is mainly used to close atrial septal defects (ASDs), it is occasionally used to close large PFOs. The PFO and ASD occluders are very similar with two differences between them. Whereas the left atrial disk is larger in the ASO device, the right atrial disk of the PFO occluder is slightly larger than the left atrial disk (except for the 18 mm PFO device where both disks measure the same) due to the often higher pressure in the right atrium and the predominantly right-to-left shunting of these defects. The Amplatzer PFO devices presently are available with a 35, 25, or 18 mm right atrial disk with equal size left atrial disks. The 18 mm device is intended for use in small PFOs with a stable septum primum. The 35 mm device is destined for large PFOs with ASA and it requires a 9 French sheath in contrast to the other smaller devices fitting through an 8 French sheath. The other difference between the PFO and ASD devices is in the diameter of the connecting waist. In the ASO, the connecting waist varies in diameter by device size (up to 38 mm in the US and 40 mm outside US) while in the PFO device, the connecting waist measures 3 mm for all available sizes. The Amplatzer PFO device has the same capability as the ASD device of being easily withdrawn back into the delivery sheath at any time before the purposeful release of the device from the delivery cable. Currently, the Amplatzer PFO occluder is not available for use in the US. *Please refer to the Devices section in the "Transcatheter closure of ASD" chapter for details regarding the ASO and "Cribriform" devices.*

TABLE 1: PFO closure devices.

Double-disk devices	• CardioSEAL/STARFlex (not available) • Amplatzer • Occlutech Figulla Flex • HELEX septal occluder • Solysafe septal occluder • Nit-Occlud
In-tunnel closure devices	• Coherex FlatStent EF • SeptRx occluder
Suture-based device	NobleStitch™
Radio frequency ablation	PFx closure system (Cierra)

(PFO: patent foramen ovale)

Gore HELEX Septal Occluder (WL Gore and Associates, Flagstaff, AZ)

The HELEX septal occluder **(Fig. 3D)** is composed of a single nitinol wire covered by expanded polytetrafluoroethylene (ePTFE) with a left atrial eyelet, central eyelet, and right atrial eyelet. The locking loop from the left atrial side to the right atrial side holds the device together after deployment. The device is currently available in various sizes (15, 20, 25, 30, and 35 mm) and comes with a green delivery catheter in which the device is already extruded from its distal tip. There is a gray catheter attached to the proximal right atrial eyelet which is used to retract or extrude the device. The mandrel attaches to the left atrial eyelet and contains the locking loop. The mandrel is pulled to release the device and lock it in place.

A newer generation of Gore Septal Occluder (GSO) is now available (called the GORE® CARDIOFORM Septal Occluder) and has replaced the HELEX device. This device consists of an implantable occluder and a delivery system. The occluder consists of a platinum-filled nickel titanium (Nitinol) wire frame covered with ePTFE. The ePTFE has a hydrophilic surface treatment that enables echocardiographic imaging of the occluder during implantation. It assumes a double-disk configuration when fully deployed and prevents shunting of blood between the right and left atria. The delivery system consists of a 10 Fr outer diameter delivery catheter that is coupled to a handle. The handle allows loading, deployment, and locking of the occluder. The occluder is available in diameters of 20, 25, and 30 mm.

CardioSEAL/STARFlex Devices (NMT Medical, Boston, MA)

The CardioSEAL/STARFlex family of devices consists of two square patches of polyester fabric hand-sewn to a stainless-steel skeleton. The CardioSEAL was a modified version of the initial

Clamshell device. It consisted of two square Dacron patches, mounted between four spring arms composed of a nonferrous alloy **(Fig. 3E)**. The device was available in diameter sizes from 17 to 40 mm. The STARFlex septal occluder represented a further revision of the CardioSEAL with the addition of small microsprings attached at the end of each opposing arm **(Fig. 3F)**. These devices have been discontinued and the manufacturer of these devices (Nitinol Medical Technologies) ceased to exist due to financial problems (Figs. 12C and 12D in Transcatheter Closure of ASD chapter).

Premere PFO Closure System (St Jude Medical, St Paul, MN)

This device is specifically designed for PFO closure, featuring two cross-shaped nitinol anchors **(Fig. 3G)**. The right-sided anchor is positioned between two membranes of knitted polyester. The left-sided nitinol anchor is uncovered. A flexible polyester braided tether connects the two nitinol anchors of the device and allows the left and right anchor arms to conform independently with the ability to adjust the distance between the left and right atrial disks according to the PFO tunnel length. Important features of the Premere device are the open architecture and low profile of the left anchor arm, minimizing the risk of thrombus formation and reducing the risk of device erosion. The device is available in 20, 25, and 30 mm sizes.

The Coherex FlatStent EF PFO (Coherex Medical, Salt Lake City, Utah)

The Coherex FlatStent EF PFO closure system is a nitinol-based lattice framework, onto which medical-grade polyurethane foam is attached **(Fig. 3H)**. The device has micro-tined anchors that extend from the PFO tunnel and attach to the walls of the left and right atrium. Radiopaque markers allow for visualization of the anchors during device placement. The system is available in 13 mm (for balloon measured diameter <8 mm) and 19 mm (for balloon measured diameter <12 mm) sizes. The size designation indicates the width of the central portion of the FlatStent, which is the part of the implant that lies within the PFO tunnel.

The implant is designed to be unsheathed in the PFO tunnel where it expands laterally. This action brings the walls of the septum primum and the septum secundum into apposition. The polyurethane foam in the intratunnel cells is intended to stimulate tissue growth inside the tunnel. The delivery system is a catheter similar to multipurpose catheter that is designed for use with 0.035 in guidewire and has a 9.5 cm rapid exchange rail. The left atrial anchors, which are intended to engage the PFO tunnel on the left side of the septum, extend 4 mm wider on each anchor than the designated device size. The device is fully repositionable and retrievable and is implanted via 12 French venous access. Whereas all other available occluders extend into both atria, this novel device leaves only a minimal amount of surface area exposed in the left atrium, thus, reducing the risk of thrombus formation. The manufacturer discontinued this device from their portfolio.

Cardia Ultrasept PFO Occluder (Cardia, Burnsville, MN)

Cardia has developed several generations of septal occluders designed for closure of PFO and ASD consisting of two Ivalon disks mounted and expanded by nitinol arms. The Ultrasept is the latest Cardia septal occluder, incorporating a dual articulating sail at the center of the device which provides a very low profile against the interatrial septum **(Fig. 3I)**. The device is available in 5 mm increments from 20 to 35 mm, delivered through 9–11 French sheaths, and is completely retrievable throughout the procedure.

Solysafe Septal Occluder (Swiss Implant, Solothurn, Switzerland)

This is a self-centering ASD closure device consisting of two synthetic patches that are attached to wires made of a cobalt-based alloy called Phynox which has similar characteristics to nitinol by virtues of elasticity and memory retention. The wires are maintained in place by two wire holders on each side of the atrial septum **(Fig. 3J)**. A major advantage of this system is the delivery over a guidewire instead of a long trans-septal sheath. The device is fully retrievable up to the point that the guidewire is removed. Distribution of this device ceased in August 2010, partly due to the high rate of wire fracture.

Occlutech Figulla Flex II PFO Device (Occlutech GmbH, Jena, Germany)

The Occlutech Figulla PFO occluder is technically similar to the Amplatzer devices; it is a double-disk device made of a self-expanding nitinol wire mesh connected by a 3 mm waist in the center. Inside each of the disks, there is a polyethylene (PET) patch to support the immediate closure **(Fig. 3K)**. The device's uniqueness lies in the fact that the left atrial disk consists only of a single layer without a hub, thereby minimizing the amount of material on the left atrial side. An integral locking delivery and retrieval mechanism ensures safe and stable deployments and allows a tilt up to 45°. Two different PFO devices are available, i.e., a single-layered and a double-layered device. With the single-layer device, the left atrial disk is single layered, forming a very flat disk, reducing the amount of metal needed. The double-layered device is available for closure of PFO defects with a long tunnel morphology and ASA. This device consists of a double-layered disk on the left atrial side. The single-layer PFO device is available in one size (23 mm left atrial disk/25 mm right atrial disk). The double-layer device is available in four sizes (16/18, 23/25, 27/30, 31/35). In 2017, OPPOSE registry data reaffirmed excellent device implantation success rate and also safety and efficacy endpoints in 100 patients followed prospectively for 6 months.[39]

PFM Nit-Occlud PFO Device (Pfm Medical Ag, Koln, Germany)

The Nit-Occlud PFO occluder consists of a single nitinol wire with a double-layer right atrial disk and a single-layer left atrial disk **(Fig. 3L)**. By the minimal amount of Nitinol in the LA, the thromboembolic risk is reduced. Both disks are identical in diameter. It is currently available in 20, 26, and 30 mm sizes requiring 9 and 10 French sheaths.

SeptRx Occluder (Secant Medical, Perkasie, PA)

The SeptRx device is a unique device in that it targets only the PFO tunnel as opposed to the right and left atrial borders. It consists of a laser-cut, self-expanding nitinol frame with flexible anchor struts at the top of the device, which uncoil from their curved shape to adapt to a variety of PFO tunnel lengths. At the base of the device are additional anchors, which are designed to grip the edge of the PFO tunnel on the right atrial side. The flat frame of the device applies a gentle force to the PFO tunnel to laterally stretch the tissues and flatten the pocket of the PFO to bring the septum primum and secundum closer together **(Fig. 3M)**. The interior of the device contains nitinol mesh which stimulates the body's natural adhesion response for permanent closure of the PFO. The device is delivered through 9 French sheath and is recapturable at any time during the procedure. Advantages of this device relate to the fact that it does not significantly change the configuration of septum primum and that foreign material in the left atrium is reduced, thus minimizing the risk of thrombus formation.

NobleStitch™ (Nobles Medical Technologies II)

The NobleStitch™ EL is a device that places a suture into the two atrial septal walls (the septum primum and the septum secundum) and ties them closed with a small implantable polypropylene knot (using KwiKnot™ catheter) which is located in the right atrium leaving nothing in the left atrium. A prospective multicenter parallel concurrent clinical trial called "STITCH" is underway with plans of recruiting 630 patients and a 5-year follow-up with estimated completion date of April 30, 2026. STITCH is a comparative trial which will compare the safety and effectiveness of the NobleStitch™ EL suture-based closure system for PFO closure to the Amplatzer™ PFO Occluder (Abbott Laboratories) **(Fig. 3N)**.

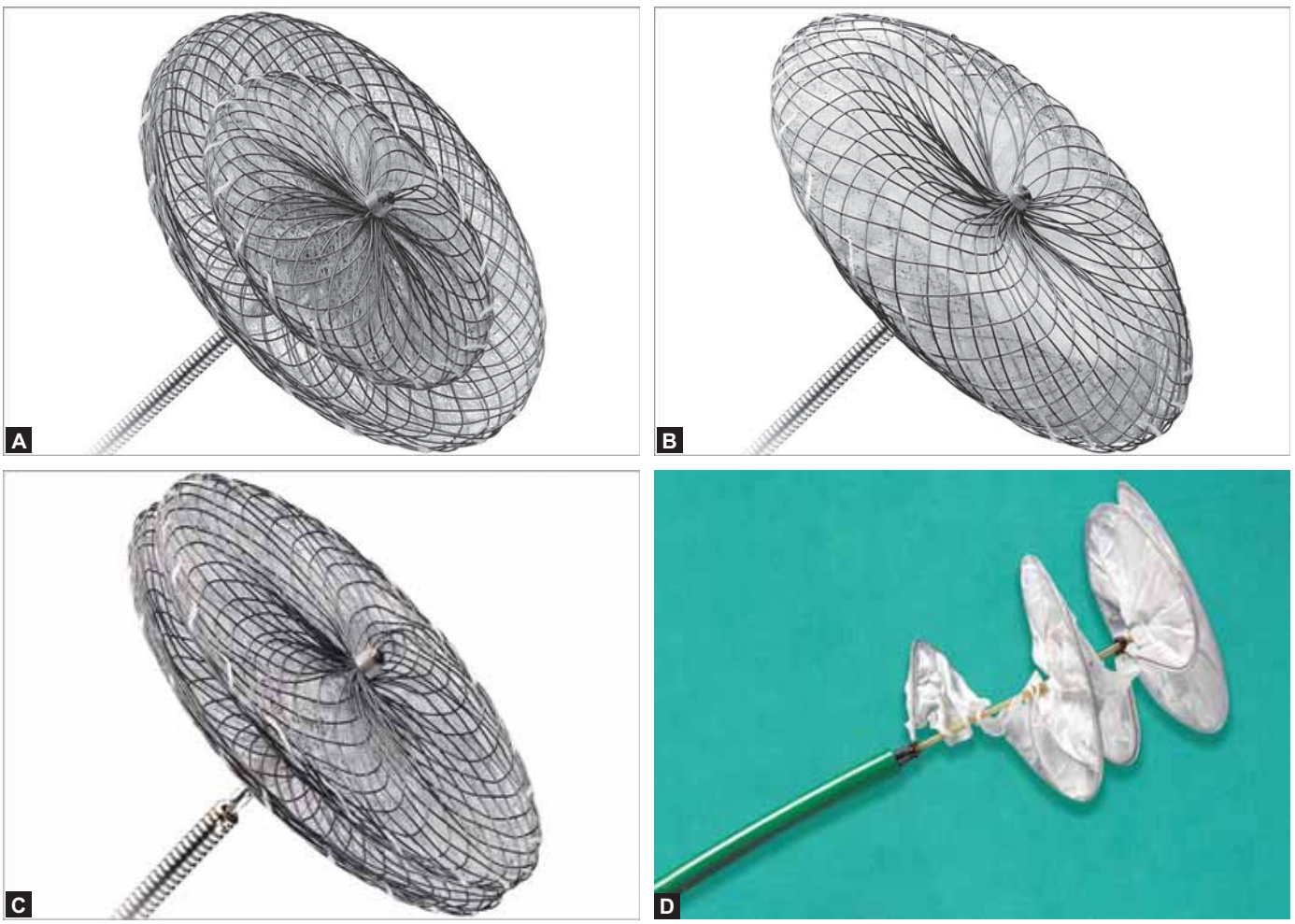

Figs. 3A to N: *Continued*

Continued



Figs. 3A to N: *Continued*

Continued

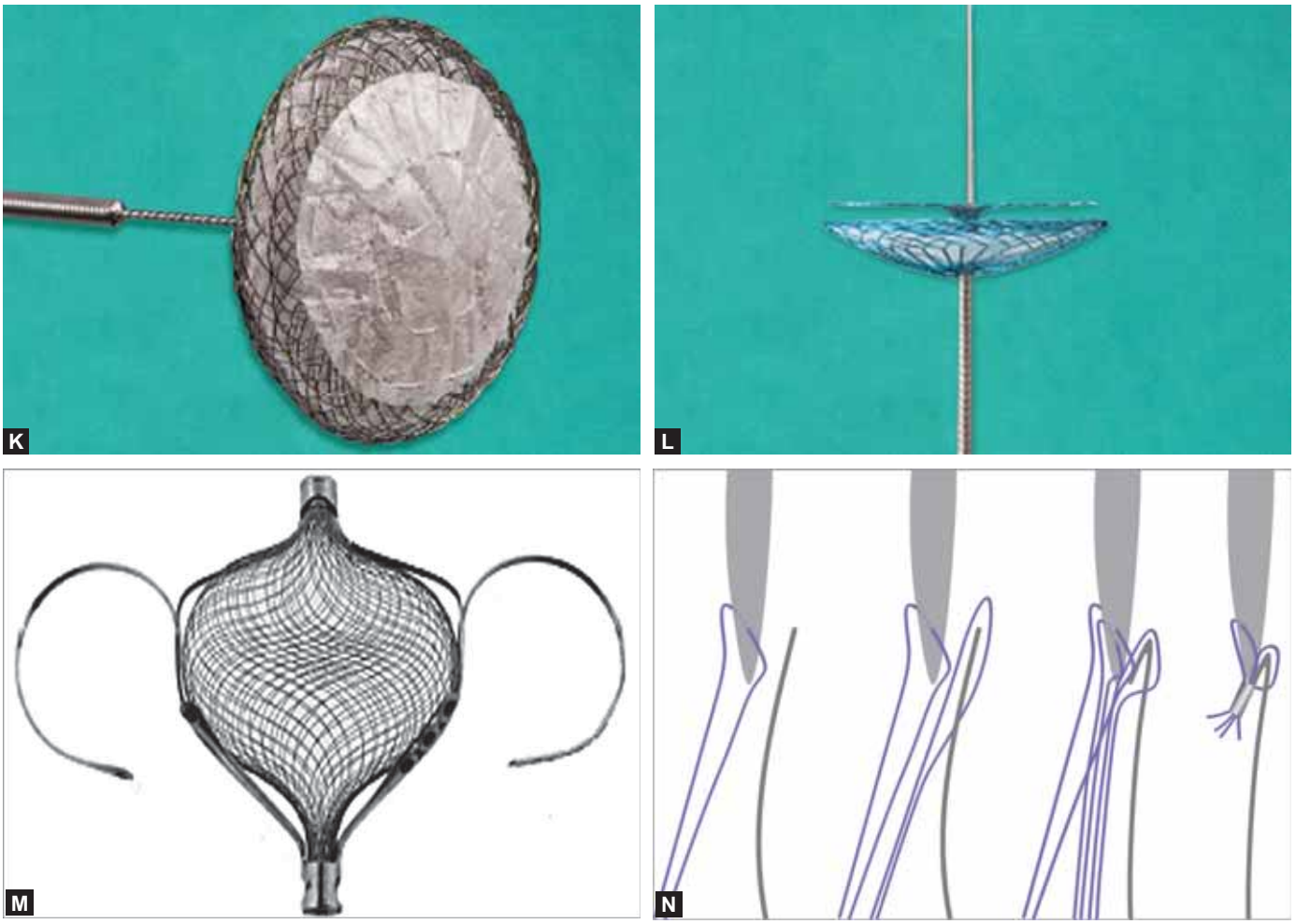

Figs. 3A to N: Various patent foramen ovale (PFO) closure devices: (A) Amplatzer PFO occluder; (B) Amplatzer Septal Occluder; (C) Amplatzer multifenestrated"Cribriform"; (D) Gore HELEX septal occluder; (E) CardioSEAL; (F) STARFlex; (G) Premere PFO closure system; (H) Coherex FlatStent EF PFO; (I) Ultrasept PFO occluder; (J) Solysafe septal occluder; (K) Occlutech Figulla Flex II PFO device; (L) PFM NitOcclud PFO Device; (M) SeptRx occluder; (N) Schematic of NobleStitch™.

The endpoints of STITCH will include closure rates, safety events, and occurrence of recurrent ischemic stroke postprocedure.

IMPLANTATION TECHNIQUE

Procedure

In recent decades, many devices have been developed for percutaneous closure of ASDs with high success rates. In the United States, PFO closure is performed on off-label basis using either the Gore HELEX occluder or the Amplatzer Septal or multifenestrated occluders. The initial procedure for PFO closure is similar to ASD closure with some differences as will be discussed here.

Depending on whether TEE or ICE is being used, the procedure can be performed under general anesthesia or conscious sedation, respectively. If ICE is used, two sheaths are inserted in the femoral vein. An 8-F or 10-F sheath is used for the ICE catheter, and a 7-F or 8-F sheath is used for the right heart catheterization. Both sheaths can be placed in the same femoral vein (if patient's weight is >35 kg) or bilateral veins (if patient's weight is <35 kg). If the femoral venous route is not available, we advocate the transhepatic approach as device deployment would be difficult using the subclavian or internal jugular veins approaches.

Although patients with PFOs do not have volume overload, a baseline right heart catheterization is recommended in all patients to exclude severe pulmonary hypertension that may preclude closure. PFO in these cases may act as a pop-off mechanism to maintain cardiac output at the expense of low systemic saturations. Measurement of pulmonary venous saturation can be obtained to rule out other sources of right-to-left shunting like pulmonary arteriovenous malformations (AVMs). Angiography may provide additional information on anatomy of the septum as well as the length and the orientation of the PFO tunnel, however, this is rarely necessary.

The closure procedure is usually performed under echocardiographic guidance. Both TEE and ICE are used safely and effectively to guide transcatheter PFO closure. The choice between them depends on patient age, familiarity of the operator with technique, and local cost issues. Complete echocardiographic assessment of the type and shape of the defect, placement of the device, and postprocedure evaluation is crucial. Since its introduction to guide device closure of ASD and PFO in the early 2000s, ICE has evolved into an established imaging modality for such procedures. The main advantages of ICE over TEE for ASD closure include avoidance of general anesthesia, better visualization of the left atrium and posteroinferior part of the septum, shorter procedure times, and the ability of the interventionist to perform the procedure as well as the imaging part without the need of additional echocardiographic personnel. Several ICE systems are currently commercially available including the AcuNav catheter (Siemens/Biosense Webster, CA), ViewFlex catheter (St Jude Medical, MN), and the Ultra ICE catheter (Boston Scientific, Boston, MA). *(Refer to Transcatheter closure of ASDs chapter for further discussion on TEE and ICE evaluation).* Occasionally, preprocedural studies merely suggest the presence of PFO and hence it is important to document right-to-left shunt in the cardiac catheterization laboratory. By placing a catheter in the right atrium, agitated saline is rapidly injected under echocardiographic visualization. At the same time, Valsalva maneuver or pressing on the patient's abdomen while asking him/her to breathe in is also performed to facilitate right to left shunting. Early visualization of the bubbles in the left atrium within the first three beats of injection is generally consistent with shunting at the atrial level.

We usually use the wedge catheter to cross the PFO defect. Gentle clockwise torque while advancing the catheter from the IVC is successful in crossing almost all defects. The trick is to be able to propagate the torque to the tip of the catheter while advancing in. Static rotation of the catheter is not helpful. However, if this maneuver fails, stiffening the catheter using a wire or switching to a multipurpose catheter might be needed. A small subset of PFOs may be more challenging to cross because of an abnormal plane of the interatrial septum with the presence of interatrial septal aneurysm or a complex tunnel. A Terumo guidewire may allow easier crossing of these anatomic variants of PFO. Rarely, transseptal needle puncture is an option in some complex long-tunnel PFOs to place a more centrally located perpendicular device that overlaps the PFO rather than using the PFO tunnel which may tilt the device.

After crossing the defect, the catheter is rotated clockwise and positioned in the left upper pulmonary vein. Anatomically, the location of the left atrial appendage and the left upper pulmonary vein are very close to each other. It is critical to be aware of the location of the wire as pushing it further into the left atrial appendage may result in perforation. A catheter or wire in the appendage seems to move excessively as opposed to when it is in the pulmonary vein which is a fixed structure in the lungs. Furthermore, a catheter in the appendage causes premature atrial contractions as opposed to when it is in the pulmonary vein. Once the catheter is in the left upper pulmonary vein, it is then exchanged with a wire to support subsequent device advancement into the left atrium. The use of a sizing balloon during the PFO closure procedure is common, although it is of uncertain value in the opinion of some experts. Moreover, the use of a sizing balloon can give inaccurate measurements causing possible overestimation or underestimation of the occluder size; it also can cause septum primum membrane damage which will eventually cause enlargement of the defect.[40] When it is performed, a compliant balloon is gently inflated across the defect until the entrance (right atrial margin), exit (left atrial margin), and length of the tunnel are identified **(Fig. 4)**. The balloon waist may be discrete, which indicates a simple PFO, or more lengthy, which suggests a tunnel-like PFO. Using the manufacturer's recommendations, a device size is selected based on the measured diameter of the PFO. Correct device position is verified by visualization of the disks on both sides of the PFO. Echocardiographic assessment using color-flow Doppler and bubble injection is performed; however, the attachment of the device to the delivery cable often distorts the interatrial septal anatomy which may preclude assessment of the final device effectiveness in closing the PFO. After the device is released, the device is reoriented to the septal plane after the tethering effect of the attachment is no longer present. The immediate effectiveness of the PFO closure can be best assessed using agitated saline injection under echocardiographic and TCD monitoring. Persistent right-to-left shunting may be seen in approximately one-third of patients following device implantation; in most patients this usually disappears in the subsequent months as a result of device endothelialization.

Detailed technical description of the use of the Gore HELEX occluder and Amplatzer devices can be found in "Transcatheter closure of ASD" chapter.

DEVICE SELECTION BASED ON ANATOMIC FEATURES

As more is understood about the morphology of PFO, the complexity of PFO closure as an intervention also increases. One of the main challenges present is which occluder to use. No single type of occluder is ideal, and different occluders are required in order to meet the different PFO morphologies. An attempt should always be made to select the most appropriate occluder based on the anatomic features **(Table 2)**.

LONG PFO TUNNEL

A long-tunnel PFO is defined by an overlap between septum primum and secundum of >8 mm[11] and is present in 10% of cases submitted to catheter closure. Long tunnels present a particular problem for devices with a short connecting waist, as there is the potential for both disks to be partially deployed within the tunnel. This can result in a poorly conformed device with risk of embolization. Techniques advocated to facilitate successful closure include the use of specific devices, balloon detunnelization, and transseptal puncture. Double disk devices with a distensible disk, such as the Amplatzer PFO device and HELEX occluder, can be used.[41] Very long tunnels that are >15 mm may require a device with a longer connecting waist and changeable distance between the disks such as the

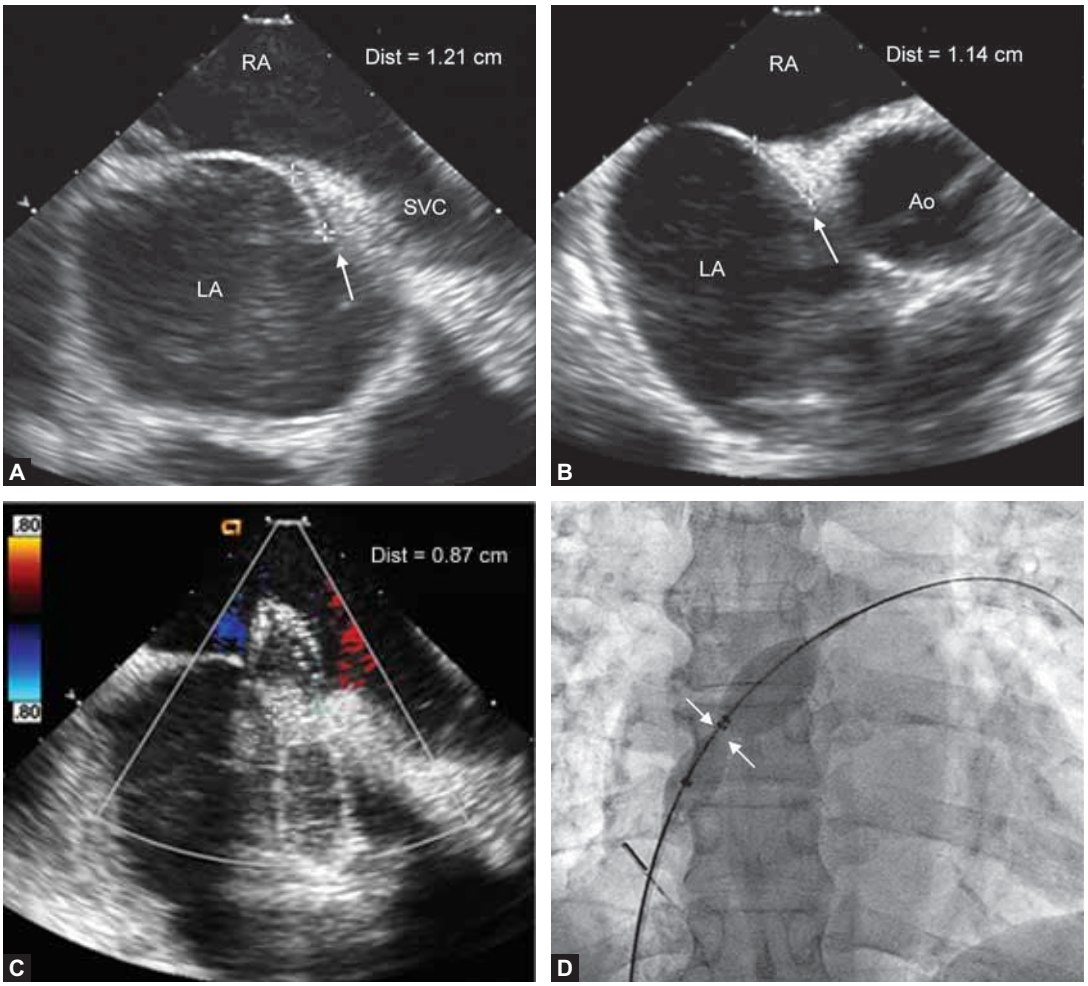

Figs. 4A to D: Intracardiac echocardiography (ICE) long-axis and short-axis view images showing significant overlap of septa forming a long tunnel with left to right shunting on color Doppler and characteristic indentation on balloon sizing.
(Ao: aorta; LA: left atrium; RA: right atrium; SVC: superior vena cava)

TABLE 2: Septal anatomical variants and suggested closure devices.

Long tunnel	Premere PFO closure system, Coherex FlatStent EF, SeptRx occluder
Large septal aneurysm	Amplatzer PFO and Cribriform occluders, Helex occluder, Occlutech PFO occluder
Multifenestrated septum	Amplatzer Cribriform occluder, Occlutech PFO occluder
Very large PFO	Amplatzer septal occluder, Occlutech PFO occluder
Lipomatous hypertrophy of the atrial septum	Premere PFO closure system, Double-disk devices (Amplatzer muscular VSD occluder for very large LHAS)

(PFO: patent foramen ovale)

Premere PFO closure system which allows a final interdependent positioning of both disks. The use of an in-tunnel closure device (Coherex FlatStent PFO closure and SeptRx occluder) without significant metallic material exposed in both atria might be ideal for this PFO morphology. The balloon detunnelization technique involves stepwise dilatation of the balloon until the PFO entrance and exit constraint points are approximated and merged on the fluoroscopic images.[42] This may provide an opportunity to modify PFO anatomy to facilitate standard PFO closure. Transseptal puncture to obtain a more central approach through the septal flap and delivery of the device through the puncture site instead of the tunnel can be attempted. However, this has the additional risk of transseptal puncture and its success is dependent on precise puncture through the septal flap. It also has a higher residual shunt rate.

LIPOMATOUS HYPERTROPHY OF THE INTERATRIAL SEPTUM

Lipomatous hypertrophy of the interatrial septum (LHAS) is a histologically benign proliferation of adipose tissue with deposition of nonencapsulated fat cells in the atrial septum.[43] It is present in up to 8% of the general population. Hypertrophy of the atrial septum has been defined as a thickness between 6 and 14 mm, whereas LHAS is characterized by massive fatty deposits in septum secundum with thickness >15 mm. On TEE, LHAS appears as a hyperechogenic enlargement of the upper and lower parts of the interatrial septum but sparing

the fossa ovalis, resulting in a dumbbell-shaped morphology **(Fig. 5)**.[21] Percutaneous PFO closure in the presence of this anatomic entity might be challenging because occluder devices with nonmodifiable short waists will not be able to encroach the thick septum secundum; resulting in residual shunt or device embolization. The use of double-disk type of occluders provides a safe PFO closure in the presence of LHAS in most situations. Also, using asymmetric devices, such as the Premere PFO closure system, can provide the maximal independence of the two prosthetic components straddling the atrial septum. Another alternative for significant LHAS (>20 mm) is the use of a device with a longer waist, such as the Amplatzer Muscular Ventricular Septal Defect Occluder (AGA Medical, Plymouth, MN) **(Fig. 6)**.[44] In some situations, marked LHAS may be an absolute contraindication for percutaneous closure. Currently, there are no safe and effective devices available for closure of very hypertrophic rims and more than moderate ASA, therefore, alternative medical or surgical therapy should be individualized.

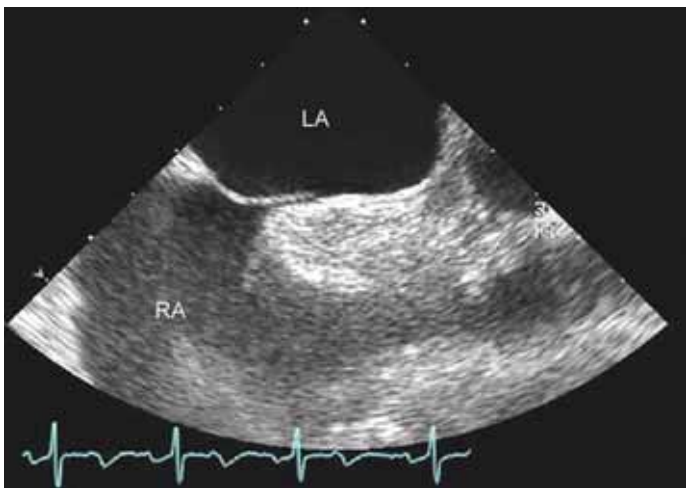

Fig. 5: Transesophageal echocardiogram demonstrating lipomatous hypertrophy of the interatrial septum and patent foramen ovale (PFO).
(LA: left atrium; RA: right atrium)
Source: Adapted with permission from Dr Lasala.[44]

MULTIFENESTRATED SEPTUM AND INTERATRIAL SEPTAL ANEURYSM

Atrial septal aneurysm refers to a redundancy of septum primum tissue bulging into the right and/or left atrium **(Fig. 7)**. It is frequently associated with PFO (50–89%)[45] and is present in up to 20–25% of cases submitted to catheter closure. A large ASA may be problematic and needs to be individually considered when selecting the type or size of the device. In the presence of moderate to large ASA, a large device approaching the length of the interatrial septum will be required to immobilize the aneurysmal septum primum (not exceeding the ratio of 0.8:1). However, this carries the increased risk associated with larger devices including arrhythmias, device thrombosis and cardiac erosions. Either rigid devices such as Amplatzer PFO and Cribriform occluders, or more malleable device such as HELEX septal occluder can be used.

In addition to the PFO, the septum primum aneurysm may also have single or multiple perforations. Transcatheter closure of the PFO in the presence of >2 perforations is very challenging and rarely is treatable with currently available devices. In the presence of two defects that are close to each other, they may be effectively closed by a single device, such as Amplatzer Cribriform device after crossing the most central defect. If the two defects are distant, two separate devices will be required with the inherent risk of device/interatrial septal misalignment or aortic impingement. Another possible method in the latter situation is by using a single device placed equidistant between the defects via a transseptal puncture.[46]

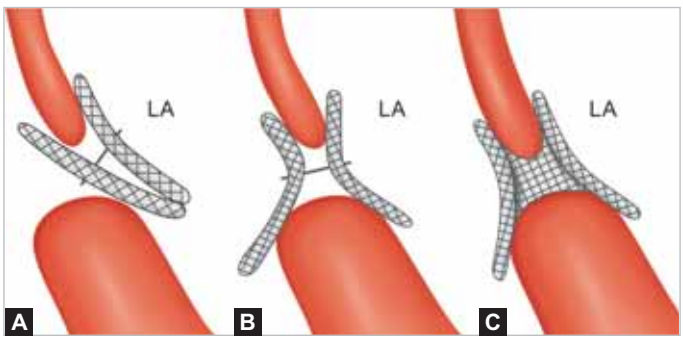

Figs. 6A to C: Schematic representations showing (A) Slippage of the device to either right or left atrium (LA) due to failure to encapsulate the hypertrophied septum secundum; (B) Encapsulation of the hypertrophied septum leading to over-splay of the device and residual shunting and higher risk of embolization; (C) Appropriate capture of septum primum and secundum using a device with a longer waist.
Source: Adapted with permission from Dr Lasala.[44]

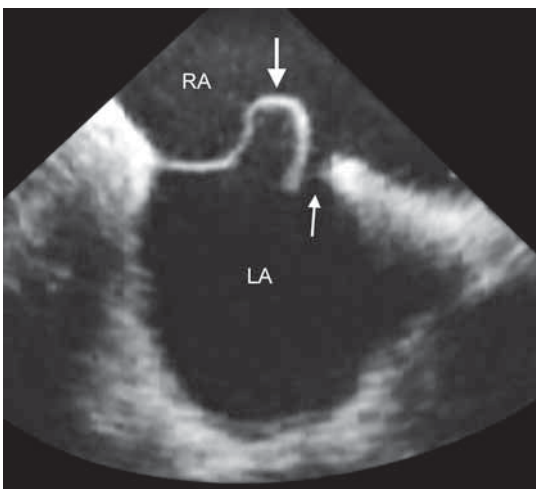

Fig. 7: Intracardiac echocardiography (ICE) septal view image demonstrating aneurysmal septum primum and patent foramen ovale (PFO) (arrows).
(LA: left atrium; RA: right atrium)

POSTPROCEDURAL CARE

Patients are typically observed overnight in telemetry wards. The following day, ECG, PA/lateral chest X-ray and TTE should be performed to assess the position of the device. Patients are asked to take endocarditis prophylaxis when necessary for 6 months after the procedure, as well as aspirin 81 mg daily indefinitely and clopidogrel 75 mg daily for 2–3 months.

POSTPROCEDURE COMPLICATIONS

Residual Shunt after Closure

As mentioned earlier, persistent right-to-left shunting may be seen in approximately one-third of cases. In most patients, this usually disappears in the subsequent months as a result of device endothelialization. Nevertheless, in a minority of patients residual shunting persists beyond the expected endothelialization period (1–2%). Residual shunts are usually the result of a mismatch between the device shape and PFO anatomy. Some patients have additional unrecognized defects at the time of the procedure. In patients with moderate to large residual shunts, it has been reported a fourfold increase risk in recurrent paradoxical embolism events compared to those with complete PFO closure.[47] Treatment options for these patients include medical therapy with antiplatelet/anticoagulation medications, surgical device removal and patch closure, and percutaneous implantation of a second device. The use of additional occluder may be technically challenging, however, in the author's experience, implantation of a second device has been feasible, safe, and effective.

Device Erosions

Cardiac erosions are a potentially lethal complication of percutaneous closure procedures and can occur at the roof of the right or left atrium, or at the atrial junction with the aorta causing hemopericardium, tamponade or aortic fistula. Risk factors implicated in this complication includes deficient anterior-superior rim and device oversizing. The first case of cardiac perforation using the Amplatzer PFO occluder device was reported by Trepels et al. in 2003.[48] *For discussion about device erosion, please refer to the complications section in "Transcatheter closure of ASD" chapter.*

Device Embolization

Embolization is among the most common complications reported in the literature, ranging from 0.5 up to 3%.[49] Usually, it occurs intraprocedurally or in the first 24 hours, but late embolizations have been reported.[50] Causes are various including: inadequate rims, eccentric and large defects, incorrect implantation, or device choice. In the majority of cases, percutaneous retrieval of the device is feasible *(See device embolization section in "Transcatheter closure of ASD" chapter).*

Device Thrombosis

Overall risk of thrombus formation is low (1%). The incidence varies from 0.2% (Amplatzer PFO occluder) to 7.1% (CardioSEAL).[51] Typically, patients are started on dual antiplatelet therapy using aspirin and clopidogrel postprocedure which is usually adequate for majority of patients to prevent such a complication. Workup for thrombophilic disorders is required in these situations. In most cases, thrombus usually resolves with anticoagulation therapy with few requiring surgical explantation.

CONCLUSION

Transcatheter closure of PFO is increasingly considered the treatment of choice for young patients with cryptogenic stroke due to paradoxical embolism. Presence of PFO is frequently associated with multiple anatomical variants that might impact the procedural results and outcome. Complete assessment of these variants is essential for increasing the success rate and lowering potential failures or complications. No single device is ideal for all PFOs, device selection should be tailored based on the anatomic features.

"Medicine is a science of uncertainty and an art of probability."

—Sir William Osler

REFERENCES

1. Lechat P, Mas JL, Lascault G, Loron P, Theard M, Klimczac M, et al. Prevalence of patent foramen ovale in patients with stroke. N Engl J Med. 1988;318(18):1148-52.
2. Handke M, Harloff A, Olschewski M, Hetzel A, Geibel A. Patent foramen ovale and cryptogenic stroke in older patients. N Engl J Med. 2007;357(22):2262-8.
3. Azarbal B, Tobis J, Suh W, Chan V, Dao C, Gaster R. Association of interatrial shunts and migraine headaches: impact of transcatheter closure. J Am Coll Cardiol. 2005;45(4):489-92.
4. Sorrentino M, Resnekov L. Patent foramen ovale associated with platypnea and orthodeoxia. Chest. 1991;100(4):1157-8.
5. Moon RE, Camporesi EM, Kisslo JA. Patent foramen ovale and decompression sickness in divers. Lancet. 1989;1(8637):513-4.
6. Sievert H, Krumsdorf U. Transcatheter closure of intracardiac shunts. Z Kardiol. 2002;91 (Suppl 3):77-83.
7. Post MC, Van Deyk K, Budts W. Percutaneous closure of a patent foramen ovale: single-centre experience using different types of devices and mid-term outcome. Acta Cardiol. 2005;60(5):515-9.
8. Hara H, Virmani R, Ladich E, Mackey-Bojack S, Titus J, Reisman M, et al. Patent foramen ovale: current pathology, pathophysiology, and clinical status. J Am Coll Cardiol. 2005;46(9):1768-76.
9. Hagen PT, Scholz DG, Edwards WD. Incidence and size of patent foramen ovale during the first 10 decades of life: an autopsy study of 965 normal hearts. Mayo Clinic Proc. 1984;59(1):17-20.
10. Ho SY, McCarthy KP, Rigby ML. Morphological features pertinent to interventional closure of patent oval foramen. J Interv Cardiol. 2003;16(1):33-8.
11. McKenzie JA, Edwards WD, Hagler DJ. Anatomy of the patent foramen ovale for the interventionalist. Catheter Cardiovasc Interv. 2009;73(6):821-6.

12. El Said HG, McMahon CJ, Mullins CE, Pignatelli RH, Grifka RG, Nihill MR, et al. Patent foramen ovale morphology and impact on percutaneous device closure. Pediatric Cardiol. 2005;26(1):62-5.
13. Hołda MK, Koziej M. Morphometric Features of Patent Foramen Ovale as a Risk Factor of Cerebrovascular Accidents: A Systematic Review and Meta-Analysis. Cerebrovasc Dis. 2020;49(1):1-9.
14. Teague SM, Sharma MK. Detection of paradoxical cerebral echo contrast embolization by transcranial Doppler ultrasound. Stroke. 1991;22(6):740-5.
15. Park S, Oh JK, Song JK, Kwon B, Kim BJ, Kim JS, et al. Transcranial Doppler as a Screening Tool for High-Risk Patent Foramen Ovale in Cryptogenic Stroke. J Neuroimaging. 2021;31(1):165-70.
16. Moon J, Park Y, Park SJ, Oh PC, Jang AY, Chung WJ, et al. Comparison of Intracardiac Echocardiography and Transesophageal Echocardiography for Image Guidance in Percutaneous Patent Foramen Ovale Closure. Medicina (Kaunas). 2020;56(8).
17. Furlan AJ, Reisman M, Massaro J, Mauri L, Adams H, Albers GW, et al. Closure or Medical Therapy for Cryptogenic Stroke with Patent Foramen Ovale. N Engl J Med. 2012;366(11):991-9.
18. Staubach S, Steinberg DH, Zimmermann W, Wawra N, Wilson N, Wunderlich N, et al. New onset atrial fibrillation after patent foramen ovale closure. Catheter Cardiovasc Interv. 2009;74(6):889-95.
19. Carroll JD, Saver JL, Thaler DE, Smalling RW, Berry S, MacDonald LA, et al. Closure of Patent Foramen Ovale versus Medical Therapy after Cryptogenic Stroke. N Engl J Med. 2013;368(12):1092-100.
20. Meier B, Kalesan B, Mattle HP, Khattab AA, Hildick-Smith D, Dudek D, et al. Percutaneous Closure of Patent Foramen Ovale in Cryptogenic Embolism. N Engl J Med. 2013;368(12):1083-91.
21. Augoustides JG, Weiss SJ, Ochroch AE, Weiner J, Mancini J, Savino JS, et al. Analysis of the interatrial septum by transesophageal echocardiography in adult cardiac surgical patients: anatomic variants and correlation with patent foramen ovale. J Cardiothorac Vasc Anesth. 2005;19(2):146-9.
22. Saver JL, Carroll JD, Thaler DE, Smalling RW, MacDonald LA, Marks DS, et al. Long-Term Outcomes of Patent Foramen Ovale Closure or Medical Therapy after Stroke. N Engl J Med. 2017;377(11):1022-32.
23. Mas JL, Derumeaux G, Guillon B, Massardier E, Hosseini H, Mechtouff L, et al. Patent Foramen Ovale Closure or Anticoagulation vs. Antiplatelets after Stroke. N Engl J Med. 2017;377(11):1011-21.
24. Søndergaard L, Kasner SE, Rhodes JF, Andersen G, Iversen HK, Nielsen-Kudsk JE, et al. Patent Foramen Ovale Closure or Antiplatelet Therapy for Cryptogenic Stroke. N Engl J Med. 2017;377(11):1033-42.
25. Kasner SE, Rhodes JF, Andersen G, Iversen HK, Nielsen-Kudsk JE, Settergren M, et al. Five-Year Outcomes of PFO Closure or Antiplatelet Therapy for Cryptogenic Stroke. N Engl J Med. 2021;384(10):970-1.
26. Lee PH, Song JK, Kim JS, Heo R, Lee S, Kim DH, et al. Cryptogenic Stroke and High-Risk Patent Foramen Ovale: The DEFENSE-PFO Trial. J Am Coll Cardiol. 2018;71(20):2335-42.
27. Nasir UB, Qureshi WT, Jogu H, Wolfe E, Dutta A, Majeed CN, et al. Updated meta-analysis of closure of patent foramen ovale versus medical therapy after cryptogenic stroke. Cardiovasc Revasc Med. 2019;20(3):187-93.
28. Varotto L, Bregolin G, Paccanaro M, De Boni A, Bonanno C, Perini F. Network meta-analysis on patent foramen ovale: is a stroke or atrial fibrillation worse? Neurol Sci. 2021;42(1):101-9.
29. Seward JB, Hayes DL, Smith HC, Williams DE, Rosenow EC 3rd, Reeder GS, et al. Platypnea-orthodeoxia: clinical profile, diagnostic workup, management, and report of seven cases. Mayo Clinic Proc. 1984;59(4):221-31.
30. Cheng TO. Mechanisms of platypnea-orthodeoxia: what causes water to flow uphill? Circulation. 2002;105(6):e47.
31. Medina A, de Lezo JS, Caballero E, Ortega JR. Platypnea-orthodeoxia due to aortic elongation. Circulation. 2001;104(6):741.
32. Shah AH, Osten M, Leventhal A, Bach Y, Yoo D, Mansour D, et al. Percutaneous Intervention to Treat Platypnea-Orthodeoxia Syndrome: The Toronto Experience. JACC Cardiovasc Interv. 2016;9(18):1928-38.
33. Germonpre P. Patent foramen ovale and diving. Cardiol Clin. 2005;23(1):97-104.
34. Rigatelli G. Migraine and patent foramen ovale: connecting flight or one-way ticket? Expert Rev Nneurother. 2008;8(9):1331-7.
35. Etminan M, Takkouche B, Isorna FC, Samii A. Risk of ischaemic stroke in people with migraine: systematic review and meta-analysis of observational studies. BMJ. 2005;330(7482):63.
36. Dowson A, Mullen MJ, Peatfield R, Muir K, Khan AA, Wells C, et al. Migraine Intervention With STARFlex Technology (MIST) trial: a prospective, multicenter, double-blind, sham-controlled trial to evaluate the effectiveness of patent foramen ovale closure with STARFlex septal repair implant to resolve refractory migraine headache. Circulation. 2008;117(11):1397-404.
37. Mattle HP, Evers S, Hildick-Smith D, Becker WJ, Baumgartner H, Chataway J, et al. Percutaneous closure of patent foramen ovale in migraine with aura, a randomized controlled trial. Eur Heart J. 2016;37(26):2029-36.
38. Tobis JM, Charles A, Silberstein SD, Sorensen S, Maini B, Horwitz PA, et al. Percutaneous Closure of Patent Foramen Ovale in Patients With Migraine: The PREMIUM Trial. J Am Coll Cardiol. 2017;70(22):2766-74.
39. Hildick-Smith D, Williams T, MacCarthy P, Melikian N, Monaghan M, Spence M, et al. Occlutech percutaneous patent foramen ovale closure: Safety and efficacy registry (OPPOSE). Int J Cardiol. 2017;245:99-104.
40. King TD, Thompson SL, Mills NL. Measurement of atrial septal defect during cardiac catheterization. Experimental and clinical results. Am J Cardiol. 1978;41(3):537-42.
41. Meier B. Closure of patent foramen ovale: technique, pitfalls, complications, and follow up. Heart. 2005;91(4):444-8.
42. Spence MS, Khan AA, Mullen MJ. Balloon assessment of patent foramen ovale morphology and the modification of tunnels using a balloon detunnelisation technique. Catheter Cardiovasc Interv. 2008;71(2):222-8.
43. O'Connor S, Recavarren R, Nichols LC, Parwani AV. Lipomatous hypertrophy of the interatrial septum: an overview. Arch Pathol Lab Med. 2006;130(3):397-9.
44. Lin CH, Balzer DT, Lasala JM. Defect closure in the lipomatous hypertrophied atrial septum with the Amplatzer muscular ventricular septal defect closure device: a case series. Catheter Cardiovasc Interv. 2011;78(1):102-7.
45. Mas JL, Arquizan C, Lamy C, Zuber M, Cabanes L, Derumeaux G, et al. Recurrent cerebrovascular events associated with patent foramen ovale, atrial septal aneurysm, or both. N Engl J Med. 2001;345(24):1740-6.
46. Ewert P, Berger F, Vogel M, Dahnert I, Alexi-Meshkishvili V, Lange PE. Morphology of perforated atrial septal aneurysm suitable for closure by transcatheter device placement. Heart. 2000;84(3):327-31.
47. Windecker S, Wahl A, Chatterjee T, Garachemani A, Eberli FR, Seiler C, et al. Percutaneous closure of patent foramen ovale in patients with paradoxical embolism: long-term risk of recurrent thromboembolic events. Circulation. 2000;101(8):893-8.
48. Trepels T, Zeplin H, Sievert H, Billinger K, Krumsdorf U, Zadan E, et al. Cardiac perforation following transcatheter PFO closure. Catheter Cardiovasc Interv. 2003;58(1):111-3.

49. Chessa M, Carminati M, Butera G, Bini RM, Drago M, Rosti L, et al. Early and late complications associated with transcatheter occlusion of secundum atrial septal defect. J Am Coll Cardiol. 2002;39(6):1061-5.
50. Mashman WE, King SB, Jacobs WC, Ballard WL. Two cases of late embolization of Amplatzer septal occluder devices to the pulmonary artery following closure of secundum atrial septal defects. Catheter Cardiovasc Interv. 2005;65(4):588-92.
51. Krumsdorf U, Ostermayer S, Billinger K, Trepels T, Zadan E, Horvath K, et al. Incidence and clinical course of thrombus formation on atrial septal defect and patient foramen ovale closure devices in 1,000 consecutive patients. J Am Coll Cardiol. 2004;43(2):302-9.

for detailed information on cardiology books, visit our website www.jaypeebrothers.com, for detailed information on cardiology books, visit our website www

Cardiac Catheterization and Imaging

(From Pediatrics to Geriatrics)

Cardiac Catheterization and Imaging (From Pediatrics to Geriatrics) is designed as an all-inclusive, comprehensive book for Catheterization Laboratory Technicians, Cardiology Fellows, Postgraduates and Interventional Cardiologists, to be used as a reference for transcatheter interventions. The book offers the spectrum of cardiac catheterization and catheter-based interventions from pediatrics to geriatrics. It covers literally the scope of these procedures from "womb to tomb". It is intended as a practical guide for the interventional treatment of congenital, structural heart diseases, coronary and peripheral vascular diseases to be used by the Invasive Pediatric and Adult Cardiologists. Some of the procedures discussed in the book are emerging techniques in the forefront of interventional cardiology, and may not be practiced in every cardiac catheterization laboratory. In all, this book represents an accumulation of knowledge, expertise, techniques and procedures that have been learned, utilized and/or developed by various experienced interventional cardiologists with rich experiences in teaching cardiac catheterization and interventions. Multiple authors from all over the world have made very fruitful contributions, and "Foreword" is written by legendary Charles E Mullins (MD FACC MSCAI).



IB Vijayalakshmi MD DM(Cardiology) DSc FICC FIAMS FIAE FCSI FICP FAMS FISH FRCP(London) is the first lady Cardiologist of Karnataka and first one to start Pediatric Cardiology Department in Karnataka. She is a Professor Emeritus and former Head of the Pediatric Cardiology Department at Sri Jayadeva Institute of Cardiovascular Sciences and Research, Bengaluru, Karnataka, India. She has had a brilliant academic career with 39 Gold Medals and two Silver Medals. She has delivered 28 prestigious orations. She is a pioneer in Amplatzer device closure, in more than 6 cases which are recorded as first time in the world. She has delivered more than 800 Guest Lectures, 1500 Public Lectures, Radio Talks and TV Programs to bring awareness about health for general public. She has the honor of delivering the Grand Rounds at the University of Minnesota in 1999. For the first time in the world, she has proposed and published *Vijaya's Echo Criteria* for the early and precise diagnosis of carditis in children with acute rheumatic fever. Her study has been quoted in latest editions of standard Pediatric Cardiology Textbooks like Heart Diseases in Infants and Children by *Moss and Adams'* and *Park's Pediatric Cardiology for Practitioners*, 5th edition. She has proposed the National Policy for Congenital Heart Disease. She has received the prestigious fellowship from National Academy of Medical Sciences. She has presented 156 research papers. She has won best paper awards 6 times that include, best presentation award at PICS and AICS International Conference at Chicago in July 2010, and for "My Night Mare Case" in the cath lab in 2011 at Boston.

She has 156 publications to her credit (National and International) with citation index of 20.8 that include monograph on acute rheumatic fever and RHD, and book on "Step-by-Step to Echo in Congenital Heart Disease". She is the Chief Editor of a Textbook on "A Comprehensive Approach to Congenital Heart Disease", for which the "book review" has been written by Dr Crystal R Bonnichsen of Mayo Clinic and published in European Heart Journal. Her paper on coronary arteriovenous (AV) fistula closed with Amplatzer duct occluder II has topped the list of top 20 publications of 2013 in noncoronary section. She has been decorated with many awards, including the Rajyotsava Award, Lifetime Achievement awards from *Bharat Ratna* Dr APJ Abdul Kalam and Smt Pratibhadevi Singh Patil, former presidents of India. She was honored with the Doctorate of Science (DSc) for outstanding contribution in the field of Science and Technology by Karnataka State Women's University. She has put in 46 years of unblemished government service, teaching the medical students, MD pediatric and DM cardiology students. She is known for her honesty, integrity, dedication and commitment to the medical profession. She is a very popular columnist in Kannada Dailies and Weekly Magazines. She is kind and compassionate to poor children with heart diseases and has dedicated her life to service of the society.

Printed in India

Available at all medical bookstores or buy online at www.jaypeebrothers.com

JAYPEE BROTHERS
Medical Publishers (P) Ltd.
EMCA House, 23/23-B, Ansari Road,
Daryaganj, New Delhi - 110 002, INDIA
www.jaypeebrothers.com

Join us on facebook.com/JaypeeMedicalPublishers

Shelving Recommendation
CARDIOLOGY

ISBN 978-93-5696-179-1
9 789356 961791