thers.com, for detailed information on orthopedics books, visit our website www.jaypeebrothers.com, for detailed information on orthopedics books

STAVYA
SPINE HOSPITAL™
& RESEARCH INSTITUTE
PRIVATE LIMITED

Stavya Spine's Thirty3

Technology and Spine Surgery



Bharat R Dave
Mirant B Dave

Forewords
S Rajasekaran • JB Park
HS Chhabra • A Patel • A Nanda

JAYPEE

Contents

SECTION 1

ENABLING TECHNOLOGY 1

Chapter 1. Integrated Operation Theater Spine Suite....3
Chapter 2. Mobile Intraoperative 3D Computed Tomography....7
Chapter 3. Navigation in Spine Surgery....9
Chapter 4. Intraoperative Neuromonitoring....13
Chapter 5. Ultrasonic Bone Scalpel and Cavitron UltraSonic Aspirator....17
Chapter 6. Exoscope—3D, 4K Vision....26

SECTION 2

CASE REPORTS 29

Case 1. Poking the Brain: Occipitocervical Fusion....31
Case 2. Flea-bitten Curtailment: Rheumatoid Atlantoaxial Fusion....40
Case 3. The Rebellious Behemoth: C2 Giant Cell Tumor Excision....47
Case 4. Age Quake, the Deteriorating Curves: Cervical Kyphosis....53
Case 5. *Griva* with WWW: Klippel–Feil Syndrome....61
Case 6. Cervical Solitaire: Myelopathy....67
Case 7. Circumscribed Concretions: Cervical Corpectomy....75
Case 8. Forbidden Motion: Bamboo Spine....82
Case 9. Artery's New Companion: C6 Osteoblastoma....88
Case 10. Disproportionate Burgeoning: D1–D10 Scheuermann's Kyphosis....93
Case 11. Extradural Zeppelin: D3 to S1 Arachnoid Cyst....98
Case 12. Bone Devoured: L2 to L5 Gorham's Disease....103
Case 13. Terrible Tetrad: D10 to S1 Fixation....112
Case 14. The Silent Thief: D11 to L3 Osteoporotic Fracture....118

Case 15. Trivakra, the Blemish: Scoliosis 125
Case 16. Dual Disquiet: D11 to L4 Kyphosis 133
Case 17. Beating Around the Bush: Thoracic Disc Herniation 139
Case 18. Minimally Invasive Spine Surgery Meets Mets: Metastasis Minimally Invasive 145
Case 19. Terrible Trio: L2–L5 Degenerative Scoliosis 150
Case 20. Bishop of Spine: Oblique Lumbar Interbody Fusion 155
Case 21. Hard to Get Rid Off: Lumbar Calcified Disc 161
Case 22. Nothing is Permanent: Side-to-side Redo Fixation 166
Case 23. Keyhole Surgery: Endoscopic Discectomy 174
Case 24. Warped Aborning: L4–L5–S1 Distorted Anatomy 180
Case 25. Slithering Foundation: High-grade Listhesis 185
Case 26. Apodictic Dislodgment: Delta Fixation 190
Case 27. The Herculean Harbor: Redo L2 to S2 Fixation 196
Case 28. Congenital, Conjoint, Conundrum: Sacral Agenesis 201
Case 29. Areflexia: Sacral Chordoma 207
Case 30. Sequential Souvenir: Tandem Stenosis 213
Case 31. Tackled in One Go: Multiregional Spinal Stenosis 222
Case 32. Diagnostic Dilemma: Popliteal Schwannoma 227
Case 33. Capsized Tail: Coccyx 233

SECTION 3

PARADOX AND CAVEATS, MURPHY'S LAW, QUOTES FROM STAVYANS 239

SECTION 4

THE INSTITUTE 247

Index *259*

Abbreviations

ACCF	:	Anterior cervical corpectomy and fusion
ACDF	:	Anterior cervical discectomy and fusion
AI	:	Artificial intelligence
ALARA	:	As low as reasonably achievable
ASAP	:	As soon as possible
B/L	:	Bilateral
BIS	:	Bispectral index
BMI	:	Body mass index
CT	:	Computed tomography
DRA	:	Dynamic reference array
FESS	:	Fully endoscopic spine surgery
GCT	:	Giant cell tumor
IONM	:	Intraoperative neuromonitoring
IOTSS	:	Integrated Operation Theater Spine Suite
JOA	:	Japanese Orthopedic Association
LECA	:	Lateral ExtraCavitatory Approach
MDCT	:	Multi-dimensional computed tomography
MISS	:	Minimally invasive spine surgery
mJOA	:	Modified Japanese Orthopaedic Assocation
MRC	:	Medical Research Council
MRI	:	Magnetic resonance imaging
MRSS	:	Multiregional spinal stenosis
NDI	:	Neck disability index
OCF	:	Occipito-cervical fusion
OLF	:	Ossified ligamentum flavum
OPLL	:	Ossified posterior longitudinal ligament
SSEP	:	Somatosensory evoked potential
SSHRI	:	Stavya Spine Hospital and Research Institute
TcMEP	:	Transcranial motor-evoked potential
TDP	:	Thoracic disc prolapses
TDR	:	Total disc replacement
TIVA	:	Total intravenous anesthesia
TLIF	:	Transforaminal lumbar interbody fusion
TOF	:	Train of four
UBS	:	Ultrasonic bone scalpel
UTI	:	Urinary tract infection
VAS	:	Visual analog scale

Chapter 3

Navigation in Spine Surgery

INTRODUCTION

The integration of navigation and computed tomography (CT) scan is a true example of a perfectly fitting puzzle pieces. These machines together work in sync and seem like poetry in motion. These gadgets have changed the medical practice and improved patient safety and accuracy.

Navigating screws **(Fig. 1)** reduce the chances of implant malpositioning and also helps in planing spinal osteotomies. In a navigation-assisted surgery, the CT scan is uploaded into the navigation machine and gleons help us guide our screws to perfection. There are special integrated instruments (factory calibrated) and technology which helps us have a real time picture of the direction, diameter, angulation, and length of the screw and cage placement.



Fig. 1: A senior consultant at Stavya, performing oblique lateral interbody fusion (OLIF). The small balls visible on the instruments are known as gleons, which communicate with the infrared camera or sensors on the navigation system.

COMPONENTS

Broadly, there are two parts of any navigation system—an image acquisition unit and a referencing system.

The function of the image acquisition unit is to obtain high-resolution images of the target area. Earlier these images were obtained preoperatively. But now with the help of three-dimensional (3D) CT scan and surgical navigation system, these images are acquired intraoperatively. Interaction with surgical navigation system through two large high-definition touch screens (surgeon's and technician's screen) provides ultimate flexibility in interacting with the system.

The crucial component is the referencing system. It analyzes the real-time movement of the surgical instruments, relative to the patient's spine. It is then projected on the computer screen, correlates with previously acquired images, allowing the surgeon to know the position of implants and devices with higher accuracy.

JAYPEE BROTHERS

The referencing system comprises a dynamic reference array (DRA), gleons (sterile reflective spheres) **(Fig. 2)** and a tracking system **(Fig. 3)**. It is mandatory to attach the dynamic reference array to a fixed anatomic structure on the patient's spine before acquiring the image with 3D CT scan. This synchronizes the virtual images with the anatomic landmarks. The distance of the DRA to the area of interest should be kept optimum for better accuracy. Similarly, there should not be significant movement of the DRA during the surgery; otherwise, the navigation accuracy will be low. The DRA comprises of an attachment frame for four or more spheres known as gleons. Sterile spheres reflect infrared light emitted by the tracking camera (another component of the referencing system), which provides the location of the reference frame. These spheres are also attached to the surgical instruments. Their position concerning the patient is also projected on the images. The camera's field of view defines the navigation field, and any interruptions will reduce navigation accuracy.



Fig. 2: Gleons—these are small round balls, used on top of the instruments for navigating screws, and using various other instruments with the navigation system.

Gleons are mounted on navigation trackers with specific geometry, different for each tracker. The navigation infrared camera tracks these gleons with respect to the tip of the instrument, navigating instrument in real time.

The last component of the referencing system is the tracking system which uses an optical infrared camera to track the light reflected from the gleons (spheres) on the patient reference frame and the surgical instruments. An emitter in the center of the tracking system and at both sides provides 3D position data of the surgical instrument



Fig. 3: The upper part of the image shows reference frames in green, orange, and silver colors. The instruments are factory calibrated, awl probe, tap and screw driver.

JAYPEE BROTHERS

concerning the reference frame. The camera should have a clear line of sight between the spheres; else, the navigational accuracy will be reduced. Once all the components are well understood, the procedure becomes relatively easy to operate.

TECHNIQUE

The first step in using 3D CT scan and navigation is registration of the virtual images with the anatomical ones **(Fig. 4)**. The reference frame is attached to either a spinous process or a fixed bony landmark near the area of interest. Next, the 3D CT scan is brought near the area of interest for scanning the target area. The 3D CT scan machine has built-in series of reference frames. It is mandatory that both the patient and the scan machine reference frames are visualized simultaneously by the tracking camera, so the images acquired by the 3D CT scan machine are directly transferred to the navigation system for spatial orientation. After the image acquisition and automatic registration procedure is completed, the surgical instrumentations with sterile spheres are registered to the navigation tracker.

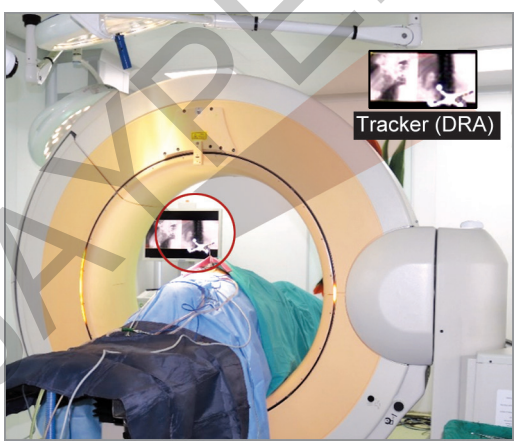

Fig. 4: The reference frame is visible on the patient, with mobile CT scan machine acquiring a 3D image for navigation.

The instruments are placed on coplanar fixed positions (predecided) on the patient reference frame. Once all the devices are registered, their movement in real-time can be projected on the 27-inch HD monitor screen.

The accuracy of the instruments is checked by placing them on known anatomic landmarks such as the spinous process, laminae, transverse process, etc. When the patient reference frame is kept appropriately fixed, the accuracy of the navigation is close to 1 mm. While placing different instruments on the spine landmarks, various projections in the axial, coronal, and sagittal images are visualized on the screen, thus accurately guiding the placement of implants.

Once the instrumentation is complete, the 3D CT scan machine can acquire the position of the implants in the spine. Radiation is much less as the scan machine offers a low-dose mode. It works on the ALARA (As Low as Reasonably Achievable) algorithm. The dose is around 3.21 mSv per spin for the lumbar spine, 1.88 mSv for the chest, and 0.33 mSv for the head. The 3D CT scan machine generates a dosing profile for each patient after the procedure for record-keeping.

COLLABORATION

- Patient registration with 3D CT scan—imaging system.
- Analog and digital output—allowing integration.
- Wireless connectivity to hospital and medical devices.

OTHER USES

- This frame can be placed on burrs, power drills, and ultrasonic bone scalpels too. This facilitates bony procedures such as spinal osteotomy procedures with accurately predicting the position of various instruments.

JAYPEE BROTHERS

- Placement of pedicle screws in thin dysplastic pedicles such as in scoliosis/listhesis is made significantly easier with this system. Reducing the rates of breach—similar application is found in the instrumentation of the craniocervical junction where congenital bony anomalies are frequently seen. The careful positioning of implants requires avoiding the spinal cord medially and vertebral artery laterally.
- It is of great use in MISS (minimally invasive spine surgery) surgeries with zero radiation to the operating team.
- We can use third party registration frame for nonfactory calibrated gadgets such as the bone scalpel. These instruments need accurate registration in the navigation system and should be used cautiously.

ADVANTAGES

This technology significantly facilitates the procedure and provides safer outcomes for patients.

- Symbiosis with another intraoperative imaging system—magnetic resonance imaging (MRI) and CT to orient surgeons with 3D images of patient's anatomy.
- Allowing one to create, store, and simulate progression along with one or more surgical trajectories.

LIMITATIONS OF TECHNOLOGY

- The operating protocol should be well defined and staff trained for it.
- If the surgeon follows a biased virtual image, any unknown deviation from routine usage protocol might injure the nearby neurovascular structure. Accuracy with the patient's anatomy needs to be confirmed repeatedly during the surgery. Since the image is static, movements of the patients after the image acquisition or movement of the dynamic reference array might lead to a false sense of safety during surgery which can lead to injury to vital structures.
- Technology comes at a higher cost. India being a developing country, the cost-benefit ratio needs to be justified. It adds to the cost of health care to the patient.
- Technology keeps upgrading, so it requires a regular update with regular consumption of monetary resources to procure the latest version and train technicians and operation theater (OT) personnel.
- Even with the use of all technologies, the rate of complications has not come down to absolute zero. Sometimes even a single complication after the use of technology would be disproportionately discussed and be frowned upon.
- There is a learning curve for adapting to new equipment. The duration of surgery increases in such cases, thereby increasing the overall complication rate. More unique the technology, the more time it takes for the surgeon to get familiar with it. Though eventually according to our experience of many years, we are able to reduce our surgical time significantly.

FUTURE DEVELOPMENT

With future technology, infrared detector machines will enable faster detection of gleons and ultimately decrease surgical time. With upgraded software, the better orientation of 3D scan can be visualized. In the future, its use in endoscopic surgeries and routine surgeries will decrease the surgical time and increase the accuracy of screw insertion. It will ultimately provide better results for patients.

"Integrated Tractography software allows us to view tracts while treating intracranial and intradural tumor/pathologies."

JAYPEE BROTHERS

detailed information on orthopedics books, visit our website www.jaypeebrothers.com, for detailed information on orthopedics books, visit our web

Stavya Spine's Thirty3

Technology and Spine Surgery

This book is for all medical professionals and especially for those who are involved in management of spinal ailments. Medicos who want to know about the advances integrated in the IOTSS (Integrated Operation Theater Spine Suite) to make spine surgeries safe.

Basic to advanced knowledge is shared by 4 sections and thirty3 case illustrations.

The book is written in 4 sections:

Section 1: It is about Enabling Technology (except Robot) and Integrated Operation Theater Spine Suite (IOTSS)

Section 2: Illustration of Thirty3 cases. These cases start from cervical (first vertebrae) and end to coccyx (last vertebrae). Each chapter starts with detailed history of patient followed with the treatment given explaining the use of technology.

Section 3: Paradox and Caveats with Murphy's law. This section explains the limitations and contradictory statements related to all the cases written in Section 2. It includes Murphy's law, how it influences in daily practice.

Section 4: It includes the information about the Institute and surgical members. The list of publications from Stavya team is highlighted.

Bharat R Dave MS MCh born in middle class family, son of school principal and brought up in small town, no big vision or dream in the eyes, just one moto "work hard and give 100% wherever you are". After getting good experience and exposure from England, he started his medical journey in Ahmedabad, Gujarat, India. Like many successful persons, he also struggled in the beginning of his journey. From down to dust, he ran from one hospital to another hospital and even outside Ahmedabad for operative spine care treatment, which was a stigma at that time. Patients were skeptical about this specialty work and even orthopedics and neurosurgeons also avoided spine surgery as a full-time career. The visionary Dr Bharat R Dave started with 313 sq feet small Spine Clinic in 1997 to change this thinking by pioneering spine surgery as a specialty. His sheer hard and smart work and perseverance, patients started accepting and understanding its obvious merits. Over the period of time, gradually his practice flourished and became a center of excellence in spine practice with high end and latest technologies. Because of his ethical and patient-centered practice, he is able to include latest spine technologies for surgeries. He keeps himself professionally renewing all the time through reading, writing, publications and serving as reviewer in medical journals as well as give training and mentoring almost 70 young professional orthopedic surgeons and 100 physiotherapists in spine care and spine surgery. He is beyond doubt a role model of simplicity, commitment to affordable healthcare and accepting and adopting new technologies in spine practice. "Be Human and do no harm" is his Moto.

Mirant B Dave MS (Ortho) is an avid educator and a gifted surgeon. Mastering various techniques in spine surgery, he has made a name for himself soon after joining the institute. He has earned the name BRD Jr after his father's name. He has presented many papers at international and national conferences. He has been an editor and a technology advisor for the current edition of this book. In the current era of robotics and artificial intelligence, he believes in welcoming advanced technology with open arms and adapting to every new technique and technology with enthusiasm.

Printed in India

Available at all medical bookstores
or buy online at www.jaypeebrothers.com

JAYPEE BROTHERS
Medical Publishers (P) Ltd.
EMCA House, 23/23-B, Ansari Road,
Daryaganj, New Delhi - 110 002, INDIA
www.jaypeebrothers.com

Join us on facebook.com/JaypeeMedicalPublishers

Shelving Recommendation
ORTHOPEDICS

ISBN 978-93-5696-191-3