sit our website www.jaypeebrothers.com, for detailed information on ophthalmology books, visit our website www.jaypeebrothers.com

JAYPEE

Recent Advances in OPHTHALMOLOGY

16

Editor
Nitin Nema

Contents

1. **Clinical Application, Limitations, and Future of Artificial Intelligence in Ophthalmology 1**
   Anthony Vipin Das, Yashas Goyal
2. **Artificial Intelligence in Refractive Errors 20**
   Purvi Bhagat, Pawan Garde
3. **Artificial Intelligence in Keratoconus 33**
   Shahnaz Anjum, Rajesh Sinha
4. **Advances in Refractive Surgery 43**
   Shreesha Kumar Kodavoor, Gitansha Sachdev, Gopal R, Ramamurthy D
5. **Optical Coherence Tomography in the Diagnosis of Glaucoma 80**
   Parul Ichhpujani, Obaidur Rehman, Sushmita Kaushik
6. **Pitfalls in the Diagnosis of Glaucoma by Artificial Intelligence 97**
   Mohana Sinnasamy, Murali Ariga, Nishanth Murali
7. **Optimizing Intraocular Lens Power Calculation in Eyes with Posterior Segment Diseases and Following Posterior Segment Surgery 107**
   Meena Chakrabarti, Arup Chakrabarti
8. **Management of Uveitic Cataract 118**
   Mohan Rajan, Arthi Mohankumar, Rakesh K
9. **Artificial Intelligence in Diabetic Retinopathy 132**
   Payal Naresh Shah, Divyansh Kailashchandra Mishra, Mahesh Shanmugam Palanivelu
10. **Artificial Intelligence in Retinopathy of Prematurity 151**
    Lingam Gopal, Arjun Bamel, Anand Vinekar
11. **Diagnosis of Retinal Detachment by Artificial Intelligence 174**
    Chaitra Jayadev, Aishwarya Joshi
12. **Artificial Intelligence in Age-related Macular Degeneration 182**
    Brughanya Subramanian, Chitralekha S Devishamani, Parveen Sen, Rajiv Raman

13. Multimodal Imaging in Macular Diseases 193
Giridhar Anantharaman, Kiran Chandran

14. Recent Advances in Optic Nerve Tumors 223
Dipankar Das, Obaidur Rehman, Sakshi Mishra, Madhusmita Mahapatra

15. Choroidal Metastasis 244
Kalpita Das, Raghulnadhan Ramanadhane

16. Artificial Intelligence in Neuro-ophthalmology 253
Hima Pendharkar, Rishabh Rathi

17. Updates in Artificial Intelligence in Ophthalmology 272
Ng Yu Ci Faye, Dinesh Visva Gunasekeran, Rupesh Agrawal, Gangadhara Sundar

Index 289

CHAPTER

4

Advances in Refractive Surgery

Shreesha Kumar Kodavoor, Gitansha Sachdev, Gopal R, Ramamurthy D

ABSTRACT

Refractive surgery remains an exciting and rapidly evolving field within ophthalmology. Extensive research has provided advancements and invaluable refinements in laser technology and diagnostic methods and tools to develop a safe and predictable treatment option for the entire gamut of refractive disorders.

Though laser in situ keratomileusis (LASIK) is the mainstay in refractive surgery and can be used in its various forms of laser vision surgeries or even combined with cataract surgery, presbyopic correction, and phakic intraocular lenses (IOLs), the refractive surgery has evolved beyond the traditional LASIK to advanced procedures such as small incision lenticule extraction (SMILE), Contoura vision, intracorneal implants and segments, phakic IOLs, and laser refractive cataract surgery with refractive lens exchange with advanced optics that provide more options in carefully selected patients.

We have techniques and technologies to suit practically all individual patients today. Possibilities with refractive surgery are mind-boggling. Selecting a particular type of procedure to suit a particular eye becomes the responsibility of a refractive surgeon and failure to do so can result in catastrophe.

Keywords: LASIK; Contoura vision; SMILE; phakic intraocular lens; Pentacam; excimer laser; femtosecond laser; microkeratome; bioptics.

INTRODUCTION

Today, refractive surgery has evolved beyond the traditional laser refractive surgery termed laser in situ keratomileusis (LASIK) to advanced procedures such as small incision lenticule extraction (SMILE), Contoura vision, intracorneal implants, and phakic intraocular implants. Laser refractive cataract surgery with refractive lens exchange with advanced optics provides more options in carefully selected patients. The advent of the femtosecond (FS) laser provides unparalleled safety, precision, and predictability. An intensive evaluation is mandatory to assess the ocular status and determine

JAYPEE BROTHERS

the ideal surgical procedure. Additionally, complications must be managed with utmost caution and care to prevent loss of corrected visual acuity.

EXCIMER LASER

The excimer laser system was first developed in 1970 and more than a decade later used in the human eye to perform corneal photoablation.[1]

Principle

The excimer laser system works on the principle of ablative photodecomposition using argon fluoride (ArF) as the essential gas mixture. When electric energy is applied, the argon molecule is stimulated to form an "excited dimer" or "excimer." This unstable dimer reverts quickly to its original state, emitting a charged photon. The charged photon has high energy, enabling breakdown of collagen bonds or "photoablation." It is a class IV laser with a near X-ray wavelength of 193 nm. This affords low tissue penetration, thereby allowing the laser to work only directly on the intended surface, unlike the FS laser. Thus, the excimer laser requires removal of the epithelium in photorefractive keratectomy (PRK) or creation of a flap in LASIK to gain direct access to the underlying stromal surface.

For myopic correction, greater ablation is carried out in the center of the cornea to flatten it, whereas in hyperopia, a doughnut-shaped mid-peripheral ablation is required, allowing incoming light to be refracted strongly when meeting the steeper flanks of the dome. Astigmatic correction is along one particular meridian. The ablation protocol is determined specifically for each individual's refractive error and calculated by a software program in the laser system. The depth of tissue ablation is calculated by Munnerlyn equation which in a simplified way states that:

$$\text{Ablation depth } (\mu m) = \frac{\text{Optic zone}^2 \times \text{Dioptric correction required}}{3}$$

Hence, the extent of stromal tissue ablation is dependent on the refractive error corrected and the optic zone diameter.

All laser systems come with their recommended list of safety precautions. Odors and fumes interfere with laser function and should not be allowed inside the laser room. The gas cylinders used in the laser have fluorine, argon, helium, and neon. Fluorine is a highly toxic gas with a sharp odor that causes irritation to nose, eyes, and throat at extremely low concentrations. Excimer lasers use <0.25% concentration of fluorine. Argon, helium, and neon are inert nontoxic gases with no color, odor, or taste.

Strict environmental conditions need to be maintained in the laser suite for proper functioning of the laser system. Temperature range should not fluctuate beyond 60–80°F and relative humidity should be between 35 and 65%.

JAYPEE BROTHERS

BOX 1: Types of excimer laser.

- *Broad beam laser:*
  - Large diameter ~ 7 mm
  - High-energy per pulse
  - Lesser pulses required
  - Lower repetition rate
  - Correction may be limited as central islands of cornea may be subtotally treated, secondary to plume of ejected particles shadowing the underlying tissue
- *Flying spot laser **(Fig. 1)**:*
  - Smaller diameter ~ 0.5–2 mm
  - Higher repetition rate
  - Higher frequency
  - *Smoother stromal bed:* Since the laser shots are distributed in placement, it allows adequate time for plume dissipation before the next laser shot is fired on the same area
- Slit scanning laser

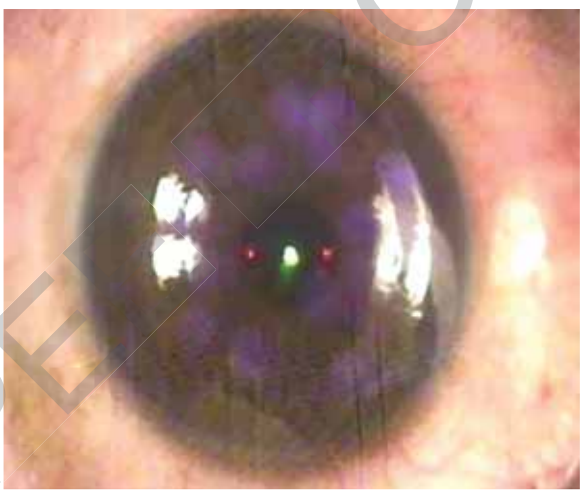

Fig. 1: Flying spot placement of an excimer laser.

Types of Excimer Laser

Types of excimer laser are given in **Box 1**.

Types of Ablation Profiles

Refractive corrections are engineered on the anterior corneal surface as the cornea is responsible for two-thirds of the refractive power of the eye. Additionally, the air-tear film anterior cornea demonstrates the greatest change in refractive index; therefore, any treatment administered here

JAYPEE BROTHERS

gives maximum refractive results. Types of ablation profiles can be broadly classified into the following:

- *Conventional ablation:* It entails the correction of lower-order aberrations (defocus or sphere and astigmatism or cylinder). However, this induces spherical aberrations secondary to peripheral loss of fluence. As the laser beam spot peripherally is more oblique as compared to circular in the center, a resultant loss of laser energy causes reduced effect in the periphery. This induces greater flattening centrally, making the corneal shape oblate, thereby inducing spherical aberrations.
- *Wavefront-guided* (*WFG*) *ablation:* This combines the conventional ablation (treatment of lower-order aberrations) with treatment of preexisting higher-order aberrations (HOAs) (coma, trefoil, and spherical aberrations). However, it does not compensate for the treatment-induced spherical aberrations.
- *Wavefront-optimized* (*WFO*) *ablation:* This compensates for loss of fluence by increasing the number of peripheral pulses. This reduces the treatment-induced spherical aberrations, which provides higher quality of vision especially in mesopic conditions. WFO ablation additionally treats preoperative lower-order aberrations but does not treat preexisting HOAs.
- *Topo-guided ablation profile:* It is a combination of WFO ablation along with treatment of preexisting corneal HOAs.

Eye Tracking in Excimer Laser

With the advent of excimer laser treatments, accurate ocular alignments are important to optimize refractive results. The pupillary center serves as the anatomical landmark for the centration of the laser ablation. Any misalignment of the ablation profile due to shifting of the pupillary center or cyclotorsion can result in undercorrection of existing aberrations or induction of newer ones. Hence, the need for an efficient eye tracking to optimize the placement of laser pulses arises.[2]

The tracking system is based on iris registration and includes both passive and active tracking. The system includes an active x-y and a passive z tracker in addition to a rotational eye tracker. The assessment is based on the difference in the position of the iris landmarks between the preoperative and intraoperative images. These images are compared using infrared cameras.

Iris Registration

An infrared camera captures the characteristic iris landmarks in the sitting position during the preoperative measurement. Prior to laser ablation, another infrared image is acquired in supine position. The difference between the two images determines the extent of cyclotorsion and pupil centroid shift,

JAYPEE BROTHERS

realigning the treatment plan accordingly. Iris registration is a static process and does not actively track eye movements during the excimer ablation.

Active Tracking

The incorporation of iris registration allows static eye movement compensation. However, active cyclotorsion and eye movements have been noted during laser ablation. Active tracking utilizes an image of the iris taken prior to ablation and measures subsequent changes to determine the intraoperative eye movement rather than using the preoperative image. Dynamic trackers reduce enhancement rates. The eye tracker locks onto the patient's iris just before the treatment and monitors the pattern throughout the procedure. The direction of the laser pulses is automatically adjusted, based on the rotation of the iris pattern. Newer advances in eye-tracking systems enable the compensation of subtler movements such as pupil centroid shift and cyclotorsion.

Cyclotorsion Compensation

While the preoperative wavefront and topographic data are collected in the sitting position, the laser ablation is delivered in the supine position. The intraoperative cyclotorsion can serve as a potential source of error during the laser treatment, especially in errors that are not radially symmetrical such as astigmatism, coma, and trefoil.[3] Intraoperative cyclotorsion can result due to a variety of factors including rotation of the head and body, distortion of globe due to placement of the eyelid speculum, unmasking of cyclophoria, and dynamic eye movements. The extent of cyclorotation is typically between 2° and 7°. Theoretically, a 5° misalignment results in 17% less effect in astigmatic reduction and a misalignment of 15° can result in an under-correction of up to 50% of astigmatism.[2]

Cyclotorsion is divided into two components: (1) Static which comprises the difference between the supine and prone position; (2) Dynamic which comprises further rotational movements during ablation treatment.

Pupil Centroid Shift

An important consideration for the centration of the laser ablation is the position of the pupil centroid. The preoperative wavefront data is captured under dim illumination, while the illumination increases during laser ablation.[4] As the lighting conditions vary, the diameter of the pupil fluctuates with a corresponding pupil centroid shift **(Fig. 2)**. Since the laser ablation is centered around the pupil centroid, any shift can lead to a decentered ablation with subsequent visual symptoms such as glare, haloes, and starbursts. Decentrations as small as 0.2 mm significantly increase the HOAs after LASIK. Theoretically, if the ablation is completed without correction

JAYPEE BROTHERS

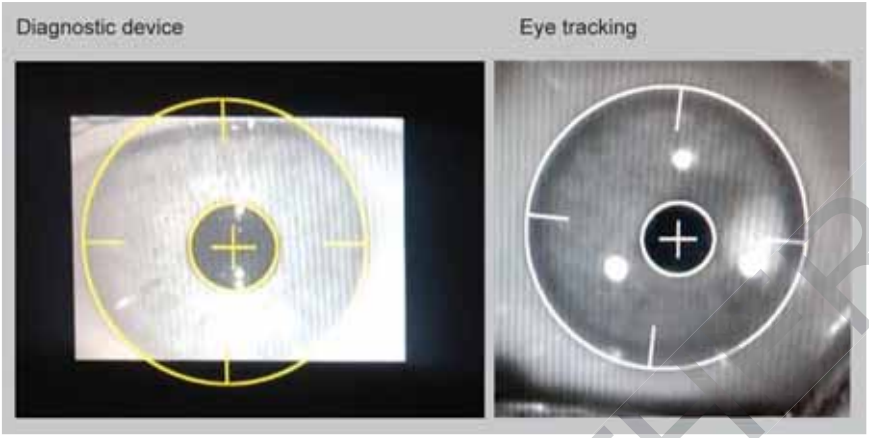

Fig. 2: Registration of iris landmarks to determine the extent of cyclotorsion and pupil centroid shift (WaveLight® Ex500 Excimer Laser, Alcon). Note a nasal shift of the pupil centroid and a cyclotorsion of –6°.

of pupil centroid shift, >40% of the patients would present with increased postoperative HOAs and reduced quality of vision.[5]

PHOTOREFRACTIVE KERATECTOMY OR SURFACE ABLATION

Photorefractive keratectomy or surface ablation entails the removal of the corneal epithelium followed by excimer laser stromal ablation to offer a refractive correction.

Various techniques may be employed for the removal of corneal epithelium including laser in transepithelial PRK **(Figs. 3A to D)**, alcohol in laser epithelial keratomileusis (LASEK), microkeratome in epi-LASIK **(Figs. 4A to D)**, and mechanical debridement in surface ablation.

Several methods have been postulated for epithelial removal in surface ablation corrections. No differences in refractive outcomes and haze have been demonstrated between various techniques including LASEK, epi-LASIK, and transepithelial PRK in myopia. However, faster re-epithelization and lower pain may be associated with the transepithelial PRK approach.[6]

Advantages of Photorefractive Keratectomy

- *Flapless procedure:* Flap-associated complications including flap striae and epithelial ingrowth are not associated with this procedure.
- *Biomechanical superiority:* PRK offers biomechanical superiority over SMILE and LASIK. This is secondary to two factors: Variable strength of the collagen lamellae and impact of penetrating cuts. The cohesive tensile strength of the cornea decreases from anterior to posterior cornea within

JAYPEE BROTHERS

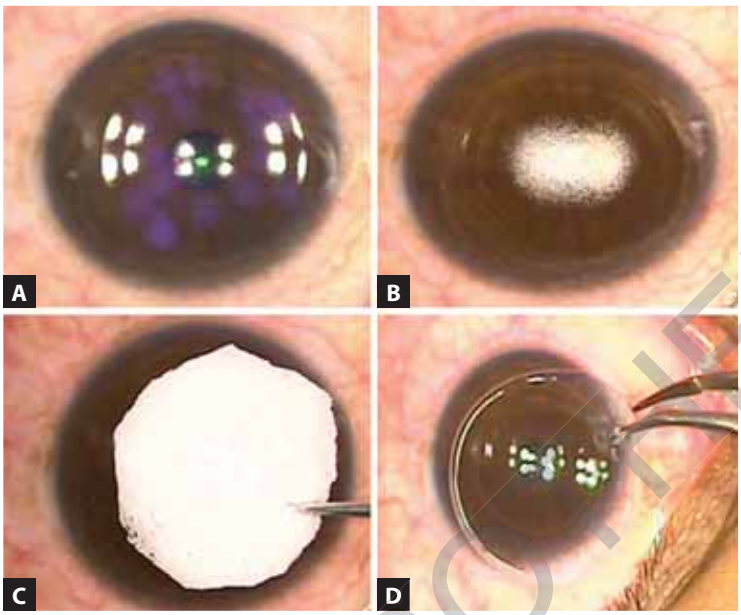

Figs. 3A to D: Steps of transepithelial photorefractive keratectomy (PRK): (A) Epithelial removed using phototherapeutic keratectomy (PTK) mode; (B) Excimer laser ablation is performed on the stromal bed; (C) Mitomycin C (MMC) 0.02% placed for 30 seconds; (D) Bandage contact lens placed after thorough saline wash.

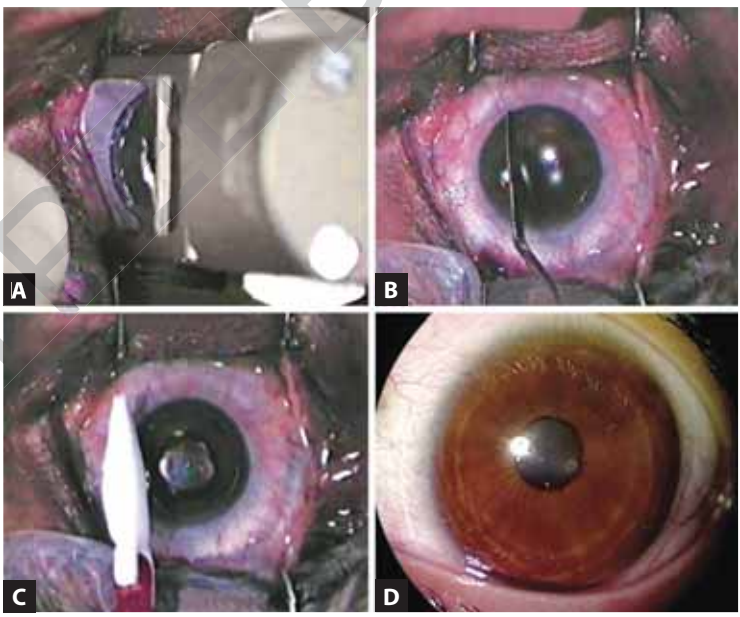

Figs. 4A to D: Steps of Epi-LASIK: (A) Epikeratome creates an epithelial flap; (B) Flap is subsequently reflected; (C) Excimer laser ablation is performed on the stromal bed and epithelial flap is reposited; (D) Postoperative image with bandage contact lens in situ.

JAYPEE BROTHERS

the central region. As there is a greater change in the anterior corneal stroma in LASIK vis-à-vis PRK, the biomechanical strength of collagen fibers following PRK is greater.

The vertical cuts have a greater biomechanical effect in comparison to stromal ablation for refractive correction. As PRK does not involve any cuts, unlike the flap cut and corneal side cut, it induces lower biomechanical weakness in comparison to LASIK and SMILE.

- *Thinner corneas:* PRK allows treatment in thinner corneas between 475 and 490 µm. However, the final corneal thickness post-ablation should not be reduced beyond 400 µm.
- *Topo-guided approach for keratoconic eyes:* Topography-guided transepithelial PRK in combination with corneal collagen cross-linking is used in mild-to-moderate cases of keratoconus will well-centered cones.[7]

TOPOGRAPHY-GUIDED TREATMENT FOR KERATOCONUS

Keratoconus is a corneal ectasia characterized by progressive steepening and thinning of corneal tissue. The ectasia can lead to refractive error and degradation of visual quality. Corneal cross-linking (CXL) is recommended for stopping the progression of keratoconus.[8] The efficacy of CXL for arresting disease progression in keratectasia, both idiopathic and iatrogenic, is well established.[9] While cross-linking achieves disease stability, corneal surface irregularities and aberrations remain untreated requiring rigid gas permeable (RGP) contact lens postoperatively. RGP also brings with it the unique challenges including reduced patient comfort, poor fit in case of increased flattening, or haze caused by cross-linking.[10] The advent of topography-guided excimer laser ablation with concomitant CXL allows the reduction of corneal anterior surface irregularities along with disease stability. Kanellopoulos and Binder first described the novel application of topography-guided ablation in a cross-linked eye to improve visual acuity. Following this, a report of two cases exhibiting stability for over a period of 30 months was published.[11]

The same author then subsequently went on to describe the stability and anterior surface normalization in a larger cohort of 232 eyes. These results were then replicated by other groups as well, demonstrating the safety and efficacy of the treatment over a 2-year follow-up period.[12] The subsequent discussion entails a comprehensive overview of the preoperative requisites, treatment parameters, and visual outcomes of this technique. Keratometric flattening is seen in most corneas undergoing CXL. However, conventional uniform intensity CXL does not reduce HOAs significantly. In contrast, topography-guided ablation of keratoconus improves the visual acuity and reduces the HOAs by regularizing the anterior corneal surface.[13] The ablation is calculated using either the anterior corneal surface features

JAYPEE BROTHERS

(topography-guided treatment) or the total ocular wavefront (WFG). The superiority of visual outcomes of corneal aberration-guided ablation compared to CXL is known from multiple studies.[14]

The conventional topography-guided PRK (TGPRK) ablation profile is centered at the geometric center of the cornea and treats an optical diameter ranging from 5.5 to 6.5 mm. A significant amount of tissue is removed at and around the region of steepest anterior curvature (the cone). As a rule of thumb, the maximum stromal ablation depth is limited to 50 µm. Further, the location of the cone relative to the geometric center can impact the visual acuity outcomes after TGPRK.[15] A centered transepithelial phototherapeutic keratectomy (PTK) can also deliver patient-specific regularization of the corneal surface.[16] However, a centered PTK also causes unnecessary laser ablation of potentially normal regions of the keratoconic cornea. In this study, 1-year outcomes of a tissue-conserving customized ablation approach were analyzed. This approach, named the topography-assisted removal of epithelium, was performed at the region of the "cone." A decentered elliptical shape "single-step" PTK [topography-assisted phototherapeutic keratectomy (TPTK)], centered at the steepest tangential curvature point, was performed. This was followed by manual removal of the epithelium up to a diameter of 8 mm and accelerated CXL of the entire deepithelialized zone.[17] The outcomes of TPTK were comparable with the outcomes of patients who underwent TGPRK and accelerated CXL.

LASER IN SITU KERATOMILEUSIS

Laser in situ keratomileusis or LASIK was originally conceived by Dr José I Barraquer in 1949 where he created a free cornea flap, froze it, sculpted the undersurface on a cryolathe, and sutured it back to the cornea. Then came the advent of automated lamellar keratoplasty, which entailed the creation of a flap followed by a disc of stromal tissue excision using a microkeratome. Burrato and Pallikaris were the first to combine the microkeratome flap with subsequent excimer laser ablation. Subsequent modification in this technique led to the current form of LASIK, wherein a microkeratome blade is used to create a hinged corneal flap. This is subsequently raised, the stroma ablated with excimer laser, and the flap is then reposited back.

Laser in situ keratomileusis has become increasingly popular since 1995 and is now one of the most commonly performed refractive procedures to correct myopia, hyperopia, and astigmatism. It is also a modality of treatment for residual refractive errors after radial keratotomy and cataract surgery.

The basic instruments required for LASIK procedure include a microkeratome or FS laser for flap creation and excimer laser unit for stromal bed ablation. The details regarding excimer laser have already been covered in depth under PRK.

JAYPEE BROTHERS

Microkeratome Laser In Situ Keratomileusis

A microkeratome consists of a fine oscillating blade which can cut through the cornea at predetermined depths to form a smooth flap. The adjustable parameters allow the surgeon to decide the depth of the corneal flap with an accuracy of 10 μm. The assembly, operation, and maintenance of the microkeratome system are crucial to ensure accurate and predictable resections of the corneal tissue. The microkeratome head includes a pneumatic suction ring which elevates the intraocular pressure to above 65 mm Hg and allows stable fixation of the globe during flap creation. The surface of the suction ring has dove-tailed grooves over which the microkeratome head is placed. The surgeon-controlled foot-pedal activates the motor allowing the blade to advance forward till the ideal hinge is achieved, after which it is reversed, and the microkeratome head and suction ring removed. The flap is subsequently raised followed by excimer laser ablation of the stromal bed **(Figs. 5A to C)**.

Femtosecond Laser In Situ Keratomileusis

Principle: The FS laser is a solid-state neodymium glass laser with pulse duration in the FS range (10^{-15} seconds). The wavelength falls in the

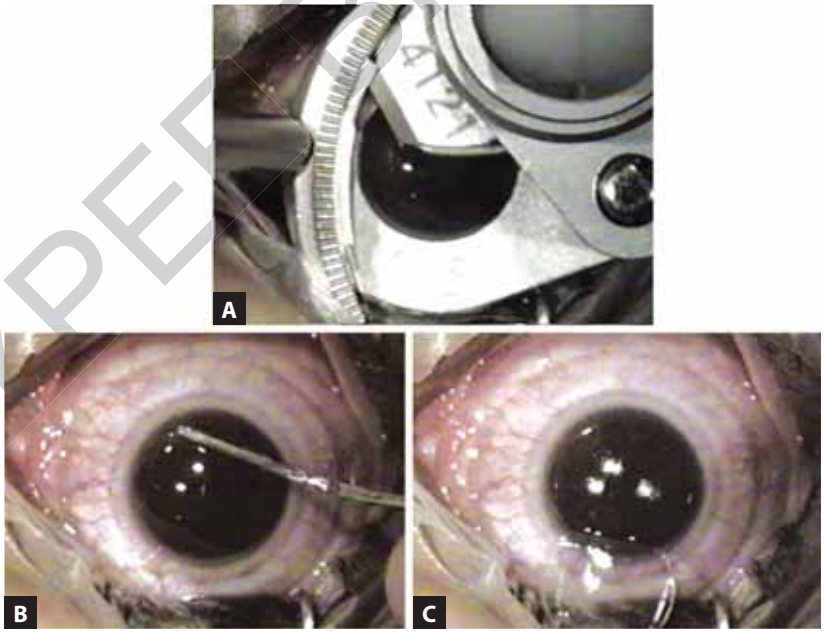

Figs. 5A to C: Steps of microkeratome laser in situ keratomileusis (LASIK): (A) Microkeratome head is placed on the suction ring; subsequent forward and reverse movement allows creation of a flap; (B) Flap is subsequently raised; (C) Underlying stroma is treated with excimer laser ablation.

JAYPEE BROTHERS

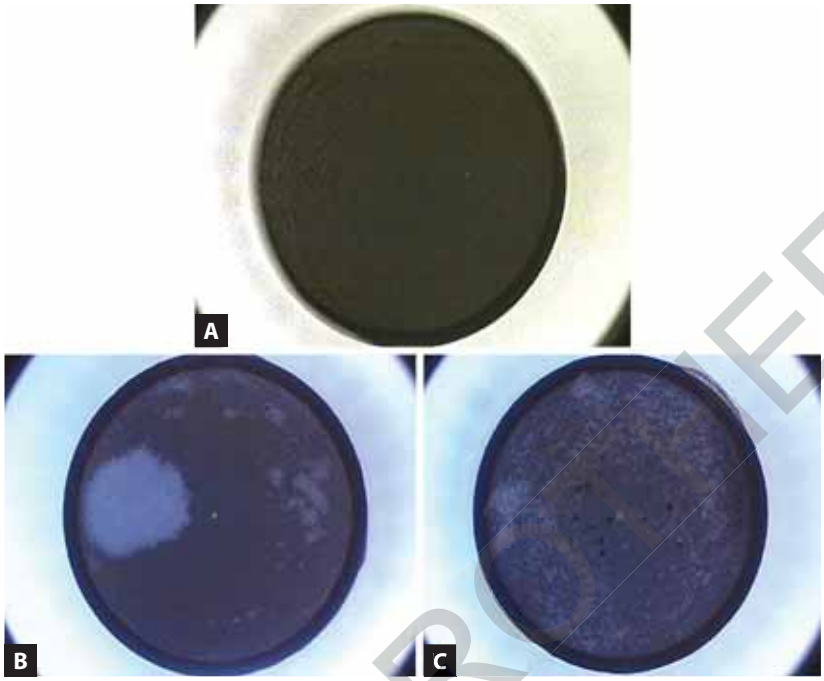

Figs. 6A to C: (A) Ideal opaque bubble layer (OBL); (B) High-energy OBL; (C) Low-energy OBL.

near-infrared range (1,053 nm). The FS laser can form precise cuts with minimum collateral damage by a process called *photodisruption*. The process begins with a sequence of laser pulses applied at a specific depth within the cornea in a predetermined pattern. The photon excites bound electrons by transmitting energy as heat, freeing them and initiating a vaporization cascade or microplasma formation. The microplasma expands to form cavitation bubbles, cleaving the tissue plane. Once the expansion stops, the cavitation bubbles collapse, emitting acoustic waves.

The following components of the FS procedure can be used to guide the surgeon in the process of optimization:[18]

Pattern of opaque bubble layer: The opaque bubble layer (OBL) is a collection of gas bubbles in the intralamellar spaces of the cornea **(Figs. 6A to C)**. OBL spontaneously clears in around 30–45 minutes. Predisposing factors for increased OBL formation include older patients and smaller and steeper corneas. The nature of the OBL allows determination of the laser energy and subsequent optimization of energy parameters.

In *OBL, secondary to high energy*, higher energy results in the formation of larger cavitation bubbles, wherein the incoming laser pulse will fall within the boundaries of the previously formed pulse (ideally the new pulse should

JAYPEE BROTHERS

fall adjacent to the previous pulse). Rather than vaporizing tissue, the new pulse will simply transfer heat to the existing cavitation bubble, increasing its size and causing a thicker OBL.

In OBL, secondary to low energy, small microplasma bubbles prevent easy coalescence during expansion, resulting in thick tissue bridges. Instead, the expanding bubbles may force the collagen around them apart, resulting in secondary bubbles.[19]

Quality of dissection

Postoperative findings: An increased incidence of diffuse lamellar keratitis (DLK) is associated with high-energy settings.

Laser Settings for Flap Creation

Laser settings for flap creation are given in **Box 2**.

Procedure

The surgical steps of LASIK are highlighted in **Figures 7A to F**.

Advantages of FS-LASIK over microkeratome LASIK include the following:

- Precise size and depth of corneal flap, independent of corneal curvature, blade sharpness, and speed of microkeratome pass

BOX 2: Laser settings for flap creation.

- *Pocket parameters:*
  - A pocket prevents dense OBL formation by allowing excessive gas bubbles to exit from the flap. The pocket depth is usually lower than 50% of corneal thickness (220–250 µm) with an ideal width of 250 µm
  - Pocket formation is associated with flat applanation contact interface, wherein the applanation force on the cornea does not allow the OBL to spread out easily. Newer curved contact interface is not associated with pocket formation
- *Hinge parameters:* The hinge angle varies with the planned ablation zone. A large hinge angle reduces the exposed stromal bed, whereas a narrow hinge will provide an inadequate fulcrum for the flap. The hinge position is fashioned nasally or superiorly.
- *Flap bed parameters:* The laser delivery for the formation of the corneal flap cut may occur in one of the following patterns:
  - Raster pattern
  - *Centrifugal spiral:* In-outward
  - *Centripetal spiral:* Out-inward
- *Side cut parameters:* Steeper side cut angle allows easier flap reposition and decreases the incidence of epithelial ingrowth. Optimal laser delivery allows a smooth and even edge creation; inadequate energy results in uncut areas or peripheral tags while excessive energy increases the risk of postoperative DLK

(DLK: diffuse lamellar keratitis; OBL: opaque bubble layer)

JAYPEE BROTHERS

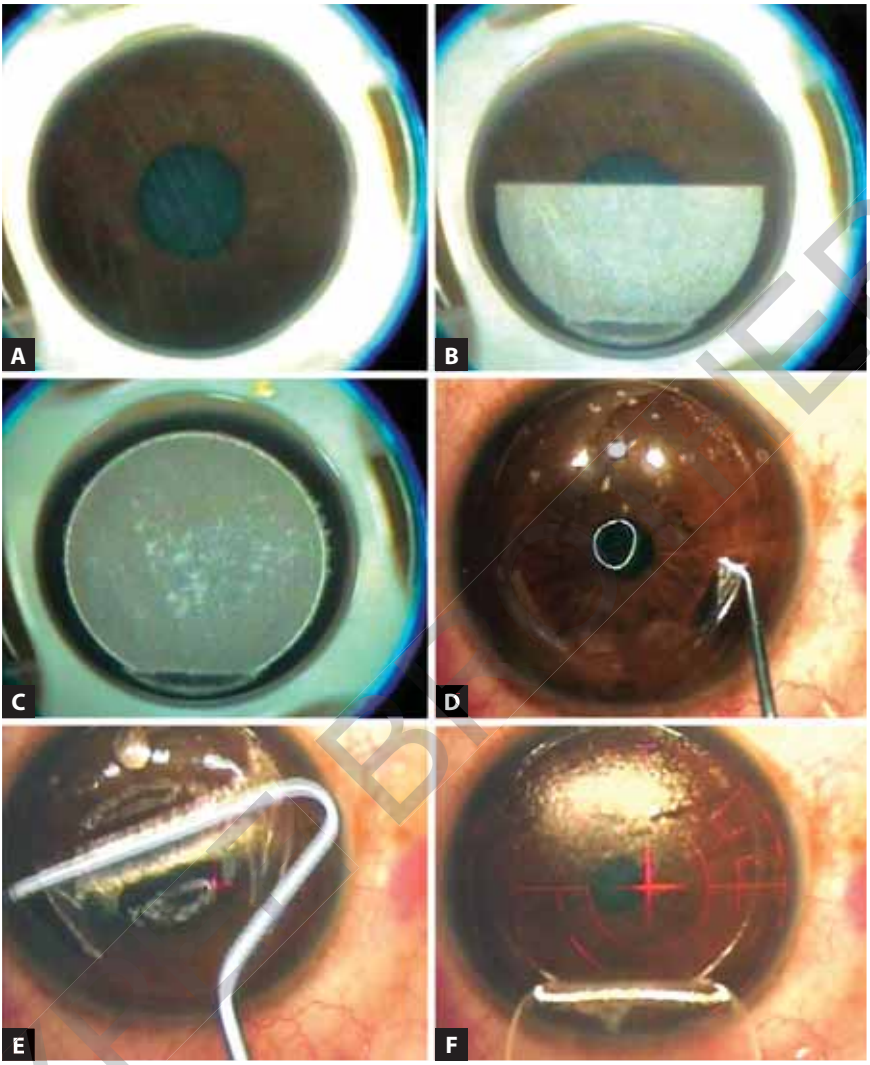

Figs. 7A to F: (A) Application of contact interface; (B) Pocket construction followed by flap cut; (C) Completion of flap cut and side cut; (D) Delineation of side cut; (E) Dissection of flap; and (F) Excimer laser stromal ablation.

- Reduced risk of complications such as free flaps, buttonhole formation, and incomplete and decentered flaps[20]
- Creation of a distinctive beveled edge flap which allows for precise repositioning and alignment, with reduced incidence of flap folds and epithelial ingrowth
- Ability to redock the eye and perform a double pass in the same sitting: The precision of the FS laser allows the flap cut to be repeated at the same depth in the event of a suction loss. The newly fired laser pulses percolate

JAYPEE BROTHERS

to the same depth as the previously formed cavitation bubbles, which offer a path of least resistance. On the contrary, an incomplete pass with a microkeratome LASIK would require the surgeon to abort the procedure as a repeat pass would risk the formation of a biplanar flap.[21]

Topography-guided Laser In Situ Keratomileusis

Currently, excimer laser systems designed to perform LASIK can correct astigmatism in different ways. The most basic method is to treat the measured refractive astigmatism based on the manifest refraction. A more advanced alternative is to use a WFG ablation that requires measuring the ocular wavefront of the entire eye and designing a specific ablation pattern to reduce or eliminate the ocular aberrations measured. Results with this approach appear only modestly better than treating the measured refractive astigmatism.[22] It is possible that the ability to accurately measure the ocular wavefront is still insufficient to provide a consistent beneficial effect. A third alternative is topography-guided LASIK **(Fig. 8)** that attempts to create a more uniform corneal surface to reduce aberrations while also correcting the refractive error. This technology was initially reserved to correct irregular astigmatism, although recent advances have led to it being used on virgin corneas as well, with promising results.[23] One of the topography-guided LASIK procedures (Contoura Vision, Alcon) has been shown to provide excellent visual outcomes in normal eyes without irregular astigmatism, with 93% of eyes achieving 20/20 or better uncorrected distance visual acuity (UDVA), 65% achieving 20/16 or better UDVA, and 34% achieving 20/12.5 or better UDVA 1-year postoperatively.[24] After Food and Drug Administration (FDA) approval of the topography-guided Contoura algorithm, it became more widely used in clinical settings.

Treatments were performed on eyes with a greater disparity between the manifest and topographic cylinder measurements. The challenge has been determining the best balance between using the topographic information and the refractive formation to provide an optimal correction for each eye. The topography-guided treatment profile is fixed by the Contoura software,



Fig. 8: Contoura workstation.

JAYPEE BROTHERS

for detailed information on ophthalmology books, visit our website www.jaypeebrothers.com, for detailed information on ophthalmolog

Recent Advances in OPHTHALMOLOGY 16

Salient Features

- Main theme is "Application of Artificial Intelligence in Ophthalmology"
- Focuses on clinical application of artificial intelligence in common ocular diseases.
- Contains an elaborate description on advances in refractive surgery
- Describes use of optical coherence tomography in diagnosis of glaucoma and pitfall in glaucoma diagnosis by artificial intelligence
- Includes review on management of uveitic cataract with excellent illustrations
- Provides a concise account of utility of multimodal imaging in macular disorders

Nitin Nema MS DNB is a Professor in the Department of Ophthalmology, Sri Aurobindo Medical College and Postgraduate Institute of Medical Sciences, Indore, Madhya Pradesh, India. He completed his postgraduation from the Department of Ophthalmology, Institute of Medical Sciences, Banaras Hindu University, Varanasi, Uttar Pradesh, India. He did his Fellowship in Vitreo-Retina from Aravind Eye Hospital and PG Institute, Madurai, Tamil Nadu, India. He gained clinical and research experience from the University of Illinois at Chicago and the University of Wisconsin at Madison in the United States of America. He was awarded GK Saraf Fellowship by the All India Ophthalmological Society to work on a project on Uveitis at Sankara Nethralaya, Chennai, Tamil Nadu, India. He received the prestigious Dr Mohan Lal Gold Medal for the best paper by the UP State Ophthalmological Society. He has authored a textbook, *Basic and Clinical Ophthalmology*, and two books (in collaboration with Dr HV Nema), *Anatomy of Eye and Adnexa* (3rd edition) and *Textbook of Ophthalmology* (6th edition). Moreover, he has co-edited 15 volumes of *Recent Advances in Ophthalmology* and 4 editions of *Diagnostic Procedures in Ophthalmology, Eye in Systemic Disorders, Ocular Tumors,* and *Genetics of Ocular Diseases*.

Printed in India

Available at all medical bookstores or buy online at www.jaypeebrothers.com

JAYPEE BROTHERS
Medical Publishers (P) Ltd.
EMCA House, 23/23-B, Ansari Road,
Daryaganj, New Delhi - 110 002, INDIA
www.jaypeebrothers.com

Join us on facebook.com/JaypeeMedicalPublishers

Shelving Recommendation
OPHTHALMOLOGY

ISBN 978-93-5696-196-8