ypeebrothers.com, for detailed information on nursing books, visit our website www.jaypeebrothers.com, for detailed information on nursing books

ECG *for* Nurses

From Basics to Bedside

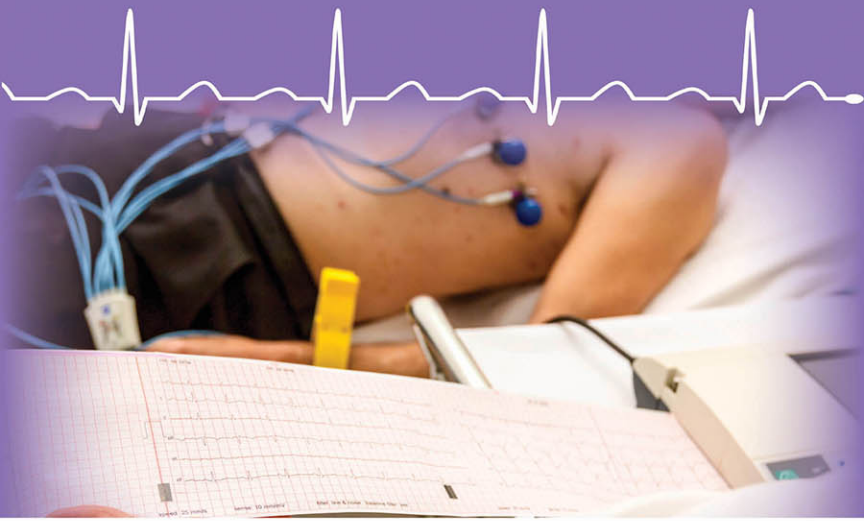

Archith Boloor

JAYPEE

Contents

1. Introduction, Anatomical and Physiological Consideration 1

- **The Cardiac Conduction System: *The Wiring System of the Heart* 1**
  - Origin and Spread of Cardiac Excitation 2
  - Impulse Conduction through the Heart 3
  - SA Node of Keith and Flack 4
  - Internodal Conduction Pathways 4
  - The AV Node 5
  - The Bundle of His and the Bundle Branches 5
  - Purkinje Fibers or Purkinje Cardiomyocytes 6
- **ECG Waveforms 6**
  - J Wave and U Wave 7

2. Technical Aspects of ECG 10

- What is an ECG? 10
- Utility of ECG: With ECGs We Can Identify 11
- **ECG Paper and Timing 11**
  - ECG Leads 13
  - Placement of Electrodes 15
  - Standard Sites Unavailable 15
  - Precordial Leads 18
  - Color Codes Given by AHA 18
  - Limb Leads Electrodes 20
  - Ambulatory ECG Monitoring 27
- **Procedure of Obtaining an ECG: A Step by Step Checklist 30**
  - Electrode Placement 31
  - Limb Electrode and Lead Placement 34
  - Recording the ECG Trace 35
  - Completion of Procedure 36

JAYPEE BROTHERS

3. Rate, Rhythm, and Axis 37

- **Reading 12-Lead ECG 37**
- **Rate 37**
  - Rule of 300 37
  - 6-Second Rule 39
  - For Irregular Rhythms 39
- **Rhythm 40**
  - Determine Regularity 40
  - Normal Sinus Rhythm—P Wave followed by QRS 41
  - Sinus Bradycardia 41
  - Sinus Tachycardia 42
  - Sinus Pause 42
  - Atrial Fibrillation 42
  - Atrial Flutter 43
  - Ventricular Fibrillation 43
  - Ventricular Tachycardia 43
  - Torsades de Pointes 44
  - Supraventricular Tachycardia 44
- **Axis 44**
  - The QRS Axis 44
  - Cardiac Axis 45
  - Determining the Axis 45
- **Cardiac Axis Thumb Rule 49**

4. Waves, Segments, and Intervals 51

- **Understanding ECG Waveform 51**
- **P Waves 52**
  - Assess the P waves 52
  - Abnormalities of P Wave 52
  - Other P Wave Abnormalities 54
- **PR Interval 54**
  - Atrioventricular Block 55
  - Short PR Interval 57
- **PR Segment 57**
- **QRS Complex 58**
- **Low Voltage QRS 60**
- **High Voltage QRS Complexes 61**
  - Bundle Branch Blocks 63
- **J Point 66**

JAYPEE BROTHERS



- **ST Segment 66**
- **T Wave 68**
- **QT-Interval 75**
- **U Wave 77**

5. ECG in Myocardial Infarction 78

- **Acute Coronary Syndrome 78**
- **Myocardial Infarction 78**
  - ECG Changes: Ischemia 79
  - ECG Changes: Injury 79
  - ECG Changes: Infarct 82
  - Evolving MI and Hallmarks of AMI 82
  - Reciprocal Changes 82
- **Localization of MI Based on ECG 82**
- **Non-ST Elevation Myocardial Infarction 85**
  - ECG manifestation 85
- **Complications of Acute Coronary Syndrome 86**

6. Tachyarrhythmia 88

- Narrow QRS Complex 89
- Wide QRS Complex 89
- **Narrow Complex Tachydysrhythmias 89**
  - Sinus Rhythm 89
  - Sinus Tachycardia 90
  - Atrial Flutter 91
  - Supraventricular Tachycardia 93
  - Atrial Fibrillation 95
  - Premature Ventricular Complex 97
  - Idioventricular Rhythm 99
  - Ventricular Tachycardia (VT) 101
  - Torsades de Pointes 104
  - Ventricular Fibrillation 105

7. Bradyarrhythmias 107

- **Sinus Bradycardia 107**
  - ECG Characteristics 107
  - Causes 107
  - Medical Management 107
- **Heart Block 108**
  - AV Block 108

JAYPEE BROTHERS

- Sinus Node Dysfunction (SND)/Sick Sinus Syndrome 111

8. Electrolytes and ECG 113

- **Potassium Disorders 113**
  - ECG Features of Hyperkalemia 113
  - ECG Features of Hypokalemia 117
- **Calcium Disorders 118**
  - ECG Features of Hypocalcemia 118
  - ECG Features of Hypercalcemia 118

9. Drugs and Miscellaneous 120

- **Digoxin Effect 120**

Miscellaneous 121

- **Pericarditis 121**
- **Pulmonary Embolism 121**
- **Pacing in ECG 123**
  - Atrial Pacing 123
  - Ventricular Pacing 123
  - Atrial and Ventricular Pacing 124

10. Review—Multiple Choice Questions 125

11. Practice ECGs 145

Appendices 183

Index 187

JAYPEE BROTHERS

CHAPTER 5

ECG in Myocardial Infarction

ACUTE CORONARY SYNDROME

An acute coronary syndrome (ACS) may include various clinical entities that involve some sort of ischemia or infarction. Specifically, acute coronary syndrome includes unstable angina, non-ST-segment elevation myocardial infarction (NSTEMI), and ST-segment elevation myocardial infarction (STEMI). Occasionally, NSTEMI is referred to as non-Q wave myocardial infarction and STEMI is referred to as Q wave myocardial infarction **(Fig. 1)**. This is because STEMI is almost always associated with a pathological Q wave.

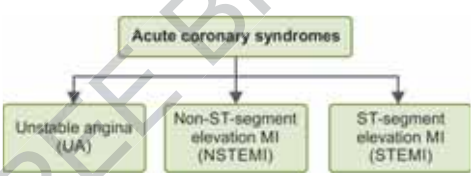

Fig. 1: Types of an acute coronary syndrome.
(MI: myocardial infarction)

MYOCARDIAL INFARCTION

For the patients to be diagnosed with myocardial infarction, they must have at least two of the following three criteria, according to the World Health Organization (WHO):

1. Clinical history of chest discomfort consistent with ischemia such as crushing chest pain
2. An elevation of cardiac markers in the blood (troponin-I, CK-MB, myoglobin)
3. Characteristic changes on electrocardiographic tracings taken serially

JAYPEE BROTHERS

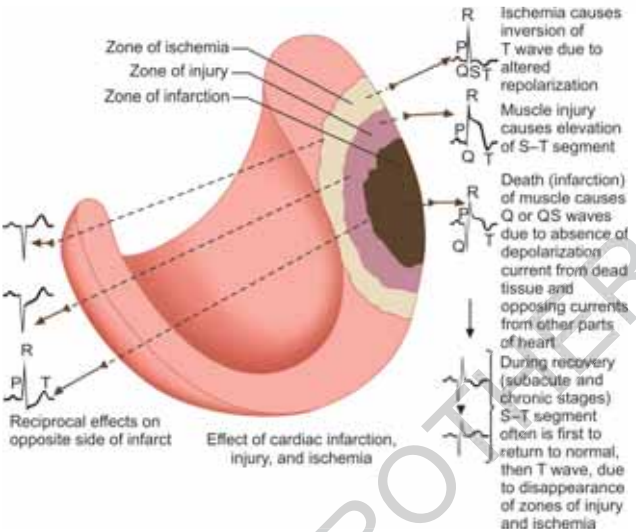

Fig. 2: ECG changes due to MI.

Recognition of infarction on the ECG relies on the detection of morphologic changes (i.e., changes in shape) of the QRS complex, the T-wave, and the ST-segment. These changes occur in relation to certain events during the infarction.

Figure 2 shows the ECG changes due to STEMI that often occur in a predictable pattern. The ECG changes appear only in leads looking at the infarct site. These changes are referred to as the indicative changes of myocardial infarction.

ECG Changes: Ischemia (Fig. 3)

- T-wave inversion (flipped T)
- ST-segment depression
- T-wave flattening
- Biphasic T-waves

ECG Changes: Injury

- ST-segment elevation of >1 mm in at least 2 contiguous leads **(Fig. 4)**

JAYPEE BROTHERS



Fig. 3: ECG changes in ischemia.



Fig. 4: ECG changes in injury.

- Heightened or peaked T-waves
- Directly related to portions of myocardium rendered electrically inactive

What is significant St elevation?

The important recommendations for significant ST elevation are given in **Box 1** and described in **Figures 5A to D**.

Box 1: Recommendations for significant ST elevation.

1. For men 40 years of age and older, the threshold value for abnormal J-point elevation should be 0.2 mV (2 mm) in leads V2 and V3 and 0.1 mV (1 mm) in all other leads.
2. For men less than 40 years of age, the threshold values for abnormal J-point elevation in leads V2 and V3 should be 0.25 mV (2.5 mm).
3. For women, the threshold value for abnormal J-point elevation should be 0.15 mV (1.5 mm) in leads V2 and V3 and greater than 0.1 mV (1 mm) in all other leads.

Contd...

JAYPEE BROTHERS

Contd...

4. For men and women, the threshold for abnormal J-point elevation in V3R and V4R should be 0.05 mV (0.5 mm), except for males less than 30 years of age, for whom 0.1 mV (1 mm) is more appropriate.
5. For men and women, the threshold value for abnormal J-point elevation in V7 through V9 should be 0.05 mV (0.5 mm).
6. For men and women of all ages, the threshold value for abnormal J-point depression should be -0.05 mV (–0.5 mm) in leads V2 and V3 and –0.1 mV (–1 mm) in all other leads.

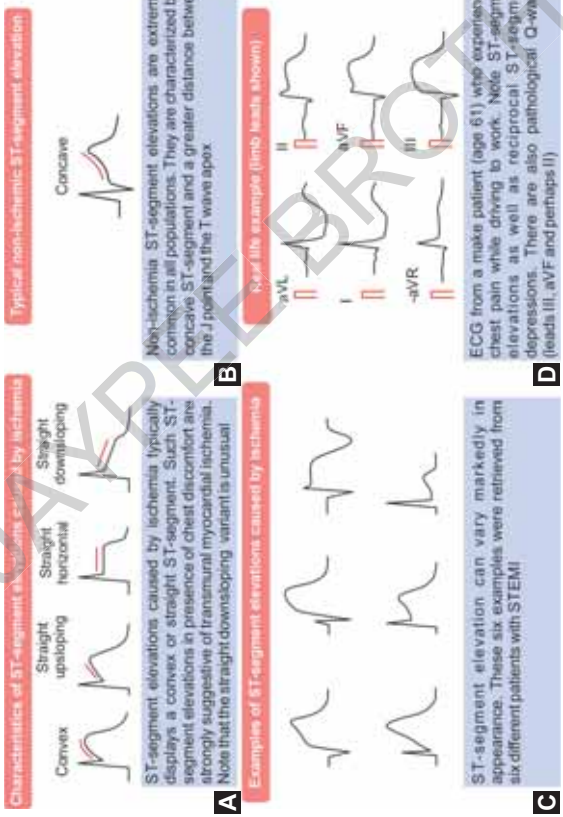

Figs. 5A to D: Significant ST elevation.

JAYPEE BROTHERS

ECG Changes: Infarct

- Significant Q wave where none previously existed
- Impulse traveling away from the positive lead
- Necrotic tissue is electrically dead
- Criteria:
  - Depth of Q wave should be 25% the height of the R wave
  - Width of Q wave is 0.04 s
  - Diminished height of the R wave

Evolving MI and Hallmarks of AMI

Figures 6A to E shows pattern of changes in evolving AMI.

Reciprocal Changes

- ECG signs of myocardial injury are reflected by the presence of ST-segment *elevation* in the leads looking directly at the affected area.
- The uninvolved areas of the heart may show ST-segment *depression*. This is called a reciprocal ("mirror image") change.
- Reciprocal changes are seen in the wall of the heart opposite the location of the infarction **(Fig. 7)**.
- Reciprocal changes are usually most readily observed at the onset of an infarction and tend to be short lived.
- When present, reciprocal changes strongly suggest an acute infarction.
- Reciprocal changes are seen in approximately 75% of inferior wall MIs and approximately 30% of anterior wall MIs.

LOCALIZATION OF MI BASED ON ECG

Location of MI	*Leads affected*	*Vessel involved*	*ECG changes*
Anterior wall	V2 to V4	Left anterior descending artery (LAD)—diagonal branch	• Poor R-wave progression • ST-segment elevation • T-wave inversion

Contd...

JAYPEE BROTHERS

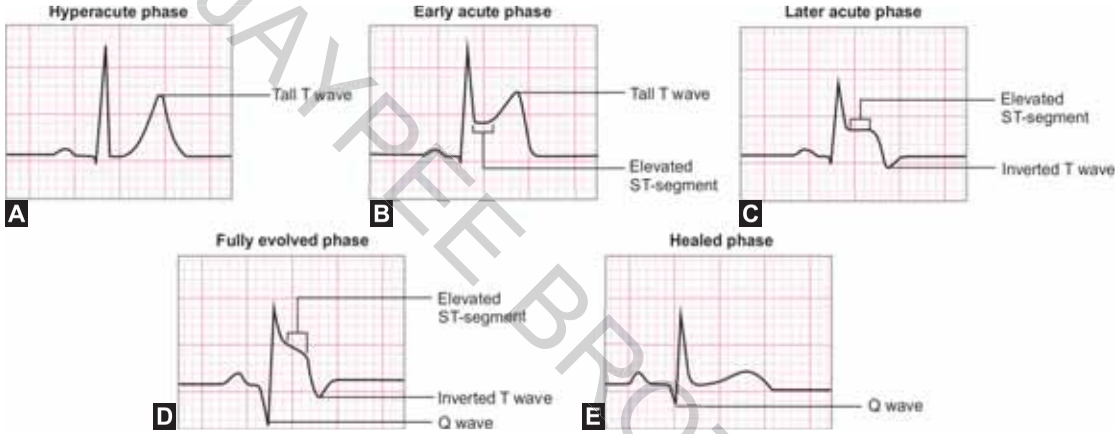

Figs. 6A to E: Pattern of changes in evolving AMI.

JAYPEE BROTHERS

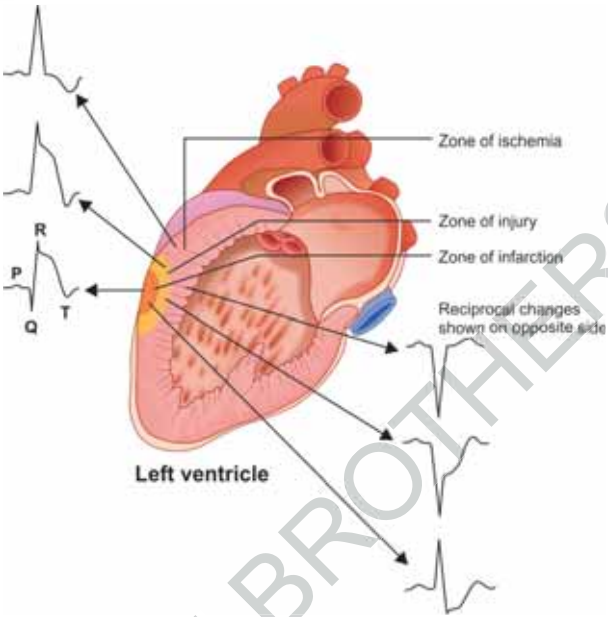

Fig. 7: Reciprocal changes are seen in the wall of the heart.

Contd...

Location of MI	*Leads affected*	*Vessel involved*	*ECG changes*
Septal wall	V1 and V2	Left anterior descending artery (LAD)—septal branch	• R-wave disappears • ST-segment rises • T-wave inverts
Lateral wall	I, aVL, V5, V6	Left aoronary artery (LCA)—circumflex branch	• ST-segment elevation
Inferior wall	II, III, aVF	Right coronary artery (RCA)—Posterior descending branch	• T-wave inversion • ST-segment elevation

Contd...

JAYPEE BROTHERS

Contd...

Location of MI	*Leads affected*	*Vessel involved*	*ECG changes*
Posterior wall	V1 to V4	• Left coronary artery (LCA)—circumflex branch • Right coronary artery (RCA)—Posterior descending branch	• Tall R-waves • ST-segment depression • Upright T-waves

NON-ST ELEVATION MYOCARDIAL INFARCTION

NSTEMI is diagnosed in patients who have symptoms consistent with acute coronary syndrome (ACS) and troponin elevation, but without ECG changes consistent with STEMI.

ECG Manifestation

- ST depressions and T-wave inversions
- ST depression can be either upsloping, downsloping or horizontal **(Fig. 8)**
- Horizontal or downsloping ST depression ≥0.5 mm at the J-point in ≥2 contiguous leads indicates myocardial ischemia
- ST depression ≥ 1 mm is more specific and conveys a worse prognosis
- ST depression ≥2 mm in ≥3 leads is associated with a high probability of NSTEMI and predicts significant mortality (6 x higher risk of death)
- Upsloping ST depression is nonspecific for myocardial ischemia.
- Presence of widespread ST depressions plus ST elevation in aVR >1 mm is suggestive of left main coronary artery occlusion

T-wave inversion must fulfill these criteria:

- Be present in ≥2 contiguous leads that have dominant R-waves (R/S ratio >1)
- Be dynamic
- Be at least 1 mm deep

JAYPEE BROTHERS

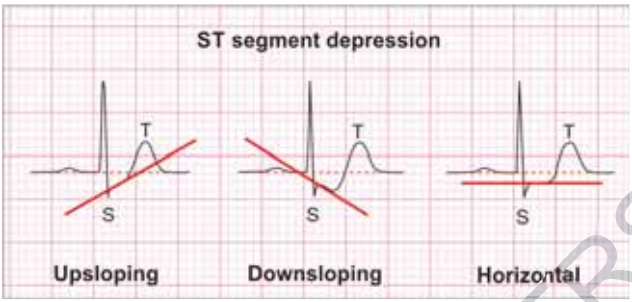

Fig. 8: ST segment depression.

COMPLICATIONS OF ACUTE CORONARY SYNDROME

The complications of ACS are given in Table 1.

Table 1: Complications of acute coronary syndrome.

Type	*Manifestation*
Ischemic	Reinfarction
	Infarct extension
	Angina
Mechanical	Cardiac failure
	Cardiogenic shock
	Mitral regurgitation
	Ventricular aneurysm
	Cardiac rupture (ventricular septum, papillary muscle or cardiac wall)
Arrhythmic	Atrial or ventricular arrhythmia
	Sinus or atrioventricular node dysfunction
Embolic	Central nervous system embolus (especially stroke)
	Peripheral embolus
	Left ventricular mural thrombus
Inflammatory	Pericarditis

JAYPEE BROTHERS

for detailed information on nursing books, visit our website www.jaypeebrothers.com, for detailed information on nursing books, visit our website

ECG *for* Nurses

Salient Features

- *ECGs for Nurses* has been written specifically for the nurses
- Easy-to-access information, full of clinically relevant practical advice
- Simple presentation of the content to ensure clear understanding
- Technical aspects and steps of recording of ECG explained with images
- Diagrams, images and tables for easy understanding of normal and abnormal ECGs
- Specific nursing considerations in common scenarios included as boxes
- Essential for nurses working and studying in intensive care, high dependency units, operation theater, theater recovery coronary care units, medical wards, and accident and emergency
- It has included review questions and practice ECGs
- Video lectures on basics of ECG, heart blocks and identification of arrhythmias are available on DigiNerve.

Archith Boloor MBBS MD (Internal Medicine) a distinguished alumnus from the Kasturba Medical College, Mangalore, Manipal Academy of Higher Education. He is presently working as Additional Professor and Unit Head in the Department of Medicine, Kasturba Medical College, Mangaluru, Karnataka, India.

In a career spanning 15 years, he has a long list of achievements; he started by being awarded the "Best Outgoing Student in Internal Medicine" during his MD in 2008. After which, he continued to work as a doctor and a teaching faculty in KMC, Mangalore, for which he has won the "Best Teacher Award" five times in Kasturba Medical College. His passion for teaching later trickled further into books. He has years of experience shining through multiple books such as: *Exam Preparatory Manual of Medicine, An Insider's Guide to Clinical Medicine, Mastering Medicine—MRCP Made Easy, The Washington Manual of Medical Therapeutics—SAE, Antibiotic Basics for Clinicians—The ABCs of Choosing the Right Antibacterial Agent—SAE, Comprehensive Medicine for Dental Students, An Insider's Guide to Cases in Internal Medicine* and *ABC of ECG*. He was most recently the recipient of the Award for Excellence in Book Production by the Federation of Indian Publishers in November 2020 for one of his clinical books. He is also a frequent researcher, having more than 50 research publications, many in high impact journals such as Nature and Lancet.

Printed in India

Available at all medical bookstores
or buy online at www.jaypeebrothers.com



JAYPEE BROTHERS
Medical Publishers (P) Ltd.
EMCA House, 23/23-B, Ansari Road,
Daryaganj, New Delhi - 110 002, INDIA
www.jaypeebrothers.com

Join us on facebook.com/JaypeeMedicalPublishers

