etailed information on physiotherapy books, visit our website www.jaypeebrothers.com, for detailed information on physiotherapy books, visit our website www.jaypeebrothers.com



Textbook of
Clinical Kinesiology

VD Bindal

2nd Edition

JAYPEE

Contents

Section 1 Introduction and Fundamentals

Chapter 1: Introduction to Kinesiology 3

- Definition 3
- Major Contributions: Past and Current 5
- Aims and Objectives of Kinesiology 9
- Practical Application of Kinesiology: In Physical Education and Physiotherapy 11
- Role and Importance of Kinesiology: In Physical Education and Sports 11

Chapter 2: Anatomical and Physiological Fundamentals of Human Motion 14

- The Skeletal System 14
- Muscular System 27
- Skeletal Muscles 28
- Gross and Microscopic Structure of Skeletal Muscle 29
- Protein Constituents of a Muscle 31
- Slow-Twitch and Fast-Twitch Muscle Fibers 31
- Muscular Attachments 32
- Nomenclature of the Muscles (Muscle Names) 32
- Structural Classification of Muscles on the Basis of Muscle Fibers Arrangement 33
- Effect of Muscle Structure on Force and Range of Motion 34
- Types of Muscle Contraction 34
- Effect of Gravity on Muscle Action 36
- Brief Physiology of Muscular Contraction 37
- Neuromuscular Concepts 37
- Roles of Muscles 43
- Nervous Control of Voluntary Movements 46

Chapter 3: Basic Biomechanical Concepts 54

- Gravity 54
- Center of Gravity 54
- Line of Gravity 55
- Base of Support 55
- Axes and Planes 55
- Equilibrium and Stability 59
- Force 62
- Motion 65
- Levers 70

Section 2 Kinesiology of Body Regions

Chapter 4: Shoulder Girdle 83

- Movements 84
- Muscles of the Shoulder Girdle 86

Chapter 5: Shoulder 91

- Movements 92
- Muscles of the Shoulder Joint 93

Chapter 6: Elbow and Radioulnar Joints 100

- Elbow 100
- Radioulnar Joints 101
- Muscles of Elbow and Radioulnar Joints 102

Chapter 7: Wrist and Hand 107

- Ligaments of Wrist and Hand 108
- Movements of Wrist and Hand 108
- Muscles of Wrist and Hand 110

Chapter 8: Pelvic Girdle 122

- Movements of Pelvic Girdle 124
- Muscles of the Pelvis 125

Chapter 9: Hip 127

- Movements 127
- Muscles 128

Chapter 10: Knee 138

- Movements 139
- Muscles 140

Chapter 11: Ankle and Foot 144

- Bones and Joints of Foot 144
- Movements 146
- Arches of the Foot 148
- Muscles of the Ankle and Foot 150

Chapter 12: Spine 157

- Structure 158
- Movements 159
- Muscles 161
- Cervical Spine (Neck) 164
- Trunk 166

Section 3 Motor Skills: Principles and Applications

Chapter 13: Posture 173

- Definitions 173
- Evolution of Erect Posture 173
- Types of Posture 174
- Maintenance of Posture 176
- Good Posture 177
- Poor or Bad Posture 177
- Static Positions 178
- Postural Defects 180

Chapter 14: Locomotion 189

- Walking 189
- Running 200
- Common Deviations of Normal Gait 204

Chapter 15: Application of Kinesiology to Selected Daily Life Activities and Sports Skills 208

- Daily Life Activities 208
- Sports Skills 215

Chapter 16: Prevention of Sports Injuries: The Mechanical and Kinesiological Viewpoint 223

- Dissipation of Force 223
- Landing 224
- Catching 225
- Summary of Mechanical and Kinesiological Principles Related to Prevention of Injuries 226

Bibliography *229*

Glossary *231*

Index *235*

CHAPTER 4

Shoulder Girdle

INTRODUCTION

The upper limb or the upper extremity is the organ of the body, responsible for manual activities. It is freely movable, especially its distal segment—the hand, which is adapted for grasping and manipulating the objects. For descriptive purposes in a kinesiology textbook, the upper limb can be divided into four parts **(Fig. 4.1)**:

1. Shoulder girdle
2. Shoulder
3. Elbow and radioulnar joints
4. Wrist and hand.

Each upper limb has a girdle, i.e., shoulder girdle by which it is attached to the axial skeleton. The shoulder girdle supports three main parts of an upper limb—(1) a proximal arm, (2) a middle forearm, and (3) a distal hand.

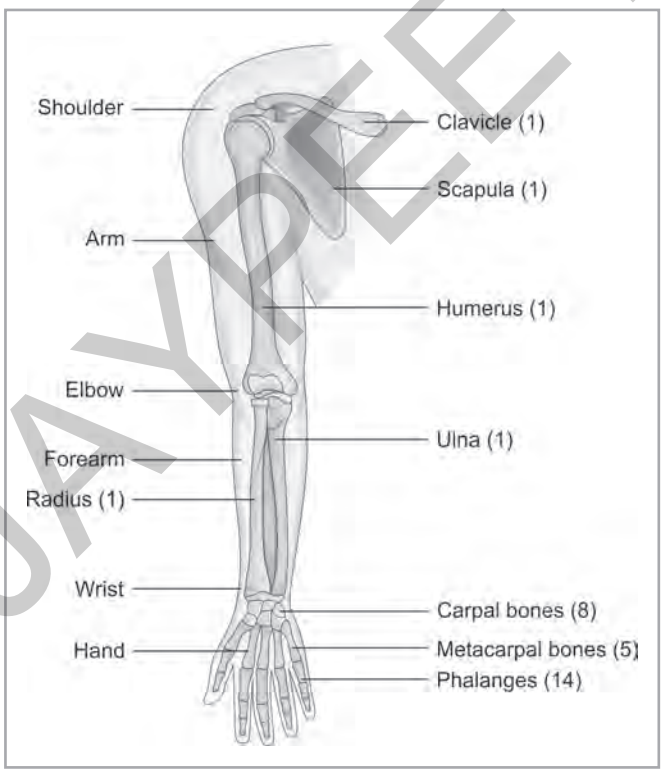

FIG. 4.1: Upper limb (parts and bones).

The shoulder complex is a term that is sometimes used to include all of the structures involved with motion of the shoulder. The *shoulder complex* consists of bones (scapula, clavicle, sternum, humerus, and ribcage), and the joints (sternoclavicular joint, acromioclavicular joint, glenohumeral joint, and possibly scapulothoracic joint also) **(Figs. 4.2A and B)**. As such, the shoulder complex mainly comprises of the shoulder girdle and shoulder joint, which are two separate functional structures. However, their anatomical inter-relationships and fine cooperation enable a wide range of arm movements and hand placement while carrying out important functions, and during various other activities of lifting, pushing, etc.

In fact, the upper extremity is suspended from the axial skeleton (head and trunk) by means of a shoulder girdle which consists of a sternum and two clavicles in front, and two scapulae in the back. Though, only two bones, the scapula, and clavicle are mainly involved in the movements of the shoulder girdle. The sternoclavicular joints connect the sternum and each clavicle, and the acromioclavicular joints connect the acromion process of each scapula with the corresponding clavicle. Since there is no structural union between the two scapulae in the back, it is an incomplete girdle.

The connection of the upper extremity to the shoulder girdle is made through the shoulder joint (also called as glenohumeral joint, formed between the head of the humerus and the glenoid cavity of the scapula).

As described above, ***the shoulder girdle mainly has two joints or articulations***:

1. **Acromioclavicular joint**
2. **Sternoclavicular joint**

Acromioclavicular joint is formed between the acromion process of scapula and outer end of the clavicle which is a biaxial type of synovial joint. It has a 20–30° total gliding and rotational motion accompanying other shoulder girdle and shoulder joint motions. Its *main ligaments* are—*acromioclavicular ligaments* (located in the front) and *coracoclavicular ligaments* (the main protection against

JAYPEE BROTHERS

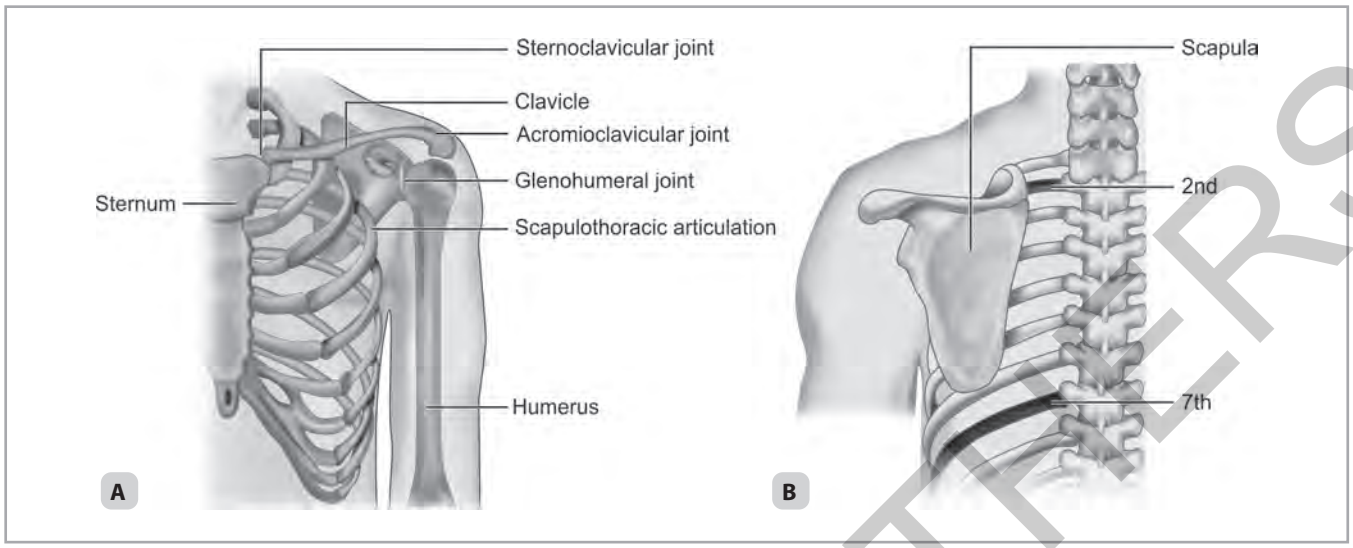

FIGS. 4.2A AND B: (A) Left shoulder complex (front view); (B) Resting position of the left scapula on the thorax (posterior view).

injury to the joint). The joint is strengthened from behind by the trapezius and deltoid muscles.

The sternoclavicular joint is a freely movable (multiaxial) arthrodial, ball, and socket type of joint formed between the sternal end of the clavicle, and both sternum and first rib. A fibrocartilage joins the top of the clavicle with the bottom of the cartilage of the first rib near its junction with the sternum. This fibrocartilage acts as a ligament and would help in preventing upward dislocation of the clavicle. The joint capsule is strengthened in front and behind by the thickened bands of fibers called the *anterior* and *posterior sternoclavicular ligaments*. There are *two other ligaments* reinforcing this joint, i.e., *interclavicular* and *costoclavicular ligaments*.

This sternoclavicular joint is of great importance in the movements of the shoulder girdle and of the arm as a whole as it is the only bony connection between the humerus and the axial skeleton. This joint moves anteriorly about 15° with *protraction* movement, and posteriorly about 15° with *retraction* movement. It allows an upward movement of about 45° with *elevation* and some 5° downward movement with *depression*. Some *rotation* of the clavicle along its axis during various movements of the shoulder girdle results in slight rotary gliding movement of the sternoclavicular joint.

Scapulothoracic Joint

Certain experts also describe one functional joint of shoulder girdle by the term *scapulothoracic joint*. Since there is no true joint or point of fixation between scapula and thorax, however, the scapula does move over the ribcage of the thorax. The scapula and thorax are indirectly attached by the clavicle and by several muscles. The moving surfaces of scapula (the medial border) and the ribs (anterolateral surfaces of the first nine ribs) form, through the muscle serratus anterior the so-called *false* or *functional joint*. It is believed that this joint plays a main function of the mobility and stability of the upper extremity. The movements of this joint provide a movable base for the humerus, and therefore increase the range of movements of the arm, and assist the functioning of the deltoid muscle, mainly in overhead movements.

In everyday life most of the movements of the scapula are closely integrated with movements of the arm, greatly increasing the possible range of arm movements. The scapula serves as a mobile base from which the arm operates. Whatever action or position is required of the arm to accomplish a given task, the scapula moves to align the glenoid cavity to the best possible position to receive the head of the humerus.

MOVEMENTS

To define the movements, the shoulder girdle customarily involves the description of the movements of the scapulae. It is worth emphasizing here that every movement of the scapula involves motion in both the joints, i.e., acromioclavicular and sternoclavicular. The main shoulder girdle movements **(Figs. 4.3A to D)** are as follows:

- ***Elevation*:** An upward movement of scapula, with the vertebral border remaining almost parallel to the spinal column (in other words, the upward movement of scapula without any rotation is called *elevation*). The range of movement is nearly 60° and it is thought that pure elevation is relatively a rare movement that

JAYPEE BROTHERS

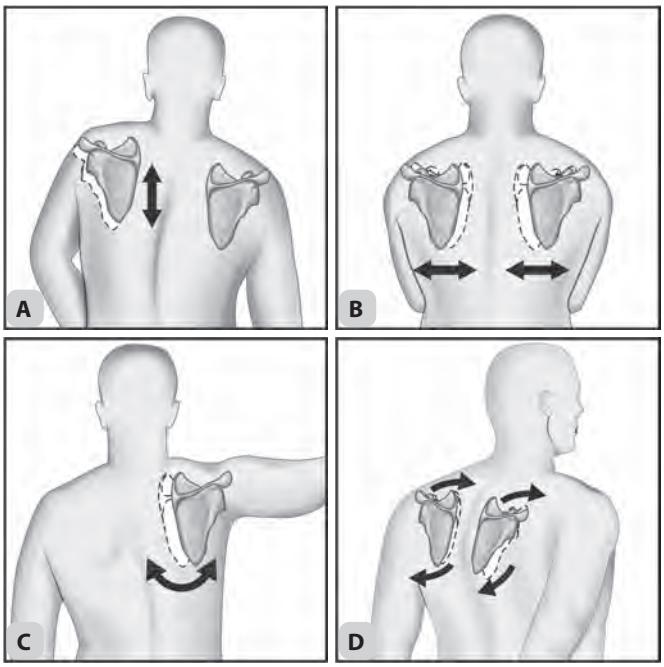

FIGS. 4.3A TO D: Movements of shoulder girdle: (A) Elevation/Depression; (B) Protraction/retraction; (C) Upward rotation/downward rotation; (D) Scapular tilt.

occurs in shoulder shrugging or picking up a suitcase and many other tasks in which the upper limb is not moved forward or sideward away from the body.

- ***Depression*:** A downward movement of scapula (from an elevated or a normal resting position). According to some, no depression movement occurs below the normal resting position; however, others claim that from a sitting resting position, 5–10° of depression movement is possible. The depression movement, from the position of maximum elevation, can involve elevation of the trunk by 4–6".
- ***Protraction (abduction of scapula)*:** A lateral movement of scapula away from the spinal column (since the pure abduction of scapula keeping its vertebral border almost parallel to the spinal column is not possible, this movement is always associated with some degrees of lateral tilt of the scapula. Clavicle also moves more forward at the acromioclavicular joint, with the medial border of scapula moving some 2–3" away from the midline).
- ***Retraction (adduction of scapula)*:** A medial movement of the scapula toward the spinal column, combined with a reduction of lateral tilt of scapula (the medial border of the scapula approaches the midline). The total range of protraction and retraction at the sternoclavicular joint has been measured at nearly 25°.
- ***Upward rotation of scapula*** is a movement of scapula in the frontal plane that involves the somewhat upward turning of the glenoid cavity. This movement is always associated with the movement of humerus, either forward or sideward. ***Downward rotation of scapula*** is a return downward movement of scapula from the position of upward rotation so that the glenoid cavity faces more downward. There may be a slight downward rotation beyond the normal resting position also. The center of rotation is within the scapula itself. The total range of upward and downward rotation is about 60° and occurs at the acromioclavicular joint. The complete range of downward rotation occurs when the dorsum of the hand is placed on the lower back region.
- ***Forward and backward tilts of scapula*** are the other specialized movements of a small extent, which are of very little significance to normal functioning. However, the *forward tilt of scapula* occurs when the inferior angle moves backward away from the ribcage and the superior border of scapula turns slightly forward and downward. This movement is mainly accompanied by the hyperextension of the shoulder and rotation of the clavicle. *Backward tilt of scapula* is the opposite movement of forward tilt in which the inferior angle and costal surface of scapula return to the surface of the ribcage and the superior border of scapula comes to a normal resting position. This movement is also accompanied by hyperflexion of shoulder joint.

Summary of muscular analysis of shoulder girdle movements is given in **Table 4.1**.

Table 4.1: Summary of muscular analysis of shoulder girdle movements.

Movement	*Prime movers*	*Assistant movers*
Elevation	• Upper trapezius • Levator scapulae	Rhomboids
Depression	• Lower trapezius • Pectoralis minor	Subclavius
Protraction (abduction of scapula)	• Serratus anterior • Pectoralis minor	
Retraction (adduction of scapula)	• Rhomboids (major and minor) • Middle trapezius	
Upward rotation of scapula	• Upper and lower trapezius • Serratus anterior (lower part)	Middle trapezius
Downward rotation of scapula	• Rhomboids (major and minor) • Levator scapulae • Pectoralis minor	

JAYPEE BROTHERS

MUSCLES OF THE SHOULDER GIRDLE

There are six main muscles acting on the shoulder girdle, which are classified as anterior or posterior muscles according to their location on the trunk **(Table 4.2)**. **Figure 4.4** shows the actions of scapular muscles. The summary of major muscles acting on shoulder girdle is given in **Table 4.3**.

Serratus Anterior

This is a broad sheet of muscle that clothes the side wall of the thorax, and one of the most important muscles of the shoulder girdle which is named from its serrated or saw-toothed anterior edge. This muscle lies on the outer lateral surface of the ribs and is covered by pectoralis major in front, and by the scapula at the back. The muscle may be palpated on the anterior lateral surface of the upper thorax, especially on a thin, muscular subject **(Fig. 4.5)**.

Origin: The outer surface of the upper eight or nine ribs at the side of the chest.

Table 4.2: Classification of shoulder girdle muscles according to their location on the trunk.

Anterior	*Posterior*
Serratus anterior	Trapezius
Pectoralis minor	Levator scapulae
Subclavius	Rhomboids

Insertion: The muscle is inserted into the anterior surface of the medial border of the scapula, from its superior to the inferior angle.

- *Action*: Prime mover for abduction (protraction) and upward rotation of the scapula. It is a powerful protractor of the scapula, i.e., it pulls the scapula forward around the chest wall for pushing and punching movements as required during boxing. Hence, serratus anterior is also called "boxer's muscle."
- *Nerve supply*: Long thoracic nerve (C_5, C_6, and C_7).

The serratus anterior and trapezius combinedly produce upward rotation of the scapula. Activity of these two muscles is clearly evident during elevation of the arm; the trapezius being more active during abduction of arm, and serratus anterior during active flexion of the arm. Serratus anterior is said to be a very important muscle in reaching and pushing activities. The paralysis of this muscle prevents elevation of the arm above 100°, and on attempting forward reaching movement; a typical *winging of scapula* is seen (in which the medial border of the scapula is lifted-up).

Pectoralis Minor

This small triangular muscle is located on the front of the upper chest and is covered by pectoralis major **(Fig. 4.6)**. The muscle may be palpated midway between the clavicle and the nipple when the arm is elevated backward against resistance (resisted shoulder extension), particularly when the pectoralis major is relaxed.

- *Origin*: The outer surfaces of the 3rd, 4th, and 5th ribs near the costal cartilages.

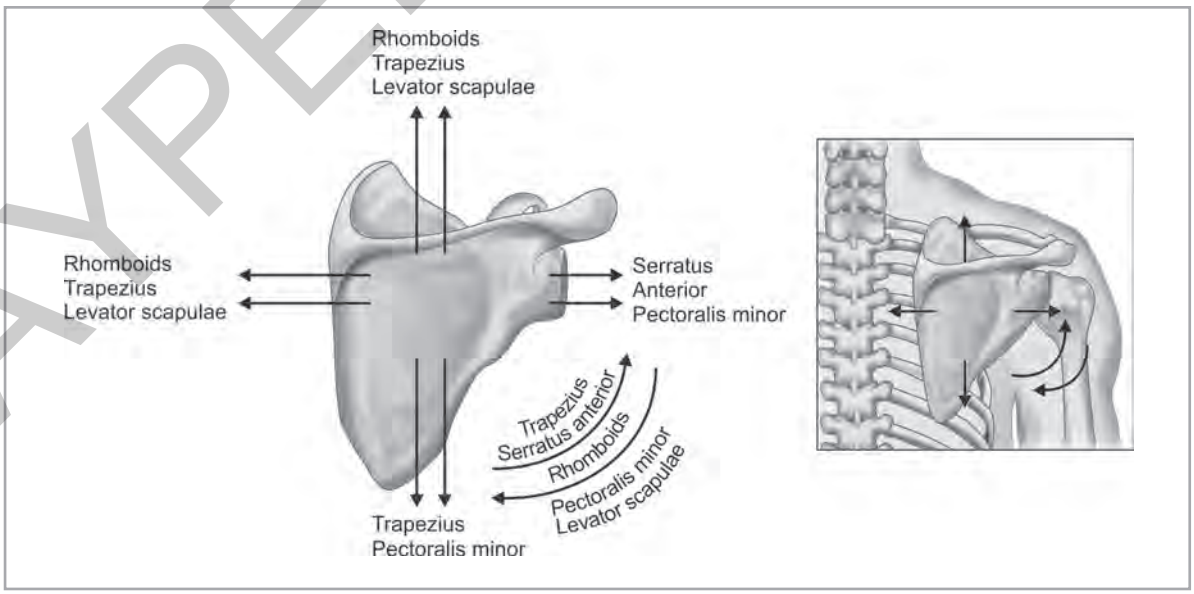

FIG. 4.4: Actions of scapular muscles.

JAYPEE BROTHERS

Table 4.3: Summary of major muscles acting on shoulder girdle.

Muscle	*Location*	*Origin*	*Insertion*	*Main action*	*Assistive action*
Trapezius	Upper back and neck	• *Upper*, base of skull, (occipital bone), posterior neck ligament • *Middle*, spinous processes of seventh cervical and upper three thoracic vertebrae • *Lower*, spinous processes of middle and lower thoracic vertebrae	• Lateral third of clavicle (posteriorly) • Spine of scapula • Base of spine of scapula	• Scapular elevation and upward rotation • Scapular retraction • Scapular depression and upward rotation	• Neck extension and scapular retraction • Upward rotation of scapula • Scapular retraction (adduction)
Levator-scapulae	Side of the neck (posterior)	Transverse processes of first four cervical vertebrae	Medial border of scapula (between spine of scapula and superior angle)	Scapular elevation and downward rotation	Lateral flexion and rotation of cervical spine to the same side
Pectoralis minor	Front of chest (deep to pectoralis major)	Anterior surfaces of 3rd, 4th, and 5th ribs	Coracoid process of scapula	Scapular depression, downward rotation, and forward tilt of scapula	Scapular protraction (abduction)
Subclavius	Beneath clavicle	Upper surface of 1st rib	Underside of clavicle	Scapular depression and medial pull of clavicle	
Serratus anterior	Lateral thorax	Lateral surface of upper eight ribs	Medial border of scapula (anterior surface)	Scapular protraction (abduction) and upward rotation	
Rhomboids (major and minor)	Deep upper back	Spinous processes of seventh cervical to upper five thoracic vertebrae	Medial border of scapula (between spine of scapula and inferior angle)	Scapular retraction (adduction) and downward rotation	Scapular elevation

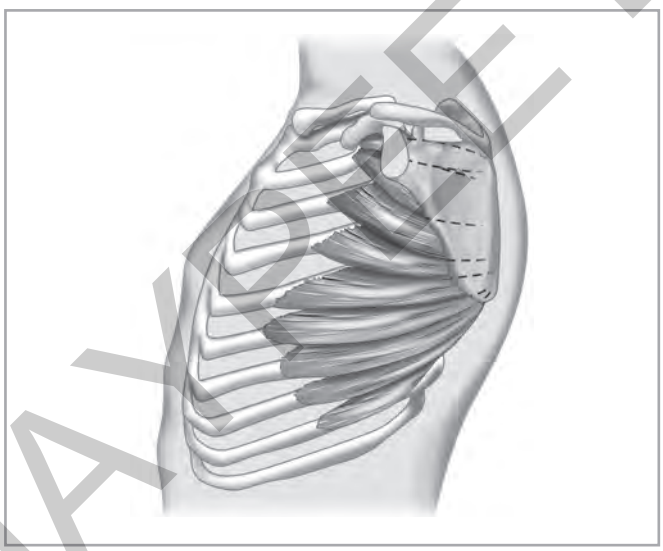

FIG. 4.5: Serratus anterior muscle.

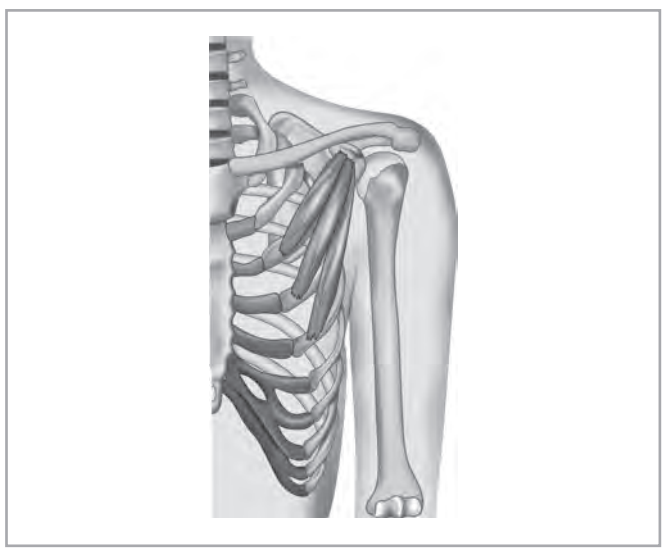

FIG. 4.6: Pectoralis minor muscle.

- *Insertion*: The muscle is inserted to the coracoid process of the scapula.
- *Action*: This muscle participates in several movements such as depression, downward rotation and forward tilt of the scapula. It also assists elevation of the 3rd to 5th ribs. This muscle is very important that influences good posture in stabilizing the scapula by the rhomboids and middle trapezius (the adductors of the scapulae).

JAYPEE BROTHERS

- *Nerve supply*: Lateral pectoral (C_5, C_6, and C_7) and medial pectoral (C_8 and T_1) nerves.

Subclavius

As the name of the muscle indicates, this rounded muscle is located horizontally beneath the clavicle, which cannot be palpated. This is the smallest of all the muscles of the shoulder girdle.

- *Origin*: The upper surface of the 1st rib, just where it joins its cartilage.
- *Insertion*: To a groove extending along the middle half of the underside of the clavicle.
- *Action*: Its chief function is to protect and stabilize the sternoclavicular joint. As such, its main action is depression and the medial pull of the clavicle.
- *Nerve supply*: Nerve to subclavius (C_5 and C_6) from the upper trunk of the brachial plexus.

Trapezius

The trapezius is a large flat triangular superficial muscle of the neck and upper back located directly under the skin and is very easy to palpate. The name of the muscle refers to its geometric figure. The trapezius muscles of both sides lie side by side in the midline and together form a diamond, shape/trapezoid shape, hence the name trapezius. The muscle has three main parts such as—(1) upper, (2) middle, and (3) lower trapezius **(Figs. 4.7 and 4.8)**. The reason for this division of the muscle into three parts is because of three different lines of pull (up, in, and down) of these parts resulting in different muscle action.

- *Origin*: The muscle originates from base of skull (occipital bone), ligament of the neck, and spinous processes of vertebrae from the 7th cervical to 12th thoracic.
- *Insertion*: To acromion, acromial end of clavicle, and the upper border of the spine of the scapula.
- *Actions*:
  - The upper trapezius performs elevation (i.e., lateral flexion and rotation of the neck to the opposite side.
  - The middle trapezius performs adduction (retraction, i.e., bracing of the shoulder backward), and upward rotation of the scapula.
  - The lower trapezius performs depression, adduction and upward rotation of the scapula.
- *Nerve supply*:
  - Spinal part of accessory (XI cranial) nerve
  - C_3 and C_4 spinal nerves (proprioceptive)

As such, the trapezius shows definite activity during elevation, and adduction (retraction) movements of the scapula. All three parts of the trapezius muscle work together (synergists) in the retraction (adduction) movement. However, the middle trapezius is the prime mover, and the upper and lower parts can only assist in this movement. The upper and lower trapezius are antagonistic to each other in depression/elevation, and agonist in upward rotation. Acting with serratus anterior, the trapezius rotates the scapula forward so that the arm can be abducted beyond 90°.

Levator Scapulae

As the name indicates this slender muscle is an elevator of the scapula, and as such, it shares with the upper part of trapezius and rhomboids in the movement of elevation. This small muscle is located on the back and side of the neck beneath the upper part of the trapezius **(Fig. 4.9)**.

- *Origin*: From the transverse processes of upper four or five cervical vertebrae.

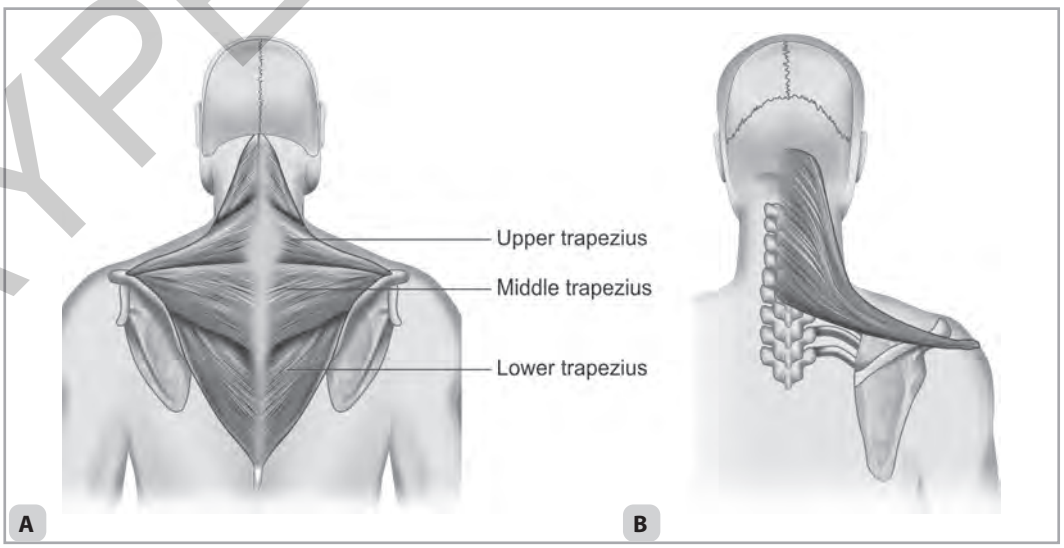

FIGS. 4.7A AND B: (A) Three parts of trapezius together (both-sided); (B) Upper trapezius.

JAYPEE BROTHERS

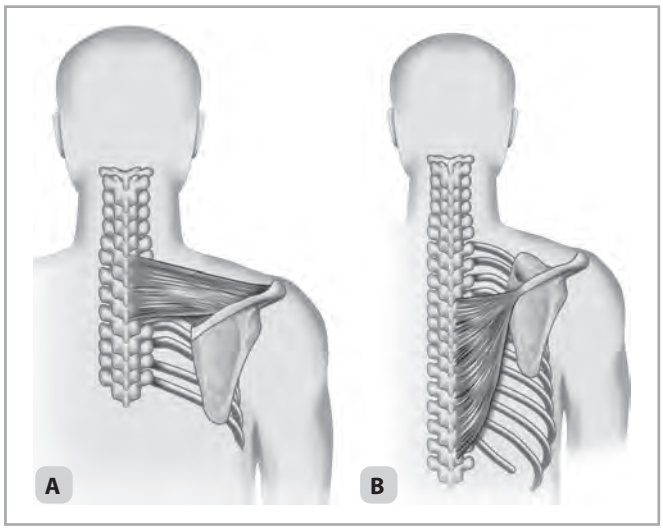

FIGS. 4.8A AND B: (A) Middle trapezius; (B) Lower trapezius.

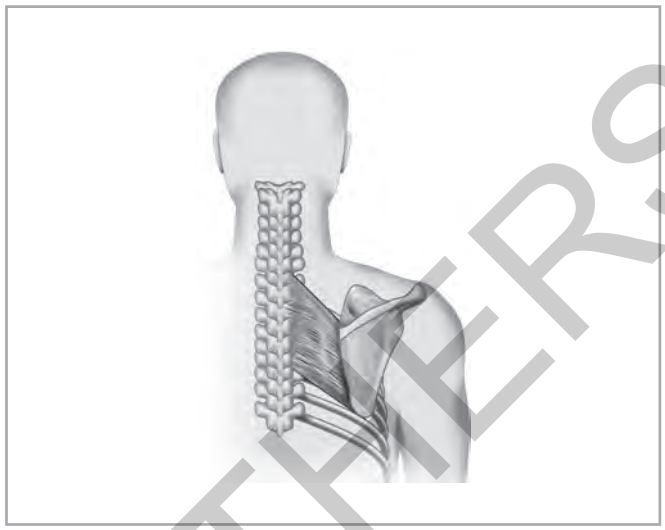

FIG. 4.10: Rhomboid muscles.

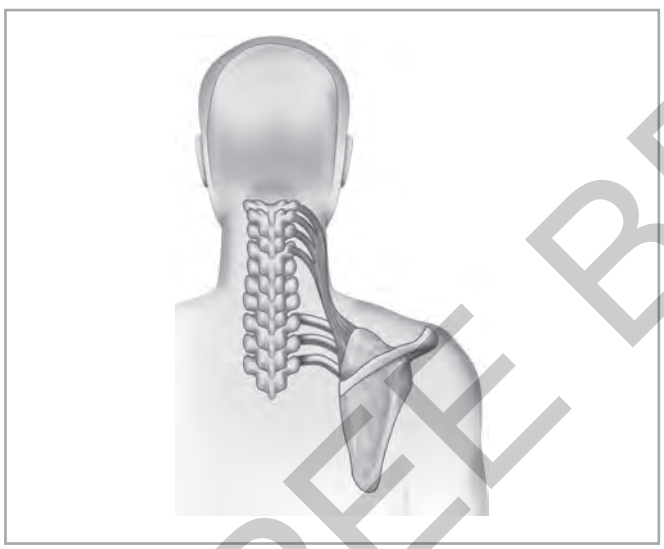

FIG. 4.9: Levator scapulae muscle.

Table 4.4: Nerve supply of shoulder girdle muscles.

Muscle	*Nerve supply*
Trapezius	• Spinal part of accessory (XI cranial) nerve • C_3 and C_4 spinal nerves (proprioceptive)
Levator scapulae	• Dorsal scapular nerve (C_5) • C_3 and C_4 spinal nerves (proprioceptive)
Pectoralis minor	Lateral pectoral (C_5 to C_7) and medial pectoral (C_8 and T_1) nerves
Subclavius	Nerve to subclavius (C_5, C_6) from the upper trunk of the brachial plexus
Serratus anterior	Long thoracic nerve (C_5, C_6, and C_7)
Rhomboids (major and minor)	Dorsal scapular nerve (C_5)

- *Insertion*: To the medial border of the scapula and its spine and near the superior angle of the scapula.
- *Action*: Its main action is elevation and downward rotation of the scapula and it steadies the scapula during movements of the arm particularly when the trunk is in an erect position. This muscle also assists the lateral flexion and rotation of cervical spine to the same side.
- *Nerve supply*:
  - Dorsal scapular nerve (C_5)
  - C_3 and C_4 spinal nerves (proprioceptive)

Rhomboids

Both the muscles rhomboid major and rhomboid minor are functionally regarded as one muscle the rhomboids **(Fig. 4.10)**. This muscle connects the scapula to the vertebral column and lies beneath the trapezius. The name of the muscle is derived from its shape that of an oblique parallelogram.

- *Origin*: From the spinous processes of the vertebrae of seventh cervical to fifth thoracic.
- *Insertion*: To the medial border of the scapula from its spine to the inferior angle.
- *Action*: Adduction (*retraction*) and downward rotation of scapula. It also assists the elevation of the scapula. The cooperative action of rhomboids and middle trapezius helps in the maintenance of good shoulder posture particularly in stabilizing the scapula during abduction of the arm.
- *Nerve supply*: Dorsal scapular nerve (C_5).

Table 4.4 summarizes the nerve supply of shoulder girdle muscles.

JAYPEE BROTHERS

MULTIPLE CHOICE QUESTIONS

1. Which is a large flat triangular superficial muscle of the neck?

a. Trapezius
b. Pectoralis minor
c. Subclavius
d. Levator scapulae

2. What is the nerve supply of serratus anterior?

a. Long thoracic nerve (C_5, C_6, and C_7)
b. Spinal part of accessory (XI cranial) nerve
c. C_3 and C_4 spinal nerves (proprioceptive)
d. Dorsal scapular nerve (C_5)

3. Which is the smallest of all the muscles of the shoulder girdle?

a. Levator sapulae
b. Subclavius
c. Rhomboids
d. Trapezius

JAYPEE BROTHERS

Answers

1. a 2. a 3. b

for detailed information on physiotherapy books, visit our website www.jaypeebrothers.com, for detailed information on physiotherapy books, visit our website www.jaypeebrothers

Textbook of **Clinical Kinesiology**

Textbook of Clinical Kinesiology is authored by a very senior faculty member of India's most prestigious institute in physical education. Divided into 3 sections and 16 chapters, the book contains detailed history, review of anatomical and physiological fundamentals and basic biomechanical concepts, all relevant as foundation to any kinesiology textbook. A discussion of various joint movements, muscles and muscular analysis of almost all the body regions is provided in the book at great length. The book also contains chapters on posture, locomotion, application of kinesiology to various daily life activities and sports skills, and prevention of sports injuries, all essentially to be incorporated in a standard textbook on kinesiology.

The organization and contents of the book, written in an easy and understandable language is primarily intended to serve as a textbook of kinesiology for the students and teachers of physical education, physiotherapy and occupational therapy. The book covers almost all the syllabus of the subject taught for the undergraduate courses in all of these disciplines in the colleges and universities in India.

VD Bindal PhD LPT (USA) was formerly Associate Professor and Head, Division of Physiotherapy, Lakshmibai National Institute of Physical Education, Gwalior, Madhya Pradesh, India, which is the country's renowned and the most premier Institute and Deemed to be University in Physical Education. Already an author of four books, *Corrective Physical Education, Therapeutic Exercise and Rehabilitation, Therapeutic and Sports Massage, Sports Injuries and Therapeutic Modalities,* and *Complete Book on Correctives, Therapeutic Exercise, Sports Injuries and Massage,* and a number of research papers published in various journals of repute to his credit, he was involved in teaching subjects, i.e., kinesiology, correctives, and athletic care and rehabilitation to the undergraduate and postgraduate students of physical education, for about 31 years.



He also holds the American License in Physical Therapy from the University of the state of New York, and has served as the Chief Physical Therapist and Clinical Instructor in one of the leading New York University Teaching Hospitals, USA. As a Sports Physiotherapist, he served the Indian Contingent during the Vth South Asian Federation Games held in Colombo, and also to many All India Inter University Tournaments.

Printed in India

Available at all medical bookstores or buy online at www.jaypeebrothers.com

JAYPEE BROTHERS
Medical Publishers (P) Ltd.
EMCA House, 23/23-B, Ansari Road,
Daryaganj, New Delhi - 110 002, INDIA
www.jaypeebrothers.com

Join us on facebook.com/JaypeeMedicalPublishers

Shelving Recommendation
PHYSIOTHERAPY

ISBN 978-93-5696-435-8

9 789356 964358