hers.com, for detailed information on orthopedic books, visit our website www.jaypeebrothers.com, for detailed information on ophthalmology book



TEXTBOOK FOR ORTHOPEDIC ASSISTANTS AND PLASTER TECHNICIANS

As per the Latest Syllabus and Guidelines

Highlights

- Radiographic findings of various cases shown
- Encompasses clinical case photographs
- Includes line diagrams for better understanding

John Ebnezar
Rakesh John

JAYPEE

Contents

Section I: Theory

Traumatic

Chapter 1: History Taking 3
Chapter 2: Details of Different Fractures 14
Chapter 3: Fracture Healing and its Problems 18
Chapter 4: Emergency Care of Fractures 24
Chapter 5: Management of Fractures—Simple and Compound 29
Chapter 6: Important Splints in Orthopedics 38
Chapter 7: Traction in Orthopedics 42
Chapter 8: Complications of Fractures 48
Chapter 9: Injuries to the Joints and Soft Tissues 65
Chapter 10: Fracture of the Clavicle and Scapula 70
Chapter 11: Humerus Fractures 74
Chapter 12: Fractures of Both Bones of Forearm 78
Chapter 13: Wrist Fractures 84
Chapter 14: Injuries of the Hand 90
Chapter 15: Fracture Pelvis and Trunk 95
Chapter 16: Injuries of the Spine 103
Chapter 17: Hip Trauma 111
Chapter 18: Injuries of the Femur 120
Chapter 19: Injuries of the Leg 125
Chapter 20: Knee Trauma 129
Chapter 21: Injuries Around the Ankle 138
Chapter 22: Injuries of the Foot 143

Non-traumatic

Chapter 23: Skeletal Tuberculosis 150
Chapter 24: Disorders of Joints 161
Chapter 25: Rheumatoid Arthritis 168

Chapter 26: Degenerative Disorders 177
Chapter 27: Neuromuscular Disorders 183
Chapter 28: Bone Neoplasias 188
Chapter 29: Metabolic Bone Disorders 197
Chapter 30: Regional Orthopedic Conditions 205
Chapter 31: Arthroplasty 220
Chapter 32: Amputations 224
Chapter 33: Prosthetics and Orthotics 228

Section II: Practical Orthopedics

Upper Limbs

Chapter 34: Upper Limb Fractures 233
Chapter 35: Forearm Fracture 246
Chapter 36: Wrist Injuries 276
Chapter 37: Hand Injuries 286

Lower Limbs

Chapter 38: Hip Injuries 305
Chapter 39: Knee Aspiration 309
Chapter 40: Leg Injuries 311
Chapter 41: Foot Injuries 329
Chapter 42: Conventional Plaster Splints 344

Index *349*

8
CHAPTER

Complications of Fractures

Chapter Outline

- Hypovolemic Shock
- Acute Respiratory Distress Syndrome
- Compartmental Syndrome of Forearm
- Delayed union and nonunion
- Avascular Necrosis
- Traumatic Myositis Ossificans
- Malunion
- Other Important Acute Complications of Fractures
- Injury to Blood Vessels
- Injury to Nerves
- Other Important Delayed Complications

HYPOVOLEMIC SHOCK

Shock due to Hypovolemia

In fractures of major long bones, pelvic fractures, multisystem injuries following road traffic accidents, etc., severe loss of blood may seriously threaten the life of a victim. Delay and apathy is attending a hypovolemic shock could prove fatal.

Source of Hemorrhage

This could be external or internal.

- **External hemorrhage:** This usually happens in compound fractures, pelvic fractures, etc.
- **Internal hemorrhage:** It is more often seen is blunt injury of abdomen femur and pelvic fractures, etc. It could be much more in multiple fractures.

Remember

Bloody facts: Do you know a staggering blood loss in fractures:

- Femoral shaft fractures—blood loss could range from 500 to 2,000 mL
- Pelvic fractures—blood loss could range from 1,000 to 2,500 mL

Clinical Features

Look for the classical features of Shock **(Box 8.1)** apart from features of fractures.

Box 8.1: Shocking facts—look for the classical features.

- Tongue—pale and dry
- Pale look
- Low BP
- Cold clammy skin
- Cold nose
- Peripheral pulses feeble or absent
- Drowsy or unconscious

Investigations

Laboratory investigations like HB%, blood group, bleeding and clotting time, HIV. HBsAg, etc., are of utmost importance. Plain X-rays of the affected

JAYPEE BROTHERS

limbs and other investigations like MRI, CT scan, etc., are done once the general condition of the patient is stabilized.

Treatment

Speed is the watchword in the treatment of shock and included.

- Resuscitation
- Immediate fluid replacement by:
  - IV fluids—normal saline, Ringer lactate, etc.
  - Hemaccel
  - Blood—best alternative
- Administrations of oxygen
- Splinting the fractures
- Controlling the bleeding points

ACUTE RESPIRATORY DISTRESS SYNDROME (SYN: FAT EMBOLISM)

Acute respiratory distress syndrome (ARDS) is defined as a post-traumatic distress syndrome occurring within 72 hours of skeletal trauma. It is seen in 10–45% cases of multiple fractures and is an important cause of morbidity and mortality (11%) in multiple fracture and multisystem injuries**.**

Etiology

Common etiological factor is a long bone fracture in young adults or a pelvic fracture in elderly.

Pathogenesis

Following injury, the bone marrow fats or the platelet agglutination are sucked into the injured vessels and are transported to various sites as emboli giving rise to varied clinical manifestation.

Source of Fat

It could be from two sources:

- From bone marrow (accepted).
- From plasma by agglutination of chylomicrons which later acts as an embolus (less accepted).

Classification (Sevitt's)

1. **Classical type:** In this variety the onset is less than 24 hours, *tachycardia* is greater than 140/min, *pyrexia* is greater than 40°C, *tachypnea*, *cyanosis*, changing *cerebral signs* vary from confusion, restlessness and coma. *Petechial rashes* and in *conjunctiva of lower lids, if present is pathognomonic.* In this type, the blood pressure is maintained throughout.
2. **Fulminating type:** Here the sequence of events are very fast and there is no time for the rashes to develop. Patient is comatose within hours and throws repeated seizures. Patient rapidly collapses and death supervenes.
3. **Incomplete type:** The manifestation is between the two types unexplained tachycardia, fever and rash are its features.

Investigations

- *X-ray of the chest* may show snowstorm appearance and if seen is pathognomonic **(Fig. 8.1)**
- PaO_2 less than 60 mm Hg.

JAYPEE BROTHERS

- Platelet counts less than 1.5 lakhs.
- ECG shows prominent S-wave.
- **Gurd test:** Isolation of fat emboli from the blood.
- There is no pathognomonic laboratory test.

Remember

The important diagnostic triad in ARDS is represented by the mnemonic TPR
- Thrombocytopenia.
- PaO_2 <60 mm Hg.
- Rashes.



Fig. 8.1: Plain X-ray of the chest showing snowstorm appearance in ARDS.

Management

There are two important steps in the management of ARDS: *Nonspecific* consists of three vital steps:
1. **Keep:** (a) airway patent, and (b) fracture immobilized by POP or external fixators.
2. **Restore:** (a) blood volume, (b) fluid, and (c) electrolyte balance.
3. **Avoid:** (a) careless handling of the injured, (b) unnecessary transportation.

Specific: Again three vital steps are described:
1. **Oxygen administration:** To restore back PaO_2.
2. **Drug therapy:** Steroids are given intravenously. These help gas exchange by decreasing inflammation in the lungs.
   - *Heparin:* This acts as a lipolytic and antiplatelet agent.
   - *Low molecular weight dextran:* Acts by increasing plasma volume.
   - *Intravenous alcohol* is not universally advocated.
   - *Antibiotics* and other treatment.
3. **Definitive fracture treatment:** Discussed in appropriate sections.

COMPARTMENTAL SYNDROME OF FOREARM

This is one of the most dreaded complications in orthopedics and ranges from mild ischemia to severe gangrene.

Definition

It is an ischemic necrosis of the structures contained within the volar compartment of the forearm.

Incidence and Etiology



Fig. 8.2: Lying prone on the forearm in an inebriated condition.

It is common in children less than 10 years of age. Supracondylar fracture is the most common cause in children. Crush injuries of the forearm are the most common causes in adults. Occasionally fracture of both bones of forearm may be the cause. More recently intra-arterial injections in drug addicts who lie on their forearm for prolonged periods in narcotized conditions are mooted to be a cause **(Fig. 8.2)**. Improper application of splints is another important cause.

Usually the flexor muscles of the forearm, especially the flexor digitorum profundus, flexor pollicis longus and rarely flexor digitorum superficialis are involved.

JAYPEE BROTHERS

Pathology

It is an inelastic and unyielding deep fascia surrounds the forearm muscles. Rise in the intracompartmental pressure due to any cause is not accommodated and the vessels are compressed resulting in muscle ischemia and consequent fibrosis **(Fig. 8.3)**.

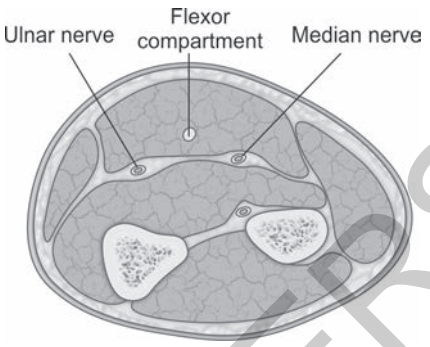

Fig. 8.3: Compartments of the forearm.

Clinical Features

Impending Volkmann's ischemia: In the acute stages patient gives history of trauma and after an interval of few hours, severe, poorly localized pain develops in the forearm. The volar aspect of the forearm is swollen, red, warm, tender and tense. Fingers are held in flexion and attempt to extend the fingers increase the pain (stretch pain) **(Fig. 8.4)**. Peripheral pulses, which are present initially, disappear later. Median nerve is more commonly affected than the ulnar nerve **(**See **Box 8.2)**.

***Note** in compartment syndrome, patient complains of pain out of proportion to the injury.*

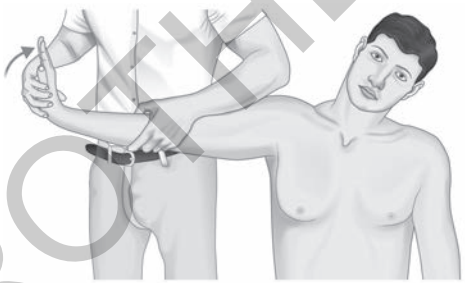

Fig. 8.4: Method of eliciting stretch pain.

Management

Acute Stage

It is a surgical emergency. All encircling tight bandages are removed if present. If there is no improvement, record the pressure within the compartment. If it is more than 30 mm Hg, an emergency surgical decompression is done by fasciotomy **(Figs. 8.5A and B)**. If the pressure is less than 30 mm Hg continuous monitoring is done **(Box 8.2)**.

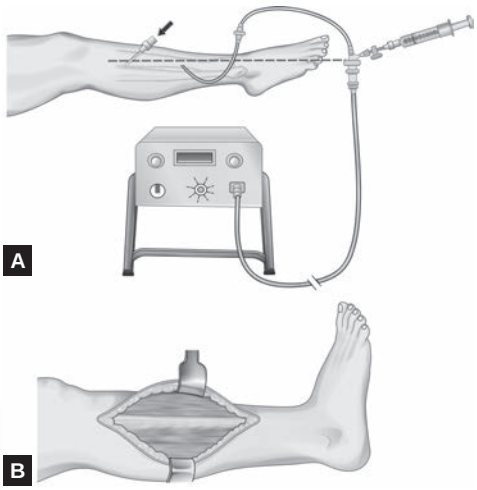

Figs. 8.5A and B: A wide fasciotomy for acute compartmental syndrome.

Remember

If 5 Ps helps in detection of acute cases, 5 Ps also form clue to the management.

- **P**ressure to be relieved either external or internal.
- **P**ressure to be monitored within the compartment.
- **P**ulse to be recorded continuously.
- **P**assive stretch test indicates the severity.
- **P**utting the fracture back into its position.

Late Cases (Volkman's Ischemic Contracture)

If mild, flexion contractures of flexor digitorum profundus and flexor pollicis longus develops but in severe cases all the finger flexors, thumb and wrist flexors are affected. The forearm is thin and fibrotic. Extensive scar tissue may be present. Peripheral nerves may be affected, amongst them median nerve is the most commonly involved. A *classical claw hand* deformity results. Joint

JAYPEE BROTHERS

Box 8.2: Impending Volkmann's ischemia is detected by 6 Ps.

- **P**ain
- **P**allor
- **P**aresthesia
- **P**aralysis
- **P**ulselessness
- **P**ositive passive stretch test

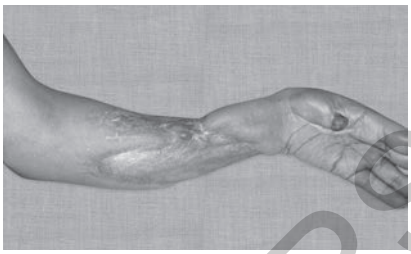

Fig. 8.6: Volkman's ischemic contracture of the forearm.

contractures and gangrene may also be seen **(Fig. 8.6)**. Of particular importance is eliciting the *Volkmann's sign* in established VIC. *This test consists of extending the wrist, which exaggerates the deformities, and on flexion, the deformities appear less prominent* **(Fig. 8.7)**.

Treatment

Here the contractures are well established and the treatment plan depends upon the severity of VIC.

Mild Type

- Dynamic splinting.
- Physiotherapy.
- Total excision if single muscle is involved.

Moderate Type

- ***Max page's muscle sliding operation:*** This consists of releasing the common flexor origin from the medial epicondyle and passively stretching the fingers. This slides the origin of the muscle down and releases the contractures.
- **Excision of cicatrix.**
- **Neurolysis:** It consists of freeing the peripheral nerves from the surrounding fibrous tissue.
- **Tendon transfers** are done if criteria are met.

Severe Type

- Excision of the scar.
- Seddon's carpectomy—it consists of excising the proximal row of carpal bones thereby shortening the forearm to overcome the effects of contracted muscles.

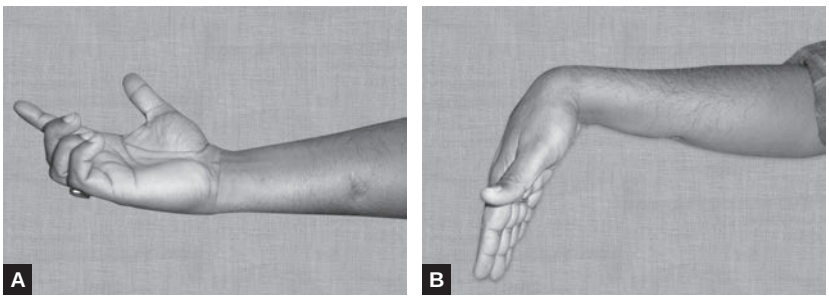

Figs. 8.7A and B: Volkman's sign.

JAYPEE BROTHERS

- *Arthrodesis* of the wrist in functional position.
- *Amputation* for very severe cases of VIC with gangrene.

DELAYED UNION AND NONUNION

The difference between delayed union and nonunion is of degree. In delayed union healing has *not advanced* at the average rate for location and type of fractures but healing can still take place if the limb is immobilized for a longer period. In nonunion there is evidence to show clinically and radiologically that healing has *ceased* and union is improbable and needs surgery. Final status of nonunion is pseudoarthrosis.

Definition (FDA Panel)

Nonunion is said to be established when a *minimum of nine months* has elapsed since the injury and the fracture shows no radiologically visible progressive signs of healing continuously *for 3 months*.

Classification of Nonunion

Muller and Weber depending on the amount of callus adopt two types **(Table 8.1)**.

Table 8.1: Showing types of nonunion.

Hypervascular nonunion	***Avascular nonunion***
Hypertrophic nonunion (exuberant callus)	Torsion wedge
	Comminuted nonunion
Horse hoof nonunion	Defect nonunion
Oligotrophic nonunion	Atrophic nonunion

Hypervascular Nonunion (Figs. 8.8A to C)

In this, the fracture ends are viable and show biological reaction, hence, stable internal fixation is enough and no bone grafting is required.

Avascular Nonunion (Figs. 8.9A to D)

In avascular nonunion the fracture ends are not viable due to the poor blood supply. No biological reaction is seen, and this needs rigid internal fixation with bone grafting after decortications of nonviable ends.

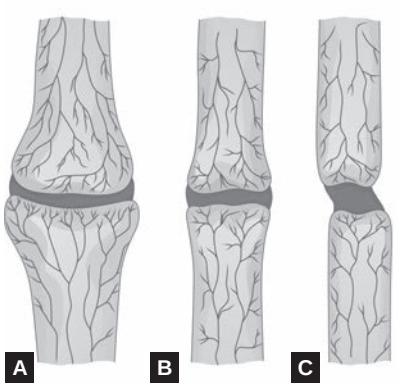

Figs. 8.8A to C: Hypervascular nonunion—elephant foot.

Causes for Nonunion

Compound fractures, infection, segmental fractures, distraction of fracture fragments, soft tissue interposition. It obstructs the growth of internal callus and thus jeopardizes union. Ill-advised open reduction, insecure and inadequate fixation of fracture.

Apart from these local factors, the general factors, which contribute to poor healing of fractures, are anemia, general debility, cachexia, steroid therapy, osteoporosis, malignancy, etc.

JAYPEE BROTHERS

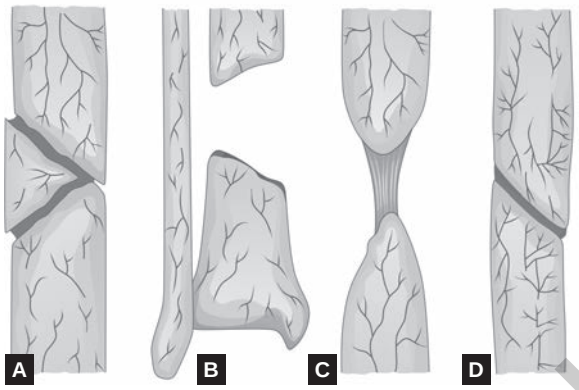

Figs. 8.9A to D: Avascular nonunion.

Clinical Features

Symptoms: The acute symptoms seen in fresh fractures are conspicuously absent in nonunion. There is usually history of no pain or minimal pain. There could be presence of a deformity or loss of function.

Signs: The important clinical signs are painless abnormal mobility, no crepitus, shortening, scars and sinuses, deformity, wasting of limb muscles, etc. **(Fig. 8.10A)**.

Note: In delayed union, patient complains of dull pain at the fracture site and deep palpation clinical tenderness.

Investigations

Radiograph of the part in AP and lateral views **(Fig. 8.10B)**.

Management Principles

- Nonunion is an absolute indication for surgery and it requires open reduction, rigid internal fixation and bone grafting.
- There is no role of conservative treatment.
- Other methods of treatment include electrical stimulation, interlocking nails, Ilizarov, excision, etc.

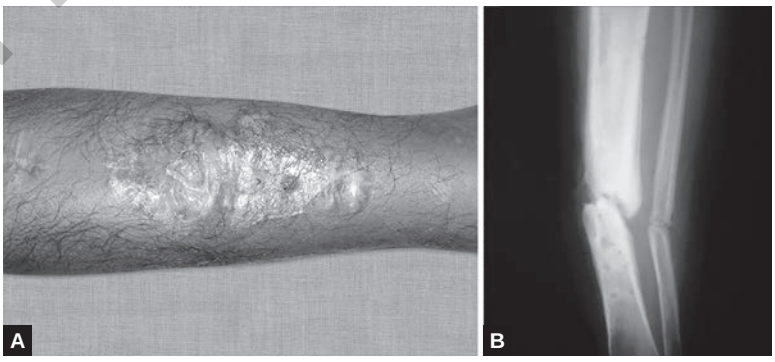

Figs. 8.10A and B: Infected nonunion of tibia.

JAYPEE BROTHERS

- In delayed union, most of the fractures unite when immobilization is further continued for several weeks. In comprehensive cases, surgery is the treatment of choice.

Other Measures

- **Masterly activity:** Do you remember the axiom "leave the sleeping tiger alone"? Well in certain situations nonunion that do not cause significant functional impairments can be left alone (e.g., scaphoid nonunion).
- **Resection of the fragments:** Certain non-viable small bone pieces can be safely excised (e.g., distal end of ulna) and in some other situations like nonunion fracture neck femur, the bone is excised and replaced with a prosthesis to make good the loss.

Role of Ilizarov in nonunion: This allows simultaneous correction of all deformities and bone loss. In hypertrophic nonunion gradual compression helps. In avascular nonunion corticotomy, bone transport and compression helps. Ilizarov provides dramatic results but is technically very demanding. It is still the best way to treat cases of infected nonunion.

AVASCULAR NECROSIS (AVN)

Avascular necrosis is a rare but severe complication of certain fractures. It occurs when the blood supply to a segment of bone is affected.

Causes

- Extensive stripping of soft tissues, which damage the periosteal blood supply.
- In certain bones where the blood supply is unique and unidirectional, e.g., talus, scaphoid, neck of femur **(Figs. 8.11A to C)**.
- Other causes like steroid therapy, Caisson's disease, etc., which may cause on embolic block of the blood vessels.

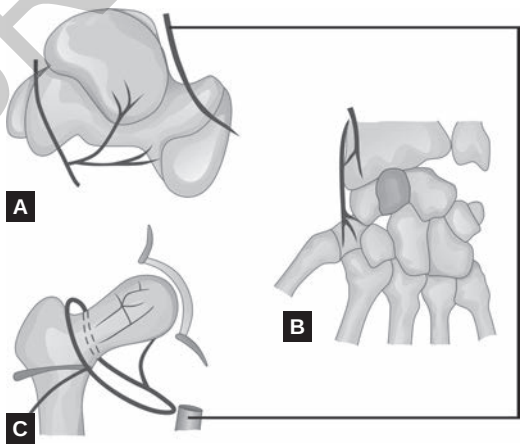

Figs. 8.11A to C: Due to the peculiar blood supply, avascular necrosis is common in the above three bones: (A) Talus; (B) Scaphoid; (C) Head of femur.

Common sites of AVN are head of femur in fracture neck of femur and dislocations of hip, body of the talus in fracture through the neck of talus, proximal pole of scaphoid in fracture through the waist of the scaphoid.

Problems in avascular necrosis: The loss of blood supply to a major bone segment impairs healing because the avascular segment cannot participate in the reparative process. This defective healing makes the bone weak and susceptible to external forces. This results in collapse of the bone and late osteoarthritic changes.

Clinical Features

Avascular necrosis of a bone is usually asymptomatic in the early stages. In the later stage patient may complain of pain, limp and slight loss of movements. In very advanced cases patient will show features of osteoarthritis.

JAYPEE BROTHERS

Investigations

In the early stages, avascular necrosis can be detected by bone scan, radioisotope study, etc. In the later stages, radiograph shows dense changes in the bone, collapse and osteoarthrotic features **(Fig. 8.12)**.

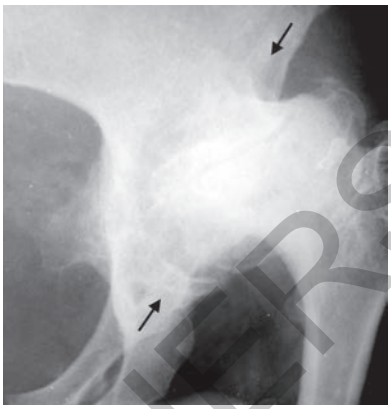

Fig. 8.12: Avascular necrosis of femoral head.

Treatment

Early stages require no treatment. Protective braces may be given to prevent bone collapse. Surgical decompression has a doubtful role. In the late stages, total hip replacement is advocated for AVN head of the femur. AVN in scaphoid needs open reduction and bone grafting.

Other Measures

- **Revascularization methods:** Meyer's muscle pedicle graft is a famous example of revascularization procedures for AVN head of femur following fracture of the neck of femur.
- **Resection and replacement (remember R's):** Hemi-replacement arthroplasty with Austin Moore's prosthesis or Thompson's prosthesis is a famous example.
  - Total joint replacement of hip and knee for advanced secondary osteoarthritis following AVN.

TRAUMATIC MYOSITIS OSSIFICANS

Definition

It is a reactive lesion occurring in the soft tissues and at times in the bone periosteum. It is characterized by fibrous, osseous and cartilaginous proliferation of the subperiosteal hematoma. This is later followed by metaplastic changes.

Causes

- **Trauma:** This has a definitive role in the causation of myositis ossificans.
- **Simple blow or repeated minor trauma**
- **Dislocations and avulsion injuries:** Because of the violent stripping of the periosteum and damage to the muscles.
- **Ill-advised massage:** This is by far the most common cause for myositis.

Interesting facts about myositis ossificans

- It is more common is children due to loose periosteum attachment
- Patients with head injury, paraplegia are more prone
- Commonest cause is ill-advised massage.

Pathology: Muscle is commonly involved, but fascia, tendon and periosteum can also be affected. The process is a peculiar alteration within the ground substance of the connective tissue associated with proliferation of undifferentiated connective tissue.

JAYPEE BROTHERS

Remember

Myossitis ossificans
Muscles commonly involved are:
- Brachialis anticus.
- Quadratus femoris.
- Adductor muscles of the thigh.

Note: All these muscles take origin from a wide area-suggesting role of periosteum in its genesis.

Clinical Features

In the acute stages, patient may complain of pain, swelling and loss of movements. On examination, there may be tenderness. In the late stages, there is no pain and a bony hard lump may be palpated. This may act as a mechanical block to the movements.

Remember

Areas commonly affected
- Elbow joint common in young athletes.
- Ankle joint—known as footballer's ankle.
- Knee—known as Pellegrini–Stieda disease.
- Shoulder.
- Hip.
- In head injuries it is more common.

Investigations

Radiography has little role in the *acute stages* but in the late stages a bony growth may be evidently seen **(Fig. 8.13)**.

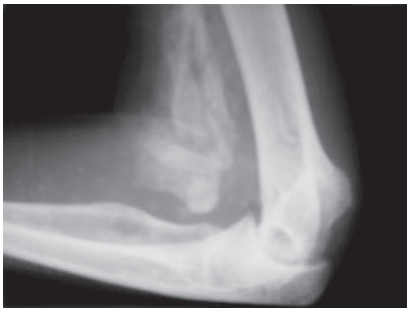

Fig. 8.13: X-ray showing traumatic myositis ossificans.

Treatment

Prevention: Remember the famous adage "*prevention is better and than cure*". It suits this conditions completely. Refraining from the ill-advised massage and handling the injured with care prevents this condition from raising its ugly head.

Curative Measures

- **Acute stages:** *Conservative* treatment is the method of choice and consists of the following:
  - *Immobilization of the part by splints, etc.*
  - *Drugs*—bisphosphonate therapy, calcitonin and nonsteroidal anti-inflammatory drugs (NSAIDs), it can be recommended.
  - *Physiotherapy:* Active physiotherapy is encouraged and passive stretching is avoided.
  - *Manipulation is done under anesthesia*: It is a double-edged sword and has to be done very carefully. *Adhesions should snap abruptly and should not be broken gradually.*
- **Chronic stages:** Surgery is the treatment of choice and consists of soft tissue release and excision of bony spur when it is well formed.

JAYPEE BROTHERS

for detailed information on orthopedic books, visit our website www.jaypeebrothers.com, for detailed information on orthopedic books, visit our webs

TEXTBOOK FOR ORTHOPEDIC ASSISTANTS AND PLASTER TECHNICIANS

Salient Features

The book focuses on being educative and presents an enjoyable reading. I am confident that it will be received well.

- This book is for students pursuing diploma and degree in plaster courses.
- It is the first ever compact and comprehensive small book for students of plaster course.
- Each and every chapter has been thoroughly planned and written.
- Each chapter has good and explicit diagrams.
- The book contains relevant clinical photographs and X-rays.
- For certain practical application in orthopedics, such as reduction of a fracture or a dislocation, live practical steps have been used as illustrations.
- This book is also useful for postgraduate students, DNB students, young orthopedic surgeons, nurses, and paramedics.

John Ebnezar, a "Padma Shri" and "Dr BC Roy National Awardee", is a prolific orthopedic writer with two Guinness World Records in book writing in 2010 and 2012, respectively. He has over 200 books in orthopedic to his credit, and no other orthopedic surgeon in the world has come anywhere close to him in the number of books he has authored in his field. He has another World Record (2012) of writing 103 books in a single calendar year, a feat unmatched by anyone in the world. He is an outstanding academician, researcher with three best research awards, editor, publisher (seven books), and contributor. He pioneered a revolutionary new treatment method in orthopedics called the Wholistic Orthopedics. He is a leader in community and social works with six Guinness World Records in social services in 2015, 2016, and 2018. He is a philanthropist and humanist, eminent teacher, excellent orator, founder of new professional bodies such as Geriatric Orthopedic Society of India and Orthopedic Author's Club. He has his own orthopedic academy for promoting orthopedics and own trust for community activities. He is a Cultural Ambassador, head of various professional bodies, and former Vice President of Indian Orthopedic Association. He is an entrepreneur with three orthopedic centers and a recipient of over 350 international-, national-, and state-level awards for his outstanding contribution to the field of orthopedics.

In 2016, the President of India awarded him the coveted "Padma Shri" in the field of orthopedics. He is the first and the only Karnataka Orthopedic Surgeon and only the 15th from all over India to get this coveted honor. He has also received the most prestigious "Dr BC Roy National Award", the highest award in the field of medicine in India. He is the first orthopedic surgeon from Karnataka and only the 10th Orthopedic Surgeon in the country to receive this coveted award. He has the rare honor of getting both the top national honors in a single calendar year, a feat unmatched by any doctor in India. He has also received another national award from the Medical Council of India, "The Silver Jubilee Research Award", in 2017.

This book, like all his other books, carries the flavor of simple and lucid writing, excellent language, beautiful illustrations, and excellent presentation of the topics required by the students pursuing the course of plaster technician.

Rakesh John FRCS(England) FRCS(International) MRCS(England) MBBS MS(Ortho) DNB Dip. SICOT MNAMS is an Orthopedic Surgeon. He completed his MS Orthopedics in 2014 from PGIMER, Chandigarh, Punjab, and has also cleared DNB and MRCS (England) examinations. He is a double FRCS, with FRCS (International) and FRCS (Ortho). He is currently a consultant at Macclesfield, Cheshire, England, and United Kingdom. Earlier he worked as a Senior Resident, Department of Orthopedics, PGIMER, Chandigarh. He has several publications to his credit, and his dissertation research on the "Role of gene polymorphisms in anterior cruciate ligament (ACL) tear in the Indian population" has found acceptance in international journals. He has completed the Asian Association of Dynamic Osteosynthesis (AADO) fellowship in trauma and has made presentations in several international and national forums. He was an Upper Limb Fellow, Wirral University Teaching Hospital, UK, and Arthroscopy & Sports Medicine Fellow, QEII Hospital, Halifax, NS, Canada. Apart from being a brilliant academician, writer, speaker, and surgeon, he is a well-trained singer.

Printed in India

Available at all medical bookstores
or buy online at www.jaypeebrothers.com



JAYPEE BROTHERS
Medical Publishers (P) Ltd.
EMCA House, 23/23-B, Ansari Road,
Daryaganj, New Delhi - 110 002, INDIA
www.jaypeebrothers.com

Join us on facebook.com/JaypeeMedicalPublishers

Shelving Recommendation
ORTHOPEDICS

