edic books, visit our website www.jaypeebrothers.com, for detailed information on orthopedic books, visit our website www.jaypeebrothers.com, for detailed information on orthopedic boo

Complimentry Online
3 Videos
Duration 1 hour 40 minutes

5th Edition



Tanna's Interlocking Nailing

DD Tanna
Sushrut Babhulkar

JAYPEE

Contents

1. Introduction to Interlocking Nailing **1**

DD Tanna

Evolution *1*; Biomechanics *1*; Biology *1*; Fracture Healing Following Intramedullary Nailing *2*

2. Interlocking Tibia Nail **3**

DD Tanna

Indications for Interlocking Nailing *6*; Preoperative Assessment for Interlocking Nail *6*; Closed Nailing of the Tibia *7*; Procedure *7*; Distal Locking *12*; Traps to be Avoided During Interlocking Tibia Nail *17*

3. Lower One-third Fracture of the Tibia **18**

Sangeet Gawhale

Distal Third Tibial Fractures *18*; Anatomy *18*; Which Fractures can be Nailed? *19*

4. Upper One-third and One-fourth Tibia **27**

Sunil Kulkarni

Anatomy of Proximal Tibia *27*; Intramedullary Nailing *28*; Preparation *28*; Positioning and Entry Point *28*; Authors' Preferred Method *30*; Reduction *30*; Poller Screws *30*; Nail Locking *32;* Cases *33*

5. Suprapatellar Nailing for Tibial Fractures **36**

Wasudeo Gadegone

Implant Specification *37*; Indications of Suprapatellar Nailing *37*; All Indications of Conventional Infrapatellar Nailing *37*; Illustrative Cases *43*

6. A New Approach for Dealing with Upper Third Tibia **46**

Sushrut Babhulkar

Advantages *46*; Position of Leg *46*

7. Locked Nails of the Femur **49**

Sushrut Babhulkar

Closed Nailing of the Femur *49*; Procedure *50*

8. Tips on Tibia and Femur **57**

DD Tanna

Observations and Tips in the use of the Interlocking Nailing Procedure in the Tibia and Femur *57*

9. Open Fractures **61**

Sudhir Babhulkar

Infection *65*

10. Interlocking Nailing in Open Fractures 67

Dheenadhayalan Jayaramaraju, Sindhura Yamajala, Nagashree Vasudeva, Shanmuganathan Rajasekaran

Location of the Fracture *67*; Reamed versus Unreamed Nailing *68*; Patient Selection and Decision Making *69*; Prerequisites for Primary Intramedullary Nailing *69*; Initial External Fixation Followed by Delayed Reamed Intramedullary Nailing *71*; Complications of Primary Interlocking Nailing *72*

11. Reaming 75

DD Tanna, Sushrut Babhulkar

Reaming in a Nonunion or a Malunion *77*; Controversy Over Reamed and Unreamed Nails *78*; Reaming in Osteopetrosis or Marble Bone Disease *79*; New Developments in Reaming *79*

12. Nonunion Aseptic 81

Ulrich Holz

Management of Noninfected Tibia Nonunions *82*; Nonunion Proximal Tibia *82*; Metaphyseal and Diaphyseal Nonunion *82*; Nonunion Distal Tibia *84*; Infected Nonunion *86*; Congenital Pseudarthrosis of the Tibia *87*

13. Complications Associated with Procedure of Nailing and Locking and Implant Removal 91

DD Tanna

Broken Drill Bit *92*; Broken Screw *93*; Bending of Nail *93*; Nail Breakage *93*

14. Complications of Internal Fixation by Proximal Femoral Nail 107

Wasudeo Gadegone

Indications of Short Proximal Femoral Nail *108*; Indications of Standard Proximal Femoral Nail *108*; Indications of Long Proximal Femoral Nail *108*; Contraindications *108*; Method of Proximal Femoral Nail Surgery *108*; Complications *112*; Prevention of Complications *117*

15. Ipsilateral Femoral Neck Fracture and Shaft Femur Fracture 119

Sushrut Babhulkar, Sudhir Babhulkar

Mechanism of Injury *119*; Management *120*; Illustrations *127*; Postoperative Protocol *127*; Complications *127*

16. Subtrochanteric Fractures 129

DD Tanna

Classification *130*; Biomechanical Factors *131*; Intramedullary Devices *134*; Procedure *134*; Discussion *142*; Painful Hardware *149*

17. Fractures of Proximal Femur 151

DD Tanna

Procedure *154*; Problems and their Solutions *155*; Subtrochanteric Fracture *155*

18. Are We Overselling Proximal Femur Nail? 162

DD Tanna, Sachin Yadav

19. Supracondylar Nail 172

Sushrut Babhulkar

Surgical Technique *173*; Postoperative Care *176*; Planning the Surgery in Intra-articular and Supracondylar Fractures *176*

20. Fracture Humerus Interlocking Nail 185

Shivshankar

Procedures *186*; Clinical Case 1 *194*; Clinical Case 2 *195*; Clinical Case 3 *196*; Clinical Case 4 *198*; Clinical Case 5 *206*; Polaris Nail for Proximal Humerus Fracture *208*

21. Nailing in Proximal Humerus Fractures 211

Shailesh Pai

Procedure for Nailing *213*; Postoperative Rehabilitation *214*; Case Examples *215*; Biomechanical Advantages over Philos Plating *217*

22. Tibiotalocalcaneal Nailing Technique Using Retrograde Intramedullary Nail 219

Sampat Dumbre Patil

Indications *219*; Preoperative Planning *219*; Operative Technique Tibiotalocalcaneal Fusion *220*; Surgical Technique Through Some Case Examples *222*; Surgical Steps of Tibiotalocalcaneal Nailing *223*; Postoperative Protocol *229*; Complications of Tibiotalocalcaneal Nailing *229*; Case Examples *229*

23. Retrograde Tibial Nailing for Arthrodesis of Ankle and Subtalar Joints 235

GS Kulkarni

Indications for retrograde nailing *235*; Clinical Cases *239*; Calcaneal screws *242*; Proximal Tibial Screws *242*; Postoperative Care *242*; Discussion *242*

24. Modified Ender Nailing of Long Bone Fractures (Femur, Humerus, and Tibia) 246

Jawahar T Jethwa

Introduction to Modified Ender Nailing *246*; Evolution of Ender Nails *246*; Ender Nails: Biomechanical Considerations *248*; Intertrochanteric Fracture Morphology and the Principles of Fixation *250*; Elements of a Typical Implant Assembly for Intertrochanteric Fracture Fixation *250*; Concept of Turbo Screw *250*; Contouring of Nails and their Purposes *253*; Sequences of Placements of Ender Nails and Screws *254*; Instruments *254*; Preoperative Workup *255*; Typical Operation Room Setup for Proximal Femoral Fractures *255*; Operative Steps for Intertrochanteric Fracture Fixation *257*; Tips and Tricks for Reducing Fracture *259*; Modification for Challenges of Subtrochanteric Fractures *259*; Concept of "Forget Lateral Wall" Fixation *263*; Modified Ender Nailing Fixation in Segmental Fracture *263*; Modified Ender Nailing for Humerus Diaphyseal Fractures *264*; Modified Ender Nailing for Tibial Diaphyseal Fractures *269*; Concluding Comments by the Author *275*

25. Locking Plates 276

DD Tanna

Biomechanics *276*; Special Considerations for use of Locking Plate *278*; Principles of Use *279*; Indications *284*; Biomechanical Basis *284*

26. Overkill in Orthopedic is a must in Junctional Fractures 292

DD Tanna

27. New Developments and Perspectives **298**

DD Tanna, Sushrut Babhulkar

Advantages *298*; Telescoping Locking Nails *298*; Future Thoughts *300*

28. What We did not Teach in Workshops? **301**

DD Tanna

Tibia *301*; Femur *305*; Forearm Interlocking Nail *307*; Humerus Fracture Shaft *308*; Humerus Fracture Neck *308*; Nail Length *309*; Malpositioned Un-United or United Distal Fracture of Tibia *309*

29. Clinical Cases **312**

Nonunion Caused by Using a Noninterlocking Nail in Unstable Situation *347*; Nonunion Caused by Using a Nonbiological Plating in Unstable Situation *348*; Difficult Situation *350*; Proximal Tibia Nailing *352*; Miscellaneous *354*

Index **359**

CHAPTER

20

Fracture Humerus Interlocking Nail

Shivshankar

JAYPEE BROTHERS

INTRODUCTION

Intramedullary nailing in femur and tibia is the accepted modality of the treatment due to its efficacy of treating lower extremity fractures has been documented in many studies. Intramedullary nailing offers the benefits of anatomic alignment, semirigid fixation with limited soft tissue dissection, and early rehabilitation of the injured limb. However, the indications for intramedullary nailing in humeral fractures should be viewed with caution. The anatomy and function of the humerus are quite different from those of the long bones of the lower extremity:

- The humerus is not a "weight-bearing" bone; therefore, rigid internal fixation is not needed to maintain limb function during fracture healing.
- Whereas the intramedullary canal widens in the metaphyseal area of the tibia and femur, the humeral canal narrows significantly, increasing the risk of distal fragment comminution **(Figs. 1 and 2)**.
- The anatomy of the upper arm also predisposes the patient to an increased risk of soft tissue injury, particularly the rotator cuff.
- The potential for neuromuscular injury is greater in humerus nailing than in the nailing of lower extremity fractures.
- The humerus bone on either side has highly mobile joints and also the entry to the humerus bone both by prograde and retrograde is eccentrically placed unless the entry is taken through the joint surface.

Before embarking on humerus nailing, one should understand the obstacles that can be encountered.

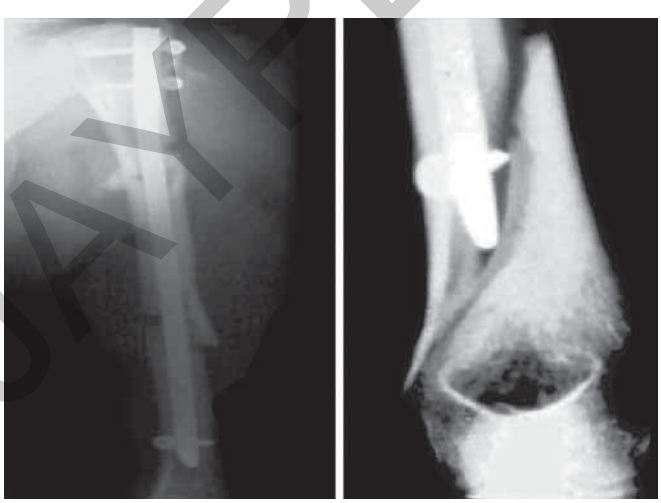

FIG. 1: If nail is too long, it can create fracture at lower end.

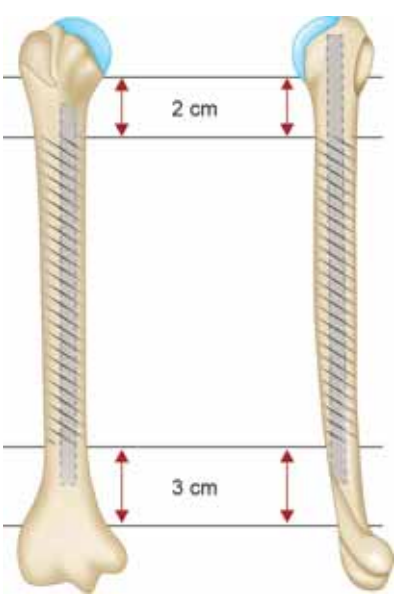

FIG. 2: Ideal zone for interlocking.

An adequate planning will minimize these difficulties. The rotator cuff injury, proximal humerus articular cartilage destruction, radial nerve injury, and extension of comminution are all possible complications of this procedure. Area of humerus shaft which can be nailed is limited by its anatomy **(Fig. 2)**.

PROCEDURES

Patient Positioning

The patient should be positioned on a radiolucent table that allows visualization of the whole upper extremity on the C-arm. The C-arm should be positioned on the side opposite to the fracture to prevent the C-arm bar from interfering with the maneuverings **(Fig. 3)** during the surgery and to allow easy handling of instrumentation. It is mandatory before starting the surgery to make sure that the rails and supports in the table do not block visualization of the whole length of the humerus **(Fig. 4)**.

Small angulation of the C-arm will be helpful, especially in beach chair position **(Fig. 5)**. In supine position, the C-arm is placed on the opposite as shown in **Figure 6**.

The patient should be positioned supine or in beach chair position **(Fig. 5)**, starting *from the head end* of table, so that surgeon can work from the head end during surgery. A roll is placed under the scapula, which extends the shoulder to expose the humeral head from under the acromion.



FIG. 3: Positioning of shoulder under C-arm.



FIG. 4: Patient position (supine).



FIG. 5: Beach chair position keep C-arm tilted like this.



FIG. 6: Keep C-arm on opposite side.

JAYPEE BROTHERS

Incision Planning

Nowadays most surgeons including me use a percutaneous entry site with a small stab incision in line of deltoid fibers on the skin confirming the line of the medullary cavity on C-arm. Humeral head under anesthesia as well as due to extension by the roll placed under the scapula brings out the entry point of the shoulder in front of the acromion. Entry point more medial on the tuberosity may avoid injury to the cuff, also the incision in line with deltoid fibers will decrease the chances of inadvertent incising of the rotator cuff. Some nails have a small lateral bent proximally and they can be entered by a more lateral entry and they can avoid the injury to the rotator cuff to a great extent. But as the entry is very eccentric to the medullary canal, the chances of iatrogenic fracture of the medial wall are to be high and I have no personal experience with that entry. Theoretically injury to cuff is very minimal if at all by this entry site.

Conventional Nailing

When carrying out nailing of proximal humerus fractures, the proximal fragment is commonly in a marked abducted position due to contraction of the muscles. To judge entry site and plan rotator cuff incision, it is important to fully adduct the proximal humerus fracture. Proximal fragment adduction will assure adequate visualization of the rotator cuff before incision.

To decrease trauma to the rotator cuff, the optimal surgical incision site should be chosen. This may be difficult to palpate in case of a recent upper extremity fracture due to edema and hematoma. It is helpful to use a 1.5 or 2 mm K-wire to locate the anterior edge of the acromion as it intersects the longitudinal axis of the humeral canal. The first lateral skeletal projection that is palpated is usually the humeral head with the acromion being somewhat superior but more medial in direction. The image intensifier can help visualize the acromion and thus, differentiate it from the head of the humerus. Once the acromion edge is located, K-wire is inserted at the junction of articular and nonarticular part of the head as seen on C-arm image intensifier and its position and direction entering into the medullary canal is confirmed under C-arm both in anteroposterior (AP) as well as by internally or externally rotating the proximal fragment, then the incision is made in line with the deltoid fibers. A 1–1.5-cm incision over this K-wire is usually adequate to carry out nailing of the humerus percutaneously. An incision in line with the deltoid fibers taken or spreading of the muscle fibers with blunt dissection can be performed. But, if one wants to visualize the rotator cuff, a larger incision of 3 cm may be required. The skin and subcutaneous tissues are incised sharply. Elevation of the subcutaneous fat from the deltoid epimysium is helpful to expose the fascia plane between the anterior and middle third of the deltoid muscle fibers. An incision in line with the deltoid fibers or spreading of the muscle fibers with blunt dissection can be performed. The deltoid bursa is then encountered. Sharp dissection of the deltoid bursa from the rotator cuff is recommended to ensure visualization of the direction of the fibers of the supraspinatus tendon. Before incising, the rotator cuff, a K-wire should again be utilized to identify the optimal entry site.

To decrease rotator cuff trauma and postoperative complications, it is mandatory to make the incision of the rotator cuff sufficiently medial to its insertion site on the greater tuberosity. The rotator cuff does not have enough mobility near its insertion to allow adequate space for handling of the nailing instruments. By proper planning of the incision, the trauma to the rotator cuff can be minimized. The rotator cuff incision should be 1.5 cm in length and in line with the fibers. This incision should be approximately 1–1.5 cm medial to the greater tuberosity, depending on the exact anatomic relationship of the tuberosity and the lateral articular cartilage.

After completing the rotator cuff incision, it is advisable to take the stay sutures in the rotator cuff on both sides of the incision. It is helpful in many ways—first, it enables adequate retraction of the rotator cuff during the entire procedure. Secondly, it enables anatomical closure of rotator cuff.

Here are the steps of percutaneous antegrade humerus nailing as carried out routinely by the author.

Step 1 ***(Fig. 7)***: K-wire of 1.5 or 2 mm is passed just medial to the greater tuberosity on the junction of articular and



FIG. 7: Starting point of entry. Outer border of articular surface and medial to greater tuberosity.

JAYPEE BROTHERS

nonarticular portion erring more on the articular side as that will be more in line with medullary canal. It is recommended that the C-arm image be utilized to confirm a good two-plane position of the K-wire in line with the intramedullary axis of the humerus. In most fractures, adequate external rotation of the proximal arm can be accomplished by manipulation to view both, a frontal and sagittal projection. If rotation is not adequately accomplished by the manipulation, a K-wire may be inserted from the lateral to medial direction to assist in manipulation of the proximal fragment. What is important is that the entry site K-wire should be in line with the medullary canal in two views at 90° to one another.

Step 2: Incision of 1.5 cm taken over the K-wire and by blunt dissection with a hemostat bone is reached **(Fig. 8)**. Care is taken to see that the incision is in line with deltoid muscle fibers and in turn in line with rotator cuff to avoid injury to rotator cuff **(Fig. 9)** and then with a hemostat is deepened up to the bone **(Fig. 10)**.

Step 3: The entry site is enlarged with a 4- or 5-mm cannulated drill bit which has inner diameter of 2 mm, so that long guidewire can be easily passed through this drill bit subsequently **(Figs. 11 and 12)**.

Step 4: After enlarging the entry site with cannulated drill bit over the K-wire, K-wire is withdrawn and a long guidewire of 2 mm is passed through the drill bit into the proximal fragment **(Fig. 13)**.

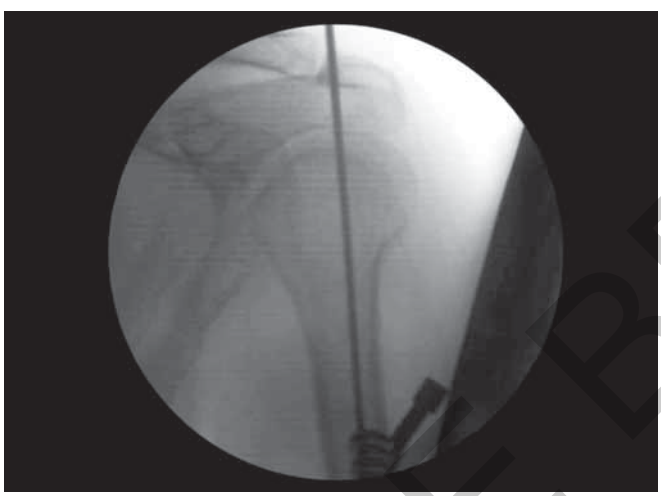

FIG. 8: Starting point of entry as seen in external rotation.



FIG. 9: Incision in line with deltoid fibers over the K-wire.



FIG. 10: Blunt dissection with hemostat.



FIG. 11: A 4-mm cannulated drill bit passed over K-wire.

JAYPEE BROTHERS

Step 5: Assistant gives gentle traction holding the elbow flexed in 90°. As the shoulder is at a higher level, a towel underneath the distal fragment may align the fragment well **(Fig. 14)**. Reduction of humerus fractures usually proceeds smoothly with longitudinal traction provided by an assistant. Occasionally, direct manipulation is required to assist in the passage of the guidewire. The radial nerve is in close proximity to the intramedullary nail, which is susceptible for injury in closed nailing. Proximal fractures may be manipulated by accessory K-wires to properly position the fragments.

Step 6: Surgeon by using the cannulated drill bit as a joystick controls the proximal fragment and advances the guidewire across the fracture site into the distal fragment **(Fig. 15)**.

Step 7: The cannulated drill bit is withdrawn and the entry site enlarged with the entry site reamer of 8 mm which comes with the set or using a cannulated awl **(Fig. 16)**.

Step 8: Reaming is carried out sequentially from 6 mm onward till about 8.5 mm **(Figs. 17 to 19)**. As these reamers come with fixed reamer head, the reaming can be carried out over the simple guidewire itself. Reamer should be passed by pushing wherever it easily goes. Whenever resistance is felt, reaming should be done. While passing across fracture site, reamer should be gently pushed by hand and not while reaming with power to avoid any inadvertent entanglement of

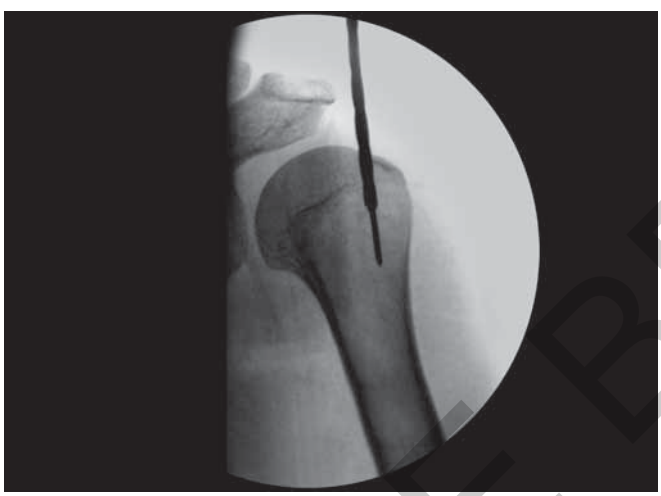

FIG. 12: Cannulated drill bit passed over K-wire.

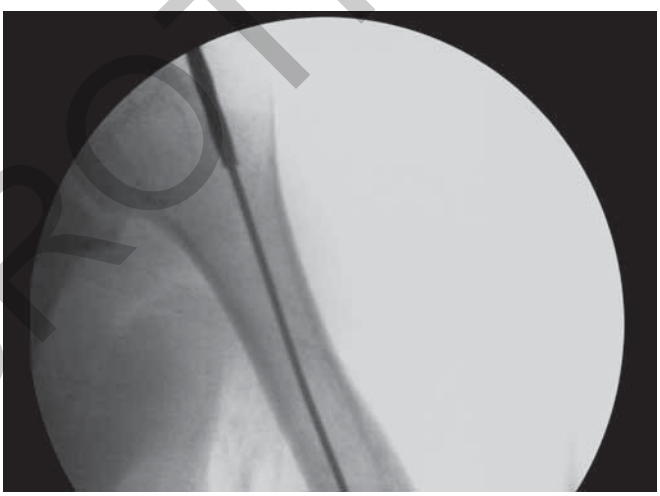

FIG. 13: A 2-mm long guidewire is passed through cannulated drill bit.



FIG. 14: Position of the assistant giving gentle traction. Note the towel under the distal fragment.

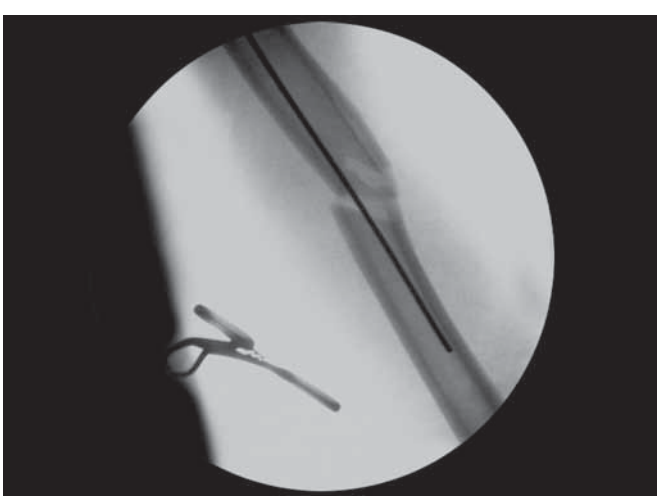

FIG. 15: A 2-mm long guidewire is passed and negotiated across fracture site.

JAYPEE BROTHERS

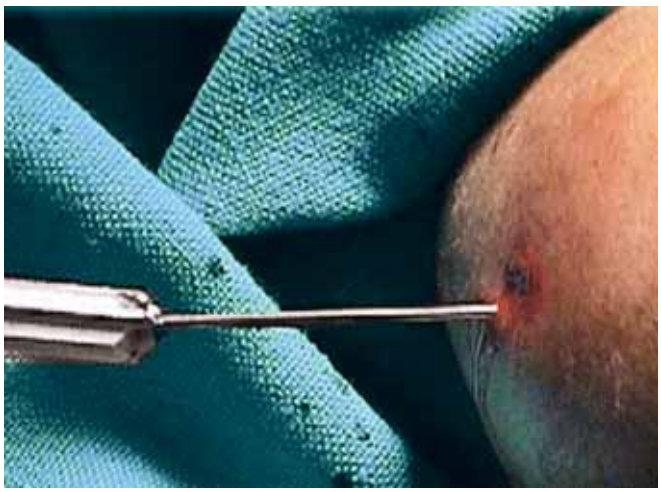

FIG. 16: Over the guidewire entry site enlarged with 8 mm reamer.



FIG. 17: 6–8.5 mm flexible reamer set.

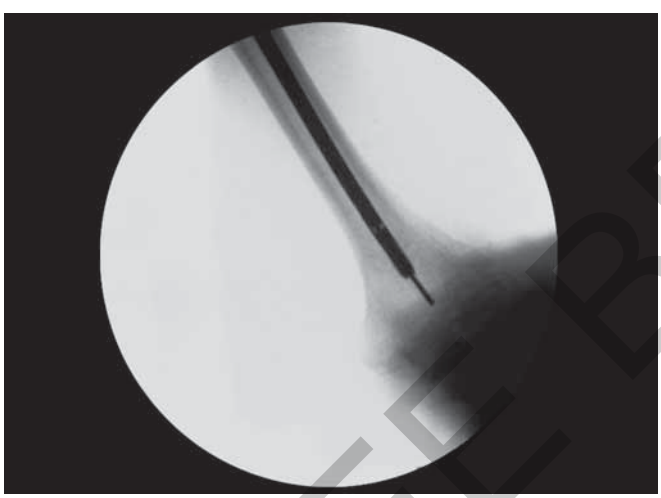

FIG. 18: Reaming with 6 mm reamer.

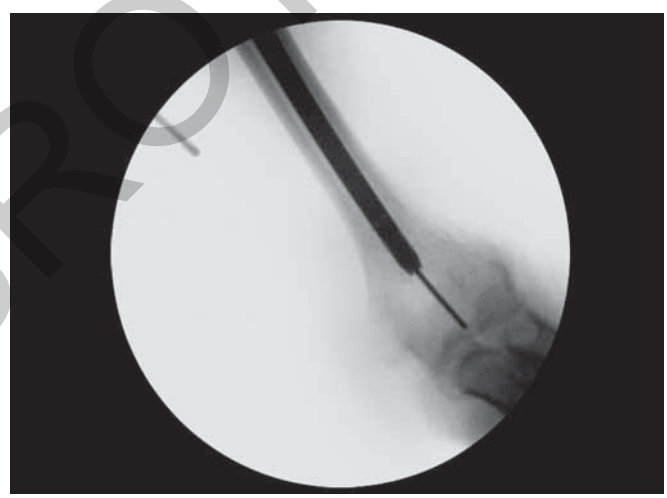

FIG. 19: Reaming with 8 mm reamer.

soft tissues at the fracture site. While reaming traction may not be required and the assistant should hold the reduction manually which is obtained while passing the initial reamers. In comminuted fractures, reamer is just pushed across the comminuted segment and this segment should not be reamed.

Step 9: Normally, the Indian medullary canal can be reamed up to 7.5 or 8.5 mm and a 7- or 8-mm cannulated humerus nail can be passed over the long guidewire **(Fig. 20)**. If the canal is too narrow then a solid nail of 6 mm may have to be used and passed by free hand technique **(Fig. 21)**. While passing the nail, it should be pushed by gentle rotational movements of the fore arm or by gentle blows over the head for insertion or insertion/extraction rod. Care should be taken to see that with each blow the nail advances further into the medullary canal. When the nail reaches the fracture site it should be passed across into the distal fragment only by gentle movements holding the jig. This will prevent inadvertent iatrogenic comminution at the fracture site. Once the nail is negotiated into the distal fragment, the nail is further advanced till the nail tip is about a centimeter from the olecranon fossa. Here too when the nail is being advanced into the distal fragment, a constant watch has to be kept over the fracture site to see if any undue distraction happens. Fracture site distraction can happen as the distal humeral canal is narrow, the nail is straight but the humerus is slightly bent anteriorly leading to the nail tip impinging against the posterior cortex of the distal humerus and the gentle pushing or hammering of the nail can cause distraction at the fracture site. Too much inadvertent distraction is known to cause radial nerve palsy and hence this care. The assistant should give counter support at the elbow holding

JAYPEE BROTHERS

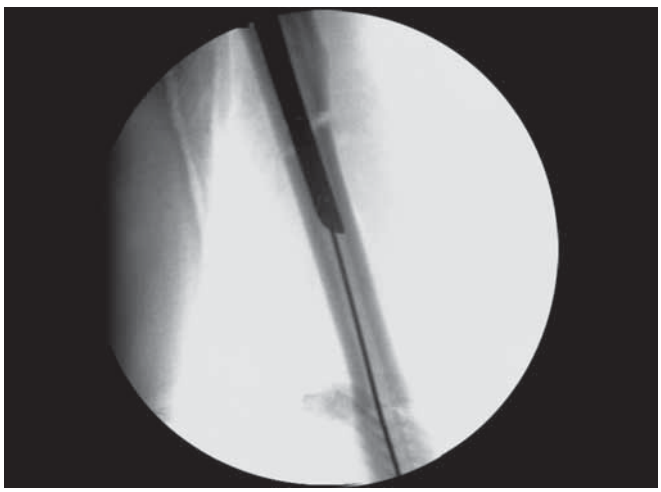

FIG. 20: Nail passing over guidewire.

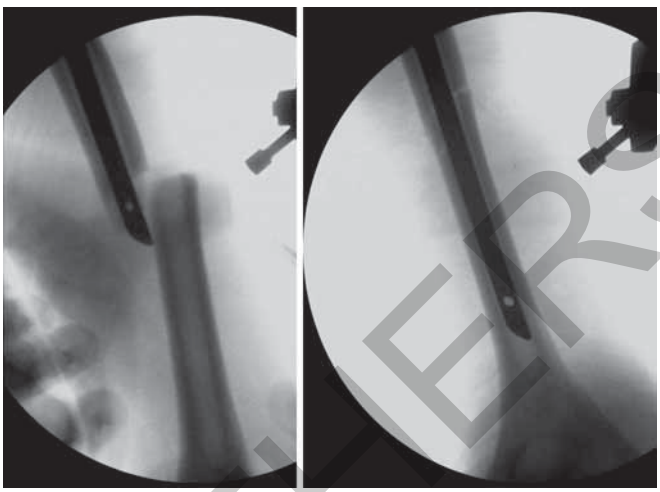

FIG. 21: Solid nail passing by free hand technique.

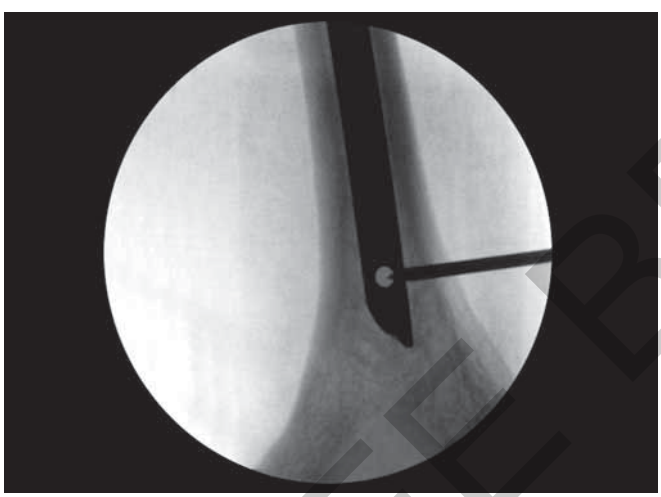

FIG. 22: K-wire making an indent in the moon of distal locking.



FIG. 23: Awl used to drill anterior cortex.

the humeral condyles properly. The tip of nail should be at least 5 mm under the subchondral bone. Nail protruding out can damage the rotator cuff and they also cause impingement and shoulder abduction restriction.

Step 10: Distal locking is done by free hand technique. Here too using the C-arm in 4.5 or 6 inch mode instead of 9 inch mode enlarges the distal interlocking hole **(Fig. 22)**. As the distal humerus is triangular, AP locking will be difficult unless all the steps are religiously followed. The assistant should hold the elbow flexed to about 60° to relax the anterior soft tissues **(Fig. 23)**. Once the level of locking marked by seeing the round moon of hole in the nail, a small skin incision is taken. Then by a hemostat artery forceps blunt dissection is done till the bone is reached and then by gradually opening this hemostat, soft tissues are retracted and separated. Then a 2-mm K-wire is passed and in the center of the hole a dent is created over the anterior cortex **(Fig. 22)**. The same K-wire can be further drilled into the hole or a awl which is used for making the interlocking drill hole can be gently hammered by rotating movements only to make the hole in the anterior cortex **(Figs. 23 and 24)**. This awl should never be hammered at the far cortex beyond the nail to prevent inadvertent iatrogenic fracture or butterfly piece coming off from the far cortex. Once the near cortex is drilled with the awl, proper drill bit is used to drill the far cortex. I normally prefer hand drill over power drill for this purpose. Then a selected bolt is passed **(Fig. 25)**. Holding the head of the bolt with a thread helps in retrieving the bolt by pulling out the thread in case sometimes the screw driver slips from the bolt head before it is locked in place.

JAYPEE BROTHERS

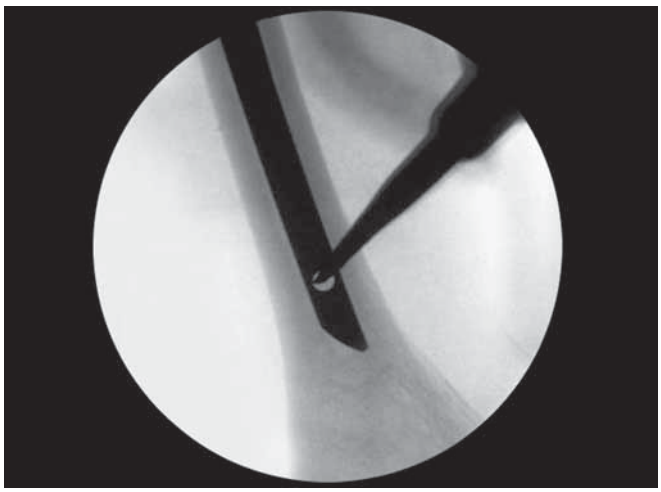

FIG. 24: Drilling of anterior cortex with awl.

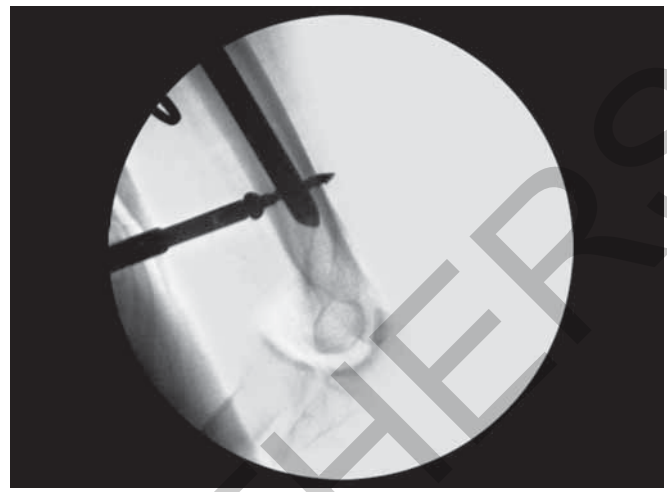

FIG. 25: Distal locking picture.



FIG. 26: Fracture site compaction technique.

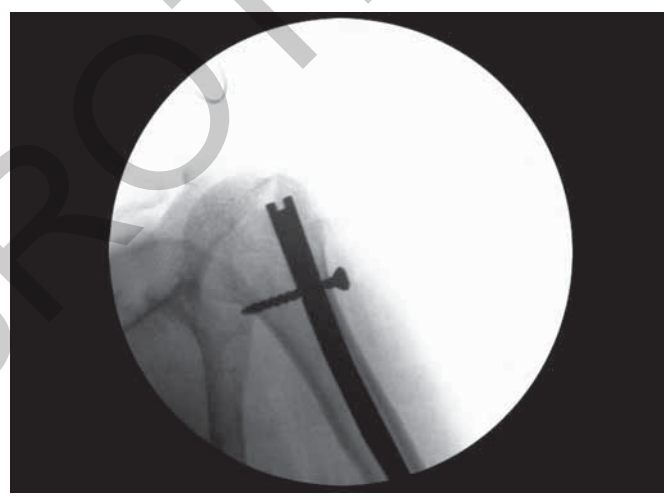

FIG. 27: Proximal locking and well-buried nail.

Step 11: Once the distal locking is completed, the fracture site is compacted by few extraction blows by attaching the extractor rod assembly **(Fig. 26)**. This technique should be used very cautiously. Too much of brute force may cause fracture site comminution. In oblique fractures and comminuted fractures, this should be done very carefully to avoid too much of shortening. And then the proximal locking is done with the help of the jig **(Fig. 27)**. In some nail systems, after doing proximal locking through the oblong hole in the nail, fracture site can be compacted by pushing this bolt down from the top by an instrument passed through the conical bolt. By all these methods, one should ensure that there is no gap left at the fracture site, especially with transverse fractures.

Nail Length Selection

Selection of the proper nail length is more critical in the humerus than in the femur or tibia. Proper proximal nail placement is approximately 5 mm below the articulating surface.

The size of the medullary cavity and the extent of humerus comminution affect the selection of nail size. A slight chance of complications due to fatigue failure does exist in the use of thin intramedullary nail. Therefore, it is recommended that the largest suitable diameter implant be used. The author does reamed nailing exclusively to insert the 7 or 8 mm nail routinely.

Preoperatively, the radiographic ruler may be placed adjacent to the contralateral unaffected humerus and viewed under image intensification to estimate the appropriate length of nail.

JAYPEE BROTHERS

Assessment of Nail Length (Figs. 36 to 38)

Intraoperatively, after fracture reduction, the nail length can be determined by two separate methods either by overlapping guidewires or with the use of the radiographic ruler as described in tibia **(Figs. 28A and B)**.

Guidewire Method

The position of the distal tip of the intramedullary guidewire should be approximately 1–2 cm proximal to the olecranon fossa. Now introduce the second guidewire of the same length which is inside the medullary cavity, so that its tip remains around 1 cm below the entry point into the bone. Calculate the length of the guidewire which is not overlapping remaining outside and measure this length. This is the length of the nail **(Figs. 28A and B)**.

Radiographic Ruler Method

The radiographic ruler may be placed adjacent to the affected humerus and viewed under image intensification to determine the appropriate length nail. This is the method which is used for solid nails.

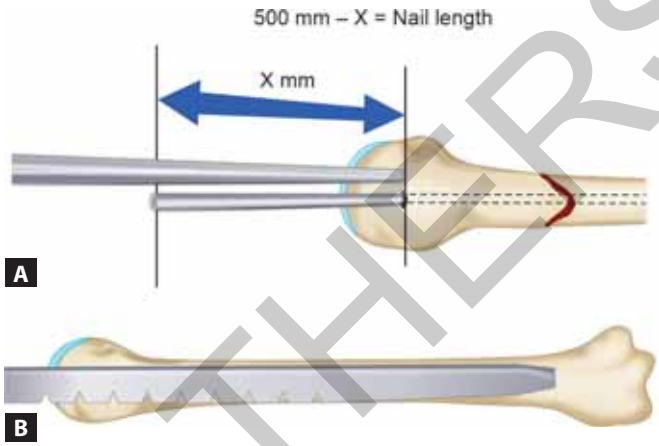

FIGS. 28A AND B: Measurement of nail length: (A) Two-guidewire method and (B) Direct ruler method.

Note: Nail length should be selected to allow for impaction and still ensure that the nail's final proximal position is beneath the proximal cortex.

Reaming

Flexible reamers with fixed reamer heads from 6 mm onwards are available exclusively for these fractures. Reaming helps in inserting thicker nail and also gives an idea about the canal size while reaming.

Nail Insertion

Proper nail placement is approximately 5 mm below the articulating surface. The nail is inserted over the guidewire in cannulated larger nail through the entry site and driven into the canal with light to moderate downward blows of the hammer. If the nail does not advance easily with each blow, remove it and ream an additional 5 mm. To avoid splitting the distal humerus, care should be taken not to overdrive the nail distally or wedge the nail tip too close to the olecranon fossa. Proximally, the humerus nail has a 2–5° lateral bend. The apex of the bend in the nail should face medially **(Figs. 29 and 30)**.

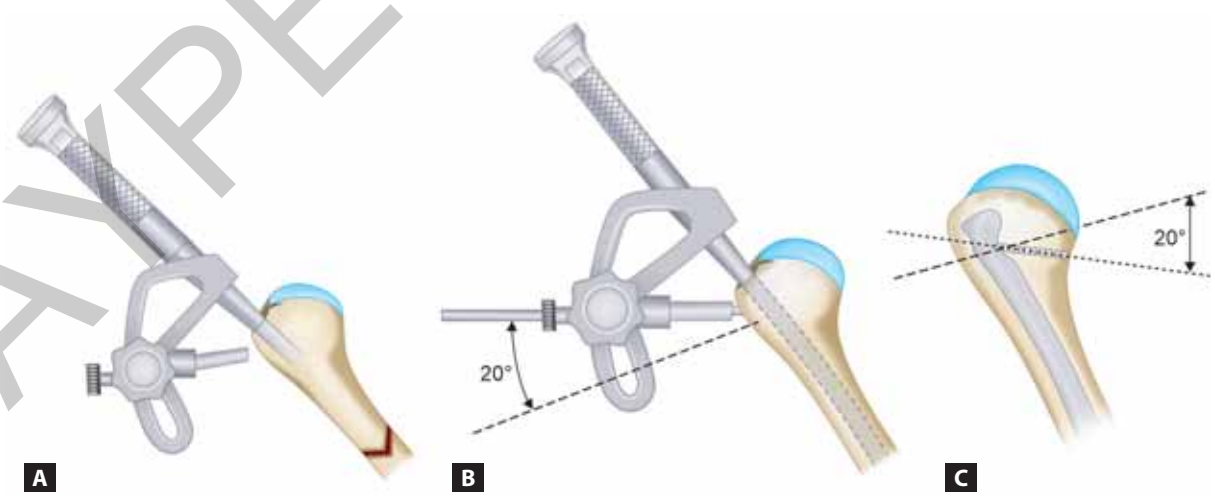

FIGS. 29A TO C: Proximal nail mounted jig.

JAYPEE BROTHERS

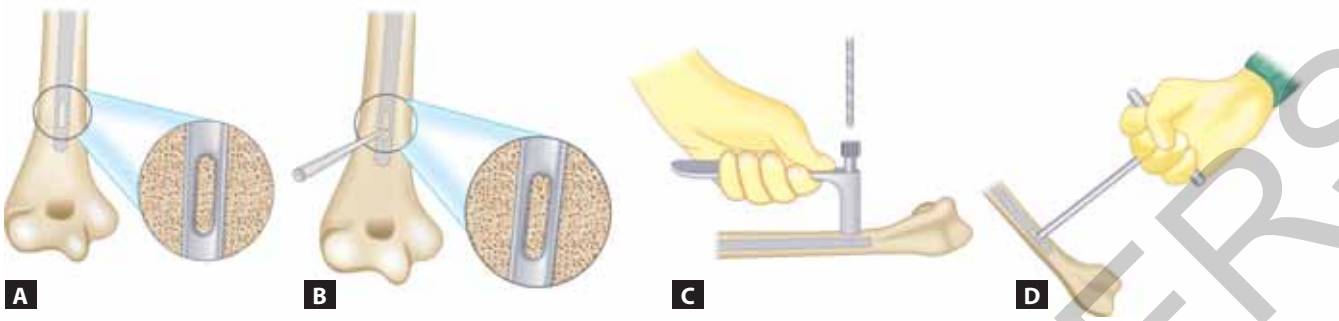

FIGS. 30A TO D: Distal locking procedure of humerus nail.

CLINICAL CASE 1 (FIGS. 31 TO 33)

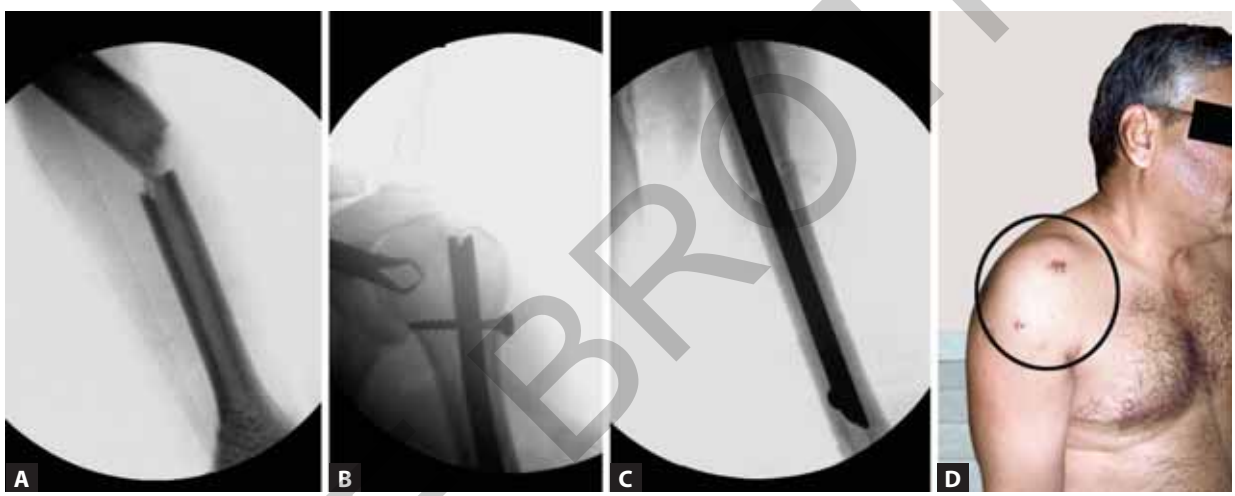

FIGS. 31A TO D: Case of fracture shaft humerus treated by closed humerus nailing. Shoulder clinical picture showing the entry as well as the interlocking site scars.

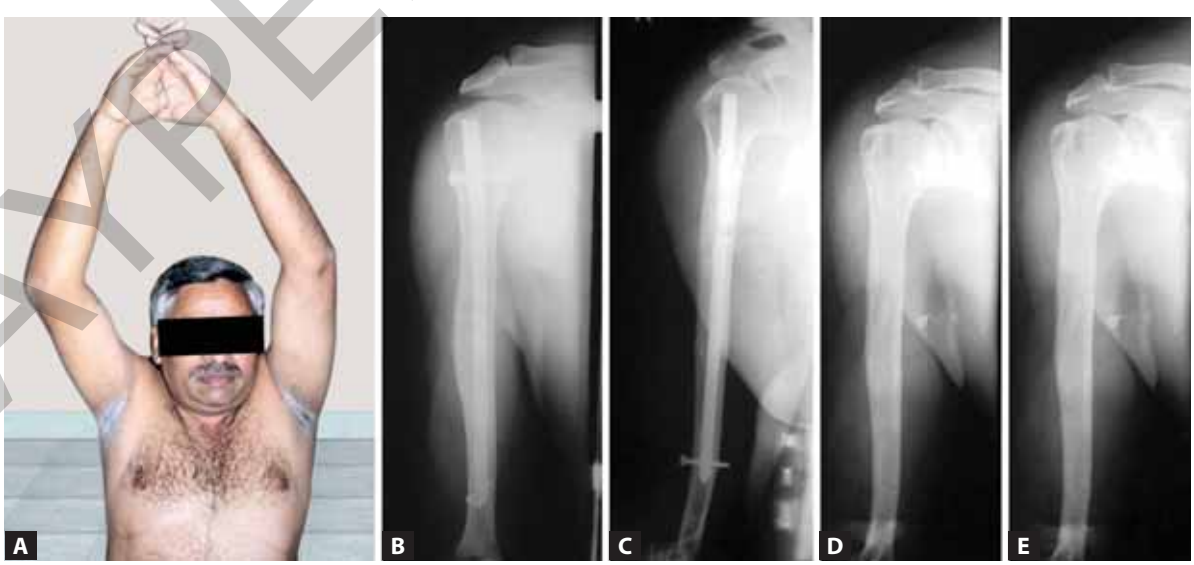

FIGS. 32A TO E: Clinical picture immediate postoperative patient doing passive shoulder abduction. And 4-year postoperative X-ray showing consolidation and removal of implants done.

JAYPEE BROTHERS

or detailed information on orthopedic books, visit our website www.jaypeebrothers.com, for detailed information on orthopedic books, visit our website www.jaypeebrothers.com, for detailed

Tanna's
Interlocking Nailing

Asia–Pacific, particularly India, has seen a dramatic change in the management of long bone fractures in the last two decades. Closed intramedullary interlocking nailing has come to mainstay for long bone fractures. Especially, the horrendous results of tibia shaft fractures following plate fixation, then infection, and then exposed shining hardware smiling at us are almost unheard of now. Those huge incisions for reducing shaft femur fractures are a story long gone by.

Tanna's Interlocking Nailing laid down the principles, techniques, and tips-to-be followed for not only young budding surgeons, but also well-established surgeons as a point of quick reference before embarking on the journey of difficult fractures and nailing.

The book is meant for young orthopedic surgeons for their tips during surgery, for more experienced surgeons for their reference, and also for those who want to start considering the nailing for their clinical scenario.



DD Tanna MS (Ortho) is an Orthopedic Surgeon who has now retired as Professor from Topiwala National Medical College and Bai Yamunabai Laxman Nair Charitable Hospital, Mumbai, Maharashtra. He is a Honorary Consultant in Jaslok, Bhatia and Saifee Hospitals for 42 years in Mumbai, Maharashtra, India. Teaching is his passion. He originated the first Thomas' splint treatment of supracondylar fracture in children, challenging conventional closed reduction way back in 1965. He started (1991) reading about interlocking without C-arm in meetings in India. Most surgeons were skeptic, when he said that he can do interlocking without C-arm. He published an article in the Journal of Bone and Joint Surgery (JBJS) British volume in 1994 on interlocking without C-arm. He got manufactured Tanna Nail and started teaching about it all over India. Till now, he has conducted about 85 workshops in India. He is considered the Father of Interlocking in India. He has been invited to talk as Guest Speaker, on varied subjects in orthopedics such as trauma, spine, joint replacement, and other nonorthopedic subjects.



Sushrut Babhulkar MS (Ortho) MCh (Ortho) (Liverpool, UK) a graduate and postgraduate from Nagpur, Maharashtra, further trained himself as a trauma and Joint Reconstruction Surgery at UK, USA, and Germany. After MCh (Ortho), he had extensive training at various places. Having decided to come back and join his roots in Nagpur, he also had the opportunity to get involved in training and teaching postgraduates since the last 18 years. He now enjoys the position of President, Trauma Society of India, and President of Interlocking Association and has to his credit more than 100 international and national publications. Been extensively traveled across the world, he demonstrates within himself an excellent blend of practical approach toward handling various levels of trauma situations. He has been asked by Dr Tanna to take the book further with more additions and updating for times to come with changing science and trends.

Printed in India

Available at all medical bookstores
or buy online at www.jaypeebrothers.com

JAYPEE BROTHERS
Medical Publishers (P) Ltd.
EMCA House, 23/23-B, Ansari Road,
Daryaganj, New Delhi - 110 002, INDIA
www.jaypeebrothers.com

Join us on facebook.com/JaypeeMedicalPublishers

Shelving Recommendation
ORTHOPEDICS

ISBN 978-93-5696-490-7