thers.com, for detailed information on obstetrics & gynecology books, visit our website www.jaypeebrothers.com, for detailed information on obstetrics & gynecology books

Ultrasound in Infertility & Gynecology

Text & Atlas

Complimentary Online 81 Videos and e-book



Sonal Panchal
Chaitanya Nagori

3rd Edition

JAYPEE

Contents

Chapter 1 Transvaginal Scan 1

- *Transvaginal Scan 2*
- *Doppler Technique 17*
- *Transrectal Scan 31*
- *Transabdominal Scan 33*

Chapter 2 Normal Uterus 34

- *Scanning and Orientation of Image 34*
- *Orientation and Position of the Uterus 37*
- *Basic Probe Movements 39*
- *Endometrium 41*
- *Myometrium 45*
- *Serosa 47*
- *Cervix 48*
- *Measurements 48*
- *Report of the Ultrasound of Uterus 51*

Chapter 3 Abnormal Uterus 53

- *Congenital Uterine Abnormalities 53*
- *Acquired Uterine Abnormalities 74*

Chapter 4 Ultrasound of Adnexal Lesions 113

- *Adnexal Lesions 113*
- *Ultrasound-based Classification of Ovarian Lesions 115*
- *Tubal Lesions 144*
- *Miscellaneous Lesions 152*

Chapter 5 Tubal Evaluation by Ultrasound 156

- *Investigations for Assessment of Tubal Status 157*

Chapter 6 Ultrasound Diagnosis of PCOS 179

- *Incidence 179*
- *Diagnosis 179*
- *Pathophysiology 197*
- *Controversies 209*

Chapter 7 Cyclical Changes in Ovaries and Follicular Tracking 214
- *Cyclical Changes Occurring in the Ovaries 214*
- *Follicle Tracking 218*

Chapter 8 Cyclical Changes in Endometrium and Uterus 251
- *Baseline Scan 256*
- *Secretory Scan 267*

Chapter 9 Transvaginal Assessment of the Cervix 273
- *Cervical Polyps 273*
- *Cervical Fibroids 275*
- *Nabothian Cysts 275*
- *Cervical Ectopic Pregnancies 277*
- *Cervical Malignancy 278*
- *Technique of Transvaginal Ultrasound Method for Cervical Assessment 282*

Chapter 10 Assessment of Early Pregnancy.....289
- *Transvaginal Sonography before Gestational Sac Appears 289*
- *Scans after the Gestational Sac Appears 290*
- *Confirmation of Intrauterine Pregnancy 291*
- *Evaluation of Abnormal Early Pregnancy 301*
- *Early Detection of Multiple Gestations 324*

Chapter 11 Ultrasound-guided Procedures in Assisted Reproduction 328
- *Oocyte Retrieval 328*
- *Embryo Transfer 334*
- *Cyst Aspiration 341*
- *Aspiration of Hydrosalpinx 342*
- *Aspiration of Ascitic Fluid in OHSS 343*
- *Fetal Reduction 343*

Appendix 1 International Endometrial Tumor Analysis: A Systematic Way of Evaluating and Describing Endometrial Lesions 351

Appendix 2 International Ovarian Tumor Analysis 357

Appendix 3 Morphological Uterus Sonographic Assessment (MUSA).....362

Index *375*

Video Contents

Chapter 1

No.	Video Legends
1.1	Probe Movement—Part 1
1.2	Probe Movement—Part 2
1.3	Probe Movement—Part 3
1.4	Probe Movement—Part 4
1.5	Gains Settings
1.6	TGC Settings
1.7	Longitudinal Scan of Uterus
1.8	Transverse Scan of Uterus
1.9	Looking for Ovaries
1.10	Finding Long Axis of Ovary
1.11	Assessing the Ovaries
1.12	Checking Ovarian Mobility
1.13	Checking Uterine Mobility
1.14	Checking for Vaginal Mobility
1.15	Locating Uterine Arteries on TVS
1.16	Locating Uterine Arteries on TAS
1.17	3D Ultrasound of Uterus
1.18	VCI of Uterus

Chapter 2

No.	Video Legends
2.1	Vaginal Wall Mobility
2.2	Uterus Orientation
2.3	Uterus Survey—Long Axis
2.4	Uterus Survey—Axial Plane
2.5	Uterus Mobility
2.6	Uterine Artery—Long Axis
2.7	Uterine Vessels—Axial Plane

Chapter 3

No.	Video Legends
3.1A	Hypoplastic Uterus—Part 1
3.1B	Hypoplastic Uterus—Part 2
3.2A	Unicornuate Uterus—Part 1
3.2B	Unicornuate Uterus—Part 2
3.3	Duplication Abnormality of Uterus—Long Axis
3.4	Duplication Defect of Uterus—Axial Plane
3.5	Uterus Septum
3.6	Arcuate Uterus—Axial Plane
3.7	Calcified Fibroid
3.8	Pedunculated Subserosal Fibroids
3.9	Subserosal Fibroid
3.10	Adenomyosis
3.11	Localized Adenomyosis
3.12	Adenomyosis on B-mode
3.13	Junctional Zone in Adenomyosis
3.14	Koch's Genitourinary
3.15	Small Endometrial Polyps
3.16	Blood in Endometrium
3.17	Weak Scar

Chapter 4

No.	Video Legends
4.1	Paraovarian Cyst—Separation from Ovary
4.2	Paraovarian Cyst—Sliding Organ Sign
4.3	Follicular Cyst
4.4	Cyst with Solid Projection
4.5	Cyst with Debris
4.6	Cyst with Internal Echogenicity
4.7	Hemorrhagic Cyst
4.8	Endometrioma
4.9	Endometrioma—Fluid-Fluid Level
4.10	Streaming Sign
4.11	3D Power Doppler of Endometrioma
4.12	3D Ultrasound of Complex Cyst

4.13A VCI of a Complex Cyst
4.13B 3D Power Doppler of Malignant Ovarian Cyst
4.14 3D Power Doppler—Malignant Vascular Pattern
4.15 Hydrosalpinx
4.16 Peritoneal Inclusion Cyst
4.17 Septated Fluid in Pelvis
4.18 Paraovarian Cyst

Chapter 6

No.	Video Legends
6.1	Longest Section of Ovary
6.2	AFC on B-mode
6.3	Stromal Flow Assessment
6.4	Baseline Scan of PCO
6.5	Vascularity in PCO

Chapter 11

No.	Video Legends
11.1	Ovum Pick Up
11.2	Ultrasound-guided Embryo Transfer
11.3	Difficult Embryo Transfer Guided by Ultrasound
11.4	OHSS
11.5	Fetal Reduction—Part 1
11.6	Fetal Reduction—Part 2
11.7	Fetal Reduction—Part 3
11.8	Fetal Reduction—Part 4
11.9	Fetal Reduction—Part 5
11.10	Fetal Reduction—Part 6
11.11	Fetal Reduction—Part 7
11.12	Fetal Reduction—Part 8
11.13	Fetal Reduction—Part 9

To access the Videos, simply scan this QR code.

CHAPTER 7

Cyclical Changes in Ovaries and Follicular Tracking

INTRODUCTION

Continuous and complex hormonal changes occurring during the menstrual cycle reflect as morphological and vascular changes in ovaries and uterus. Therefore, tracking these changes by ultrasound (US) and Doppler can explain the physiology. Transvaginal US is the modality of choice to study these changes. The accuracy of diagnosis and monitoring of infertility treatments such as ovulation induction has greatly increased because of the availability of sophisticated US technology and equipment.[1] We shall in detail study the ovarian changes occurring during menstrual cycle in this chapter.

CYCLICAL CHANGES OCCURRING IN THE OVARIES

Population of the antral follicles drastically decreases during the luteal phase of the previous cycle. A new cohort of small antral follicles develops during the menstruation phase. During the course of sequential cellular proliferation and differentiation, primordial follicles develop into intermediate, primary and eventually secondary preantral follicles. This is a phase of slow follicular growth and takes about 150 days. Secondary antral follicles are the first follicular structures to be visualized and beyond this is a phase of accelerated follicular growth. During this phase, the secondary antral follicle grows to become dominant and then mature. It further ruptures to release the ovum and then becomes a corpus luteum which then regresses in the course of time. Follicles up to 2 mm diameter grow independent of gonadotropins follicle-stimulating hormone (FSH).[2] These are secondary antral follicles that recruit from the primordial follicles to preantral follicles and primary antral follicles under the effect of androgen. Further development of the follicle is only possible in the presence of appropriate levels of gonadotropins. Before day 5 of the cycle, selection of the dominant follicle occurs and becomes apparent almost the same time. Follicle that is 10–12 mm in size is known as a dominant follicle, and it is this follicle that is most likely to grow to become a mature follicle and others and become atretic **(Fig. 7.1)**. It is interesting to know that often first largest follicle on baseline scan is not the dominant follicle. This is possible when the follicle is a residual follicle of the previous cycle. Blood flows surrounding dominant the follicle can be seen by Doppler when follicle reaches 10 mm in diameter **(Fig. 7.2)**. A normal growth rate of a healthy dominant follicle is approximately 2 mm/day and reaches a size of 18–24 mm **(Fig. 7.3)** by the time of ovulation.[3]

JAYPEE BROTHERS

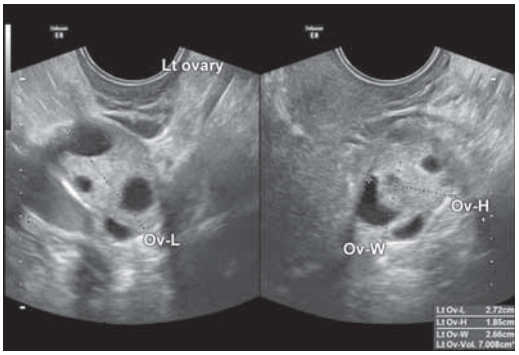

Fig. 7.1: Longitudinal and transverse section of the ovary showing antral follicles.

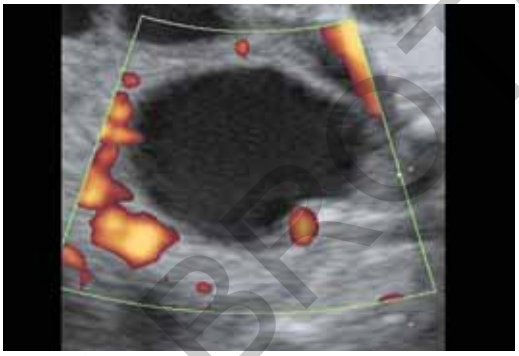

Fig. 7.2: Dominant follicle of 12 mm diameter showing blood vessels close to its margins on power Doppler. Vascular development close to follicle confirms it is an active follicle.

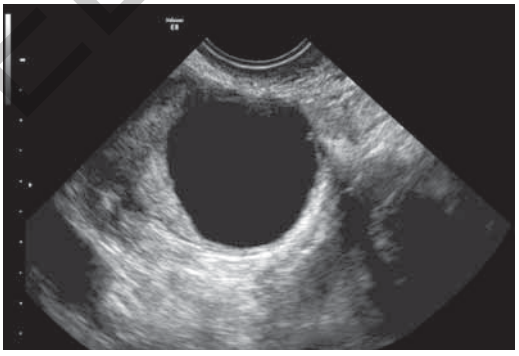

Fig. 7.3: Preovulatory follicle of 19 mm with regular round shape, thin walls and no internal echogenicity.

When the follicle reaches maturity, estrogen levels rise and this leads to positive feedback to pituitary for luteinizing hormone (LH) release and negative feedback for FSH release. In response to LH surge, resulting preovulatory changes in follicle are seen as appearance of a sonolucent halo surrounding the follicle and appearance of cumulus (a small solid projection

JAYPEE BROTHERS

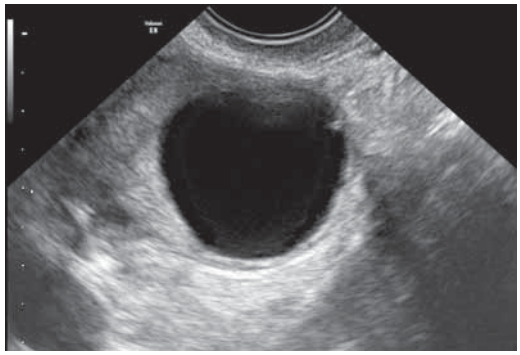

Fig. 7.4: Preovulatory follicle of 20 mm with regular round shape, thin walls and no internal echogenicity. The follicle shows a tiny solid projection from its wall, which is probably a cumulus oophorus. A hypoechoic halo is seen on the periphery of the mature follicle. Cumulus and the perifollicular halo are both seen with the mature follicle 24–36 h before rupture.

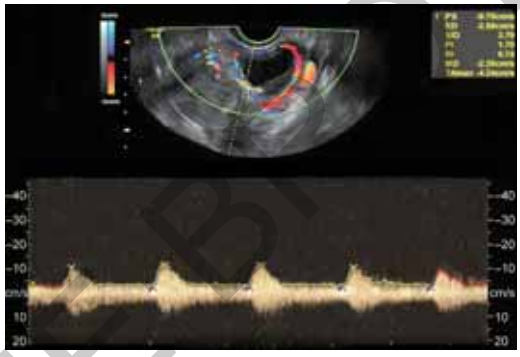

Fig. 7.5: Follicle in the midproliferative phase shows blood vessels around the follicle with RI between 0.50 and 0.58. (RI: resistance index)

from the follicle wall) 24–36 h before ovulation **(Fig. 7.4)**. Resistance index (RI) of the vessels seen around the follicle is reported as 0.54 ± 0.04, in midproliferative phase of the cycle **(Fig. 7.5)**. RI starts falling 2 days prior to ovulation and reaches its nadir of 0.44 ± 0.04 at ovulation **(Fig. 7.6)**.[4] Just prior to eruption, the vascularity surrounding the follicle increases along with the increase in its flow velocity.[5] The rise in peak systolic velocity (PSV) **(Fig. 7.7)** follows the rise in LH by approximately 12 h. PSV increases 29 h before the time of follicular rupture and continues for ≥72 h after corpus luteum is formed.[6]

Ovulation results in collapse of the follicle with irregular contour followed by filling of its cavity with echogenic fluid, now called corpus luteum. This may or may not be associated with free fluid in pouch of Douglas.

Corpus luteum has variable appearances. It usually has thick shaggy walls with ground glass echogenicity in lumen, fibrin strands or lacelike echogenicities **(Fig. 7.8)** and has circumferential blood flow referred to as a "ring of fire" **(Fig. 7.9)**. The corpus luteum resolves

JAYPEE BROTHERS

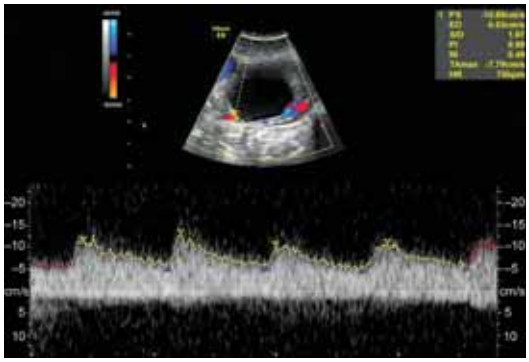

Fig. 7.6: The same follicle in the preovulatory phase shows RI of 0.49 and a PSV of >10 cm/s, indicating a physiologically mature follicle. (RI: resistance index; PSV: peak systolic velocity)

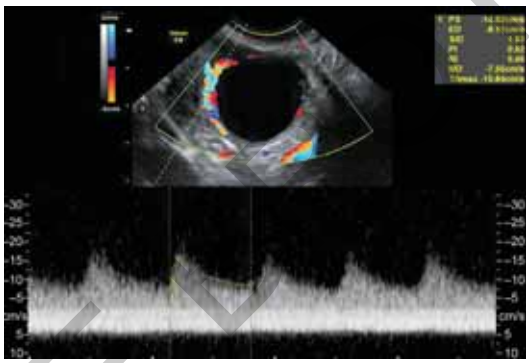

Fig. 7.7: As the follicle progresses toward rupture, with the progress of LH surge, there is sharp increase in the perifollicular PSV, with low RI. This indicates impending rupture. (PSV: peak systolic velocity; RI: resistance index)



Fig. 7.8: With follicular rupture, the follicular walls collapse and there is bleeding in the lumen leading to thick irregular walls and internal echogenicities in corpus luteum.

JAYPEE BROTHERS

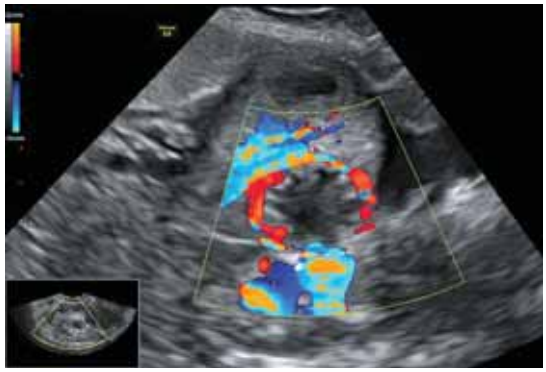

Fig. 7.9: Normal corpus luteum has a dense surrounding capillary network, seen as ring of fire around the corpus luteum.

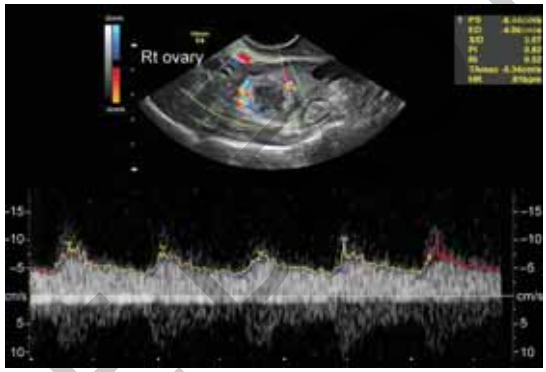

Fig. 7.10: Corpus luteal blood vessels have a low-resistance flow with resistance index of <0.5.

if pregnancy does not occur at the end of the luteal phase. Three to seven times increase in the blood flow is noted in the dominant ovary (ovary from which ovulation occurs) during the luteal phase.[7] The flow is highest in the midluteal phase and declines till menstruation in absence of conception. A healthy corpus luteum will show a vascular ring surrounding itself on color Doppler, and on power Doppler, these vessels show RI 0.35–0.50, PI (pulsatility index) 0.70–0.80 and PSV 10–15 cm/s **(Fig. 7.10)**.[8,9] This resistance starts increasing on day 23 of the normal length cycle if there is no conception to RI 0.5–0.55.

Rarely, ovulation fails to occur leading to a luteinized unruptured follicle. Despite the absence of follicular rupture and release of the oocyte, the unruptured follicle undergoes luteinization under the effect of LH.

FOLLICLE TRACKING

Follicular tracking is ultrasonographic study of follicle recruitment, growth and rupture of the menstrual cycle.

JAYPEE BROTHERS

The purpose of follicular tracking is:

- To predict and evaluate ovarian response to stimulation in terms of the number and size of ovarian follicles
  - To identify exaggerated response
  - To identify poor response
- To decide the correct time of ovulation trigger and intrauterine insemination (IUI) or ovum pickup.

Follicular tracking is actually a continuous process but for the convenience of understanding, this can be divided into three phases of menstrual cycle:

1. Baseline scan in early proliferative phase
2. Preovulatory scan
3. Luteal scan.

Baseline Scan

Monitoring of a menstrual cycle should start in early proliferative phase, preferably day 2–3 of the cycle. At this time, estrogen, progesterone, FSH and LH are all at their baseline levels.

The ovarian reserve and response can be assessed by this scan. It is important to mention here that ovarian reserve and response are the two terms used interchangeably, these two terms actually have two absolutely different meanings. Ovarian reserve talks about how many follicles would grow at the end of ovulation induction and that depends on the antral follicle count (AFC) and ovarian volume. Where as ovarian response means the sensitivity of the ovary to gonadotropins and that is decided by the daily dose of gonadotropin required to allow the follicles that have reached dominance to grow at a normal pace of 2–3 mm a day.

Secondary antral follicles (1–2 mm) are the first follicular structures that may be visualized on US (ultrasound). Number of antral follicles (AFC) in the ovaries with ovarian volume on this scan decides the ovarian reserve and may therefore help to plan the stimulation protocol. Commonly used morphological US markers for deciding the stimulation protocol are:[10]

- *Antral follicle count:* Antral follicles in one ovary is follicle number per ovary (FNPO), in both ovaries together is AFC
- Ovarian volume
- Mean ovarian diameter and size
- Ovarian stromal blood flow.

Number of antral follicles, measuring 2–10 mm in diameter, correlates well with the female's age, ovarian reserve and ovarian response to gonadotropin stimulation.[11] Normal FNPO ranges from 5 to 19 **(Figs. 7.11A and B)**. AFC <6 correlates well with reduced ovarian reserve **(Fig. 7.12)** and poor response to ovarian stimulation, with positive predictive value of 75%. Total AFC >21 could lead to the decision to adjust the gonadotropin dose in trying to prevent a hyper-response leading to ovarian hyperstimulation syndrome (OHSS) **(Figs. 7.13 and 7.14)**.[12]

The mean ovarian diameter significantly correlated with age, day 3 FSH, day 3 LH and day 3 estradiol.[13] Ovarian volume is a poor predictor of number of oocytes obtained in an in

JAYPEE BROTHERS



Figs. 7.11A and B: Longitudinal and transverse sections of the ovary on B-mode (A) showing 10–12 antral follicles. This is a normal reserve ovary. The same ovary is seen on 3D US rendered image on inversion mode showing the follicles as solid balls (B).



Fig. 7.12: Longitudinal and transverse sections of the ovary on B-mode showing a small size and only one follicle in the ovary on baseline scan. This is low-reserve ovary.

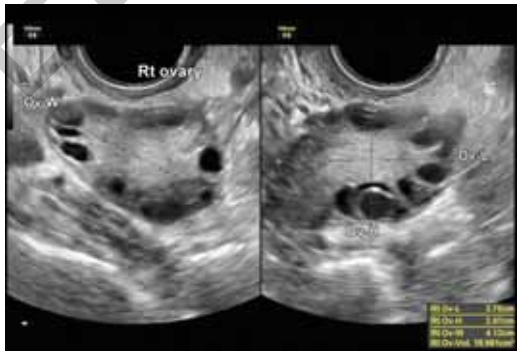

Fig. 7.13: Longitudinal and transverse sections of the ovary on B-mode ultrasound shows peripherally arranged multiple follicles with hyperdense echogenic stoma, suggestive of polycystic ovaries.

vitro fertilization (IVF) cycle.[12] Though a study by Lass et al. has shown that ovarian volume <3 cm^3 was significantly predictive of higher IVF cancellation rates >50%.[14] Volume of the polycystic ovary is considered as 10cc. These facts can be simply summarized as: ovary of <3cc

JAYPEE BROTHERS

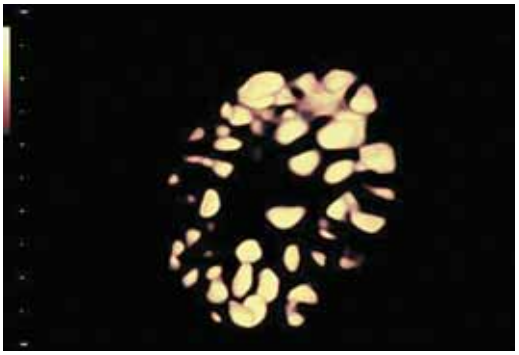

Fig. 7.14: Same ovary in 3D rendered inversion mode image with all follicles seen as echogenic balls.

is poor reserve and one >10cc is a polycystic ovary and has high chance of developing OHSS on ovarian stimulation.

Coming to ovarian response. It is known that unless the FSH threshold is reached the follicles will not achieve dominance and will not start growing to become mature. To allow adequate amount of FSH to reach the ovary therefore the daily dose of FSH needs to be adjusted in every patient. This can be decided by the ovarian stromal blood flow. If the blood flow to the ovarian stroma is abundant, then more percentage of total gonadotropin (endogenous or exogenous) present in the patient's circulation will be delivered to the ovary every cardiac cycle and the FSH threshold will be reached whereas if the blood flow to the ovarian stroma is low, then less percentage of total gonadotropin (endogenous or exogenous) present in the patient's circulation will be delivered to the ovary every cardiac cycle and to allow the FSH threshold to be reached, larger amount of gonadotropin needs to be loaded into the patient's circulation. That means that a patient who has more ovarian stromal flow requires lower doses for stimulation and is a hyper or a good responder, where as one who has lesser ovarian stromal blood flow requires higher doses of gonadotropins and is a poor responder. The ovarian stromal flow can be calculated by 2D Doppler and a combination of RI and PSV, or by 3D power Doppler indices vascularity index (VI), flow index (FI), and vascularity flow index (VFI). There is adequate literature evidence to that too.

Measurement of ovarian stromal flow in early follicular phase is related to subsequent ovarian response in IVF treatment **(Figs. 7.15A and B)**.[15] Ovarian stromal blood flow velocity after 2–3 weeks of pituitary suppression is a true representative of baseline ovarian blood flow and predictive of ovarian responsiveness and outcome of IVF treatment.[16] Therefore, Doppler of ovaries on baseline scan can be helpful to decide stimulation protocol.

Undetectable basal ovarian stromal blood flow in at least one ovary is related to low ovarian response in infertile women undergoing IVF–ET.[17] Ovarian stromal PSV was the most important single independent predictor of ovarian response in patients with normal basal serum FSH level. Patients with PSV ≥10 cm/s had significantly higher median number of mature oocytes and higher clinical pregnancy rates.[16] It needs to be understood here that in these cases the AFC is also more, because the total number of follicles that grow can never exceed the AFC. That is why very high doses of gonadotropins in with low reserve ovaries does not improve the follicular yield.

JAYPEE BROTHERS

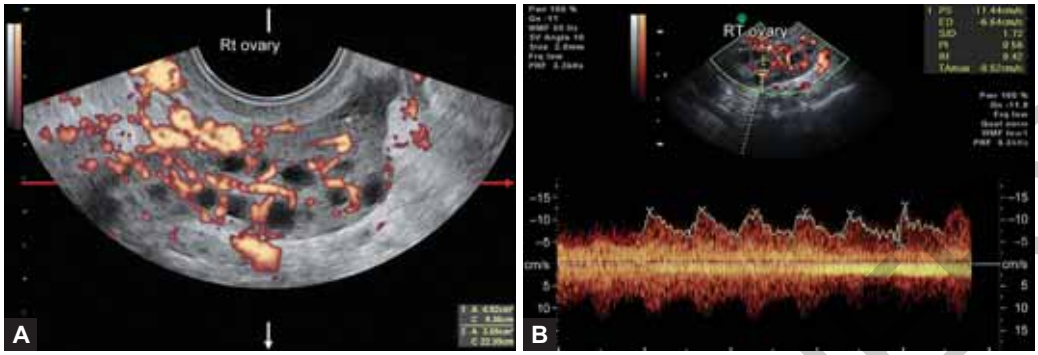

Figs. 7.15A and B: Power Doppler image (A) of ovary shows multiple follicles and blood vessels in the stroma. The stromal vessels are the vessels that are in the stroma and not close to the follicles; (B) shows spectral Doppler of the stromal vessels of the ovary. This shows low resistance (RI 0.46), high-velocity (PSV 14.61) flow, typical of polycystic ovaries.

Table 7.1: Scoring system for deciding the stimulation protocol.

Score	*1*	*2*	*3*	*4*	*5*
Age	>40	35.1–40	30.1–35	25.1–30	</ = 25
BMI	>30	30–28.1	28–25.1	25–22.1	</ = 22
AFC	<5	5–10	10.1–15	15.1–20	>20
Ov volume	<3	3–5	5.1–7	7.1–10	>10
Stromal RI	>0.75	0.75–0.651	0.65–0.551	0.55–0.451	<0.45
Stromal PSV	<3	3–5	5.1–7	7.1–10	>10

(BMI: body mass index; RI: resistance index; PSV: peak systolic velocity. Ov: ovarian)

One more factor that may be of importance before starting a stimulation protocol would be the size of antral follicles. It is known that follicles of <6 mm in diameter are less responsive to either endogenous or exogenous gonadotropins. If therefore all follicles are smaller than this, it would lead to higher total dose of gonadotropins consumption in a cycle. Of course when considering the stimulation protocol, the non-US clinical features like age and body mass index (BMI) of the patient cannot be ignored. A study by La Marca et al. shows that daily FSH dose may be calculated on the basis of age, AFC and FSH. It has 85–90% sensitivity and specificity for poor response if <0.2 and high response if it is >0.9.[18]

Based on these literature evidences and also on our experience of more than 25 years, in the field, for calculating the required gonadotropin doses for ovarian stimulation, we have developed a scoring system. This was a prospective study of 1,570 patients of IUI and 350 patients for IVF. Patients included had dysovulatory or unexplained infertility, including PCOS and poor responders, mild-to-moderate male factor, grade 1,2 endometriosis, cervical factor infertility. A scoring system was developed based on clinical and US findings **(Table 7.1)**.

JAYPEE BROTHERS

The US features that demanded higher doses indicated poor response and therefore were given lower score, and those US features which required lower doses indicated better response and were given higher score. The ovulation induction in all patients was done by rFSH (recombinant FSH), and the stimulation doses were based on the scores of individual patient based on the **Table 7.1**. The parameter values were calculated by ultrasound and Doppler scan done on day 2 of the cycle. But it must be remembered that the success of the system depends on the precision of the scan. The doses according to the patient's score were decided.

Depending on the baseline score, the doses of rFSH for ovulation induction are shown in **Table 7.2**.

No response to stimulation was documented when neither the follicle nor the endometrium was growing. This is so because even when the follicle actually does not show increase in size, its granulosa cell mass might be increasing which, in turn, leads to more estrogen production and therefore growth of the endometrium. In IUI cycles, if there was no response after 5 days of stimulation in a patient who had a score of <10, the dose of rFSH was increased by 75 IU. If the score was >10–<20, the dose was increased by 37.5 IU from day 7 of stimulation **(Flowchart 1)**.

If the score was 20–22, the dose was increased by 37.5 IU only on the 10th day of stimulation. If the score is >22, wait till 14 days before you increase the dose by 25–37.5 IU **(Flowchart 2)**. And the overall study results showed consistent 30–40% conception rate per cycle, with 2–3% twin pregnancy rate, 0.5% triplets, extremely low cycle cancellation rate due to poor response and 0.05% mild/moderate OHSS rate, with no severe OHSS at all.[19]

For selecting the stimulation doses for IVF also, the same scoring system can be used. Depending on the scores, the doses calculated are as follows **(Table 7.2)**:

Table 7.2: Starting dose in IVF cycles, based on the scoring system.

Score	*IUI*	*IVF (Fresh)*	*IVF FET*
>/ = 25	25 IU	75 IU	150 IU
21–25	37.5 IU	150 IU	225 IU
16–20	75 IU	225 IU	300 IU
11–15	112.5 IU	300 IU	375 IU
6–10	150 IU	375 IU	450 IU

Flowchart 1: Algorithm for dose change in case of no response in IUI cycles.

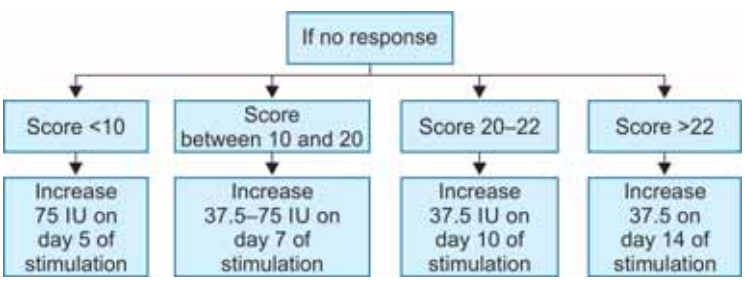

JAYPEE BROTHERS

Flowchart 2: Algorithm for change in dose in case of no response in IVF cycle.

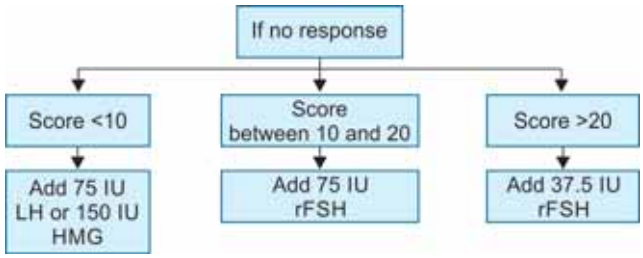

(HMG: human menopausal gonadotropin; IVF: in-vitro fertilization; LH: luteinizing hormone; rFSH: recombinant follicle-stimulating hormone)

For the scores of <10 or >20, antagonist protocol is used to prevent over-downregulation and hyperstimulation, respectively. It is recommended to add LH in patients with score <10 and in those when score is 10–20, but there was unexplained poor response in one cycle.[20]

Technique for Baseline Scan of Ovaries

B-mode US assessment of the ovaries consists of assessment of ovarian diameters and volume and counting of antral follicles as quantitative assessment and qualitative assessment of stromal density.

Once ovary is located, it is brought in the center of the image and the probe is rotated to find out the longest diameter of ovary and is stored as one frame on a dual screen. Then probe is rotated 90° to get a true transverse axis of ovary. The anteroposterior diameter is measured as the longest diameter perpendicular to the longest diameter.

Measure the largest longitudinal, anteroposterior diameters on the long section and transverse diameter of the ovary on transverse section. All the diameters are measured in centimeters (cm), and ovarian volume can be calculated by the formula ($x \times y \times z \times 0.523$) **(Fig. 7.16)**.

The number of antral follicles is counted in the whole ovary by taking a 2D sweep across whole ovary. As a rule when counting the antral follicles, the probe should not be rotated or should not be brought back to prevent overcounting of follicles. This method is very feasible and reliable when number of antral follicles is approximately 10–15. But when number of follicles is much more as in polycystic ovaries, the calculation using B-mode scroll may be inaccurate. In these cases 3D US with SonoAVC is a reliable method.

Stromal echogenicity is assessed against echogenicity of myometrium **(Fig. 7.17)**, especially if ovary and uterus are at almost same depth from probe. Normally ovarian stroma is hypoechoic or isoechoic to normal myometrium **(Figs. 7.18A and B)**.

Color or power Doppler box is now placed on the ovary, so that whole ovary is included in color box. Doppler is used to see presence of vessels in ovarian stroma **(Fig. 7.19)**. To locate the stromal flow, as the color box is placed on the ovary, hilar vessels are located. These vessels are identified as vessels in long axis that extend beyond the ovary. In other words this vessels are entering the ovary from outside. Once the hilar plane is identified, then the probe

JAYPEE BROTHERS

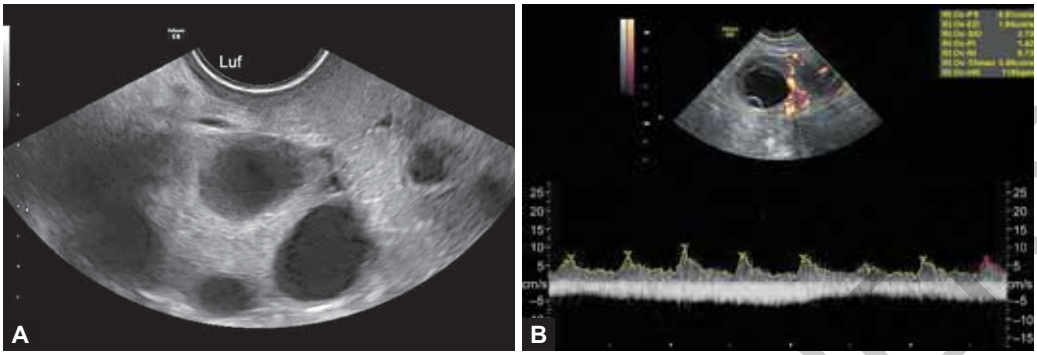

Figs. 7.47A and B: (A) B-mode ultrasound image of intraovarian cystic lesion with echogenic walls and low-level internal echogenicities, suggestive of an LUF; (B) On color and spectral Doppler, LUF shows scanty and high-resistance flow. (LUF: luteinized unruptured follicle)

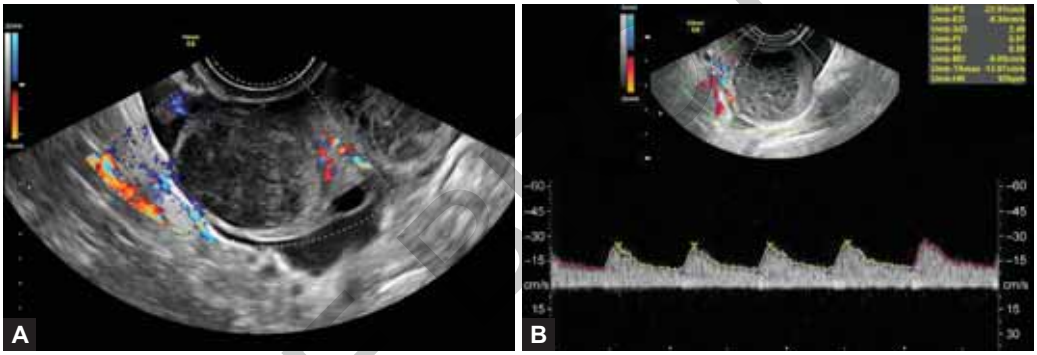

Figs. 7.48A and B: (A) B-mode ultrasound image of corpus luteum seen as thick-walled cystic lesion with lacelike internal echogenicity. This lesion of color Doppler shows some peripheral vascularity. On pulsed Doppler (B), these blood vessels show high resistance flow. This suggests luteal phase defect.

is also seen in spiral arteries. This is the case when luteal phase defect is due to insufficient corpus luteum. But when luteal phase defect is due to insufficient progesterone receptors in the endometrium, the endometrial flow is normal but endometrium is thin, nonhyperechogenic and shows scanty vascularity. Though in cycles in which exogenous luteal support is given, good secretory changes may be seen in the endometrium even in absence of low resistance corpus luteal flow.

CONCLUSION

US is an excellent tool for cycle monitoring. Doppler helps to understand the hormonal changes occurring during the cycle and is an important tool to assess the ovarian response, functional follicular maturity and corpus luteal function. Volume assessment for follicle gives much more reliable parameters than follicular diameter alone. The presence of cumulus that can be confirmed by 3D US increases the possibility of the presence of a mature ovum

JAYPEE BROTHERS

in the follicle. The 3D-power Doppler gives idea about the global vascularity of follicle and endometrium. Though larger studies and standardization of US parameters and settings are required to establish more precise values for follicular and endometrial VI, FI and VFI, the results are fairly promising. We can hope to understand the follicular and endometrial physiological status better with these parameters and achieve better pregnancy rates with ART procedures and reduce the span of unexplained infertility.

KEY POINTS

- Transvaginal US is the modality of choice to study follicular changes during natural or treatment cycle.
- Follicular tracking describes the serial ultrasonographic study of the ovary during the follicular phase of the menstrual cycle.
- Monitoring of a menstrual cycle should ideally start in early proliferative phase.
- A normal growth rate of a healthy follicle is approximately 2 mm per day and reaches a size of 18–24 mm by the time of ovulation.
  - Doppler plays an important role in assessing the ovarian response to stimulation on baseline scan.
  - Based on ovarian volume, antral follicle count and ovarian stromal flows, scoring system has been devised to decide the stimulation protocols for ovulation induction.
  - Perifollicular flow covering three-fourths of the follicular circumference, with RI <0.48 and PSV <10 cm/s are essential parameters to confirm functional follicular maturity.
- Corpus luteum typically has variable appearances with ground-glass echogenicity in lumen or lacelike echogenicities and has circumferential blood flow referred to as a "ring of fire".
- SonoAVC has been used to provide automated measures of follicle size and number on baseline scan as well as on the preovulatory scan and may have implications for the workflow within IVF centers.
- The 3D-power Doppler gives idea about the global vascularity of follicle.
- While larger studies and standardization of US parameters and settings are required to establish more precise values for follicular and endometrial vascularity indices as measured by 3D US, the results are fairly promising.

REFERENCES

1. Kyei-Mensah A, Zaidi J, Pittrof R, et al. Transvaginal three-dimensional ultrasound: accuracy of follicular volume measurements. Fertil Steril. 1996;65:371-6.
2. Hackeloer BJ, Sallam HN. Ultrasound scanning of ovarian follicles. Clin Obstet Gynecol. 1983;10:603-20.
3. Hackeloer BJ, Fleming R, Robinson HP. Correlation of ultrasonic and endocrinological assessment of human follicular development. Am J Obstet Gynecol. 1979;135:122.

JAYPEE BROTHERS

for detailed information on obstetrics & gynecology books, visit our website www.jaypeebrothers.com, for detailed information on obstetrics & gynecology books, visit our w

Ultrasound in Infertility & Gynecology
Text & Atlas

Ultrasound in Infertility and Gynecology: Text and Atlas concentrates only on ultrasound of infertility-related problems along with ultrasound of gynecological conditions related to patients presenting for fertility treatment. It includes everything from very basics to most advanced knowledge about the subject with the latest evidence. It has maximum possible images of every condition, so as to make it easier for the busy consultants to differentiate between different pelvic lesions at a glance. Along with that, it also contains a detailed text description and pathological or physiological basis of pathology to make it a complete guide for anybody practicing gynecology and infertility scans. It will be of ultimate help for all gynecologists, infertility consultants, and radiologists interested in female imaging.

Sonal Panchal MD PhD is an Ultrasound Consultant, Dr Nagori's Institute for Infertility and IVF, Ahmedabad, Gujarat, India. She has been one of the pioneers of the use of Doppler and 3D-4D ultrasound for infertility and gynecological applications. She is a popular Teacher in the field and an admired Trainer for Infertility and Gynec-ultrasound and for 3D-4D ultrasound. She is known for her thorough knowledge and insight into the subject for the art of transferring this to the students in the simplest possible ways. She has a high repute for innovative thinking in imaging.

Chaitanya Nagori MD DGO is the Director, Dr Nagori's Institute for Infertility and IVF, Ahmedabad, Gujarat, India. He is a very successful Infertility Consultant with experience of more than 27 years with a very high pregnancy rate for the patients treated by him. With his highly innovative thinking, he was one of the first workers to use Doppler for monitoring of infertility treatment. He is a core Academician and a Teacher of high repute. He is very popular for his to-the-point teaching, with crisp and clear concepts. He is a Contributor and Author of several books and had several research publications.

Printed in India

Available at all medical bookstores
or buy online at www.jaypeebrothers.com



JAYPEE BROTHERS
Medical Publishers (P) Ltd.
EMCA House, 23/23-B, Ansari Road,
Daryaganj, New Delhi - 110 002, INDIA
www.jaypeebrothers.com

Join us on facebook.com/JaypeeMedicalPublishers

Shelving Recommendation
OBSTETRICS & GYNECOLOGY

