lmology books, visit our website www.jaypeebrothers.com, for detailed information on ophthalmology books, visit our website www.jaypeebrothers.com, for detailed information on ophthalmology books

Scan to Download the App
diginerve
A Jaypee Initiative
Your Guide at Every Step
Video Lectures | Notes | Self-Assessment

2nd Edition

Manual of Oculoplasty

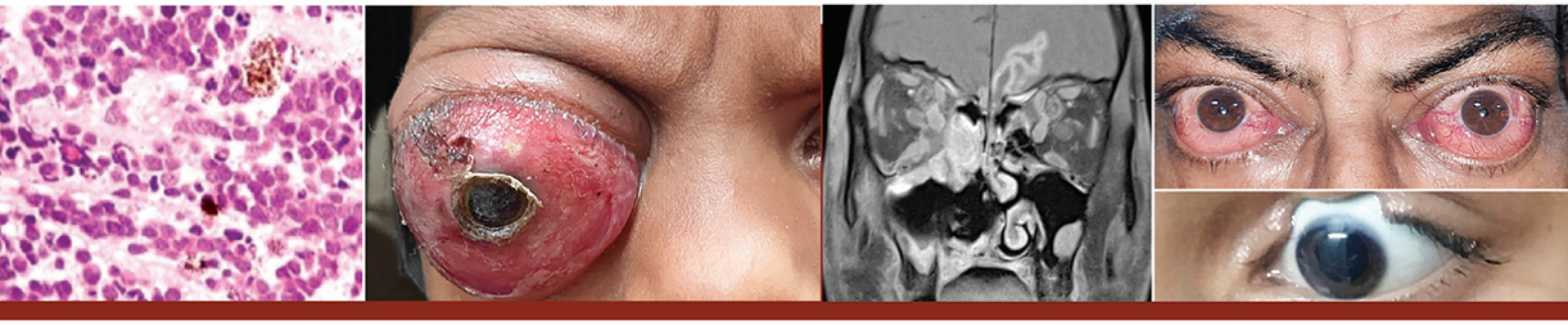

Editor
Ruchi Goel

Foreword
Gangadhara Sundar

JAYPEE

Contents

SECTION 1: ORBIT

1. **Surgical Anatomy of Orbit** 3
   Shaloo Bageja, Ishita Anand, Swapnil Jadhav
2. **Evaluation of Orbital Disorders** 17
   Mohit Chhabra, Ruchi Goel
3. **Orbital Imaging** 24
   Mankirat Singh, Jyoti Kumar
4. **Congenital Orbital Anomalies** 45
   Sumit Kumar, Ruchi Goel
5. **Orbital Infection and Inflammation** 49
   Smriti Bansal, Sima Das
6. **Rhino-orbito-cerebral Mucormycosis** 70
   Smriti Bansal, Ruchi Goel
7. **Thyroid-associated Orbitopathy** 74
   Ruchi Goel, Amit Goel
8. **Orbitotomy** 85
   Ruchi Goel
9. **Orbital Decompression** 92
   Ruchi Goel
10. **Enucleation, Evisceration, Orbital Exenteration, and Orbital Implants** 97
    Akshay Gopinathan Nair
11. **Anophthalmic Socket: Evaluation and Management** 109
    Raj Anand

SECTION 2: TRAUMA

12. **Evaluation of a Case of Orbital Trauma** 123
    Tanvi Gaonker, Ruchi Goel
13. **Orbital Fractures: A Conceptual Approach** 127
    Gangadhara Sundar
14. **Traumatic Optic Neuropathy** 138
    Shalin Shah, Ruchi Goel

SECTION 3: LID

15. **Embryology and Anatomy of Eyelid** 143
Ruchi Goel

16. **Ptosis Examination and Management of Congenital Ptosis** 148
AK Grover, Shaloo Bageja, Amrita Sawhney

17. **Complicated Ptosis** 164
Sonam Singh, Paromita Dutta

18. **Acquired Ptosis: Classification and Management** 169
Ruchi Goel, KPS Malik

19. **Entropion and Ectropion** 173
Ruchi Goel, KPS Malik

20. **Eyelid Retraction** 192
Ruchi Goel, KPS Malik

21. **Blepharospasm and Hemifacial Spasm** 194
Neha Rathie, Tanvi Gaonker, Ruchi Goel

22. **Congenital Abnormalities of the Eyelid** 197
Samreen Khanam, Ruchi Goel

23. **Inflammatory Disorders of the Eyelid** 202
Samreen Khanam, Ruchi Goel

24. **Facial Nerve Palsy** 206
Taru Dewan, Kanika Jain, Tanvi Gaonker

25. **Eyelid and Canthal Reconstruction** 211
Ruchi Goel, KPS Malik

26. **Facial Rejuvenation: Blepharoplasty, Brow Ptosis Correction, and Nonsurgical Methods** 218
Kasturi Bhattacharjee, Samir Serasiya, Deepika Kapoor

SECTION 4: LACRIMAL SYSTEM

27. **Embryology, Anatomy, and Physiology of Lacrimal Secretory and Drainage System** 235
Mohit Chhabra, Ruchi Goel

28. **Evaluation and Abnormalities of Lacrimal Secretory and Drainage System** 244
Sumit Kumar, Ruchi Goel

29. **Lacrimal Surgeries** 260
Swati Singh, Saurabh Kamal, Akshay Gopinathan Nair, Ruchi Goel

30. **Recent Advances in Dacryology** 270
Nandini Bothra, Mohammad Javed Ali

SECTION 5: TUMORS

31. Neoplasms and Malformations of the Orbit 279
Ruchi Goel, Bita Esmaeli

32. Malignant Tumors of the Lid 296
Ruchi Goel

33. Ocular Surface Tumors 308
Sima Das, Chhavi Gupta Narula

34. Intraocular Tumors 330
Raksha Rao, Santosh G Honavar, Rolika Bansal

SECTION 6: HISTOPATHOLOGY

35. Histopathology Slides 349
RK Saran, Shweta Raghav, Shalin Shah

SECTION 7: INSTRUMENTS AND SUTURE MATERIALS

36. Oculoplastic Instruments—I 359
Smriti Nagpal Gupta, Ruchi Goel

37. Oculoplasty Instruments—II 376
Priyanka Golhait, Ruchi Goel

Index 381

CHAPTER 2

Evaluation of Orbital Disorders

Mohit Chhabra, Ruchi Goel

JAYPEE BROTHERS

INTRODUCTION

Orbital disorders are somewhat different from intraocular disorders, which are usually amenable to direct visualization. Owing to this inaccessibility of orbital contents to direct examination, a different clinical skill set along with rational and relevant imaging and diagnostic modalities are required to localize the pathology and predict the most probable cause and extent of disease. Despite this, certainty of diagnosis is by no means guaranteed and many a times, a definitive decision depends on a close watch on clinical evolution of the disease, and its response to therapy.

Orbital disorders can be classified into five basic clinical patterns:

1. Inflammatory disorders
2. Mass effect causing axial or abaxial proptosis
3. Bony structural abnormalities
4. Vascular lesions
5. Functional disorders of neuromuscular structures

The evaluation begins with a detailed history which is of paramount importance in orbital diseases.

HISTORY

A good clinical history helps in guiding examination, investigations, and therapy. The demographic details of the patients are extremely important to reach appropriate differential diagnoses.

The usual symptom complex of orbital diseases includes one or more of the following—pain, proptosis, enophthalmos, diminution of vision, diplopia, epiphora, congestion and a significant cosmetic blemish.

A detailed evaluation of these complaints should include:

- Age of onset, duration, progression, and previous photographs to establish the timeline
- Systemic disease and therapeutic history (e.g., thyroid disorders)
- Prior injury or surgery
- Family history
- Personal history such as smoking that may aggravate thyroid orbitopathy, weight gain (hypothyroidism), or weight loss (hyperthyroidism)

Age of onset serves as an important guide to differential diagnosis while most congenital and developmental anomalies present at an early age, metastatic diseases and malignancies such as leukemia present at a much later age **(Table 1)**.

Pain is usually a symptom of inflammation, infection, emphysema, invasive malignancies, or metastatic tumors.

Duration of symptoms is necessary to ascertain probable pathology. The rate of progression may vary from days to weeks in cases of cellulitis, hemorrhage, fulminant neoplasms, thrombophlebitis or metastatic tumors. Conditions occurring over months to years include dermoid cysts, benign lacrimal tumors, hemangioma, lymphoma or osteoma. Lymphatic malformations may have an acute presentation following upper respiratory infection. A dermoid cyst may also present in emergency following trauma, leading to rupture of cyst or sudden increase in size due to hemorrhage.

TABLE 1: Common causes of proptosis according to age.

Age group	*Common causes of proptosis*
Infants	Dermoid cyst, teratoma, capillary hemangioma, microphthalmia with cyst, orbital extension of retinoblastoma, histiocytosis, orbital cellulitis
Children	Dermoid cyst, teratoma, microphthalmia with cyst, lymphatic malformation, rhabdomyosarcoma, chloroma, neuroblastoma, optic nerve glioma, histiocytosis, parasitic cysts, hematoma, orbital cellulitis
Adults	Thyroid orbitopathy, cavernous hemangioma (venous malformation), pseudotumor, lacrimal gland tumor, orbital varix, schwannoma, lymphoma, metastasis, optic nerve meningioma, orbital cellulitis

TABLE 2: Signs in orbital pathology.

Signs	*Probable pathology*
S-shaped deformity of lid	Lacrimal gland enlargement, plexiform neurofibroma
Injection around insertion of recti	Thyroid orbitopathy
Optociliary shunt vessels on the disk	Meningioma, metastases, inflammatory tumor
Corkscrew conjunctival vessels	Arteriovenous fistula
Vascular anomaly of eyelid skin	Varix, lymphatic malformation, hemangioma
Lid retraction	Thyroid eye disease
Ecchymosis of eyelid skin	Leukemia, metastatic neuroblastoma
Frozen globe	Orbital malignancy or zygomycosis
Salmon-colored mass on conjunctiva	Lymphoma
Café-au-lait spots	Neurofibromatosis type 1 (NF1)
Facial asymmetry	Fibrous dysplasia, neurofibromatosis

Poor vision in orbital diseases may be due to a variety of reasons and must be evaluated extensively for proper therapy and prognosis.

A plethora of signs also provide clues to diagnosis **(Table 2)**.

Involvement of one or both the orbits may occur.

CAUSES OF BILATERAL PROPTOSIS

- Thyroid orbitopathy
- Dacryoadenitis due to sarcoidosis and tuberculosis
- Lymphoma
- Leukemia
- Metastatic carcinoma
- Metastatic neuroblastoma
- Histiocytosis

Thyroid orbitopathy is the most common cause of proptosis in adults. Other endocrine disorders causing proptosis are:

- Diabetes mellitus
- Pituitary adenoma
- Cushing syndrome
- Acromegaly

PHYSICAL EXAMINATION

Due to its intimate relation to surrounding structures, diseases of the orbit are bound to matters, of much wider than just ocular interests. Apart from anatomical proximity, intimacy of venous drainage with surrounding structures makes it an important focus in this region. Hence, examination must not be limited to the eye and orbit but should also encompass nose, paranasal sinuses, face, and cranium. Of course, general medical examination also requires adequate attention as many diseases are linked to systemic disorders. Abnormalities of pulse, rhythm, blood pressure, and temperature should be evaluated along with an examination of the neck in thyroid orbitopathy.

General examination of the orbit includes inspection, palpation, auscultation, transillumination, and several special methods of examination specific to the orbit.

INSPECTION

- Globe displacement is the most common manifestation of an orbital anomaly that may be caused by a tumor, vascular disease, inflammation, or a traumatic event. The usual terms that describe this displacement include:
  - *Proptosis or exophthalmos:* Forward displacement of the globe (exophthalmos refers to dynamic rather than passive mechanical factors)
  - *Enophthalmos:* Retrodisplacement of globe within the bony confines of the eye socket
  - *Exorbitism:* Angle between the lateral walls >90°
  - *Hypertelorism:* Wider than normal separation between medial orbital walls
  - *Telecanthus:* Increase in distance between medial canthi
  - *Hyperglobus:* Vertical upward displacement of globe
  - *Hypoglobus:* Vertical downward displacement of globe
  - *Orbital dystopia:* Abnormal displacement of entire orbital cone and its content

JAYPEE BROTHERS

- *Types:*
  - *Vertical:* Orbits do not lie on the same horizontal plane.
  - *Horizontal/transverse dystopia:* Orbits are displaced laterally or medially.

Proptosis needs to be differentiated from pseudoproptosis.

Causes of pseudoproptosis:
- High myopia
- Buphthalmos
- Staphyloma
- Eyelid retraction
- Shallow orbit as in Crouzon syndrome
- Progressive facial hemiatrophy as in Parry–Romberg syndrome

The detection of proptosis can be done by two methods:
1. *Naffziger's method:* The patient sits in front of the examiner with the head slightly thrown back and looking downward. The surgeon raises the upper lids with the index fingers and compares the apex of the cornea. As the patient bends his head forward, the two corneas should disappear at the same time **(Fig. 1)**.
2. *Worm's eye view:* The examination is performed from below with the patient's head tilted back **(Fig. 2)**.

The direction of any displacement gives valuable diagnostic information regarding the site of disease:
- *Downward and outward:* Medial side or roof of orbit, e.g., ethmoidal or frontal mucocele, meningocele, and dermoid
- *Downward and inward:* Lacrimal gland neoplasia and dermoid
- *Upward:* Lesion in the maxillary antrum, lacrimal sac tumor
- *Axial proptosis:* Lesion within the muscle cone or apex of the orbit. Axial proptosis may occur in intraconal cavernous hemangioma, optic nerve glioma, optic nerve sheath meningioma, thyroid orbitopathy, etc.
  - Periocular changes in color, abnormal vasculature, erythema, frank induration or ulceration should be noted. Any limitation of extraocular movements may point to restrictive or paretic pathologies of orbital structures.
  - Intermittent proptosis that becomes prominent on Valsalva maneuver or by asking patient to bend forward is suggestive of orbital varix.



Fig. 1: Naffziger's view.



Fig. 2: Worm's view.

Palpation

Palpation should be done to confirm findings of inspection:
- Orbital rim and anterior portion of the orbital cavity should be felt and compared to the other side in case of any suspected mass, erosion, or irregularity. Though very deep palpation is not possible in the orbital space, it is desirable to explore the extent of mass. The skin temperature of the surrounding area should also be noted.
- Presence of tenderness should be noted, especially of the bony structures.
- Retropulsion should be elicited by pushing the globe through the upper eyelid and feeling the resistance or compressibility of the mass. Vascular lesions are usually compressible while retrobulbar tumors or thyroid ophthalmopathy give a resistance to retropulsion.
- Reducibility should be checked to differentiate between vascular lesions and other masses

JAYPEE BROTHERS

- Orbital thrill or pulsation should be felt by placing two fingers over the orbit through closed lids. A *true pulsation* causes the fingers to move up and separate while a *transmitted pulsation* causes the fingers to move up but not separate.

True pulsation is felt in caroticocavernous fistula, while transmitted pulsation is felt in neurofibromatosis due to sphenoid wing dysplasia, meningoencephalocele (children), and large mucoceles that have eroded the bony walls of both orbit and intracranial vault (adults).

- Infra- or supraorbital anesthesia or paresthesia may result from perineural spread of malignant tumors like adenoid cystic carcinoma of the lacrimal glands.

Auscultation

Whenever a pulsation is evident, an auscultation must be done to look for an audible bruit as in case of arteriovenous (AV) malformations. A stethoscope should be used over the eyeball or temporal area.

Transillumination

A penlight must be used for this test and the findings vary depending upon the opacity of the mass relative to the surrounding tissue.

- A fluid-filled cystic lesion gives a bright transillumination **(Fig. 3)**
- Lipoma causes the area to light up equally as the surrounding area
- Solid tumors and aneurysms create a dark transillumination due to their shadow effect
- Alternatively, transillumination can also be interpreted as *positive or negative* based on the above findings.

Ophthalmological Examination

- Conjunctiva when examined may reveal dilated tortuous vessels, corkscrew-shaped episcleral vessels, hyperemia or a subconjunctival mass as an extension of a deeper orbital mass.
- Cornea should be examined for signs of exposure keratopathy.
- Tests for dry eye should be performed especially in thyroid eye disease.
- Sclera and iris should be seen for signs of inflammation.
- Presence of a relative afferent pupillary defect in many cases is the first clue of optic nerve involvement.
- Ductions are measured in degrees.



Fig. 3: Transillumination of an upper lid mass.



Figs. 4A and B: Differential tonometry in a case of thyroid ophthalmopathy in (A) Primary gaze and in (B) Upgaze.

- *Visual fields:* The defects may not be as distinct as those caused by intracranial lesions. All orbital lesions if large enough will cause irregular quadratic contractions or relative scotomas due to direct pressure on the eye. A central scotoma disproportionately greater than the amount of proptosis suggests optic nerve glioma. The defects in meningioma are more irregular in contour and density and affect the peripheral field much sooner than central field.

In children, confrontation testing may reveal gross defects in the peripheral field:

- Intraocular pressure should be measured in all gazes (differential tonometry), especially in cases of suspected thyroid ophthalmopathy. A difference of >6 mm Hg is significant (*Brailey's sign*) **(Figs. 4A and B)**.

JAYPEE BROTHERS

In children, rise in intraocular pressure in proptosed eye may indicate an associated neurofibromatosis.
- Lens and vitreous are usually unaffected, except for intraocular tumors.
- Fundus examination must be done to look for venous engorgement, tortuosity, choroidal folds, papilledema, or optic atrophy. In cases of cavernous sinus thrombosis, there may be retinal edema, exudates, and venous engorgement.

SPECIAL METHODS OF EXAMINATION

Several methods require mention such as exophthalmometry, orbitonometry, and several imaging techniques.

Exophthalmometry

Proptosis is measured by protrusion of the apex of the cornea in front of the outer orbital margin while the eye looks straight ahead.
- *Normal value:* 10–20 mm
- *Average values:*
  - *Male:* 17 mm
  - *Female:* 16 mm
  - *Children:* 14.5 mm

A difference of >2 standard deviations normal for age, sex and race, an absolute reading of >21 mm or difference of >2 mm between the two eyes is considered abnormal.

Proptosis is graded as mild (21–24 mm), moderate (25–27 mm), and severe (≥28 mm). Anything <14 mm should be considered as enophthalmos and may be encountered in metastatic disease or trauma.

Three types of measurements have been described:
1. Absolute exophthalmometry (result compared with normal value)
2. Comparative exophthalmometry (result compared over a period of time)
3. Relative exophthalmometry (results of the two eyes are compared)

The first attempt at exophthalmometry was made in 1865 by Cohn who produced an instrument used to measure the distance between the orbital rim and the corneal apex from the side. Since that time, many instruments of varying mechanisms have been devised.
- *Hertel's exophthalmometer (1905):* This is a binocular instrument, allowing the examiner, with the aid of mirrors, to see the two eyes superimposed upon a measuring scale and measuring the distance between the lateral orbital rim and the corneal apex. A difference of >2 mm is significant. The procedure is not possible in uncooperative patients with poor fixation, in the presence of lateral orbital rim fractures and abaxial proptosis.
- Patient and examiner must be at the same eye level to remove parallax.
- The footplates of the instrument are placed on the orbital notch (deepest point on the rim) with the patient's eye closed.
- The baseline reading of the separation of the two prisms should be carefully noted and all future measurements must be done on that baseline reading.
- The patient is asked to look straight. The red lines should overlap and the millimeter marking corresponding to the corneal apex should be noted **(Fig. 5)**.



Fig. 5: Hertel's exophthalmometry.

Sources of error: Parallax, compression of soft tissues at the lateral orbital rim can produce an error of 0.5–1.0 mm.
- Other attempts at exophthalmometry were made by Luedde, Naugle, Davanger (right angled 45° prism to see the cornea), Zehnder (introduction of mirror), Coccius (plunger sliding on the measuring scale placed on lids), and Gormaz (plunger placed on the anesthetized cornea)

  Luedde's exophthalmometer is the simplest and consists of a simple thick transparent ruler with a groove to rest on the lateral rim. It is more accurate than Hertel's in cases of facial asymmetry.
- Stereophotographic methods of exophthalmometry introduced by Lobeck and Ollers provide for more accurate measurements.
- Radiographic exophthalmometry employs superimposing the lateral radiograph with a radiopaque

JAYPEE BROTHERS

contact lens with a central dot placed on the cornea. The nasion–clinoid distance and the cornea–clinoid distance are measured.

Despite many advancements in exophthalmometry, vertical or horizontal globe dystopia is usually not counted for and may require a special instrument known as the ocular topometer (Watson 1967), which can measure a displacement in any direction. Watson connected two Luedde-type instruments by a horizontal plastic plate that rests on the nasal bridge with sliding scales for measurement.

A simpler method employed routinely involves the use of a perspex ruler:

- With the upper edge of the ruler corresponding with the outer canthi, vertical deviation may be measured.
- Horizontal deviations are measured from a mark on the bridge of the nose to the nasal limbus **(Figs. 6A to D)**.

Orbitonometry (Piezometry)

Though not done routinely nowadays, it deserves mention to stress upon the importance of orbital compressibility in many disorders.

The compressibility of orbital contents depends partly upon orbital volume and partly on tissue consistency.

From the clinical viewpoint, orbitonometry may be an adjunct but cannot be used as a criterion for diagnosis that still depends upon assessment of clinical signs and symptoms.

LABORATORY TESTS

- Total and differential leukocyte count, absolute eosinophil count peripheral smear—useful in leukemia, lymphoma, and parasitic infestation
- Thyroid function tests—triiodothyronine (T3), thyroxine (T4), and thyroid-stimulating hormone (TSH). Additional tests include thyrotropin-releasing hormone, anti-thyroglobulin, and antimicrosomal antibodies.



Figs. 6A to D: (A) Axial view of CT orbit showing a mass in the lateral extraconal compartment encroaching the intraconal compartment and causing excavation of lateral wall of the orbit and proptosis; (B) Coronal view CT scan showing inferior displacement of globe by the superiorly located mass; (C) Measurement of vertical displacement of the globe. The horizontal displacement is estimated by measuring the distance from a mark on the center of bridge of the nose to the nasal limbus or corneal reflex (the contralateral eye is occluded in presence of squint); (D) Measurement of proptosis with plastic ruler. (CT: computed tomography)
Note: Either cut the end of the ruler to start with zero or subtract no marking zone from your reading.

JAYPEE BROTHERS

- Angiotensin-converting enzyme—sarcoidosis
- Antinuclear cytoplasmic antibody (C-ANCA)—Wegener's granulomatosis
- Other tests such as bone marrow studies, chest X-ray abdominal, and chest CT scan are performed, whenever indicated.

CONCLUSION

To conclude, the orbital disorders may present due to varied etiology and clinical features. A detailed history and examination is indicated to assess the associated morbidity.

SUGGESTED READING

1. Genders SW, Mourits DL, Jasem M, Kloos RJ, Saeed P, Mourits MP. Parallax-free exophthalmometry: a comprehensive review of the literature on clinical exophthalmometry and the introduction of the first parallax-free exophthalmometer. Orbit. 2015 Feb;34(1):23-9.
2. Weiler DL. Thyroid eye disease: a review. Clin Exp Optom. 2017 Jan;100(1):20-25.

JAYPEE BROTHERS

for detailed information on ophthalmology books, visit our website www.jaypeebrothers.com, for detailed information on ophthalmology books, visit our website www.jaypeebrothers.com, for detailed info

Manual of Oculoplasty

Salient Features

- Covers all aspects of oculoplasty
- Quick reference book for postgraduate students, fellows, and general ophthalmologists
- Addition of new chapters on orbital trauma, mucormycosis, endoscopy instruments, and complicated ptosis
- Updation of recent advances in each section
- Inclusion of flowcharts, tables, and images for ease in comprehension.



Ruchi Goel MS DNB FAICO (Oculoplasty) FRCOphth, served as Faculty at Maulana Azad Medical College, New Delhi, India, for nearly two decades. She has recently joined as Director, Academics and Quality Control at Healing Touch Super Speciality Eye Care, New Delhi and Visiting Consultant, Rajiv Gandhi Cancer Institute and Research Centre, New Delhi. She was heading the oculoplasty services at Guru Nanak Eye Centre, New Delhi, and was actively involved in training of postgraduates and senior resident doctors in oculoplasty and ocular oncology. She is an examiner for the Royal College of Ophthalmologists (London, UK), MD/MS, DNB, PhD, FAICO and MBBS. She is on the editorial board of the Indian Journal of Ophthalmology and is a reviewer of prestigious journals such as OPRS, Orbit, Clinical Ophthalmology, IJO, Eye, BMJ, etc. She has 110 indexed, 40 (non-indexed), and more than 30 book chapters to her credit. Some of her various academic awards include Dr VP Chadha Memorial University Gold Medal, Smt Rukmani Gopala Krishnan Memorial Gold Medal, APAO-Honavar Award (for the best paper in the lacrimal session of AIOC 2016), AIOS-IJO Silver Award, and the Outstanding Paper Award from the International College of Surgeons. She has performed live surgery at more than a dozen centers and has conducted more than 50 instruction courses on oculoplasty and cataract in India and abroad.

Printed in India

Available at all medical bookstores
or buy online at www.jaypeebrothers.com

JAYPEE BROTHERS
Medical Publishers (P) Ltd.
EMCA House, 23/23-B, Ansari Road,
Daryaganj, New Delhi - 110 002, INDIA
www.jaypeebrothers.com

Join us on facebook.com/JaypeeMedicalPublishers

Shelving Recommendation
OPHTHALMOLOGY

ISBN 978-93-5696-517-1