brothers.com, for detailed information on ophthalmology books, visit our website www.jaypeebrothers.com, for detailed information on ophthalmology books



TEXTBOOK FOR OPHTHALMIC ASSISTANTS

As per the Latest Guidelines and Syllabus

Highlights

- Tables and flowcharts for better clarity
- Explanation of the various disorders of the eye
- Preliminary medical treatment incorporated
- Encompasses diverse clinical case pictures

PK Mukherjee

JAYPEE

CONTENTS

1. Anatomy of the Eye 1

- General Consideration 1
- Gross Anatomy of the Eye 1
- Nerve Supply of the Eye 22

2. Development of the Eye 23

- Development of the Lens 24

3. Physiology of the Eye 26

- Metabolism 26
- Physiology of Vision 26
- Clinical Optics 39

4. Symptomatology 53

- Nonvisual Ocular Symptoms 58

5. Examination of the Eye 63

- History 63
- Examination of the Eye 64
- Clinical Examination of the Eye 79
- Examination Under Diffuse Light 79
- Examination Under Focal Illumination 81
- External Examination of the Specific Structure of the Eye 82
- Examination of the Lacrimal System 84
- Examination of the Eye with Watering 84
- Examination of the Orbit 85
- Examination of a Case of Proptosis 86
- Examination of the Conjunctiva 86
- Examination of the Globe and Sclera 89
- Examination of Cornea 90
- Examination of the Anterior Chamber 93
- Examination of the Uvea 93
- Examination of the Pupillary Margin 94
- Examination of the Lens 96
- Examination of the Squint (Strabismus) 99
- Examination of a Case of Glaucoma 103

6. Disorders of the Lids 105

- Ptosis 105
- Epicanthus 108
- Blepharophimosis 108
- Ankyloblepharon 108
- Coloboma of Lids 108
- Distichiasis 108
- Acquired Disorders of the Lids 109
- Acquired Structural Anomalies of the Lids 115
- New Growths on the Lids 116
- Malignant Growth of the Lids 117

7. Disorder of the Lacrimal System 120

- Drainage of Tears 120
- Dryness of the Eyes 121
- Diseases of the Lacrimal Drainage System 121
- Diseases of the Lacrimal Gland 126

8. Disorders of the Orbits 128

- Proptosis and Exophthalmos 128
- Infectious Diseases of the Orbit 131

9. Disorders of Conjunctiva 137

- Common Clinical Features of Conjunctival Disorders 138
- Conjunctivitis 146
- Some Specific Types of Conjunctivitis 147
- Chlamydial Conjunctivitis 150
- Allergic Conjunctivitis 153

10. Disorders of the Cornea 156

- Disorders of the Cornea 156
- Contact Lenses 169

11. Disorders of Sclera 174

- Congenital Anomalies of Sclera 174
- Inflammation of Sclera 175
- Ectasia (Bulging) of Cornea and Sclera 176

12. Disorders of the Lens 179

- Loss of Transparency 179
- Congenital Anomalies of the Lens 192

13. Disorders of the Iris, Ciliary Body and Choroid 194

- Aniridia 194

14. Disorders of Retina 210

- Media 213
- Common Macular Disorders 222
- Vascular Retinopathies 224
- Vascular Obstructive Disorder of Retina 227
- Tumors of Retina 233

15. Disorders of the Optic Nerve.....236

- Visual Path 236

16. Glaucoma.....245

- Applied Anatomy of Glaucoma 245
- Applied Physiology of Glaucoma 247
- Glaucoma 248
- Chronic Simple Glaucoma (Wide-Angle Glaucoma) 251
- Glaucoma Suspect 256

17. Squint.....261

- Diplopia 264
- Amblyopia 264
- Squint 265

Index *273*

8
CHAPTER

Disorders of the Orbits

The disorders of the orbits are—displacement, infection, inflammation, growths, and trauma. Out of these displacements, the most common cause may be primary or secondary. The displacement may be forward or backward. The forward displacement is known by proptosis and exophthalmos. While posterior displacement is called enophthalmos, the term anophthalmos should be strictly used to denote the congenital absence of an eyeball. The condition; more common than anophthalmos is microphthalmos, which means an overall congenital reduction of the eyeball. A soft eye is called phthisis bulbi, and the removal of the structures is called an emptysocket. Removal of all the orbital structures, including the periorbita, is called exenteration; removal of intraocular tissues leaving the sclera intact is called evisceration; and removal of eyeballs with intraocular structures is called enucleation.

PROPTOSIS AND EXOPHTHALMOS

In the past, the two terms were used to denote separate conditions. The term proptosis was used to denote a passive bulge of the globe due to retrobulbar or peribulbar mass. The term **exophthalmos** was exclusively used to denote thyroid oculopathy **(Fig. 8.1)**. Nowadays, the two are used to denote the forward displacement of the globe due to any cause.

Proptosis

Proptosis can be congenital or acquired; the second is more common than the first.

Congenital Proptosis

Congenital proptosis is due to underdevelopment of the orbit, generally associated with maldevelopment of the skull and face. The eyes, which are normal in all dimensions, are too large for the shallow orbits hence are pushed forwards. The eyes have poor vision due to associated

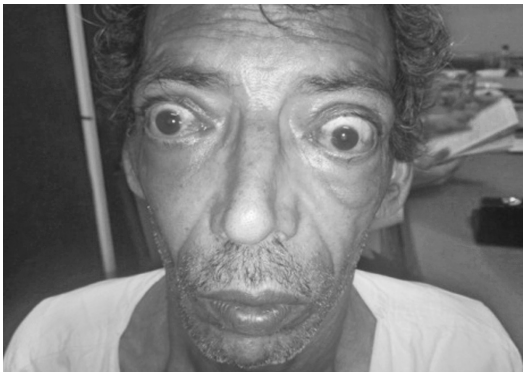

Fig. 8.1: Exophthalmos.

JAYPEE BROTHERS

optic atrophy; squintsand mental retardationsare common. Rarely there may be an abnormal congenital mass in a normal orbit, causing proptosis. The causes of deformed skulls are seen in Crouzon and Apert syndromes. The proptosis is generally bilateral and symmetrical.



Fig. 8.2: Meningocele.
(For color version, see Plate 2)

Acquired Proptosis

Acquired proptosis is generally unilateral. The main causes of proptosis are tumor, benign or malignant. The malignancy can be primary, secondary, or an extension from the surrounding structures. The mass can be inflammatory and called pseudotumors of the orbit. The other causes are hematoma (blood), abscess (pus) parasites cysts, dermoid, mucocele of paranasal sinuses, meningoencephalocele, and meningocele **(Fig. 8.2)**.

The common tumors causing proptosis in children are orbital retinoblastoma, leukemia, rhabdomyosarcoma (RMS), and optic nerve glioma.

The common tumors in adults that cause proptosis could be primary or secondary.

The **primary** tumor causing proptosis are—optic nerve meningioma, neurofibroma, orbital varices, dermoid, cavernous hemangioma, and orbital lymphomas.

The **secondary** tumors deposited in the orbit are from the bronchus, breast, prostate, kidney, and lymphomas. The malignancies that arise from the intraorbital and paraorbital structures are growths from the globe, lacrimal glands, paranasal sinuses, and brain. The malignancies from the globe that invade orbit are retinoblastoma and malignant melanoma. From the lacrimal gland arise the mixed lacrimal gland tumors. The mucocele invading the orbit are mucocele from the paranasal sinuses. The meningocele and meningoencephalocele arise from the brain. The other cause consists of parasitic cysts and retained foreign bodies.

Table 8.1 shows the causes of unilateral and bilateral proptosis.

Table 8.1: Causes of unilateral and bilateral proptosis.

	Proptosis	
Sl. No.	***Unilateral***	***Bilateral***
1.	**Congenital**: Meningocele, encephalocele, and dermoid	Oxycephaly
2.	**Tumors** • Primary tumors—retinoblastoma, rhabdomyosarcoma (RMS), hemangioma, optic nerve glioma, meningioma leukemia, lymphoma neuroblastoma. • Extension from surrounding structures • Secondaries from distant organs	Retinoblastoma, lymphoma, lymphosarcoma, and leukemia
3.	• **Infective lesion:** Orbital cellulitis, cavernous sinus thrombosis	Cavernous sinus thrombosis, Wegener granuloma, tuberculosis, and fungal granuloma
4.	• **Inflammatory:** Pseudotumors of the orbits	Pseudotumors
5.	• **Others:** Orbital thyroid disease, parasitic cyst, foreign body, orbital varix	Orbital thyroid disease

Note: Some of the unilateral conditions become bilateral.

JAYPEE BROTHERS

Proptosis can be Acute or Chronic

The acute proptosises are generally associated with pain and are unilateral.
Proptosis as per onset can be acute or chronic, as shown in the **Table 8.2.**

Pseudoproptosis

These are the conditions where the globe seems to bulge out of its orbit without actually being so. **The causes are:** Unilateral high myopia, unilateral buphthalmos, unilateral large ciliary staphyloma, retraction of the upper lid, unilateral lagophthalmos, contralateral microphthalmos and phthisis, contralateral mild ptosis, and familial.

Direction of Proptosis

The direction of proptosis and its extent point many a time towards the possible cause of proptosis.

The direction of proptosis can be any of the following or in combination. **They are:**

1. **Axial:** straight forward due to any growth inside the muscle cone **(Fig. 8.3)**. Common causes are glioma of the optic nerve and meningioma of the optic nerve sheath.
2. Downwards due to growth from the roof of the orbit.
3. Upwards due to growth from the floor of the orbit.
4. Down towards and medial lacrimal gland tumors
5. Down towards the ear, growth from the frontal sinus

Extent of proptosis can be measured by simple inspection or by employing various types of instruments called exophthalmometers. The fully developed proptosis is too obvious to miss;

Table 8.2: Acute or chronic proptosis.

Acute onset	*Gradual onset*
Retrobulbar hemorrhage, surgical emphysema of the orbit, acute orbital cellulitis, cavernous sinus thrombosis, panophthalmitis, acute dacryoadenitis, and fast-growing rhabdomyosarcoma (RMS)	Craniofacial dysostosis, pseudotumor of the orbit, dysthyroid orbitopathy, orbital tumor, orbital parasites, leukemia, periorbital tumor, optic nerve glioma, optic nerve meningioma, aneurysm of the ophthalmic artery, orbital varices

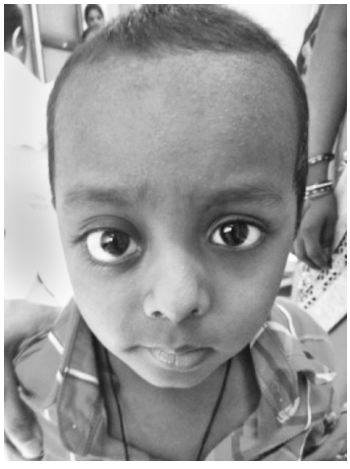

Fig. 8.3: Unilateral axial proptosis.

JAYPEE BROTHERS

difficulty arises when the proptosis is mild or minimum. To inspect, the patient is made to sit in a chair with the observer standing behind, and the patient's head is bent backwards. The observer looks down and notices the position of the cornea in relation to the upper orbital rim. In a normal orbit, the apex of the cornea is not visible in this position; if the cornea is visible beyond the upper lid margin, the patient suffers from proptosis **(Fig. 8.4)**. Proptosis can be accurately measured by exophthalmometers.



Fig. 8.4: Inspection of proptosis.

INFECTIOUS DISEASES OF THE ORBIT

The infectious diseases of the orbit could be intraorbital or from the walls and periosteum of the orbit. The common sources of infection with the orbital contents are any of the following, i.e., paranasal sinuses, blood, or penetrating injury. The infections of the contents are called orbital cellulitis, which could be acute, chronic, or recurrent.

Acute Orbital Cellulitis

This is an ocular emergency, specially in children requiring urgent attention; it is the most common cause of acute, painful unilateral proptosis. More common in children, it is associated with fever, chills, headaches, and pain in the orbit and periorbital structures. The most common source of infection is from acute or chronic paranasal sinuses. The signs consist of swelling of the lids, pseudoptosis congestion, and chemosis of the conjunctiva. Proptosis is mild to moderate. The movement of the globe is restricted. Diminished vision and sluggish pupillary reaction due to involvement of the optic nerve. The condition should be differentiated from preseptal Cellulitis, cavernous sinus thrombosis, panophthalmitis, retained foreign body, X-ray, shows presence of foreign body and evidence of sinusitis. CT is better than X-rays as it delineates specific sinuses involved, especially the ethmoid. It also reveals subperiosteal abscesses and intracranial involvement. Ultrasonography is also helpful in the diagnosis of orbital cellulitis. It shows the involvement of individual muscles. The management consists of the administration of an appropriate intravenous, broad-spectrum antibiotic in an age-related dose. Orbital cellulitis, if not treated well, will result in the formation of an orbital sinus opening on the skin. Partially treated orbital cellulitis passes into a stage of recurrence or chronic orbital cellulitis, which rarely may be converted into an orbital abscess.

Orbital Abscess

An orbital abscess is a collection of pus behind the orbital septum; its most common sign is mild to moderate proptosis, generally axial. The amount of proptosis depends on the size of the abscess. The other signs are restricted movement of the globe and diminished vision. The diagnosis is confirmed by ultrasonography and CT. A CT will reveal the exact position and size of the abscess. The treatment is a broad-spectrum systemic antibiotic. No attempt should be made to drain the abscess blindly.

Cavernous Sinus Thrombosis

This is yet another ophthalmic emergency that requires consultation with neuro physicians. The condition is an acute infection of the cavernous sinus situated just behind the orbit, receiving

JAYPEE BROTHERS

venous blood from many sources. Infections of the nose and face are most likely to cause cavernous sinus thrombosis. The disease starts on one side; the other side gets involved a few days later. The patient has a high fever, headache, and vomiting with diplopia and mild to severe proptosis. The effected side develops edema of the lids, and the conjunctiva is chemosed and red. The movements are restricted with diminished vision. The other eye commonly develops paralysis of the lateral rectus. That is followed by a clinical picture similar to the other eye involved. The condition should be differentiated between orbital cellulitis and ophthalmitis. The diagnosis is confirmed by CT and MRI. The treatment is multidisciplinary and requires the administration of broad-spectrum antibiotics and a life-support system.

Chronic Inflammation of the Orbit

This consists of a group of chronic inflammatory conditions of uncertain origin. The conditions are mostly wrongly diagnosed as malignancies of the orbit. They are called pseudotumors of the orbit. That may involve any structure in the orbit or even the lacrimal gland. The condition is supposed to be an autoimmune disease. The other causes are tuberculosis, syphilis, ruptured dermoid, leaking orbital abscess, and ruptured parasitic cyst. The condition is generally unilateral. Seen in the fourth to fifth decade, equally in both sexes. The symptoms are variable; they are mild to moderate proptosis. Swelling of the lids, puffiness of the conjunctiva, restricted muscle movement, and diminished vision. The diagnosis is by exclusion. X-rays has hardly any used in diagnosis; better results are found by USG, CT, and MRI. When the superior orbital fissure through which pass. All the cranial nerves serving the eye are involved; the condition is called superior orbital fissure syndrome. If the apex of the orbit is involved, it is called orbital apex syndrome. The superior orbital fissure syndrome presents with the underaction of single or many extraocular muscles. In the orbital apex syndrome, the optic nerve is also involved, along with the extraocular muscles.

Tumors of the Orbit

The orbit contains tissues of varied origin; it is surrounded by many extraorbital structures, such as paranasal sinuses; and it communicates with the brain as well. The orbital tumors may arise from its structures, invasion from neighboring structures, and secondaries from distant organs. The tumors of the orbit can be congenital or acquired. **Flowchart 8.1** shows the classification of orbital tumors.

Flowchart 8.1: Classification of orbital tumor.

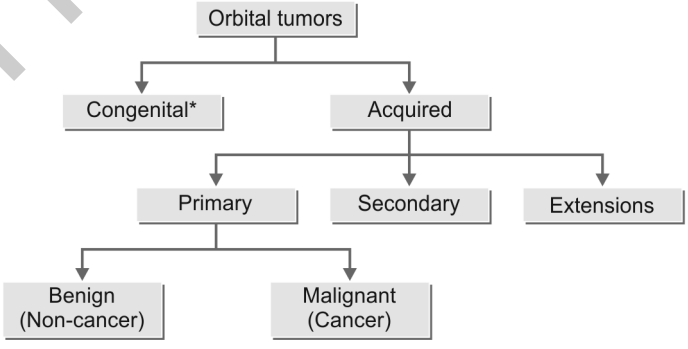

Congenital*

The congenital growths are dermoid, hemangioma, encephalocele, meningocele, and meningoencephalocele. The congenital growths are non-cancerous. They may be obvious at birth or diagnosed in the next few months or years.

JAYPEE BROTHERS

Dermoids

Dermoids are very common tumors encountered in orbital and paraorbital structures. They are cystic growths; they contain skin, hair, and fatty tissue. They may arise anywhere in the orbit; the growths behind the orbital septum cause proptosis, the amount of which depends on the position and size of the growths. The preseptal growths do not cause proptosis; the common sites of the tumors are the superomedial and superiotemporal ends or orbital margin **(Fig. 8.5)**. The dermoids present in front of the septum are visible and palpebral. They are spherical, firm growths over which the skin can be moved, non-tender, and fixed to the bone underneath. The growths are slow to develop, showing an increase in size at puberty; otherwise, they are symptoms-free. The diagnosis is confirmed by X-rays and CT, and the definite treatment of all dermoids is surgical removal without rupturing the wall. There is no recurrence following surgical removal; retroseptal dermoids are difficult to remove. They are removed by various orbitotomies.

Hemangioma of the Orbit

They are benign tumors of vascular origin, generally congenital, that remain asymptomatic and were discovered on routine imaging with a well-defined capsule. They are seen mostly in the fourth and fifth decades, causing the gradual onset of proptosis. The type and degree of proptosis depend on the position and size of the tumor. The standard management is surgical removal through an appropriate orbitotomy.

Meningocele (Fig. 8.2)

A normal orbit does not contain meninges that stop beyond the apex of the orbit. If the meninges find access to the orbit, they may lie dormant throughout their lives or may convert into a round cystic swelling. They may be pre- or retroseptal; the retroseptal growths are responsible for proptosis. They are best seen on CT and MRI. The treatment is surgical removal. If brain tissue finds its way into the meningocele, it is called a meningoencephalocele; still rare is the encephalocele, where brain tissue finds its way into the orbit. The treatment for all the above conditions is surgical removal.

Acquired Orbital Tumors

Acquired orbital tumors can be benign or malignant; the malignant tumor can be primary, secondary, extension from neighboring structures.

The common benign orbital tumors are hemangioma, glioma of the optic nerve, meningioma of the optic nerve, neurofibroma, and mixed tumor of the lacrimal gland.



Fig. 8.5: Preseptal dermoids in different ages not causing proptosis.

JAYPEE BROTHERS

The common primary malignant tumor of the orbit are rhabdomyosarcoma*, orbital lymphoma**, and carcinoma of the lacrimal gland.

Rhabdomyosarcoma (RMS)*

Rhabdomyosarcoma is a rare malignant tumor of soft tissue anywhere in the body, at all ages. It is a sarcoma that spreads rapidly. Orbital Rhabdomyosarcoma is the most common primary malignancy of orbit in children; 90% of them are seen before 15 years of age, with the average age being 5–7 years. The boy-to-girl ratio is 5:3 without any racial predisposition without any genetic background. Ophthalmologists are first to see them. The child is brought in with fast-growing puffiness of the lid with mild to moderate proptosis. That has not responded to the usual broad-spectrum antibiotics because it is often missed and diagnosed as slow-growing orbital cellulitis. The treatment consists of a combination of chemotherapy and radiation following an excisional biopsy by an oncologist.

Orbital lymphoma**

Primary orbital lymphoma is a rare malignant disorder of the orbit. It presents as gradual, progressive swelling of the lid and conjunctiva lacrimal gland with mild to moderate proptosis. The treatment consists of **surgery, radiotherapy, and chemotherapy by an oncologist.**

Common malignant tumors that invade the orbit are from eyeballs and neighbouring structures. The two intraocular malignancies that extend into the orbit are retinoblastoma in children and malignant melanoma. The second group consists of malignancies in the paranasal sinuses, nasopharynx, and brain. The metastatic tumors of the orbit in children are neuroblastoma, nephroblastoma, and Ewing's sarcoma. In adults, they are from the breast, lung, stomach, and prostate.

Clinical Presentation of an Orbital Tumor

They can be seen in any age in all races in both the sexes can be unilateral, bilateral, malignant, or non-malignant **(Figs. 8.6 and 8.7)**. Some of which respond well with treatment, occurrence following treatment is common. The symptoms depend on the location and size of the lesion and its nature, i.e., malignant or non-malignant. The most common symptoms are—proptosis, reduced movement diplopia—diminished vision pain in and around the orbit associated with symptoms of the primary tumor.



Fig. 8.6: Late presentation of unilateral retinoblastoma.



Fig. 8.7: Late presentation of bilateral retinoblastoma.

JAYPEE BROTHERS

Signs of Orbital Tumors

- **Proptosis:** Tumors in the muscle cone cause axial proptosis **(Fig. 8.3)**, tumors outside the cone cause eccentric proptosis away from the growth. Tumor from superiotemporal aspect cause proptosis down and in **(Fig. 8.8)**, growth from superomedial cause proptosis down and out **(Fig. 8.9)**.
- Restricted movement
- Variable diplopia
- Lagophthalmos
- Diminished vision
- Corneal and conjunctival exposure
- The eyeball may/may not be pushed back by pressure

The diagnosis is confirmed by:

- X-ray, USG, CT and MRI
- Biopsy
  - Fine needle biopsy
  - Excisional biopsy

Treatment

Treatment depends on the nature of the tumor, the benign tumors are best removed surgically, while primary malignant tumors are treated by surgery, chemotherapy, and radiation. May be alone by one method or combination. The tumors extending from the neighboring structures and the metastatic tumor require treatment of the primary tumor along with ophthalmic treatment, both under the supervision of an oncologist.

Exophthalmos

The term exophthalmos is used to denote the forward placement of the eyes in thyroid orbital diseases. It generally happens in hyperthyroidism, can be seen in hypothyroidism, or even without



Fig. 8.8: Eccentric proptosis due to growth from superomedial orbit.
(*Courtesy:* Professor Somen Misra)



Fig. 8.9: Eccentric proptosis due to growth from superiotemporal orbit.
(*Courtesy:* Professor Somen Misra)

JAYPEE BROTHERS

involvement of the thyroid. It is more commonly seen in women; it may start in one eye. When bilateral, the amount of exophthalmos need not be the same in the two eyes. The patients may not be aware of developing exophthalmos because it is slow and progressive. The first clinical feature is lid retraction, followed by lid lag and diplopia. The exophthalmos is clinically divided into mild, moderate, and severe grades; in the late stages, there may be exposure to the cornea, causing irritation and lacrimation. The corneal exposure may lead to corneal ulceration. Hyperthyroidism and hypothyroidism are treated by endocrinologists. The ocular features are managed by the ophthalmologist**.**

Enophthalmos

Enophthalmos is the backward placement of a normal or small eyeball in relation to the normal position. The causes of these are microphthalmos **(Fig. 8.10)**, phthisis bulbi, and fibrosis of the muscle, fracture of the flow of the orbit following squint surgery, retraction syndrome, and Horner's syndromes. The signs of enophthalmos are a narrow interpalpebral aperture and the appearance of pseudoptosis; the curvature is less; the vision is low and cannot be corrected; the only treatment is either to increase the orbital volume or to place an artificial eye **(Fig. 8.11).**



Fig. 8.10: Bilateral enophthalmos.



Fig. 8.11: Left artificial eye due to microphthalmos.

JAYPEE BROTHERS

for detailed information on ophthalmology books, visit our website www.jaypeebrothers.com, for detailed information on ophthalmology books, visit our websi

TEXTBOOK FOR
OPHTHALMIC ASSISTANTS

Salient Features

- The book is meant for students who have passed a higher secondary examination.
- Use of simple language for easy understanding.
- Comprises 17 chapters.
- The first deals with the basics of ophthalmology, including optics. The remaining chapters deal with disorders of parts of the eye.
- The book covers preliminary medical treatment without going into advanced therapeutics.
- Operative procedures have been deliberately omitted.
- Generously illustrated by photographs and diagrams.

PK Mukherjee MBBS MS is a Practicing Consultant and Counselor in ophthalmology. He is a *Former* Professor and HOD in the upgraded Department of Ophthalmology, presently known as the Regional Institute of Ophthalmology, at Pt Jawahar Lal Nehru Memorial Medical College, Raipur, Chhattisgarh, India. He has an experience of 40 years as a clinical teacher in various medical colleges in states of Madhya Pradesh (MP) and Chhattisgarh. He has been an examiner in undergraduate and postgraduate examinations in various universities. Along with teaching assignments, he has been in administration positions as well, i.e., Superintendent of the Medical College Hospital, Principal of the medical college, Dean of the faculty of medicine, Pt Ravishankar Shukla University, Raipur, Chhattisgarh. He was in-charge of the mobile unit of the medical college in Raipur, performing numerous eye camps all over the state of Chhattisgarh. He specializes in community and pediatric ophthalmology. He has three innovations to his credit, i.e., corrections of cicatricial entropion from the conjunctival surface, correction of spastic entropion, and nasolacrimal duct intubation. He has published many postgraduate books in ophthalmology and published papers in national and international journals. He was awarded the Professor Wagle Oration Award for his work on ocular leprosy. He is a recipient of the Dr RK Mishra Gold Medal for his contribution toward ophthalmology by the MP State Ophthalmological Society. He is also a recipient of the Dr MR Pandey Gold Medal for his contribution in the field of community ophthalmology. In the years 2011–2012, he was honored with the Dr Kummud Joshi Oration Award of the National Society for the Prevention of Blindness (MP). He received Lifetime Achievement Award from the Chhattisgarh State Ophthalmic Society in 2009 and from Association of Community Ophthalmologists of India (ACOIN) in 2013. He is President Emeritus of the Chhattisgarh State ACOIN. He is a lifetime member of All India Ophthalmological Society (AIOS), the MP State Ophthalmological Society, the Chhattisgarh State Ophthalmological Society, and the Ocular Trauma Society of India. In 2023, he was bestowed with the honor of Mentor of Mentors at the first international conference of ACOIN.

Printed in India

Available at all medical bookstores
or buy online at www.jaypeebrothers.com

JAYPEE BROTHERS
Medical Publishers (P) Ltd.
EMCA House, 23/23-B, Ansari Road,
Daryaganj, New Delhi - 110 002, INDIA
www.jaypeebrothers.com

Join us on facebook.com/JaypeeMedicalPublishers

Shelving Recommendation
OPHTHALMOLOGY

ISBN 978-93-5696-545-4