ed information on cardiology books, visit our website www.jaypeebrothers.com, for detailed information on cardiology books, visit our website www.jaypeebrothers.com, for detailed

DECODING CTO

(Chronic Total Occlusion)

Case-based Discussions

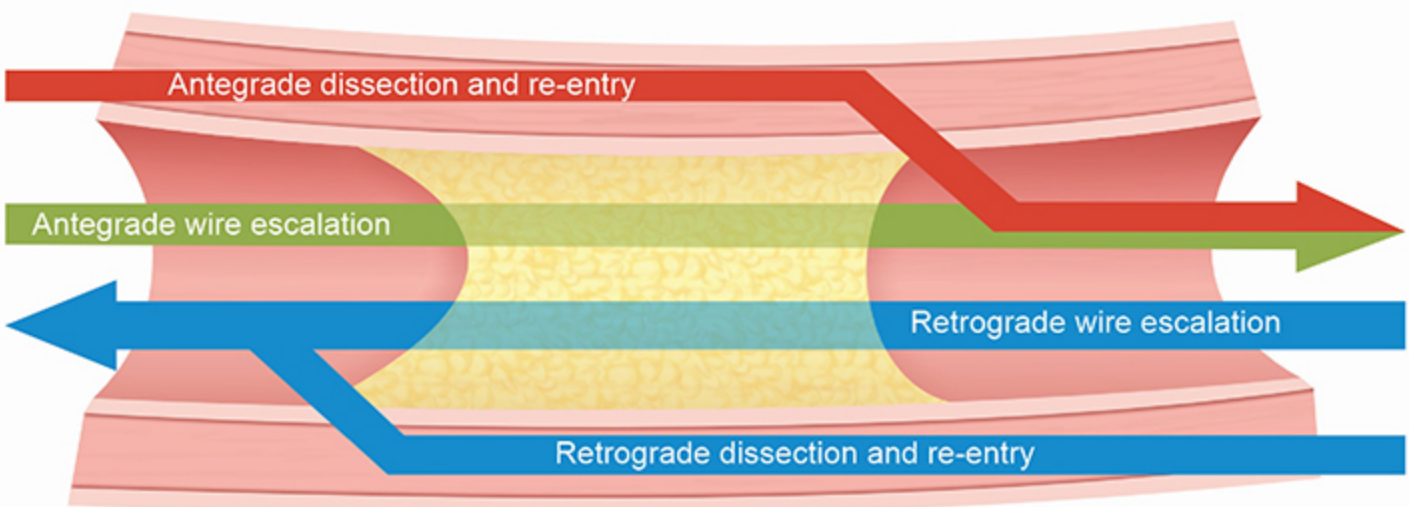

Editor-in-Chief
Sharath Reddy

Editor
Himanshu Gupta

JAYPEE

Contents

Case 1. Post-CABG Right Coronary Artery CTO: Antegrade Approach 1

Sharath Reddy, Balaji

- Review of Relevant Techniques Used/Useful in Case
- Microchannels Visualization and Wiring

Case 2. Successful Retrograde PCI after Antegrade Failure 8

Sharath Reddy, Bharath Reddy

- Review of Relevant Techniques Used/Useful in Case
- Conventional Reverse CART
- Directed Reverse CART
- Extended Reverse CART

Case 3. Collateral Uncrossability with Microcatheter 18

Sharath Reddy, Harshavardhan

- Review of Relevant Techniques Used/Useful in Case
- Collateral Uncrossability with Microcatheter

Case 4. Stumpless Ostial CTO of Right Coronary Artery 25

Sharath Reddy, Chaitanya

- Review of Relevant Techniques Used/Useful in Case
- Ostial RCA CTO

Case 5. Difficult Reverse CART 35

Sharath Reddy, Anil Krishna

- Review of Relevant Techniques Used/Useful in Case
- Difficult Reverse CART

Case 6. Ipsilateral Retrograde with Ping-pong Guide for LAD CTO 44

Sharath Reddy, Premchand

- Review of Relevant Techniques Used/Useful in Case
- Guiding System for Ipsilateral Collateral
- Techniques to Avoid Wire Externalization after Retrograde CTO Crossing

Case 7. Long RCA CTO with LV Dysfunction and Renal Failure 53

Sharath Reddy, Lalith Aggarwal

- Review of Relevant Techniques Used/Useful in Case
- CrossBoss-Stingray® System
- Failure to Obtain Reentry
- Managing the Reentry Zone/Subintimal Hematoma

Case 8. Mid-RCA CTO with Impenetrable Proximal and Distal Cap 64

Sharath Reddy, Venkat Rao

- Review of Relevant Techniques Used/Useful in Case
- Techniques Useful/Used in Impenetrable Proximal Caps
- Prevention and Management of Subintimal Hematoma

Case 9. Ambiguous Proximal Cap: ADR after Retrograde Failure 74
Sharath Reddy, Praveen
- Review of Relevant Techniques Used/Useful in Case
- How to Choose between Parallel Wire and Stingray® Reentry when Antegrade Wire Ended Up in Subintimal Position?
- How to Use Stingray® Reentry without CrossBoss®

Case 10. Long RCA CTO with Bifurcation at Distal Cap after Failed Retrograde Approach 84
Sharath Reddy, MSS Mukherjee
- Review of Relevant Techniques Used/Useful in Case
- Knuckle Wire Technique
- ADR in Patients with Bifurcation at Distal Cap
- Side Branch Salvation Using Retrograde Wire in RCA ADR with Reentry in PLVB

Case 11. Balloon Uncrossable CTO 97
Sharath Reddy, Movva Srinivas
- Review of Relevant Techniques Used/Useful in Case
- Strategies in Balloon Uncrossable Lesions

Case 12. Long RCA CTO with Ambiguous Course: Use of Retrograde Knuckle Wire 104
Sharath Reddy, Damodhar Reddy
- Review of Relevant Techniques Used/Useful in Case
- Approach in Patient with Wire Divergence in RCA
- Reasons for Wire Divergence in Mid-RCA

Index 115

9

CASE

Ambiguous Proximal Cap: ADR after Retrograde Failure

Sharath Reddy , Praveen

I. CASE DISCUSSION

Clinical Data

- *Age:* 75 years
- *Gender:* Male
- *Clinical history and diagnosis:* ACS, NSTEMI
- *ECG:* Deep T inversions in anterior leads
- *ECHO:* No RWMA, good LV/RV function
- *Left ventricular systolic function:* EF 58%
- *Estimated glomerular filtration rate:* 84 mL/min/1.73 m^2
- *Other comorbidities:* None
- *Target lesion:* LAD CTO

Coronary Angiographic Image Analysis

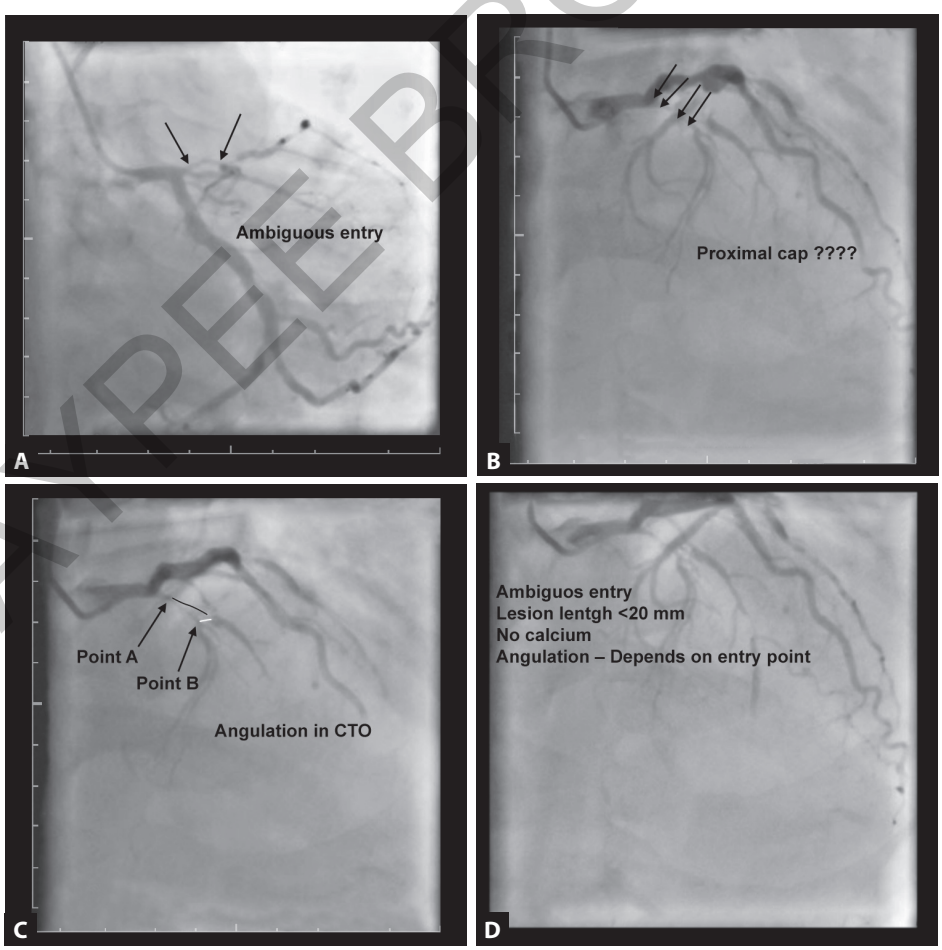

Figs. 9.1A to D

JAYPEE BROTHERS

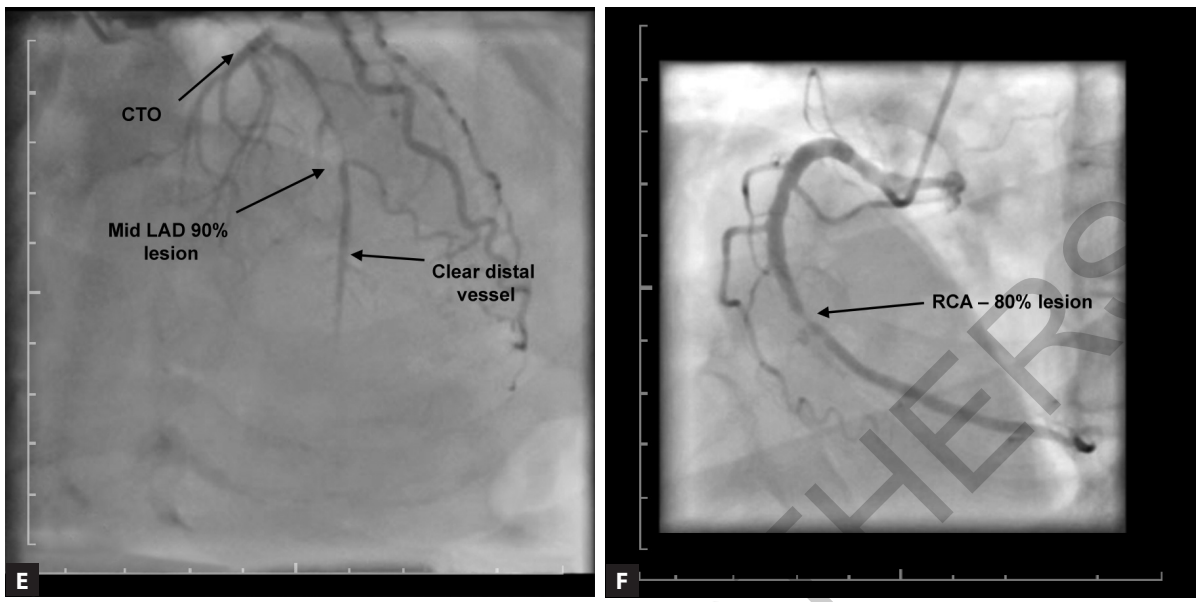

Figs. 9.1E and F

Figs. 9.1A to F: Preprocedural coronary angiographic images: (A) AP-caudal view: Proximal cap ambiguity; (B) AP-cranial view: Proximal cap ambiguity: Proximal cap can be at any point (marked by arrows); (C) Angulation within the CTO depends on site of proximal cap; if entry is at point A there is no angulation, if entry is at point B angulation within CTO segment is very acute; D J-CTO score: Ambiguous entry, no calcification, lesion length <20 mm, angulation depends on proximal cap location; (E) Post-CTO segment mid-LAD 70–80% lesion with clear distal vessel; and (F) Mid-RCA 80% lesion.

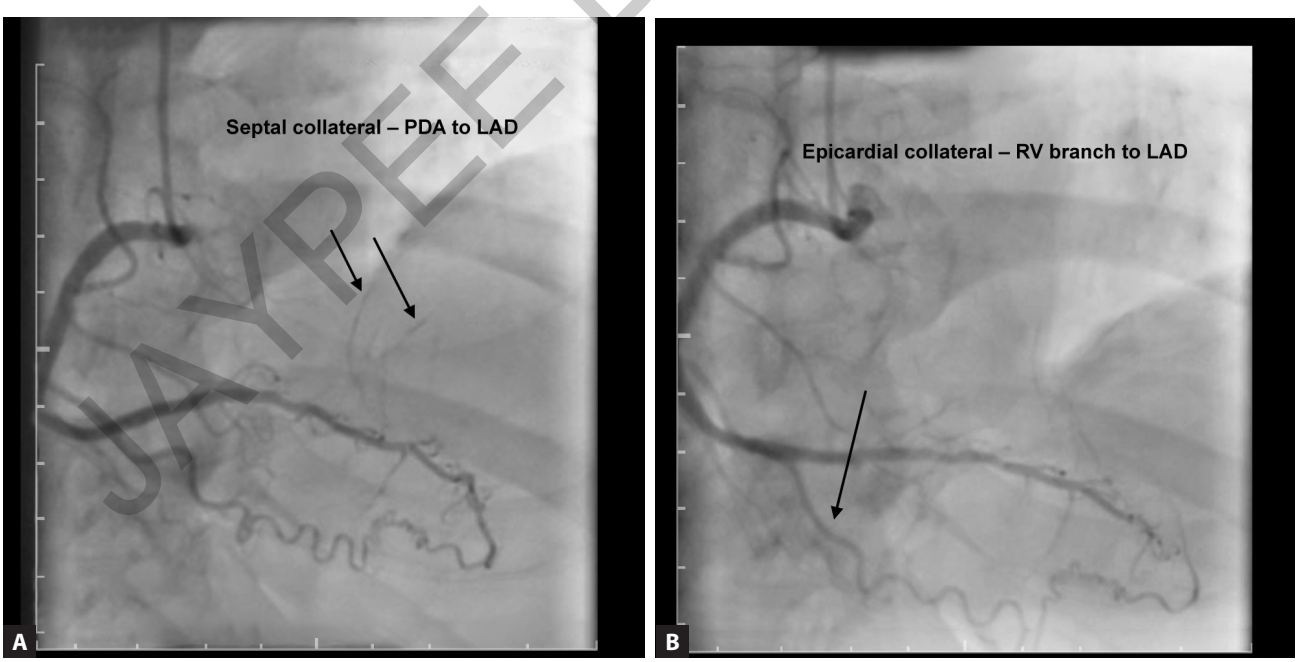

Figs. 9.2A and B: Collateral channel types: (A) Septal collaterals from PDA to LAD filling before LAD filling from epicardial collateral; (B) Epicardial collaterals from RV branch to distal LAD.

JAYPEE BROTHERS

Anatomicogram

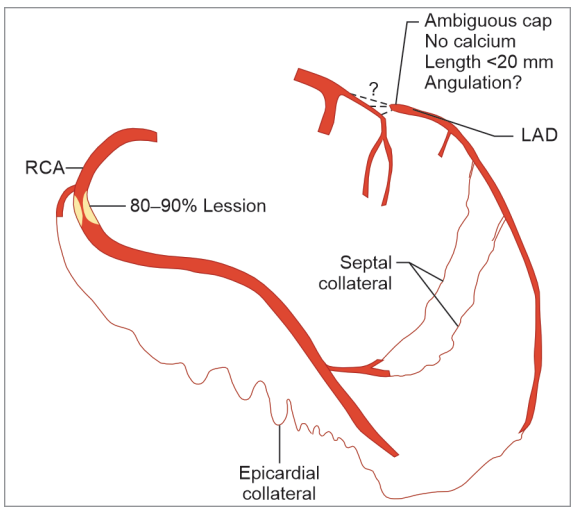

Collateralogram

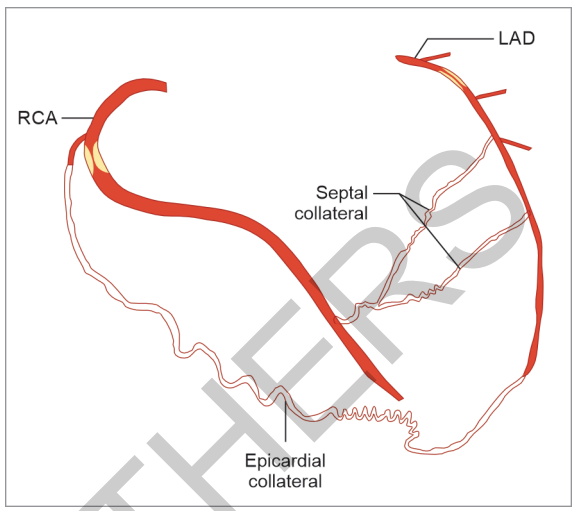

J-CTO Score

Parameter		Score
Entry shape	Ambiguous	1
Calcification	Absent	0
Bending >45°	Present	?
Occlusion length	>20 mm	0
Retry lesion	Yes	0
Total		1 or 2 (depends on proximal cap entry point)

Which Vessel to Treat First? RCA or LAD

Treat RCA first; chances of retrograde wiring for LAD are of high probability due to ambiguous proximal cap and possible acute angulation.

Planning Wiring Strategy

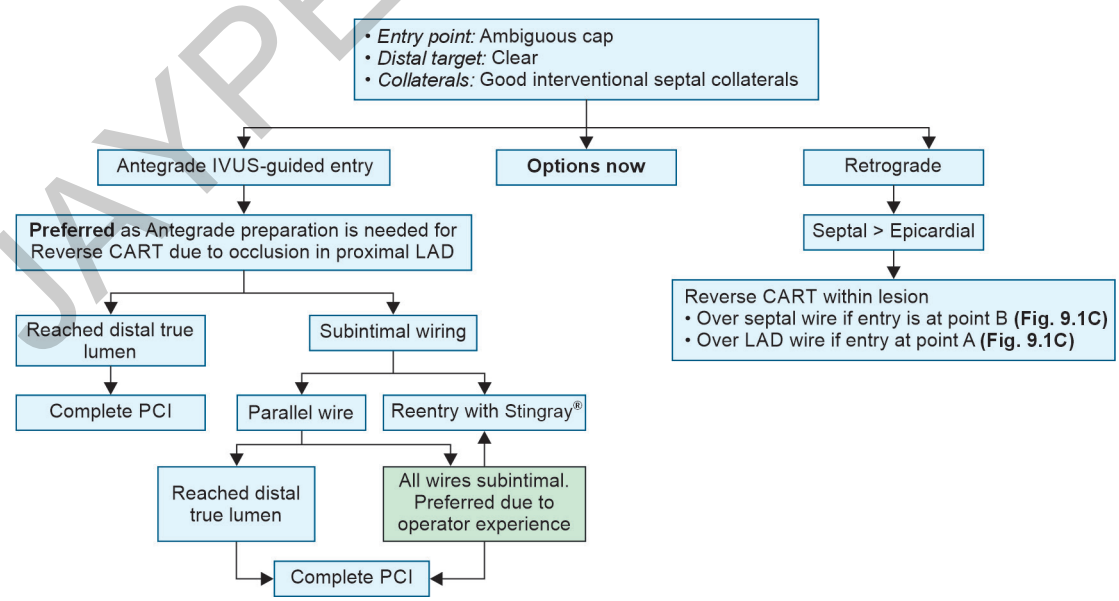

JAYPEE BROTHERS

Technical Challenges and Solutions

Challenges	*Solutions*
Ambiguous entry	IVUS-guided antegrade wiring
If proximal cap is located at point B **(Fig. 9.1C)**, angulation >45° within CTO segment	• Attempt wiring with Gaia® series guidewire with double-lumen catheter within septal • If unsuccessful, go retrograde with reverse CART with balloon over septal wire
Donor vessel lesion	Complete PCI to RCA first
Collaterals: Tortuosity in septal collaterals	Choose Suoh-03® wire for crossing may need to try different types of microcatheters for crossing

PCI Procedure

- *Access:* Bifemoral
- *Sheath:* Two 7F 45 cm Cook sheaths
- *Guide: RCA:* 7F, AL-1
- *Microcatheter:* Antegrade: FineCross 150®

Note: Correlate the following figures with the PCI procedure steps in the flowchart.

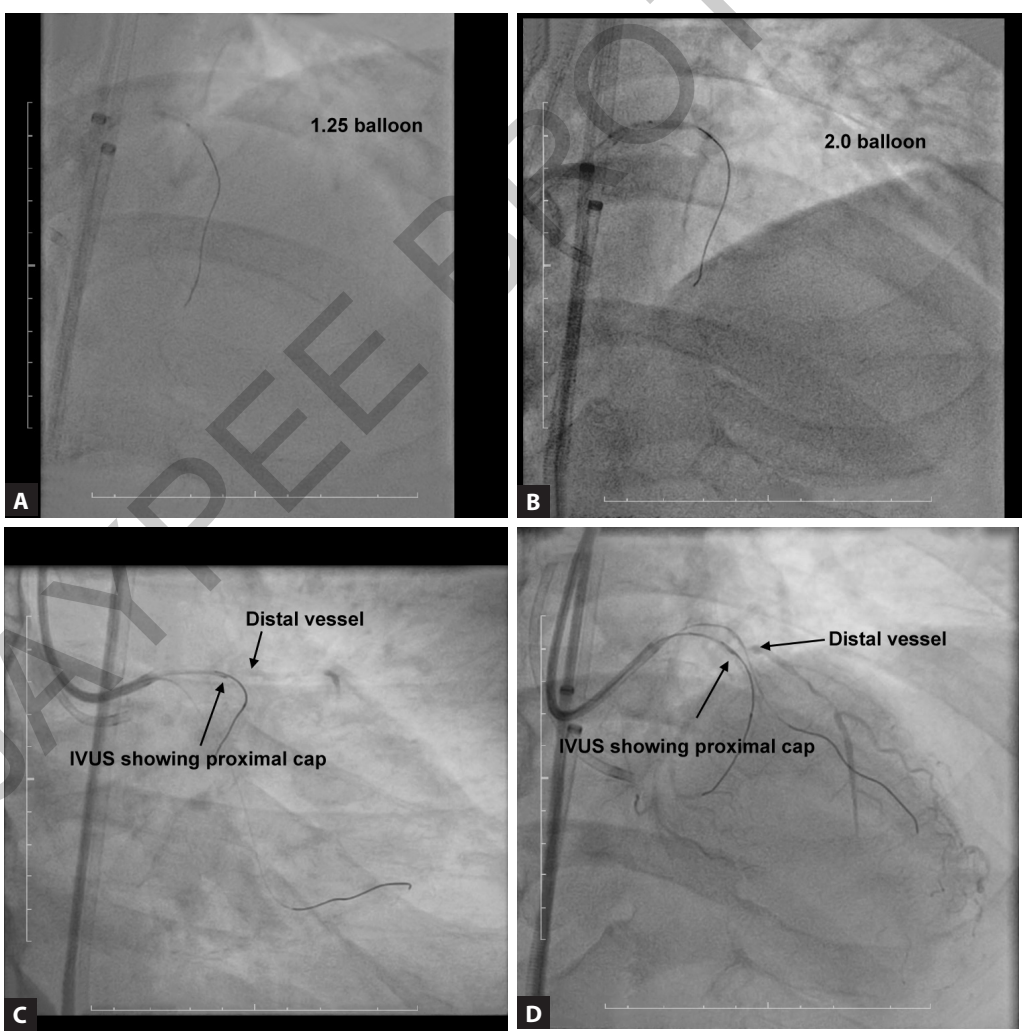

Figs. 9.3A to D

JAYPEE BROTHERS

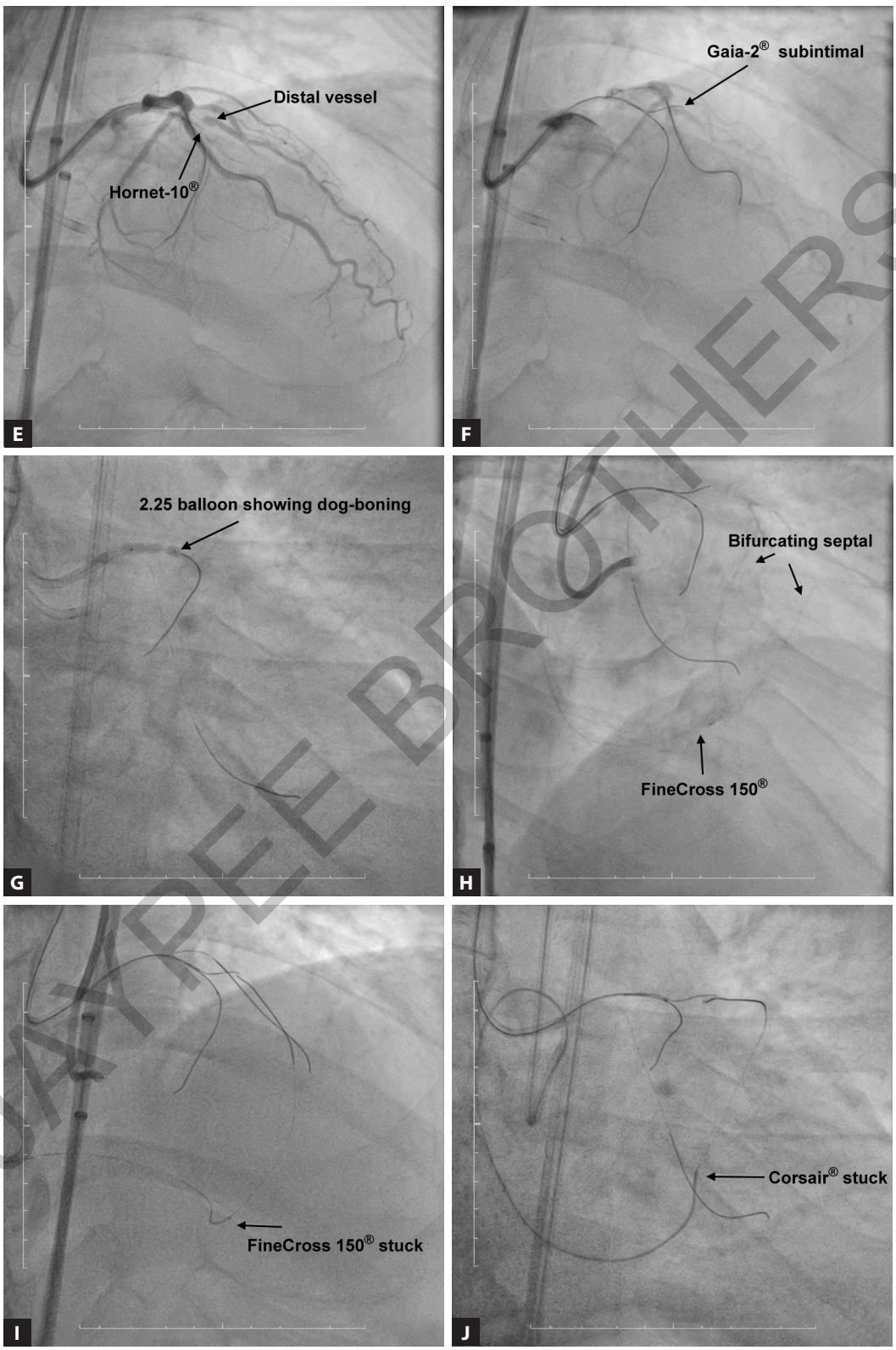

JAYPEE BROTHERS

Figs. 9.3E to J

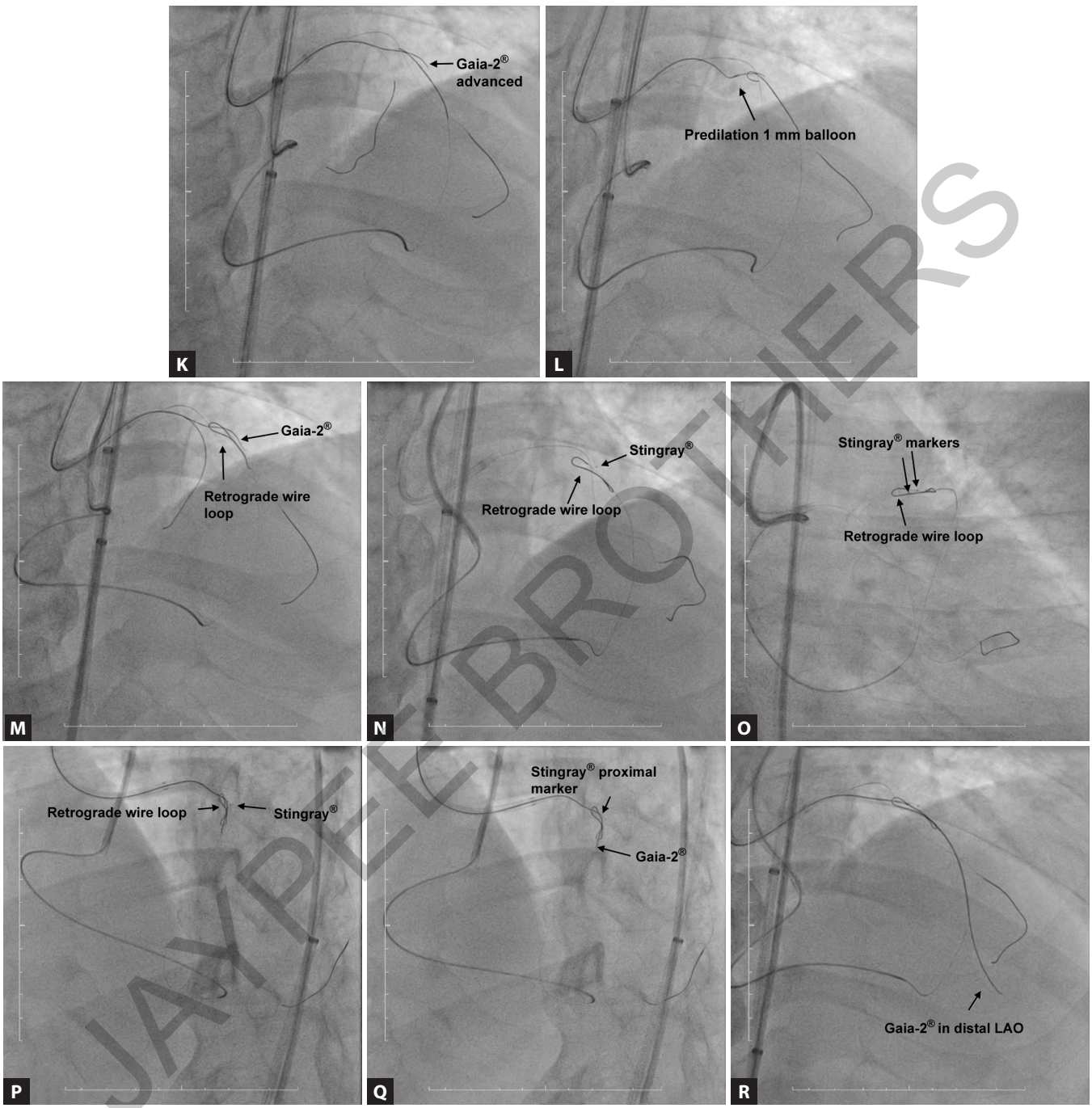

JAYPEE BROTHERS

Figs. 9.3K to R

Figs. 9.3A to R: Coronary angiographic images of CTO PCI procedure: (A) Serial predilatation with 1.25 mm balloon; (B) Serial predilatation with 2 mm balloon; (C) IVUS used for determining proximal cap location in AP caudal view; (D) IVUS used for determining proximal cap location in AP cranial view; (E) Hornet-10® wire perforated the cap and went off due to severe angulation; (F) Gaia-2® deviated into subintimal plane; (G) Dog-boning with 2.25 mm balloon; (H) Selective septal angiogram showing septal bifurcation and position of FineCross 150®; (I) FineCross 150® stuck in the septal collateral channel; (J) Angiogram showing Corsair® stuck in the septal; (K) Gaia-2® advanced further; (L) Predilatation was performed with 1 mm balloon; (M) Retrograde wire looped for Stingray® reentry; (N) Retrograde wire loop at distal cap and both Stingray® markers seen outside the loop; (O) Retrograde wire loop and Stingray® markers observed in parallel to each other; (P) Retrograde wire loop and Stingray® relation observed in LAO Cranial view; (Q) Angiogram showing Gaia-2® in distal LAD; and (R) Stick and drive technique with Gaia-2® in LAO cranial view.

PCI Procedure Flowchart with Available Options at Various Stages

Flowchart 9.1: Stepwise presentation of CTO PCI procedure.

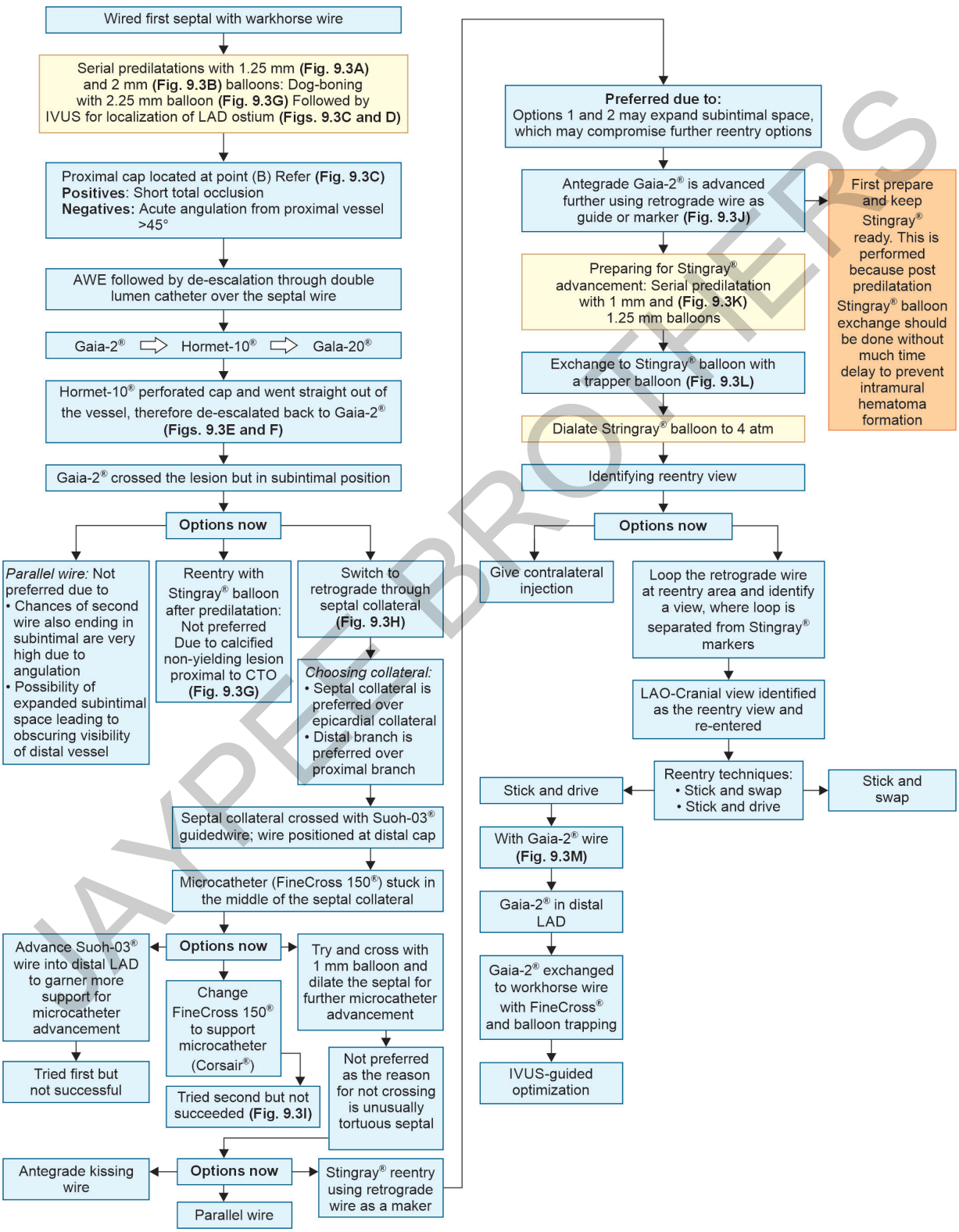

JAYPEE BROTHERS

Pre- and Post-PCI Images

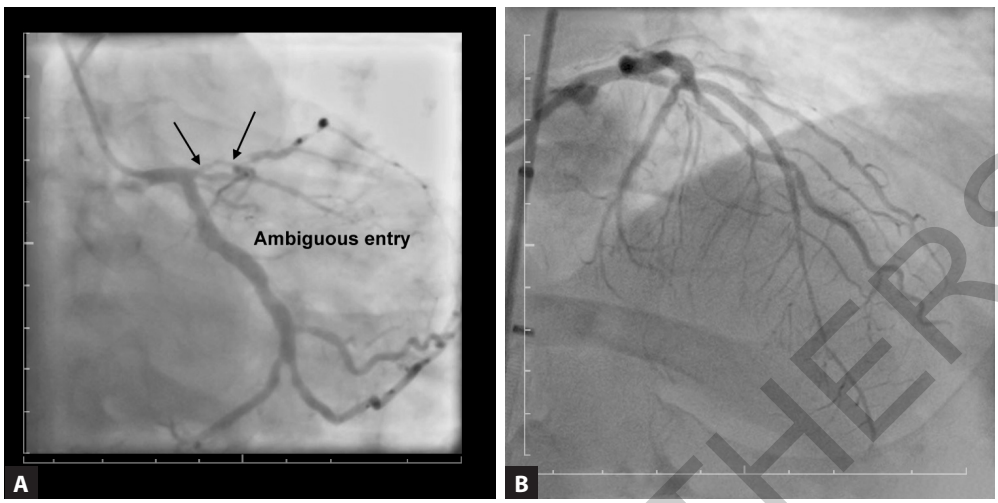

Figs. 9.4A and B: Pre- and post-PCI coronary angiographic images: (A) Pre-PCI image; (B) Post-PCI image.

Postprocedure Details

- *Volume of contrast:* 120 mL
- *Fluoro time:* 80 minutes
- *Contrast and radiation dose:* 3,050 mGy
- *Procedure time:* 120 minutes

Periprocedure Complications

None

II. CASE SUMMARY

In this case we treated non-CTO vessel (RCA) before treating the CTO. We started with IVUS-guided antegrade entry after performing predilatation over septal wire. However, as the angulation between proximal cap and proximal LAD was very acute (<45°), antegrade wire (Gaia-2®) through double lumen catheter ended up subintimal. So, at this stage we changed strategy to retrograde rather than antegrade parallel wire for Stingray® reentry. Although, we were able to wire (Suoh-03® wire) LAD retrogradely we failed to advance microcatheter (FineCross 150®) across septal despite increasing support and changing microcatheter. Here, we switched back to antegrade to reenter into true lumen by using Stingray®. The Stingray® is positioned at reentry area (immediately after CTO, i.e., in-between CTO and mid-LAD lesion) after thorough predilatation with smaller balloons (1.25 mm). Reentry view is identified by knuckling retrograde wire (Suoh-03®) within the lumen and identifying a view where the knuckle and balloon markers are separated well. Reentry is achieved by stick and drive approach with Gaia-2® wire followed by PCI optimization with IVUS.

II. REVIEW OF RELEVANT TECHNIQUES USED/USEFUL IN CASE

In this case, we discuss:

- How to choose parallel wire versus Stingray® reentry when antegrade wire ended up in subintimal position
- How to use Stingray® reentry without CrossBoss®
- Using retrograde wire loop marker to understand Stingray® lumen relation for reentry

How to Choose between Parallel Wire and Stingray® Reentry when Antegrade Wire Ended Up in Subintimal Position?

Parallel Wire Technique

Factors favoring parallel wiring:

- Softer distal cap
- Lack of expansion of peri-wire space with preserved antegrade wire control
- Large distal true lumen size
- Good retrograde filling
- Ease of delivering a DLC to the distal cap

The following **Table 9.1** represents the differences in the anatomical factors while choosing between Stingray® and parallel wiring.

JAYPEE BROTHERS

TABLE 9.1: Differences in the anatomical factors between Stingray® and parallel wiring.

Factors	*Stingray®*	*Parallel wiring*	*Notes*
Bifurcation at distal cap	–	+	Retrograde is the best option; parallel wiring is favored if no retrograde option
Soft distal cap	–	+++	–
First wire position subintimal intraplaque	++	–	Subintimal manipulation of wire increases risk of hematoma expansion
Good reentry zone	+++	–	–
Mid-RCA distal cap	–	++	Mid-RCA is often difficult to sting and so parallel wiring is preferable
First wire near to lumen	+++	+	–
Good antegrade wire control	–	+++	If antegrade wire control is poor, then prefer Stingray®
Calcium in reentry zone	–	+++	Calcium in reentry zone does not influence parallel wire
Calcium in CTO	++	–	Calcium reduces parallel wire control

Reentry with Stingray® Balloon

Factors that favor Stingray® include:

- A large vessel
- Calcium free entry zone
- Distal right coronary artery reentry zone
- Wire position <0.5 mm from true lumen
- Absence of bifurcation in distal cap
- Lack of hematoma expansion
- Good retrograde filling
- Ease of delivery of the Stingray® catheter to the reentry zone

How to Use Stingray® Reentry without CrossBoss®

When antegrade wire ends in subintimal position **(Flowchart 9.2)**, after crossing CTO, following techniques can be used for Stingray® reentry.

Flowchart 9.2: Antegrade wire in subintimal position.

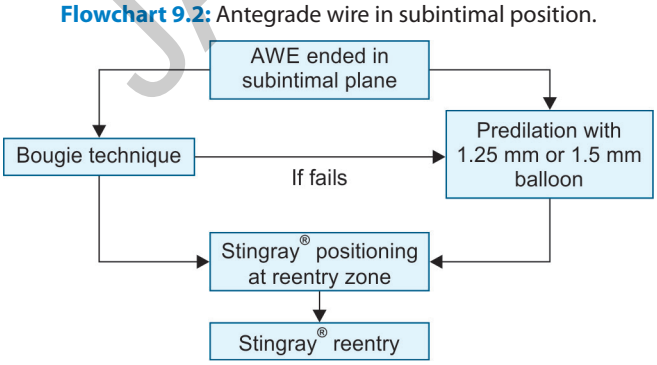

Bougie technique: When antegrade wire ends in subintimal plane parallel to the distal cap, advance the antegrade rotational microcatheter (Corsair® and Turnpike®) over the wire into the reentry zone to create subintimal space for subsequent advancement of Stingray® balloon for reentry. If microcatheter is not tracking down, dilate the track with 1.25 mm balloon followed by Stingray® advancement.

Intentional Stingray® after knuckle wiring: When Stingray® reentry is planned after knuckle wiring to cross the CTO segment, the following method will increase the success of reentry **(Flowchart 9.3)**.

Flowchart 9.3: Intentional Stingray® after knuckle wiring.

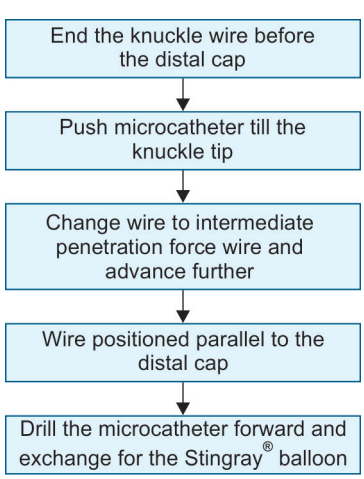

JAYPEE BROTHERS

IV. CONCLUSION

This is a case of successful ADR performed using Stingray® balloon using retrograde wire as marker for reentry after a failure of retrograde microcatheter to cross.

V. SUGGESTED READING

1. Carlino M, Azzalini L, Mitomo S, Colombo A. Antegrade fenestration and re-entry: A new controlled subintimal technique for chronic total occlusion recanalization. Catheter Cardiovasc Interv. 2018;92(3):497-504.
2. Horisaki T, Surmely JF, Suzuki T. Contact wire technique: a possible strategy for parallel wire techniques. J Invasive Cardiol. 2007;19(9):E263-4.
3. Rathore S, Suzuki T. Parallel wire technique. In: Waksman R, Saito S (Eds). Chronic Total Occlusions: A Guide to Recanalization, 1st edition. Germany: John Wiley & Sons, Ltd.; 2013. pp. 143-6.
4. Tanabe G, Oikawa Y, Yajima J, Matsuno S, Kano H, Yamashita T. Retrograde parallel wire technique using a dual lumen catheter can be useful for percutaneous coronary intervention with chronic total occlusion. Cardiol Cases. 2018:17(1):25-8.
5. Tanabe M. TCTAP C-l 03 The "Contemporary" Parallel Wire Technique Against Heavy Calcified CTO Lesion. J Am Coll Cardiol. 2015:65(17 Supplement):S247-50.
6. Toma C, Karatasakis A, Karmpaliotis D, Alaswad K, Yeh RW, Jaffer F, et al. TCT-273 Predictors of successful Stingray-assisted antegrade dissection reentry: data from the Progress CTO registry. J Am Coll Cardiol. 2016:68(18 Supplement):B111-2.

JAYPEE BROTHERS

for detailed information on cardiology books, visit our website www.jaypeebrothers.com, for detailed information on cardiology books, visit our website www.jaypeebrothers.com, for

DECODING CTO

(Chronic Total Occlusion)

Case-based Discussions

Salient Features

- Case-based approach for translating theory into practice
- Depiction of anatomicogram and collateralogram for easy understanding of coronary anatomy to tailor-wiring strategy for the case
- Flowcharts of wiring strategy, which make reader understand all available options at every step of wiring strategy
- "Challenges and Solutions" column discussing unique challenges in the case and its circumvention with specific strategy.

Sharath Reddy MD DM FSCAI FACC FAHA FESC is a renowned Senior Interventional Cardiologist and Director of CTO and Complex Coronary Interventions, TAVR and Structural Heart Diseases, and CATH Lab Medicover Hospitals, Hyderabad, Telangana, India, with a career spanning over two decades. He has extensive experience and expertise in treating chronic total occlusions (CTOs), complex coronary interventions, complex high-risk indicated percutaneous coronary interventions (CHIP-PCIs), and structural heart interventions. He was awarded Fellowships in the Society for Cardiovascular Angiography and Interventions (SCAI), American College of Cardiology (ACC), and American Heart Association (AHA).

He has received several awards in national and international conferences for his innovative techniques in resolving complex scenarios. He was honored with the Anumolu Seshagiri Rao Memorial Gold Medal for being the best outgoing postgraduate in cardiology for the year 2009. As a prolific Researcher, he has published numerous peer-reviewed papers in national and international journals and contributed for book chapters.

Dr Reddy is a Proctor for complex coronary interventions and regularly conducts workshops and webinars to share his invaluable expertise to the next generation. This book, *Decoding CTO: Case-based Discussions* reflects his practical efforts to decode this unchartered territory of interventions in a country which is still evolving in fine-tuning its healthcare strategies.

Printed in India

Available at all medical bookstores or buy online at www.ejaypee.com

JAYPEE BROTHERS
Medical Publishers (P) Ltd.
EMCA House, 23/23-B, Ansari Road,
Daryaganj, New Delhi - 110 002, INDIA
www.jaypeebrothers.com

Join us on facebook.com/JaypeeMedicalPublishers
Follow us on instagram.com/JaypeeMedicalPublishers

Shelving Recommendation
CARDIOLOGY

ISBN 978-93-5696-553-9