brothers.com, for detailed information on nursing books, visit our website www.jaypeebrothers.com, for detailed information on nursing books



# A Practical/Clinical Case Record of Maternal and Newborn Nursing Practice

**Name of the Candidate:** _____

**Name of the Institution:** _____

_____

**Sushila Singh Bais**
**Biula**

JAYPEE

# Contents


1. **Antenatal Examinaion** ..... 1
2. **Per Vaginal Examination** ..... 131
3. **Normal Delivery** ..... 155
4. **Episiotomy and Suturing** ..... 287
5. **Cesarean Section** ..... 295
6. **Medical Termination of Pregnancy/Dilatation and Evacuation** ..... 303
7. **Postnatal Cases** ..... 311
8. **Newborn Assessment** ..... 419
9. **Neonatal Resuscitation** ..... 433
10. **IUCD Insertion** ..... 455

# Antenatal Examination



JAYPEE BROTHERS

JAYPEE BROTHERS

## PREGNANCY

- Pregnancy is the state of a female after conception and until the termination of gestation. The duration of pregnancy is approximately 280 days or 40 weeks.
- Calculation of expected date of delivery (EDD) and duration of pregnancy.
- EDD = LMP + 9 months + 7 days (Naegele's formula).
- Duration of pregnancy in weeks (gestational age) = Total number of days from first day of LMP to the date of examination ÷ 7.

## SPECIFIC NURSING PROCEDURE IN OBSTETRICS

### Antenatal Abdominal Examination

#### *Purposes*

- To determine the fetal lie, presentation, position and engagement.
- To observe the sign of pregnancy.
- To detect any deviation from normal.

#### *Articles*

- Fetoscope and stethoscope.
- Measuring tape and weighing machine.

#### *Procedure*

| *Nursing action* | *Rationale* |
|---|---|
| Explain the procedure to the mother and advice her to empty the bladder and come | Reduce anxiety and avoids discomfort during palpation |
| **Inspection**<br>◆ Position the women in supine position with a pillow under the head and shoulder, have arms by side, expose abdomen from below breast to symphysis pubis<br>◆ Inspect abdomen for contour, umbilicus, flanks, skin changes like linea nigra, striae gravidarum, striae albicans and previous scars | Promotes relaxation of abdominal muscle<br> |
| **Palpation**<br>◆ Measure the abdominal girth using measuring tape (at term normal abdominal girth is 90–100 cm)<br>◆ Identity the fundus using the ulnar border of the palm, and measure the fundal height using measuring tape<br>◆ Determine the gestational age by using finger method, keep the border of the index finger of the supinated right arm at the level of umbilicus and calculate the gestational age (four fingers indicate 4 weeks) | The number of centimeters measured should be approximately equal to the weeks of gestation after 22 to 24 weeks |

*Contd...*

JAYPEE BROTHERS

*Contd...*

| *Nursing action* | *Rationale* |
|---|---|
| ***Leopold's maneuvers***<br>◆ Be sure your hands are warm before the procedure<br>◆ Use the flat palmar surface of fingers and apply smooth deep pressure as firm as necessary to obtain accurate findings<br>***Fundal palpation (1st Leopold)***<br>Face the women's head, place your hands on the sides of the fundus and palpate around the top of the uterus. Palpate for shape, size and mobility of the fetal part | 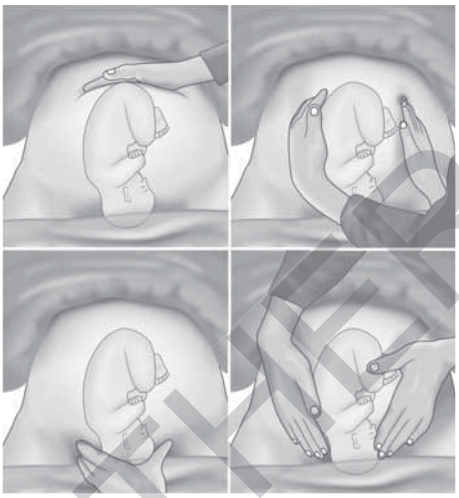<br>The maneuvers consist of four distinct actions to determine the position and estimate the birth weight of a fetus inside the utetur, And the shape of the maternal pelvis. It can indicate whether the delivery is going to be complicated, or whether a caesarean section is necessary. |
| ***Lateral palpation (2nd Leopold)***<br>Continue to face the women's head, place your hands on both sides of the uterus about midway between the symphysis pubis and the fundus. Apply pressure with one hand against the side of the uterus, pushing the fetus to the other side and stabilizing it there. Palpate both sides of the abdomen | ◆ Cold hands cause muscle contraction and discomfort<br>◆ Round hard mass—fetal head, soft broad mass-buttocks<br>◆ Continuous soft mass—spine small, knobby, irregular mass- limbs |
| ***Pelvic palpation***<br>*Fourth Leopold (pelvic grip 1)*<br>Face the women's feet, place your hands on the sides of the uterus, press deeply with the finger tips into the lower abdomen and move towards pelvic inlet | ◆ If hands are converging, fetal head is not engaged<br>◆ If diverging—head is engaged<br>◆ If movable—not engaged |
| *Pawlik's grip (third Leopold)*<br>Grasp the portion of the lower abdomen immediately above the symphysis pubis | Not movable engaged |
| Auscultation place fetoscope/stethoscope over the convex portion of the fetus close to the anterior uterine wall | Fetal heart sound are heard over fetal back |
| Inform the mother of your findings and make her comfortable | |
| Replace articles and wash hands | |
| Record the findings | |

## Antenatal Advice

Following advices are to be given:

- To impress the patient about the importance of regular checkup.
- To maintain or improve the health status of women to the optimum till delivery by judicious advice regarding drug, diet and hygiene.
- To improve and tone up the psychology and to remove the fear of pregnancy by talking sympathetically to the patient and explaining the principal changes and events likely to occur during pregnancy.

JAYPEE BROTHERS



# ANTENATAL CARE



The care of women during pregnancy is called **antenatal care**. This begins soon after conception. The ultimate objective is to have a healthy mother and a healthy child at the end of pregnancy.

**ANC**
It includes visit to antenatal clinic, examination, investigations, immunization, supplements (Iron, Folic acid, Calcium, Nutritional) and interventions as required.

**Objectives**

- To promote, protect and maintain health of the mother
- To detect 'at risk' ases and provide necessary care
- To provide advise on self-care during pregnancy
- To educate women on warning signals, child care, family planning
- To prepare the woman for labor and lactation
- To allay anxiety associated with pregnancy and childbirth
- To provide early diagnosis and treatment of any medical condition/complication of pregnancy
- To plan for "Birth" and emergencies/complications (where, how, by whom, transport, blood)
- To provide care to any child accompanying the mother

**VISITS**
Under RCH, a minimum of 3 antenatal visits are recommended. Ideally once a month during first 7 months, twice a month for 8th month and every week thereafter till delivery

**First visit**

- Confirmation of pregnancy
- Screening for high-risk pregnancy
- Baseline investigations
- Initiation of Iron and Folic Acid supplementation
- Immunization with Tetanus toxoid
- Education of the mother on pregnancy and childbirth

**Second visit**

- Confirmation of EDD, certain screening tests like maternal serum alpha fetoprotein (16–18 weeks) for neural tube defects (4 per 10,000 live births).
- Rule out gestational diabetes.
- Rh negative women are given anti-D immunoglobulin at 28 weeks

**Third trimester visit**

- Watch for complications.
- Counsel the lady on warning signs, labor and delivery workout birth plan.
- Assess adequacy of pelvis

**Subsequent visits**

- Monitor progress of pregnancy
- Monitor fetal well being
- Identify and manage any condition

**Warning signs**

- Swelling of feet
- Convulsions/unconsciousness
- Severe headache
- Blurring of vision
- Bleeding or discharge per vaginum
- Severe abdominal pain
- Any other unusual symptoms

**Antenatal advice/health education**

- Diet and rest
- Personal hygiene and habits
- Sexual intercourse
- Drugs
- Exercise
- Travel
- Care of breasts
- Warning signs

JAYPEE BROTHERS

## ANTENATAL EXERCISE

### Purposes

- To treat pre-eclampsia.
- To treat gestational diabetes.
- Pregnancy with orthopedic problems.
- Obesity.
- Improving the physical and psychological well-being of an expected mother for labor and preventing pregnancy-induced pathologies by various physical means.

| *Nursing action* | *Rationale* |
|---|---|
| Explain the procedure to the mother | Reduce anxiety |
| Instruct the mother to empty the bladder and follow the instructions | Promotes comfortable level |
| **Breathing exercises**<br>It can be done on sitting or any other position. Place the hands on the abdomen. While breathing place abdomen and ribs should expand outward, in the through the partially separated lips, pulling in abdominals |  |
| **Pelvic floor exercises (Kegal exercises)**<br>Repeatedly contracting and laxing the muscles that form part of the pelvic floor (While urinating try to stop the flow, this tightening is the basic move of Kegal). Tighten and relax these muscles daily. Can perform this exercise either sitting in a chair or lying on the floor. Concentrate only on the pelvic floor muscles |  |
| **Transverse exercise**<br>Sit comfortably on kneel on fours with a level spine. Breath in and out then gently pull in the lower part of the abdomen below the umbilicus, keeping the spine still and breathing normally. Hold up to 10 seconds then relax gently, repeat up to 10 times |  |
| **Arms slides on wall**<br>Stand against a wall with elbows and wrist against the wall, slowly side arms upward as high as while keeping the elbows and wrist against the wall |  |
| **Wall slide**<br>Stand with back, shoulders and head against a wall and look straight ahead. Keep the shoulders relaxed and feet one foot away from the wall and a shoulder width apart | 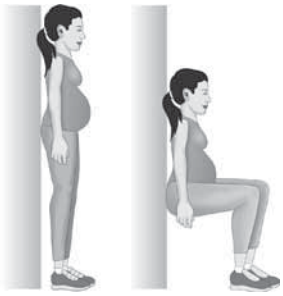 |

JAYPEE BROTHERS

| *Nursing action* | *Rationale* |
|---|---|
| **Leg raising exercises**<br>Lie on your back, arms alongside your body, palms facing downwards. Stretch out your legs in front of you and press your feet together. Contract your abdomen and slowly raise your legs from the ground. Stop when you've formed a 45° angle. Gently lower your legs until they are two inches from the ground, and bring them back up to a 45° angle |  |
| Record the procedure | |

## STEPS OF BREAST SELF-EXAMINATION

### Step 1

- Stand before a mirror.
- Inspect both breasts for anything unusual such as any discharge from the nipples or puckering, dimpling, or scaling of the skin.

### Step 2

- Watching closely in the mirror, clasp your hands behind your head and press your hands forward.
- Note any change in the contour of breast.

### Step 3

Next, press your hands firmly on your hips and bow slightly toward your mirror as you pull your shoulders and elbows forward.

### Step 4

- Raise your left arm. Use three or four fingers of your right hand to explore your left breast firmly, carefully, and thoroughly.
- Beginning at the outer edge.
- Press the flat part of your fingers in small circles, moving the circles slowly around the breast.
- Gradually work toward the nipple. Be sure to cover the entire breast.
- Pay special attention to the area between the breast and the underarm, including the underarm itself.
- Feel for any unusual lump or mass under the skin.
- Gently squeeze the nipple and look for a discharge.
- Repeat the examination on your right breast.

### Step 5

- Steps 4 and 5 should be repeated lying down.
- Lie flat on your back with your left arm over your head and a pillow or folded towel under your left shoulder.
- This position flattens the breast and makes it easier to examine. Use the same circular motion described earlier.
- Repeat the exam on your right breast.

JAYPEE BROTHERS

## BREAST SELF-EXAMINATION

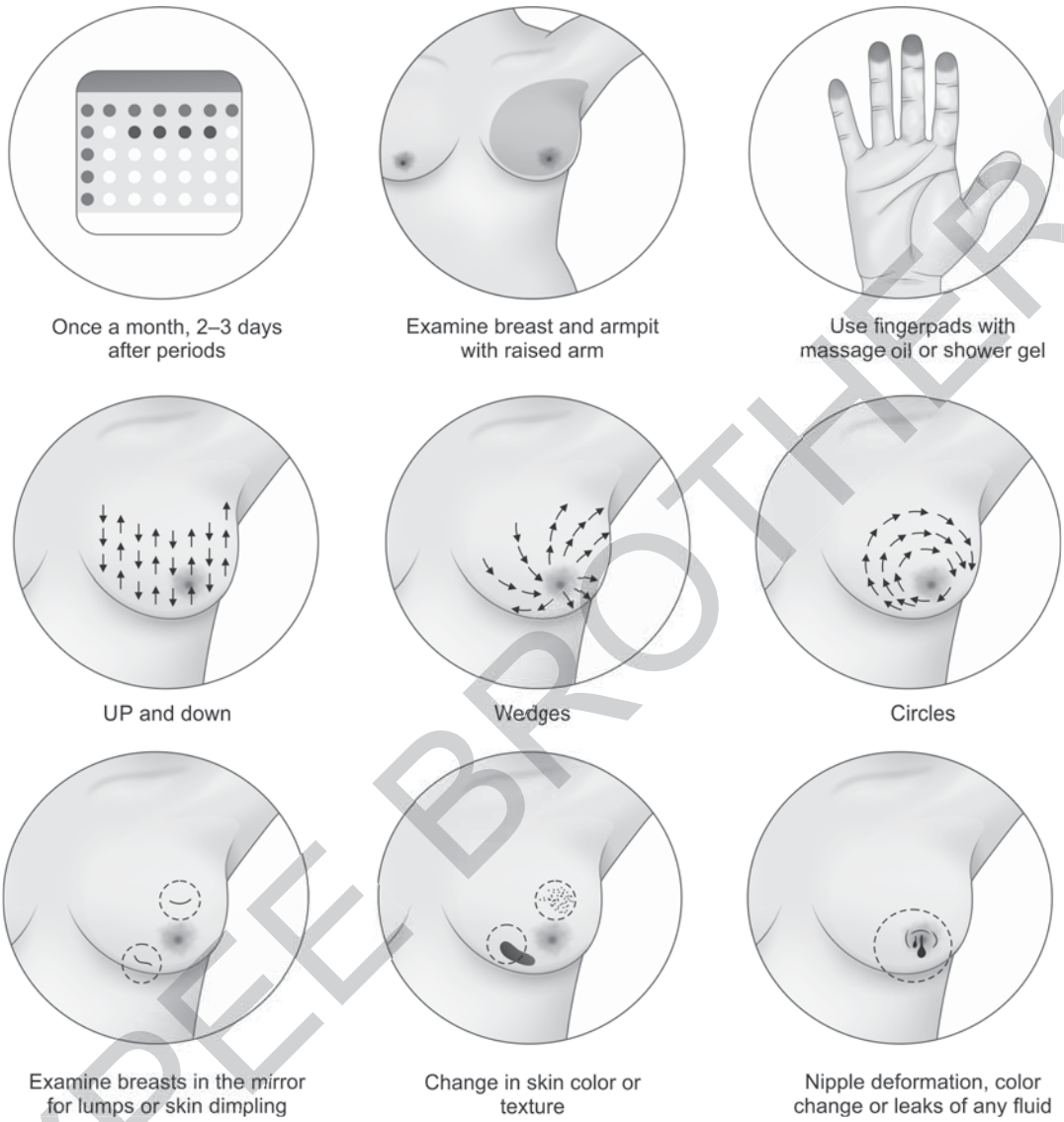


JAYPEE BROTHERS

## ANTENATAL EXAMINATION

| S. No. | Date | Name of the mother | Age | Obstetrical score | LMP | EDD |
|---|---|---|---|---|---|---|
| 1. | | | | | | |
| 2. | | | | | | |
| 3. | | | | | | |
| 4. | | | | | | |
| 5. | | | | | | |
| 6. | | | | | | |
| 7. | | | | | | |
| 8. | | | | | | |
| 9. | | | | | | |
| 10. | | | | | | |
| 11. | | | | | | |
| 12. | | | | | | |
| 13. | | | | | | |
| 14. | | | | | | |
| 15. | | | | | | |
| 16. | | | | | | |
| 17. | | | | | | |
| 18. | | | | | | |
| 19. | | | | | | |
| 20. | | | | | | |
| 21. | | | | | | |
| 22. | | | | | | |
| 23. | | | | | | |
| 24. | | | | | | |
| 25. | | | | | | |
| 26. | | | | | | |
| 27. | | | | | | |
| 28. | | | | | | |
| 29. | | | | | | |
| 30. | | | | | | |

JAYPEE BROTHERS

# Antenatal Examination – 1

## 1. Identification

## 2. Data

Name: ..... Age:..... IP No.: .....

Ward/OPD:..... Education:..... Occupation: .....

Religion: ..... Marital status: ..... Gestational age:.....

Address:.....

Date of booking:..... Date of admission:..... Obstetric score:.....

Chief complaints: .....

.....

.....

## 3. Past Obstetric History

| *S. No.* | *Year* | *Full-term/ pre-term/ abortion/ stillbirth* | *Mode of delivery* | *Place of delivery* | *Baby* | | | *Remarks* |
|---|---|---|---|---|---|---|---|---|
| | | | | | *Sex/ birth weight* | *Alive/ death* | *Age in days/months* | |
| | | | | | | | | |

## 4. Present Obstetrical History

LMP: ..... EDD:.....

***Antenatal Visits***

| *Date* | *Weight* | *BP* | *FHR* | *Height of fundus* | *Presentation/ position* | *Investigation* | *Antenatal advise* | *Remarks* |
|---|---|---|---|---|---|---|---|---|
| | | | | | | | | |

JAYPEE BROTHERS

### 5. Socioeconomic History

Breadwinner of the family: ..... Monthly income: ..... Type of house: .....

Ventilation/lighting: Adequate/inadequate Water supply/electricity: Yes/No

Standard of living:..... Relationship with others: .....

### 6. Personal History

Appearance: ..... Grooming: ..... Diet: Vegetarian/non-vegetarian/mixed

Sleeping pattern:.....Bowel/bladder pattern:.....Habits/hobbies:.....

### 7. Family History

| *S. No.* | *Name of the family members* | *Relationship with mother* | *Age/sex* | *Education* | *Occupation* | *Marital status* | *Health status* |
|---|---|---|---|---|---|---|---|
| | | | | | | | |

### 8. Menstrual History

Age of menarche:..... Menstruation: Regular/irregular

Flow: Normal/scanty/excess Interval:..... Dysmenorrhea: Yes/No

### 9. Marital History

Age at marriage:..... Duration of marriage:..... History of consanguinity: Yes/No

Use of contraceptives: Yes/No..... Relationship with husband. .....

### 10. Past and Present Medical History

.....

.....

.....

### 11. Past and Present Surgical History

.....

.....

.....

JAYPEE BROTHERS

## Antenatal Examination

**General appearance: Active/anemic/pallor**

Body built:

Facial appearance:

Head:

Eyes:

Ears:

Nose:

Mouth:

Neck and throat:

Chest:

Extremities:

Genitalia:

## Obstetrical Examination

***Breast:***

**Inspection:**

Symmetry: ..... Size/shape: ..... Nipples: ..... Dilated veins: Yes/No

Primary/secondary areola: ..... Montgomery tubercles: .....

**Palpation:**

Tenderness: ..... Pain: ..... Axillary lymph nodes: ..... Colostrum: .....

***Abdomen:***

**Inspection:**

**Contour:**

Size: ..... Shape: ..... Umbilicus: ..... Bladder: .....

Visible fetal movement: .....Flanks: ..... Visible scar: .....

**Skin changes:**

Linea nigra: Present/absent

Striae gravidarum: Present/absent

Striae albicans: Present/absent

Any other: .....

JAYPEE BROTHERS

**Palpation:**

**Abdominal girth:**

Fundal height (by inch tape): ..... By finger method: .....

Fundal palpation: .....

Lateral palpation: .....

Left: .....

Right: .....

Pelvic grip 1: .....

Pelvic grip 2: .....

Auscultation: .....

**Findings:**

Lie: ..... Presentation: ..... Position: .....

Attitude: ..... FHR: .....

## Antenatal Clinic Chart

Name of the mother: ..... Age: ..... Diagnosis: .....

| *Date* | | | | | | | | | | | | | | |
|---|---|---|---|---|---|---|---|---|---|---|---|---|---|---|
| *Days* | *1* | | *2* | | *3* | | *4* | | *5* | | *6* | | *7* | |
| | *M* | *E* | *M* | *E* | *M* | *E* | *M* | *E* | *M* | *E* | *M* | *E* | *M* | *E* |
| *Temp* | | | | | | | | | | | | | | |
| *FHR* | | | | | | | | | | | | | | |
| *BP* | | | | | | | | | | | | | | |
| *Pulse* | | | | | | | | | | | | | | |
| *Respiration* | | | | | | | | | | | | | | |
| *Urine* | | | | | | | | | | | | | | |
| *Motion* | | | | | | | | | | | | | | |

JAYPEE BROTHERS

**Signature of Student** **Signature of Teacher**

# Antenatal Examination – 2

## 1. Identification

## 2. Data

Name: ..... Age:..... IP No.: .....

Ward/OPD:..... Education:..... Occupation: .....

Religion: ..... Marital status: ..... Gestational age:.....

Address:.....

Date of booking:..... Date of admission:..... Obstetric score:.....

Chief complaints: .....

.....

.....

## 3. Past Obstetric History

| *S. No.* | *Year* | *Full-term/ pre-term/ abortion/ stillbirth* | *Mode of delivery* | *Place of delivery* | *Baby* | | | *Remarks* |
|---|---|---|---|---|---|---|---|---|
| | | | | | *Sex/ birth weight* | *Alive/ death* | *Age in days/months* | |
| | | | | | | | | |

## 4. Present Obstetrical History

LMP: ..... EDD:.....

***Antenatal Visits***

| *Date* | *Weight* | *BP* | *FHR* | *Height of fundus* | *Presentation/ position* | *Investigation* | *Antenatal advise* | *Remarks* |
|---|---|---|---|---|---|---|---|---|
| | | | | | | | | |

JAYPEE BROTHERS

### 5. Socioeconomic History

Breadwinner of the family: ..... Monthly income: ..... Type of house: .....

Ventilation/lighting: Adequate/inadequate Water supply/electricity: Yes/No

Standard of living:..... Relationship with others: .....

### 6. Personal History

Appearance: ..... Grooming: ..... Diet: Vegetarian/non-vegetarian/mixed

Sleeping pattern:.....Bowel/bladder pattern:.....Habits/hobbies:.....

### 7. Family History

| *S. No.* | *Name of the family members* | *Relationship with mother* | *Age/sex* | *Education* | *Occupation* | *Marital status* | *Health status* |
|---|---|---|---|---|---|---|---|
| | | | | | | | |

### 8. Menstrual History

Age of menarche:..... Menstruation: Regular/irregular

Flow: Normal/scanty/excess Interval:..... Dysmenorrhea: Yes/No

### 9. Marital History

Age at marriage:..... Duration of marriage:.....History of consanguinity: Yes/No

Use of contraceptives: Yes/No..... Relationship with husband. .....

### 10. Past and Present Medical History

.....

.....

.....

### 11. Past and Present Surgical History

.....

.....

.....

JAYPEE BROTHERS

## Antenatal Examination

**General appearance: Active/anemic/pallor**

Body built:

Facial appearance:

Head:

Eyes:

Ears:

Nose:

Mouth:

Neck and throat:

Chest:

Extremities:

Genitalia:

## Obstetrical Examination

***Breast:***

**Inspection:**

Symmetry: ..... Size/shape: ..... Nipples: ..... Dilated veins: Yes/No

Primary/secondary areola: ..... Montgomery tubercles: .....

**Palpation:**

Tenderness: ..... Pain: ..... Axillary lymph nodes: ..... Colostrum: .....

***Abdomen:***

**Inspection:**

**Contour:**

Size: ..... Shape: ..... Umbilicus: ..... Bladder: .....

Visible fetal movement: .....Flanks: ..... Visible scar: .....

**Skin changes:**

Linea nigra: Present/absent

Striae gravidarum: Present/absent

Striae albicans: Present/absent

Any other: .....

JAYPEE BROTHERS

**Palpation:**

**Abdominal girth:**

Fundal height (by inch tape): ..... By finger method: .....

Fundal palpation: .....

Lateral palpation: .....

Left: .....

Right: .....

Pelvic grip 1: .....

Pelvic grip 2: .....

Auscultation: .....

**Findings:**

Lie: ..... Presentation: ..... Position: .....

Attitude: ..... FHR: .....

## Antenatal Clinic Chart

Name of the mother: ..... Age: ..... Diagnosis: .....

| *Date* | | | | | | | | | | | | | | |
|---|---|---|---|---|---|---|---|---|---|---|---|---|---|---|
| *Days* | *1* | | *2* | | *3* | | *4* | | *5* | | *6* | | *7* | |
| | *M* | *E* | *M* | *E* | *M* | *E* | *M* | *E* | *M* | *E* | *M* | *E* | *M* | *E* |
| *Temp* | | | | | | | | | | | | | | |
| *FHR* | | | | | | | | | | | | | | |
| *BP* | | | | | | | | | | | | | | |
| *Pulse* | | | | | | | | | | | | | | |
| *Respiration* | | | | | | | | | | | | | | |
| *Urine* | | | | | | | | | | | | | | |
| *Motion* | | | | | | | | | | | | | | |

JAYPEE BROTHERS

**Signature of Student** **Signature of Teacher**

# Antenatal Examination – 3

## 1. Identification

## 2. Data

Name: ..... Age:..... IP No.: .....

Ward/OPD:..... Education:..... Occupation: .....

Religion: ..... Marital status: ..... Gestational age:.....

Address:.....

Date of booking:..... Date of admission:..... Obstetric score:.....

Chief complaints: .....

.....

.....

## 3. Past Obstetric History

| *S. No.* | *Year* | *Full-term/ pre-term/ abortion/ stillbirth* | *Mode of delivery* | *Place of delivery* | *Baby* | | | *Remarks* |
|---|---|---|---|---|---|---|---|---|
| | | | | | *Sex/ birth weight* | *Alive/ death* | *Age in days/months* | |
| | | | | | | | | |

## 4. Present Obstetrical History

LMP: ..... EDD:.....

***Antenatal Visits***

| *Date* | *Weight* | *BP* | *FHR* | *Height of fundus* | *Presentation/ position* | *Investigation* | *Antenatal advise* | *Remarks* |
|---|---|---|---|---|---|---|---|---|
| | | | | | | | | |

JAYPEE BROTHERS

for detailed information on nursing books, visit our website www.jaypeebrothers.com, for detailed information on nursing books, visit our websi

# A Practical/Clinical Case Record of Maternal and Newborn Nursing Practice

***Salient Features***

- As per the revised curriculum of Indian Nursing Council (INC).
- All the procedures are related to the curriculum of Midwifery and Obstetrical Nursing (6th and 7th semesters).
- Emphasizes on the development of the clinical skills of nursing students.
- Detailed description of all the procedures performed.
- Content has been reviewed and contributed by eminent nursing professionals.
- Provides all the nursing procedures to be performed by the students.
- It is useful for BSc, Post-Basic BSc, MSc Nursing students.

**Sushila Singh Bais** PhD (Obstetrics and Gynecological Nursing) is presently working as Head of Department, PG College of Nursing, Bhilai, Durg, Chhattisgarh, India. She has a huge experience of teaching Obstetrics and Gynecological Nursing to undergraduate and postgraduate students for up to 25 years. She has been providing guidance as a mentor to undergraduate and postgraduate nursing students in their research projects at PG College of Nursing, Bhilai. Additionally, she has served both as a guide and co-guide for PhD nursing students in their research projects at various universities in India, including AIIMS in West Bengal and universities in Rajasthan, among others. She acted as an external examiner at various universities. Apart from teaching, she has organized many conferences, workshops, and seminars at national and international levels. She is President of Society of Midwives-India (SOMI), executive member of Trained Nurses' Association of India (TNAI), state executive member of national celebration of Midwife India. She has been a speaker in various state, national, and international levels. She is INC Inspector and Master Trainer of HIV, Tuberculosis Control Program, and Basic Neonatal Resuscitation and Advanced Resuscitation Programs. She also has numerous research articles in national and international journals to her credit. She has reviewed numerous research articles for national and international journals and a number of nursing books.

**Biula** MSc (N) (Obstetrics and Gynecological Nursing) is presently working as Assistant Professor in Bharti College of Nursing, Durg, Chhattisgarh, India. She has a huge experience of teaching in obstetrics and gynecological nursing for more than 7 years. She has been imparting guidance as a guide to undergraduate and postgraduate nursing students in their research projects. Apart from teaching, she done certificate course of Forensic Nursing Science, BLS Certified, and Infection Control Nurse. She has also published various research articles in national and international journals of repute. She is the member of several nursing associations.

Scan for more nursing titles...

*Printed in India*

**Available at all medical bookstores or buy online at www.ejaypee.com**

**JAYPEE BROTHERS**
**Medical Publishers (P) Ltd.**
**EMCA House, 23/23-B, Ansari Road,**
**Daryaganj, New Delhi - 110 002, INDIA**
**www.jaypeebrothers.com**

Join us on facebook.com/JaypeeMedicalPublishers
Follow us on instagram.com/JaypeeMedicalPublishers

ISBN 978-93-5696-604-8
9 789356 966048