our website www.jaypeebrothers.com, for detailed information on anatomy books, visit our website www.jaypeebrothers.com, for detailed information on anatomy books, visit our website www.jaypeebrothers.com

6th Edition

Comparative Microscopic Features Included

HISTOLOGY
PRACTICAL MANUAL

As per the Competency-Based Medical Education Curriculum (NMC)

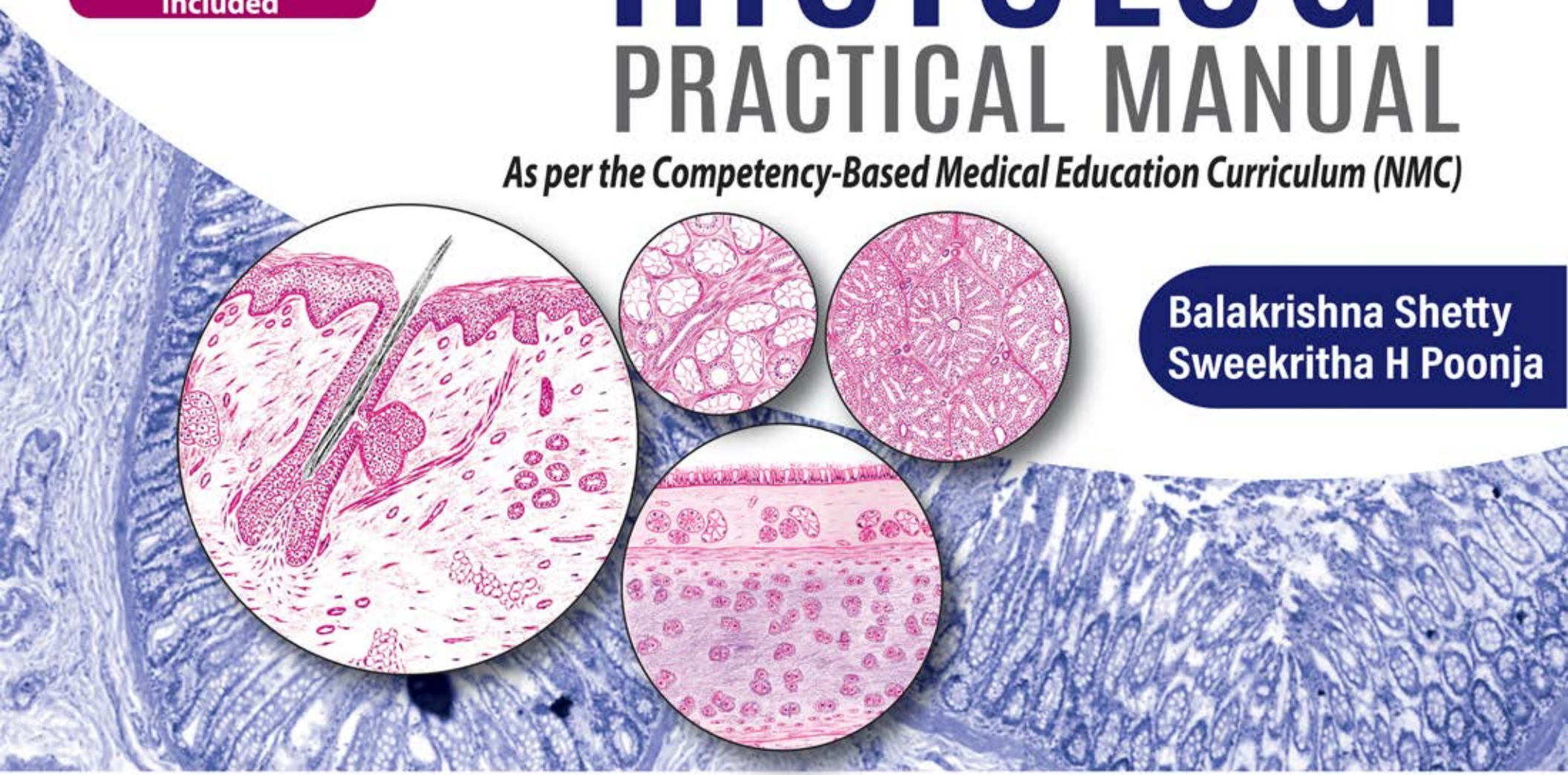

Balakrishna Shetty
Sweekritha H Poonja

Foreword
Chitra Prakash Rao

STUDY AUTHENTIC
Scratch the Hologram and Scan the QR Code to Check the Genuineness

Original Books Matter!!!
SAY NO TO PIRACY

JAYPEE

CONTENTS

1. Simple Epithelium **2–3**
2. Stratified Epithelium **4–9**
   - A. Stratified Squamous (Non-Keratinized)
   - B. Stratified Squamous (Keratinized)
   - C. Transitional Epithelium
3. Connective Tissue **10–11**
4. Connective Tissue Fibers **12–13**
5. Adipose Tissue **14–15**
6. Hyaline Cartilage **16–17**
7. Elastic Cartilage **18–19**
8. White Fibrocartilage **20–21**
9. Bone—Transverse Section **22–23**
10. Bone—Longitudinal Section **24–25**
11. Cancellous Bone **26–27**
12. Skeletal Muscle **28–29**
13. Cardiac Muscle **30–31**
14. Smooth Muscle **32–33**
15. Peripheral Nerve—Transverse Section **34–35**
16. Peripheral Myelinated Nerve **36–37**
17. Optic Nerve—Transverse Section **38–39**
18. Sympathetic Ganglion **40–41**
19. Dorsal Root Ganglion/Spinal Ganglion **42–43**
20. Large Artery/Elastic Artery **44–45**
21. Medium-sized Artery/Muscular Artery **46–47**
22. Large Vein **48–49**
23. Medium-sized Vein **50–51**
24. Capillaries and Sinusoids **52–53**
25. Lymph Node **54–55**
26. Spleen **56–57**
27. Tonsil **58–59**
28. Thymus **60–61**
29. Serous Salivary Gland **62–63**
30. Mucus Salivary Gland **64–65**
31. Mixed Salivary Gland **66–67**
32. Thick Skin **68–69**
33. Thin Skin **70–71**
34. Hair **72–73**
35. Trachea **74–75**
36. Lung **76–77**
37. Epiglottis **78–79**
38. Lip **80–81**
39. Tongue **82–85**
    - A. Filiform and Fungiform Papillae
    - B. Circumvallate Papillae
40. Tooth **86–87**
41. Esophagus **88–89**
42. Stomach: Fundus and Body **90–91**
43. Stomach: Pylorus **92–93**
44. Duodenum **94–95**
45. Jejunum **96–97**
46. Ileum **98–99**
47. Large Intestine **100–101**
48. Appendix **102–103**
49. Liver **104–105**
50. Gallbladder **106–107**
51. Pancreas **108–109**
52. Kidney **110–111**
53. Ureter **112–113**
54. Urinary Bladder **114–115**
55. Prostatic Urethra **116–117**

56. Testis **118–119**
57. Epididymis **120–121**
58. Ductus Deferens/Vas Deferens **122–123**
59. Prostate **124–125**
60. Seminal Vesicle **126–127**
61. Ovary **128–129**
62. Uterus **130–133**
    A. Proliferative
    B. Secretory
63. Fallopian Tube **134–135**
64. Mammary Gland **136–141**
    A. Inactive Stage
    B. In Pregnancy
    C. In Lactation
65. Umbilical Cord **142–143**
66. Placenta **144–145**
67. Pituitary Gland **146–147**
68. Suprarenal/Adrenal Gland **148–149**
69. Thyroid and Parathyroid **150–151**
70. Cornea **152–153**
71. Corneoscleral Junction **154–155**
72. Retina **156–157**
73. Eyelid **158–159**
74. Organ of Corti **160–161**
75. Cerebrum **162–163**
76. Cerebellum **164–165**
77. Spinal Cord **166–167**

25. LYMPH NODE

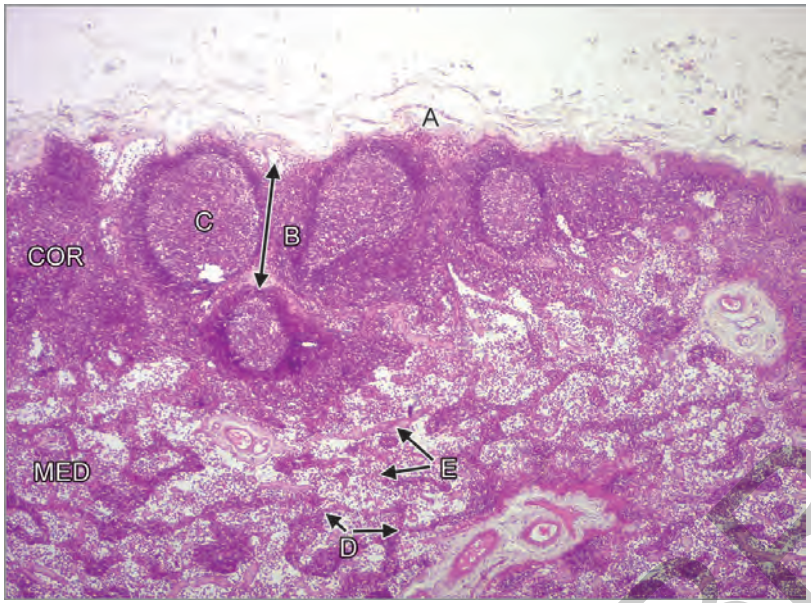

COR	Cortex
MED	Medulla
A	Capsule
B	Lymphoid Follicle
C	Germinal Center
D	Medullary Cords
E	Medullary Sinus

Identification Points

1. **Fibrous capsule and subcapsular space seen.**
2. **Outer cortex, inner medulla differentiated.**
   Cortex contains lymphoid follicles with germinal center.
   Medulla contains medullary cords and sinuses.

- Lymph node has outer fibrous capsule. This sends trabeculae inside. There is distinct subcapsular space.
- Afferent lymphatics around the gland pierces the capsule and drain into subcapsular space.
- Cortex contains lymphoid follicles with pale staining germinal center. Rim of the follicles have densely packed inactive B lymphocytes. Germinal centers contain pale staining large, rapidly dividing B lymphocytes.
- Paracortex, which is the junction between cortex and medulla contains T lymphocytes.
- In medulla lymphocytes arranged like branching cords along the sinuses called as medullary cords. These are mainly macrophages and plasma cells.
- Lymph will drain from the afferent lymphatics into subcapsular sinus, then passes along the trabacular sinus into medullary sinuses.
- Finally drains out from the hilum through the efferent lymphatics.
- As it passes through the sinuses it comes in contact with antigen presenting cells which present it to the lymphocytes.
- Functions of lymph node—filtration of lymph, proliferation of lymphocytes and forms a part of immune system.

JAYPEE BROTHERS

25. LYMPH NODE

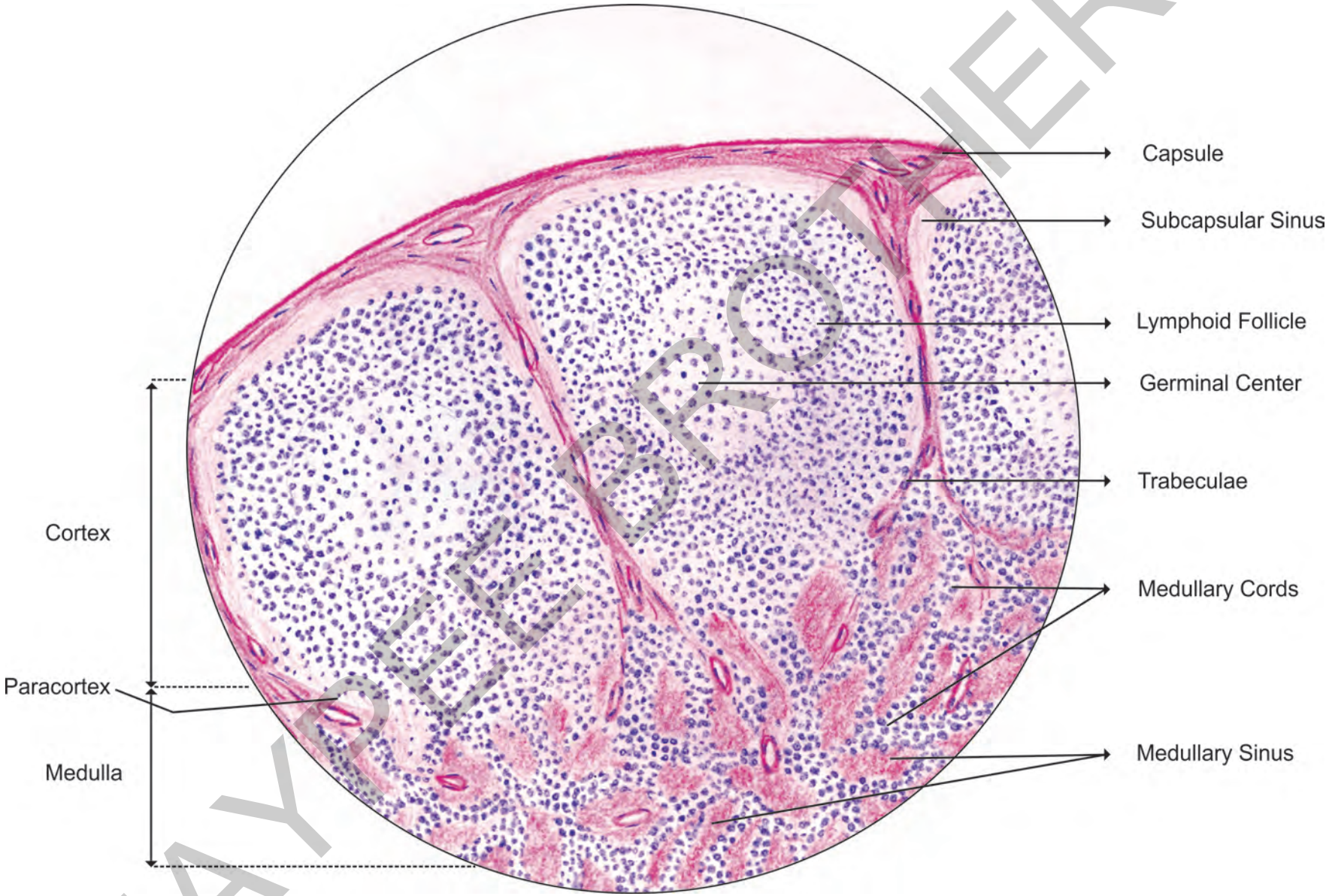

JAYPEE BROTHERS

26. SPLEEN

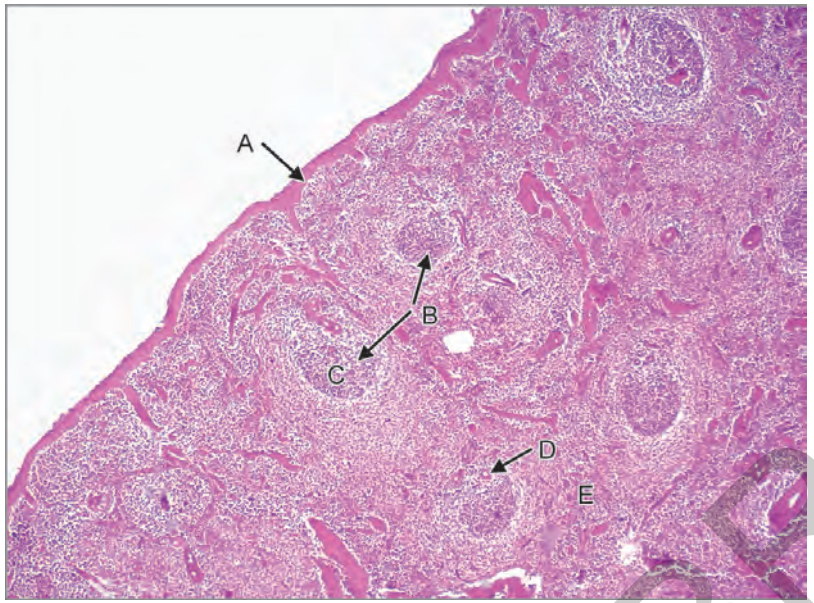

A	Capsule
B	White Pulp
C	Germinal Center
D	Eccentrically Placed Central Artery
E	Red Pulp

Identification Points

1. **Red pulp, white pulp differentiated.**
2. **White pulp—lymphoid aggregations with eccentric central artery.**
3. **Red pulp contains splenic cords surrounded by sinusoids.**

- Spleen has thick capsule, sends septa into substance of spleen.
- White pulp is aggregation of lymphocytes around the artery—periarterial lymphatic sheath (PALS) made of T lymphocytes. At some places it forms lymphatic nodules with germinal centers called as Malpighian bodies. They contain B lymphocytes.
- Red pulp forms the major part of spleen. It is made of lymphocytes arranged like branching and anastomosing cords along the sinusoids.
- Spleen is the largest hemolymphoid organ.
- Function—removes old red blood cells (RBCs), production of lymphocytes, removes blood-borne antigens. In fetal life it also acts as a site of erythrocyte production.
- Splenic circulation:
  - Central artery from white pulp enters red pulp and divides into straight vessels called as penicilli. It is then surrounded by sheath of macrophages and is called as ellipsoid which has a narrow lumen. Further it dilates to form ampulla and blood enters sinusoids of red pulp by two ways.
  - In closed circulation theory blood directly enters into sinusoids from ampulla. In open circulation theory blood passes out of capillaries between the cords and then enters sinusoids.

JAYPEE BROTHERS

26. SPLEEN

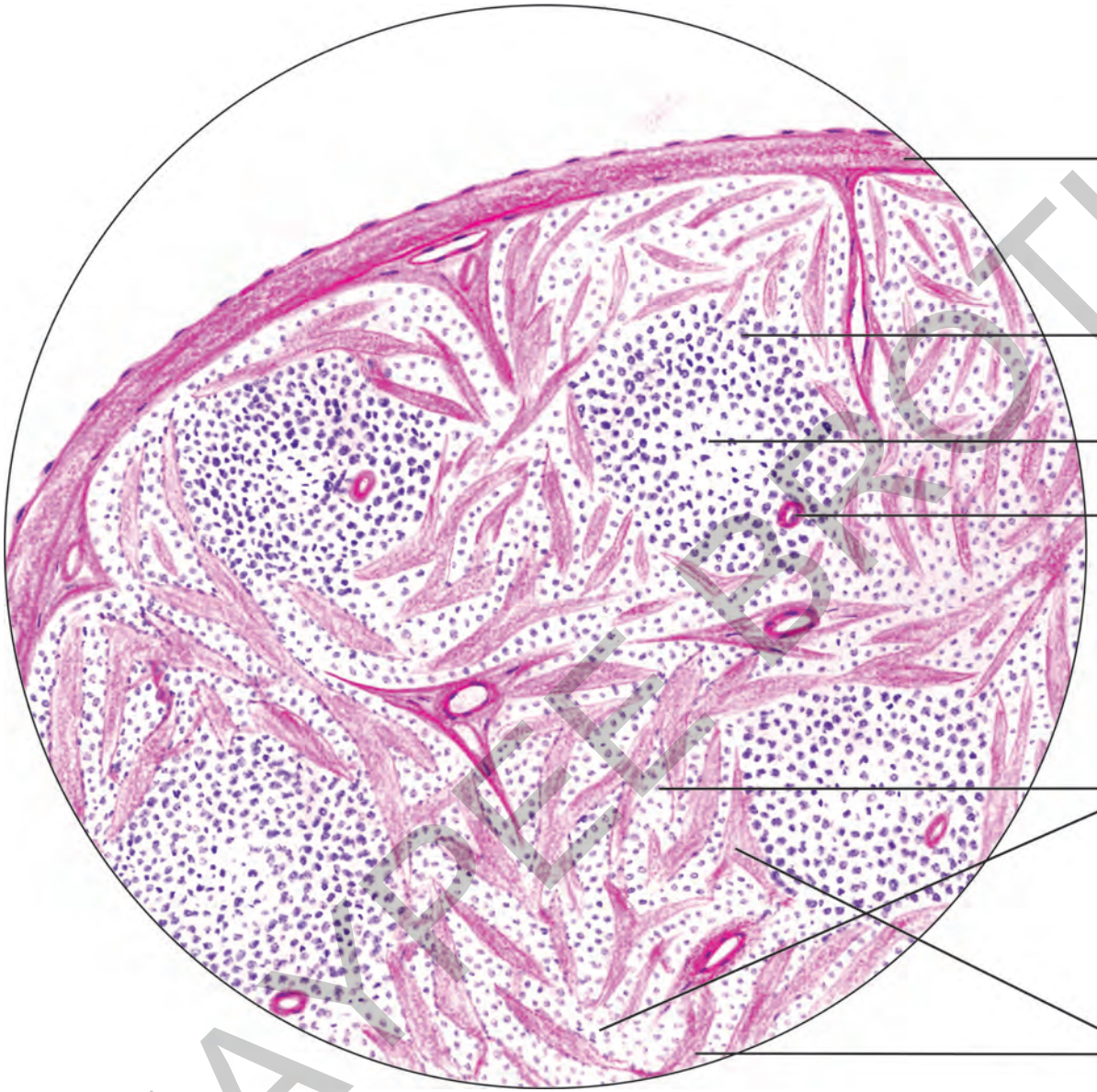

JAYPEE BROTHERS

27. TONSIL

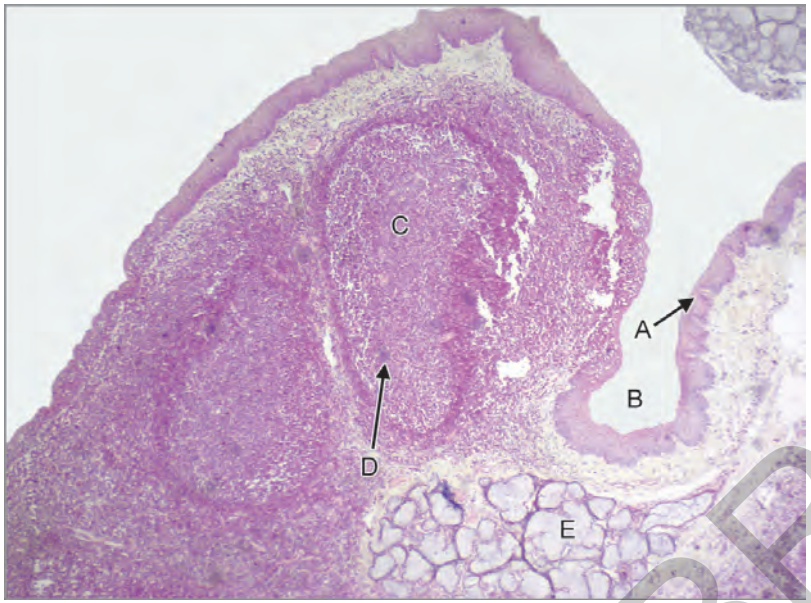

A	Stratified Squamous Non-keratinized Epithelium
B	Crypt
C	Lymphoid Follicle
D	Germinal Center
E	Mucus Acini

Identification Points

1. **Surface lined by stratified squamous non-keratinized epithelium.**
2. **Surface shows depressions called tonsillar crypts.**
3. **Lymphoid follicles with germinal center seen along the crypts.**

- Palatine tonsil is situated in tonsillar fossa, on lateral wall of oropharynx.
- It forms one of the constituents of Waldeyer's ring.
- It belongs to MALT (mucosa-associated lymphoid tissue). It is active during early life.
- Mucosal lining is non-keratinized stratified sqamous epithelium.
- Mucosal lining invaginate to form crypt which are characteristic of palatine tonsil.
- Lymphocytes aggregated in the form of follicles with a central germinal center along the crypts. Follicles mainly contain B lymphocytes. T lymphocytes lie outside the follicle.
- Mucus acini are seen in the deeper plane.

JAYPEE BROTHERS

27. TONSIL

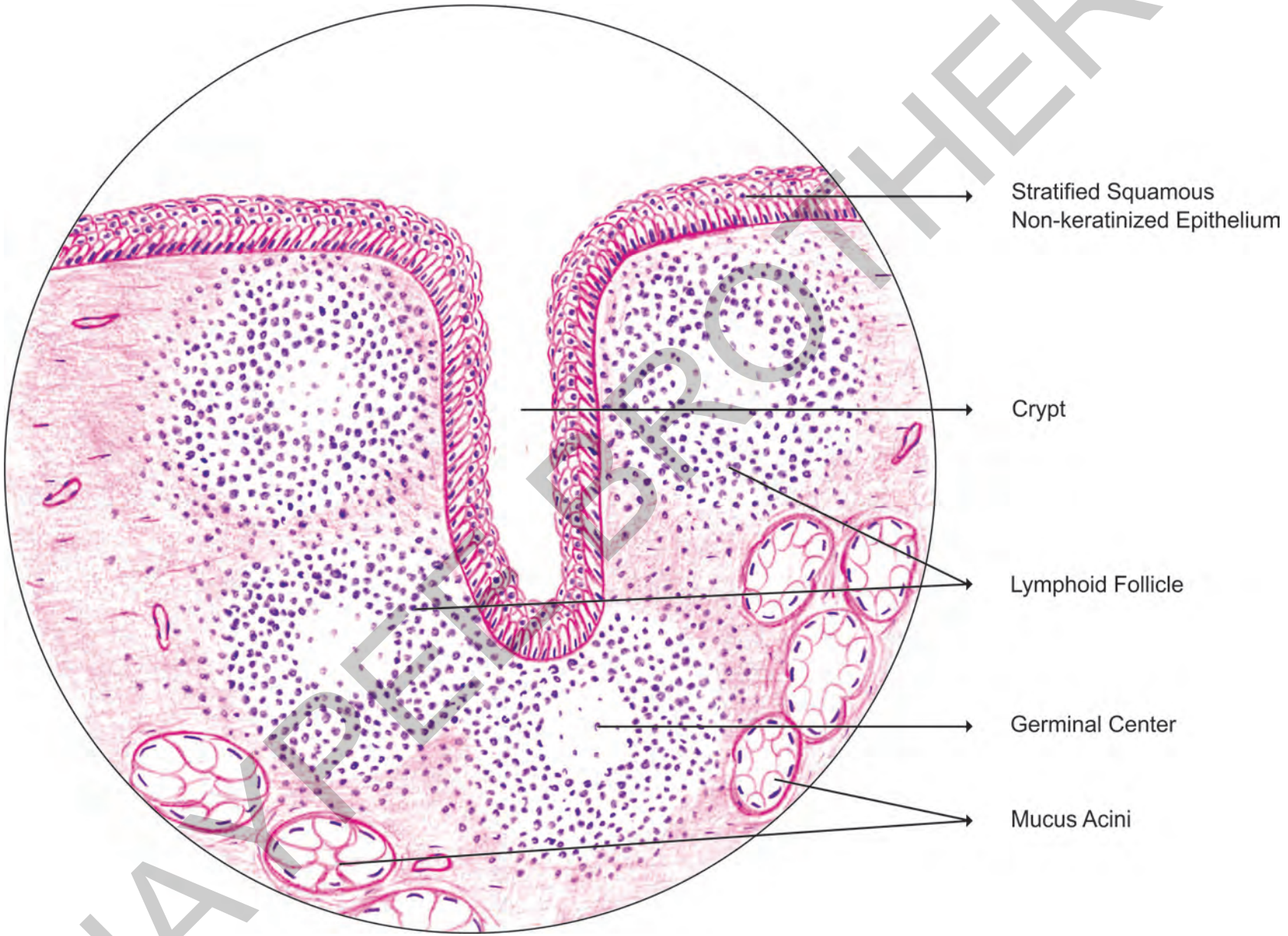

JAYPEE BROTHERS

28. THYMUS

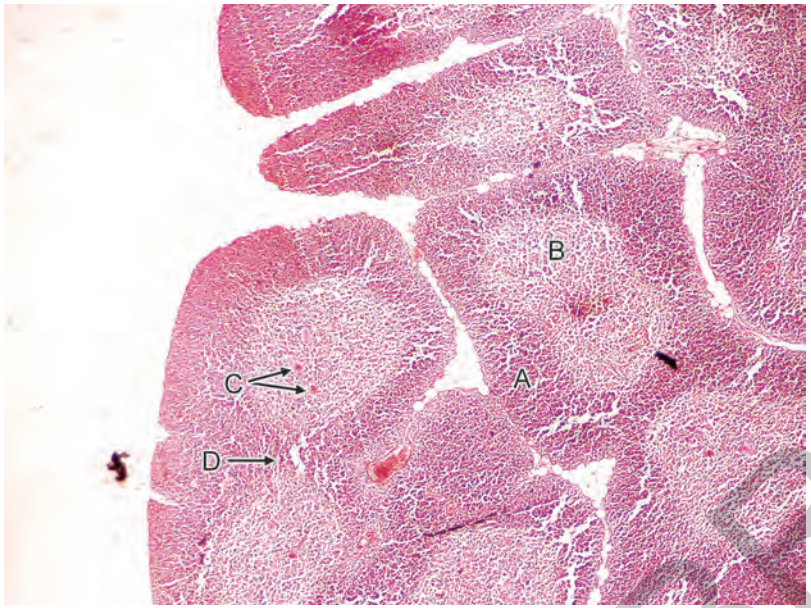

A	Cortex
B	Medulla
C	Hassall's Corpuscles
D	Incomplete Septa

Identification Points

1. **Lobules separated by incomplete fibrous septa.**
2. **Each lobule contains peripheral cortex of densely packed small lymphocytes and central medulla with sparsely arranged larger lymphocytes and Hassall's corpuscles.**

- Thymus is a primary lymphoid organ. It grows in size up to puberty and regress during adulthood.
- Capsule sends incomplete septa into the parenchyma, dividing it into lobules.
- Each lobule contains outer cortex and central medulla.
- Cortex is made of densely packed small lymphocytes.
- Also contains macrophages for phagocytosis of degenerating lymphocytes and epitheliocytes which provide supporting meshwork.
- Medulla of adjacent lobules are interconnected. It contains sparsely arranged larger lymphocytes and epitheliocytes.
- Degenerated epitheliocyte cell aggregations appear as concentric eosinophilic mass called Hassall's corpuscles in the medulla.
- Epithelioid cells form reticular system of thymus and forms blood-thymus barrier. Also produce hormones for proliferation and maturation of T lymphocytes.
- Function of thymus—differentiation of T lymphocytes.

JAYPEE BROTHERS

28. THYMUS

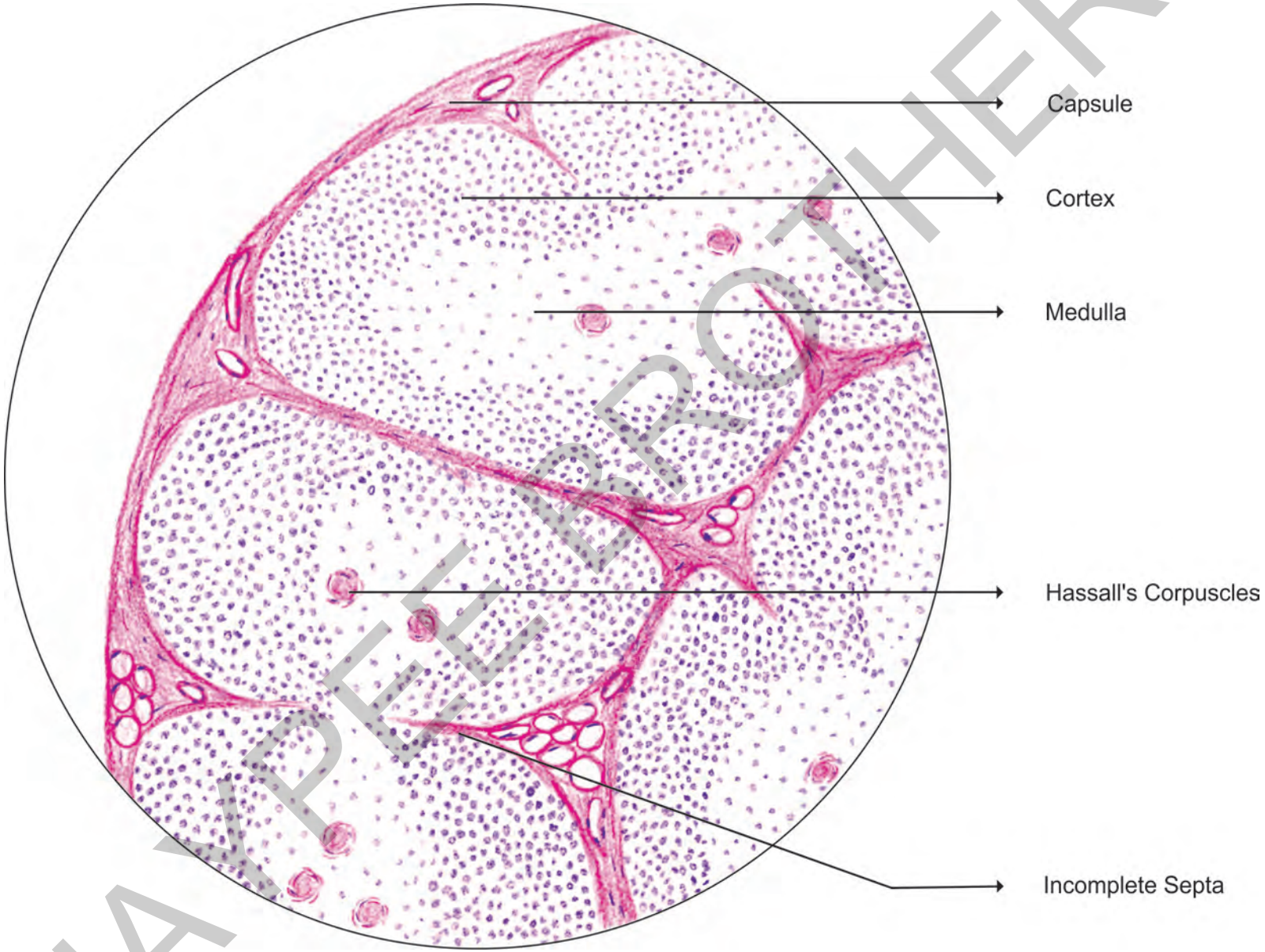

JAYPEE BROTHERS

for detailed information on anatomy books, visit our website www.jaypeebrothers.com, for detailed information on anatomy books, visit our website www.jaypeebrothers.com, for detailed information on anatomy

Scan to Download the App
diginerve
A Jaypee Initiative
Your Guide at Every Step
Video Lectures | Notes | Self-Assessment

HISTOLOGY
PRACTICAL MANUAL

Salient Features

- New slides added as per the National Medical Council of India (NMC) curriculum
- Contains hand drawn H & E diagrams of all the slides which are included in the syllabus for undergraduate students
- Short specific identification points for each slide have also been given
- Identification points which are must know for an undergraduate medical student about the structure and function of the tissue have also been added
- Included compare and contrast microscopic features tables for quick revision during exams.

Balakrishna Shetty MBBS MD is Professor, Department of Anatomy, AJ Institute of Medical Sciences and Research Centre, Mangaluru, Karnataka, India. He completed his graduation from JSS Medical College, Mysuru, Karnataka and Postgraduation (MD) from AJ Institute of Medical Sciences and Research Centre, Mangaluru. He has more than 10 years of teaching experience for both undergraduate and postgraduate students.

Sweekritha H Poonja MBBS MD is Associate Professor, Department of Anatomy, AJ Institute of Medical Sciences and Research Centre, Mangaluru, Karnataka, India. She completed her graduation from Yenepoya Medical College, Mangaluru and Postgraduation (MD Anatomy) from AJ Institute of Medical Sciences and Research Centre, Mangaluru. She was awarded a gold medal for her academic performance in MD (Anatomy) examination. She has been actively involved in teaching anatomy more than 10 years of teaching experience for both undergraduate and postgraduate students.

Printed in India

Available at all medical bookstores
or buy online at www.jaypeebrothers.com

JAYPEE BROTHERS
Medical Publishers (P) Ltd.
EMCA House, 23/23-B, Ansari Road,
Daryaganj, New Delhi - 110 002, INDIA
www.jaypeebrothers.com

Join us on facebook.com/JaypeeMedicalPublishers

Shelving Recommendation
ANATOMY

ISBN 978-93-5696-617-8