ebrothers.com, for detailed information on radiology books, visit our website www.jaypeebrothers.com, for detailed information on radiology books



TEXTBOOK FOR X-RAY TECHNICIANS

As per the Diploma and Certificate Courses on Radiography and X-ray

Highlights

- Comprehensive coverage of radiographic positioning of different parts of human body
- Covered basics of radiograph procedures
- Special emphasis on physics of X-rays
- Includes radiation hazards & protection

Hariqbal Singh
Prashant Naik
Mritunjoy Kumar Srivastava

JAYPEE

Contents

SECTION 1: RADIOGRAPHIC POSITIONING

1. Positioning **3**
Anatomic Positions *3*
Planes of the Body *3*
Positions of the Body *3*
Movement of the Body *4*
2. Good Quality Radiograph **5**
Definition *5*
Distortion *5*
Density *5*
Contrast *6*
3. X-ray Films **7**
4. Upper Extremity **8**
Hand Posteroanterior View *8*
Wrist Posteroanterior View *9*
Wrist Lateral View *10*
Elbow Joint Anteroposterior View *11*
Elbow Joint Lateral View *12*
Shoulder Joint Anteroposterior View *13*
5. Lower Extremity **14**
Foot Anteroposterior View *14*
Ankle Joint Anteroposterior View *15*
Ankle Joint Lateral View *16*
Knee Anteroposterior View *17*
Knee Joint Lateral View *18*
Patella Posteroanterior View *19*
Patella—Axilla View or Skyline View *20*
Hip Joint Anteroposterior View *21*
Pelvis Anteroposterior View *22*
6. Chest **23**
Chest Posteroanterior View *23*
Chest Lateral View *24*
Chest Anterior Oblique View *25*

7. Abdomen **27**
Abdomen Anteroposterior View *27*
KUB Anteroposterior View *28*
Abdomen Erect View (AP View) *28*
8. Head–Skull **29**
Skull Anteroposterior View *29*
Skull Lateral View *30*
Towne (Half Axial Anteroposterior) View *31*
Caldwell (Inclined Posteroanterior) View of Orbit View *32*
Skull-Base (Submentovertical) View or Basal View *33*
Skull-Waters (Inclined Posteroanterior) View or PNS View *34*
Mastoid-Schuller View *35*
9. Spine **36**
Cervical Spine Anteroposterior View *36*
Cervical Spine Lateral View *37*
Dorsal Spine Anteroposterior View *38*
Dorsal Spine Lateral View *39*
Lumbar Spine Anteroposterior View *40*
Lumbar Spine Lateral View *41*
Lumbosacral Spine Lateral View *42*
Sacrum and Sacroiliac Joints Anteroposterior View *43*
Sacrum Lateral View *44*
Coccyx Vertebrae Anteroposterior View *45*

SECTION 2: ANATOMY ON X-RAYS

10. Skull **49**
The Nasal Cavity and Nasal Septum *58*
11. Spine **60**
Radiological Importance of Vertebral Column in Spinal Injuries *70*
12. X-ray Chest **72**
Anatomical Segmental Division of Lungs *72*
Important Points to Observe on Chest X-rays *76*
13. Abdominal Radiograph **78**
14. Upper Limb **81**
Shoulder Joint *81*
Upper Arm *82*
Elbow Joint *84*
Forearm *86*
Wrist Joint and Hand *87*
Hand *89*
15. Lower Limb **90**
Hip Joint *90*
Thigh *93*

SECTION 3: ANGIOGRAPHY

16. Angiograms 105
Cerebral Circulation *105*
Abdominal Angiography *111*

SECTION 4: CASES

17. Typical Cases with Captions 119

SECTION 5: RADIOLOGY PROCEDURES

18. Barium Swallow 127
19. Barium Meal Follow-Through 130
20. Barium Enema 135
21. Intravenous Urogram 138
22. Micturating Cystourethrogram 142
23. Retrograde Urethrogram 145
24. Female Reproductive Organs and HSG 146
Female Reproductive Organs *146*
Hysterosalpingogram (HSG) *148*
25. Dacryocystogram 150
26. Fistulogram and Sinogram 152
Technique *152*
27. Sialography 153
Indications for Sialography *153*
Technique *153*

SECTION 6: PHYSICS

28. Electromagnetic Radiations 157
Properties of Electromagnetic Radiation *157*
Classification of Radiation *157*
29. Production of X-rays 158
Mechanism of X-ray Production *159*
Rotating Anode *160*
Transformer *160*
Rectification *161*
Electronic Timer *162*
Cooling of X-ray Tube *162*
Focal Spot *162*
Anode Heel Effect *162*
Spectrum Out of X-ray Tube *163*
30. X-ray Interactions 164
Relative Importance of Photon Interaction to Radiography *164*
Applications of Photoelectric Effect in Diagnostic Radiation *165*

Attenuation *165*
Scattered Radiation *165*
31. Grids, Collimators and Filters **168**
Grids *168*
Filters *171*
Beam Restrictor: Collimators *172*
32. X-ray Films **174**
Types of X-ray Films *174*
Cassette *174*
Intensifying Screens Used in Cassettes *176*
Types of Phosphors *177*
Speed of Intensifying Screen *177*
Care of Screens *178*
Processing of Exposed X-ray Films *178*
Dry Imaging Cameras *180*
33. Fluoroscopic Imaging **181**
34. Image Quality **183**
Blur *183*
Density *184*
Contrast *184*
Distortion *185*
35. Radiation Hazards and Protection **186**
Classification of Radiation Injury *186*
Radiation Units *186*
The Deciding Authority *187*
The Objective of Radiation Protection *187*
Optimization of Protection and the ALARA Principle *187*
Principles of Radiation Protection *188*
Triad of Radiation Protection Actions *188*
X-ray Tube Shielding (Source Shielding) *188*
Room Shielding (Structural Shielding) *188*
Personnel Shielding *189*
Lead Free Aprons (Zero Lead Aprons) *190*
Film Badge *190*
36. Mammography **193**
37. Artifacts **195**
Artifacts in Conventional Radiography *195*
Computed Radiography Artifacts *196*
38. Computed Radiography and Digital Radiography **198**
Computed Radiography *198*
Direct Digital Radiography *199*
Dry Imaging Cameras *201*
Printing in Dry Laser Camera *202*
39. Picture Archiving and Communication System **203**
Picture Archiving and Communication System *203*

40. Planning of Radiology Department **205**
Modalities *205*
Planning Considerations *206*
Safety Considerations and Protective Measures *207*
Maintenance and Management *207*
41. Miscellaneous **208**
Safelight *208*
Soft Tissue Radiography *208*
Dental Film *209*
Mobile Radiography *210*
Thermoluminescence Dosimeter Badge *210*
Mass Miniature Radiography *210*
Index *211*

16
CHAPTER

Angiograms

CEREBRAL CIRCULATION

Normal Intracranial Arterial System

The convexity of aortic arch gives off three branches—the brachiocephalic trunk, the left common carotid artery and left subclavian artery **(Flowchart 16.1)**.

Extracranial carotid arteries: The right common carotid artery usually arises from the bifurcation of the brachiocephalic artery. The left common carotid artery arises from the aortic arch distal to the origin of brachiocephalic artery. Both the right and left common carotid arteries bifurcate into the external and internal carotid arteries on either side at C4- C5 level.

Branches of the external carotid artery: Superior thyroidal artery, ascending pharyngeal artery, lingual artery, occipital artery, facial artery, posterior auricular artery, internal maxillary artery and superficial temporal artery.

The internal maxillary artery branches are superficial temporal artery, middle meningeal artery, accessory meningeal artery and anterior deep temporal artery.

The superior thyroid artery supplies the thyroid and larynx. The ascending pharyngeal artery supplies the nasopharynx and tympanic cavity. The lingual artery supplies the tongue, floor of

Flowchart 16.1: Arch of aorta and its branches (showing cerebral circulation).

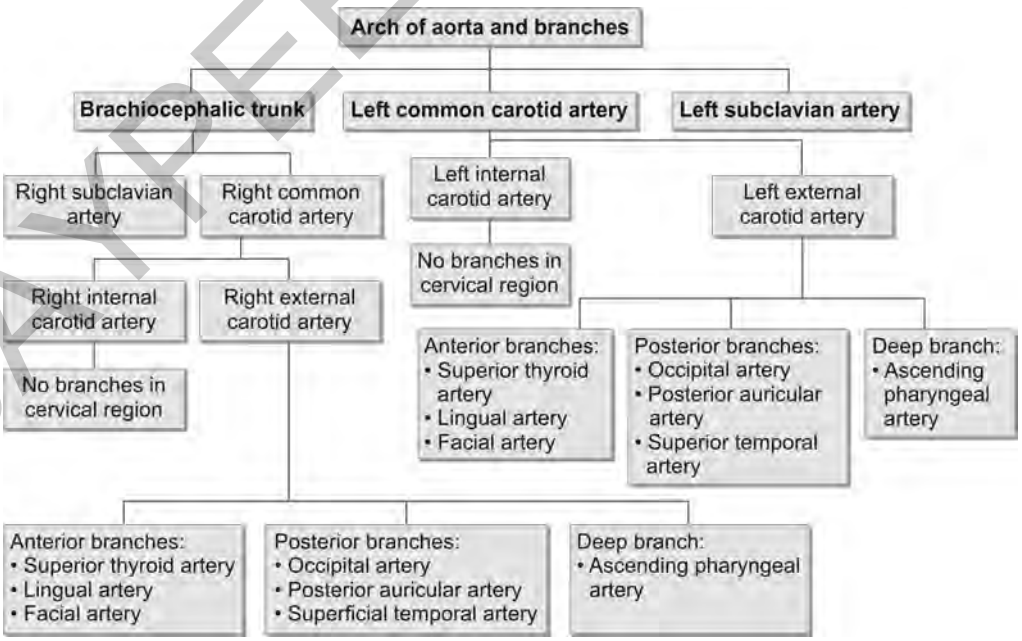

JAYPEE BROTHERS

the mouth and submandibular gland. The occipital artery supplies the scalp and upper cervical musculature.

Facial artery branches supply the palate, pharynx, orbit, face and important anastomosis with other external carotid artery branches.

The superficial temporal artery and posterior auricular arteries supply the scalp, buccal region and ear structures. The internal maxillary artery gives vascular supply to temporalis muscles, meninges, paranasal sinuses and mandible. While traversing the foramen spinosum, the middle meningeal artery may supply a branch, through the petrous bone, to the facial nerve.

Internal carotid artery: The intracranial portions are petrous and cavernous portions.

Petrous portion of internal carotid artery: The ICA while passing through the carotid canal, gives of the Vidian artery which anastomoses with the basilar artery of posterior circulation.

Cavernous portion of internal carotid artery: It gives off the following branches—meningohypophyseal trunk, inferolateral trunk, ophthalmic artery, posterior communicating artery, anterior choroidal artery, anterior and middle cerebral arteries.

The ophthalmic artery is the first branch of the supraclinoid portion of the ICA and thus serves as a demarcation between the intracavernous and subarachnoid segments of the ICA.

The posterior communicating artery (PCOM) connects the ICA with vertebrobasilar circulation (P1 segment of ipsilateral posterior cerebral artery). The posterior communicating artery supplies the thalamus, hypothalamus and optic chiasm.

Circle of Willis: It is an important collateral system at the base of the brain surrounding the optic chiasm and pituitary stalk. It comprises of—the basilar artery bifurcation (basilar tip), P1 segments of posterior cerebral artery paired distal segments of ICA's, paired posterior communicating arteries (PCOM), paired proximal A1 segments of ACA's and the anterior communicating artery (ACOM). This vascular ring is complete only in about 25% of cases **(Fig. 16.1)**. Perforating vessels arising from the circle of Willis include branches to the thalamus, limbic system, reticular activating system, cerebral peduncles, posterior limb of internal capsule and oculomotor nerve nucleus. The recurrent artery of Heubner originates from the A1 segment to supply the anterior limb of internal capsule, portion of the globus pallidus and head of the caudate nucleus.

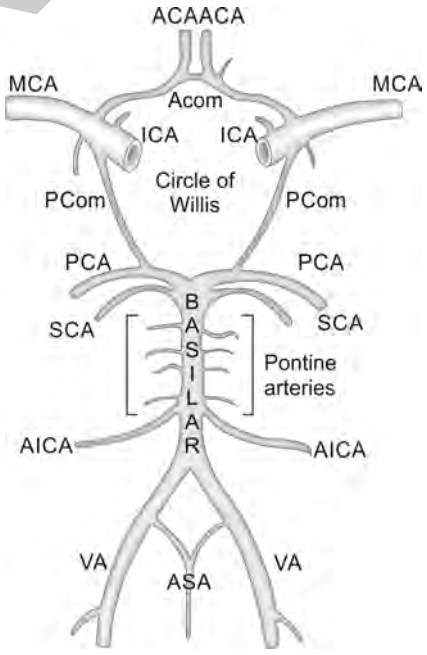

Fig. 16.1: Circle of Willis.

(ACA: anterior cerebral artery; ACOM: anterior communicating artery; MCA: middle cerebral artery; ICA: internal carotid artery; PCOM: posterior communicating artery; PCA: posterior cerebral artery; SCA: superior cerebellar artery; Basilar: basilar artery; AICA: anterior inferior cerebellar artery; VA: vertebral artery; ASA: anterior spinal artery).

Anterior cerebral artery: The most proximal segment is the A1 segment, originating from the terminal ICA to the anterior communicating artery (ACOM). A2 segment is the portion distal to the ACOM and extends into the distal ACA. The A2 segment supplies the head of the caudate nucleus, portions of the globus pallidus, anterior limb of the internal capsule

JAYPEE BROTHERS

and anterior two-thirds of medial cerebral cortex. The main branches of the A2 segment are the orbitofrontal and frontopolar arteries. The ACA bifurcates into the pericallosal and callosomarginal arteries **(Fig. 16.2)**.

Middle cerebral artery: The most proximal segment is M1 segment. It extends from ICA bifurcation to the insular cortex (island of Reil). M2 segment is the course of the artery in the insular cortex and sylvian fissure and it bifurcates into anterior and posterior cortical branches. The branches of the anterior cortical M2 segment are lateral orbitofrontal, operculofrontal and central sulcus arteries. The central sulcus arteries are called precentral (prerolandic) and central (rolandic) branches which supply motor and sensory cortical strips. The branches of posterior cortical M2 segment are the anterior and posterior parietal, angular and posterior temporal arteries **(Fig. 16.2)**.

Anterior spinal arteries: It originates from the vertebral arteries distal to the posteroinferior cerebellar artery origin, they course inferomedially to join with their contralateral artery along the anterior cord.

Basilar artery: The two vertebral arteries join together to form the basilar artery at the pontomedullary junction. The basilar artery courses anterosuperiorly over the ventral pons. It gives off small pontine perforating branches which supply the pyramidal tracts, medial lemnisci, red nuclei, respiratory centers and nuclei for cranial nerves (III, VI, XII). The basilar artery gives off the anterior inferior cerebellar artery and the superior cerebellar artery. The labyrinthine artery is a branch of the anterior inferior cerebellar artery.

Superior cerebellar artery provides vascular supply to the cerebellar peduncles, vermis, dentate nucleus, lateral pontine structures and spinothalamic tracts.

Posterior cerebral arteries: Arise from the basilar artery at the level of pontomesencephalic junction, superior to the oculomotor nerve and tentorium. The proximal PCA is divided into P1 and P2 segments at the junction of the PCA with the posterior communicating artery. A filling defect is frequently seen at the transition between P1 and P2 during frontal vertebral artery angiograms due to the inflow of unopacified blood from the ipsilateral posterior



Fig. 16.2: Angiogram of right anterior cerebral circulation arterial phase—AP view.

JAYPEE BROTHERS

communicating artery. The proximal P2 segment gives rise to the posterior thalamoperforating and thalamogeniculate arteries which supply the posterior portions of the thalamus, geniculate bodies, choroid plexus of third and lateral ventricles, posterior limb of internal capsule, optic tract and small branches to the cerebral peduncles. The other branches of posterior cerebral artery are the splenial artery, anterior and posterior temporal branches, parietooccipital artery. The distal PCA courses posteriorly around the brainstem in the ambient cistern, traveling more medially in the quadrigeminal plate cistern. The distal calcarine cortical branches converge towards the midline but are separated by falx, on Townes projection vertebral angiogram.

Normal Intracranial Venous System

Cerebral cortical veins: Multiple cortical veins drain towards the superior sagittal sinus. The superficial middle cerebral vein which lies in the sylvian fissure may have anastomotic communication with the deep cerebral venous system, the facial veins and the extracranial pterygoid venous plexus. Posteriorly, the superficial middle cerebral vein communicates with the veins of Trolard and Labbé towards the ipsilateral transverse sinus. The veins of Trolard and Labbé cross the subdural space to enter the dural sinuses **(Fig. 16.3)**.

Deep cerebral veins: These are the paired septal veins which run close to midline beside septum pellucidum. The paired thalamostriate veins pass along the floor of the lateral ventricles between the body of caudate nucleus and thalamus. The internal cerebral veins run posteriorly in the roof of third ventricle. The paired basal veins of Rosenthal are formed by the confluence of deep middle and anterior cerebral veins on the ventral surface of brain. The basal veins then coalese posteriorly with the internal cerebral veins to form the vein of Galen **(Fig. 16.3)**. This vein of Galen travels in the midline for about 1–2 cm under the splenium of corpus callosum, it then joins the inferior sagittal sinus in the posterior fossa to form the straight sinus at the junction of falx and tentorial incisura **(Flowchart 16.2)**.



Fig. 16.3: Angiogram of right anterior cerebral circulation venous phase—lateral view.

JAYPEE BROTHERS

Flowchart 16.2: Normal venous anatomy of the brain.

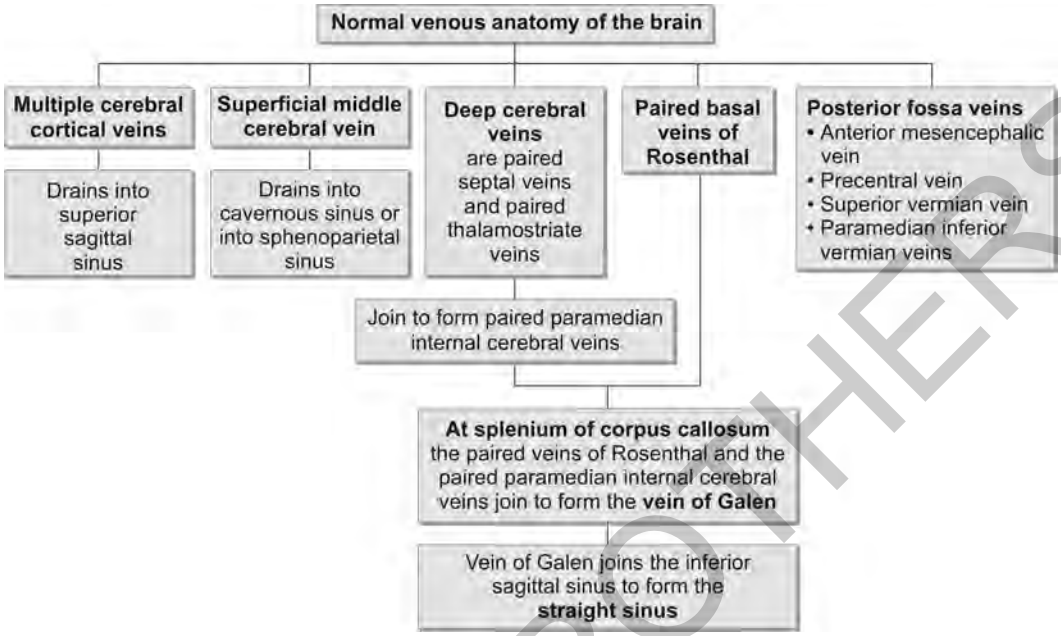

Posterior fossa veins: These are the anterior pontomesencephalic veins, the precentral veins, superior and inferior vermian veins. The anterior pontomesencephalic vein runs along the ventral surface of pons, it drains either into the basal vein of Rosenthal or posterior mesencephalic vein. The precentral veins run posteriorly along the roof of fourth ventricle and drains into the vein of Galen.

Dural sinuses: The dura mater which envelops the central nervous system has two layers that form the reflections like the falx cerebri, tentorium and falx cerebelli. The layers of dura separate to form venous drainage channels or dural sinuses for the brain. Some of them anastomose with the veins of scalp through the emissary veins. The main dural sinuses found are the superior sagittal sinus, inferior sagittal sinus, occipital sinuses, paired transverse sinuses and paired cavernous sinuses.

The superior sagittal sinus travels along the superior margin of falx cerebri, it continues posteriorly and inferiorly in a cresenteric course to the junction point between the falx and tentorium containing the confluence of sinuses—the torcular Herophili near the occipital protuberance.

The inferior sagittal sinus is found within the lower edge of falx between the cerebral hemispheres. It drains posteriorly to join with the vein of Galen forming the straight sinus. The straight sinus drains posteriorly in midline into the torcular herophili.

The occipital sinuses are of variable size, are seen to course superomedially within the dura of the posterior fossa, just lateral to foramen magnum and drains towards the torcular herophili.

The paired transverse sinus follows a cresenteric course within the periphery of the tentorium, laterally and anteriorly from the torcula. The transverse sinuses receive drainage from the inferior cerebral veins and vein of Labbé, it communicates with the cavernous sinuses via the superior petrosal sinuses, which run along the petrous bone and as it nears the tentorium it is called the sigmoid sinus which later empties into the internal jugular vein.

JAYPEE BROTHERS

The paired cavernous sinuses receive venous drainage from the orbits through the superior and inferior ophthalmic veins. The jugular bulbs communicate with the cavernous sinuses by means of the paired inferior petrosal sinuses. The inferior petrosal sinuses also interconnect with those on the opposite side through a clival venous plexus.

Thoracic Aorta

The ascending aorta arises at the aortic root, from the left ventricle. Immediately above the aortic root, the ascending aorta bulges to form the aortic sinuses, the aortic sinuses give rise to right and left coronary arteries to supply the heart. The ascending aorta then courses upwards and continues as the aortic arch. The main branches of the aortic arch (arch of aorta) are the brachiocephalic trunk, left common carotid artery and the left subclavian artery **(Figs. 16.4 and 16.5)**. Sometimes the thyroidea ima artery may arise from the aortic arch. These branches of aortic arch supply the head, neck, brain and upper limbs **(Flowchart 16.3)**.

The aortic arch on plain chest X-ray appears behind the mediastinal structures in midline. (A) **(Fig. 16.4)** The ascending aorta is the first part of aorta and begins at sinotubular junction and terminates as it exists the fibrous pericardium, where it becomes aortic arch; (B) Arch of aorta curves above the left main bronchus and descends into posterior mediastinum. It gives off the: (1) Brachiocephalic trunk; (2) Left common carotid artery; (3) Left subclavian artery; (C) At the level of 4th thoracic vertebra, the arch of aorta becomes the descending thoracic aorta; (D) Descending thoracic aorta in posterior mediastinum enters the abdominal cavity through the aortic hiatus (12th dorsal vertebra level) the left of trachea and esophagus. At the level of 4th thoracic vertebra, the arch of aorta courses downwards as the descending thoracic aorta in the posterior mediastinum.

The descending thoracic aorta gives off 9 posterior intercostal arteries on either side. These intercostal arteries pass laterally into the intercostal spaces. At the level of the aortic hiatus in diaphragm (at 12th thoracic vertebra), the descending aorta passes into the abdominal cavity and continues in the abdomen as the abdominal aorta.

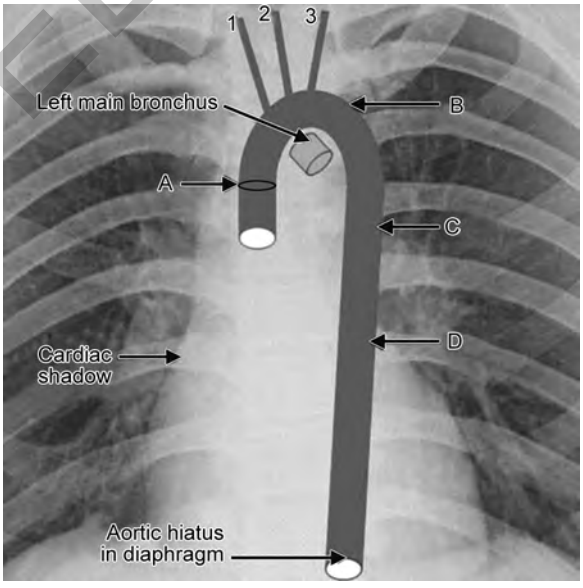

Fig. 16.4: Outline of the thoracic aorta on chest X-ray—PA view.

JAYPEE BROTHERS



Fig. 16.5: Angiogram showing the thoracic aorta.

Flowchart 16.3: Thoracic aorta.

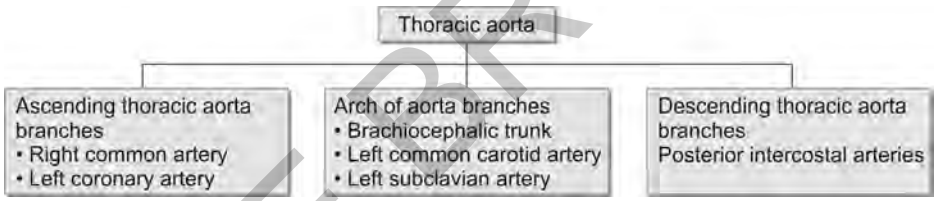

ABDOMINAL ANGIOGRAPHY

Abdominal Aorta

The abdominal aorta is the continuation of the thoracic aorta below the diaphragm at T12 vertebral level. In the abdomen aorta is retroperitoneal in its course and travels downwards to its bifurcation at the level of L4 vertebral body. The abdominal aorta supplies the viscera, peritoneum, gonads and spine during its course. Its anterior branches are the celiac arterial trunk, superior mesenteric artery, inferior mesenteric artery **(Fig. 16.6)**. Its lateral branches are inferior phrenic artery, suprarenal arteries, gonadal arteries, lumbar arteries. Its terminal branches at L4 vertebral level are the common iliac arteries and the median sacral artery **(Flowchart 16.4)**.

Celiac Trunk

The celiac trunk is the main vascular supply of the foregut supplying the lower part of the esophagus to the duodenum; it also supplies the liver, pancreas and spleen. The celiac trunk arises at the level of T12 vertebra from the abdominal aorta and courses forwards until the upper border of pancreas and terminates into: the left gastric artery, splenic artery, common hepatic artery **(Fig. 16.7)**. The left gastric artery gives off esophageal branches, then courses to the right along the lesser curvature of stomach and gives of branches to the stomach. The

JAYPEE BROTHERS

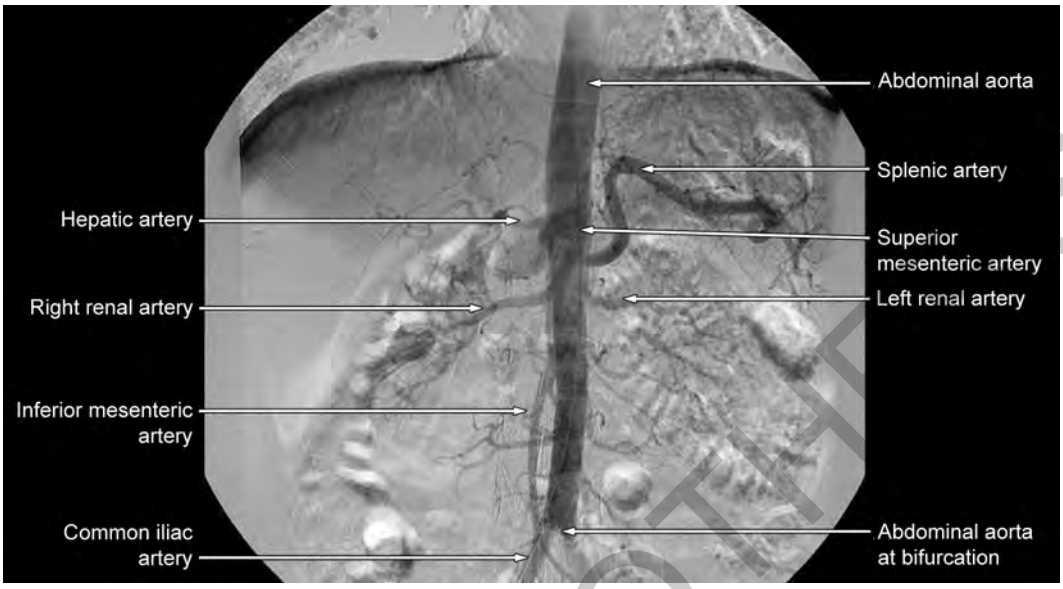

Fig. 16.6: Angiogram of abdominal aorta.

Flowchart 16.4: Abdominal aorta branches.

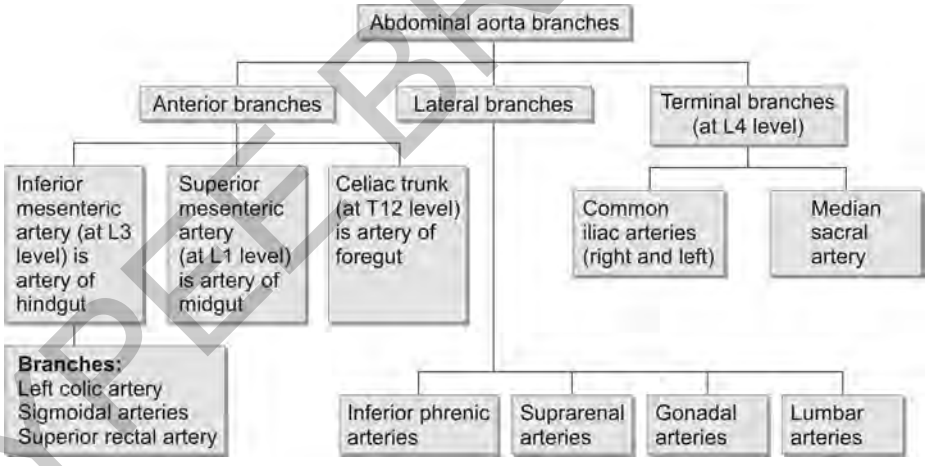

splenic artery courses to the left, is tortuous and runs in the splenorenal ligament to the hilum of the spleen. Before giving off terminal splenic branches it gives off 6-7 short gastric arteries which course in gastrosplenic ligament and the left gastroepiploic artery (which supplies the stomach and omentum).

The splenic artery also gives off the posterior gastric artery during its course to splenic hilum. The common hepatic artery courses over the upper border of the pancreas, the main branches are: right gastric artery, gastroduodenal artery, small supraduodenal arteries and terminal branch—the hepatic artery. The right gastric artery runs forwards in the lesser omentum and to the left in lesser curvature of stomach to anastomose with the left gastric artery. The gastroduodenal artery passes behind the 1st part of duodenum and at the lower border of duodenum divides into the right gastroepiploic artery and superior pancreaticoduodenal

JAYPEE BROTHERS

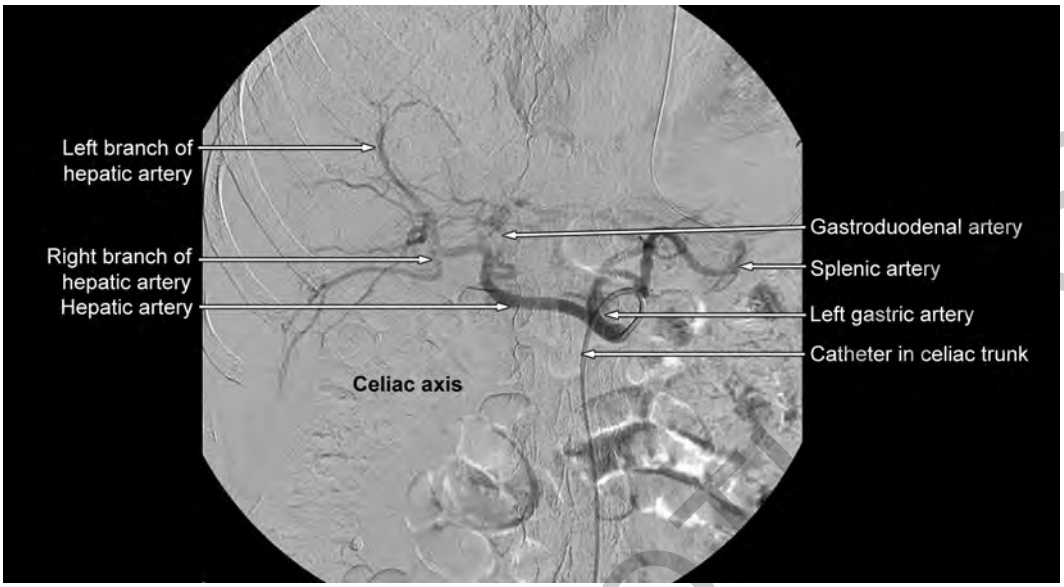

Fig. 16.7: Angiogram of celiac arterial trunk.

Flowchart 16.5: Celiac arterial trunk (artery of foregut).

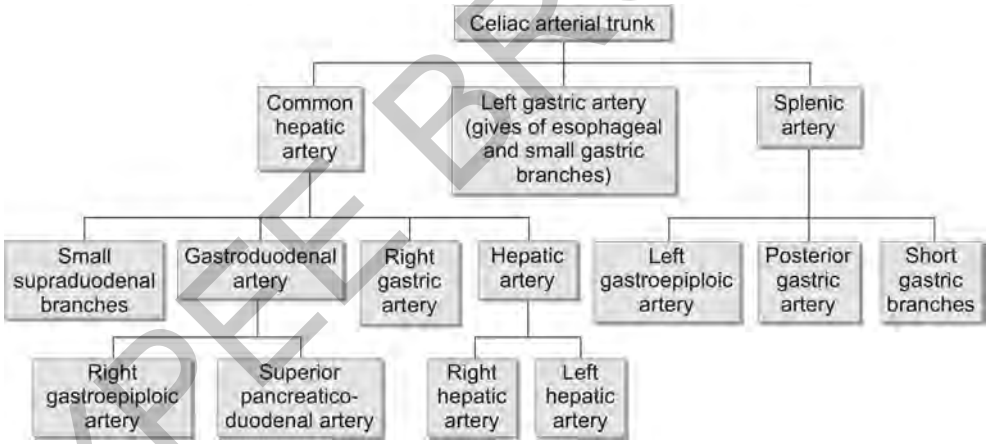

arteries. The supraduodenal arteries are smaller branches arise from the common hepatic artery. The common hepatic artery at the porta hepatis divides into the right and left hepatic arteries to supply the liver **(Flowchart 16.5)**.

Superior Mesenteric Artery

The superior mesenteric artery is the artery of midgut and supplies the gut from the bile duct entrance to the splenic flexure of colon. This artery arises from the abdominal aorta at the level of lower border of L1 vertebra. It courses behind the body of pancreas, later it lies anterior to the left renal vein, uncinate process of pancreas and third part of duodenum. Its main branches are the inferior pancreaticoduodenal artery, jejunal and ileal branches, ileocolic artery, right colic artery, middle colic artery **(Fig. 16.8)**. The inferior pancreaticoduodenal artery is the first branch of superior mesenteric artery. It further divides into anterior and posterior branches to supply the head of pancreas and adjacent duodenum.

JAYPEE BROTHERS

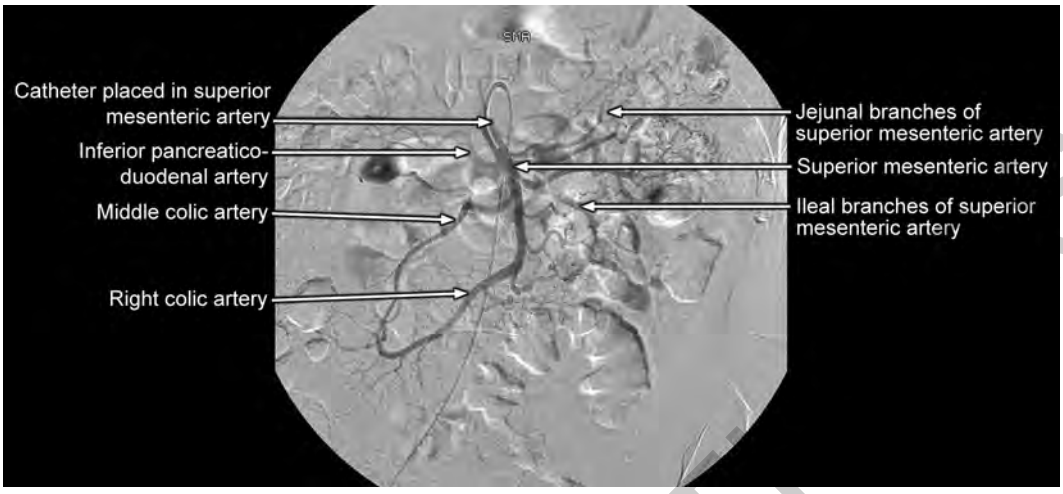

Fig. 16.8: Angiogram of superior mesenteric artery.

The jejunal and ileal branches pass between the two layers of the mesentery and create a network of arteries along the jejunum and ileum to supply the same. The ileocolic artery courses down to the base of mesentery into the right iliac fossa and divides into superior and inferior branches. The superior branch courses along the ascending colon to anastomose with the right colic artery. The inferior branch courses down to the ileocolic junction and gives off the anterior and posterior cecal arteries, an appendicular artery and an ileal artery that anastomoses with the terminal branches of superior mesenteric artery. The right colic artery course downwards into the right infracolic compartment and divides into the ascending and descending branches. The ascending branch courses along the ascending colon upwards to anastomose with a branch from middle colic artery at hepatic flexure of colon. The descending branch courses downwards along the ascending colon to anastomose with a branch from the ileocolic artery. The middle colic artery arises from the superior mesenteric artery at the lower border of neck of pancreas. It courses into the transverse mesocolon and on the right side of transverse colon divides into two branches—right and left branches. The right branch anastomoses with the ascending branch of right colic artery. The left branch anastomoses with a branch of the left colic artery **(Flowchart 16.6)**.

Inferior Mesenteric Artery

It is also called as the artery of hindgut. It arises as an anterior branch of abdominal aorta at the level of L3 vertebra and courses downwards in lower abdomen. Its branches are the left colic artery, sigmoidal arteries and superior rectal artery. These branches supply the descending colon, sigmoid colon and upper rectum. The marginal artery of Drummond is formed by an interconnecting anastomotic network of the branches along the mesenteric border of large bowel. The marginal artery of Drummond is crucial to maintain the vascular supply of large bowel.

Renal Artery

Both the renal arteries arise at right angles to the abdominal aorta at the level of L2 vertebra. The left artery is shorter than the right. Each renal artery gives off small suprarenal and ureteric

JAYPEE BROTHERS

Flowchart 16.6: Superior mesenteric arteriogram (artery of midgut).

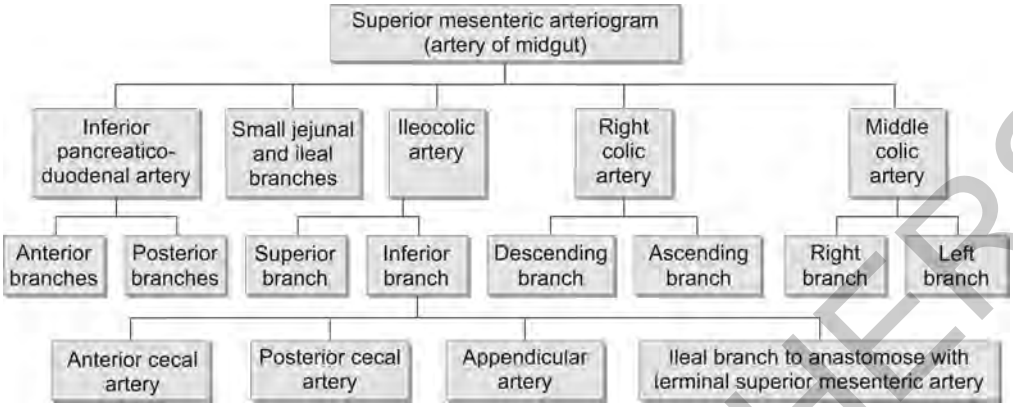

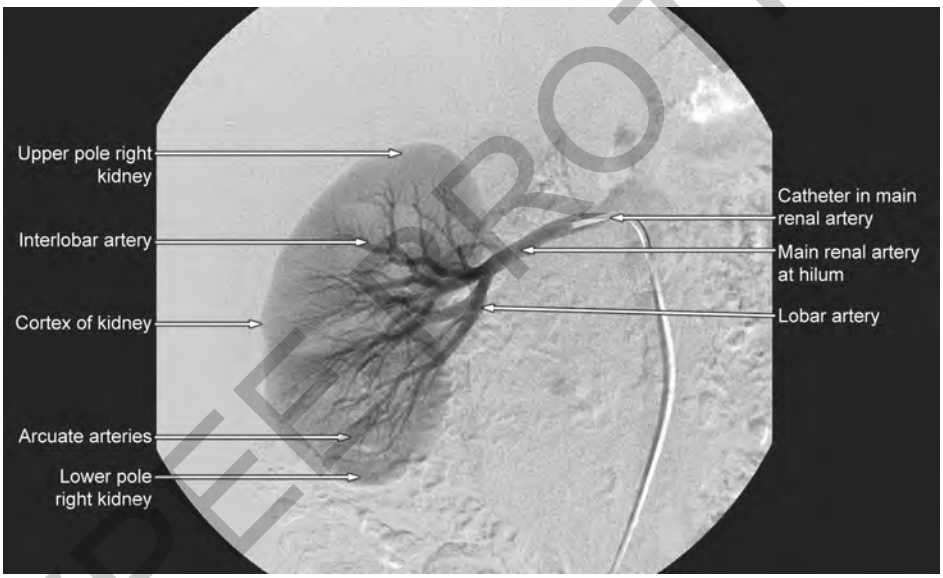

Fig. 16.9: Angiogram of right renal artery nephrogram phase.

branches. The renal arteries course behind the pancreas and the renal vein to reach the hilum of the kidney on either side **(Fig. 16.9**). At the hilum, the renal artery branches into anterior and posterior divisions.

Each kidney is sub-divided into five segments based on arterial supply. The anterior arterial division supplies the apical, upper, middle and lower segments while the posterior arterial division supplies the posterior segment. There is no collateral circulation between these segmental arteries. The segmental arteries are accompanied by their corresponding veins. Each segmental artery divides into lobar artery, interlobar artery, arcuate artery and finally into interlobular arteries. The segmental veins communicate with each other and at the hilum they join to form the renal vein. At the hilum of each kidney, the structures from front to back are vein, artery and ureter.

JAYPEE BROTHERS

for detailed information on radiology books, visit our website www.jaypeebrothers.com, for detailed information on radiology books, visit our webs

TEXTBOOK FOR X-RAY TECHNICIANS

- *Textbook for X-ray Technicians* is a remarkable contribution to the field of imaging technology.
- With this wonderful book of medical imaging technology, students of all levels can excel in performance with confidence.
- This book covers from basic anatomy to technological advancements with lucid presentation and makes it an excellent source for radiography students and teaching faculty of imaging technology.
- It is a must-have title for every medical college library.
- This book helps the students of all levels of medical imaging technology and can do extremely well.

Salient Features

- It is a should-have book for Radiographers and X-ray Technicians, undergoing Diploma or Certificate courses.
- It is very useful for teachers who teach "Radiography".
- The language used is simple and understandable.
- It contains meticulously labelled illustrations for better understanding.
- It includes answers to questions asked in theory and practical examinations.

Hariqbal Singh MD DMRD graduated from Armed Forces Medical College. He served Armed Forces (India) as a Consultant Radiologist and held various administrative appointments in Army Hospitals and Armed Forces Medical College till 2007. Through stages, he achieved the rank of Brigadier. Since 2007, he is involved with few medical colleges as Head of Radiology, and Dean and Director of Administration.

At present, he is Professor and Additional Director. He has technical expertise in managing equipments, personnel, and resources. He is an effective administrator. He has many publications in countrywide and global medical journals. He has authored several books on "Radiology".

He has been a postgraduate teacher, examiner and guide since 1989 with Maharashtra University of Health Sciences, Diplomate National Board, Savitribai Phule Pune University, Sumandeep University, Gujarat, BP Koirala Institute of Health Sciences, Nepal and Kathmandu University, Nepal.

Prashant Naik MD Professor and Head of the Department of Radiology, Shrimati Kashibai Navale Medical College, Pune, Maharashtra, India. He is a keen and enthusiastic teacher. He has several publications in countrywide medical journals. He has been a postgraduate teacher, examiner and guide for Maharashtra University of Health Sciences.

Mritunjoy Kumar Srivastava BSc (Radiography) Diploma in Medical Records is a Senior Radiography Technician at Shrimati Kashibai Navale Medical College, Pune, Maharashtra, India. He is enthusiastic and dedicated to his profession and always takes wholehearted interest in development and growth of the department.

Printed in India

Available at all medical bookstores or buy online at www.jaypeebrothers.com

JAYPEE BROTHERS
Medical Publishers (P) Ltd.
EMCA House, 23/23-B, Ansari Road, Daryaganj, New Delhi - 110 002, INDIA
www.jaypeebrothers.com

Join us on facebook.com/JaypeeMedicalPublishers

Shelving Recommendation
RADIOLOGY

ISBN 978-93-5696-663-5

9 789356 966635