d information on ophthalmology books, visit our website www.jaypeebrothers.com, for detailed information on ophthalmology books, visit our website www.jaypeebrothers.com


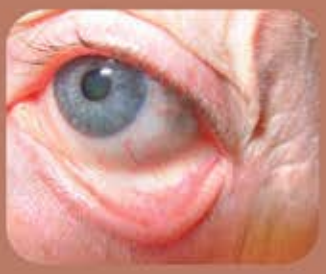

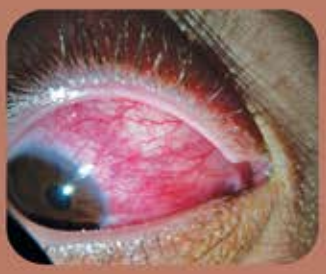

Decision Making in OPHTHALMOLOGY

An Algorithmic Approach

Johan Zwaan

3rd Edition

JAYPEE

Contents

SECTION 1 General Ophthalmology

1. **Visual Loss** 2
   WAJ van Heuven
2. **Transient Visual Loss** 6
   John E Carter, Susan M Berry, Martha P Schatz
3. **Distorted Vision** 8
   WAJ van Heuven
4. **Poor Color Vision** 12
   Joseph M Harrison
5. **Poor Night Vision** 16
   Joseph M Harrison
6. **Isolated Diplopia** 20
   Susan M Berry, John E Carter, Martha P Schatz
7. **Photophobia** 24
   Johan Zwaan
8. **Flashes and Floaters** 26
   WAJ van Heuven
9. **Acquired Increasing Myopia** 30
   Johan Zwaan
10. **Acquired Hyperopia** 34
    Johan Zwaan
11. **Low Vision** 36
    Sandra M Fox, Melanie P Gonzalez
12. **Headache** 42
    Johan Zwaan
13. **Eye Pain** 46
    Tomy Starck, Lorena Larez
14. **Red Eye** 50
    Tomy Starck, Lorena Larez
15. **Itchy Eye** 54
    Kristin Story Held
16. **Dry Eye** 58
    Kristin Story Held
17. **Epiphora** 62
    Kenneth L Piest (Deceased), Martha A Walton
18. **Blepharitis** 64
    Kristin Story Held
19. **Nonpigmented Lesion of the Eyelid** 68
    Reid A Mollman, Eric Hink
20. **Pigmented Lesion of the Eyelid** 72
    Marilyn C Kincaid, Frank W Scribbick
21. **Lesion of the Conjunctiva** 74
    Marilyn C Kincaid, Frank W Scribbick
22. **Acute Conjunctivitis** 78
    Kristin Story Held, Ronald E Wise
23. **Chronic Conjunctivitis** 82
    Kristin Story Held
24. **Subconjunctival Hemorrhage** 86
    Patricia C Nelson
25. **Pigment Alterations of the Iris** 90
    Maria Q Husain
26. **Increased Transillumination of the Iris** 94
    Johan Zwaan
27. **Tumor of the Iris** 98
    Negin Agange, Johan Zwaan
28. **Hyphema** 100
    John P Wooten, Kent L Anderson
29. **Hypopyon** 104
    Lilian Nguyen, Kent L Anderson
30. **Microphthalmos** 108
    Johan Zwaan
31. **Macrophthalmos** 112
    Johan Zwaan
32. **Painful Orbital Swelling** 116
    Constance L Fry
33. **Orbital Compartment Syndrome** 122
    Constance L Fry, Barrett G Haik
34. **Eye Trauma** 126
    Johan Zwaan
35. **Intraocular Calcium Density** 130
    Marilyn C Kincaid, Frank W Scribbick

SECTION 2 Oculoplastics

36. **Eyelid Swelling** 134
David EE Holck, Dimitrios Sismanis

37. **Retraction of the Upper Eyelid** 138
Christopher M DeBacker, David EE Holck

38. **Drooping of Upper Eyelid (Blepharoptosis)** 140
Constance L Fry, Mary Kelly Green, Kenneth L Piest (Deceased)

39. **Acquired Ectropion** 144
Christopher M DeBacker, David EE Holck

40. **Acquired Entropion** 148
Christopher M DeBacker, David EE Holck

41. **Upper Eyelid Reconstruction** 152
David EE Holck, Dimitrios Sismanis

42. **Lower Eyelid Reconstruction** 154
Christopher M DeBacker, David EE Holck

43. **Blepharospasm** 158
Christopher M DeBacker, David EE Holck

44. **Orbital Floor Fracture (Blowout Fracture)** 162
David EE Holck, Dimitrios Sismanis

45. **Enophthalmos** 166
David EE Holck, Dimitrios Sismanis

46. **Exophthalmos** 168
Christopher M DeBacker, David EE Holck

47. **Symblepharon** 172
Dimitrios Sismanis, David EE Holck

SECTION 3 Pediatric Ophthalmology and Strabismus

48. **Treatment of Amblyopia Secondary to a Refractive Error** 176
James L Mims III

49. **The Diagnosis of Strabismus** 180
Johan Zwaan

50. **Infantile Esotropia** 184
James L Mims III

51. **Overaction of the Inferior Oblique Muscles and Dissociated Vertical Deviation** 186
James L Mims III

52. **Recurrent Esotropia After Bimedial Recession for Infantile Esotropia** 188
James L Mims III

53. **Surgical Treatment of Consecutive Exotropia** 190
James L Mims III

54. **Intermittent Exotropia** 192
James L Mims III

55. **Acquired Esotropia of Childhood** 194
James L Mims III

56. **Diagnosis of Head Tilts and Face Turns in Children** 196
James L Mims III

57. **Diagnosis of Cyclovertical Muscle Palsies** 198
James L Mims III

58. **Choice of Surgery for Unilateral Superior Oblique Palsy** 200
James L Mims III

59. **Choice of Surgery for Duane Retraction Syndrome** 202
James L Mims III

60. **Choice of Surgery for Limited Supraduction in a Child** 206
James L Mims III

61. **Choice of Surgery for Sixth Cranial Nerve Palsy** 208
James L Mims III

62. **Choice of Surgery for A- and V-Pattern Strabismus** 212
James L Mims III

63. **Surgical Treatment of Nystagmus with Constant Face Turn, Head Tilt, or Chin Depression** 214
James L Mims III

64. **Developmental Glaucoma** 218
Ankur Gupta, Johan Zwaan, Peter A Netland

65. **Conjunctivitis of the Newborn (Ophthalmia Neonatorum)** 222
Johan Zwaan

66. **Does This Baby See?** 226
Johan Zwaan

67. Leukocoria 230
Johan Zwaan

68. Cloudy Cornea in a Neonate 234
Johan Zwaan

69. Cataract in a Child: Diagnosis 240
Johan Zwaan

70. Cataract in a Child: Treatment 244
Mary A O'Hara, Johan Zwaan

71. Retinoblastoma 248
Timothy P Cleland, Johan Zwaan, Lina Marouf

72. Uncorrectable Poor Vision in a Child 252
Johan Zwaan

73. Nasolacrimal Duct Obstruction in Children 256
Johan Zwaan

SECTION 4 Corneal Disorders

74. Punctate Corneal Staining 260
Lisa Vogel, Daniel A Johnson

75. Corneal Dendritic Lesions 264
Brian P Schallenberg, Daniel A Johnson

76. Marginal Corneal Ulcer 268
Anhtuan H Nguyen, Kent L Anderson

77. Central Corneal Ulcers 272
Ekta Kakkar, Kent L Anderson

78. Corneal Endothelial Dystrophies 276
Lindsay T Davis

79. Corneal Edema 280
John Awad, Richard W Yee

80. Interstitial Keratitis 284
Elizabeth Shane, Richard W Yee

81. Corneal Neovascularization 288
Clinton Duncan, Daniel A Johnson

82. Band Keratopathy 292
Abbie S Ornelas, Kent L Anderson

83. Corneal Pigmentation 296
Mark L McDermott, Nitya Kumar, Richard W Yee

84. Corneal Crystals 302
Mark L McDermott, Lindsay T Davis

85. Corneal Epithelial Dystrophy 306
Maria Q Husain, Richard W Yee

86. Corneal Stromal Dystrophy 310
Maria Q Husain, Richard W Yee

87. Corneal Hypesthesia 314
Gary L Legault, Mark L McDermott

SECTION 5 Glaucoma and Intraocular Pressure Problems

88. Diagnosis of Glaucoma 318
Scott D Smith

89. Elevated Intraocular Pressure 320
Scott D Smith

90. Anatomically Narrow Angles 324
John M Parkinson, J Kevin McKinney, Manishi A Desai

91. Acutely Elevated Intraocular Pressure 328
Scott D Smith, John M Parkinson

92. Primary Open-Angle Glaucoma 332
Scott D Smith, Roy Whitaker Jr

93. Low-Tension (Normal-Tension) Glaucoma 334
Alvaro PC Lupinacci, Peter A Netland

94. Neovascularization of the Iris 338
Roy Whitaker Jr, Scott D Smith, Manishi A Desai

95. Enlarged Episcleral Veins 342
Joshua Nunn, John Ryan McManus, J Kevin McKinney, Peter A Netland

96. Surgical Treatment of Medically Uncontrolled Primary Open-Angle Glaucoma 346
Scott D Smith, John M Parkinson

97. Shallow Anterior Chamber After Glaucoma Surgery 350
J Kevin McKinney, Roy Whitaker Jr, Kundandeep S Nagi

98. High Intraocular Pressure After Glaucoma Filtration Surgery 354
John M Parkinson, J Kevin McKinney, Kundandeep S Nagi

99. The Glaucoma Patient with Cataract 358
John W Boyle IV, Peter A Netland

100. Ocular Hypotony 362
John Ryan McManus, J Kevin McKinney, Peter A Netland

101. Medical Therapy of Glaucoma 364
Kevin Gamett, Johan Zwaan, Peter A Netland

101A. Uveitis-Associated Glaucoma 368
John Ryan McManus, Ashvini K Reddy, Peter A Netland

SECTION 6 Lens Disorders

102. Opacities on the Lens Surface 372
Johan Zwaan

103. Subluxated and Dislocated Lenses 376
Johan Zwaan

104. Pain After Cataract Surgery 380
Kristin Story Held, Irene M Lee

105. Poor Vision After Cataract Surgery 386
Sonya Dhar

106. Shallow Anterior Chamber After Cataract Surgery 390
Sonya Dhar

107. Diplopia After Cataract Surgery 394
Johan Zwaan

SECTION 7 Retinal and Vitreous Disorders

108. Retinal Imaging (Imaging in Ophthalmology) 398
Gelareh Abedi

109. Macular Bull's Eye 400
Gelareh Abedi, Joseph M Harrison

110. Macular Star 404
Gelareh Abedi

111. Macular Cherry-Red Spot 406
Armand Daccache, Amir Mohsenin, Elizabeth Yang

112. Crystals in the Fundus 408
Gelareh Abedi

113. Retained Lens Fragments 410
Lina Marouf, Gelareh Abedi, Timothy P Cleland

114. Subretinal Neovascular Membranes 412
Juan E Rubio Jr, Lina Marouf, Bailey L Lee

115. Juxtapapillary Lesion 418
Ron A Adelman, Aaron J Parnes

116. Choroidal Folds 422
Farhan F Malik, Deeba Husain

117. White Spots in the Fundus 426
Manju Subramanian

118. Hard Exudates in the Fundus 430
Nisha Warrier, Steven Ness

119. Black Spots in the Fundus 434
Vasiliki Poulaki, Sotiria Palioura

120. Intraocular Hemorrhages 438
Negin Agange, Gelareh Abedi

121. Cotton-Wool Spots in the Fundus 444
Gelareh Abedi

122. Retinal Vascular Anomalies 448
Ambar Faridi, Mark Pennesi

123. Sheathing of Retinal Vessels 454
Lina Marouf, Lanny S Odin, Juan E Rubio Jr, Timothy P Cleland

124. Retinal Arterial Occlusive Disease 458
Timothy P Cleland, Lina Marouf

125. Retinal Vein Occlusion 462
Omar S Punjabi, Lina Marouf

126. Retinal Elevation 466
Steven Ness

127. Malignant Melanoma of the Choroid 470
Thanos D Papakostas, Vasiliki Poulaki

128. Vitreous Opacities 474
Lina Marouf, Lanny S Odin, Bailey L Lee

129. Retinal Holes and Tears 480
Maria Stephanie R Jardeleza, WAJ van Heuven

130. Retinal Detachment 484
Mitchell J Goff, James E Bell

131. Diabetic Retinopathy 490
Maria Stephanie R Jardeleza, WAJ van Heuven

132. Retinal Drug Toxicity 494
Bailey L Lee

SECTION 8 Uveitis

133. External Ocular Inflammation 498
Olga A Shif, Daniel A Johnson

134. Anterior Uveitis 502
Daniel A Johnson

135. Intermediate Uveitis 506
Daniel A Johnson

136. Retinitis 508
Daniel A Johnson

137. Choroiditis 510
Daniel A Johnson

138. Panuveitis 512
Daniel A Johnson

139. Local Ocular Therapy 514
Steven R Cohen, Daniel A Johnson

140. Systemic Therapy 518
Steven R Cohen, Daniel A Johnson

SECTION 9 Neuro-Ophthalmic Disorders

141. The Abnormal Pupil 524
Angela M Herro, Martha P Schatz, John E Carter

142. Nystagmus 528
Jorge A Montes, Martha P Schatz, John E Carter, Susan M Berry

143. Swollen Disc 530
Martha P Schatz, Angela M Herro

144. Optic Neuropathy 532
John E Carter, Susan M Berry, Martha P Schatz, David K Scales

145. Loss of Visual Field 536
Angela M Herro, Johan Zwaan

Index 541

Distorted Vision

3

WAJ van Heuven

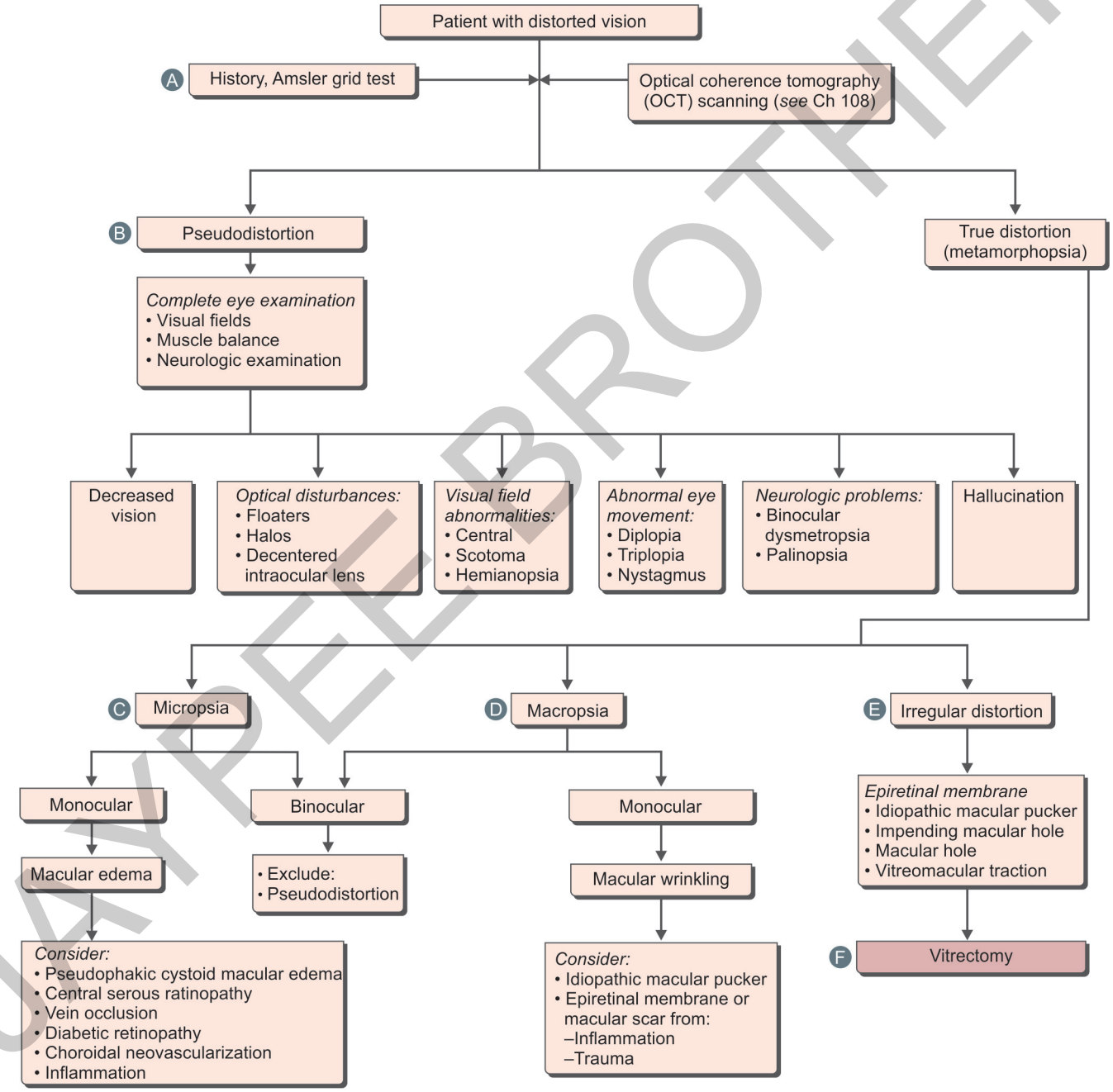

JAYPEE BROTHERS

Distorted vision, or irregularities of lines and figures in the central visual field, is called *metamorphopsia*. Micropsia and macropsia, the two forms of dysmetropsia (seeing abnormal size), are forms of metamorphopsia in which objects appear smaller or larger than they really are.

A. Take a careful history because patients complaining of distorted vision are often nonspecific in describing symptoms. They also often do not know whether the distortion is monocular or binocular, or whether it is associated with other symptoms. Testing for distortion, one eye at a time, is easily done using the Amsler grid, which tests the central 20° of vision at reading distance. Optical coherence tomography (OCT) can yield significant information (Chapter 108).

B. Some patients use the word *distortion* to describe the perception of blur caused by acquired decreased vision or central scotoma in one eye. Monocular visual acuity and Amsler grid testing elicit these causes. Occasionally, large vitreous floaters, usually from vitreous detachment, may interfere with vision, especially at close range, and mimic monocular distortion. Halos around lights, with or without blurring of vision, may indicate glaucoma. Diplopia or triplopia, whether monocular or binocular, must be investigated initially with a careful examination of muscle balance. Acquired nystagmus requires a thorough neurologic evaluation. Binocular dysmetropsia, although usually retinal in origin, may be cerebral. Cerebral micropsia is more common than macropsia. It may be associated with other neurologic conditions such as migraine, epilepsy, hysteria, schizophrenia, drug intoxication and focal lesions. These symptoms may be difficult to differentiate from hallucinations. *Palinopsia,* a term meaning visual perseveration, which is the persistence of visual perception after the object has been removed, also requires neurologic evaluation. Visual hallucinations occur from a variety of causes, most of which are not ocular. They represent complex integrative processes and often have little value in topical diagnosis. However, formed hallucinations are often the result of temporal lobe involvement, and unformed ones suggest involvement of the occipital lobe. Many hallucinations are associated with cerebral tumors, although they can be caused by cerebral injury or infection. A complete neurologic evaluation is indicated because different forms of epilepsy, visual field defects and other neurologic findings may help localize the cause.

C. Micropsia from ocular causes, so-called peripheral metamorphopsia, is often monocular. If binocular, just like binocular macropsia, central metamorphopsia (i.e. resulting from cerebral causes) must be ruled out. True ocular micropsia is caused by an abnormal separation of the rods and cones, usually in the macular region, which causes fewer retinal receptors to be stimulated by an object than would normally be stimulated by that object. Therefore, the brain receives and perceives the object to be smaller. Conditions that separate the retinal receptors, such as stretching or edema of the retina, cause micropsia.

D. True peripheral or retinal macropsia, in contrast to micropsia, is caused by the retinal photoreceptors being closer together than normal. Thus more retinal receptors are stimulated by an object than would normally be stimulated by that object, which causing the brain to receive and perceive that the object is larger than actual. Conditions causing shrinkage of the retina, such as retinal scars, are the most common cause of macropsia. If a retinal condition, such as inflammation or trauma, initially causes edema and later causes scarring, macropsia may follow micropsia.

E. Irregular metamorphopsia can result from any condition that causes an irregular distortion of the retina, so the photoreceptors are no longer evenly spaced. Patients perceive straight lines to be crooked and, if the condition involves the fovea, may also have blurred vision. Any condition that causes scarring of the retina or shifting of the retina because of traction may cause metamorphopsia. Patients with impending macular holes or small full-thickness macular holes may also have complaints of metamorphopsia. Like the vitreomacular traction syndrome, these may not be obvious unless one performs careful contact lens biomicroscopy.

JAYPEE BROTHERS

F. Pars plana vitrectomy and membrane stripping can improve vision and distortion in patients with epiretinal membranes and vitreomacular traction syndrome. Macular holes can be closed with improved vision after vitrectomy and fluid-gas exchange. Because of the high rate of spontaneous resolution of impending macular holes, these are generally observed unless a full-thickness hole develops.

BIBLIOGRAPHY

1. Gass JDM. Macular dysfunction caused by vitreous and vitreoretinal interface abnormalities. Stereoscopic Atlas of Macular Diseases: Diagnosis and Treatment, 4th Edition. St Louis: Mosby; 1997.
2. Miller NR. Walsh and Hoyt's Clinical Neuro-ophthalmology, 5th Edition. Baltimore: Williams & Wilkins; 1998.

JAYPEE BROTHERS

for detailed information on ophthalmology books, visit our website www.jaypeebrothers.com, for detailed information on ophthalmology books, visit our website www.jaypeebro

Decision Making in OPHTHALMOLOGY

An Algorithmic Approach

The third edition of this updated work provides an overview of the decision-making processes used in the diagnosis and treatment of 145 common and uncommon ophthalmic conditions, including

- General Ophthalmology
- Oculoplastics
- Pediatric Ophthalmology and Strabismus
- Corneal Disorders
- Glaucoma and Intraocular Problems
- Lens Disorders
- Retinal and Vitreous Disorders
- Uveitis
- Neuro-Ophthalmic Disorders

Each chapter features an algorithm that details in a step-by-step fashion how a clinician should proceed from a symptom or sign to a diagnosis or from a diagnosis to an appropriate management plan.

Features new to this edition include

- Updated content, including new chapters on Orbital Compartment Syndrome, Corneal Endothelial Dystrophies, Uveitic Glaucoma, Diplopia after Cataract Surgery, and Imaging in Ophthalmology.
- New full color format, with the addition of tables, illustrations, and color images that help to illustrate key clinical findings.

Printed in India

Available at all medical bookstores or buy online at www.jaypeebrothers.com

JAYPEE BROTHERS
Medical Publishers (P) Ltd.
EMCA House, 23/23-B, Ansari Road,
Daryaganj, New Delhi - 110 002, INDIA
www.jaypeebrothers.com

Join us on facebook.com/JaypeeMedicalPublishers

Shelving Recommendation
OPHTHALMOLOGY

ISBN 978-93-5696-672-7