sit our website www.jaypeebrothers.com, for detailed information on surgery books, visit our website www.jaypeebrothers.com, for detailed information on surgery books

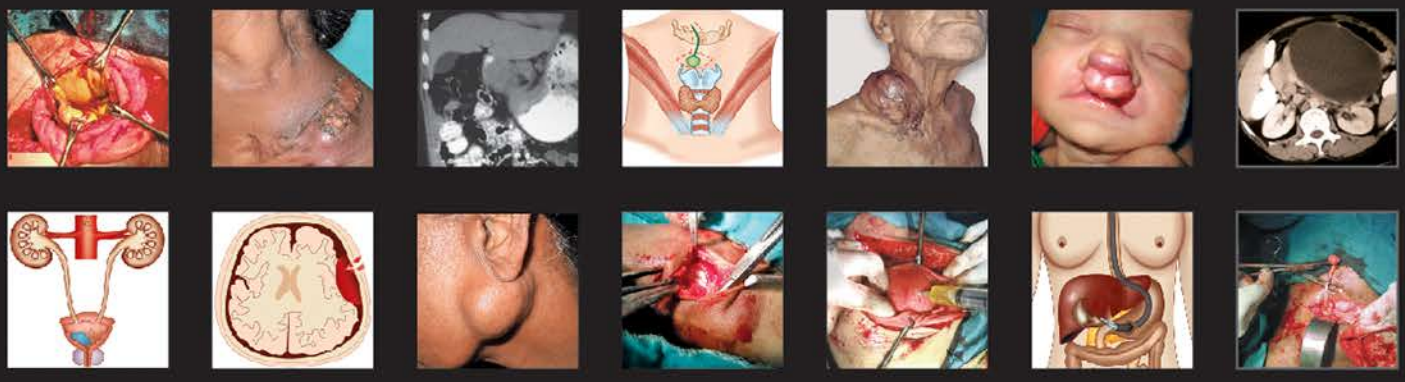

2nd Edition

Illustrated SURGERY

A Basic Road Map for the Postgraduates

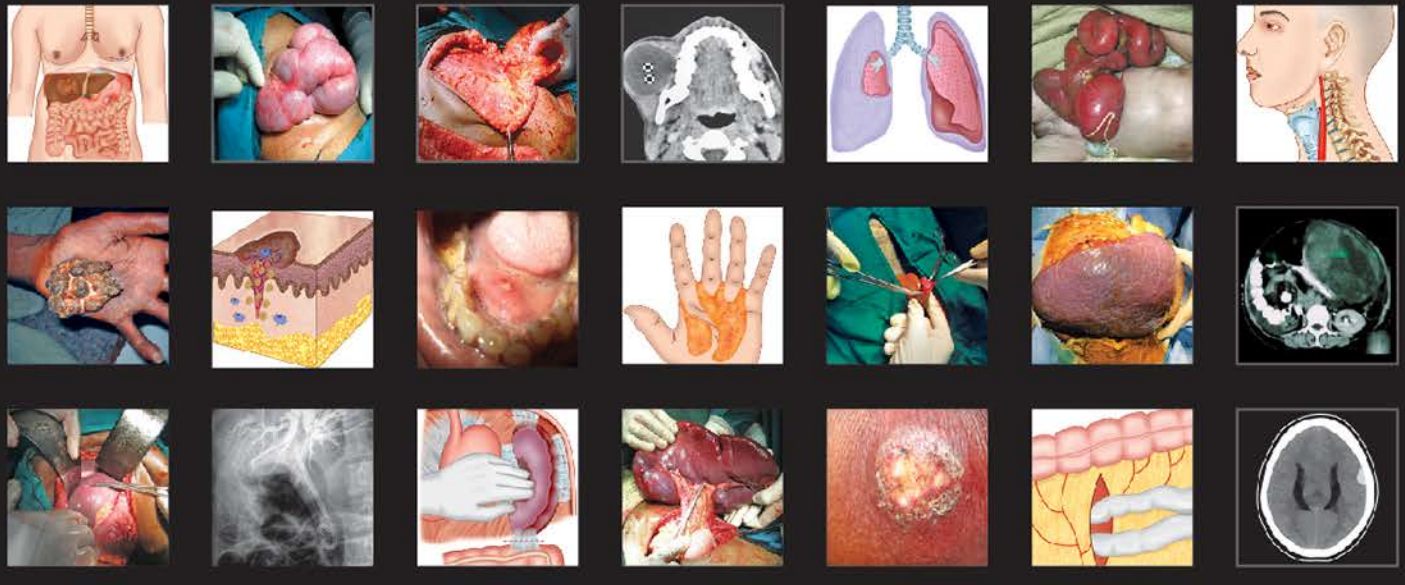

Nilay Mandal

JAYPEE

Contents

CHAPTER 1 Wound Healing 1
CHAPTER 2 Disorders of Fluid, Electrolyte, and Acid-base Balance 16
CHAPTER 3 Hemostasis–Coagulation–Hemorrhage 30
CHAPTER 4 Gallbladder and Extrahepatic Biliary System 40
CHAPTER 5 Diseases of the Liver 107
CHAPTER 6 Diseases of Pancreas 160
CHAPTER 7 Spleen 205
CHAPTER 8 Abdominal Wall, Peritoneum, Mesentery, and Retroperitoneum 218
CHAPTER 9 Diseases of the Stomach 239
CHAPTER 10 Intestine 292
CHAPTER 11 Appendix 374
CHAPTER 12 Diseases of Rectum and Anal Canal 390
CHAPTER 13 Breast 436
CHAPTER 14 Disorders of Thyroid 487
CHAPTER 15 Parathyroid, Adrenal, Endocrine Pancreas, and MEN 532
CHAPTER 16 Trauma 570
CHAPTER 17 Burn 649
CHAPTER 18 Arterial, Venous, and Lymphatic Diseases 665
CHAPTER 19 Hernia 711
CHAPTER 20 Diseases of Testes, Scrotum, and Penis 752
CHAPTER 21 Diseases of the Esophagus 771
CHAPTER 22 Diseases of the Salivary Gland 801
CHAPTER 23 Diseases of Skin and Adnexa 816
CHAPTER 24 Ulcer, Sinus, and Fistula 841
CHAPTER 25 Urology 856

CHAPTER 26 Minimally Invasive Surgery 929

CHAPTER 27 Nerve Injury 946

CHAPTER 28 Surgery of Hand 954

CHAPTER 29 Neck Swelling 962

CHAPTER 30 Cleft Lip and Palate 976

CHAPTER 31 Anesthesia 981

CHAPTER 32 Instrument 994

CHAPTER 33 Do's and Dont's in Surgery 1018

CHAPTER 34 Miscellaneous (Trials, Terminologies, Classification, Criteria, Scoring, Important Facts, Most Appropriate Investigations) 1043

Index 1091

Chapter 20

Diseases of Testes, Scrotum, and Penis

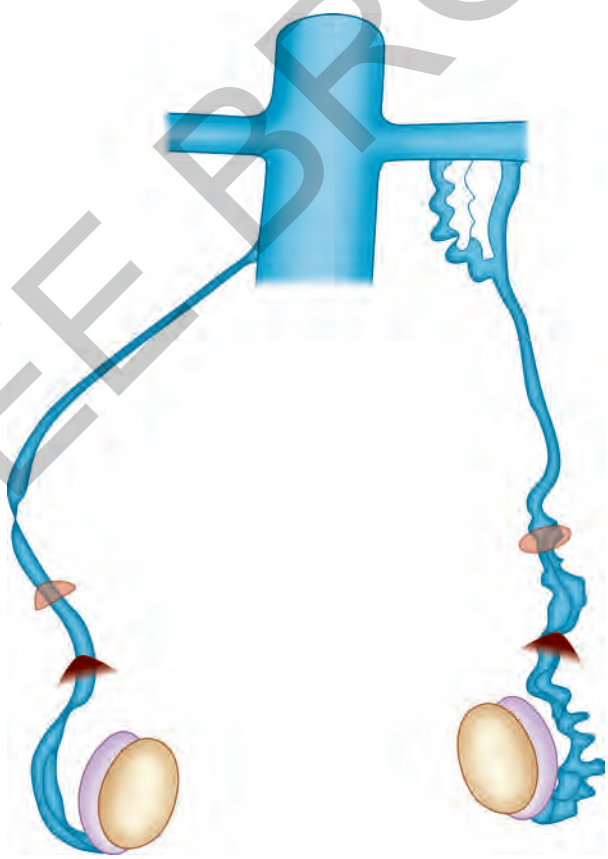

JAYPEE BROTHERS

Important Topics

- Undescended Testis
- Torsion of Testis
- Acute Epididymitis
- Varicocele
- Hydrocele
- Other Scrotal Diseases
- Phimosis
- Paraphimosis

JAYPEE BROTHERS

'Science can never be a closed book. It is like a tree, ever growing, ever reaching new heights. Occasionally, the lower branches, no longer giving nourishment to the tree, slough off. We should not be ashamed to change our methods; rather we should be ashamed to do so.'

Charles Value Chapin (1856–1941)
American Physician and Public Health Officer

Undescended Testis

Cryptorchidism or undescended testis

Failure of a testis to descend into a scrotal position

Congenital cryptorchidism
Testes that are extrascrotal from the time of birth

Acquired cryptorchidism
Testes that are intrascrotal at birth but later shifted to extrascrotal position

Ascending
From intrascrotal to extrascrotal position spontaneously at some time after birth

Entrapped
From intrascrotal to extrascrotal position after inguinal surgery

Congenital Cryptorchidism

- Found in 3% of full-term male newborns and 30% of preterm newborns
- More prevalent in preterm, small for gestational age, low birth weight, and twin neonates. About 70–77% of undescended testes will spontaneously descend, by 3 months of age
- By the age of 1 year, incidence of spontaneous descent become 1%.
- Risk is 6.9-fold if brothers is affected, risk is 4.6 fold if father is affected.

Possible Sites of Cryptorchid Testis

- Canalicular (within the inguinal canal)
- At superficial inguinal ring
- Prescrotal (above or at the scrotal inlet)
- Abdominal (proximal to the internal inguinal ring, near the urinary bladder, kidney, iliac vessels)

Ectopic Testis

- Testis descends along the normal pathway upto external ring. Then, it deviates on an ectopic location.
- Ectopic testis is fully developed.

Possible Sites of Ectopic Testis

- Superficial inguinal pouch (distal and lateral to the superficial inguinal ring, between Scarpa's fascia and external oblique fascia)
- Femoral
- Prepubic
- Peripenile
- Perineum
- Contralateral scrotum (crossed ectopia)
- Perirenal

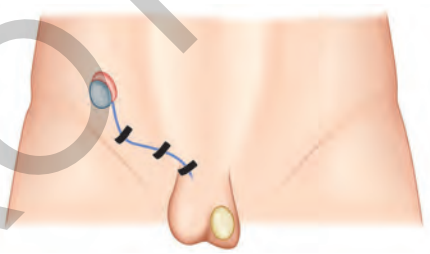

Descent is arrested anywhere in its path of its descent.



Right sided undescended testis.

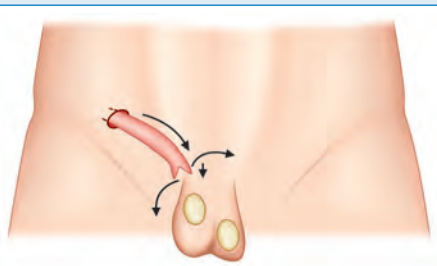

Deviation to different ectopic locations.

JAYPEE BROTHERS

Retractile Testis

Testis that moves easily out of scrotal position, but can be manually replaced in scrotal position easily.

Predisposing factors: (i) Hyperactive cremasteric reflex; (ii) Short patent processus vaginalis; and (iii) Entrapping adhesions.

To differentiate undescended from retractile testes: Manipulation of a extrascrotal testis into the scrotum and maintained into that position for 30 seconds (to fatigue cremasteric muscle), then release, if it remains in place, it is retractile testis and if it immediately retracts to an extrascrotal position, it is undescended testis.

Treatment: Boys with retractile testis should be monitored yearly, up to puberty or till the testis no longer retractible.

Recurrent cryptorchidism: Testes that was undescended at birth, descended spontaneously, and then become extrascrotal subsequently.

Vanishing testis: Testis was developed at initial phase but disappeared at some point of development (may be due to spermatic cord torsion or vascular accident). Unilateral absent testis is termed as Monorchia and bilateral absent testes is termed as Anorchia.

Peeping testis: In nonpalpable testes during laparoscopic exploration, after insufflation of the abdomen, the testis moves through the internal ring and can be palpated.

Testicular Descent

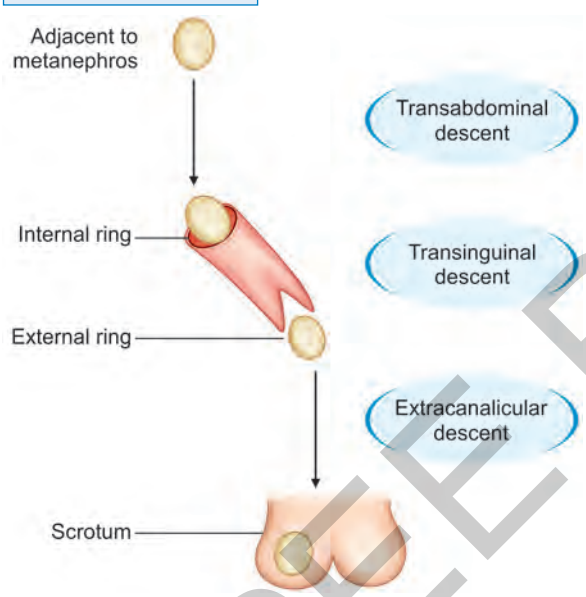

Testicular descent is divided into three phases:

1. **After 23rd weeks of gestation:** Testis descends to just inside the internal ring
2. **After 28th weeks of gestation:** Testis travels through the inguinal canal alongside and posterior to processus vaginalis
3. **After 28th weeks of gestation:** From external ring to the scrotum.

Factors Responsible for Testicular Descent

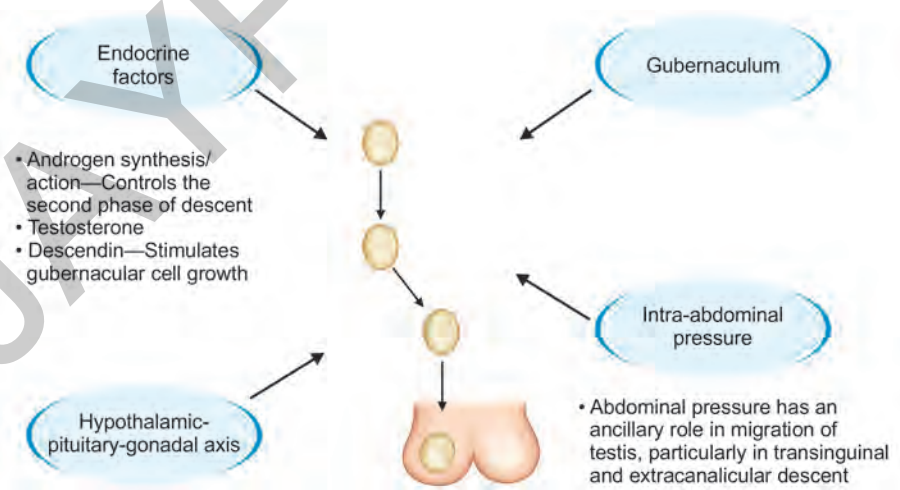

Syndromes Associated with Cryptorchidism

- Persistent Müllerian duct syndrome
- Klinefelter syndrome
- Down syndrome
- Prune belly syndrome

JAYPEE BROTHERS

Histological Changes in Cryptorchid Testes

Changes started between 1–2 years of age.

Changes:

- Decreased numbers of Leydig cells
- Degenerated Sertoli cells
- Delayed disappearance of gonocytes
- Delayed appearance of adult dark (Ad) spermatogonia
- Developmental failure of primary spermatocytes
- Decreased number of total germ cell counts.

Hypoplasia of the Leydig cells–earliest postnatal histological abnormality.

Complications

Infertility: Paternity is almost 90% in unilateral cryptorchidism, 35–65% in bilateral cryptorchidism.

Neoplasia: Men with persisting or treated cryptorchidism have a relative risk of 3.6 for developing testicular cancer (seminoma); no increase in risk in men with history of spontaneous descent.

[Most common tumor in cryptorchid testis is seminoma]

Hernia: Patent processus vaginalis is found in more than 90% of patients.

Torsion of testis: Increased susceptibility is due to developmental anatomic abnormality between the testis and its mesentery.

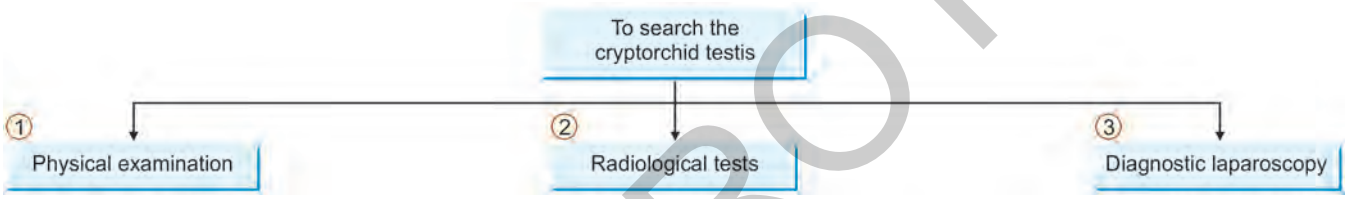

Methods of examination of testes in infants: Infants in supine position with legs gently frog-legged or sitting on the lap of the parent, then gentle downward pressure from the anterior superior iliac spine to the scrotum along the path of inguinal canal with counter palpation with the opposite hand.

In older children, the baby have to examined in either upright cross-legged or supine position. Complete examination of the groin, perineum, femoral region, contralateral hemiscrotum (to exclude transverse testicular ectopia), pubic area is necessary to classify testis as palpable or nonpalpable.

In prepubertal boys with nonpalpable testes, examine under anesthesia is recommended to assess whether testis is palpable or not.

In laparoscopic exploration, search for testis is done from the level of kidney to the internal ring.

- **If testis is identified** and anatomy appropriate for salvage, then primary orchidopexy or Fowler Stephens orchidopexy (one stage/two stage) is planned, if not appropriate for salvage, then orchiectomy.
- **If testis is not identified**, exploration should be continued to identify the testicular vessels. If the vessels end blindly in the retroperitoneum, exploration can be terminated or may be explored distal to the internal ring.
- If vessels entering the inguinal ring, then inguinal canal or scrotum should be explored. If any nubbin (vanishing testis) is present, it should be sent for histopathological examination.

Other clinical findings that have to be searched:

- Is scrotum underdeveloped or not
- Is any penile malformations present (hypospadias, micropenis)
- Any paratesticular abnormalities, any hernia or hydrocele in contralateral side.

When testis becomes nonpalpable:

- Intra-abdominal testis
- Absent (vanishing testis)
- Atrophic testis
- Missed on clinical examination.

JAYPEE BROTHERS

Role of Imaging in Undescended Testis

Both USG and MRI have limited accuracy in diagnosis of nonpalpable testes and therefore not recommended for management of nonpalpable testes. MRI may be helpful to locate abdominal ectopic testis that cannot be detected by diagnostic laparoscopy.

A newborn with male phallus and bilateral nonpalpable gonads is potentially a genetic female (46XX) with congenital adrenal hyperplasia until proven otherwise. These patients may present with shock, hyponatremia, and hyperkalemia. Serum electrolyte estimation, hormonal profile (17-hydroxyprogesterone, LH, FSH, testosterone, androstenedione), and karyotyping is indicated.

If bilateral nonpalpable testes is without congenital adrenal hyperplasia, either bilateral abdominal testes or bilateral congenital anorchia should be suspected. Serum MIS (Mullerian Inhibiting Substance) or AMH (Anti-Mullerian Hormone), inhibin B, FSH, LH, and testosterone should be assessed for anorchia.

Treatment

- Definitive treatment should be started between 6 and 12 months of age, particularly in bilateral or unilateral intra-abdominal testis (to preserve most of the testicular tissues).
- Child presenting after this time period also must be treated by orchiopexy to prevent further testicular impairment (spermatogenic as well as endocrinal) and to attain the scrotal position for easy palpation (early detection is possible if any malignant transformation). **Orchiopexy does not reduce the risk of development of cancer.**
- Orchiectomy is indicated only for postpubescent patients, particularly for abdominal testis or difficult to mobilize with contralateral normally descended testis.

Benefits of Orchidopexy

- Optimization of testicular function (spermatogenic and endocrinal)
- Early diagnosis of testicular malignancy (if any malignant transformation)
- Less risk of testicular torsion
- Psychological

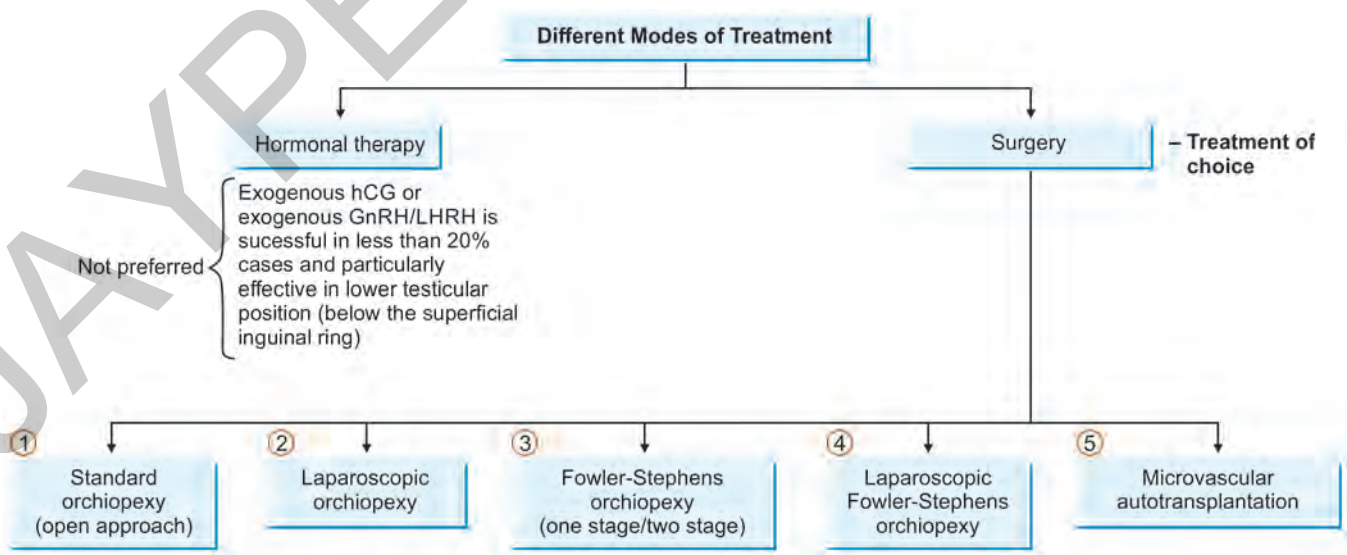

JAYPEE BROTHERS

Standard Orchiopexy (Open Approach)

Standard Two-incision (Inguinal and Scrotal) Approach

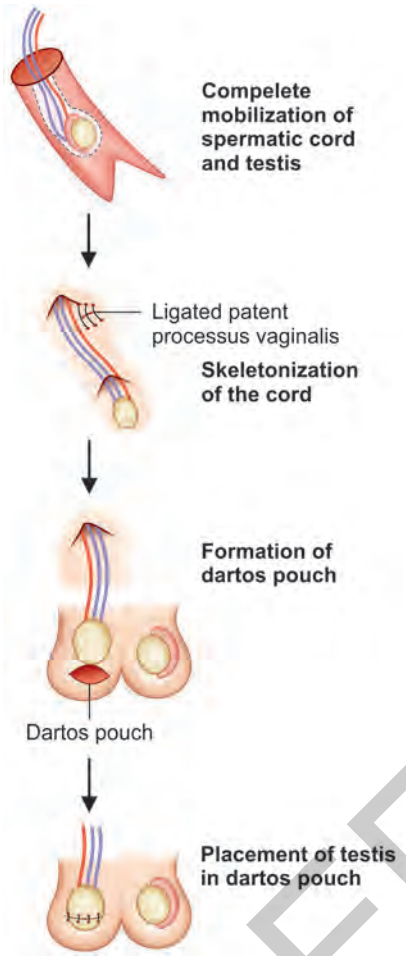

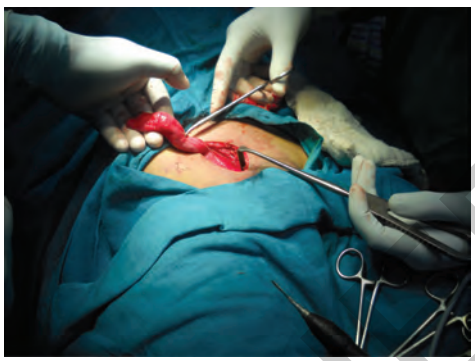

Operative Picture Showing Complete Mobilization of Spermatic Cord and Testis



Placement of Testis in Dartos Pouch

Primary Single Incision Scrotal Approach

Another approach for low lying (distal to the external inguinal ring) palpable testes.

- **Different incisions for transscrotal orchidopexy are:** (i) Bianchi incision; (ii) Midline scrotal approach; and (iii) Transverse low scrotal approach.
- **Advantages:** (i) Less operative time; (ii) Enhanced recovery; and (iii) Better cosmesis

Laparoscopic Orchidopexy

A useful surgical approach for nonpalpable undescended testes. In this approach, mobilization of the spermatic cord structures can be done under vision. Laparoscopic approach is also indicated for rare conditions, e.g., bilateral undescended testes, polyorchidism, transverse testicular ectopia.

Fowler-Stephens Orchidopexy

- Fowler-Stephens orchidopexy (one-stage or two-stage) is indicated for high intra-abdominal testes. This orchidopexy is now commonly performed laparoscopically.
- **In one-stage procedure**, spermatic vessels are clipped by laparoscopic approach followed by testicular mobilization (open or laparoscopic approach) in the same sitting. During dissection, collateral vessels between the spermatic vessels and the vas should be preserved.
- **In two-stage procedure**, spermatic vessels are clipped in the initial stage, then testicular mobilization 6 months after the primary procedure.

Complications of orchidopexy: (i) Testicular atrophy; (ii) Testicular ascent; and (iii) Vas deferens injury. **Modified Prentiss maneuver:** A method of testicular rerouting to gain adequate length for orchiopexy in high inguinal undescended testes (HIUT).

JAYPEE BROTHERS

Torsion of the Testis (Torsion of the Spermatic Cord)

Torsion of the testis is one of the common causes of **acute scrotum** and a **true surgical emergency**.

Predisposing Factors

- Bell-clapper deformity (abnormal proximal fixation of tunica vaginalis on the cord)—this deformity allows the testis to rotate and swing freely within the tunical vaginalis just like a 'clapper' inside the 'bell'
- Cryptorchidism

Pathophysiology

- When there is sudden contraction of cremasteric muscle (following trauma, athletic activity, physical activity) or even at sleep, twisting of the spermatic cord happens. This results in venous congestion with subsequent decrease in arterial flow to the testis that leads to necrosis.
- Spiral attachment of cremaster onto the cord favors rotation around a vertical axis (as much as 360°)

Clinical Presentation

- Most of the patients are around puberty, but torsion may develop at any age.
- Patients most commonly present with acute onset severe unilateral scrotal pain with nausea and vomiting. Clinical findings include **generalized testicular tenderness, high lie of the testis, absent cremasteric reflex**, thickening of the cord, scrotal edema.

Diagnosis

- If history and clinical findings are strongly suggestive of testicular torsion, patient should be referred for immediate surgical exploration. Imaging should not be planned in this scenario because imaging related delay decreases the testicular salvage rates and also chance of false-negative report.
- In pediatric patients (3 months to 18 years of age), **TWIST (Testicular Workup for Ischemia and Suspected Torsion), a clinically validated scoring system**, has been shown to have high positive predictive values.
- **US duplex Doppler** of the bilateral scrotum and inguinal area is the most appropriate imaging modality in suspected testicular torsion.

Management

- **If there is any doubt about diagnosis, the scrotum should be explored urgently.**
- On exploration, testis with good or marginal viability must be preserved and after detorsion, it must be placed in dartos pouch and fixed with fine, nonreactive, nonabsorbable suture.
- If necrotic testis is found, orchidectomy should be done.
- **Contralateral hemiscrotum must be explored and the testis must be fixed to reduce the risk of metachronous torsion.**

Causes of Acute Scrotum

- Torsion of testis
- Torsion of the appendix testis and epididymis
- Acute epididymitis
- Acute epididymo-orchitis
- Mumps orchitis
- Scrotal hematoma
- Incarcerated hernia
- Idiopathic scrotal edema
- Scrotal fat necrosis.

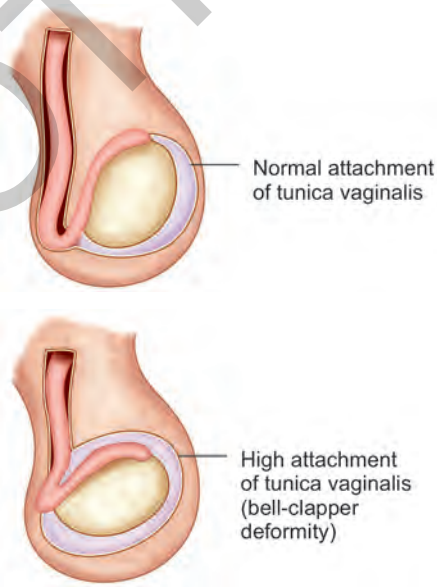

Cremasteric Reflex (Genitofemoral Reflex Arc)

- A superficial reflex in males. This reflex normally present after 2 years of age.
- This is elicited by scratching the inner thigh, causes elevation of the ipsilateral testis.
- The female counterpart of this reflex is Geigel reflex.

Two most important determinants of testicular salvage rate are:

(i) Time interval between onset of symptoms and detorsion.

(ii) Degree of cord twisting. If torsion is more than 360°, testis becomes non-viable within few hours (≥4 hours) of onset of torsion.

JAYPEE BROTHERS

TWIST Scoring System.

Criteria	Score
Testicular swelling	2
Hard testes	2
Absent cremasteric reflex	1
Nausea or vomiting	1
High riding testicle	1

- **Score 0-2:** Low-risk—100% negative predictive value for torsion; no USG or urological consultation required.
- **Score 3-4:** Intermediate-risk—USG warranted.
- **Score 5 or above:** High-risk—100% positive predictive value for torsion
- USG not required, urgent urological consultation and surgery required to salvage testicle.

Indications of Orchiectomy (Orchidectomy)

- **Unilateral simple orchiectomy—**for testicular torsion, trauma when testicular salvage is impossible; in postpubescent patients, particularly for abdominal testis or difficult to mobilize with contralateral normally descended testis.
- **Bilateral subcapsular orchiectomy—**in hormonally-responsive metastatic prostate cancer patients who like to avoid medical androgen deprivation therapy
- **Radical orchiectomy—**in suspected testicular cancer.
- **Bilateral simple orchiectomy—**in sex reassignment surgery.

Testicular Prosthesis

- Testicular prosthesis is a silicone implant, inflatable with normal saline, available in various sizes, i.e., Extra small, Small, Medium, and Large.
- The prosthesis can be implanted via scrotal, high-scrotal, and inguinal incision into the subdartos pouch.
- Complications are pain, discomfort, infection, extrusion, migration, implant deflation, fibrosis.

Torsion of the Appendix Testis and Epididymis

- **The most common cause of acute scrotum in prepubertal boys is appendage torsion** (torsion of the appendix testis and epididymis). This condition most commonly occurs in prepubertal age group (7–12 years), but may occur at any age.
- **Clinical presentations** are almost similar to torsion of testis or acute epididymo-orchitis. Pathognomonic **"blue dot sign"** (blue or purple discoloration at the upper pole of testis visible through stretched scrotal skin) is not so common. Other clinical findings include palpable nodule with localized tenderness at the upper pole of testis and intact cremasteric reflex. As the condition progresses, scrotal erythema and edema develops along with tenderness of testis and epididymis.
- **Color Doppler USG** rarely detects appendage torsion but shows hyperperfusion of the epididymis.
- **Treatment** includes scrotal support, ice pack, anti-inflammatory agents. Surgery is indicated only if testicular torsion cannot be excluded or if pain is prolonged or recurrent.

- **Appendix testis** is a vestigial remnant of the mullerian duct, present on the upper pole of the testis or in the groove between testis and epididymis.
- **Appendix epididymis** is a vestigial remnant of the wolffian duct, present along the caput.

JAYPEE BROTHERS

Acute Epididymitis

- Acute epididymitis is the most common cause of acute scrotal pain. It is commonly seen in patients 19 to 25 years of age.
- **Causative organisms:** (i) Sexually transmitted infections (e.g., *Chlamydia trachomatis*, *N. gonorrhoeae*, *M. genitalium*) and (ii) Enteric organisms (e.g., *Escherichia coli*)
- **Risk factors:** (i) Anal intercourse; (ii) Abnormalities of the lower urinary tract; and (iii) Urinary tract instrumentation, prostate biopsy
- **Clinical presentation:** Patients commonly present with gradual onset unilateral scrotal pain. History of urinary tract infection, urethral discharge, sexual activity, voiding difficulty may be present. Clinical findings include palpable swelling and tenderness of the epididymis, tender, and swollen spermatic cord. The pain may be relieved with the elevation of the testis **(Prehn's sign)**. As the condition progresses, scrotum becomes swollen and erythematous. Cremasteric reflex should be intact.
- **Diagnosis:** (i) Culture and sensitivity of mid-stream urine in all patients; (ii) Urethral swab or smear for gram staining and culture if *N. gonorrhoeae* is likely; (iii) Nucleic acid amplification test (NAAT) on first-voided urine for C. trachomatis and *N. gonorrhoeae* in patients with suspected sexually transmitted infections (STI); and (iv) Color Doppler USG should be done if any suspicion of testicular torsion.
- **Treatment:** (i) Scrotal support; (ii) Ice pack; (iii) Anti-inflammatory agents; and (iv) Antibiotics
- **Choice of antibiotics: (i) Patients with low risk of gonorrhoeae**—Doxycycline 200 mg initial dose then 100 mg twice daily for 10–14 days plus antibiotic active against Enterobacteriaceae for 10–14 days; **(ii) Patients with high risk of gonorrheal acute epididymitis**—Ceftriaxone 500 mg intramuscularly single dose plus Doxycycline 200 mg initial dose, then 100 mg twice daily for 10–14 days; and **(iii) Non-sexually active patients**—Fluoroquinolones (e.g., Levofloxacin 500 mg once daily for 10–14 days)

Varicocele

- Varicocele is abnormal dilation and tortuosity of internal spermatic veins in the pampiniform plexus of the spermatic cord. Most of the varicoceles are on left-side. Tall, thin men with pendulous scrotum are more frequently develop varicocele.
- **Pathophysiology:** Factors likely to be responsible are increased venous pressure in left renal vein, collateral venous anastomoses, incompetent valve at the junction of left internal spermatic vein and left renal vein. Genetic factors may also play some role.
- **Clinical presentation:** Most of the varicoceles are asymptomatic, detected during routine clinical examination or by the patient during self-examination. Clinical examination should be done in **both standing and supine position, with and without Valsalva maneuver.** Varicocele is typically described as painless compressible mass (consistency of a **"bag of worms"**) above the testis. Varicocele is not palpable when the patient is in supine position. If the veins do not decompress, retroperitoneal pathology or previous varicocele repair should be suspected. **Testicular volume should be assessed to detect testicular hypotrophy.**
- **Treatment:** Indications of surgery are: (i) Unilateral or bilateral varicocele with objective evidence of testicular hypotrophy; (ii) Varicocele with abnormal semen analysis findings; (iii) Symptomatic varicocele; and (iv) Bilateral palpable varicocele.

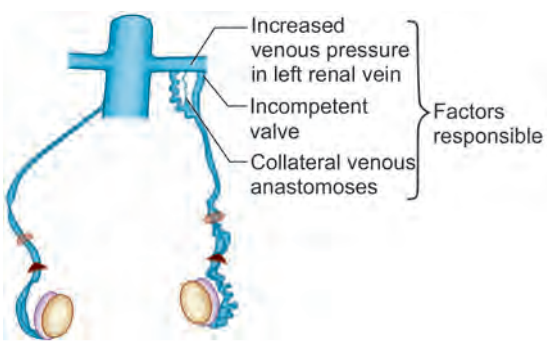

Clinical Grading of Varicocele

- **Grade 0 (subclinical)**—nonpalpable and visualized only by color Doppler USG
- **Grade 1**—palpable only with Valsalva maneuver
- **Grade 2**—easily palpable but not visible
- **Grade 3**—Easily visible

Measurement of Testicular Volume

- Prader orchidometer
- Takihara orchidometer
- Ultrasound

Testicular hypotrophy—Testis that is smaller by 2 mL or 20% to other testis.

JAYPEE BROTHERS

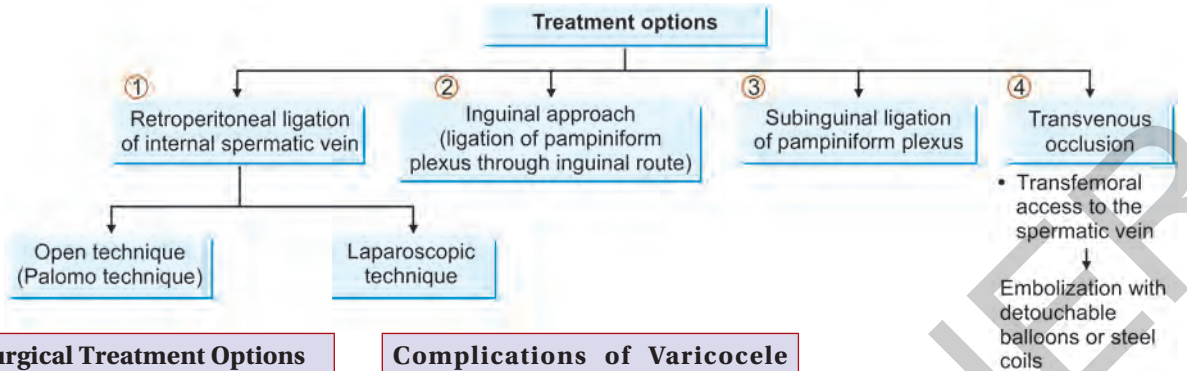

Nonsurgical Treatment Options

- Retrograde embolization
- Antegrade sclerotherapy
- Retrograde sclerotherapy

Complications of Varicocele Repair

- Recurrence
- Hydrocele
- Injury to the genitofemoral nerve

Complications of Sclerotherapy and Embolization

- Thrombophlebitis
- Venous perforation
- Retroperitoneal hemorrhage
- Migration of coils

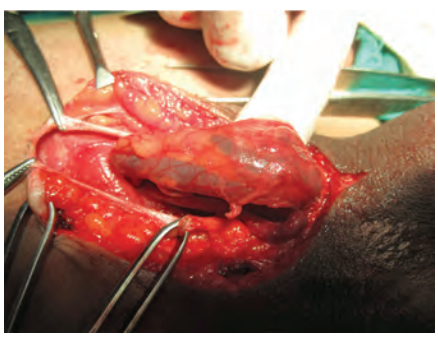

Inguinal Approach of Varicocele Repair

Hydrocele

Abnormal collection of fluid in tunica or processus vaginalis.

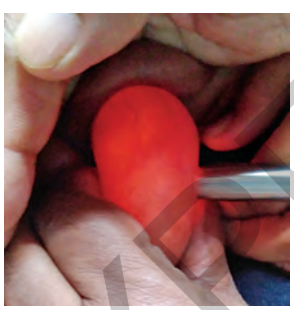

Congenital hydrocele—a transilluminant scrotal swelling.



Surgical approach for congenital hydrocele.

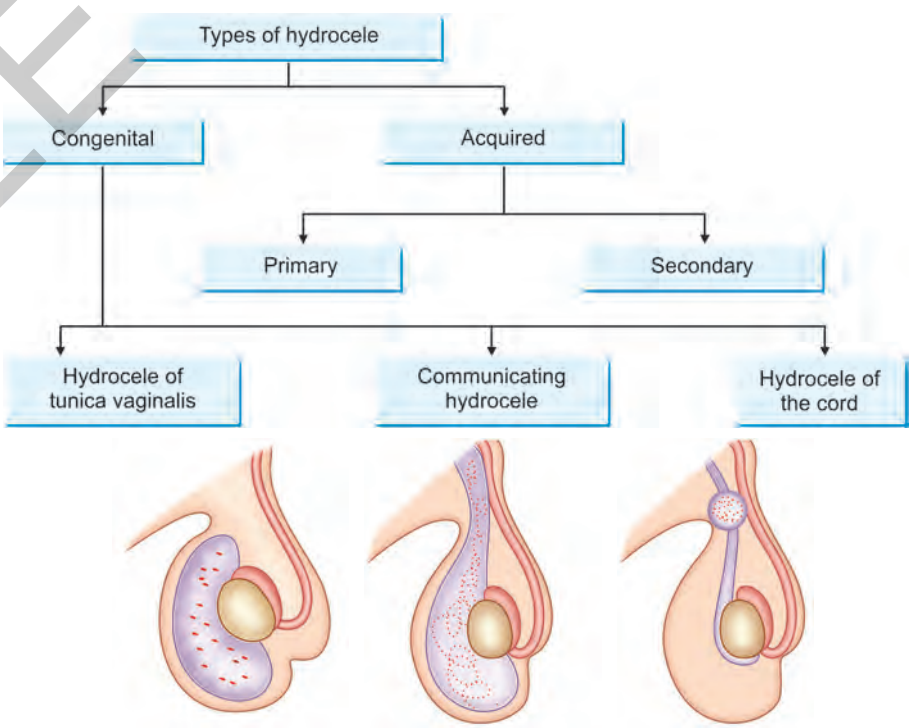

JAYPEE BROTHERS

Hydrocele of Tunica Vaginalis

- It develops due to delayed closure of processus vaginalis
- Fluid is trapped within the tunica vaginalis only
- Commonly seen at birth
- Tense, nontender pure scrotal swelling with positive transillumination test
- Most of them resolve within 2 years of life
- If surgical intervention is indicated it must be intervened through an inguinal approach

Communicating Hydrocele

- Persistence of processus vaginalis allows peritoneal fluid to communicate with the tunica vaginalis
- Classic description is that, the swelling is smaller in the morning and becomes more prominent as day progresses
- Communication is too small to allow herniation of intra-abdominal contents
- Most communicating hydroceles close spontaneously by 1 year of age
- All persistent communicating hydroceles must be explored through inguinal incision

Hydrocele of the Cord

- Due to segmental closure of processus vaginalis
- Manifested as painless groin swelling contiguous with the cord structures
- Can be palpated at any position just above the testis to superficial inguinal ring
- Swelling moves downwards and becomes less mobile when testis is pulled downwards
- Exploration must be done through inguinal approach. Ligation of the processus vaginalis at internal ring and excision or unroofing of the cyst is the treatment

Hydrocele of the Canal of Nuck

- It is the female counterpart of the hydrocele of the cord in males. Hydrocele of the canal of Nuck develops due to failure of obliteration of canal of Nuck.
- **There are three types of hydrocele of canal of Nuck:** (i) Encysted hydrocele (no communication with the peritoneal cavity); (ii) Hydrocele with persistent communication between peritoneal cavity and hydrocele; and (iii) Hour-glass type (constriction at deep inguinal ring so that proximal part is retroperitoneal and distal part is in the inguinal canal)
- **Clinical presentation:** Patient presents with painless irreducible translucent inguinolabial swelling.
- **Diagnosis:** USG or MRI is helpful for diagnosis but most of the patients are finally diagnosed after surgical exploration.
- **Treatment:** Surgical exploration followed by careful isolation of the cyst from the round ligament, excision of the cyst and high ligation of the hernial sac.

Canal of Nuck

- A pouch of parietal peritoneum accompanies the round ligament of uterus in the inguinal canal.
- It is analogs to processus vaginalis in males.

Hydrocele Fluid

- Amber colored
- Sterile
- Contains albumin and fibrinogen

Primary Vaginal Hydrocele

- Primary vaginal hydrocele is abnormal serous fluid collection between the parietal and visceral layer of tunica vaginalis. It is the most common cause of painless scrotal swelling. This hydrocele most commonly develops in middle aged or elderly men.
- **Pathophysiology:** Primary vaginal hydrocele develops due to defective absorption of fluid in tunica vaginalis (imbalance between secretion by mesothelial cells and absorption of fluid by lymphatics)
- **Clinical presentation:** Patients present with gradual onset painless scrotal swelling. Clinical examination reveals nontender scrotal swelling, 'get above the swelling' present, fluctuation and transillumination positive, testis cannot be felt separately.
- **Diagnosis:** Imaging is not indicated if the diagnosis of primary hydrocele is confirmed by history and clinical findings. Imaging is indicated if any suspicion of secondary hydrocele or other pathologies.
- **Treatment:** Surgery is the treatment of choice.

JAYPEE BROTHERS

for detailed information on surgery books, visit our website www.jaypeebrothers.com, for detailed information on surgery books, visit our website www.jaypeebrothers.com

Illustrated Surgery

A Basic Road Map for the Postgraduates

Salient Features

- Illustration-based discussion of pathology, pathophysiology of surgical diseases for better understanding
- Management based on recent guidelines
- Up-to-date information of surgical diseases collected from recent national and international guidelines, e.g., National Comprehensive Cancer Network (NCCN), American Thyroid Association (ATA), American College of Radiology (ACR), Society of American Gastrointestinal Endoscopic Surgeons (SAGES), etc.
- Case discussions at the end of each chapter
- New section containing 450+ Do's and 150+ Don'ts in Surgery
- Another section contains 'Important Classifications', 'Important Criteria', Important Terminologies and their Abbreviations', 'Important Trials', 'Important Scoring Systems' and 'Most Appropriate Investigations'. This section also includes 350+ important facts in surgery.

Nilay Mandal MS (General Surgery) is a Professor, Department of Surgery, Calcutta National Medical College and Hospital, Kolkata, West Bengal, India, has a teaching experience for over 14 years and has been both an undergraduate and postgraduate Examiner for the last few years. He has published articles in various national and international journals. He is also involved in editing postgraduate surgery and undergraduate surgery books.



Printed in India

Available at all medical bookstores or buy online at www.jaypeebrothers.com

JAYPEE BROTHERS
Medical Publishers (P) Ltd.
EMCA House, 23/23-B, Ansari Road,
Daryaganj, New Delhi - 110 002, INDIA
www.jaypeebrothers.com

Join us on facebook.com/JaypeeMedicalPublishers

Shelving Recommendation
SURGERY

ISBN 978-93-5696-705-2