rmation on mbbs books, visit our website www.jaypeebrothers.com, for detailed information on mbbs books, visit our website www.jaypeebrothers.com

Thoroughly Revised Multiple Choice Questions and Clinical Questions According to Latest Syllabus of NMC

Scan to Download the App
diginerve
A Jaypee Initiative
Your Guide at Every Step
Video Lectures | Notes | Self-Assessment

Mastering the MBBS 1st Year

Includes 2023 Papers



Last 10 Years Solved Questions | Also Covering NExT Pattern Questions

As per the Competency Based Medical Education Curriculum (NMC)

General Anatomy	Genetics
Neuroanatomy	Functional Anatomy
General Histology	Physiology
Embryology	Biochemistry
Osteology	AETCOM

Hemant Gupta

JAYPEE

Contents

Section 1: Anatomy

UPPER LIMB AND THORAX 3

1. Bones of Upper Limb 3
2. Pectoral Region 3
3. Axilla 6
4. Scapular Region 13
5. Arm 15
6. Forearm and Hand 18
7. Joints of Upper Limb 26
8. Introduction of Thorax 30
9. Bones and Joints of Thorax 32
10. Walls of Thorax 34
11. Thoracic Cavity and Pleurae 36
12. Lungs 37
13. Mediastinum 40
14. Pericardium and Heart 41
15. Superior Vena Cava, Aorta and Pulmonary Trunk 54
16. Trachea, Esophagus and Thoracic Duct 56

LOWER LIMB, ABDOMEN AND PELVIS 61

1. Front of Thigh 61
2. Medial Side of Thigh 68
3. Gluteal Region 68
4. Popliteal Fossa 73
5. Back of Thigh 74
6. Front of Leg with Dorsum of Foot; Lateral and Medial Sides of Leg 76
7. Back of Leg 77
8. Sole of Foot 79
9. Venous and Lymphatic Drainage; Segmental and the Sympathetic Innervation; Comparison of Upper and Lower Limbs 80
10. Joints of Lower Limb 83
11. Arches of Foot 92
12. Anterior Abdominal Wall 95
13. Male External Genital Organs 102
14. Abdominal Cavity and Peritoneum 105
15. Abdominal Part of Esophagus and Stomach 107
16. Small and Large Intestines 115
17. Large Blood Vessels of the Gut 120
18. Extrahepatic Biliary Apparatus 123
19. Spleen, Pancreas and Liver 127
20. Kidney and Ureter 135
21. Suprarenal Gland and Chromaffin System 141
22. Diaphragm 143
23. Posterior Abdominal Wall 143
24. Perineum 143
25. Urinary Bladder and Urethra 147
26. Female Reproductive Organs 153
27. Male Internal Genital Organs 164
28. Rectum and Anal Canal 167
29. Walls of Pelvis 170

HEAD AND NECK 171

1. Scalp, Temple and Face 171
2. Side of the Neck 174
3. Anterior Triangle of Neck 178
4. Parotid Region 181
5. Temporal and Infratemporal Regions 185
6. Submandibular Region 189
7. Structures in the Neck 191
8. Prevertebral and Paravertebral Region 196
9. The Cranial Cavity 197
10. Contents of the Orbit 199
11. Mouth and Pharynx 201
12. Nose, Paranasal Sinuses and Pterygopalatine Fossa 205
13. Larynx 211
14. The Tongue 214
15. Ear 219

NEUROANATOMY 222

1. Introduction 222
2. Meninges of Brain and Cerebrospinal Fluid 222
3. Cranial Nerves 222
4. Brainstem 228
5. Cerebellum 231
6. Cerebrum, Diencephalon, Basal Nuclei and White Matter 233
7. Third Ventricle, Lateral Ventricle and Limbic System 244
8. Fourth Ventricle 244
9. Blood Supply of Spinal Cord and Brain 246

Section 2: Osteology

1. Osteology 251

Section 3: Functional Anatomy

1. Skeleton 255
2. Joints 257
3. Muscles 261

Section 4: Embryology

1. Reproductive System, Gametogenesis, Ovarian and Menstrual Cycles 267
2. First Week of Development: Stages of Embryology/ Gestational Period 269
3. Second Week of Development: Bilaminar Germ Disc Formation 271
4. Third Week of Development: Germinal Period 273
5. Placenta, Fetal Membranes and Twinning 278
6. Branchial Apparatus (Pharyngeal Arches + Endodermal Pouches + Endodermal Clefts) 279
7. Face, Nose and Palate 280
8. Alimentary System II: Gastrointestinal Tract 287
9. Cardiovascular System 288
10. Urogenital System 290
11. Nervous System 298
12. Endocrine Glands 299

Section 5: Histology

1. Epithelia and Glands 303
2. Cartilage 303
3. Lymphatics and Lymphoid Tissue 304
4. Cardiovascular System 306
5. Skin and its Appendages 307
6. Salivary Glands 309
7. Respiratory System 309
8. Digestive System: Oral Cavity and Related Structures 311
9. Gastrointestinal Tract, Stomach and Intestines 312
10. Hepatobiliary System and Pancreas 313
11. Urinary System 315
12. Spinal Cord, Cerebellar Cortex and Cerebral Cortex 318
13. Male Reproductive System 320
14. Female Reproductive System 321
15. Endocrine System 321
16. Special Senses 325

Section 6: Genetics

1. Chromosomes and their Classification 331
2. Chromosomal Anomalies 332
3. Patterns of Inheritance 335

Section 7: Physiology

1. General Physiology 357
2. Blood and Body Fluids 370
3. Nerve Muscle Physiology 393
4. Digestive System 403
5. Cardiovascular System 418
6. Respiratory System and Environmental Physiology 444
7. Excretory System 468
8. Endocrine System 479
9. Reproductive System 505
10. Nervous System 516
11. Special Senses 560
12. Integrated Physiology 576

Section 8: Biochemistry

1. Biomolecules and the Cell 603
2. Chemistry of Carbohydrates 604
3. Chemistry of Lipids 606
4. Proteins and Amino Acids 609
5. Nucleic Acids and Nucleotides 614
6. Enzymes and Cardiac Markers 618
7. Vitamins 631
8. Plasma Proteins 640
9. Hemoglobin, Porphyrins and Jaundice 642
10. Biological Oxidation 656
11. Metabolism of Carbohydrates 663
12. Metabolism of Lipids 679
13. Metabolism of Amino Acids 700
14. Metabolism of Nucleotides 713
15. Mineral Metabolism 723
16. Hormones 730
17. Organ Function Tests 735
18. Water, Electrolyte and Acid-Base Balance 749
19. Nutrition 763
20. DNA—Replication, Recombination and Repair 770
21. Transcription and Translation 781
22. Regulation of Gene Expression 799
23. Recombinant DNA and Biotechnology 801
24. Gene Therapy 807
25. Metabolism of Xenobiotics (Detoxification) 808
26. Prostaglandins and the Related Compounds 811
27. Biological Membranes and Transport 813
28. Free Radicals and Antioxidants 817
29. Environmental Biochemistry 821
30. Insulin, Glucose Homeostasis, Diabetes Mellitus and Starvation 823
31. Cancer 832
32. Overview of Biophysical Chemistry 837
33. Tools of Biochemistry 838
34. Immunology 844

Section 9: Attitude, Ethics and Communication (AETCOM)

1. What does it Meant to be a Doctor? 873
2. Doctor-Patient Relationship 875
3. Cadaver as Our First Teacher 879

ANATOMY

UPPER LIMB AND THORAX

1. BONES OF UPPER LIMB

Q.1. Write very short answer on glenoid labrum.
(Aug 2019, 1 Mark)

Ans. The glenoid labrum is fibrocartilaginous tissue within the glenoid cavity of the shoulder joint. The purpose of the glenoid labrum is to provide stability and shock absorption within the joint.

Q.2. Write short answer on winging of scapula.
(July 2023, 2 Marks) (Feb 2023, 2 Marks)

Ans. Paralysis of the serratus anterior muscle leads to the 'winging' of scapula. Here, both inferior angle and medial border of scapula bone get unduly prominent due to which the arm should not be abducted beyond 90°.

Due to winging patient is unable to perform any of the pushing action, nor the patient is able to raise his arm above head. If the patient tries to attempt such movements, this makes inferior angle of scapula more prominent.

Causes

Following are the causes which lead to injury to serratus anterior muscle:

- Due to the application of sudden pressure on shoulder arm from above.
- While carrying heavy loads on shoulder.

Clinical testing: Applying the forward pressure with hands against the wall, or against the resistance which is offered by an examiner, leads to the medial border and inferior angle of scapula prominent, i.e., winging of scapula, if serratus anterior muscle get paralyzed.



Fig. 1: Winging of scapula.

2. PECTORAL REGION

Q.1. Describe the mammary gland under the following headings: *(Apr 2020, 10 Marks)*

A. Extent and relations **B. Blood supply**
C. Lymphatic drainage **D. Applied anatomy**

Ans.

Extent

- **Vertically:** It is extended from 2nd rib to 6th rib.
- **Horizontally:** It is extended from lateral border of the sternum to the midaxillary line.

Relations/Deep Relations

Deep surface of breast is related to following structures:

- Breast lies on deep fascia (pectoral fascia) covering the pectoralis major muscle.
- More deeply it consists of parts of three muscles viz the pectoralis major, the serratus anterior, and the external oblique muscle of abdomen.
- Breast got separated from pectoral fascia by the loose areolar tissue known as retromammary space. Due to the presence of this loose tissue, normal breast can be moved freely over pectoralis major muscle.

Blood Supply

Mammary gland is extremely vascular and is supplied by the branches of following arteries:

- Internal thoracic artery which is the branch of subclavian artery, from its perforating branches.
- Lateral thoracic, superior thoracic and acromiothoracic (thoracoacromial) branches of the axillary artery.
- Lateral branches of posterior intercostal arteries.

Arteries converge on breast and get distributed from anterior surface. Posterior surface is relatively avascular.

Veins follow the arteries. Veins first converge towards base of nipple where they form anastomotic venous circle, from where veins run in two sets, i.e., superficial and deep sets.

- Superficial veins drain in internal thoracic vein and in superficial veins of lower part of neck.
- Deep veins drain in axillary and the posterior intercostal veins.

JAYPEE BROTHERS

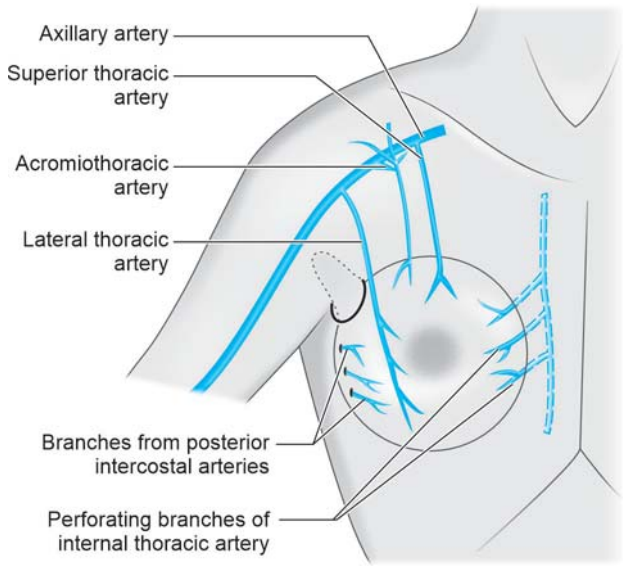

Fig. 2: Arterial supply of mammary gland.

Lymphatic Drainage

For details refer to Ans 2 of same chapter.

Applied Anatomy

Upper and the outer quadrant of breast is the common site of carcinoma (cancer). First lymph node which drains tumor bearing region is known as 'sentinel node.' Abscesses may also form inside the breast and can need drainage. The following facts are important:

- Incisions of breast are given radially to avoid cutting of lactiferous ducts.
- Cancer cells may infiltrate suspensory ligaments. Breast then gets fixed. Contraction of ligaments can than leads to retraction or puckering of skin.
- Infiltration of lactiferous ducts as well as their consequent fibrosis can lead to retraction of nipple.
- Obstruction of superficial lymph vessels due to cancer cells can cause edema of skin which give rise to an appearance like that of skin of an orange (*peau d'orange* appearance).
- Due to the communications of superficial lymphatics of breast across midline, cancer cells can spread from one breast to another.
- Due to the communications of lymph vessels along with those in abdomen, cancer of breast may be spreaded to the liver, and cancer cells may 'drop' in the pelvis producing the secondaries there.
- Besides lymphatics, cancer can be spread through segmental veins. Here the veins which are draining to breast communicate with the vertebral venous plexus of veins. Through these communications, cancer can spread to vertebrae and to brain.
- Carcinoma of breast mainly arises from epithelium of large ducts.
- **Self-examination of breasts:**
  - Inspection of the symmetry of breasts and nipples is done.
  - Change in color of skin should be observed.
  - If there is retraction of nipple present, it is a sign of cancer.
  - If there is discharge from nipple while squeezing it.
  - Palpate for all four quadrants of breast with the palm of hand. Note if there is presence of any palpable lump.
  - Raise arm to feel the lymph nodes in axilla.

Self-examination of mammary gland is considered to be the only way for early diagnosis and proper treatment.

- Mammogram may reveal cancerous mass.
- Fine needle aspiration cytology is considered to be the safe as well as quick method of diagnosis of the lesion of breast.
- Size of mammary gland can be increased by placing an implant inside the mammary gland while the size can be decreased by breast reduction surgery.
- Cancer of mammary glands is most common cancer in the females of all the ages. It is more frequently seen in the post-menopausal females because of lack of estrogen hormones.
- The medical term for the surgical removal of one or both breasts, partially or completely is known as mastectomy. Mastectomy is done for treating breast cancer. Lumpectomy is only the removal of tumor.
- Surgical procedure which involves the removal of breast which underlie pectoral muscles and lymph nodes of axilla is known as radical mastectomy. This is the treatment for advanced breast cancer.

Q.2. Write short answer on lymphatic drainage of breast. *(Apr 2018, 3 Marks)*

Write brief answer on lymphatic drainage of mammary gland. *(May 2013, 4 Marks)*

Or

Write brief answer on lymphatic drainage of breast. *(Jan 2012, 4 Marks)*

Ans. Lymphatic drainage of breast is divided into two categories, i.e., lymph nodes and lymphatic vessels.

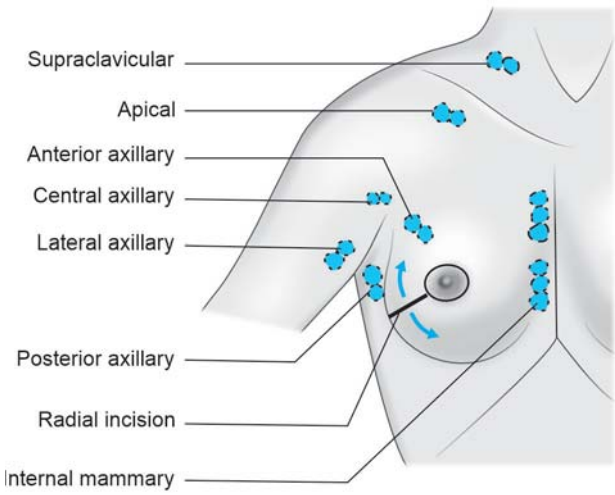

Fig. 3: Lymph nodes draining the breast.

JAYPEE BROTHERS

Lymph Nodes

Lymph from breast drains mainly in:

- Axillary lymph nodes mainly the anterior group. Posterior, lateral, central and apical groups also receive lymph from breast which is either directly or indirectly.
- Anterior thoracic nodes which lie along internal mammary vessels.
- Some lymph from breast also reaches to supraclavicular nodes, cephalic nodes, posterior intercostal node, subdiaphragmatic and subperitoneal lymph plexuses.

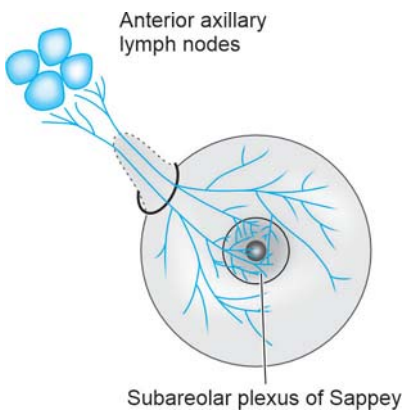

Fig. 4: Subareolar plexus of Sappey.

Lymphatic Drainage

- Superficial lymphatics drains the skin over breast except areola and nipple. Lymphatics pass radially to surrounding lymph nodes, i.e., axillary, anterior thoracic, supraclavicular and cephalic.
- Deep lymphatics drain parenchyma, nipple and areola.
- 75% of lymph from the breast drains into axillary nodes; 20% to parasternal lymph nodes and 5% to posterior intercostal nodes. Among axillary lymph nodes lymphatics ends in anterior group and partly in posterior and apical groups. Lymph from anterior and posterior groups pass from central and lateral groups and via them to apical group. Lastly it reaches supraclavicular lymph nodes.
- Anterior thoracic nodes drain lymph not only from the inner half of the breast but also from outer half.
- Subareolar plexus of Sappey and most of lymph from breast drains to anterior or pectoral group of lymph nodes.
- Lymphatics from deep surface of the gland pass via pectoralis major muscle and clavipectoral fascia to reach apical lymph nodes and to anterior thoracic nodes.
- Lymphatics from lower and inner quadrants of the breast may communicate with subdiaphragmatic and subperitoneal lymph plexuses.
- Anterior and the central group of nodes are very commonly involved in breast carcinoma.

Q.3. Write brief answer on clavipectoral fascia.
(Jan 2013, 4 Marks)

Or

Write very short answer on structures piercing clavipectoral fascia. *(Apr 2018, 1 Mark)*

Ans. It is a fibrous sheet which is situated deep to clavicular portion of pectoralis major muscle.

It extends from clavicle above to axillary fascia below.

- Upper part of the fascia splits to enclose *subclavius muscle.*
- Posterior lamina gets fused to investing layer of deep cervical fascia and to *axillary sheath.*
- Inferiorly, clavipectoral fascia get splits to enclose pectoralis minor muscle.
- Medially, it remains attached to the external intercostal muscle of upper intercostal spaces and laterally to coracoid process.
- Below intercostal muscle, it become continues as *suspensory ligament* which is attached to dome of axillary fascia, and helps to maintain it.

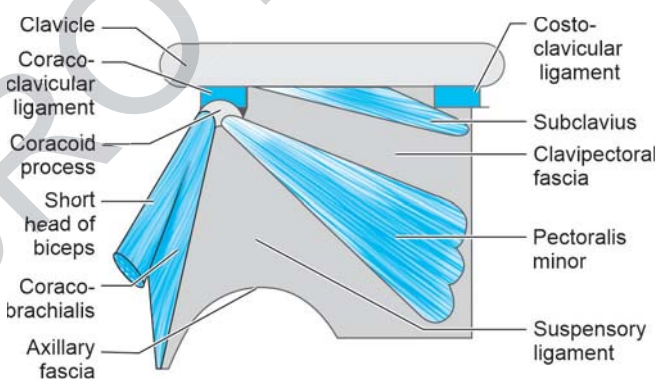

Fig. 5: Clavipectoral fascia.

Structures Piercing Clavipectoral Fascia

Clavipectoral fascia is pierced by:

- Lateral pectoral nerve
- Cephalic vein
- Thoracoacromial vessels.
- Lymphatics passing from breast and pectoral region to apical group of axillary lymph nodes.

Q.4. Name the artery piercing the clavipectoral fascia.
(Aug/Sep 2016, 1 Mark)

Ans. Thoracoacromial artery pierces the clavipectoral fascia.

Q.5. Describe structure, deep relations, blood supply, lymphatic drainage and applied anatomy of breast.
(Feb 2023, 20 Marks)

Ans.

Structure of Breast

Structure of breast is divided into skin, parenchyma and stroma. Parenchyma is called as mammary gland.

JAYPEE BROTHERS

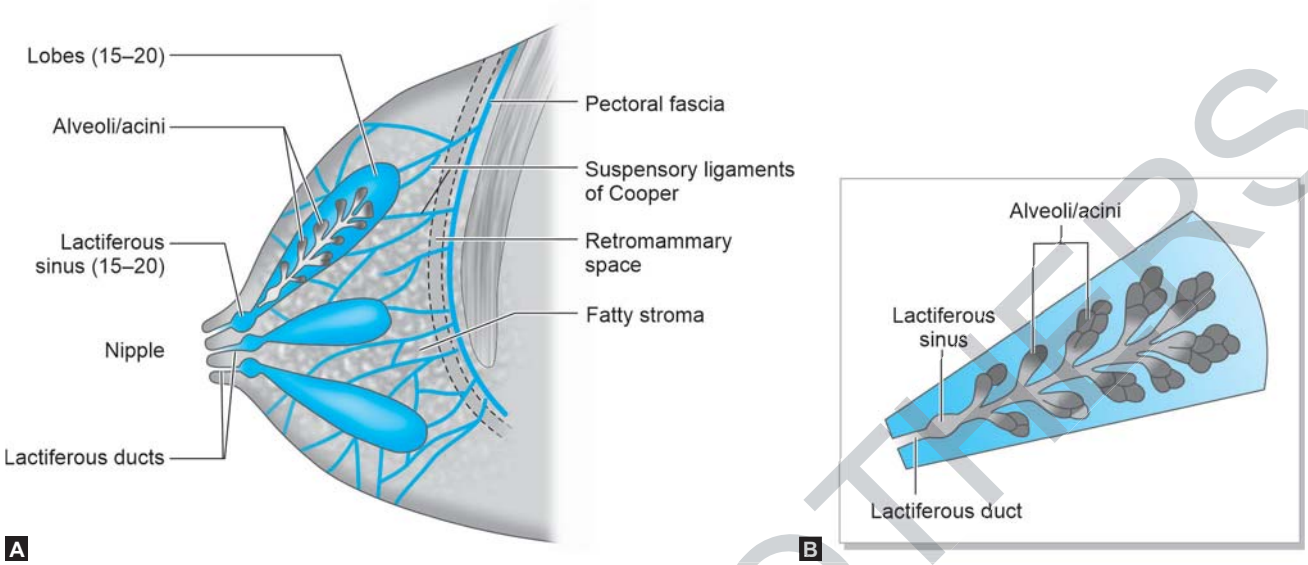

Figs. 6A and B: (A) Suspensory ligament of breast and its lobes; (B) Structure of single lobe of mammary gland.

Skin

Skin provides coverage to gland and represents the following features. Conical projection is known as the *nipple* and this lies below the center of breast at the level of fourth intercostal space which is usually 10 cm from midline. Nipple gets pierced by the 15–20 lactiferous ducts. It has both circular and the longitudinal smooth muscle fibers which make the nipple stiff or allow it to get flatten. It consists of few of the modified sweat and the sebaceous glands. Skin remains rich in the nerve supply and consists of many of the sensory end organs where the termination of the nerve fibers occurs.

- Base of the nipple is surrounding by skin which remains pigmented and forms the circular area which is known as *areola*. Areola consists of numerous modified *sebaceous glands* which lie at outer margin. These modified sebaceous glands get enlarged at the time of pregnancy and lactation to form the raised *tubercles of Montgomery*. Oily secretions from these modified glands provide lubricate to both nipple and areola, and this prevent these both from cracking at the time of lactation. Areola also consists of some of the sweat glands as well as the accessory mammary glands. Skin of areola and of nipple does not consist of hair, and there is absence of the fat subjacent to it. Below areola lactiferous sinus is present where the stored milk is present.

Parenchyma (Mammary Gland)

- Mammary gland is chiefly a compound tubuloalveolar gland which leads to the secretion of the milk. As this gland is located lies in superficial fascia, there is absence of capsule.
- Mammary gland is basically a modified sweat gland and it has 15–20 lobes.
- Each of the lobe is cluster of alveoli, and this should be drained by the lactiferous duct.
- Lactiferous ducts undergo convergence towards nipple and they open on it. Near to its termination, each of the duct consists of the dilatation which is known as *lactiferous sinus.*

Stroma

- This lead to the formation of supporting framework of mammary gland.
- Stroma is partly fibrous and it is partly fatty.
- Fibrous stroma forms the septa which are called as suspensory ligaments of Cooper, function of which is *to* anchor both skin and gland to pectoral fascia.
- Fatty stroma here leads to the formation of main bulk of gland. This is distributed all over breast, except beneath areola and nipple.

For deep relations, blood supply and applied anatomy refer to Ans 1 of same chapter.

For lymphatic drainage refer to Ans 2 of same chapter.

3. AXILLA

Q.1. Describe brachial plexus with its applied anatomy. *(Aug 2019, 5 Marks)*

Or

Write short answer on brachial plexus (only diagram). *(Apr 2018, 3 Marks)*

Or

Write short answer on anatomical basis of Erb's paralysis. *(May 2017, 4 Marks)*

Or

Describe the formation and branches of brachial plexus. *(Aug 2015, 5 Marks)*

Or

JAYPEE BROTHERS

Write short answer on Klumpke's paralysis. *(June 2016, 4 Marks)*

Or

Describe brachial plexus in detail. *(May 2015, 8 Marks)*

Or

Write brief answer on anatomical basis of Erb's paralysis. *(Jan 2012, 4 Marks)*

Or

Write brief answer on brachial plexus. *(Dec 2022, 5 Marks)*

Ans.

Formation of Brachial Plexus

The brachial plexus consist of roots, trunks, divisions, cords and branches.

1. **Roots**
   - Roots are constituted by anterior primary rami of spinal nerves C5, C6, C7, C8 and T1, with contributions from anterior primary rami of C4 and T2.
   - Origin of plexus may shift by one segment either upward or downward, resulting in prefixed or postfixed plexus.
   - In prefixed plexus, contribution by C4 is large and that form T2 is often absent.
   - In postfixed plexus, contribution by T1 is large, T2 is always present, C4 is absent and C5 is reduced in size. Roots join to form trunk.
2. **Trunks—supraclavicular part**
   - Roots C5 and C6 join to form the upper trunk.
   - Roots C7 forms the middle trunk.
   - Roots C8 and T1 joins to form the lower trunk.
3. **Divisions of the trunks—retroclavicular part:** Each trunk divides into ventral and dorsal divisions. These divisions join to form cords.
4. **Cords and branches—infraclavicular part:**
   - Lateral cord is formed by the union of the ventral division of the upper and the middle trunks.

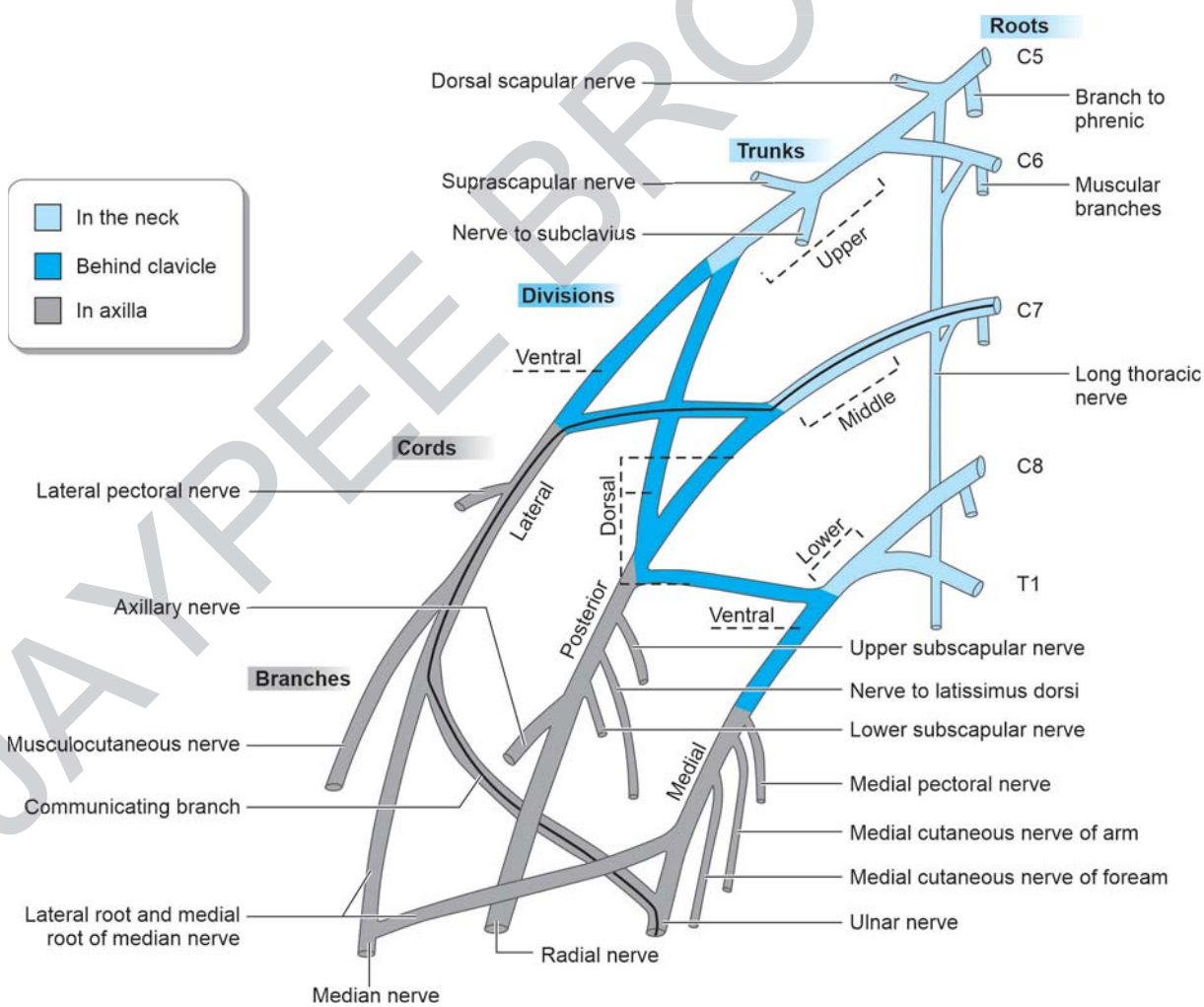

Fig. 7: Brachial plexus.

JAYPEE BROTHERS

- Medial cord is formed by the ventral division of the lower trunk.
- Posterior cord is formed by the union of dorsal division of all the three trunks.

5. **Sympathetic innervation**
   - Sympathetic nerves for upper limb are derived from the spinal segments T2 to T6. Most of the vasoconstrictor fibers which supply arteries emerge from the segments T2 and T3.
   - Preganglionic fibers originate from the lateral horn cells and they emerges from spinal cord through ventral nerve roots.
   - Passing through white rami communicantes, the fibers reach to sympathetic chain.
   - These fibers ascend in the chain and they end in middle cervical, inferior cervical and first thoracic ganglia.
   - Postganglionic fibers from the middle cervical ganglion pass through the gray rami communicants to reach the C5 and C6 nerve roots.
   - Postganglionic fibers from the inferior cervical ganglion pass through gray rami communicants to reach to the C7 and C8 nerve roots.
   - Postganglionic fibers from first thoracic sympathetic ganglion pass through gray rami communicants to reach the T1 nerve roots.
   - Arteries of the skeletal muscles get dilated by the sympathetic activity. For skin, these nerves are considered to be vasomotor, sudomotor and pilomotor.

     Vasomotor: It constricts arterioles of skin.

     Sudomotor: This increases sweat secretion.

     Pilomotor: They contract the arrector pilorum muscle to produce the erection of hair.

Branches of Brachial Plexus

Branches of the Root

1. Nerve to serratus anterior (C5, C6, C7): This only supply serratus anterior muscle.
2. Nerve to rhomboids (C5): It supply rhomboid minor and rhomboid major muscles which causes retraction of shoulder girdle and provide a branch to levator scapulae.
3. Branches to longus colli and scaleni muscles (C5–C8) and branch to phrenic nerve (C4). Root of the phrenic nerve from C5 is the small one while the main root is from C4.

Branches of the Trunk

These arises only from the upper trunk. It gives two branches:

1. **Suprascapular nerve (C5, C6):** It supply to supraspinatus and infraspinatus muscles.
2. **Nerve to subclavius (C5, C6):** It supply to small subclavius muscle. It may provide root for phrenic nerve.

Branches of the Cords

1. Branches of the lateral cord
   a. *Lateral pectoral (C5–C7):* It supply to both pectoralis major and pectoralis minor muscle.
   b. *Musculocutaneous (C5–C7):* It supplies to coracobrachialis both long and short heads of biceps brachii and brachialis muscles.
   c. *Lateral root of median (C5–C7):* It join medial root of median nerve. Median nerve is the main nerve of muscles of front of forearm and muscles of thenar eminence.
2. Branches of medial cord
   a. *Medial pectoral (C8, T1):* It supply to both pectoralis major and pectoralis minor muscle.
   b. *Medial cutaneous nerve of arm (C8, T1):* It carries sensory impulses from small area of medial side of arm.
   c. *Medial cutaneous nerve of forearm (C8, T1):* It carries sensory impulses from large area of medial side of arm.
   d. *Ulnar (C7, C8, T1):* C7 fibers reach by communicating branch from lateral root of median nerve.
   e. *Medial root of median (C8, T1):* It leads to the joining of lateral root and is distributed with the branches of median nerve.
3. Branches of posterior cord
   a. *Upper subscapular (C5, C6):* It supplies the large multipennate subscapularis muscles.
   b. *Nerve to latissimus dorsi (C6, C7, C8):* It supply only the muscles of its name. It is also known as thoracodorsal nerve.
   c. *Lower subscapular (C5, C6):* It assists the upper subscapular nerve to supply subscapularis muscles. It also supply teres major muscle.
   d. *Axillary (C5, C6):* It supplies to deltoid muscle and also to small teres minor muscle.
   e. *Radial (C5–C8, T1):* It is the thickest branch of brachial plexus. All the three heads of triceps brachii muscle are supplied by this nerve along with 12 muscles of back of forearm.

Additionally in relation to the branches of brachial plexus, upper limb is also supplied near to trunk by supraclavicular branches of cervical plexus and also by intercostobrachial branch of second intercostal nerve. Sympathetic nerves get distributed through brachial plexus.

Special Features

- Lateral cord, medial cord along with their branches lead to the formation of letter 'M' with three corners extended.
- Lateral cord provides the musculocutaneous and lateral root of median.
- Medial cord provides the ulnar and the medial root of median.
- Lateral and the medial roots of the median nerve combine to form median nerve.

Blood Supply of Brachial Plexus

Vertebral artery and the thyrocervical trunk along with its branches, suprascapular and the transverse cervical arteries, supply blood to brachial plexus.

Applied Anatomy

Global total brachial plexus birth baby is considered to be the most severe type of the paralysis.

JAYPEE BROTHERS

Erb's Paralysis

Injury to the upper trunk of brachial plexus leads to Erb's paralysis.

In Erb's paralysis arm cannot be abducted. Elbow is extended and forearm is pronated. This is Erb's paralysis.

Causes of Injury

It is because of undue separation of head from shoulder, which is encountered during:

1. Birth injury
2. Fall on shoulder
3. During anesthesia.

Nerve Roots Involved

Mainly C5 and partially C6 nerve roots are involved.

Muscle Paralyzed

- Mainly biceps brachii, deltoid, brachialis and brachioradialis muscles get paralyzed.
- Partially supraspinatus, infraspinatus and supinator get paralyzed.

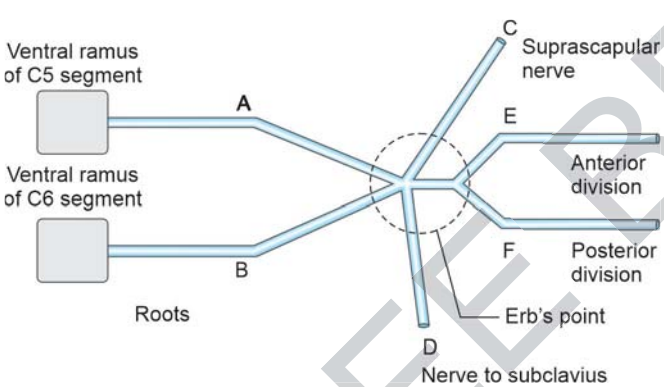

Fig. 8: Erb's paralysis.

Deformity and Position of Limb

Arm: It hangs by side, it is adducted and medially rotated.

Forearm: It remains extended and pronated.

The deformity is also known as "policeman's tip hand" or "Porter's tip hand".

Disability

The following movements become lost:

1. Abduction and the lateral rotation of arm at shoulder joint.
2. Flexion and the supination of forearm.
3. Biceps and supinator jerks become lost.
4. Sensations are lost over a small area in lower part of deltoid.

Klumpke's Paralysis

Site of injury: It is the lower trunk of brachial plexus.

Cause of injury: Due to undue abduction of arm, as carried out in clutching something with hands after fall from the height, or sometimes during birth injury.

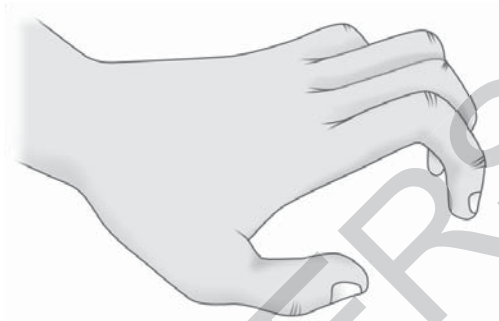

Fig. 9: Claw hand.

Nerve roots involved: Mainly T1 and partly C8 nerve roots get involved.

Muscles paralyzed: Intrinsic muscles of the hand (T1) and ulnar flexors of the wrist and fingers (C8) are the muscles which get paralyzed.

Deformity and position of the hand: There is presence of claw hand because of the unopposed action of long flexors and extensors of fingers. There is presence of hyperextension at metacarpophalangeal joints and flexion at interphalangeal joints in the claw hand.

Disability:

- Presence of complete claw hand.
- Presence of the cutaneous anesthesia and also analgesia in a narrow zone along with the ulnar border of forearm and the hand.
- **Horner's syndrome:** If T1 get injured proximal to the *white ramus communicans* to the first thoracic sympathetic ganglion, there is presence of following symptoms such as ptosis, miosis, anhydrosis, enophthalmos and loss of the ciliospinal reflex—may be present. This is due to the injury to the sympathetic fibers to head and neck which leave spinal cord through nerve T1.
- **Vasomotor changes:** Skin area present with the sensory loss is warmer because of arteriolar dilation. This remains dry because of absence of sweating as there is presence of loss of the sympathetic activity.
- **Trophic changes:** In the long-standing case of the paralysis there is presence of dry and the scaly skin. Nails crack easily along with the atrophy of the pulp of fingers.

Injury to the Nerve to Serratus Anterior (Nerve of Bell)

Causes

This occur because of:

- Sudden pressure present on shoulder from the above.
- Carrying the heavy loads on shoulder.

Deformity: There is presence of winging of scapula.

Disability:

- There is presence of loss of both pushing and the punching actions. If person attempts at pushing, there is presence of winging of scapula.
- Overhead abduction of the shoulder girdle gets partly affected because of presence of intact trapezius muscle.

JAYPEE BROTHERS

Q.2. Write short answer on axillary artery.
(Aug 2019, 3 Marks)

Or

Describe the relations of 1st, 2nd and 3rd part of axillary artery and its applied anatomy.
(Dec 2022, 20 Marks)

Ans. It is the continuation of subclavian artery.

Extent

Axillary artery extends from outer border of first rib to lower border of teres major muscle where it remain continues as brachial artery. Direction of the artery varies with position of arm.

Divisions

Pectoralis minor muscle crosses the axillary artery and consecutively divides it into three parts viz:

- First part is superior or proximal to pectoralis minor muscle.
- Second part is posterior or deep to pectoralis minor muscle.
- Third part is inferior or distal to pectoralis minor muscle.

Relations of Axillary Artery

Relations of First Part

- **Anteriorly:** Skin, superficial fascia, platysma and supraclavicular nerves, deep fascia, clavicular part of pectoralis major muscle; clavipectoral fascia with the cephalic vein, lateral pectoral nerve, and thoracoacromial artery; loop of communication between lateral and medial pectoral nerves.
- **Posteriorly:** First intercostal space with the external intercostal muscle, first and second digitations of serratus anterior along with the nerve to serratus anterior, medial cord of brachial plexus with its medial pectoral branch.
- **Laterally:** Lateral and posterior cords of brachial plexus.
- **Medially:** The axillary vein—first part of axillary artery gets enclosed along with the brachial plexus in axillary sheath which is derived from prevertebral layer of deep cervical fascia.

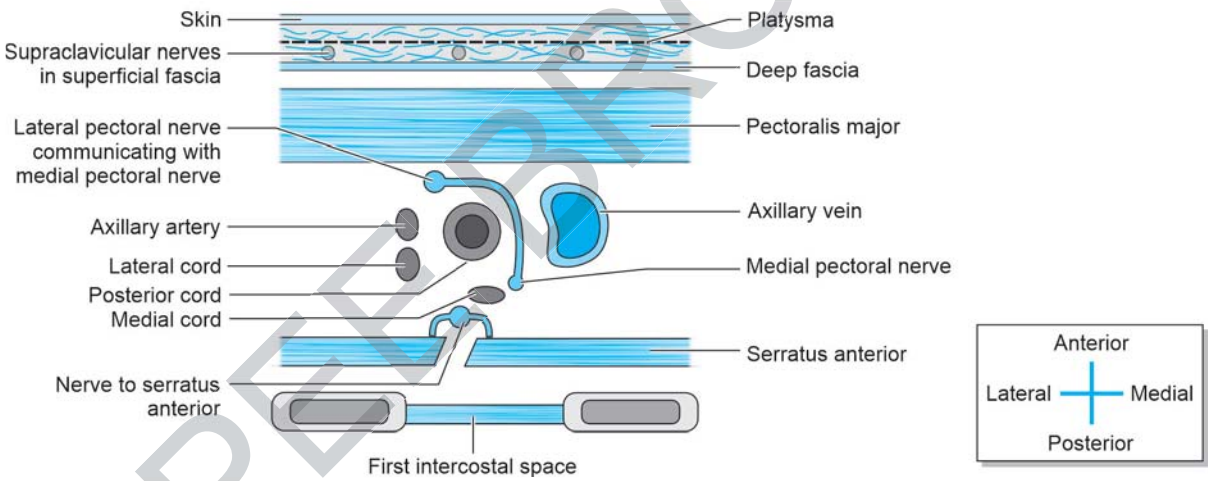

Fig. 10: Relations of first part of axillary artery.

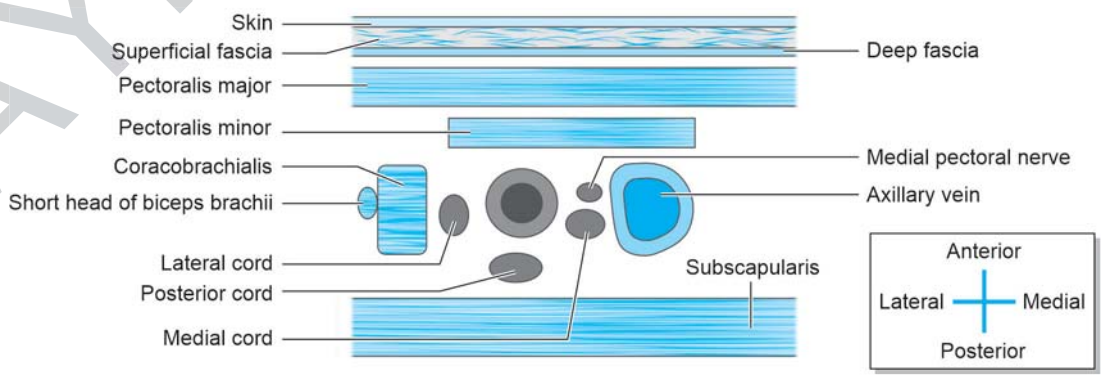

Fig. 11: Relations of second part of axillary artery.

JAYPEE BROTHERS

Relations of Second Part

- **Anteriorly:** Skin, superficial fascia, deep fascia, pectoralis major, pectoralis minor
- **Posteriorly:** Posterior cord of brachial plexus, subscapularis
- **Laterally:** Lateral cord of brachial plexus, coracobrachialis
- **Medially:** Medial cord of brachial plexus, medial pectoral nerve and axillary vein

Relations of Third Part

- **Anteriorly:** Skin, superficial fascia, deep fascia, in upper part there are pectoralis major and medial root of median nerve.
- **Posteriorly:** Radial nerve, in upper part there is axillary nerve, in upper part there is subscapularis, tendons of latissimus dorsi and teres major in lower part.
- **Laterally:** Coracobrachialis, musculocutaneous nerve in upper part, lateral root of median nerve in upper part, trunk of median nerve in lower part.
- **Medially:** Axillary vein, medial cutaneous nerve of forearm and ulnar nerve in between the axillary artery and axillary vein, medial cutaneous nerve of arm which is medial to axillary vein.

Branches

Axillary artery gives off six branches:

- One branch arise from first part
- Two of the branches arise from second part
- Three branches arise from third part.

Following is the description of all the branches

Superior Thoracic Artery

It is a very small branch which originates from first part of axillary artery. Superior thoracic artery runs downwards, forwards and medially and it passes in between two pectoral muscles and terminates by supplying these two pectoral muscles and thoracic wall.

Thoracoacromial (Acromiothoracic) Artery

This is a branch from second part of axillary artery. Thoracoacromial artery emerges at upper border of pectoralis minor, it pierces clavipectoral fascia and now soon divides into the following four terminal branches viz:

- **Pectoral branch** passes in between the pectoral muscles and it supplies these pectoral muscles and the breast.
- **Deltoid branch** runs in deltopectoral groove along with cephalic vein.

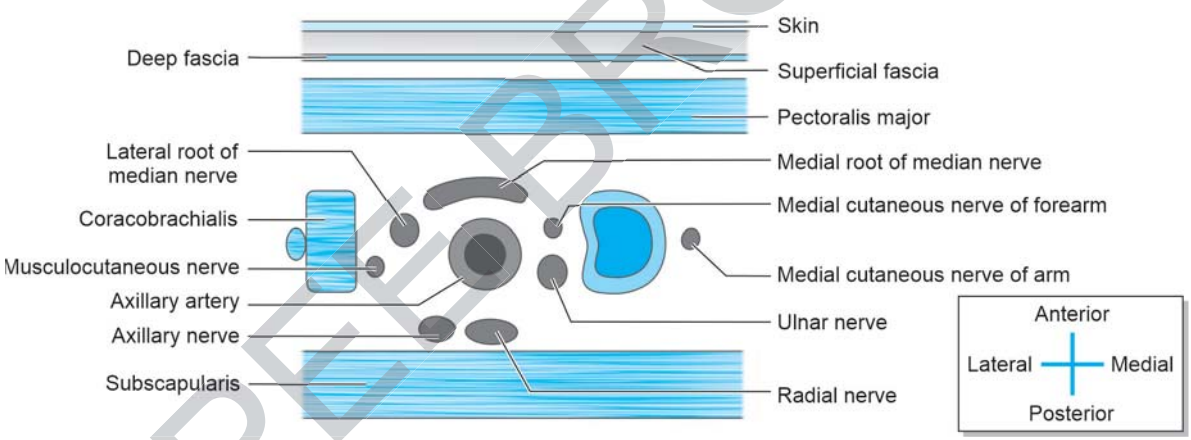

Fig. 12: Relations of third part of axillary artery (proximal part).

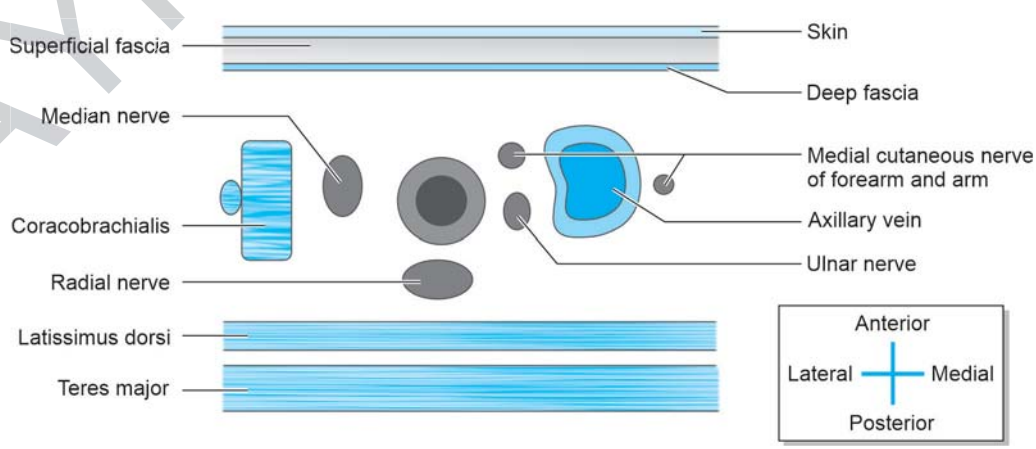

Fig. 13: Relations of third part of axillary artery (distal part).

JAYPEE BROTHERS

- **Acromial branch** crosses the coracoid process and it ends by joining the anastomoses over acromion process.
- **Clavicular branch** runs superomedially deep to pectoralis major and it supplies the acromioclavicular joint and subclavius.

Lateral Thoracic Artery

It is the branch of second part of axillary artery. This artery emerges at and runs along lower border of pectoralis minor in close relation with anterior group of the axillary lymph nodes. In females, lateral thoracic artery is large and it gives off lateral mammary branches to breast.

Subscapular Artery

It is the largest branch of axillary artery which arises from its third part. This artery runs along lower border of subscapularis to terminate at near inferior angle of scapula. It supplies to the latissimus dorsi and serratus anterior muscles.

Subscapular artery provides a large branch, i.e., the *circumflex scapular artery,* which is larger as compared to the continuation of main artery. This branch passes via upper triangular intermuscular space and it winds around lateral border of scapula in between the two slips of teres minor, and this gives off a branch to subscapular fossa, and one more branch to infraspinous fossa, both of these branches take part in anastomoses at around scapula.

Anterior Circumflex Humeral Artery

This is the small branch which arises from third part of axillary artery at lower border of subscapularis.

This artery passes laterally in front of intertubercular sulcus of humerus, and become anastomoses with posterior circumflex humeral artery, and form an arterial circle round to surgical neck of humerus.

This gives off an ascending branch which mainly runs in intertubercular sulcus, and supplies to head of humerus and the shoulder joint.

Posterior Circumflex Humeral Artery

It is much larger as compared to the anterior artery. This artery arises from third part of axillary artery at lower border of subscapularis. Now, it runs backwards and is mainly accompanied by axillary nerve which passes via *quadrangular intermuscular* space and ends by anastomosing with anterior circumflex humeral artery around surgical neck of humerus. This artery supplies to shoulder joint, deltoid, and to the muscles which are bounding the quadrangular space.

This artery gives off a descending branch which become anastomoses along with ascending branch of *profunda brachii artery*.

Anastomoses and Collateral Circulation

Branches of axillary artery get anastomose with one another and also with branches which are derived from the neighboring arteries which namely are internal thoracic, intercostal, suprascapular, deep branch of transverse cervical, profunda brachii.

As axillary artery get blocked, there is establishment of collateral circulation through anastomoses around the scapula which undergo linkage of first part of subclavian artery with third part of the axillary artery.

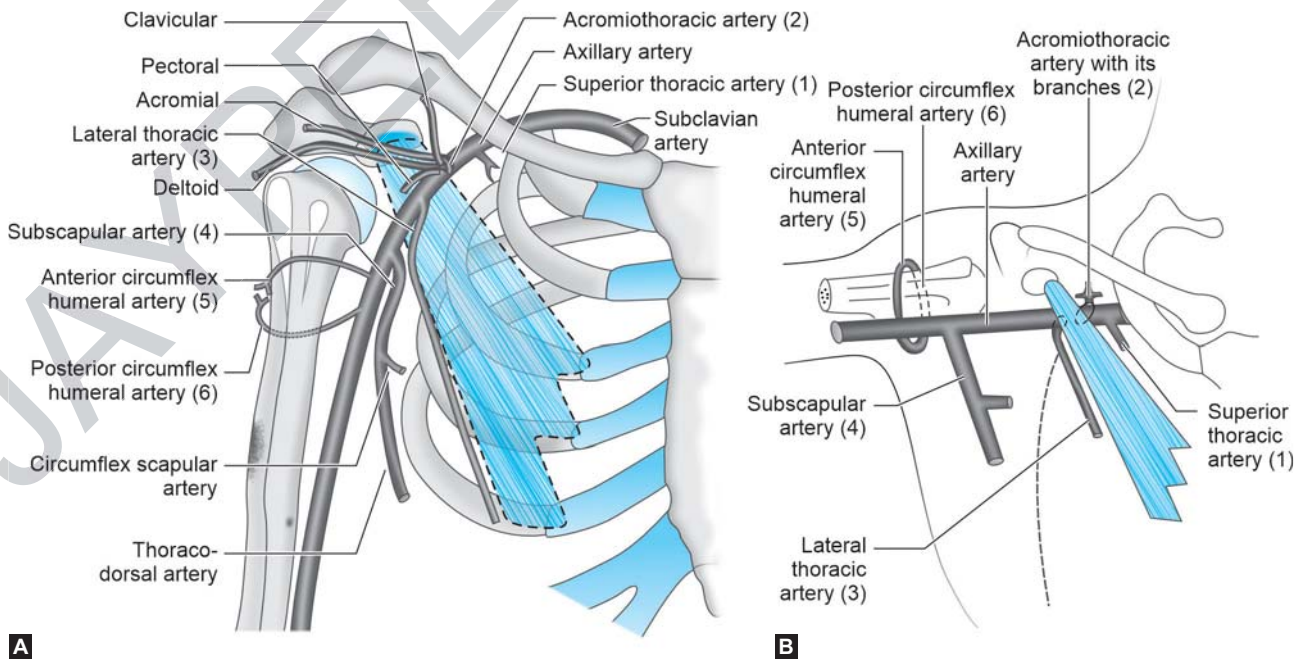

Figs. 14A and B: Branches of axillary artery.

JAYPEE BROTHERS

for detailed information on mbbs books, visit our website www.jaypeebrothers.com, for detailed information on mbbs books, visit our website www.jay

Mastering the MBBS Ist Year

(Last 10 Years Solved Questions)

Salient Features

- Updated as per the competency based medical education curriculum (NMC).
- Provides broad coverage of all the subjects in MBBS Ist year.
- Includes vast topics in simple flowcharts, tables and diagrammatic forms so as to make the content easy to understand and recall.
- Supports in quick revision during examinations.
- One weapon, two targets, i.e., MBBS examinations and PG entrance: It is the only book written, which can be used to clear university graduation examinations.
- As NExT pattern is coming under the enforcement, the book is based on NExT pattern.

Highlights of first edition are:

- Exam-oriented book with unique collection of last 10 years solved question papers.
- Extensively revised and updated chapters to provide knowledge of present era.
- All the sections are thoroughly written.
- All clinical questions as per NMC of all subjects are thoroughly solved.
- Contains illustrations and high quality photographs with explanatory legends for easy explanation of text.
- Provides recent and internationally accepted classification systems by eminent professional bodies, WHO, etc.
- Includes solved papers of year 2013 to 2023 of multiple universities all over India.
- Explains questions in point-wise manner for the clear overview and eye-catching remembrance.
- Illustrates H&E stained histological photographs in color plates which help students to understand the general histology section.
- Incorporates a clinical overview in various chapters for highlighting the clinical applications.
- A highly structured, user-friendly, systemic and attractive layout with enriched illustrations.
- Content is more with less pages—handy look is there which saves the time of student.
- Concise, bullet format and to-the-point text which is easy-to-read during MBBS examination.
- Language is simple and lucid which makes the understanding easy.

Hemant Gupta MDS (Oral and Maxillofacial Pathology, Microbiology and Forensic Odontology) has over 18 years of experience of authorship. He is CEO of Shivom Multispecialty Dental Clinic, Indore, Madhya Pradesh, India. He is general practitioner and also a consultant as oral cancer diagnostician at various clinics and hospitals. He has also specialized in pathology technique such as immunohistochemistry. He has published research papers in various indexed journals of national and international repute. His pioneer work in Forensic Odontology is on Ameloglyphics. Mastering BDS series was written by the him in dentistry which is successfully running all over India and abroad and is appreciated among the dental students. He has also contributed some chapters in two academic textbooks.

If any reader wishes to share feedback, suggestions, updates, and errata, please scan the QR code and fill the google form.

Printed in India

Available at all medical bookstores or buy online at www.jaypeebrothers.com

JAYPEE BROTHERS
Medical Publishers (P) Ltd.
EMCA House, 23/23-B, Ansari Road,
Daryaganj, New Delhi - 110 002, INDIA
www.jaypeebrothers.com

Join us on facebook.com/JaypeeMedicalPublishers

ISBN 978-93-5696-714-4