lastic surgery books, visit our website www.jaypeebrothers.com, for detailed information on plastic surgery books, visit our website www.jaypeebrothers.com, for detailed information

2nd Edition

Principles and Practice of Burn Care



Editor-in-Chief
Sujata Sarabahi

Editors
VK Tiwari
Arun Goel
Suvashis Dash

Foreword
SP Bajaj

JAYPEE

Contents

SECTION 1: GENERAL CONSIDERATIONS

CHAPTER 1: **History, Epidemiology, and Prevention of Burns** 3
Ravi Chittoria

CHAPTER 2: **Anatomy of the Skin** 19
Sujata Sarabahi

CHAPTER 3: **Burns: Etiology and Classification** 26
Sameek Bhattacharya, V Suman Babu

CHAPTER 4: **Pathophysiology of Burn Shock** 42
Arvind Vartak, Suhas V Abhyankar

CHAPTER 5: **Pathophysiology of Burn Wound** 50
Arvind Vartak, Suhas V Abhyankar

CHAPTER 6: **Wound Healing in Burns** 61
N Shanmuganathan, Ramyaa Lakshmi TS, Mary Babu

CHAPTER 7: **Immunological Responses to Burn Injury** 80
Shankar Sriniwasan, Suvashis Dash

CHAPTER 8: **The Immunobiology of Skin Transplant: Rejection and Acceptance** 90
Rakesh Kain, Archana Sinha

CHAPTER 9: **Microbiology in Burns** 99
Deepthi Nair, Rojaleen Das

SECTION 2: EARLY CARE IN BURNS

CHAPTER 10: **Initial Evaluation and Resuscitation of Burn Patient** 119
Madhuri Gore, Suvashis Dash

CHAPTER 11: **Respiratory Tract Injury in Burns** 148
JC Suri, MK Sen, Thakur Thussu

CHAPTER 12: **Fluid, Electrolyte, and Acid–Base Disturbances in Burns** 161
Sujata Sarabahi, Suvashis Dash, Rahul M

CHAPTER 13: **Acute Renal Failure in Burns and its Management** 167
Rajiv Kohli, Arun Goel, Aakanksha Goel

SECTION 3: LOCAL CARE OF BURN WOUND

CHAPTER 14: **Burn Wound Management** 181
Deepti Gupta, Sujata Sarabahi

CHAPTER 15: **Surgical Excision of Burn Wound and Skin Grafting** 218
Pramod Kumar

CHAPTER 16: **Anesthesia for the Thermally Injured** 232
PK Verma, Bhavya Krishna

CHAPTER 17: **Biological Dressings and Skin Substitutes in Burns** 248
PK Bilwani, Suvashis Dash

CHAPTER 18: **Skin Banking** 261
Amrita More, Sujata Sarabahi, Deepak Nanda

CHAPTER 19: **Keratinocyte Culture and Cell Therapy** 272
RP Narayan, Mula Rohit Babu

CHAPTER 20: **Burn Wound Infection** 280
VK Tiwari, Sujata Sarabahi, Anoop S

SECTION 4: BURNS OF SPECIAL TYPES

CHAPTER 21: **Electrical Burns** 305
SP Bajaj, Aakanksha Goel, Arun Goel

CHAPTER 22: **Industrial and Chemical Burns** 342
Mamta Sikroria, Mula Rohit Babu

CHAPTER 23: **Radiation Burns Injuries** 365
BC Shankar, Suvashis Dash, Lukesh Patil

CHAPTER 24: **Friction Burns** 381
Karoon Agrawal, Mula Rohit Babu

CHAPTER 25: **Fireworks and Firecracker Injuries** 389
Aakanksha Goel, Arun Goel, Sameek Bhattacharya

SECTION 5: BURNS OF SPECIAL SITES

CHAPTER 26: **Facial Burns** 407
PS Bhandari, Aakanksha Goel, Arun Goel

CHAPTER 27: **Hand Burns** 426
S Raja Sabapathy

CHAPTER 28: **Burns of Perineum and External Genitalia** 449
Deepak Nanda, Mula Rohit Babu

CHAPTER 29: **Pediatric Burns** 458
Harish Chellani, Sugandha Arya, Raghav Rajesh Mago

CHAPTER 30: **Burns during Pregnancy** 484
Shailesh Ranade, Akanksha Mohanty, Rekha Bharti

SECTION 6: GENERAL MANAGEMENT AND REHABILITATION

CHAPTER 31: **Multiple Organ Dysfunction Syndrome in Burns** 493
Poonam Gupta, PK Verma

CHAPTER 32: **Guidelines for Nutritional Management of the Burn Patient** 515
Savita Arora, Komal Tripathi

CHAPTER 33: **Physiotherapy in Burns** 536
R Raja Shanmugakrishnan

CHAPTER 34: **Postburn Sequelae and their Management** 552
Arun Goel, Aakanksha Goel

CHAPTER 35: **Medicolegal Aspects of Burn Injuries** 618
Chandrakant, Sujata Sarabahi, Manish Kumath, Reisha Rijal

CHAPTER 36: **Legal Requirements in Managing Burn Patients** 629
Atul Kumar Shah

CHAPTER 37: **Burn Disfigurement and Physical Impairment Calculations** 632
Atul Kumar Shah

SECTION 7: ORGANIZATION OF BURN CARE

CHAPTER 38: **Organization of a Burn Unit** 643
Madhuri Gore, Shivangi Saha, Maneesh Singhal

CHAPTER 39: **Burn Injury Management in Disasters: Indian Perspective** 658
Ravindra Tah

Appendices 683

Appendix 1.1: Composition of Common Intravenous (IV) Fluids *683*
Appendix 1.2: Body Surface Area *684*
Appendix 1.3: Normal Biochemical Values *684*
Appendix 1.4: Body Build and Blood Volume in Adults *685*
Appendix 1.5: Fluid Composition of Body Compartments *685*

Appendix 1.6: Composition of Different Body Fluids *685*
Appendix 1.7: Normal Values for Coagulation Tests *685*
Appendix 2.1: Available Enteral Formulae *686*
Appendix 2.2: Nutritive Value of Indian Food *687*
Appendix 2.3: Diet Chart for Burn Patients and their Nutritive Value *688*
Appendix 2.4: Total Parenteral Nutrition *689*
Appendix 2.5: Standard Parenteral Solution *689*
Appendix 2.6: Nutritional Assessment Chart *690*
Nutritional Values *693*

Index **703**

SECTION

3

Local Care of Burn Wound

JAYPEE BROTHERS

JAYPEE BROTHERS

CHAPTER

14

Burn Wound Management

Deepti Gupta, Sujata Sarabahi

JAYPEE BROTHERS

INTRODUCTION

The survival of a moderate-to-extensively burnt patient depends on the successful management of the burn wound. A burn patient is always at risk as long as his/her wounds persist. There is a general consensus that burn wound infection is the primary cause of morbidity and mortality following an extensive burn injury. Hence, an early wound closure can eliminate not only the risk of infection but also the risk to life of the extensively burnt victim.

After the initial management and resuscitation of a burn patient is complete, the focus shifts to the management of the burn wound. This management requires a careful evaluation of the burn wound and it's nature.

MECHANISM OF WOUND HEALING

Superficial Dermal Burns

Superficial dermal burns involve the papillary layer of dermis and are typically pink and moist with intact hair **(Fig. 1)**. Sensations are retained as the sensory receptors in the deep dermis and hypodermis are spared.[1]

The remaining adnexal elements such as hair follicles, sweat glands, and sebaceous glands aid in re-epithelization of these wounds and such burns spontaneously heal over a period of 3 weeks **(Figs. 2A and B)**. Therefore, these wounds can be managed conservatively in the form of topical antimicrobial creams and dressings, to prevent infection, promote healing, and protect the fragile new epithelium.[2]

Deep Dermal Burns

Deep dermal burns involve the reticular layer and are dry and pearly (waxy) white in color. Hair can be easily pulled out **(Fig. 3)**. Some sensations may be present due to the sparing of sensory receptors in deeper layers of dermis and those in hypodermis.[1]



FIG. 1: Superficial dermal or superficial partial thickness burn with moist and red look.

Deeper a burn injury, greater is the loss of adnexal elements and only deeper parts of hair follicles or sweat glands survive. As the eschar separates, epithelial buds emerge from the site of these remaining epidermal appendages and from these tiny islands the neoepithelium proliferates over the wound surface **(Fig. 4)**. As this re-epithelialization is very slow, the healed skin shows hypertrophic scarring later. Superimposed bacterial infection can convert a partial-thickness wound into a full-thickness wound hampering the process of spontaneous healing. Thus, it is imperative to prevent this conversion by appropriate wound care.[2] The primary objective in treating a partial thickness burn injury is to provide an environment that inhibits microbial growth and at the same time promotes wound healing. Hypertrophic scarring can be prevented by early

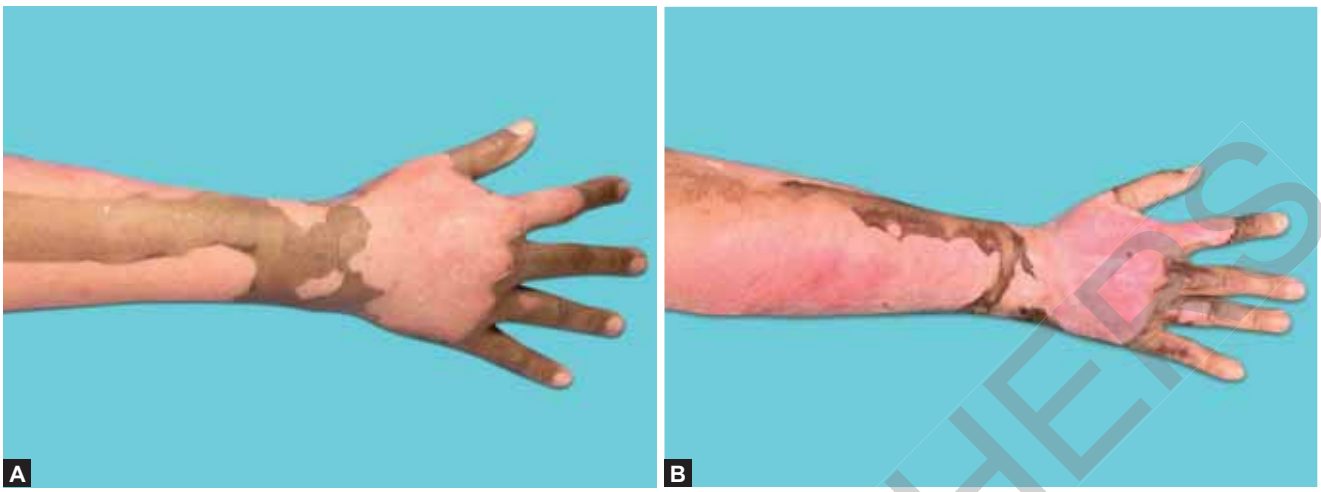

FIGS. 2A AND B: (A) Superficial partial thickness burn; (B) Closed dressing achieved complete healing in 10 days.



FIG. 3: Deep dermal burns with pearly white look.



FIG. 5: Full thickness burns with charred look and thrombosed veins.



FIG. 4: Epithelialization occurring underneath the eschar, seen once the slough is removed.

tangential excision and resurfacing by skin grafts in such wounds.

Full-thickness Burns

Full-thickness burns **(Fig. 5)**, as the name indicates, involve the whole of epidermis and dermis and appear parchment-like with visible, thrombosed subcutaneous veins. Sensory receptors are completely destroyed resulting in insensate wounds. There are no chances of spontaneous healing as all epidermal elements are lost. In such burns, the dead tissues become dry, firm, and black resulting in eschar formation. Beneath this eschar, cellular and capillary activity in the underlying viable tissues produces a layer of red granulation tissue, which is exposed when the eschar separates. The granulation tissue is totally devoid of epithelial cells, so the healing

JAYPEE BROTHERS

of a burn raw area can take place only by epithelial migration from the normal surrounding epithelial edge and wound contraction. Initially, this ingrowth is rapid but only for a certain distance after which the cells stop growing. Over flexor aspects of joints or in areas where the skin is loose and contraction is possible, the wound closes on its own with the development of contractures **(Fig. 6)**. In areas where the underlying bone(s) prevent contraction, the granulation tissue remains as a non-healing wound till it is covered with a skin graft/flap **(Fig. 7)**. If these areas are not grafted at the earliest, they go on to develop chronic granulation tissue. Their vascularity reduces, the superficial layers of granulation tissue ooze serum that clots, and this is again invaded by inflammatory cells and capillaries to form fresh granulation tissue. As time passes, the deeper layers progressively mature into fibrous scar tissue with overlying thin granulations. Therefore, to avoid the formation of chronic granulation tissue and to prevent development of contractures, full-thickness wounds need early excision and resurfacing with a skin graft or early closure of raw areas if being managed conservatively.



FIG. 6: Wound contraction in full thickness burns—if surgical intervention is not done the wound bed contracts leading to contracture of the neck and axilla.



FIG. 7: Granulating wound—shows that epithelialization from the margins stops after a certain distance.

AIMS OF LOCAL BURN WOUND CARE

The basic aims of local burn wound care are:[3]

- Oxygenation of tissues
- Prevention of wound infection and sepsis
- Promotion of healing:
  - Prevention of damage to remaining viable epithelium
  - Prevention of damage to regenerating, delicate neoepithelium
  - Allowing free drainage of exudates from the wound and prevent them from coming in contact with the environment
- Early excision of dead tissue and resurfacing with skin grafts
- Encouragement of spontaneous slough separation in conservatively managed wounds
- Immobilization of the injured area to reduce pain

INITIAL CARE OF BURN WOUND

Once the resuscitation procedures have been initiated, the burnt area has to be evaluated in detail for its extent and depth. It is preferable to shift the patient to a specified dressing room where the wound can be managed with all aseptic precautions. This is important because immediately following burns the skin surface is sterile as all surface bacteria are killed by the heat. One should avoid introducing exogenous bacteria to the wound by all means in order to avoid burn wound infection. Initial burn wound care involves:[4]

- Cleaning and debridement
- Burn wound assessment
- Ensuring adequate oxygenation of tissues
- Dressing of the burn wound:
  - Open or exposure method
  - Occlusive or semi-occlusive method

Cleaning and Debridement

The area is thoroughly washed with an antiseptic solution and normal saline to remove all the debris. All the loose nonviable tissues are removed with minimum trauma. Management of blisters remains controversial. Theoretically, the fluid in an intact blister is sterile. However, it is rich in proteins that cause it to set into a

JAYPEE BROTHERS

gelatinous form, which is an ideal culture medium for bacterial growth if the fluid happens to get contaminated. This fluid retards the local immunity by impairing the normal function of inflammatory cells and also retards the fibrinolytic process, thus delaying wound healing.[5] While very small blisters (< 5 cm) may be allowed to be kept intact, the larger blisters (> 5 cm) run the risk of rupture and are preferably deroofed at the time of initial dressing. Another way to manage blisters is to aspirate them with a needle to allow the blister membrane to stick to the wound. Some authors consider the blister skin as dead and necrotic tissue and prefer to deroof all blisters **(Figs. 8A and B)**.

Burn Wound Assessment

After a thorough cleaning, a proper appraisal of the depth of burns is done and it should be properly charted in the "burn chart" for future reference **(Fig. 9)**. This chart contains detailed observations of the wound. Any surgical procedure performed can also be noted in the chart. Any change in burn wound depth can also be charted in the same form at a later date to follow the progress of the burn wound.

Ensuring Adequate Oxygenation of Tissues

A continuous supply of oxygen is essential for all phases of wound healing. Following burns, the blood supply to the burn wound is reduced because of edema and impaired circulation leading to poor oxygenation of tissues. This reduced tissue oxygenation not only impairs wound healing but also favors bacterial invasion of the wound. The result is that the wound heals poorly and with excessive scarring. To counter this, some burn centers have used hyperbaric oxygen to assist wound healing. However, it has not been used widely.[6,7] Simpler measures can also be taken to ensure adequate oxygenation of burn wounds.

- All encircling bracelets, rings, and other jewelry on the burn victim are removed because they can act as tourniquets once edema sets in, causing distal ischemia.
- Constricting dressings and casts should be avoided, and the burned extremities should be elevated.
- Early escharotomies/fasciotomies should be done to avoid compromising circulation in case of circumferential full-thickness/electrical burns respectively **(Figs. 10A and B)**.

Dressing of the Burn Wound

After cleansing, the wounds are dabbed dry with sterile gauze and then the appropriate method of further wound management is selected, i.e., exposure method (open method) or closed method (occlusive method) of dressing. In most patients, neither of these methods used alone is ideal for local care, and frequently both methods are used in different areas of the body in the same patient for best results.

Open or Exposure Method

The open method of burn treatment has been used since eternity but was reintroduced by Wallace in 1948.[8] It is especially useful for burns of face and perineum, which cannot be adequately dressed. Extensive nonsalvageable burns > 90% of total body surface area (TBSA) may also be managed by this method decreasing the requirement for manpower, material, and cost. This technique consists

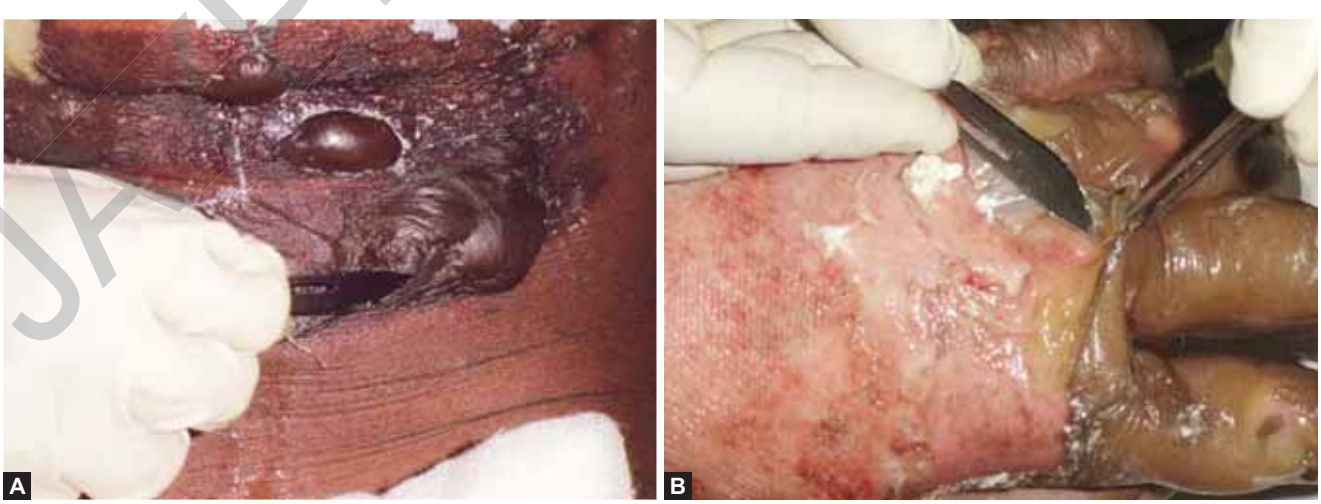

FIGS. 8A AND B: (A) Blister being incised; (B) Deroofing of blister being done surgically—underlying coagulum seen.

JAYPEE BROTHERS

Department of Burns, Plastic and Maxillofacial Surgery, Safdarjang Hospital, New Delhi

Name _____ MRD No. _____

Age _____ Index No. B _____

Weight _____ Sex _____

Date of Observation _____

Estimating the area burned

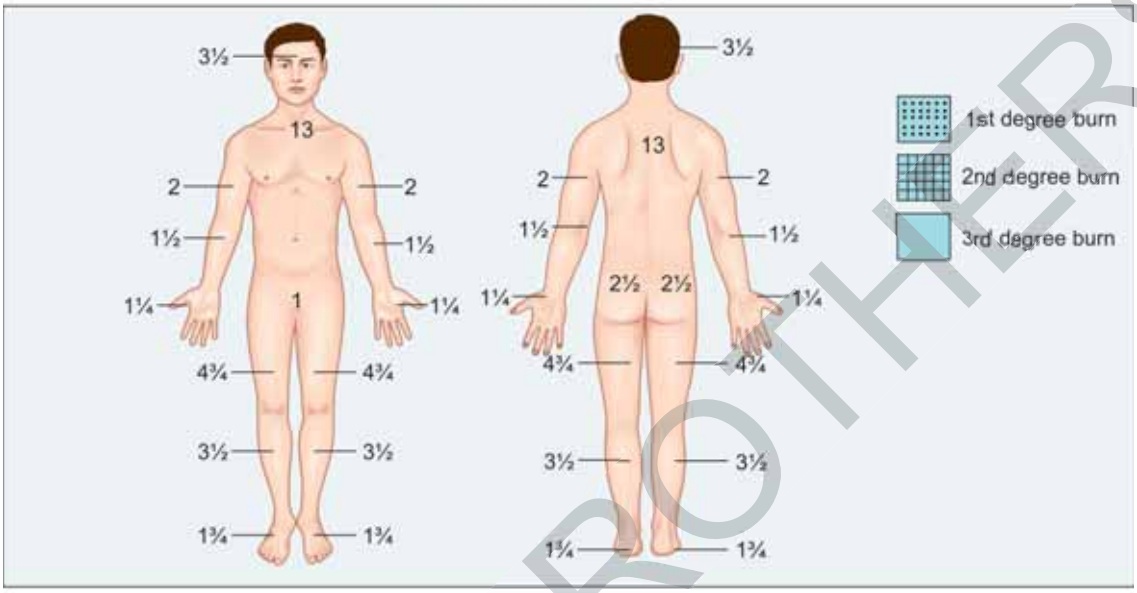

Area	Birth 1 yr	1–4 yrs	5–9 yrs	10–14 yrs	15 yrs	Adult	Partial-thickness second degree	Full-thickness third degree	Total
Head	19	17	13	11	9	7			
Neck	2	2	2	2	2	2			
Anterior trunk++	13	13	13	13	13	13			
Posterior trunk+	13	13	13	13	13	13			
Right buttock	2½	2½	2½	2½	2½	2½			
Left buttock	2½	2½	2½	2½	2½	2½			
Genitalia	1	1	1	1	1	1			
Right upper arm	4	4	4	4	4	4			
Left upper arm	4	4	4	4	4	4			
Right lower arm	3	3	3	3	3	3			
Left lower arm	3	3	3	3	3	3			
Right hand	2½	2½	2½	2½	2½	2½			
Left hand	2½	2½	2½	2½	2½	2½			
Right thigh	5½	6½	8	8½	9	9½			
Left thigh	5½	6½	8	8½	9	9½			
Right leg	5	5	5½	6	6½	7			
Left leg	5	5	5½	6	6½	7			
Right foot	3½	3½	3½	3½	3½	3½			
Left foot	3½	3½	3½	3½	3½	3½			
Total									

FIG. 9: Burn chart used in the author's unit—depth of burns in different areas can be charted.

JAYPEE BROTHERS

of placing the patient on a clean, dry, sterile sheet under a cradle after cleaning and debriding the wounds. The wounds are left exposed to air without any topical agents or any covering agents. The exudate from the wounds dries up and along with the layers of destroyed skin forms a scab or an eschar. The latter acts as a "dressing" protecting the underlying tissues from bacterial colonization **(Fig. 11A)**. Although the dry cool air inhibits bacterial growth, pathogenic organisms can grow from the deep surface of the crust. Under these circumstances, the activity of the organisms is usually low, and the body is able to fight them and hence, healing can take place. The drying process, however, may retard the spread of epithelium which is faster under moist conditions. For deeper wounds, open treatment may be less satisfactory as the dry eschar takes a long time to separate. The patient

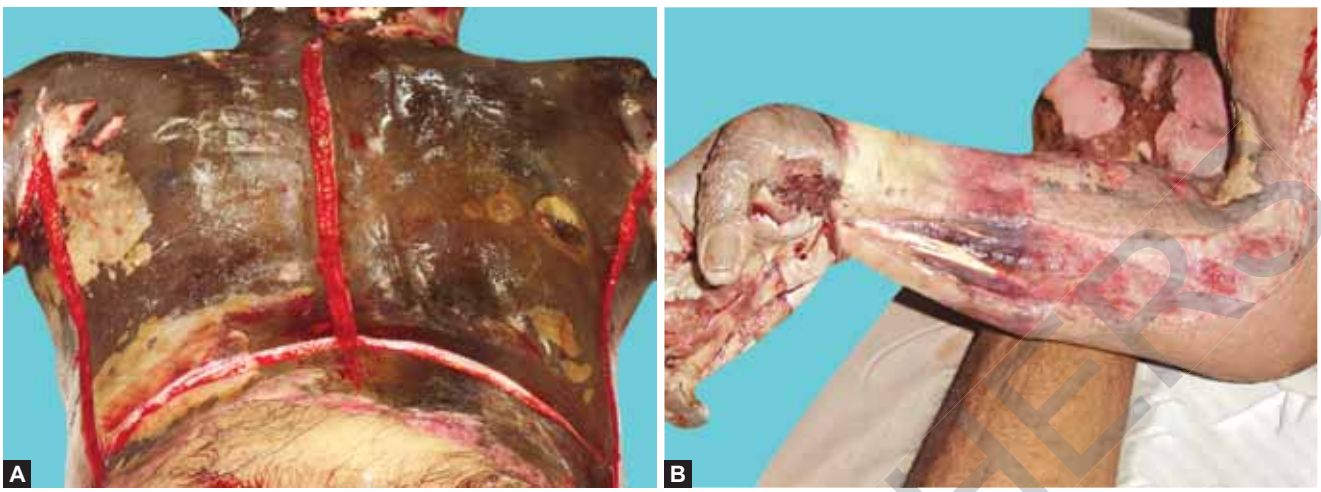

FIGS. 10A AND B: (A) Escharotomy incisions for full-thickness circumferential burn; (B) Fasciotomy incision over arm in electrical contact burn.



FIGS. 11A AND B: (A) Facial wounds treated by exposure technique–exudates from the wound dry up and form a scab, which acts as an external dressing to protect underlying tissues from infection; (B) Exposure technique but with the application of antibiotic-impregnated paraffin gauze—this transports exudates to the surface of the gauze so that the scab does not adhere to the wound surface and gauze can be removed easily without causing pain or bleeding from the wound surface.

and his/her attendants also may find the exposed wounds unsightly and uncomfortable. This method is not very suitable for wounds over joints as the scabs over a joint surface may crack repeatedly and bleed. In case of hands, exposure method allows full range of movements at all joints which avoids deformities of the hand.

A modification of the open technique is to apply a thin layer of antibiotic ointment over the wounds after cleansing and drying them daily, especially on the face. Sometimes an antimicrobial impregnated gauze is used on exposed wounds and this gauze acts as a wick to transport the exudates to the gauze surface where it dries up forming a scab. The advantage with this technique is that the scab does not adhere to the wound and the gauze can be removed easily without the risk of bleeding from the wound or else damage to the newly formed epithelium **(Fig. 11B)**.

If the burned area is of superficial partial thickness, the whole scab/gauze begins to separate after a week or so and this is trimmed gently and repeatedly with scissors and it finally comes out in 15–21 days to leave a well-healed skin surface. If the scab does not separate by 3 weeks, the burn is treated as a deep partial-thickness burn, and the management is changed to the technique of occlusive dressings, which hastens the separation of eschar. For patients treated by exposure method, appropriate maintenance of the environmental temperature in the range of 28–32°C and humidity at about 40% is

JAYPEE BROTHERS

important as leaving the wounds exposed increases the evaporative losses as well as body heat loss.

The advantages of open method are:
- Wound examination is easier
- Earlier detection of wound infection
- Early physiotherapy
- Easier control of hyperpyrexia
- Wound environment is not conducive to bacterial colonization.

The disadvantages of open method are:
- Delay in eschar separation
- Evaporative losses increase
- Chances of hypothermia
- Not possible where isolation is not available

Occlusive Dressing or Closed Technique

This method is most useful for patients with circumferential burns of extremities and torso **(Fig. 12)**. Occlusive dressings are avoided in burns of face, neck, and perineal region.

The advantages of occlusive dressings are:
- Reduces evaporative losses
- Provides a mechanical barrier to prevent bacteria from contaminating the wounds
- Absorbs exudates from the wound surface
- Maintains a moist environment which encourages epithelialization
- Patient is more comfortable

Dressing technique: The technique of dressing a burn wound determines the final outcome of burn wound treatment program. All burn dressings should be done with proper aseptic precautions to prevent wound contamination. All doctors and nursing staff should be properly gowned and gloved. Majority of the dressings can be performed without general anesthesia. Usually, sedation with opioid analgesics (e.g., morphine) is adequate.



FIG. 12: Closed dressing technique.

A satisfactory burn dressing is one that can absorb all the fluid exuded from the burn wound and distribute evenly so that there is no collection of the exudate on the wound surface. The material that fulfills these requirements is the Gamgee pad, which consists of cotton wool sandwiched between two layers of absorbent gauze. These are easy to prepare and can be made in assorted sizes suitable for small as well as extensive areas. These are prepared, sterilized, and kept ready to use so that they are available at all times.

The innermost layer of occlusive dressing consists of a layer of an antimicrobial agent over which a wide mesh gauze impregnated with paraffin or petroleum jelly is applied. This tulle grass is nonadherent so that pain and trauma to the regenerating neoepithelium can be minimized at the time of change of dressing. After the nonadherent gauze and antimicrobial agent are applied, multiple layers of gauze and Gamgee pads, depending on the expected amount of exudate, are applied and kept in place with a gentle compression bandage. This dressing prevents edema formation, splints the wound, and facilitates absorption of discharge. However, it should not be constricting in any way. This outer layer of the dressing should be porous to allow evaporation of water and prevent inner layers from becoming soggy as that encourages microbial growth **(Figs. 13A to D)**.

The frequency of dressing change depends upon the depth of burns and the degree of infection in the burn wound. In case of partial-thickness burns, when there are no signs of infection, the first dressing can be left intact for 3–5 days. In case of full-thickness burns, the dressing should be changed every 3 days. Earlier change of dressing is indicated if there is soakage in dressing or any sign of infection of burn wound which includes local pain, unexplained fever, foul smell from dressing, and increased purulent discharge from wound. The topical agent being used on wound should also be changed if discharge increases. There are various antimicrobial agents and dressing materials used for burn dressings that are discussed later in this chapter.

TOPICAL ANTIMICROBIAL THERAPY

A variety of local medicaments have been used on burn wounds since eternity, which ranged from tinctures (600 BC), vinegar-soaked dressing (430 BC), greasy dressing

JAYPEE BROTHERS

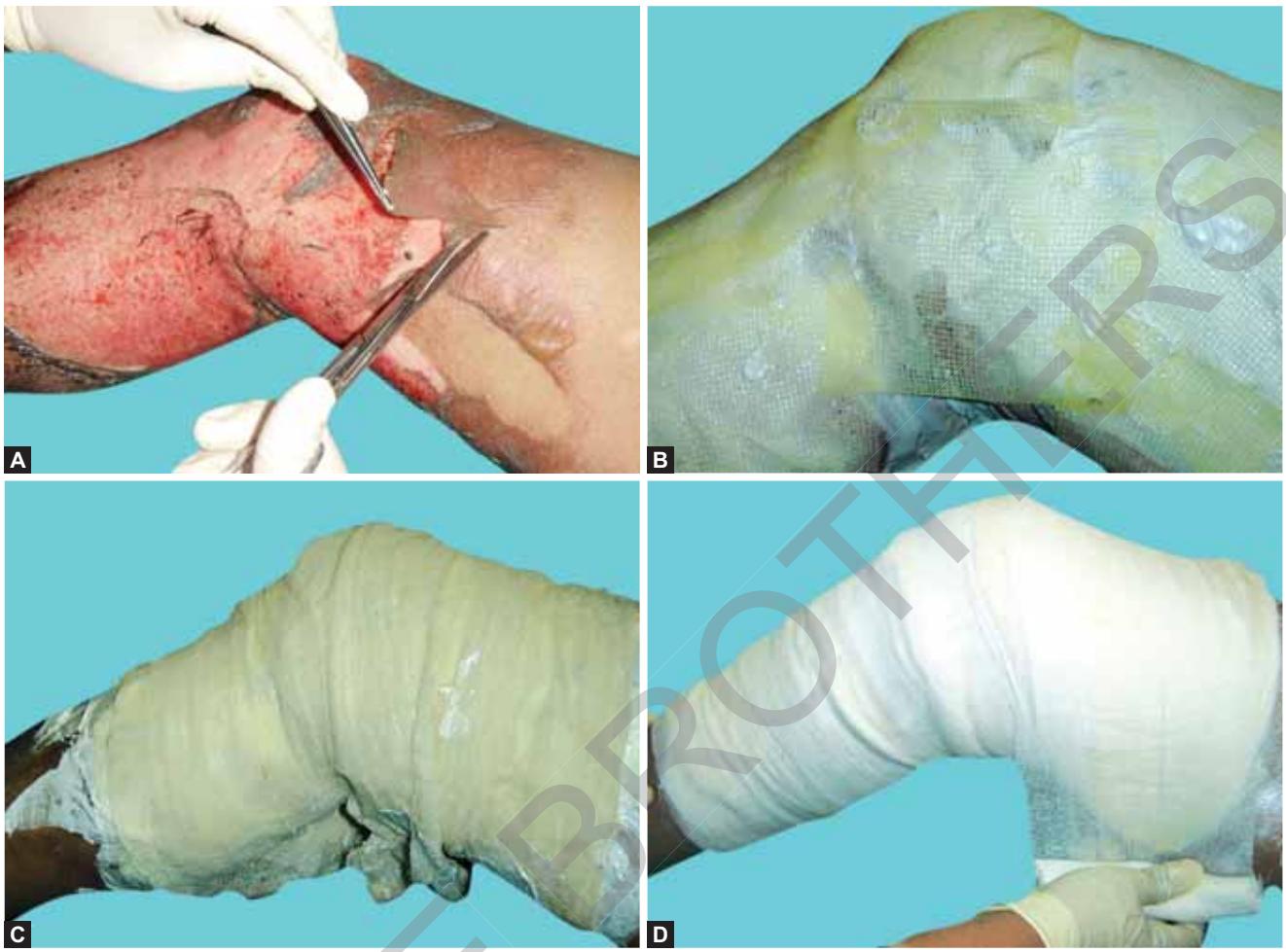

FIGS. 13A TO D: (A) Removal of loose dead skin; (B) Application of silver sulfadiazine over paraffin gauze; (C) Application of gauze and Gamgee; (D) A light compressive bandage over the limb.

JAYPEE BROTHERS

(1596), tannic acid by Edward Clark Davidson (1894–1933) to Gentian violet by Aldridge in 1933 to Petroleum gauze by Harvey Allen in 1942. All these methods, however, fell into disrepute because of local and systemic toxicity or ineffectiveness of these substances. This initiated research for finding newer topical agents that are more effective and have fewer side effects.

History of Topical Antimicrobial Agents

The topical therapy of burn wounds dates back to the beginning of civilization. Throughout history, a number of famous philosophers, physicians, and scientists have contributed to the knowledge of burn wound management, including such notables as Hippocrates, Celsus, Pliny the Elder, Galen, Aristotle, Rhases, Clowes, Paré, Hildanus, Marjolin, Dupuytren, and Syme. A variety of substances have been advocated as effective topical burn treatments including some plants, gums, milk (goat milk and milk from "a women who has given birth to a son"), tea leaves, roasted angle worms, oak bark extract, honey, cork, bear fat, bran, ashes, vinegar, wine, fat from "very old wild hogs", calcium chloride soaks, moss "from the skull of a person hung", red sandalwood, cold water, saline baths, lemon strips soaked in oily dressings, soot, spider webs, linseed oil mixed with lime water, picric acid, medicated paraffin, carbolic acid, cod liver oil, and "portions of a genuine mummy". At the beginning of the 20th century, it was believed that the systemic derangements seen in burn patients resulted from a release of "toxins" from the burn wound, and thus the goal of topical therapy was to bind or leach toxins before they can be absorbed.[9] A secondary goal was to dry out the burn wound or to create a hard coagulum to minimize exudate, drainage, or fluid loss. A number of "escharotics", including 5% or 10% silver nitrate solution, gentian violet,[10,11] "triple" dyes, trinitrophenol, and tannic acid

were employed, either alone or in combination. Over the years, the goals of topical burn treatment have changed. There was a drastic change in the treatment of burn wounds with dressings along with an antiseptic agent in 1868 following discovery of the concept of antiseptics by Lister. Carbolic acid, mercurial compounds, and aniline dyes were used as an inner layer of burn dressing. Unfortunately, they were unselective in their action and damaged normal tissues along with bacteria colonizing the wound surface. Hence, their use was discontinued. In the mid-twentieth century, phenol-containing dressings were highly recommended. Davidson at the Henry Ford Hospital first described the use of tannic acid spray in 1925 and believed that this modality reduced pain and produced a cleaner wound bed.[10,12] In 1935, Bettman added 10% silver nitrate to a 2.5% tannic acid solution, which allowed wound tanning to occur in seconds. Reports of liver necrosis in patients treated with tannic acid began to appear in the 1930s, although liver necrosis was often ascribed to the burn injury itself. Additionally, pus tended to accumulate under the coagulum formed by tannic acid application. McClure (1944), also from Henry Ford Hospital, reported that tannic acid was a hepatotoxin and the use of this agent was discontinued.

Work by Aldrich, Teplitz, Lindberg, and others established that septicemia in burn patients, a major cause of mortality, frequently originated in the burn wound.[11] Attention then turned to the application of various topical antimicrobials to the burnt surface and the development of mafenide (Sulfamylon®), silver nitrate, silver sulfadiazine (SSD), and others revolutionized burn care.

In early part of World War II, Marfanil which was later called Mafenide was used by the German army and was found to reduce the incidence of gas gangrene. Subsequently, it was used by the United States (US) Army for traumatic wounds as it was found to be effective against clostridial and enteric organisms. Its efficacy in controlling burn wound sepsis was discovered by Moncrief in 1964. Although it was found to be very effective against *Pseudomonas,* especially in the treatment of established infections, it was relatively inactive against gram-positive organisms, especially streptococci which was the main cause of burn wound infection at that time. In 1965, Moyer and colleagues showed excellent prophylactic use of 0.5% silver nitrate against *Pseudomonas*. However, it had no role in established infections and also caused dyselectrolytemia and the patient was uncomfortable because of the black staining and continuous wet feeling. So, its use fell into disrepute. In 1968, a new antimicrobial, namely SSD, was discovered by Fox for use in burns. Even half a century later, no serious side effects have been reported despite its widespread use. Many other antibiotics and antiseptics have been used singly and in various combinations for burn dressing, namely, gentamicin, neomycin, bacitracin, polymyxin, framycetin, nitrofurazone, and chlorhexidine, etc. Many of these have proved useful under certain circumstances. However, they have all failed to prevent serious systemic infections in extensive burns, especially *Pseudomonas* infection, which is now the most common organism responsible for burn wound sepsis worldwide.

Basis for Topical Therapy

Immediately following burns, the surface of the burnt skin is sterile, and the only organisms present are deep in the skin appendages and these are not very pathogenic. Some of these organisms come to the surface following burn but a sterile dressing and use of an antimicrobial agent can kill these organisms. In the case of closed dressings, presence of exudates in the dressings, warmth, and lack of light under the dressing are ideal conditions for the proliferation of organisms after they gain entry to the skin surface through exogenous or endogenous routes, resulting in infection. This can be avoided by using a broad-spectrum antimicrobial agent which has action against both gram-positive and gram-negative organisms. The topical agents used for burn wound dressing should have a dual purpose—first to control any organisms on the surface of the burn wound and secondly to prevent entry of new organisms from the exterior.

By the end of the first week postburn, the deeper surface of eschar especially around the hair follicles shows active proliferation of organisms, which can penetrate deeper into tissues and adjacent viable tissue as well, if not controlled. This can again be checked by the application of topical antimicrobial agents that have a good eschar penetration. The deeply burned areas are avascular, which not only provide a favorable environment for bacterial proliferation but also prevent penetration of systemically administered antibiotics into the burn wound surface. This is better tackled by topical antimicrobial agents and obviates the need for systemic antibiotics. It is very important to understand that topical therapy does not sterilize the burn wound. It only controls the bacterial proliferation and confines it within the limits of the burn wound. Topical agents are also no substitute for meticulous wound care which includes proper debridement of devitalized tissues and deroofing of sub escharotic abscesses. On the other hand, proper and judicious use of topical agents can prevent the conversion of superficial burns into deeper wounds and decrease the incidence of systemic sepsis.

JAYPEE BROTHERS

Criteria for a Good Antimicrobial Agent

Criteria for a good antimicrobial agent are as follows:

- It should have a broad spectrum of activity against organisms that are most commonly isolated from the burn wound, for example, *Pseudomonas aeruginosa, Staphylococcus aureus, Klebsiella,* and *Enterococci,* etc.
- It should penetrate the eschar but not have a significant systemic absorption.
- There should be minimal emergence of resistance amongst organisms against the agent.
- It should cause minimal or no discomfort to the patient.
- It should be economical and easily available.
- It should have minimal side effects.
- Application should be simple and easy.

Topical Agents

The topical antimicrobial agents, most frequently used for burn wound dressings, are discussed below.

Silver Sulfadiazine[13-15]

Silver sulfadiazine is a white crystalline, highly insoluble compound synthesized by Fox in 1968 by reacting silver nitrate with sodium sulfadiazine. It is the most frequently used topical agent in the form of a water soluble cream base at 1% concentration, which provides the same amount of elemental silver as 0.5% silver nitrate solution (30 mEq/L). At this concentration, the amount of agent at the surface is more than that necessary in vitro to inhibit the growth of sensitive organisms.

Mode of action: The mechanism of action is due to both silver ion and sulfadiazine moiety, which are released at the wound surface by gradual dissociation. Sulfadiazine is a competitive inhibitor of para-aminobenzoic acid (PABA) which is a metabolic precursor. The ionic silver acts by impairing DNA replication, denaturing of proteins and enzymes, and increasing the permeability of the cell walls. It is primarily bacteriostatic and is active in vitro against a wide range of organisms which include *Staphylococcus aureus*, *Escherichia coli*, *Proteus*, *Enterobacteriaceae*, and Herpes virus. Clinical trials have shown reasonable prophylactic effect against gram-negative bacteria. It delays wound colonization by gram-negative bacteria in extensive burns.

In spite of the dissociation of the compound, there is no absorption of the silver from the wound. On the other hand, sulfadiazine levels of 1.5–4 mg/100 mL have been reported in the blood. There is also some grayish silver discoloration of the wound because of minimal precipitation of silver chloride or silver sulfide following oxidation of silver by exposure to sunlight.

Technique of application: It is applied as 1% cream to the burn wound in a thickness of approximately 0.5–1 cm either twice a day in case of exposed treatment or once a day in closed method. The substance has to be washed off between applications in order to debride the wound properly.

Advantages: It is an odorless cream, easy to apply, and causes minimal to no pain on application. It does not stain the skin or linen, unlike silver nitrate. It has an intermediate penetration capacity into the eschar. Bacterial resistance to SSD, even after prolonged therapy, has not been reported.

Disadvantages: Crystalluria has been occasionally reported. Methemoglobinemia is a well-known side effect of sulfonamide, although seen very rarely. Transient leucopenia can occur in patients treated with SSD after 2–3 days of starting treatment. This resolves spontaneously within a few days despite continued use of the agent. A macular rash is seen in <5% patients and is a cutaneous sensitivity reaction to SSD. A thin proteinaceous gel called "Pseudoeschar" forms on the wound surface after topical application of SSD. This can confuse an inexperienced observer during assessment of the depth of burn. With prolonged use of topical SSD, there is a risk of sulfadiazine-resistant gram-negative bacilli, especially Enterobacteriaceae group, developing plasmid-mediated resistance. Inhibition of epithelial regeneration with the use of 1% SSD has been demonstrated experimentally.

Silver Nitrate Solution (0.5%)[9]

Silver nitrate has been used for the treatment of burn wounds for over a century but fell into disrepute because of its side effects. Silver nitrate was used as a caustic and escharotic agent for burn care in the early 20th century in the form of a 10% solution, but was largely abandoned by the time of World War II as it was found to be toxic at such high concentrations. It was reintroduced by Moyer in 1965 as 0.5% solution and later popularized by Monafo as a topical agent for burn wound treatment. At this concentration, it is not toxic to the epithelium and has bacteriostatic action. For many years, 0.5% silver nitrate has also been used as a topical agent for patients with toxic epidermal necrolysis (TEN).

Mode of action: The free silver ion released is effective against the common microbial flora seen in the burn wound especially gram-negative bacteria. It is mainly bacteriostatic. There is no known resistance seen to this agent and if properly used, it is very effective as a prophylactic agent. There is minimal absorption of silver through the open wounds into systemic circulation

JAYPEE BROTHERS

because its salts are insoluble. Instead, there is precipitation of its salts, i.e., silver chloride and silver sulfide which cause the characteristic black discoloration of the burn wounds.

Mode of application: The technique of application of silver nitrate solution is as described by Monafo and Moyer. After cleaning and debriding the loose tissues in the wound, it is covered with 8–10 layers thick gauze dressing, which is then soaked with warm 0.5% silver nitrate solution. The dressing has to be wetted every 2 hours to ensure that the concentration does not become caustic (>2–3%). The advantage of this bulky wet dressing is that it minimizes evaporative loss.

Advantages: Application of silver nitrate is painless. No patient hypersensitivity has been reported to it. No resistant organisms have been isolated after its use. Its use helps in rapid debridement of the eschar because of twice daily change of the bulky gauze dressing. Its continuous use decreases evaporative water loss, which further helps in decreasing metabolic rate and improves the nutritional status of the patient.

Disadvantages:

- 0.5% silver nitrate has been found to be ineffective in established burn wound infections and its ability to penetrate the eschar is poor.
- It stains all the linen and floor brown or black. Thus, its use necessitates use of disposable linens and stain-resistant floor and wall coverings, which can increase the cost of treatment.
- There are severe electrolyte derangements noticed with its use. Use of distilled water as a vehicle for application of silver nitrate leads to a markedly hypotonic solution and it causes absorption of large volumes of distilled water into the tissues and eventually into the bloodstream. There is leaching of sodium by reverse mechanism, which results in hyponatremia, which can lead to convulsions, if severe. This can be prevented by administering large quantities of sodium chloride orally or intravenously. The precipitation of silver as silver chloride and silver sulfide salt results in hypochloremia, which can also be corrected by infusing saline. Hypokalemia and hypocalcemia can result from leaching of potassium and calcium. Ideally, 40–120 mEq of potassium and 4–8 g calcium along with vitamin supplements are necessary either orally or intravenously. It is recommended to replace about 350 mEq of sodium per square meter of wound surface in order to maintain adequate serum levels. The electrolyte imbalance with the use of silver nitrate is noticed mainly in infants and children and in patients with larger burns particularly >20% TBSA, unless the replacement therapy is maintained. In extremes of age, dyselectrolytemia can occur within 6–8 hours of its use and therefore, less frequent saturation of wound dressings is recommended in these age groups.
- The black discoloration of the burn wound surface interferes with clinical assessment of the wound.
- Some of the gram-negative bacteria especially *Enterobacter cloacae* metabolize nitrate ion to nitrite, which when absorbed through the wound results in methemoglobinemia. Though it is a rare complication, it has to be suspected if there is cyanosis or slate gray discoloration of skin without any pulmonary injury and arterial blood is brown in color even though PaO_2 is normal. Diagnosis can be confirmed by estimating methemoglobin levels in the blood. Management of this condition includes withdrawal of silver nitrate dressing and intravenous administration of reducing agents like methylene blue or ascorbic acid.

Mafenide (11.1%)[16-19]

Mafenide is a methylated sulfonamide, which was introduced for clinical use as a topical agent for burn wounds in 1964 by Moncrief. It is presently used as a cream with 11.1% concentration of the drug in a water-miscible base.

Mechanism of action: It is active against most gram-positive organisms and a wide spectrum of gram-negative organisms including *Pseudomonas*. It is particularly effective against Clostridial species. It has minimal antifungal action. Its mechanism of action is not known but it is primarily bactericidal only in higher concentrations. It actively penetrates the burn wound and minimal amount is left on wound surface after 3 hours. After 10 hours, the tissue level is below the concentration required to inhibit bacterial growth. Therefore, to maintain therapeutic levels of the agent in the wound, it has to be reapplied after 12 hours.

Mode of application: The cream is applied to the wound with a gloved hand in a thickness of 3–5 mm with or without a covering dressing. As the patient is free to move about in bed, the joint activity is maintained. Usually, twice-a-day application suffices as a means for controlling burn wound sepsis, but reapplication may be required in some areas. During reapplication, the remaining cream on the wound surface has to be wiped off with wet gauze.

Advantages: Mafenide is the most useful topical antibacterial agent for control of established or incipient burn wound sepsis where the bacterial invasion has started or extensive colonization is present. This is mainly because it has the best eschar penetration ability.

JAYPEE BROTHERS

An overall reduction in mortality of 50% was noticed with the use of mafenide in a number of studies.

Disadvantages: Application of mafenide is associated with significant pain which is probably because of its high osmolarity and hygroscopic effect of the sulfonamide suspension. The painful sensation persists for several minutes, thereby earning its nickname of "white lightning". Alternatively, the application of mafenide cream can be limited to no more than 20% of the body surface area (BSA) at any one time. The sites of mafenide applications can then be rotated every 2 hours until the entire burn has been treated. It is also advisable to alternate mafenide and silver sulfadiazine creams on badly contaminated wounds as a form of "pulse therapy". 5% of the patients develop maculopapular rash, which is characteristic of sulfa sensitivity. It can be easily controlled by oral antihistamines. Experiments have shown that its use also leads to inhibition of epithelial regeneration. The most significant complication of the use of topical mafenide is compensated metabolic acidosis, which results from its carbonic anhydrase inhibiting effect that decreases the reabsorption of bicarbonate from the renal tubule. The acidic breakdown product of mafenide adds to the acid load. In addition, the bicarbonate is converted to carbon dioxide in the lung and excreted during hyperventilation, which is a compensatory mechanism. This is usually seen in patients with >40% TBSA burns being treated with mafenide. If the patient is only hyperventilating, it may not be a big problem. However, if the patient shows signs of respiratory distress in the form of use of accessory muscles, the drug has to be immediately removed from the burn wound surface and some other topical antimicrobial agent has to be applied. Additionally, ventilatory support and metabolic support in the form of sodium bicarbonate as per the laboratory test reports are also to be provided in these circumstances. Patients treated with mafenide also exhibit inappropriate polyuria, which results from significant reduction in evaporative water loss from the burn wound (because of 95% water content of the cream base) as well as the osmotic load on the kidney due to the breakdown product of mafenide. Hemolytic anemia is a rare complication seen with the use of mafenide.

Despite its disadvantages, mafenide is still one of the best topical agents for the control of established burn wound infection. Its use should be reserved for a short duration of time and withdrawn before significant side effects become evident.

Gentamicin[11,20,21]

Gentamicin is an aminoglycoside used as a 0.1% ointment or cream in burn wound dressing. It is a relatively safe broad-spectrum antibiotic.

Mode of action: It is primarily bactericidal. It is not effective against viruses or fungi. It is effective against both gram-positive and gram-negative organisms, particularly *Pseudomonas aeruginosa*. It acts by inducing defective protein synthesis. Indiscriminate use of gentamicin for serious systemic infections has shown development of resistant strains.

Technique of application: It is applied as 0.1% ointment or cream as a thin layer to the wound surface twice a day without dressing or with a light dressing. The application is painless and absorption rate from wound is low. Therefore, the incidence of ototoxicity and nephrotoxicity with topical application is negligible.

It has good eschar penetration, but its absorption decreases as the water content of the eschar decreases. Later, as the eschar separates and granulation tissue appears, the rate of absorption of drug again increases. The absorption of the drug is faster if applied as a cream base than from the ointment base. Therefore, if an occlusive dressing is used, it should be applied as ointment rather than as cream.

Advantages: Its application is easy and painless. It actively penetrates the eschar. There is a low incidence of toxicity when used topically and has a good antipseudomonal action.

Disadvantages: If used indiscriminately, there are high chances of developing resistant strains, especially of *Pseudomonas*. There are chances of ototoxicity and nephrotoxicity with prolonged use.

Although gentamicin gives good results as a topical agent on the burn wound, its use should be reserved exclusively for systemic use.

Bacitracin

Despite the lack of efficacy against common gram-negative burn pathogens, bacitracin remains popular in burn care, particularly on partial-thickness face burns. Whether this beneficial effect is due to the antibiotic itself or simply to the bland petroleum base remains controversial.

Less Commonly Used Topical Agents

Chlorhexidine gluconate: It has been used in moderate burn injuries either as such or in combination with 0.5% silver nitrate as a prophylactic agent. Its absorption and toxicity are not documented fully and hence, it is not used routinely.

Povidone iodine (Betadine®): It has been used as a water-miscible base (10%) for burn wound dressing. Though it is effective against gram-negative, gram-positive organisms, fungi, viruses, and protozoa, it has little effect

JAYPEE BROTHERS

on *Staphylococcus* strains. Its use is restricted because of certain disadvantages like its painful application. If used in large quantities in extensive burns, there can be absorption of large quantities of iodine leading to high iodine levels in the blood.

Soframycin, Polymyxin B: These have been used only for dressing of small burn wounds and are not indicated for extensive burns because of systemic toxicity resulting from absorption of these drugs from the extensive wounds.

Newer Dressing Materials

Collagen **(Figs. 14A to C)**: It is a biomaterial that has been shown to provide a moist wound healing environment. The dressing may be in the form of sheets, pads, or gels containing animal-source collagen. Collagen sheet dressings are thin, porous, and flexible, and thus can be applied easily to the wound. Many such dressing materials are available in the market such as Skin Temp,® Diacoll-S,™ Puracol,® and Revitalize-M.™ These are especially useful in superficial dermal burns and can also be used to treat facial burn wounds with exposure method.[22,23]

Hydrofiber dressings **(Figs. 15A to E)**: This consists of nonwoven carboxymethylcellulose fibers that convert into a gel when it comes in contact with wound fluid. This aids in creating an optimal environment for wound healing by locking in the moisture. The dressing material contours well to the wound bed, thus minimizing any dead space. Aquacel® is a hydrofiber dressing material, and benefits of silver are also available in another version of this dressing material. Aquacel Ag® incorporates 1.2% silver, which is released in a controlled manner into the wound.[24]

Polyurethane foam dressing **(Figs. 16A to C)**: This is a nonadhesive dressing material that absorbs the exudates and retains moisture to optimize wound healing. It conforms closely to the wound bed owing to its foam structure. Biatain Ag® is one such dressing that also incorporates a patented silver complex that is



FIGS. 14A TO C: (A) Superficial dermal burns; (B) Dressing with collagen sheet—skin Temp® (C) Healed scar.

JAYPEE BROTHERS



FIGS. 15A TO E: (A) Superficial dermal burns on hand; (B) Blister debrided; (C) Dressing with hydrofiber (Aquacel Ag® Gloves); (D) Healed area after 1 week; (E) Scar after 6 months.

JAYPEE BROTHERS

released slowly into the wound for a sustained action. Mepilex Ag® is also a foam dressing that has a soft silicone wound contact layer.[25]

Nanocrystalline silver **(Figs. 17A to E)**: In the traditional silver containing antimicrobial agents, such as silver nitrate and SSD, most of the silver carries a strong positive electrical charge which makes it highly soluble, but it also reacts readily with substances such as chloride from the salt in the wound forming silver chloride which is ineffective. Most of these compounds allow an initial release of silver ions and then are rapidly inactivated. Therefore, it is necessary to apply these agents frequently.



FIGS. 16A TO C: (A) Deep dermal burns of back; (B) Dressing with Mepilex Ag® foam dressing; (C) Healed area after 2 weeks.



FIGS. 17A TO E: (A) Superficial to deep dermal burns of the back; (B) Nanocrystalline silver dressing (ACTICOAT)® applied to the burns on the back; (C) Wound in healing phase after first dressing with ACTICOAT®; (D) Wound almost healed after three dressings with ACTICOAT, i.e., after 12 days, showing gray staining because of metallic silver; (E) Same patient after 1 month with well-settled scars.

JAYPEE BROTHERS

The newer nanocrystalline dressings such as Acticoat™ provide sustained bactericidal action due to the presence of Ag^0 form of silver, which is far less deactivated. Ag^0 is the uncharged form of metallic silver. Free silver cations have a potent antimicrobial effect, which destroys micro-organisms immediately by blocking cellular respiration and disrupting the function of bacterial cell membranes. They act by binding to tissue proteins, causing structural changes in the bacterial cell membranes, which in turn cause cell death. Silver cations also denature the bacterial deoxyribonucleic acid (DNA) and ribonucleic acid (RNA), thus inhibiting cell replication.

Nanocrystalline dressings are layered dressing constructs of a silver mesh containing silver nanocrystals applied to either side of a rayon/polyester core. They are manufactured by passing electric current through a chamber containing Argon gas that acts as an anode and silver as a cathode. The silver atoms knocked out are deposited on the substrate as nanocrystals measuring around 15 nanometers across, containing 30–50 atoms resulting in a metastable, high energy form of silver, by a process called physical vapor deposition. The smaller the particles of silver, the greater the wound surface area that will be in contact with silver, thus increasing bioactivity and silver solubility. These dressings release as much as 30 times less silver than other topical products but the silver released is more effective as it is not bound by halide and is released over a longer period of time.

In vitro and animal studies have shown that the nanocrystalline dressings are effective against a broad spectrum of microorganisms including the most common strains of bacteria, multiresistant organisms, and fungal spores. They have been shown to reduce the number of viable bacteria to very low levels within 30 minutes of application. These can be left in place for a longer period of time reducing wound manipulation and causing less trauma to the new epithelial growth. Apart from the antibacterial effects, these also decrease the level of matrix metalloproteinases (MMP) in patients with chronic wounds. Human studies show that nanocrystalline dressings are cost-effective, reduce burn wound infection, have decreased pain levels during dressing changes, and reduce bioburden. Additionally, they have no in vivo evidence suggestive of toxicity against keratinocytes and fibroblasts.

Nanocrystalline dressings are thus an effective way to manage burn wounds. They are effective at reducing inflammatory process, promote wound healing, and are less toxic than other forms of silver dressings.[26-28]

Summary

The use of topical antimicrobial agents in burn wound care can prevent or minimize burn wound infections and sepsis. It is important to understand that any one single topical agent cannot be used in all patients in all circumstances. All agents are effective if used in the right circumstances, and at the same time, indiscriminate use of any one single agent can be harmful in the long run. It is, therefore, imperative to use the topical antimicrobial agents judiciously, selecting the right agent for the right patient at the right time. Thus, the main aim of topical therapy is to control burn wound sepsis and improve the condition of the deep wounds so that they can be closed as early as possible by skin grafting/flap cover.

ROLE OF ESCHAROTOMY/FASCIOTOMY

In full-thickness circumferential burns of limbs, neck, and chest, the tight dry eschar with underlying edema may produce a tourniquet effect resulting in ischemic injury. This has to be diagnosed early in order to avoid vascular compromise to distal extremities and respiratory impairment. The following clinical signs and symptoms are indicative of ischemia: Cyanosis of distal unburned skin, delayed capillary filling in nails of fingers or toes, and paresthesias or deep tissue pain. This can be confirmed by a reduced flow on a color Doppler. An early escharotomy is warranted in such cases to prevent ischemic changes from setting in. An incision made through the full thickness of the eschar releases the constricting effect **(Figs. 18A and B)** and decompresses the underlying structures, thus improving the distal blood supply.[29,30]

Technique: The procedure is done bedside using a sterile technique. Anesthesia is not required as the eschar is dead tissue, and hence painless. Sites for incisions for escharotomy are given in **Figures 18A and B**; care should be taken to avoid injury to major peripheral nerves. The

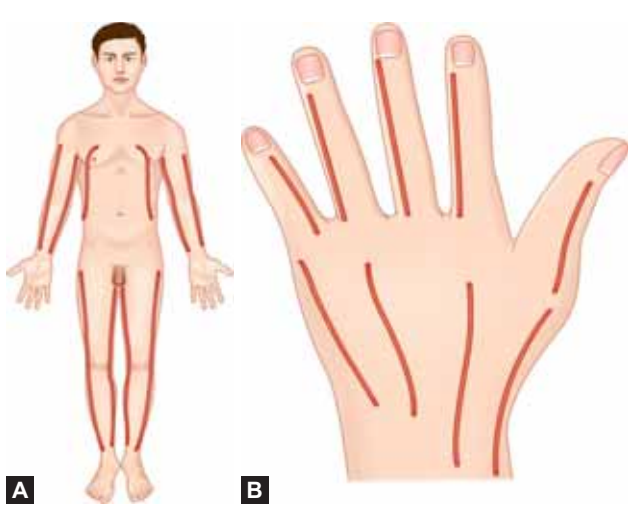

FIGS. 18A AND B: (A) Escharotomy incision lines; (B) Escharotomy incisions for hand.

JAYPEE BROTHERS

for detailed information on plastic surgery books, visit our website www.jaypeebrothers.com, for detailed information on plastic surgery books, visit our website www.jaypeebrothers.

Principles and Practice of Burn Care

Salient Features

- Updated information: Reflecting the latest advancements and practices in burn care, with revised chapters
- Evidence-based protocols: Incorporating the latest evidence-based guidelines for effective burn management
- Enhanced visual learning: More than 200 color illustrations, photographs, for enhancing comprehension and engagement
- Multidisciplinary approach: Emphasizing collaboration across disciplines for optimal burn patient outcomes and rehabilitation
- Diverse contributions: Combining expertise from experienced practitioners and fresh perspectives for a comprehensive learning experience
- Educational value: Serving as an invaluable resource for both practicing surgeons and students

This book provides a comprehensive and up-to-date overview of critical developments in burn care, covering a wide range of topics and interests within the discipline. It uniquely emphasizes a multidisciplinary approach, ensuring a holistic understanding of burn management.

Sujata Sarabahi MBBS MS MCh DNB MNAMS is a Professor, Consultant, and Head of the Department of Burns and Plastic Surgery, Vardhman Mahavir Medical College (VMMC) and Safdarjung Hospital, New Delhi, India. With her extensive experience and expertise in the field burn care, she provides valuable insights and guidance in compiling this comprehensive overview of developments in the subject. She is currently the President Elect, National Academy of Burns, India (2025–2026). Her areas of research interest are burn sepsis markers, postburn reconstruction, dermal templates, and prevention of burn injury in community.

VK Tiwari MBBS MS MCh is currently serving as Dean at NDMC Medical College and Hindu Rao Hospital, New Delhi, India. He has previously worked as Professor and Consultant Plastic Surgeon in the Department of Burns and Plastic Surgery, Vardhman Mahavir Medical College and Safdarjung Hospital, as well as Head of Department, Ram Manohar Lohia Hospital, New Delhi. A devoted teacher and surgeon par excellence, his insights and experience provide a well-rounded perspective in this book. He is also a reviewer for various national and international journals.

Arun Goel MBBS MS MCh FICS is a Consultant and Head of Unit, Department of Burns, Plastic, Maxillofacial and Microvascular Surgery, Lok Nayak Hospital and Associated Maulana Azad Medical College, New Delhi (Superannuated), India, served at his alma mater for more than 38 years. He is very popular among his students for his endeavor for teaching and has shaped the lives of many. He was the recipient of "Distinguished Teacher Award" from Association of National Board Accredited Institutions (2019). Closely associated with the Indian Journal of Burns as its Assistant Editor for 5 years since its inception in 1993, Dr Goel has numerous publications in textbooks and national and international journals. He has extensive experience in reconstructive surgery for burns, extremity trauma and wound management, and has been dedicated to the service of the needy.

Suvashis Dash MBBS MS MCh is Assistant Professor, Department of Plastic Surgery, All India Institute of Medical Sciences, New Delhi, India. Dr Dash has contributions, particularly in addressing modern advancements and challenges in burn surgery and care. He represents South-East Asia Region in the Burn Care Committee of the International Society of Burn Injury.

Together, this esteemed editorial team brings a wealth of knowledge, experience, and dedication to the compilation of this book, ensuring that it serves as a valuable resource for professionals and students in the field of burn care.

Printed in India

Available at all medical bookstores or buy online at www.ejaypee.com

JAYPEE BROTHERS
Medical Publishers (P) Ltd.
EMCA House, 23/23-B, Ansari Road,
Daryaganj, New Delhi - 110 002, INDIA
www.jaypeebrothers.com

Join us on facebook.com/JaypeeMedicalPublishers
Follow us on instagram.com/JaypeeMedicalPublishers

Shelving Recommendation
PLASTIC SURGERY

ISBN 978-93-5696-770-0