matology books, visit our website www.jaypeebrothers.com, for detailed information on dermatology books, visit our website www.jaypeebrothers.com, for detailed information on dermatology books

2nd Edition






Manual of DERMATOLOGY in General Practice




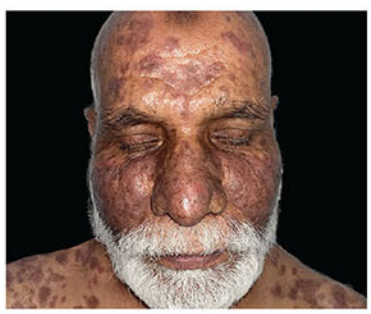

Prof Dr Md Rokon Uddin

JAYPEE

Contents

1. Basic Principles and Cutaneous Signs and Symptoms 1
2. Pruritus and Dysesthesia 11
3. Psoriasis and Related Disorders 13
4. Dermatitis (Eczema) 31
5. Psychoneurodermatitis 45
6. Urticaria and Angioedema 52
7. Erythema Multiforme, Stevens–Johnson Syndrome, Toxic Epidermal Necrolysis, and Fixed Drug Eruption 55
8. Environmental and Occupational-related Dermatoses 63
9. Endocrine, Metabolic, and Nutritional Diseases 67
10. Genetic Diseases of Skin (Genodermatosis) 83
11. Cutaneous Signs of Systemic Disease 94
12. Cutaneous Manifestation of Bacterial, Viral, Protozoal, Worm, Fungal Infection, and Other Infections/Infestation 96
13. Bullous Diseases (Genetic, Autoimmune and Acquired) 161
14. Rheumatologic Dermatology 171
15. Neutrophilic Dermatosis 186
16. Disorders of Sebaceous, Eccrine, and Apocrine Glands 190
17. Hair, Nail, and Mucous Membrane 197

Index 215

CHAPTER

3

Psoriasis and Related Disorders

JAYPEE BROTHERS

INTRODUCTION

- Psoriasis is a common skin disease. It affects up to 2% of the populations.
- Chronic inflammatory disease of skin, mucous membrane, nails, and joints with polygenic predisposing and triggering factors such as infections [especially streptococcal pharyngitis and human immunodeficiency virus (HIV) infection], minor trauma, anxiety, or drugs [beta-blockers, lithium, antimalarial drugs, interferon, systemic corticosteroids (rebound), etc.]. Alcohol ingestion is a putative trigger factor.
- Well-demarcated, erythematous papules and plaques with silvery white scale are most common presentation **(Figs. 1 to 17)**. Common sites are scalp, extensor elbow and knee, palm sole, back of trunk (intergluteal folds), and nails **(Fig. 18)**.
- Other lesions are sterile pustule, and glistening plaque in intertriginous areas **(Figs. 19 to 22)**.
- Major systemic association is psoriatic arthritis. Psoriatic arthritis occurs in 5–30% of patients.
- *Koebner phenomenon*: Isomorphic new lesions at the site of trivial injury.



FIG. 1: Erythematous plaques with thick scale and desquamation on left shin.



FIG. 2: Bilateral symmetrical erythematous papule-plaque with silvery white scale over both extensor forearms.



FIG. 3: Well-defined psoriatic plaque not crossing hair line.



FIG. 4: Symmetric distribution of psoriatic plaque.



FIG. 5: Erythematous plaques with thick asbestos like scales over scalp of a 3-year-old child.



FIG. 6: Guttate psoriasis on back of trunk.



FIG. 7: Widespread chronic plaque psoriasis.



FIG. 8: Chronic stable plaque psoriasis on both extensor forearm.

JAYPEE BROTHERS



FIG. 9: Thick plaque on dorsum of foot easily confused with chronic eczema [lichen simplex chronicus (LSC)].



FIG. 10: Large scaling plaque on left thigh. Lesions are polycyclic and confluent forming geographic pattern.



FIG. 11: Repeated trauma resultant psoriatic plaque on forehead.



FIG. 12: Psoriatic nail change (thick nail plate).

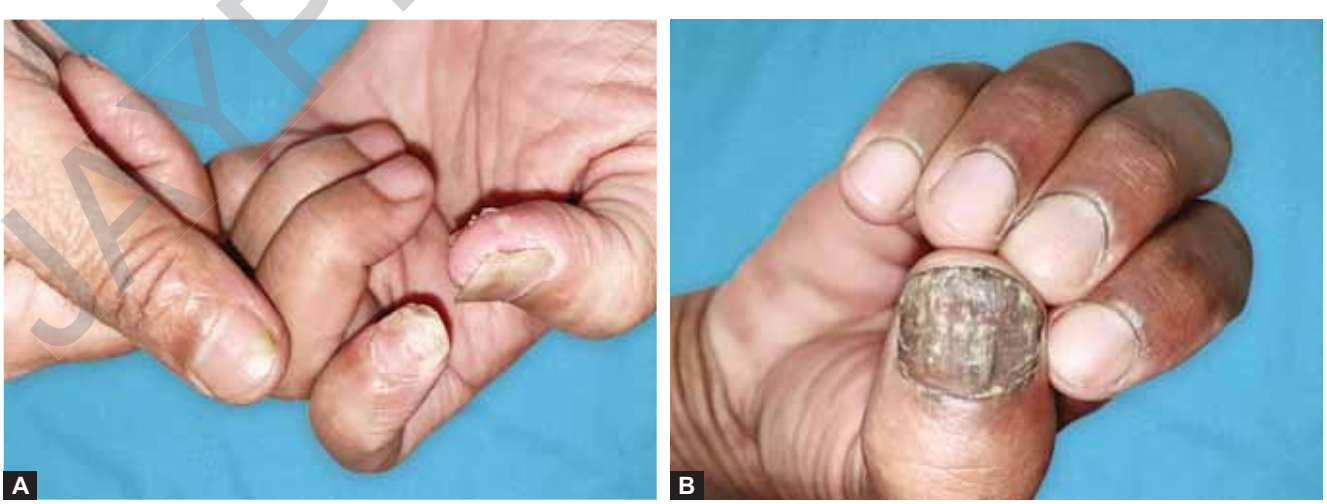

FIGS. 13A AND B: Pitting, onycholysis, thickening of nail plate on a psoriasis patient.

JAYPEE BROTHERS







FIGS. 14A TO C: Plantar psoriasis. Thick scale.

JAYPEE BROTHERS



FIG. 15: Erythematous plaque with silvery white scale involving extensor upper extremity and right periareolar region.



FIG. 16: Involvement of skin, nail, and joint.



FIG. 17: Treated case: Hypopigmented patches just like pityriasis alba.

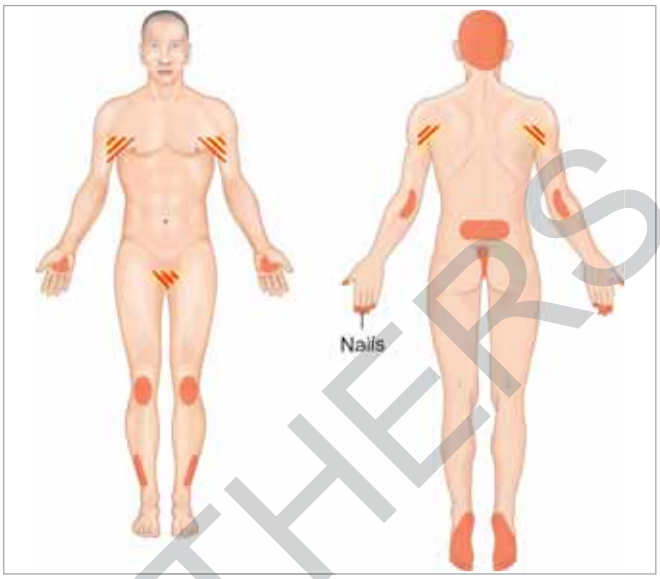

FIG. 18: Common sites where psoriasis occur.



FIG. 19: Glistening plaque (inverse pattern psoriatic) on groin that mimic tinea cruris.



FIG. 20: Erythematous papule plaque on groin, glans penis in inverse pattern.





FIGS. 21A AND B: Creamy-yellow pustule that are confluent in some areas. Pustules are sterile and pruritic and when get larger, become painful.

JAYPEE BROTHERS



FIG. 22: Inverse pattern psoriatic plaque on submammary region.

COMMON SITES OF PSORIASIS

Common sites of psoriasis are shown in **Figure 18**.

Variants

- **Chronic plaque psoriasis:**
  - Typical lesion—well-demarcated, erythematous plaque with silvery scale
  - Often symmetrical lesions on the elbows and knees **(Figs. 2, 7, and 8)**, additional sites includes the scalp **(Figs. 3 and 5)**, presacral **(Fig. 4)**, hands **(Fig. 16)**, feet **(Figs. 9 and 14)**, intergluteal fold **(Figs. 19 and 20)** and umbilicus
  - It may be generalized.
- **Guttate psoriasis:**
  - Typical lesion—small papules or plaque (3 mm to 1.5 cm) with adherent scale **(Fig. 6)**
  - It affects children more than adults.
  - Usually, it is preceded by an upper respiratory tract infection.
  - In children, it may have spontaneous remission but often responds well to ultraviolet B (UVB).
- **Linear psoriasis:** Linear, erythematous, and scaly lesions that often follow the lines of Blaschko.
- **Erythrodermic psoriasis:**
  - Generalized erythema, plaques with scaling
  - Gradual or acute onset
  - Nail changes, facial sparing, and a history of typical plaque type psoriasis may be helpful clues.
  - It may be seen after abrupt tapering of medication, especially CS.
- **Pustular psoriasis:**
  - Generalized pustular psoriasis (von Zumbusch pattern)
  - Erythema and sterile pustules arising within erythematous, painful skin; lakes of pus characteristic **(Figs. 21A and B)**
  - Often associated with fever
  - Triggering factors—pregnancy (termed impetigo herpetiformis), rapid tapering of corticosteroids (CS), hypocalcemia, and infections.
- **Palmoplantar pustulosis:**
  - Sterile pustules on palms/soles
  - It may have no evidence of psoriasis elsewhere
  - Triggering factors—infections, stress, and smoking
  - Associated with inflammatory bone lesions

Special Sites

- Scalp psoriasis:
  - Well-demarcated, erythematous plaques with silvery scale
  - Scales may be attached for some distance onto scalp hairs, giving an asbestos like appearance.
  - Occasionally, alopecia may be seen within lesions **(Figs. 3 and 5)**.
- Inverse psoriasis:
  - Shiny, pink, well-demarcated thin plaques with minimal scale
  - Common sites include the axilla, inguinal crease, intergluteal cleft, and inframammary are and retroauricular fold.
  - Mucous membrane:
    - Migratory, annular lesions with central denuded areas and white borders
    - Similar to geographic tongue clinically and histopathologically
- **Nail changes:**
  - Fingernails are more affected than toenails.
  - It is associated with psoriatic arthritis.
  - Findings—nail pitting, oil spots (salmon patch), onycholysis with proximal red rim, splinter hemorrhages, and subungual debris

INVESTIGATIONS

Skin biopsy for histopathological examinations confirmation.

Psoriatic Arthropathy (Figs. 23A to C)

- It occurs in about 5–30% of patients with psoriasis.
- Most commonly as an asymptomatic oligoarthritis affecting the distal interphalangeal joints
- More rarely but classically is arthritis of all the interphalangeal joints.
- Occasionally presented as rheumatoid arthritis like, affecting small and medium-sized joints symmetrically.

JAYPEE BROTHERS



FIGS. 23A TO C: Psoriatic arthropathy changes.

JAYPEE BROTHERS

Reactive Arthritis (Previously Referred to as Reiter's Disease)

- Urethritis, arthritis, ocular findings (conjunctivitis), and oral ulcers in addition to psoriasiform lesions especially on the sole [keratoderma blennorrhagicum **(Figs. 24A and B)**] or genital (balanitis circinata).
- This disease occurs chiefly in young men of HLA-B27 genotypes, generally following a bouts of urethritis or diarrheal diseases.
- Course is often self-limited.

TREATMENT

Topical Agents

- *First line*:
  - Topical corticosteroid (e.g., clobetasol propionate)
  - Vitamin D3 analog (calcipotriene and calcitriol)
- *Second line*:
  - Calcineurin inhibitor (tacrolimus may be first line for sensitive areas)
  - Tars
  - Anthralin
  - Tazarotene

Systemic Agents

- *First line*:
  - Phototherapy: UVB and psoralen plus ultraviolet A (PUVA)
  - Methotrexate (MTX)
  - Oral retinoids (e.g., acitretin and isotretinoin)
- *Second line*:
  - Targeted immunomodulators (biological agents)
  - Cyclosporine





FIGS. 24A AND B: Plantar lesions of keratoderma blennorrhagicum.

Adalimumab

Adalimumab is a recombinant human immunoglobulin G1 (IgG1) monoclonal antibody specific for tumor necrosis factor (TNF). It binds specifically to TNF-α and blocks its interaction with the p55 and p75 cell surface TNF receptors. TNF is a naturally occurring cytokines that is involved in normal inflammation and immune responses. In psoriatic arthritis, nail psoriasis and plaque type psoriasis adalimumab bring excellent outcome.

Secukinumab

Secukinumab works by selectively binding to interleukin-17A (IL-17A) which is main proinflammatory cytokines produced by T-helper cells. IL-17A mediates innate immunity to infecting substances and it can also contribute to the development of chronic disease characterized by inflammation.

Cyclosporine

Cyclosporine is most often used for recalcitrant psoriasis that does not respond to other systemic treatments.

Cyclosporine can provide rapid relief from symptoms. Some improvement symptoms after two weeks of treatment, particularly with stronger doses. However, it may take from three to four months to reach optimal control. Cyclosporin is usually used for the induction of psoriasis remission at a daily dose included in the range of 2.5–5 mg/kg and with intermittent short-term regimens, lasting on average 3–6 months. The magnitude and rapidity of response are dose dependent, as well as the risk of development of adverse events. Therefore, the dose should be tailored to patient's needs and general characteristics and adjusted during the treatment course according to both the efficacy and tolerability.

Adverse effects:

- Decreased kidney function
- Headache
- High blood pressure
- High cholesterol
- Excessive hair growth
- Tingling or burning sensation in the arms or legs
- Skin sensitivity
- Increased growth of gum tissues
- Flu-like symptoms
- Upset stomach
- Tiredness

Contraindication:

- A compromised immune system
- Abnormal kidney function
- High blood pressure
- Cancer, or a history of cancer (other than basal or squamous cell skin cancers)
- Severe gout
- Pregnant or breastfeeding
- Undergoing radiation treatment

Individuals previously treated with methotrexate or other immunosuppressive agents, PUVA, UVB, coal tar, or radiation therapy are at an increased risk of developing skin cancer when taking cyclosporine. Additional risks with cyclosporine include kidney damage.

Methotrexate

Indication:

- Chronic plaque psoriasis [>10% bovine serum albumin (BSA) or interference with employment or social functioning]
- Pustular psoriasis
- Erythrodermic psoriasis
- Psoriasis arthritis

JAYPEE BROTHERS

- Severe nail psoriasis
- Psoriasis is not responding to topical tacrolimus, photo therapy, and/or systemic retinoids.

Contraindication:

- *Absolute*:
  - Severe anemia, leukopenia, and/or thrombocytopenia
  - Significant liver function test (LFT) abnormalities
  - Concomitant medications that increased MTX level, e.g., trimethoprim/sulfamethoxazole.
  - Significant reduced pulmonary fibrosis
  - Pregnancy or lactation
  - Severe infections
  - Peptic ulcer (active)
  - Hypersensitivity of MTX
  - Unreliable patient
- *Relative*:
  - Impaired kidney infections (creatinine clearance <60 mL/min)
  - Concomitant hepatotoxic medications
  - Currently planning to have children (discontinue MTX 3 months prior to attempts to conceive)

PITYRIASIS ROSEA

- The etiology is unknown, but viral infections may serve as a trigger.
- It occurs most commonly in adolescents and young healthy adults.
- Pityriasis rosea is an acute erythematous eruption (pink to salmon-colored papules or plaque) with their long axis following Langer's lines of cleavage **(Figs. 25 and 26)**, creating a "Christmas tree" pattern on the trunk.

Initially, a single (primary or herald) plaque lesion develops with a collarette scale on the trailing edge of the advancing border. Usually on the trunk, 1–2 weeks later, a generalized secondary eruption develops.

The average duration of illness is 6–8 weeks, while some cases last for months.

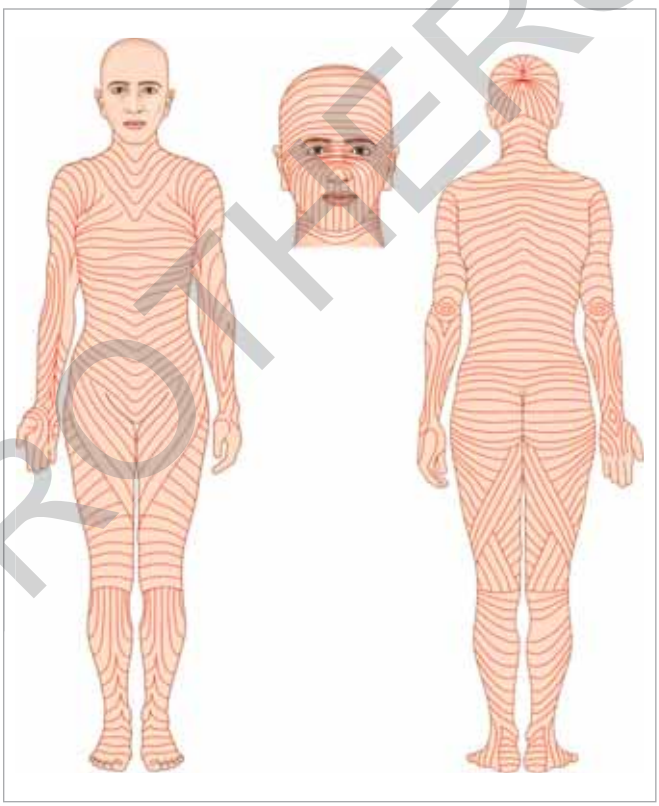

FIG. 25: Langer's lines of cleavage.

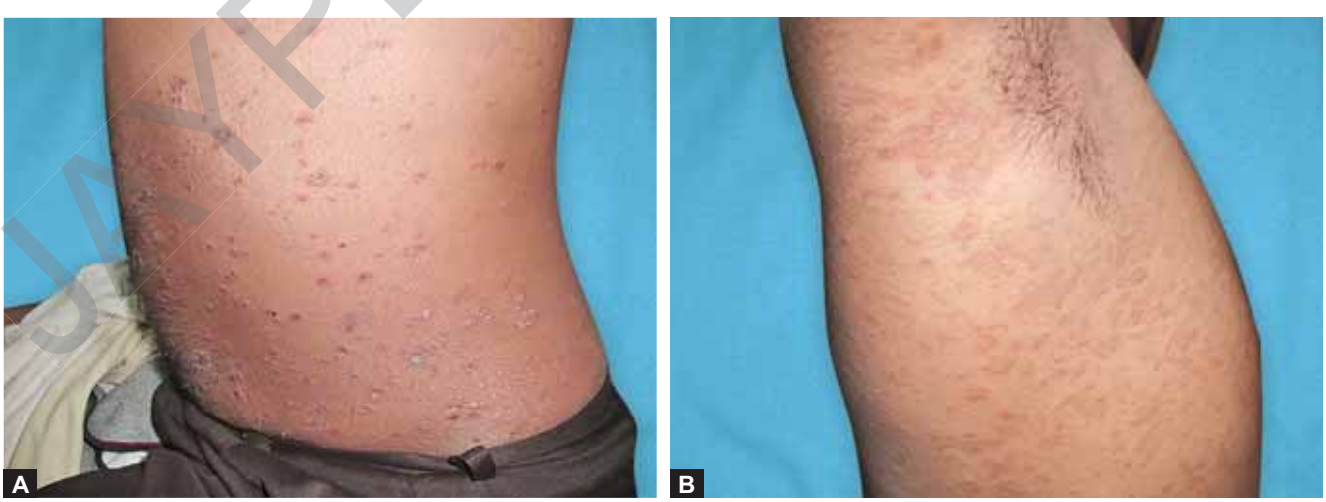

FIGS. 26A AND B: Papule and plaque with oval configurations that follow the lines of cleavage. Plaque has collarette scale in which scale attached at periphery and loose toward the center of lesion.

JAYPEE BROTHERS

Diagnosis

Biopsy and histopathological examination.

Treatment

- Topical antipruritic lotion or corticosteroid
- Natural sunlight
- 14 days course of erythromycin or 10 days course of azithromycin

PITYRIASIS RUBRA PILARIS

- Rare, chronic, papulosquamous disorder often progressive to erythroderma of unknown etiology.
- Characterized by a salmon or orange red color **(Figs. 27 to 30)**, islands of sparing, follicular papules, and waxy keratoderma
- It may be exacerbated by exposure of UV light; classic form spontaneously resolves with 3–5 years.

Diagnosis

- Diagnosis is made on clinical grounds.
- Confirmation by biopsy and histopathology examination

Treatment

- Topical therapies consist of emollients, keratolytic agents, vitamin D3 (calcipotriol), glucocorticoids, and vitamin A analogue (tazarotene).
- Oral isotretinoin, acitretin, MTX, TNF-α inhibitors response within 6 months.



FIG. 27: Orange-red follicular papules. These are sharply demarcated islands of unaffected normal skin.



FIG. 28: Diffuse waxy hyperkeratosis of left palm with an orange hue.



FIGS. 29A AND B: Diffuse, waxy hyperkeratosis of both palm and sole.

JAYPEE BROTHERS

LICHEN PLANUS AND LICHENOID DERMATOSES

Lichen Planus

- Lichen planus (LP) is an acute or chronic inflammatory dermatosis involving skin, nail, and/or mucous membrane (oral, vulvovaginal) of unknown origin **(Figs. 31 to 41)**.
- Characterized by flat topped (lichenoid) papules; pink to violaceous, shiny, and pruritic polygonal papules **(Figs. 42 and 43)**.
- For easy remember 4P: Papule, purple, polygonal, and pruritic
- A characteristic finding is Wickham's striae, a network of fine white lines on the surface of papules and plaques **(Fig. 44)**.



FIG. 30: Widespread involve—pityriasis rubra pilaris.



FIGS. 31A TO D: Violaceous papules and plaques on mucous membrane of different sites.

JAYPEE BROTHERS

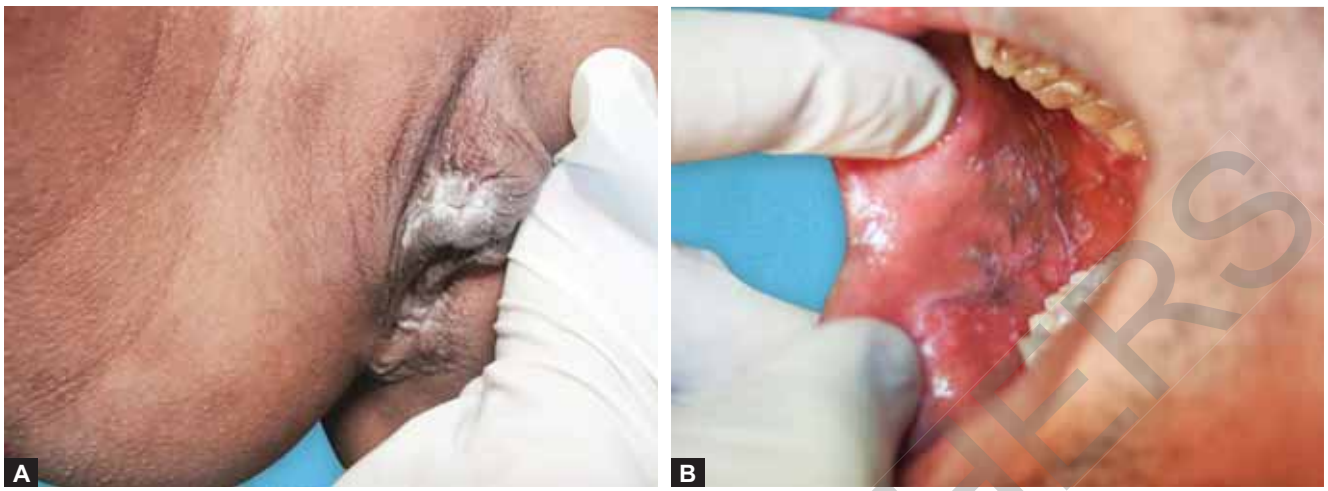

FIGS. 32A AND B: Hyperkeratotic papules plaque; reticular, lacy pattern on mucous membrane.

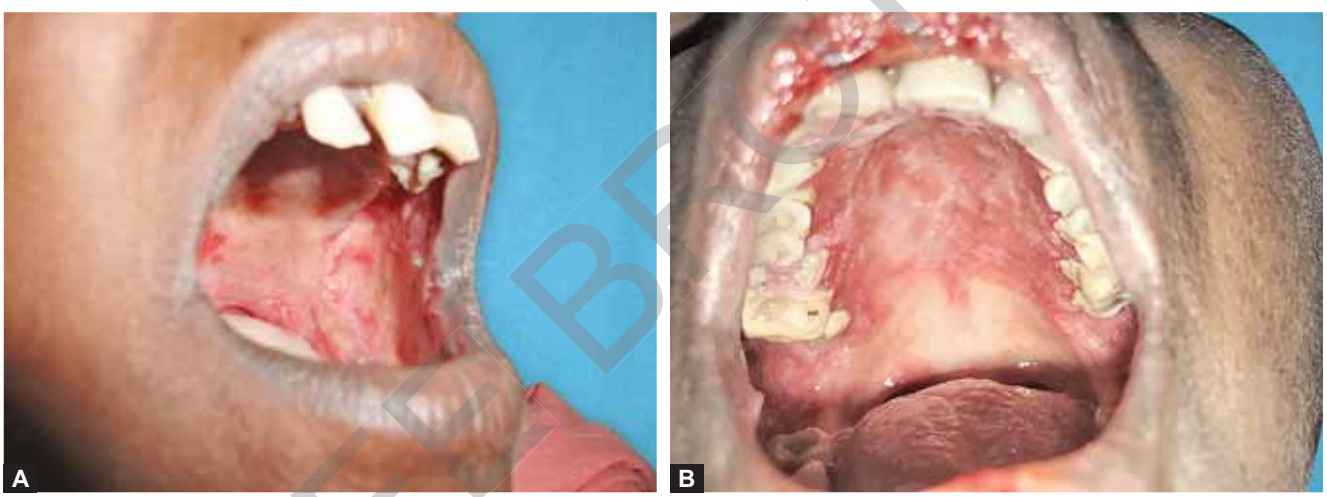

FIGS. 33A AND B: Erosive pattern on mucous membrane.

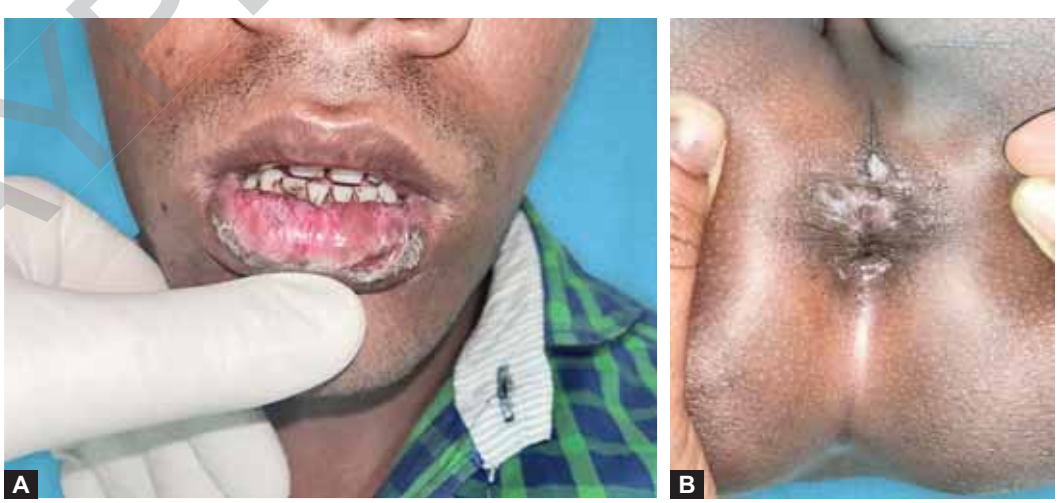

FIGS. 34A AND B: Erosive, ulcerative, and scarring of mucous membrane.

JAYPEE BROTHERS

for detailed information on dermatology books, visit our website www.jaypeebrothers.com, for detailed information on dermatology books, visit our website www.jaypeebrothers.com, for detailed infor

Manual of DERMATOLOGY in General Practice

Salient Features

- Over 900 vivid color photographs capturing diverse skin conditions: Common, rare, typical, and atypical
- Up-to-date coverage of new and emerging skin diseases' cutaneous manifestations
- Streamlined approach for easy diagnosis and treatment in clinical practice
- Incorporates new treatment modalities based on the latest clinical findings and treatment guidelines
- Concise yet comprehensive overview of key clinical features, etiology, prognosis, and the latest therapeutic approaches

Prof Dr Md Rokon Uddin currently holds the esteemed position of a Consultant within the Department of Dermatology and Laser Unit at Bangladesh Specialized Hospital (BSH). He earned his Medical Degree from Dhaka Medical College in 1998, situated in Dhaka, Bangladesh. Subsequently, he completed his Diploma in Dermatology from BSMMU in 2002, further enhancing his expertise in the field. Following his academic achievements, he garnered invaluable experience by dedicating his skills and knowledge to several reputable medical colleges in Bangladesh.

Prof Dr Md Rokon Uddin stands as a stalwart figure in the medical community, serving as one of the founding Directors of Bangladesh Specialized Hospital and assuming the pivotal role of General Secretary for the Bangladesh Medical Teachers Welfare Trust. His enduring dedication to the field of medicine is exemplified through his role as a passionate educator and mentor. Renowned for his precision in clinical diagnosis, he has become a source of inspiration for young dermatologists. Dr Md Rokon Uddin's commitment to his patients and his significant contributions to medical education make him a highly respected and influential professional in the realm of dermatology.

Prof Dr Md Rokon Uddin holds the prestigious distinction of being the first Bangladeshi dermatologist to author an international book on dermatology. This remarkable accomplishment underscores his expertise and scholarly contributions to the field. As a trailblazer in the realm of dermatology, his groundbreaking work has not only enriched the medical literature but has also elevated the reputation of Bangladeshi professionals on the global stage. Dr Md Rokon Uddin's achievement in writing an international book is a testament to his profound knowledge, dedication, and significant impact on the advancement of dermatological expertise worldwide.

Printed in India

Available at all medical bookstores or buy online at www.jaypeebrothers.com

JAYPEE BROTHERS
Medical Publishers (P) Ltd.
EMCA House, 23/23-B, Ansari Road,
Daryaganj, New Delhi - 110 002, INDIA
www.jaypeebrothers.com

Join us on facebook.com/JaypeeMedicalPublishers

Shelving Recommendation
DERMATOLOGY

ISBN 978-93-5696-853-0