matology books, visit our website www.jaypeebrothers.com,for detailed information on dermatology boo

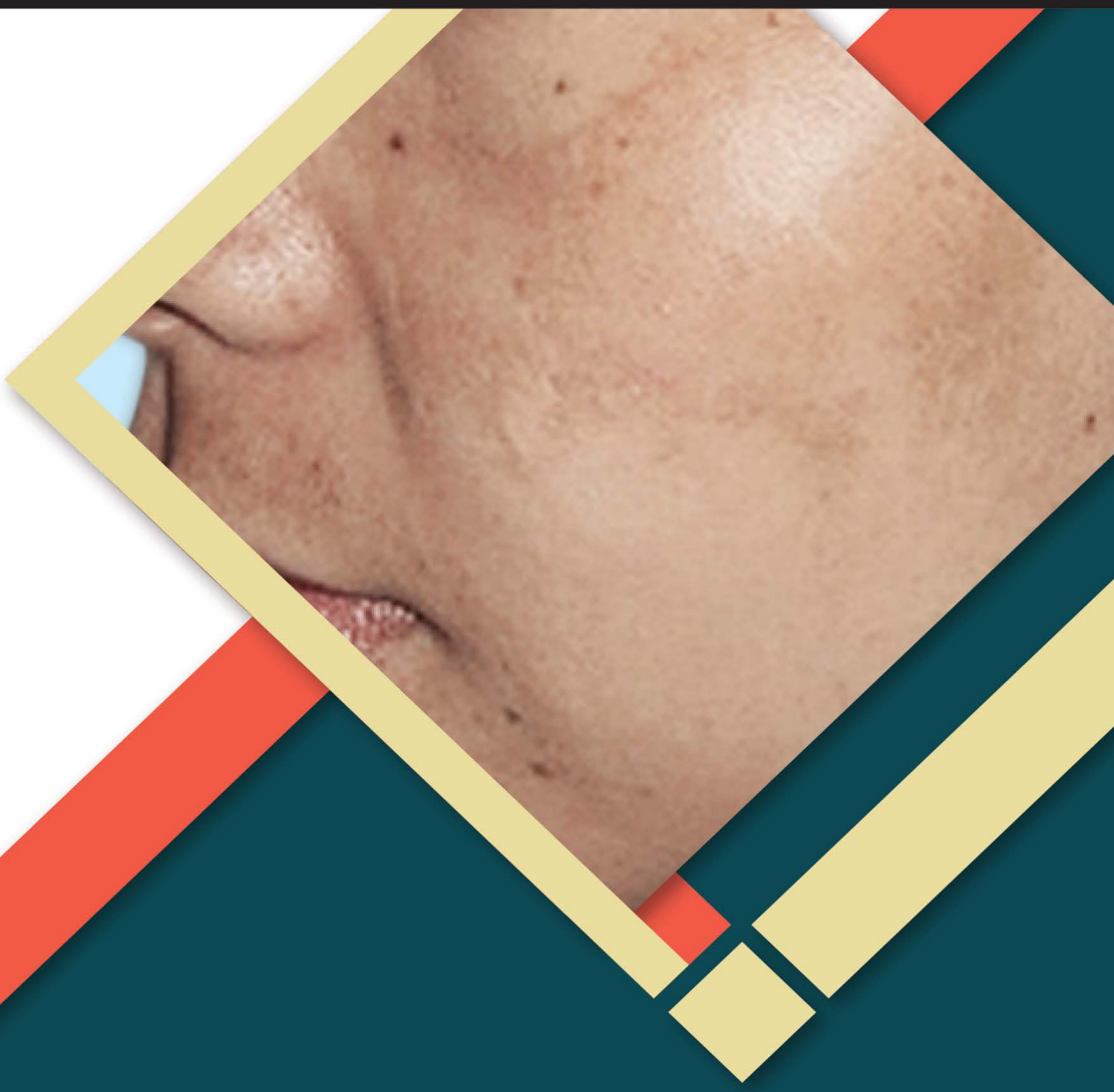

Melasma
A Monograph

Editor
Rashmi Sarkar

4th Edition

JAYPEE

Contents

1. **Epidemiology and Global Distribution of Melasma** 1
   Nokubonga Khoza, Ncoza Dlova, Anisa Mosam

2. **Etiological Factors and Triggering Factors** 5
   Hee Young Kang

3. **Etiopathogenesis of Melasma** 8
   Vignesh Narayan R, Rashmi Sarkar

4. **Clinical Features and Classification of Melasma, Wood's Lamp, and Melasma Area Severity Index Score** 29
   Shreya Deoghare

5. **Investigation in Melasma: Histopathology, and In Vivo Reflection Confocal Microscopy in Melasma** 36
   Hee Young Kang

6. **Investigation in Melasma: Dermoscopy in Melasma** 41
   Saloni Katoch

7. **Photoprotection for Melasma** 49
   Vignesh Narayan R, Rashmi Sarkar

8. **Hydroquinone-based Therapies for Melasma** 64
   Rashmi Sarkar, Shivani Bansal

9. **Nonhydroquinone-based Therapies for Melasma** 74
   Latika Arya

10. **Oral Agents in the Treatment of Melasma** 85
    Maria Suzanne L Datuin, Evangeline B Handog

11. **Chemical Peels for the Treatment of Melasma** 94
    Shehnaz Arsiwala, Nazneen Arsiwala (Lokhandwala)

12. **Lasers in Melasma** 109
    Pooja Arora Mrig, Rashmi Sarkar, Neha Meena

13. Melasma and Quality of Life **120**
Soumya Jagadeesan, Smruthi T

14. Melasma in Men **129**
Rashmi Sarkar, Surabhi Sinha

15. Postinflammatory Hyperpigmentation **141**
Shivani Bansal, Rashmi Sarkar

16. Platelet-rich Plasma Therapy, Microneedling, and Mesotherapy for the Treatment of Melasma **154**
Rashmi Sarkar, Chingshubam Bikash

17. Treatment of Melasma: Current Understanding and Future Trends **160**
Anuva Bansal, Pallavi Ailawadi, Rashmi Sarkar

18. Blue Light in Melasma **179**
Pooja Pandey, Rashmi Sarkar

***Appendix*: Treatment Algorithm for Melasma** **183**

Index **185**

3

CHAPTER

Etiopathogenesis of Melasma

Vignesh Narayan R, Rashmi Sarkar

JAYPEE BROTHERS

INTRODUCTION

Melasma, one of the most prevalent conditions involving excessive skin pigmentation, can be quite vexing. Despite taking the best precautions, it inevitably reoccurs, and dermatologists can only manage its effects rather than offering a definitive cure. Although there has been a continuous effort to uncover the underlying causes and mechanisms behind melasma, its exact origin remains unclear, making treatment a complex challenge. Over the past 10 years, modern techniques such as dermoscopy, in vivo reflectance confocal microscopy (RCM), and immunohistochemistry from tissue samples have shed light on its development, while traditional theories about its origin are still relevant, new ideas that have emerged require further validation. There are two main sets of factors that appear to play a significant role—firstly, inherent factors such as genetic predisposition and skin vasculature, and secondly, external triggers such as sex hormones and exposure to ultraviolet (UV) light.

EPIDERMAL HYPERPIGMENTATION: THE MAIN CULPRIT

Melasma has conventionally been categorized as epidermal, mixed, or dermal. This classification based on Wood's lamp examination has been popular, with epidermal melasma showing intensified pigmentation within lesions, dermal melasma lacking enhancement of pigmentation, and mixed melasma displaying a combination of enhancing and nonenhancing areas; however, this concept has become obsolete due to a recent in vivo study using RCM, which revealed an uneven distribution of melanophages across various parts of melasma lesions and even within a specific region of a lesion. These findings cast significant uncertainty on the existence of strictly "true epidermal" or "true dermal" melasma, strongly suggesting that all forms of melasma are essentially mixed in nature.[1]

The distinguishing feature of melasma-affected skin is now understood to be the heightened production of melanin within epidermal melanocytes, leading to

epidermal hyperpigmentation. This phenomenon has been supported by a study on 56 Korean patients, where a significant 83% surge in epidermal pigmentation was observed in the affected skin. This finding was further substantiated through the use of RCM; therefore, the primary characteristic of melasma involves increased pigmentation in the epidermal layer, sometimes accompanied by the presence of melanophages. The potential role of minimal dermal melanin in melasma-affected skin remains speculative. Also the levels of androglobin—a peptide responsible for degrading melanosomes is decreased in patients with melasma.[1,2]

MELANOGENESIS AND HYPERACTIVE MELANOCYTES: INSIGHTS FROM HISTOLOGICAL AND REFLECTANCE CONFOCAL MICROSCOPY STUDIES

The examination of melasma lesions at a histopathological level has yielded valuable insights into comprehending its underlying causes. In the study conducted by Kang et al. (as mentioned earlier), a comparison between the histology of melasma lesions and normal facial skin revealed the following distinguishing characteristics in the former—heightened solar elastosis, an increased number of epidermal melanocytes, presence of dermal-free melanin and melanophages, fragmentation of elastic fibers, and notably elevated levels of epidermal melanin.[2]

In the affected skin, the melanocytes were observed to be pendulous and biologically more active when compared to their counterparts in healthy skin. Melanocytes[3] from patients with melasma had revealed that there was an increase in the number of cytoplasmic organelles, suggesting that there was a higher metabolic activity.

These active melanocytes exhibited enhanced dendritic structures and a greater abundance of organelles such as mitochondria, Golgi apparatus, and rough endoplasmic reticulum.[4]

Recent discoveries have shown an escalated melanogenesis within these melanocytes present in melasma lesions, substantiated by the upregulation of several genes involved in melanin biosynthesis, along with heightened expression of melanocyte markers such as tyrosinase (*TYR*), tyrosinase-related protein 1 (*TYRP1*), tyrosinase-related protein 2 (*TYRP2*), and microphthalmia-associated transcription factor (*MITF*). However, the extent to which the proliferation of melanocytes contributes to this process remains a topic of debate.[1,2,4]

Aside from the heightened pigmentation within the basal layer, the dermal layer of melasma-affected skin displays a mild to moderate presence of mononuclear infiltrate, melanophages, and solar elastosis **(Fig. 1)**.

Histological examination of melasma lesions also reveals the presence of mast cells and heightened dermal vascularity. Although abnormalities within the dermal extracellular matrix (ECM) have been commonly observed in cases of melasma, only recently have these changes gained recognition for their potential role in melasma's pathogenesis. Solar elastosis, a characteristic sign of prolonged sun exposure-related skin aging, which involves the accumulation of irregular elastic tissues within the dermis, is frequently identified in melasma-affected skin samples. A considerable

JAYPEE BROTHERS

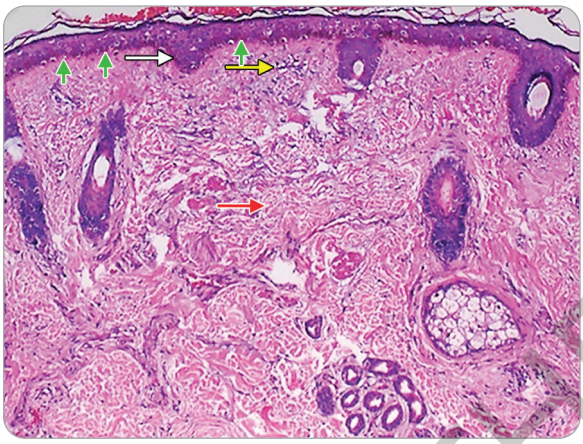

FIG. 1: Histopathology of a melasma lesion revealing preservation of rete ridges, epidermal hyperpigmentation clustered in the basal layer (white arrow), superficial dermal perivascular infiltrate predominantly of melanophages (yellow arrow), and widespread solar elastosis (red arrow). Additionally, note the focal disruptions in the basement membrane (BM) (green arrows) (H&E, 400×).

increase in the extent of solar elastosis was noted in melasma lesions when compared to the surrounding skin (83% vs. 29%, $p < 0.05$).[5]

The histopathological findings related to melasma have been validated through the use of RCM, which offers the ability to scrutinize melasma at the cellular level. The hyperpigmented basal keratinocytes present as heightened hyperreflective cobblestone-like cells, activated melanocytes manifest as dendritic cells within the epidermis, and melanophages exhibit a plump, bright appearance when observed through RCM.[6]

MULTIFACTORIAL ETIOPATHOGENESIS OF MELASMA (FLOWCHART 1)

The primary causative factors thought to contribute to melasma appear to interact synergistically. In a research involving 210 participants, the prevalence of distinct contributing elements was observed as follows: sunlight exposure accounted for 100%, pregnancy for 27%, cosmetics for 14%, familial factors for 13%, and oral contraceptive pill (OCP) usage for 6.3%.[7] In another comprehensive investigation conducted by Ortonne et al., encompassing 324 women with melasma, the outcomes further indicate the involvement of a combination of hormonal factors, such as pregnancy and OCP usage, along with sun exposure.[8]

GENETICS AND RACIAL FACTORS

A marked genetic predisposition is indicated by a notably elevated occurrence within family members of specific ethnic groups. This frequency has displayed a range spanning from 10% to a striking 70%, as observed in the research from Iran, Singapore, and even among Latino men.[9] Noteworthy disparities in prevalence are

JAYPEE BROTHERS

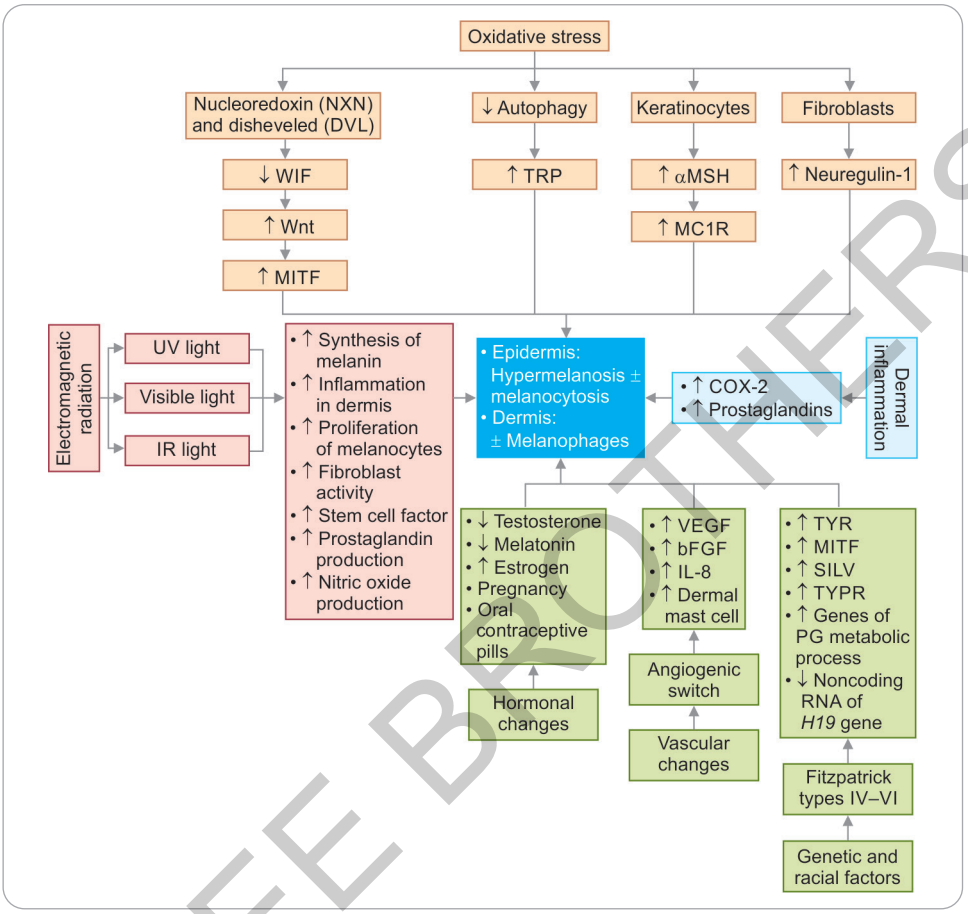

FLOWCHART 1: Major etiological factors of melasma with mechanisms associated with them.

(αMSH: alpha-melanocyte-stimulating hormone; bFGF: basic fibroblast growth factor; COX-2: cyclooxygenase-2; IL-8: interleukin-8; MC1R: melanocortin 1 receptor; MITF: microphthalmia-associated transcription factor; PG: prostaglandin; RNA: ribonucleic acid; SILV: silver homolog; TRP: tyrosinase-related protein; TYR: tyrosinase; VEGF: vascular endothelial growth factor)

observed in Southeast Asia, varying between 40% among females and 20% among males.[10] A comprehensive worldwide survey by Ortonne et al., involving women from nine distinct nations, further underscored the susceptibility of individuals possessing Fitzpatrick skin phototypes III and IV, coupled with a heightened likelihood of a positive familial background, particularly notable among African–Americans.[8]

While comprehensive genome-wide analyses have yet to be executed to probe the genes associated with melasma, it is posited that the underlying genetic elements encompass pigmentary, inflammatory, hormonal, and potentially vascular responses.[11] Unraveling the precise molecular mechanisms at play remains a task yet to be achieved.

In research conducted by Passeron et al., involving a transcriptional examination of melasma-affected skin in comparison to the adjacent healthy skin, it was discovered

JAYPEE BROTHERS

that 279 genes exhibited increased expression, while 152 genes displayed decreased expression. The upregulated genes included: *TYR*, microphthalmia associated transcription factor (*MITF*), silver homolog (*SILV*), *TYRP1*, genes of prostaglandin (PG) metabolic process, genes that regulate fatty acid metabolism. The downregulated genes were noncoding RNA of *H19* gene and Wnt inhibitory factor (*WIF*).

ROLE OF OCCUPATIONAL HEAT EXPOSURE

In a recent study by Sarkar et al. in India, it was seen that melasma was more severe in those who had greater exposure to heat from cooking. This is an important factor to consider, given that more people are exposed to heat from open furnaces in India. Sunscreens may have an important role, and need to be applied even while indoors.[12]

ROLE OF SUN EXPOSURE

Facts Suggesting the Relationship of Melasma with Sun Exposure

Undoubtedly, the primary causative element behind melasma is sun exposure, particularly to UV radiation (UVR). The appearance of lesions predominantly in sun-exposed regions of the face and the observed delay in recurrence subsequent to effective mitigation with consistent utilization of broad-spectrum sunscreens substantiates the significance of unhindered sun exposure in the advancement and development of melasma. Furthermore, indications of sun-damaged skin, notably solar elastosis as identified through histological examination, are frequently evident within melasma lesions.

Cellular and Humoral Mechanisms

Underlying Ultraviolet-induced Melasma

In melasma, intricate cellular dynamics and the intricate interplay of cytokines and hormones play a pivotal role in the impact of UVR. Recent findings have pinpointed the involvement of cell types beyond just melanocytes, particularly emphasizing keratinocytes, dermal fibroblasts, and the vasculature of the skin.[13]

- *Effects of UVR on keratinocyte–melanocyte interaction*: UVR triggers melanogenesis through both direct effects on melanocytes and indirect effects on keratinocytes, which release crucial melanogenic elements. The direct stimulation encompasses the creation of inherent 1,2-diacylglycerols (DAGs), activation of protein kinase C-beta, and the generation of nitric oxide (NO) and cyclic guanosine-3',5'-monophosphate (cGMP). On the other hand, the paracrine influence of UV exposure on melanocytes through keratinocytes involves the release of melanogenic factors, including notable players such as basic fibroblast growth factor (bFGF), nerve growth factor (NGF), endothelin-1

JAYPEE BROTHERS

(ET-1), and peptides derived from pro-opiomelanocortin (POMC) such as melanocyte-stimulating hormone (MSH) and adrenocorticotrophic hormone (ACTH) **(Flowchart 1)**.[14] These peptides not only encourage melanocyte proliferation but also facilitate melanin production by triggering TYR activity and TRP1.[15]

The interaction between melanocortin (MC) and the MC-1 receptor (MC1R) heightens melanogenesis through the intracellular cyclic adenosine monophosphate (cAMP) signal transduction route, via protein kinase A (PKA) activation, and by influencing MITF, with a specific focus on the MITF-M isoform. Furthermore, the heightened expression of inducible nitric oxide synthase (iNOS) within keratinocytes in cases of melasma adds to the melanogenesis process.[16]

Also there is an upregulation of protein kinase A, which phosphorylates cAMP-response element binding protein (CREB) and increases the activity of TYR. There is also a generation of DAG from phospholipids of melanocytes, which in turn activate TYR and increase melanogenesis.

Opsin 3 sensor is a negative regulator of melanin production, gets modulated by visible light exposure and results in increased mobilized colistin resistance (MCR-1) expression.

- *Effects of UVR on dermal inflammation and fibroblast activation*: Significant augmentation of both stem cell factor (SCF) from fibroblasts and c-kit expression within melasma-afflicted skin has been documented by Kang et al., illustrating a noteworthy observation.[17] The cytokines released by fibroblasts play a crucial role in stimulating melanocyte proliferation and melanogenesis. Hence, the plausible narrative emerges: UV-triggered dermal inflammation prompts fibroblast activation, thereby triggering an upsurge of SCF within the dermis of melasma lesions. This chain of events culminates in amplified melanogenesis. Additional inflammatory mechanisms at the cellular level may also exert an influence.

  There is also the reported occurrence of UV-induced synthesis of PGs and heightened expression of cyclooxygenase-2 (COX-2) within affected skin, leading to hyperpigmentation of the epidermis.[2] The application of PG analogs as a potential therapeutic avenue for vitiligo provides further reinforcement to this hypothesis.
- *Visible light and melasma*: Apart from the effect of UVR, the role of visible light is being increasingly recognized. Visible light is known to induce hyperpigmentation especially in skin types IV–VI.[18] A significant role is played by the blue and UV spectrum, which constitutes the high-energy visible light (HEVL). These are longer than the UV rays, and thus can penetrate deeper, contributing to free radical formation and melanogenesis. It could explain the only partial protective effect of most UV-A and UV-B protective sunscreens and higher efficacy of tinted mineral sunscreens that additionally protect against visible light in prevention of melasma relapses.
- *Other UV-induced mechanisms*: Ultraviolet light additionally triggers melanin production by causing disturbance in the basement membrane (BM), irregularities in the surrounding ECM, and activation of mast cells (as discussed below).[19]

JAYPEE BROTHERS

BASEMENT MEMBRANE DISRUPTION: A RELATIVELY RECENTLY DETECTED FEATURE OF MELASMA

Recent investigations have directed their attention toward examining the existence and function of focal vacuolar degeneration in the BM concerning melasma. Despite the considerable range of documented occurrences of BM disruption in melasma, varying between 3 and 95.5% depending on the specific study group, this phenomenon is deemed a pivotal attribute that strengthens the link between persistent UV exposure and the development of melasma.[19] Pendulous melanocytes associated with BM abnormalities were demonstrated as a characteristic feature of melasma **(Flowchart 1)**.[20]

In a recent investigation involving melasma patients exhibiting Fitzpatrick skin types IV and V, a remarkable 95.5 and 83 of skin specimens displayed disrupted BM through the utilization of periodic acid–Schiff–diastase (D-PAS) staining and anticollagen type IV immunohistochemistry, respectively.[5] This disruption stemmed from prolonged exposure to chronic UVR, which prompted heightened levels of matrix metalloproteinase (MMP)-2 and MMP-9. These enzymes then proceeded to degrade type IV and type VI collagen within the skin, ultimately culminating in the disruption of the BM's integrity.[21] Additionally, recently unearthed UV-independent pathways have been uncovered, leading to BM disruption in melasma lesions. A noteworthy observation is the potential role of cadherin 11 (CDH11) overexpression that can trigger BM disruption and consequential dermal alterations in melasma, independent of the UV exposure.[22] This disruption of the BM also elucidates the descent of melanocytes and melanin into the dermal layers, resulting in the presence of free melanin or melanophages in the dermis of melasma-affected skin **(Fig. 1)**. This phenomenon contributes to the resistance of melasma to treatment and its susceptibility to relapse, further accentuating its complexity and challenges.[5,19]

ROLE OF DERMAL MAST CELLS

In comparison to the surrounding perilesional skin, the affected skin in individuals with melasma has exhibited a notably higher abundance of dermal mast cells.[5,23] This disparity is particularly pronounced and has been established through rigorous examination. The heightened presence of these cells becomes more apparent when subjected to UV irradiation, which prompts an elevated release of diverse inflammatory mediators:

- Histamine, acting through H2 receptors, triggers the proliferation and migration of melanocytes. This effect is suspected to involve growth-differentiation factor-15, an intriguing component of the transforming growth factor-β (TGF-β) family, potentially influencing these processes.[23]
- Mast cell tryptase, on the other hand, activates pro-MMP-9, leading to the degradation of type IV collagen. This enzymatic activity does not merely affect the ECM, but also directly impacts the structural integrity of the BM. The consequential degradation is amplified by the concurrent release of other cytokines, exacerbating the disruption.[23]

JAYPEE BROTHERS

- An increased population of the mast cells expresses granzyme B, a serine protease. This enzyme's presence is associated with the deterioration of the ECM following UV exposure. This phenomenon serves to further underscore the intricate interplay between mast cells and the skin's structural components.[23,24]
- Among their contributions, mast cells are also responsible for the secretion of angiogenic factors such as vascular endothelial growth factor (VEGF), fibroblast growth factor-2 (FGF-2), and TGF-β.[23,25] This secretion contributes to the dilation of blood vessels, a process that has implications for the overall vascular dynamics of the affected skin.

Given these cumulative effects, it stands to reason that mast cells could potentially act as initiators of epidermal pigmentation in melasma. Their influence is mediated through a range of mechanisms, including the direct stimulation of melanocyte proliferation, the perturbation of the BM, the damage inflicted upon the ECM, and the facilitation of aberrant angiogenesis. This multifaceted impact underscores the complex nature of the relationship between mast cells and the development of melasma-associated skin changes.

ROLE OF SEBOCYTES

Melasma typically affects the face—an area rich in sebaceous glands. In vitro studies have shown that upon exposure to UVA radiation, sebocytes upregulated the expression of α-MSH, ET-1, and bFGF. This was capable of increasing the pigment produced by melanocytes. This was further confirmed, when extracted lesional sebocytes from patients with melasma were found to express the UVA activated pathway.[26]

ROLE OF HORMONES

The relationship of melasma with female sex hormones, OCPs, and pregnancy has been perplexing and needs further elucidation.

Pregnancy and Melasma

Numerous patients frequently observe the emergence or intensification of melasma amidst pregnancy, a phenomenon often referred to as "chloasma gravidarum" or "the mask of pregnancy." This manifestation typically arises during the latter part of the gestational period, contributing to its distinctive nature. It is important to note that melasma might manifest even prior to pregnancy or manifest many years postdelivery. The documented occurrence of melasma's onset during pregnancy has displayed a wide spectrum, spanning from 2.5 to 75%. This variance is especially notable among pregnant individuals with skin of color (SOC), who seem to experience a higher incidence. The incidence of melasma's onset or exacerbation during pregnancy is most commonly observed in women with black, Hispanic, or Asian heritage. While comprehensive studies regarding the epidemiology of melasma in Indian women are lacking, two distinct studies have reported an incidence of

JAYPEE BROTHERS

2.5–8.5% during pregnancy within the Indian female population. This reinforces the fact that the timing and prevalence of melasma in relation to pregnancy can differ considerably based on various factors, including geographical and ethnic considerations.[27,28]

Oral Contraceptive Pills and Melasma

The emergence of melasma subsequent to the utilization of OCPs has been extensively documented. A comprehensive global investigation conducted by Ortonne et al. revealed that a notable 25% out of 324 women afflicted with melasma reported the onset of the condition concurrently with their usage of OCPs.[8] This occurrence of melasma has been recorded in varying degrees, ranging from 11.3 to 46%, within individuals across diverse countries, including Singapore, Iran, India, Tunisia, and Brazil.[14]

The collective body of evidence stemming from various research endeavors, dedicated to probing the epidemiology of OCP-induced melasma, implies that this phenomenon is more prevalent among patients without a familial history of melasma. Interestingly, this subgroup of patients also tends to exhibit a heightened risk of melasma recurrence or its deterioration during pregnancy. Consequently, while those who experience melasma development during OCP usage may find relief by discontinuing such medications and steering clear of them in the future, adopting a comprehensive alteration in hormonal contraception practices for individuals with melasma appears to be an unwarranted measure.[9,14]

This perspective is underscored by the research conducted by Wiedmann et al., who unearthed that the progesterone component present in oral contraceptives actually impedes the proliferation of melanocytes when studied in vitro.[1] Furthermore, Lufti et al. contributed to this discourse by revealing a significant finding—among women who developed melasma during either pregnancy or OCP usage, a substantial 70% exhibited associated thyroid abnormalities. This figure stands in contrast to the 39.4% prevalence observed among those with idiopathic melasma. These interconnected observations deepen our understanding of the complex interplay between hormonal factors, thyroid function, and the development of melasma in various contexts.[2]

Hormones, Hormone Receptors, and Melasma

With respect to female sex hormones, estrogens and progesterones have been implicated in the development of melasma, although the extant studies have reported conflicting results. One of the major limitations of exploring this association stems from the wide variation of results reported from studies conducted in varied genetic and ethnic study populations, which may have different sex hormone metabolizing enzyme milieu. While studies from the Indian subcontinent have reported significant increase in estradiol levels (both in the follicular and in the luteal phases) in patients with melasma, compared to the controls, contradictory results have been reported by other authors.[14,18,29,30]

Recent credence to the pathogenetic role of estrogens in melasma has been lent by a literature-search based preliminary suggestion of a possible association

JAYPEE BROTHERS

TABLE 1: Proposed mechanisms of melanogenesis stimulation by estrogen–estrogen receptor interaction in the pathogenesis of melasma.[14]

Mechanism	Effect
Direct induction of protein synthesis	Upregulation of tyrosinase, TRP-1, TRP-2, MITF
Activation of the cAMP-PKA pathway	Upregulation of tyrosinase
Overexpression of *PDZK1* gene (present in keratinocytes and melanocytes)	Enhanced tyrosinase expression and melanosome transfer
Increased expression of MC1R in melanocytes	Upregulation of tyrosinase via cAMP-PKA pathway stimulation

(cAMP-PKA: cyclic adenosine monophosphate-protein kinase A; MC1R: melanocortin type 1 receptor; PDZK1, PDZ: domain protein kidney 1; TRP-1, 2: tyrosinase-related protein 1, 2)

between improvement of melasma in patients with oligomenorrhea associated with a hyperestrogenic state with systemic antiestrogenic therapy, and anecdotal reports of development of extrafacial melasma following topical estrogen application, reduction of melasma following application of antiestrogen cream, and development of melasma in Caucasian men following treatment with finasteride.[31-34] Although, hormonal pathogenesis of melasma in men lacks robust evidence, increased levels of luteinizing hormone and reduced levels of testosterone have been reported in Indian men with melasma.[35,36]

With lack of clarity on the role of levels of circulating levels in pathogenesis of melasma, the role of hormone receptors has become an active area of research. The practical impact of increased expression of progesterone receptor (PR) in melasma lesional skin remains ill-understood and needs further exploration. Immunohistochemical studies have shown that compared to melanocytes of nonlesional skin, cells from melasma lesions exhibit increased estrogen receptor (ER) expression. Based upon cultured melanocyte studies, at least four mechanisms have been hypothesized to be involved in the estrogen-ER interaction induced hypermelanogenesis **(Table 1)**.[14]

There has been recent speculation and interest in the role of testosterone in melasma in men. In a study conducted in India, it was seen that men with melasma had a lower level of testosterone than those without.[36] Normal levels of serum testosterone possibly keep the adenosine monophosphate and TYR activity in check. When low however, the check on the cyclical activity is lost, leading to melanogenesis and melasma.[37]

A recent[38] study also found that patients with melasma had a lower serum melatonin level. Melatonin plays the role of an indirect antioxidant and stabilizes the cell membrane and scavenges free radicals. It also acts via inhibiting the expression of α-MSH and the cAMP-mediated induction of TYR.

Thyroid autoimmunity has been postulated to play a role in melasma via the expression of proinflammatory cytokines.[4]

In conclusion, factors such as heightened sensitivity of melanocytes of melasma lesions to estrogens (and possibly other hormones) and additional synergistic influences such as UVR, cutaneous vasculature, activity of sebaceous glands, and

JAYPEE BROTHERS

oxidative stress need to be analyzed collectively.[9] This conclusion is clearly backed by the relative failure of any anti-melasma treatment that targets just one aspect of the pathogenesis. It is well known that treatment with sunscreens and depigmenting agents often provide suboptimal and short-lasting improvement only.

VASCULAR FACTORS

The exhibition of more pronounced solar elastosis within lesional melasma skin in contrast to the adjacent perilesional skin, coupled with UV-induced dermal inflammation leading to fibroblast activation and consequent escalation in melanogenesis, presents a compelling argument for the involvement of the dermal environment in melasma's development.[2,17] This assertion is grounded in the understanding that dermal elements, such as the ECM, fibroblasts, and mast cells, play a pivotal role in fostering melanogenesis through paracrine effects over the melanocyte–keratinocyte unit, as discussed earlier.

In addition to these factors, there is an emerging focus on the contribution of cutaneous vasculature to the pathogenesis of melasma. Despite hyperpigmentation predominantly characterizing the clinical manifestation of melasma, many patients exhibit an added distinctive trait: conspicuous telangiectatic erythema localized to the melasma-affected skin **(Fig. 2)**, although increased erythema may also be observable in the surrounding perilesional skin.[39] Recent research, involving colorimetric analysis, immunohistochemical investigations, and laser confocal microscopy examinations, has yielded evidence indicating that melasma lesions exhibit higher vascularity in comparison to the neighboring perilesional skin.[9,17,39-44] These vascular alterations, though frequently overlooked by the naked eye, can be discerned with techniques like dermoscopy **(Fig. 3)**.[42] The use of advanced tools such as the chromameter and spectrocolorimeter further facilitates the identification of heightened vascularity.[40,41]

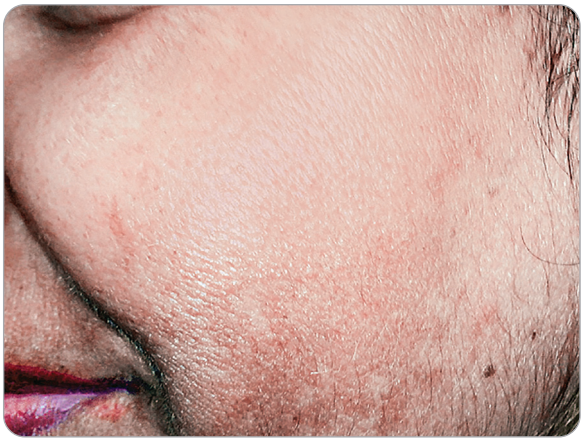

FIG. 2: Clinical appearance of an untreated patient with melasma showing pronounced telangiectatic erythema interspersed with hyperpigmented macules.

JAYPEE BROTHERS

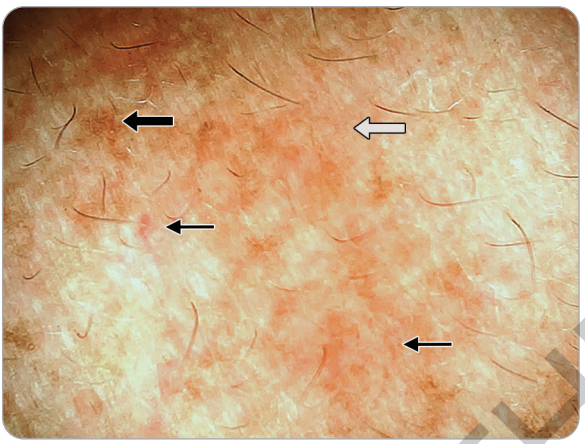

FIG. 3: Dermoscopic appearance of the patient in Figure 2, demonstrating patchy hyperpigmentation (solid black arrow), prominent interspersed erythema (solid white arrow), and multiple telangiectasias (black arrow with white margins) (eScope video dermatoscope, polarized mode, original magnification ×20).

A noteworthy investigation by Kim et al., conducted on a group of 50 women newly diagnosed with melasma, substantiated the vascular theory and its potential underlying mechanisms. This study revealed a significant augmentation in both the quantity and size of dermal blood vessels within the lesional skin when compared to the perilesional normal skin.[39] The study also documented an upregulation of VEGF expression in the lesional skin. This aligns with the speculation that UV irradiation prompts an angiogenic shift marked by the increased expression of proangiogenic factors such as VEGF, bFGF, and interleukin (IL)-8. Notably, VEGF, a pivotal angiogenic factor, appears to influence melanogenesis by interacting with VEGF receptors in epidermal keratinocytes, ultimately leading to the release of essential mediators, including arachidonic acid metabolites and plasminogen, from the proliferated vessels.[17,39]

The role of augmented dermal mast cells, which stimulate the secretion of angiogenic factors such as VEGF, FGF-2, and TGF-β, thereby contributing to vascular dilation, has also been acknowledged.[23,25] Moreover, the reports of moderate effectiveness associated with two contemporary treatment approaches—tranexamic acid (TEXA), a plasminogen inhibitor, and pulsed dye laser (PDL)—both targeting the vascular components of the skin, serve as additional substantiation for the vascular theory's relevance in understanding melasma's complex etiology.[40,41]

Nonetheless, it is judicious to bear in mind that:

- Not all individuals would benefit from interventions concentrating on the vascular aspect of melasma's pathogenesis. This approach is potentially beneficial solely for those who exhibit unequivocal evidence of heightened vascularity within their melasma condition. This determination can now be made through meticulous naked eye assessment, employment of dermoscopy, and the utilization of colorimetry-driven methodologies. Furthermore, individuals who have experienced persistent disappointments with treatments exclusively addressing the pigmentation aspect of melasma might find this approach advantageous.

JAYPEE BROTHERS

etailed information on dermatology books, visit our website www.jaypeebrothers.com, for detailed inform

Melasma
A Monograph

Key features

- This monograph is the fourth edition after the success of the previous three editions which were very well accepted and embraced by the readers
- The chapters have been updated with the latest information and current scientific knowledge, strengthened by clinical experience that helps in the appropriate management of the disorder
- New chapters on Postinflammatory Hyperpigmentation and Blue Light have been added
- Illustrated with clinical photographs, tables, and references for further reading
- Written by experts in this field with immense knowledge and experience
- Serves as a ready reckoner for dermatologists, general practitioners, and postgraduate students

Rashmi Sarkar MBBS MD FAMS IFAAD is Director Professor of Dermatology at Lady Hardinge Medical College and Associated KSCH and SSK Hospital, New Delhi, India. She has done her MD (Dermatology) from PGIMER, Chandigarh, India. She was the Editor-in-Chief of the Pigment International journal and World Clinics in Dermatology book. She was the Founder Editor of Asian Pigment Bulletin (APB). She has worked as Associate Editor for the Journal of Cutaneous and Aesthetic Surgery (2011–2014); is Associate Editor of International Journal of Dermatology, Journal of Cosmetic Dermatology, International Journal of Women's Dermatology; and Editorial Board, Indian Journal of Dermatology, Venereology, and Leprology, Indian Journal of Pediatric Dermatology, Indian Journal of Dermatology, and Journal of Clinical and Aesthetic Dermatology, besides being a reviewer for 20 journals. She has 230 publications in peer-reviewed international and national journals and 80 chapters in textbooks of dermatology and pediatrics. She has edited 17 textbooks in dermatology. She was the President of Indian Association of Dermatologists, Venereologists, and Leprologists (IADVL) in 2022. She is the Regional Director of South Asia, Africa and Middle East in ILDS; Chief Founder and President of Pigmentary Disorders Society; and Founding President of the Indian Women's Dermatologic Association. She is also a recipient of several prestigious awards and honors including Maria Duran Medal from the International Society of Dermatology (ISD), Member Making a Difference Award from American Academy of Dermatology (AAD), and International Pioneer Award and Career and Community Development Award from Women's Dermatologic Society. She has also received the prestigious ICMR Lala Ram Chand Kandhari Award (2020), Dr BM Ambady Oration from IADVL (2019), Dr Madhusudan Das Oration (2019), Dr BV Sathyanarayanan Oration (2015) from IADVL AP, and the prestigious "Inspiring Dermatologist" award from Economic Times in 2019. She has been an invited speaker in many international and national conferences, including the prestigious Annual AAD Meetings since 2006. She is on Board of Directors of ISD; President ASPCR (2020–2022); International Representative, Board of Directors in Women's Dermatologic Society (WDS) (2011–2014; 2017–2018); former Board of Directors in Skin of Color Society (SOCS); Chair of International Mentorship Committee of ISD; and Member of International Affairs Committee of AAD.

Printed in India

Available at all medical bookstores or buy online at www.jaypeebrothers.com

JAYPEE BROTHERS
Medical Publishers (P) Ltd.
EMCA House, 23/23-B, Ansari Road, Daryaganj, New Delhi - 110 002, INDIA
www.jaypeebrothers.com

Join us on facebook.com/JaypeeMedicalPublishers

Shelving Recommendation
DERMATOLOGY

ISBN 978-93-5696-875-2