ur website **www.jaypeebrothers.com,** for detailed information on medicine books, visit our website **www.jaypeebrothers.com**

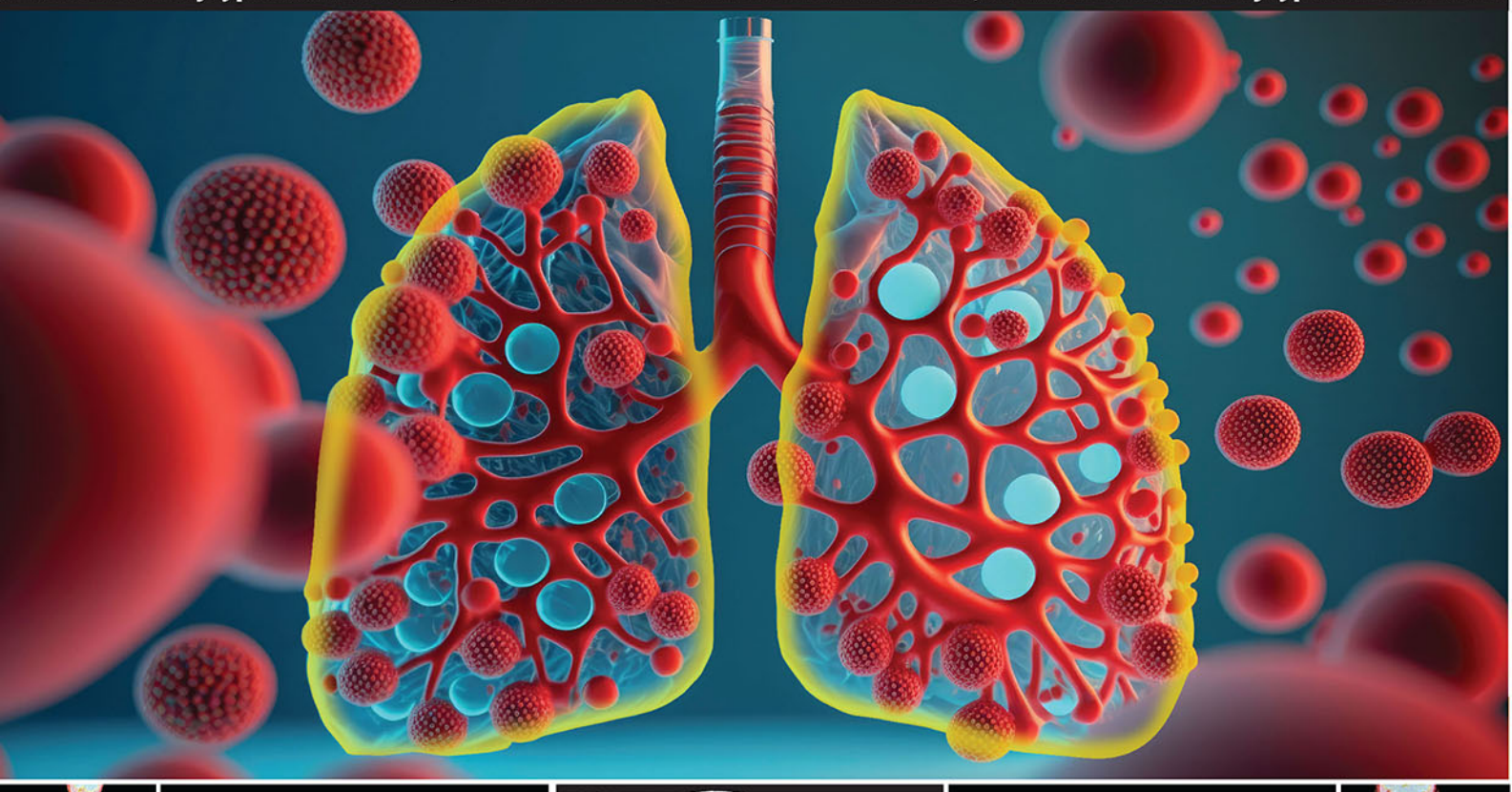



Textbook of PLEURAL DISEASES

Ashish Kumar Prakash
Anand Jaiswal
Randeep Guleria
Bornali Datta

JAYPEE

CONTENTS

CHAPTER 1: Pleural Anatomy 1
Dhananjay Kumar Dubey, Anant Mohan

CHAPTER 2: Physiology of the Pleural Space 8
SK Chhabra

CHAPTER 3: Radiology in Pleura 13
Kulbir Ahlawat, Surabhi Gupta, Ashish Kumar Prakash

CHAPTER 4: Role of Ultrasound in Pleural Diseases 24
Pooja Tyagi, Devireddy Madhava Reddy, Deepak Govil

CHAPTER 5: Approach to Pleural Effusion 36
Randeep Guleria, Shubhi Singhal

CHAPTER 6: Transudative Pleural Effusion 44
Sandeep Tilve, Sumit K Pahariya

CHAPTER 7: Tubercular Pleural Effusion 54
Saroj Meena, Anuj K Bhatnagar

CHAPTER 8: Parapneumonic Effusions and Empyema 61
Roopanshi Jain, Rajkumar

CHAPTER 9: Pleural Effusion Secondary to Fungal, Nocardia, and Parasitic Infections 71
Sonam Singla, Manan Bedi

CHAPTER 10: Pleural Diseases in HIV 78
Vikas Deswal, Sandeep K Mittal

CHAPTER 11: Malignant Pleural Effusion 82
Manoj K Goel, Ajay Kumar, Gargi Maitra

CHAPTER 12: Mesothelioma and Other Primary Pleural Tumors 90
Siddharth Chatterjee, Ashok Vaid

CHAPTER 13: Pneumothorax and Bronchopleural Fistula 103
Pralhad P Prabhudesai, Bhaumik J Kamdar, Nafeesath PCP

CHAPTER 14: Hemothorax 116
Aditi Singh, Pinky Goyal, Bornali Datta

CHAPTER 15: Chylothorax 120
Vidhi Jobanputra, Abhijeet Khandelwal

CHAPTER 16: Thoracocentesis 129
Shweta Bansal, Ashwani Prakash

CHAPTER 17: Intercostal Drainage Tubes and Pleural Drainage Systems 133
Ashish Kumar Prakash, Anand Jaiswal

CHAPTER 18: Chest Tube Monitoring, Complications, and Its Management 150
Ashish Kumar Prakash, Anand Jaiswal, Mayank Pratap Singh

CHAPTER 19: Pleural Effusion in Pulmonary Embolism 159
Hardeep Kaur Grewal, Manish Bansal

CHAPTER 20: Pleural Effusion due to Heart Diseases 166
Avi Kumar, Bhavana Mastebhakti

CHAPTER 21: Hepatic Hydrothorax 172
Narendra S Choudhary, Abhishek Saini

CHAPTER 22: Pleural Effusion in Obstetrics and Gynecology 179
Monika Madaan Gaur, Reena Verma Prakash

CHAPTER 23: Pediatric Pleural Diseases 185
Nishant Gupta, Sangeeta Basu

CHAPTER 24: Pleural Effusion due to Collagen Vascular Diseases 196
JN Durga Rao Yadavalli, Rajiva Gupta

CHAPTER 25: Pleural Effusion due to Kidney Diseases 204
Amit Kumar Mahapatra, Shabd Prakash

CHAPTER 26: Pleural Effusion due to Drugs and Miscellaneous Diseases 209
Bhawana Sharma, Mrinal Sircar

CHAPTER 27: Pleural Disorders in Lung Transplantation—Overview 219
Mohan Venkatesh Pulle, Vivek Singh, Arvind Kumar

CHAPTER 28: Medical Thoracoscopy 226
Rajiv Goyal, Sandeep Katiyar

CHAPTER 29: Pleural Biopsy and Cryobiopsy 237
Rahul Roshan, Amit Dhamija

CHAPTER 30: Surgical Management of Pleural Diseases 245
Harshvardhan Puri, Mohan Venkatesh Pulle, Sukhram Bishnoi

CHAPTER 31: Pleural Diseases in COVID 258
Ashish Kumar Prakash, Saurabh Mandilwar, Yatin Mehta

Index 271

CHAPTER

3 Radiology in Pleura

Kulbir Ahlawat, Surabhi Gupta, Ashish Kumar Prakash

JAYPEE BROTHERS

INTRODUCTION

To understand the radiology of pleura, it is very important to understand the various radiological modalities available for visualization of pleura. Imaging plays a pivotal role in identification, characterization, and management of pleural diseases. A basic chest radiograph often serves as the first imaging investigation in assessment of pleural pathologies. Since sir William Conrad Roentgen has discovered X-rays, there has been a significant advancement in the field of radiology, which now serves as a valuable tool in evaluation of pleura and its pathologies. Apart from the basic chest radiograph, other imaging modalities such as ultrasonography, computed tomography (CT), and magnetic resonance imaging (MRI) are also available. The initial and least expensive is the simple chest radiograph. The use of ultrasonography, a noninvasive modality with no radiation exposure, is an evolving concept in evaluation of pleural and lung pathologies; it is being discussed as a separate chapter in this textbook. In this chapter, we will be discussing the use of chest radiograph and other diagnostic modalities, apart from ultrasonography. Further, role of imaging using ultrasound (US), CT, or magnetic resonance (MR) depends on clinical context, initial imaging findings, and cost-effectiveness.

Different imaging modalities available are as follows:

- Chest radiograph
- CT, both high-resolution and contrast-enhanced (HRCT and CECT)
- US of chest
- MRI
- Positron emission tomography–CT (PET-CT)

CHEST X-RAY

Chest radiography till date is accepted as initial modality for the diagnosis of pleural disease. X-ray was discovered by *Willian Conard Roentgen*, revolutionizing the whole diagnostic armamentarium. Chest X-ray (CXR) is widely available nowadays and because of the digitalization, it has become more and more sensitive and specific. It is the first investigation of choice for any lung and pleural abnormality. The first step in evaluation of a chest radiograph before evaluating any pathology is to determine its technical adequacy, failing which one may overdiagnose or underdiagnose a disease entity. In an adequately positioned chest radiograph, the spinous processes should fall in line with an imaginary vertical line drawn midway between the clavicular heads. Scapulae should be rotated laterally to avoid superimposition on the upper lungs. There should be faint visualization of the vertebral bodies and disc spaces through the mediastinum. Motion blur can be assessed by noting the sharpness of the superior cortices of the ribs, vessel margins, and the diaphragmatic contours. Optimal inspiratory effort is assessed by noting the position of the right hemidiaphragm with respect to the ribs; this point should correspond to the sixth anterior rib or tenth posterior rib in the midclavicular line.[1] On a chest radiograph, the pleural pathologies can manifest as air (pneumothorax) or fluid (pleural effusion) in the pleural space or involve the pleural surfaces and present as thickening (ranging from benign pleural plaques to neoplasms) or calcification.[2]

PNEUMOTHORAX

The term pneumothorax describes the presence of air in the pleural space. A pneumothorax can be primary (with no underlying lung disease) or secondary (with underlying lung disease). An erect chest radiograph can easily demonstrate the pneumothorax **(Figs. 1 and 2)**. A pneumothorax is seen as an area of peripheral radiolucency (compared to adjacent lung), with a very thin but sharp line, representing the visible pleural edge. No lung markings can be appreciated lateral to the pleural edge. There may be complete or partial passive lung collapse. Other ancillary findings such as subcutaneous emphysema or pneumomediastinum can also be present. If there is tracheal or mediastinal shift toward the contralateral side of the pneumothorax, it is said to be a "tension pneumothorax." This is a medical emergency! It requires immediate management **(Fig. 3)**.

Various methods have been described in literature to estimate the volume of pneumothorax on a standard erect posteroanterior (PA) view radiograph.

Collins Method[3]

$$\% \text{ of pneumothorax} = 4.2 + 4.7\,(A + B + C)$$

Distance between partially collapsed to **(Fig. 4)**:

- A—lung apex to apex of thoracic cavity (black color)
- B—midpoints of upper half of collapsed lung (red color)
- C—midpoints of lower half of collapsed lung (yellow color)

4.2—correction factor

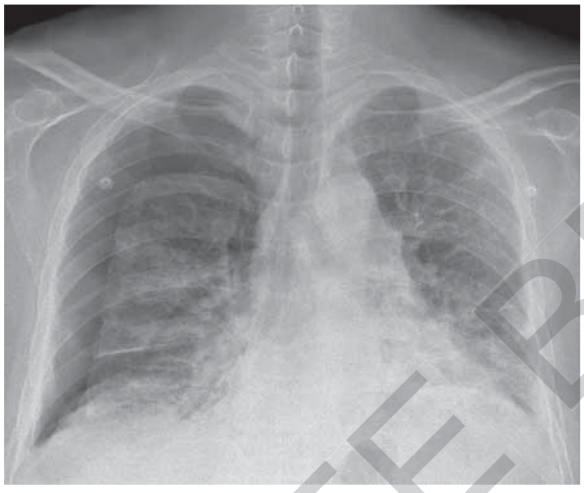

FIG. 1: Right-sided pneumothorax with lung margins clear.

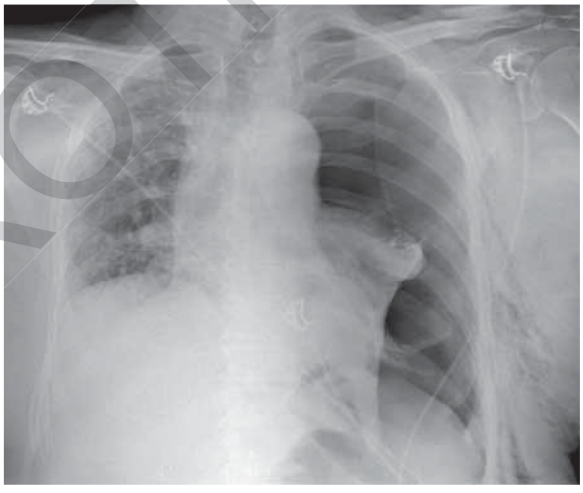

FIG. 3: Left-sided tension pneumothorax with mediastinal shift.



FIG. 2: Right-sided pneumothorax in a patient in underlying interstitial lung disease (ILD).

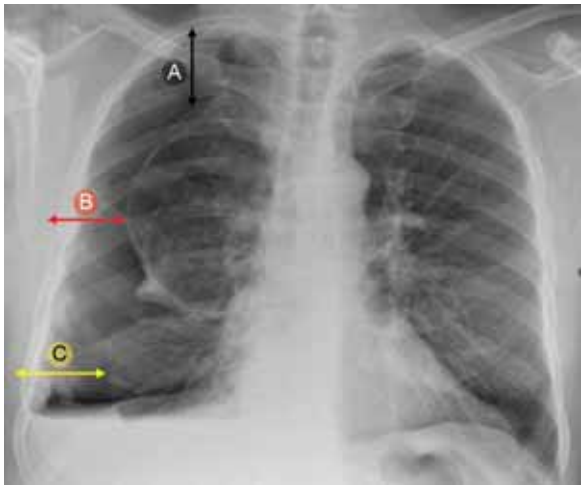

FIG. 4: Collins method to calculate size of pneumothorax: (A) Lung apex to apex of thoracic cavity (black color); (B) Midpoints of upper half of collapsed lung (red color); and (C) Midpoints of lower half of collapsed lung (yellow color).

JAYPEE BROTHERS

Rhea Method[4]

The intrapleural distance is measured at the lung apex, lung base, and midpoint between the two and the average of these three is taken. The average pleural distance is marked on the nomogram, where *1 cm corresponds to 10% pneumothorax*. It is the easiest method to recall.

Light Index[5]

$$\% \text{ of pneumothorax} = 100 - (D_L^3/D_H^3 \times 100)$$

- D_L is the diameter of collapsed lung.
- D_H is the diameter of hemithorax on the collapsed side.

The simpler and more practical method involves measuring the distance between the lung margin and chest wall (at the level of pulmonary hilum), <2 cm is considered a small pneumothorax and >2 cm is considered a large pneumothorax. Quantification of pneumothorax is important to plan optimal management strategies, namely needle aspirations versus large-bore chest drains. Now as per the latest British Thoracic Society (BTS) guidelines, size of primary spontaneous pneumothorax (PSP) hardly matters for the conservative management.[6] In case of asymptomatic PSP if there is no significant pain or dyspnea or any hemodynamic compromise, conservative management can be tried regardless of size of the pneumothorax.

PLEURAL EFFUSION

Pleural effusion refers to the accumulation of fluid in the pleural space. The radiographic appearance of pleural effusion depends on the volume of fluid, position of the patient (erect vs. supine), and mobility of the effusion (free vs. constrained).

Distribution of Pleural Fluid in Erect Radiograph

The pleural fluid follows the gravity and is seen to initially accumulate in the most dependent region, i.e., between the lung base and dome of diaphragm on PA view, known as the subpulmonic region in the upright position. This is often difficult to pick on routine PA/lateral view radiographs as the upper edge of the effusion mimics the contour of the diaphragm, resulting in mild elevation of diaphragm, also referred to as the pseudodiaphragm appearance.

The posterior costophrenic sulcus being deeper than the lateral costophrenic sulcus is seen to accumulate

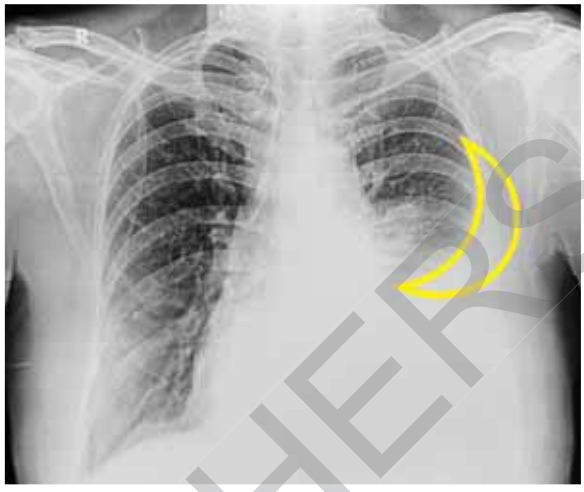

FIG. 5: Meniscus sign in the left side (pleural effusion).

significant pleural fluid, before being apparent on the erect PA radiographs. A lateral radiograph may prove beneficial in such cases, where obliteration of posterior costophrenic sulcus could represent pleural effusion not apparent on erect PA radiographs. At least 200–250 mL of fluid is required to cause obliteration of lateral costophrenic sulcus on erect PA view.[7] As the fluid quantity increases, the concave, upward slope of the fluid gives rise to the *"meniscus" sign* on erect frontal and lateral views. Sometimes this is also called *Ellis S* curve[7] **(Fig. 5)**, which is basically a radiological illusion. The radiological picture is not very easy to predict confidently about the height of fluid present in the pleural space. The exact upper limit is same throughout the hemithorax. The shape of meniscus is due to the layer of fluid which is of insufficient depth to create a noticeable shadow when viewed enface **(Fig. 6)**. Massive effusions can cause mass effect, demonstrated as contralateral tracheal and mediastinal shift.

Distribution of Pleural Fluid in Supine Radiograph

In the supine radiographs, the free pleural fluid layers posteriorly, resulting in a veil-like increased density of the hemithorax, which may often be difficult to detect. Other features include obscuration of the hemidiaphragm, reduced visibility of the pulmonary vessels below the level of the apparent dome of the diaphragm, increased opacity of the spleen in left-sided effusions, and thickening of the minor fissure.[8]

JAYPEE BROTHERS

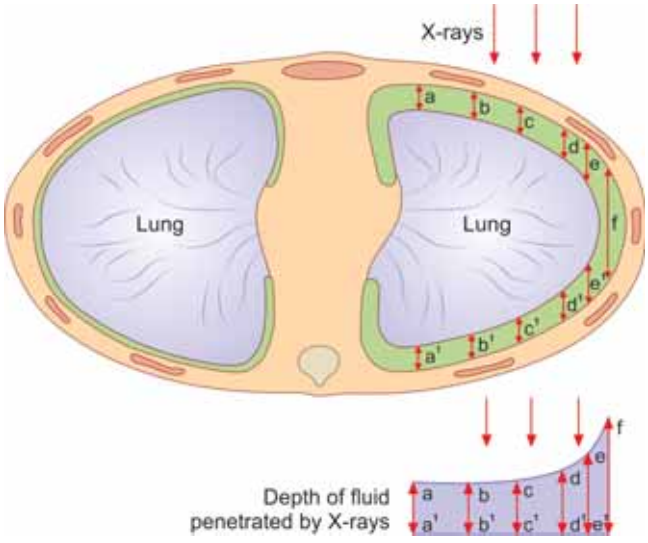

FIG. 6: Diagram explaining the meniscus sign. The distance between the chest wall and lung is same throughout the hemithorax. The fluid depth which is viewed enface a–a[1] and c–c[1] is not sufficient enough to cause radiodensity. If we move more laterally to d–d[1] and f–f[1], the beam of the X-ray passes through more and more pleural fluid, causing radiolucency which is a continuous phenomenon; hence, density gradually increases, causing meniscus sign.

Free pleural fluid can also cap the apex of the lung on supine radiographs, known as the *apical cap sign*.

Atypical Distribution and Loculation of Pleural Fluid

Loculated pleural effusions represent accumulation of fluid secondary to adhesions between contiguous pleural surfaces. The effusion typically produces biconvex mass-like opacities along the dependent costal pleural surfaces. When it occurs between two lobes, it can be misinterpreted as a pulmonary neoplasm on chest radiographs. However, fluid accumulations between two lobes **(Fig. 7A)** tend to resolve spontaneously or with diuretics **(Fig. 7B)**, and therefore have also been called *vanishing/pseudo-tumor/phantom tumor*.[9-11]

PLEURAL TUMORS AND TUMOR-LIKE CONDITIONS

Many neoplastic, both benign and malignant, and non-neoplastic pathologies can involve the pleura.

Basic Imaging Pearls (Table 1)

A peripherally placed opacity on chest radiograph can be localized in three different locations with respect to the pleura:

1. *Extrapleural opacity*: It originates from the chest wall and forms obtuse angles and a sharp medial margin in relation to the pleura.
2. *Pleural opacity*: It has partially or completely well-circumscribed margins and also forms obtuse angles with the pleura.
3. *Subpleural opacity*: It is localized to the lung parenchyma, has irregular margins, and forms acute angles with pleural reflections.

The general features on radiograph suggestive of pleural tumors include peripheral location abutting the chest wall, a sharp margin with the surrounding lung, and obtuse angle of contact with the chest wall/mediastinum. *If the angle of contact with the chest wall is acute, then it favors lesion to be of parenchymal origin* **(Fig. 8A)**, *and if the angle is obtuse (D shaped), then it suggests it to be of pleural origin* **(Fig. 8B)**.

PLEURAL THICKENING

Thickening of the pleura can be appreciated on chest radiographs. It can be focal or diffuse, benign or malignant. Diffuse pleural thickening is defined as thickening of pleura > 5 mm with total area of involvement >25% of chest wall if bilateral and 50% involvement if unilateral.[13] Apical pleural thickening is one of the most common findings seen on routine chest radiographs and is considered to be part of normal age-related changes; however, apical pleural thickening >2 cm requires further evaluation. On imaging, benign pleural thickening is seen as a diffuse involvement of pleura. Pleural thickening >5 cm in width, 8 cm in craniocaudal extent, and 3 mm in thickness usually points toward a benign etiology.[14] Furthermore, features such as volume loss, calcifications, and proliferation of extrapleural fat also support a diagnosis of diffuse benign pleural thickening. Nodular circumferential pleural thickening with involvement of mediastinal pleura suggests a malignant process.

COMPUTED TOMOGRAPHY—BOTH HIGH-RESOLUTION AND CONTRAST-ENHANCED

Computed tomography, formerly called *computed axial tomography scan* (*CAT scan*), is one of the latest imaging techniques, which plays a major role in medical imaging today. In CT, the patient is placed in a gantry, with an X-ray tube rotating around the patient, the X-ray beam used to radiate the patient can be pencil beam, fan beam, or cone beam in configuration. The multirow detectors simultaneously record the radiation that passes through the body, which is used to produce the image, available to us in its digitized format on our computer screens. Its

JAYPEE BROTHERS

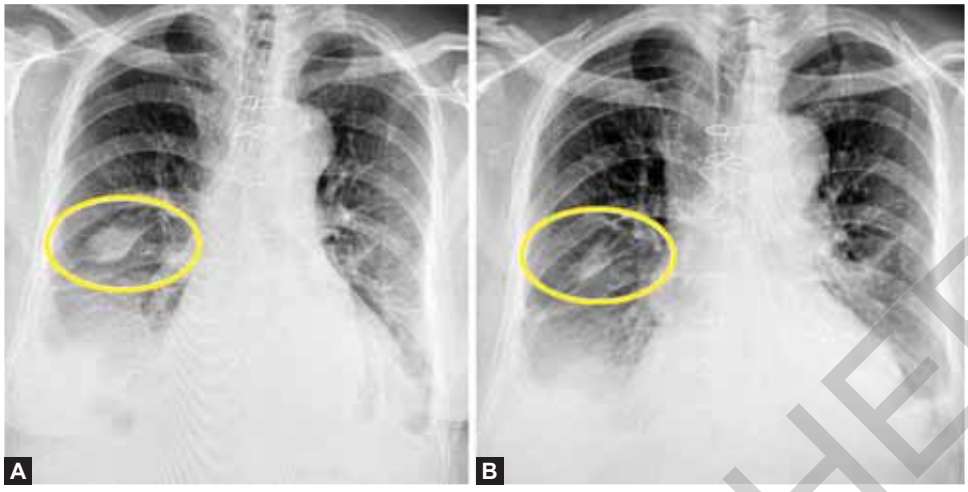

FIGS. 7A AND B: Fluid accumulation in fissure-vanishing/pseudo-tumor/phantom tumor. (A) Before and (B) after diuretics.

TABLE 1: Pleural versus pulmonary versus extrapleural lesions.[12]

Pleural	Extrapleural	Pulmonary
Obtuse angle	Obtuse angle	Acute angle
Displace pulmonary vasculature	Displace pulmonary vasculature	Engulf pulmonary vasculature
Centered along chest wall	Centered along chest wall	Centered in the lung
Tapered well-defined margins	Tapering margins	Nontapering, ill-defined margins
Changes location with respiration	–	–
Displace extrapleural fat outward	Displace extrapleural fat inward	–
Rib erosion unusual	Rib erosion common	Rib erosion unusual

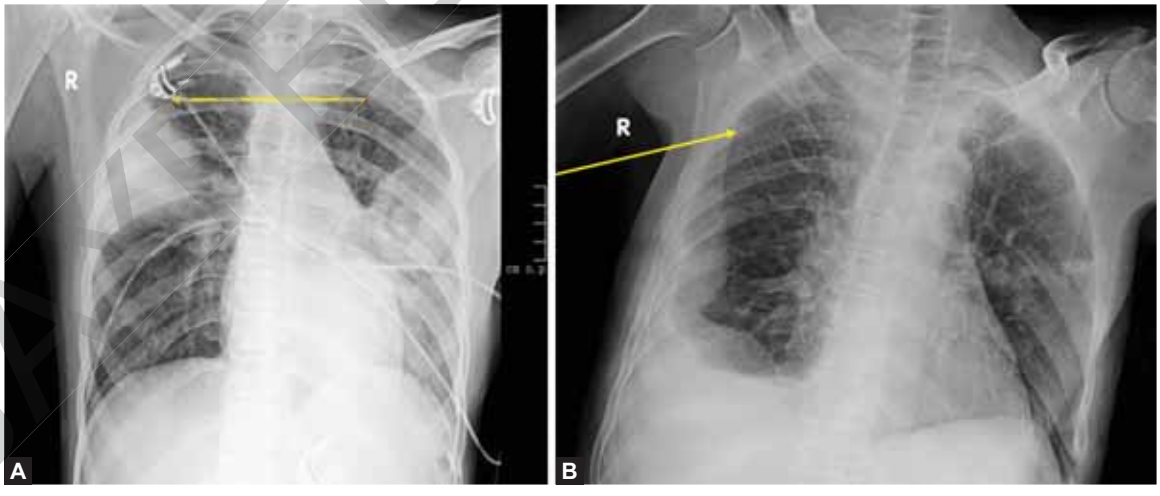

FIGS. 8A AND B: Difference between pulmonary and pleural lesions: (A) Acute angle favors—parenchymal origin and (B) obtuse (D-shaped) favors—pleural origin.

JAYPEE BROTHERS

use in case of lung as well as mediastinal pathologies is well known.[15] Nowadays it is widely available, quick, and gives a detailed view of the internal organs.[16-18] In order to study the details of pleura, it should involve multislice thin sections (0.5–2.0 mm), which will enable subsequent multiplanar reconstruction[19-21] **(Fig. 9)**. The CT image generated is viewed on appropriate window settings to have a complete and detailed evaluation of lung parenchyma, mediastinal structures, and the bony structures of chest wall. The window width (W) refers to the range of CT numbers that a CT image contains, or in simpler terms the different shades of gray that it contains. The window level (L) refers to the center point or midpoint HU value in the window setting. Window setting for viewing lung parenchyma is W: 1,500, L: 500, for viewing mediastinum is W: 400, L: 40, and for viewing bone is W: 2,000, L: 500. Different organs of our body have different density through which the radiation beam passes. The linear attenuation coefficient for every material at the selected effective energy is converted to CT numbers known as *Hounsfield units* using the standard equation:

$$HU = (\mu_{material} - \mu_{water})/(\mu_{water}) \times 1{,}000$$

Contrast-enhanced CT is the best to view pleural abnormality and the image acquisition should be done after 60–90 seconds of intravenous contrast administration to allow maximum pleural enhancement called the *pleural phase*.[22] The pleural pathologies like fluid or blood or the masses obliterate the pleural space. It is very important to confirm the lesion obliterating pleural space that will be either pleural or parenchymal. In case of chest radiograph, the angle of contact between the opacity and chest wall helps us to determine if the lesion is pleural based or parenchymal in nature. CECT has good sensitivity and specificity to differentiate between the pleural and extrapleural lesions.[23,24] The free fluid looks like sickle-shaped fluid density in the gutter or the most dependent part of the chest posteriorly.[25] In case of loculated pleural effusions, there are fluid-attenuating lenticular densities showing fixed position[26] *(split pleura sign)* **(Figs. 10A and B)**. Rarely, the CT findings may be equivocal particularly when there is parenchymal abnormality like collapse/consolidation or loculated pleural collection, which form acute angles with the chest wall. When the lesions are in the posterior costophrenic recess, which is adjacent to the diaphragm, it is difficult to differentiate them from ascites. There are various CT findings to differentiate the pleural fluid from ascites,[25] as shown in **Figures 11A and B**. There are few important signs to be recalled as "**ABCD**" as shown in the diagrammatic representation **(Figs. 12A to D)**.

A. The *interface sign*: A hazy interface between the fluid and organs such as liver and spleen is indicative of pleural fluid, whereas a sharp interface between the

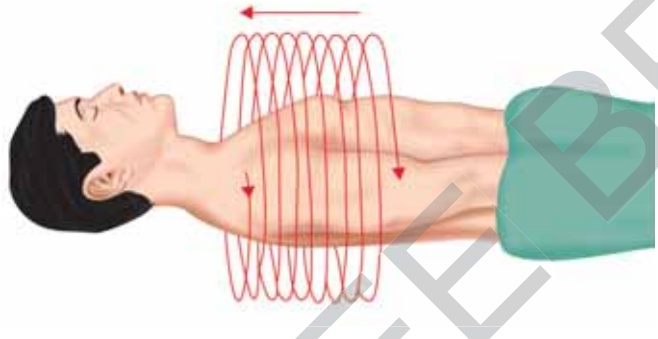

FIG. 9: Scanning geometry of a helical computed tomography (CT)—the schematic representations.

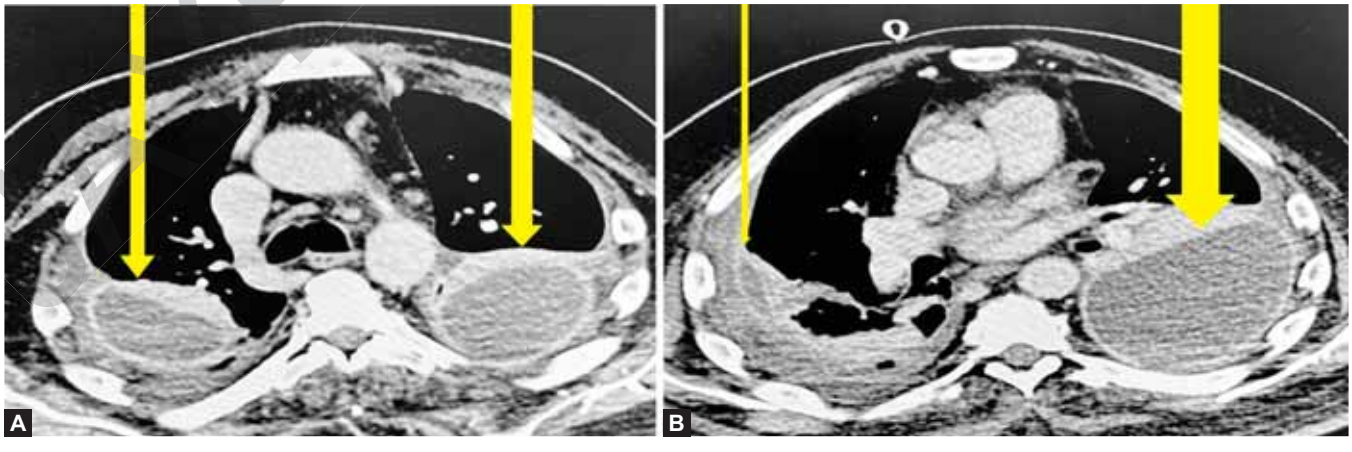

FIGS. 10A AND B: Computed tomography (CT) representing the bilateral split pleura sign (four yellow arrows). The width of the yellow arrow is representing the amount of loculated effusion.

FREE BROTHERS

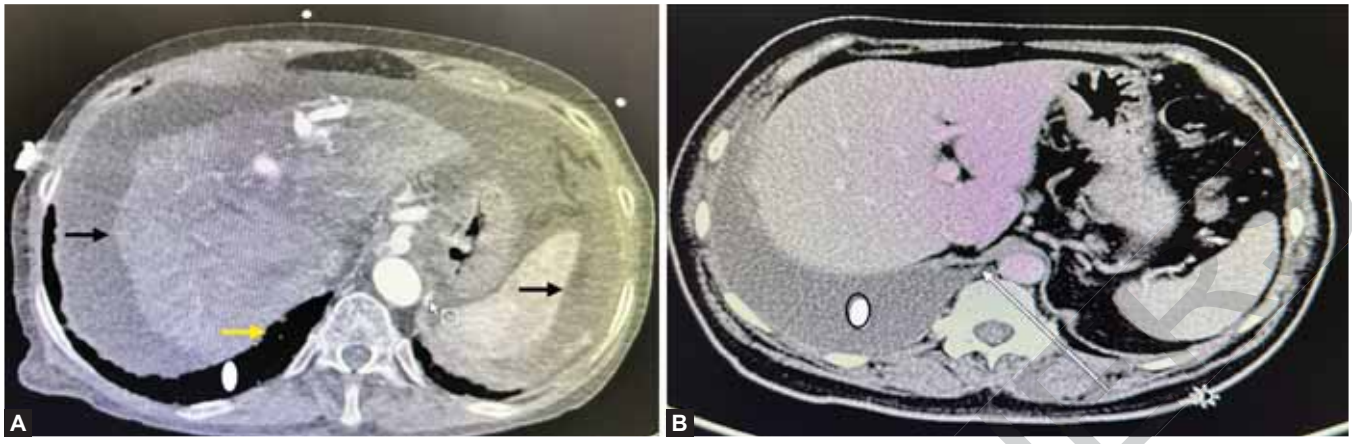

FIGS. 11A AND B: (A) 1-ascites showing interface sign (black arrows) and bare-area sign (yellow arrow) [bare area (white dot)—no fluid in case of ascites]. (B) Displaced crus sign—the right crus of the diaphragm is displaced (white arrow) laterally in case of pleural effusion [white dot (bare-area sign) in case of pleural effusion, unrestricted access to the posterior costophrenic sulcus].

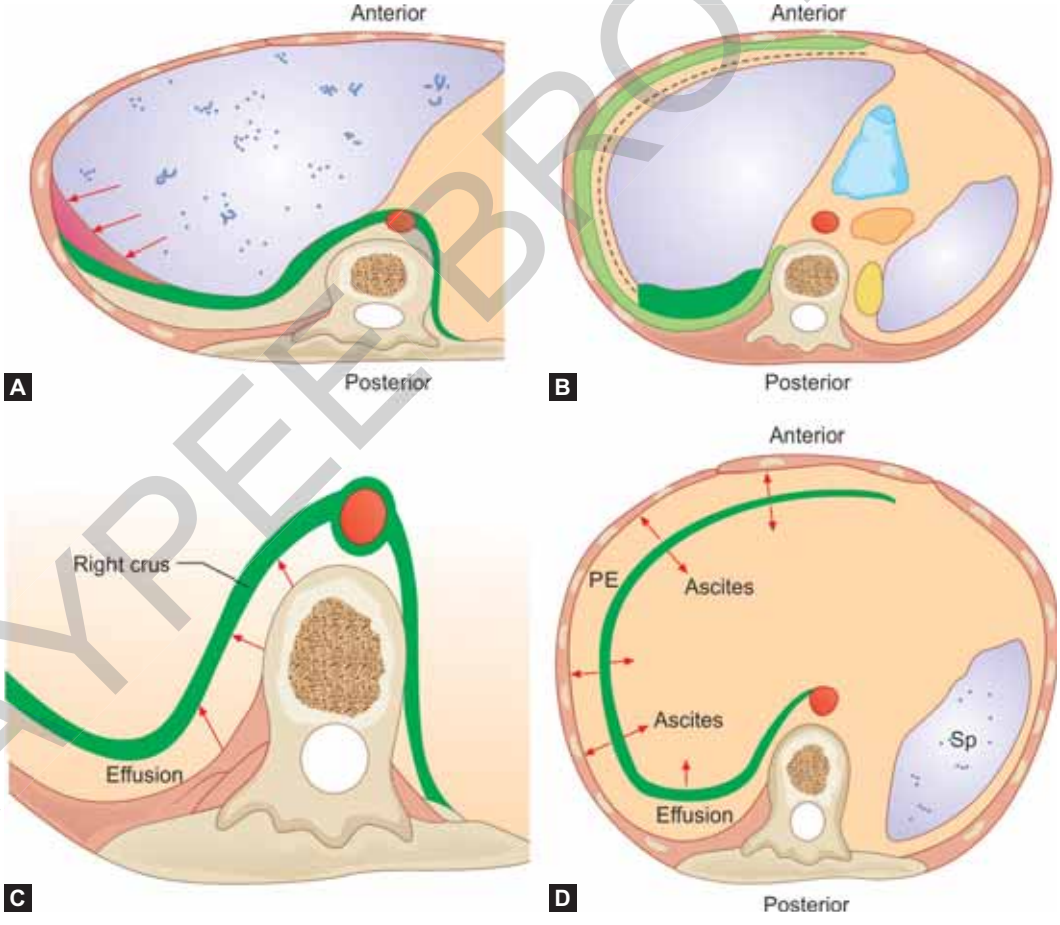

FIGS. 12A TO D: Diagrammatic representation of (A) interface sign, (B) bare-area sign, (C) crus-diaphragm sign, and (D) diaphragm sign.

JAYPEE BROTHERS

fluid and abdominal organs is suggestive of ascites. Because diaphragm makes the interface, the organs such as spleen and liver are well delineated in case of ascites but not in pleural effusion.

B. The ***b**are-area sign*: If there is restriction of fluid by the coronary ligaments from the bare area of the liver, it indicates that the patient has ascites. The pleural fluid has unrestricted access to the posterior costophrenic sulcus and is therefore also seen in relation to the bare area of liver.
C. The *displaced **c**rus sign*: If the diaphragmatic crus is displayed away from the vertebral body by the fluid, it indicates that the fluid is in the pleural space, while ascites displaces the diaphragmatic crus toward the vertebral body.
D. The ***d**iaphragm sign*: The fluid that lies outside the diaphragm is pleural fluid, whereas that lies inside the diaphragm is ascites.

Computed tomography is the most effective way for demonstrating abnormalities in the lung parenchyma and chest wall, which are not seen on the conventional chest radiograph. CT chest is very helpful in differentiating empyema with air-fluid levels from lung abscesses. Almost every disease of pleura has CT findings and are described in subsequent chapters of this book. CT is also helpful in differentiating benign versus malignant pleural effusion. A study done by Yilmaz et al.[27] in 146 patients suggested its sensitivity/specificity for pleural nodularity 37%/97%, pleural rind 22%/97%, mediastinal pleural involvement 31%/85%, and pleural thickening >1 cm, 35%/87%, respectively. Another study done by Traill et al.[28] reported that 27 out of 32 patients with malignant pleural effusion had pleural nodularity or irregularity or pleural thickness > 1 cm. Chest CT is not indicated in all patients with suspected pleural disease. The coefficient density in CT is not very specific to distinguish among parenchymal lesions, solid pleural masses, or pleural fluids such as blood, serous fluid, or pus.[29] The coefficients of attenuation in CT scan cannot differentiate significantly between transudative and exudative pleural effusion.[30] Sometimes in case of hemothorax, there could be dual density **(Fig. 13)** inside the lesion in terms of HU units which may suggest the possibility of hemorrhage, but the gold standard is still the diagnostic tapping. In case of acute extravasated blood, the HU values tend to be high in comparison to chronic hemorrhage.[31] There is extensive literature regarding the HU units with respect to blood in pleural space.[32-33] One study done by Liu et al.[34] suggested a cutoff value of 15.6 HU or 30.0% of the perimeter/area (P/A) ratio to differentiate hemothorax from pleural effusion. In case of 15.9 HU cutoff or 56% of P/A ratio, better discrimination was obtained between hemothorax and empyema.



FIG. 13: Computed tomography (CT) showing double density in a post-traumatic patient (white arrow favoring fluid while black arrow favoring blood).

Computed tomography examinations of the chest can also give additional information regarding the effects of effusion on the underlying lung. Study done by Paling and Griffin[35] reviewed the chest CT of 46 cases in supine position with a moderate or large pleural effusion. The volume size of the underlying lung, especially lower lobe, was reduced in all patients, whereas atelectasis of the underlying lung was seen in 96% (44 of the 46) cases. Segmental collapse of the lower lobe was seen in 19 cases. Among 7 patients, the atelectatic segment was massive enough to cause complete collapse of the lower lobe. CT chest can also be used to evaluate the fissures (major and minor fissures).[36]

MAGNETIC RESONANCE IMAGING

Even today, CECT remains the most important radiological investigation in evaluation of pleural pathologies, but role of MRI in pleural pathologies can no longer be ignored. CT imaging has several limitations, including the use of iodinated contrast media, exposure to ionizing radiations, and restricted differentiation of pleural tumors from surrounding soft tissues. MRI provides superior contrast resolution and various MRI sequences can not only detect but also delineate pleural tumors more effectively than CT. It can be used to determine the invasion of surrounding tissues—chest wall, diaphragm, bone marrow, and endothoracic fascia, and in addition also provide functional information.[37] MRI is also serves as a radiation-free alternative in imaging, and therefore has huge potential in cases where repetitive imaging is required and in pediatric population. The choice of MR sequences is usually tailored to the clinical question and the individual case; however, the basic sequences that are acquired in almost all cases include multiplanar

JAYPEE BROTHERS

electrocardiogram-(ECG)-triggered T1 (T1-weighted), T2 (T2-weighted), and CE T1 (contrast-enhanced T1-weighted) with respiratory triggering and breath-holding techniques.[38] Additional sequences like short tau inversion recovery (STIR) sequences may be added to look for bone marrow involvement in malignant pleural pathologies. Dynamic contrast-enhanced MRI (DCE-MRI) DCE-MRI is used for functional imaging. It tracks signal changes after administration of contrast agents through sequential imaging. DCE-MRI can give information regarding vascularity and perfusion characteristics of a pleural tumors and monitor its response to chemotherapy. The diffusion-weighted MRI (DW-MRI) can help differentiate between benign and malignant pleural lesions. It is based on the mobility of protons in a given tissue; the malignant pathologies have restricted water movement and show higher signal intensity on DW-MRI compared to areas with free water movement. Despite its huge potential and diverse roles, thoracic MRI also comes with a set of limitations, namely the artifacts caused by respiratory and cardiac motion. Respiratory motion artifacts can be minimized by the use of breath-hold sequences and respiratory gating during acquisition.[39] Cardiac motion can be overcome by using techniques such as cardiac gating (gating using ECG) and using ultrashort sequences.

POSITRON EMISSION TOMOGRAPHY–COMPUTED TOMOGRAPHY

It is an increasingly utilized imaging modality in evaluation of malignant pleural conditions, especially mesothelioma and pleural metastasis. Fluorodeoxyglucose (FDG) PET-CT is a hybrid imaging technique, combining the benefits of FDG-PET, which provides metabolic parameters of a pleural tumor and CT, which has improved spatial resolution. It contributes to the diagnosis and staging of pleural malignancy, helps in planning of therapy, and also assessing response to the treatment. The procedure involves PET acquisition approximately 60 minutes after intravenous injection of 18F-FDG in conjunction with contrast-enhanced or unenhanced CT. To limit motion blur and reduce artifacts, use of respiratory-gated PET acquisition has been advocated; this improves the accuracy of standardized uptake value (SUV) and metabolic tumor volume measurements for intrathoracic neoplasms.[40] Integrated PET/CT has shown to be more accurate in the staging of thoracic malignancies than either modality alone. Like any other imaging modality, FDG PET-CT also comes with its own set of pitfalls and one must be aware of them before reporting a PET-CT. Inflammatory/infectious processes with increased metabolic activity can also show moderate-to-intense FDG avidity and may be wrongly interpreted as malignancy **(Figs. 14A and B)**; therefore, obtaining clinical history becomes absolutely essential before reading a FDG PET-CT scan.

Fluorodeoxyglucose Positron Emission Tomography–Computed Tomography in Malignant Pleural Mesothelioma

Fluorodeoxyglucose PET-CT is pivotal in imaging of malignant pleural mesothelioma. The typical findings in malignant pleural mesothelioma are unilateral circumferential or near-circumferential pleural and fissural thickening that shows FDG avidity and SUV

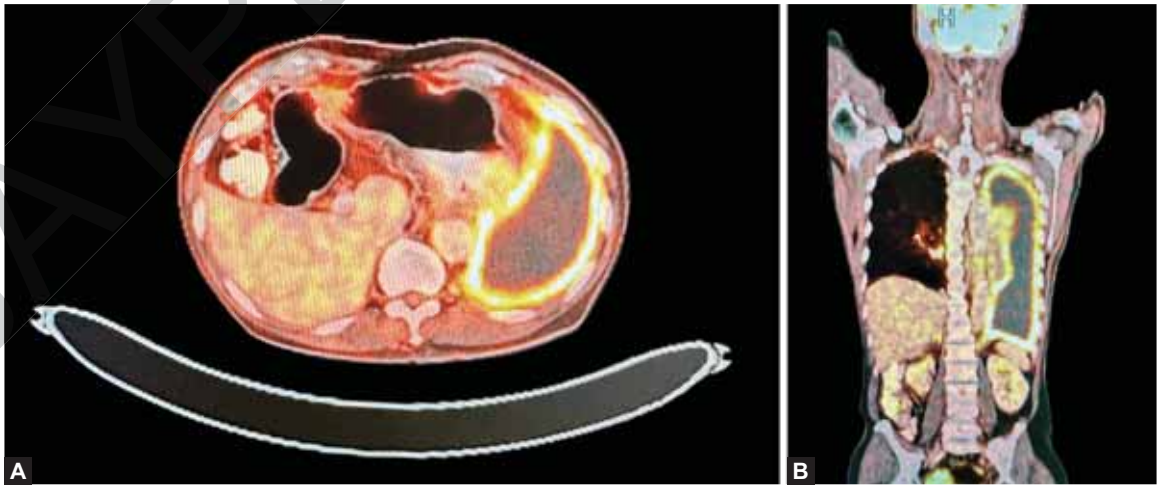

FIGS. 14A AND B: (A) Tubercular empyema patients with high uptake in PET in axial view. (B) Coronal section of PET–CT of tubercular empyema patients.

(PET–CT: positron emission tomography–computed tomography)

JAYPEE BROTHERS

value > 2.0–2.2.[41] The tumor, node, metastasis (TNM) staging including the TNM system utilizes quantitative and qualitative parameters obtained from FDG PET-CT. An important role of imaging is to distinguish resectable tumor from unresectable tumor, preventing unnecessary thoracotomies and other morbid surgical procedures. This includes differentiation between T3 (resectable) and T4 (unresectable) disease and identifying involvement of N3 node and/or distant metastasis. FDG PET-CT has proven to be superior to other imaging modalities in this regard. The irregular and asymmetric morphology of malignant pleural mesothelioma poses difficulties in assessment of tumor burden; however, FDG-avid tumor volume values are an effective method to plan treatment and monitor response in patients undergoing radiation therapy. To overcome challenges in response assessment, owing to the asymmetric morphology of this tumor, Byrne and Nowak proposed a modified Response Evaluation Criteria for Solid Tumors (RECIST).[42] In this the tumor, burden is assessed by summing a total of six measurements of the tumor with maximum thickness perpendicular to the chest wall, with two measurements at reproducible landmarks carried out on three different slices, 1 cm apart.

KEY POINTS

- CXR is an initial modality for the diagnosis of pleural disease. CXR is widely available and is very sensitive.
- The ultrasonography of chest is noninvasive and no radiation exposure is very important for evaluation of pleural and lung pathologies. It can also be helpful for point-of-care management, emergency, and in intensive care unit.
- Other imaging modalities such as CT, MRI, and PET-CT are also available to evaluate for pleural diseases.
- CXR-PA view is the simplest, easiest, and quickest method to diagnose pneumothorax. There are various methods to quantify the pneumothorax (Collins, rhea, and light).
- The easier method is measuring the distance between the lung margin and chest wall, <2 cm is small and >2 cm is considered a large pneumothorax.
- In PSP, if patients are asymptomatic, conservative management can be tried regardless of the size of the pneumothorax.
- Meniscus' sign or Ellis S curve is a radiological illusion. The shape of meniscus is due to the layer of fluid which is of insufficient depth to create a noticeable shadow when viewed enface.
- When effusion occurs between two lobes (fissural). It tends to resolve spontaneously or with diuretics (vanishing/pseudo-tumor/phantom tumor).
- If the contact angle of the lesion with the chest wall gives a good clue regarding location, acute angle favors parenchymal while obtuse (D-shaped) suggests pleural origin.
- Pleural phase in CECT—when the image acquisition is done after 60–90 seconds of intravenous contrast administration.
- In loculated pleural effusions, there is split pleura sign.
- To differentiate between pleural effusion and ascites, there are few important signs to be recalled as A—interface, B—bare area, C—crus of diaphragm, and D—diaphragm sign.
- In case of hemothorax, there could be dual density inside the lesion in terms of HU units, which may suggest the possibility of hemorrhage, but the gold standard is still the diagnostic tapping.
- Inflammatory/infectious processes with increased metabolic activity can also show moderate-to-intense FDG avidity and may be wrongly interpreted as malignancy.

REFERENCES

1. Walz-Flannigan AI, Brossoit KJ, Magnuson DJ, Schueler BA. Pictorial review of digital radiography artifacts. Radiographics. 2018;38(3):833-46.
2. Qureshi NR, Gleeson FV. Imaging of pleural disease. Clin Chest Med. 2006;27(2):193-213.
3. Collins CD, Lopez A, Mathie A, Wood V, Jackson JE, Roddie ME. Quantification of pneumothorax size on chest radiographs using interpleural distances: regression analysis based on volume measurements from helical CT. AJR Am J Roentgenol. 1995;165(5):1127-30.
4. Rhea JT, DeLuca SA, Greene RE. Determining the size of pneumothorax in the upright patient. Radiology. 1982;144:733-6.
5. Light RW. Management of spontaneous pneumothorax. Am Rev Respir Dis. 1993;148(1):245-8.
6. Roberts ME, Rahman NM, Maskell NA, Bibby AC, Blyth KG, Corcoran JP, et al.; BTS Pleural Guideline Development Group. British Thoracic Society Guideline for pleural disease. Thorax. 2023;78(Suppl 3):1-42.

JAYPEE BROTHERS

7. Davis S, Gardner F, Qvist G. The shape of a pleural effusion. Br Med J. 1963;1:436-7.
8. Woodring JH. Recognition of pleural effusion on supine radiographs: How much fluid is required? AJR Am J Roentgenol. 1984;142:59-64.
9. Oliveira E, Manuel P, Alexandre J, Girão F. Phantom tumour of the lung. Lancet. 2012;380(9858):2028.
10. Tesloianu DN, Chioarta M, Corduneanu D, Ignat AM, Petris AO, Tesloianu A. Does Phantom Tumor Really Exist? Maedica (Bucur). 2017;12(4):281-5.
11. Gefter WI, Boucot KR, Marshall EW. Localized interlobar effusion in congestive heart failure; vanishing tumor of the lung. Circ. 1950;3:336-43.
12. Sureka B, Thukral BB, Mittal MK, Mittal A, Sinha M. Radiological review of pleural tumors. Indian J Radiol Imaging. 2013;23(4): 313-20.
13. Downer NJ, Ali NJ, Au-Yong IT. Investigating pleural thickening. BMJ. 2013;346:e8376.
14. Jelen TH, Bankier AA, Eisenberg RL. Solid Pleural Lesions. Am J Roentgenol. 2012;198:W512-20.
15. Henschke CI, Yankelevitz OF, Davis SD. Pleural diseases: multimodality imaging and clinical management. Curr Probl Diagn Radio. 1991;20:155-81.
16. Kang MJ, Park CM, Lee CH, Goo JM, Lee HJ. Dual-energy CT: clinical applications in various pulmonary diseases. Radiographics. 2010;30:685.
17. Otrakji A, Digumarthy SR, Lo Gullo R, Flores EJ, Shepard JA, Kalra MK. Dual-Energy CT: Spectrum of Thoracic Abnormalities. Radiographics. 2016;36:38.
18. McCollough CH, Leng S, Yu L, Fletcher JG. Dual- and Multi-Energy CT: Principles, Technical Approaches, and Clinical Applications. Radiology. 2015;276:637.
19. Hallifax RJ, Talwar A, Wrightson JM, Edey A, Gleeson FV. State-of-the-art: Radiological investigation of pleural disease. Respir Med. 2017;124:88-99.
20. Hallifax RJ, Haris M, Corcoran JP, Leyakathalikhan S, Brown E, Srikantharaja D, et al. Role of CT in assessing pleural malignancy prior to thoracoscopy. Thorax. 2015;70:192-3.
21. Kalender WA, Sissler W, Klotz E, Vock P. Spiral volumetric CT with single-breath-hold technique, continuous transport, and continuous scanner rotation. Radiology. 1990;176:181-3.
22. Görg C, Bert T, Görg K. Contrast-enhanced sonography for differential diagnosis of pleurisy and focal pleural lesions of unknown cause. Chest. 2005;128(6):3894-9.
23. Leung AN, Müller NL, Miller RR. CT in differential diagnosis of diffuse pleural disease. AJR Am J Roentgenol. 1990;154:487-92.
24. Scott EM, Marshall TJ, Flower CD, Stewart S. Diffuse pleural thickening: percutaneous CT-guided cutting needle biopsy. Radiology. 1995;194:867-70.
25. McLoud TC, Flower CD. Imaging the pleura: sonography, CT, and MR imaging. AJR Am J Roentgenol. 1991;156:1145-53.
26. Aquino SL, Webb WR, Gushiken BJ. Pleural exudates and transudates: diagnosis with contrast-enhanced CT. Radiology. 1994;192:803-8.
27. Yilmaz U, Polar G, Sahin N, Soy O, Gülay U. CT in differential diagnosis of benign and malignant pleural disease. Monaldi Arch Chest Dis. 2005;63:17-22.
28. Traill ZC, Davies RJ, Gleeson FV. Thoracic computed romography in patients with suspected malignant pleural effusions. Clin Radiol. 2001;56(3):193-6.
29. Koh DM, Burke S, Davies N, Padley SP. Transthoracic US of the chest: clinical uses and applications. Radiographies. 2002;22(1):E1.
30. Abramowitz Y, Simanovsky N, Goldstein MS, et al. Pleural effusion: characterization with CT attenuation values and CT. AJR Am J Roentgenol. 2009;192:618-23.
31. Parizel PM, Makkat S, Van Miert E, Van Goethem JW, van den Hauwe L, De Schepper AM. Intracranial hemorrhage: principles of CT and MRI interpretation. Eur Radiol. 2001;11:1770-83.
32. Broderick SR. Hemothorax: etiology, diagnosis, and management. Thorac Surg Clin. 2013;23:89-96.
33. Kaewlai R, Avery LL, Asrani AV, Novelline RA. Multidetector CT of blunt thoracic trauma. Radiographics. 2008;28:1555-70.
34. Liu F, Huang YC, Ng Y-B, Liang JH. Differentiate pleural effusion from hemothorax after blunt chest trauma; comparison of computed tomography attenuation values. J Acute Med. 2016:1-6.
35. Paling MR, Griffin GK. Lower lobe collapse due co pleural effusion: a CT analysis. Comput Assist Tomogr. 1985;9:1079-83.
36. Proco AV, Ball JB Jr. Computed tomography of the major and minor fissures. AJR Am J Roentgenol. 1983;140:439-48.
37. Szczyrek M, Bitkowska P, Jutrzenka M, Szudy-Szczyrek A, Drelich-Zbroja A, Milanowski J. Pleural Neoplasms—What Could MRI Change? Cancers. 2023;15:3261.
38. Ohno Y. New Applications of Magnetic Resonance Imaging for Thoracic Oncology. Semin Respir Crit Care Med. 2014;35:27-40.
39. Puderbach M, Hintze C, Ley S, Eichinger M, Kauczor H, Biederer J. MR imaging of the chest: a practical approach at 1.5T. Eur J Radiol. 2007;64:345-55.
40. Feigen M, Lee ST, Lawford C, Churcher K, Zupan E, Scott AM, et al. Establishing locoregional control of malignant pleural mesothelioma using high-dose radiotherapy and (18) F-FDG PET/CT scan correlation. J Med Imaging Radiat Oncol. 2011;55:320-32.
41. Yildirim H, Metintas M, Entok E, Ak G, Ak I, Dundar E, et al. Clinical value of fluorodeoxyglucose-positron emission tomography/computed tomography in differentiation of malignant mesothelioma from asbestos-related benign pleural disease: an observational pilot study. J Thorac Oncol. 2009;4:1480-4.
42. Byrne MJ, Nowak AK. Modified RECIST criteria for assessment of response in malignant pleural mesothelioma. Ann Oncol. 2004;15:257-60.

JAYPEE BROTHERS

for detailed information on medicine books, visit our website **www.jaypeebrothers.com,** for detailed information on medicine bo

Textbook of
PLEURAL DISEASES

Salient Features

- First textbook about pleural disease written and edited by Indian authors
- First pleural textbook which has contributions from multiple authors
- Textbook of pleural disease which has been authored by multiple specialties—a unique feature where each chapter has been written by the concerned specialists, e.g., pleural disease in kidney disease by nephrologist, hepatic hydrothorax by hepatologist, and pleural disease in gynecological disorder by gynecologist
- Every aspect of pleura from embryology, anatomy, physiology, and radiological diagnosis has been covered in detail
- Role of ultrasonography in pleura, which is now a vital tool for point-of-care management has been described in detail
- High-quality pleural imaging and its highlights are shown in concerned chapters
- Pathophysiologic basis of pleural diseases has been discussed with each specific disease
- Concise algorithm summarizing disease management has been clearly depicted
- Updated treatment as per recent guidelines has been incorporated
- The topics in pleural diseases have been written by eminent chest physicians all over India
- A special chapter describes pleural diseases in COVID, in the post pandemic era
- Being a Lung Transplant center, a special chapter on overview on pleura issues in lung transplant has been elaborated

Ashish Kumar Prakash is a Respiratory Medicine Specialist in Gurugram and is currently working as a Senior Consultant in Department of Respiratory and Sleep Medicine in Medanta. He is a qualified MBBS, DTCD (Patel Chest), DNB (Pulmonary Medicine) (Lilavati Hospital, Mumbai), and EDARM (Netherlands). He is a Fellow of American College of Chest Physician, USA, Asia Pacific Society of Respirology and NCCP; life member of ERS, Indian Chest Society, Indian Sleep Disorder Association and Indian Allergy Society. He is a great scholar with several original research papers. He has vast experience of pleural disease and special interest in Allergy and Interventional Pulmonary Medicine.

Anand Jaiswal is the Senior Director of Department of Respiratory and Sleep Medicine in Medanta. He has completed his MD from Patel Chest, Delhi in 1987 in TB and Respiratory Diseases and was awarded gold medal for overall performance for the same by Delhi University. He has more than 30 years of experience in various hospitals. He was awarded a fellowship in TB research and operations in USA by WHO in 1996. He has been a part of many research works with Indian and overseas trail sponsors. He is an astute clinician and loves teaching postgraduate students. His students are practising pulmonary medicine all over the India and worldwide. His expertise are in tuberculosis and lung cancer.

Randeep Guleria is the chairman of the Institute of Internal Medicine and Respiratory and Sleep Medicine and Director, Medical Education at Medanta. He was leading AIIMS, New Delhi as Director and CEO. He is the former Professor and Head of Pulmonary Medicine, Critical Care and Sleep Disorders at the AIIMS. He has received "Padma Shri" in 2015 in the field of Medicine and Dr BC Roy National Award for Eminent Medical person in 2014 and the "Lung India Award" by the Indian Chest Society in 2014. He has been awarded Doctor of Science (DSc) Honoris Causa by IIT, Kharagpur, Rajasthan University of Health Science and Amity University. He had many other prestigious awards, such as the Swastha Bharat Samman for Medicine from LIC and Zee TV, Himachal Gaurav Puraskar, the 22nd Lal Bahadur Shastri National award for excellence in 2021, and Doctor of the decade of Indian Medical Association. He is also an advisor and consultant to various international and national bodies, including the WHO (Geneva) and the International Atomic Energy Agency (IAEA) (Vienna). He has more than 485 publications, 52 book chapters, over 50 research grants, and has delivered more than 12 orations. He has been the personal physician to the Prime Minister of India.

Bornali Datta is the Director in Department of Respiratory and Sleep Medicine, Medanta. She has done MBBS and MD (Medicine) from MAMC, New Delhi and MRCP from Royal College of Physicians, Edinburgh and CCST (Respiratory/GIM), Postgraduate Training Board UK. She has recently completed her MPH from London School of Hygiene and Tropical Medicine. She has worked as Specialist Registrar and Consultant Respiratory Medicine in Yorkshire, UK, before returning to India and joining Medanta. She feels passionately about medicine and health inequity and runs a public private program called Mission TB Free India. She has written a fiction book, "In A Better Place—A Doctor's Journey" about the lives of doctors.

Printed in India

Available at all medical bookstores
or buy online at www.jaypeebrothers.com

JAYPEE BROTHERS
Medical Publishers (P) Ltd.
EMCA House, 23/23-B, Ansari Road,
Daryaganj, New Delhi - 110 002, INDIA
www.jaypeebrothers.com

Join us on facebook.com/JaypeeMedicalPublishers

Shelving Recommendation
MEDICINE

ISBN 978-93-5696-892-9