ebsite www.jaypeebrothers.com, for detailed information on pediatric books, visit our website www.jaypeebrothers.com

Case Based Reviews in Pediatric Endocrinology



Editors
Vandana Jain
Ram K Menon

2nd Edition

Forewords
Vinod K Paul
Raghupathy Palany

JAYPEE

Contents

Contributors ..... *ix*
Forewords ..... *xv, xvii*
Preface to the Second Edition ..... *xix*
Preface to the First Edition ..... *xxi*
Acknowledgments ..... *xxiii*

SECTION 1: Endocrine Disorders Presenting in Neonatal Period or Early Infancy

1. **Hypoglycemia in Neonates and Infants** **3**
   Zainaba Mohamed, Indraneel Banerjee, Raja Padidela
2. **Neonatal Diabetes Mellitus** **22**
   Hemchand Krishna Prasad, Ram K Menon
3. **Disorders of Sex Development Presenting During Neonatal Period/Early Infancy** **34**
   Sudha Rao, Kavya DR
4. **Disorders of Calcium Homeostasis in the Neonate** **57**
   Preeti Singh, Anju Seth
5. **Hypothyroidism and Hyperthyroidism in the Neonate** **74**
   Sarah Mathai, Anna Simon

SECTION 2: Disorders of Growth, Sex Development, and Puberty

6. **Abnormalities of Growth** **87**
   Jacqueline Fisher, Ram K Menon
7. **Disorders of Sex Development Presenting in Older Children** **106**
   Karen Lin-Su, Mabel Yau, Ming Chen
8. **Puberty and Its Disorders** **114**
   Brigid E Gregg, David P Olson
9. **Endocrine Issues in Children with Neoplastic Disorders** **129**
   Ildiko H Koves, Christian L Roth

10. **Polycystic Ovarian Syndrome and Hyperandrogenism in Adolescent Girls 141**
Ahila Ayyavoo

SECTION 3: Disorders of Thyroid and Adrenal Glands

11. **Hypo- and Hyperthyroidism in Children and Adolescents..... 153**
Alexander C Waselewski, Inas H Thomas

12. **Thyroid Nodules and Thyroid Cancer in Children and Adolescents 163**
Steven W Bruch

13. **Adrenal Insufficiency 171**
Sukanya Priyadarshini, Vandana Jain

14. **Cushing Syndrome..... 186**
Anurag R Lila, Nalini S Shah

15. **Endocrine Hypertension in Children and Adolescents 195**
Aashima Dabas, Rajesh Khadgawat

SECTION 4: Diabetes Mellitus

16. **Type 1 Diabetes Mellitus 211**
Varuna Vyas, Vandana Jain

17. **Type 2 Diabetes Mellitus 233**
Nellie S Hani, Ram K Menon

18. **Maturity-Onset Diabetes of the Young and Other Forms of Diabetes Mellitus..... 244**
Rochelle N Naylor

SECTION 5: Obesity, Metabolic Syndrome and Dyslipidemia

19. **Exogenous Obesity and Its Management 257**
Naval K Vikram

20. **Genetic and Syndromic Forms of Obesity..... 269**
Neerja Gupta, Rakesh Kumar, Madhulika Kabra

21. Lipid Disorders in Children and Adolescents 284
Christy Foster, Ambika Ashraf

SECTION 6: Disorders of Water, Electrolyte, and Mineral Balance

22. Endocrine Causes of Abnormalities in Water and Sodium Homeostasis 297
Jaivinder Yadav, Amit Kumar Satapathy, Vandana Jain

23. Disorders of Calcium Homeostasis in Children and Adolescents 312
Pamali Mahasweta Nanda, Devi Dayal

24. Rickets 329
Rajni Sharma

25. Osteoporosis and Other Disorders of Bone Health in Children 346
Sapna Nayak, Preeti Dabadghao

SECTION 7: Endocrine Imaging, Dynamic Endocrine Tests, and Growth Charts

26. Radiological Imaging in Pediatric Endocrine Disorders 369
Manisha Jana, Devasenathipathy Kandasamy, Arun K Gupta

27. Nuclear Imaging in Pediatric Endocrine Disorders 390
Sneha Prakash, Nishikant Avinash Damle, Priyanka GB

Appendix 1. Growth Charts and Nomograms 408
Priyanka Gupta, Vandana Jain

Appendix 2. Protocols for Dynamic Endocrine Tests and Reference Values 421
Jaivinder Yadav, Arun George, Praveen George Paul

Index 443

3 CHAPTER

Disorders of Sex Development Presenting During Neonatal Period/Early Infancy

Sudha Rao, Kavya DR

CASE 1

A 6-month-old baby, reared as male, is referred for passing urine from an abnormal site and atypical genitalia. He is second born to 28-year-old mother, with an uneventful antenatal period, by vaginal delivery at full term with birth weight of 2,560 g. He had a normal perinatal transition and neonatal period, was feeding adequately at breast, growing well and gaining milestones appropriately.

Family history: No significant family history, specifically no adrenal disorders, precocious puberty, neonatal death, infertility, virilization in women, or short stature. Consanguinity is denied.

Physical examination: Active, feeding well, has attained age-appropriate milestones. Present weight is 6,200 g, length 65 cm, and occipitofrontal circumference is 41 cm, with normal blood pressure (BP) and no dysmorphism. Genitalia reveal well-formed, rugose scrotum with both gonads palpable which are normal in feel. A single pseudovaginal penoscrotal opening is present. Stretched penile length (SPL) is 3 cm with width of 0.5 cm. External masculinization score (EMS) is 6. There is no hyperpigmentation **(Figs. 1A and B)**. Rest of the physical examination is unremarkable.

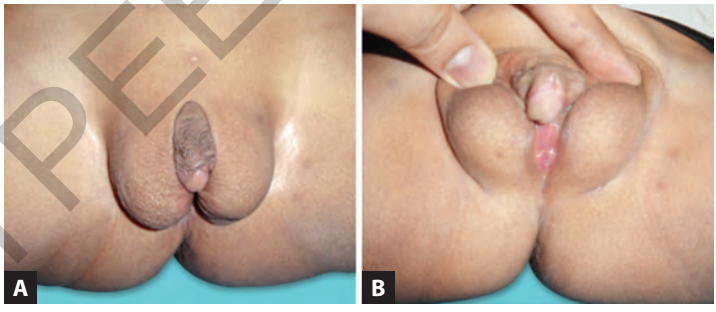

Figs. 1A and B: Case 1—atypical genitalia.

Q. What are disorders (differences) of sex development?

Disorders of sex development (DSD), also referred to as differences of sex development, are a heterogeneous group of congenital conditions of human sex determination and/or differentiation, wherein the chromosomal, gonadal, and phenotypic/anatomical sexes are atypical. Although many children with DSD present with atypical genitalia, some forms of DSD may have normal-looking external genitalia.

JAYPEE BROTHERS

Q. Does this infant have a DSD?

This infant has an atypical phenotypic/anatomical sex, hence, needs evaluation for DSD.

When an infant presents with atypical genitalia, it is essential to ascertain that it is not part of a developmental defect, as is seen with cloacal anomalies, aphallia, penoscrotal transposition, buried penis, labial fusion, etc. It is important to note that 3.5% of term and 20% of preterm babies may have unilateral undescended testes in the newborn period, which may be a normal variation and of less concern if the penile length and the location of the uretheral meatus are normal. Similarly, isolated distal hypospadias is typically unlikely to represent a DSD.

Q. How common is DSD and what are the causes?

The incidence of DSD is approximately 1:4,500–1:5,000 live births. Normal human sex development is a dynamic process which requires a sequential, well-orchestrated interaction between multitude of genes, proteins, and endocrine and paracrine factors. The sequential stages of fetal sex development of gonadal determination, gonadal differentiation, and differentiation of external and internal genitalia are depicted in **Flowchart 1**.

DSD may result from numerical or structural variation in sex chromosomes, variation in genes involved in gonadal and/or genital development, disorders of steroidogenesis, endocrine disruptors interfering with genital development, epigenetic changes predicted to disrupt gene expression in the fetal period via deoxyribonucleic acid (DNA) methylation, histone modifications, and noncoding ribonucleic acids (RNAs). Despite a large number of genes characterized in DSD, currently known genes explain only about 50% of cases. Etiological classification of DSD is shown in **Box 1**.

JAYPEE BROTHERS

Flowchart 1: Schematic representation of sex development. At 4–6 weeks of gestation, the urogenital ridges develop as paired outgrowths of coelomic epithelium on the ventral side of the mesonephros. *SF1, WT1, GATA4, EMX2*, and *LIM1* are responsible for differentiation of bipotential gonads from urogenital ridges. Bipotential gonads differentiate into testes in the presence of sex-determining region on Y *(SRY), SOX9*, and *SF1*. Ovarian differentiation is influenced by specific genes such as *RSPO1, WNT4, DAX1, FOXL2*, and *CTNNB1* (β catenin). Anti-Müllerian hormone (AMH) secreted by Sertoli cells promotes regression of Müllerian ducts via its paracrine action on the AMH type 2 receptor (AMHR2). Testosterone secreted by Leydig cells stabilizes the Wolffian structures in 46,XY fetuses. In the absence of AMH and local testosterone in 46,XX fetuses, Müllerian structures persist and Wolffian ducts regress. Testosterone undergoes conversion to dihydrotestosterone (DHT) by 5α-reductase type 2 in target tissues to promote androgenization of external genitalia and the urogenital sinus. Testosterone and DHT mediate their effects through the androgen receptor (AR).

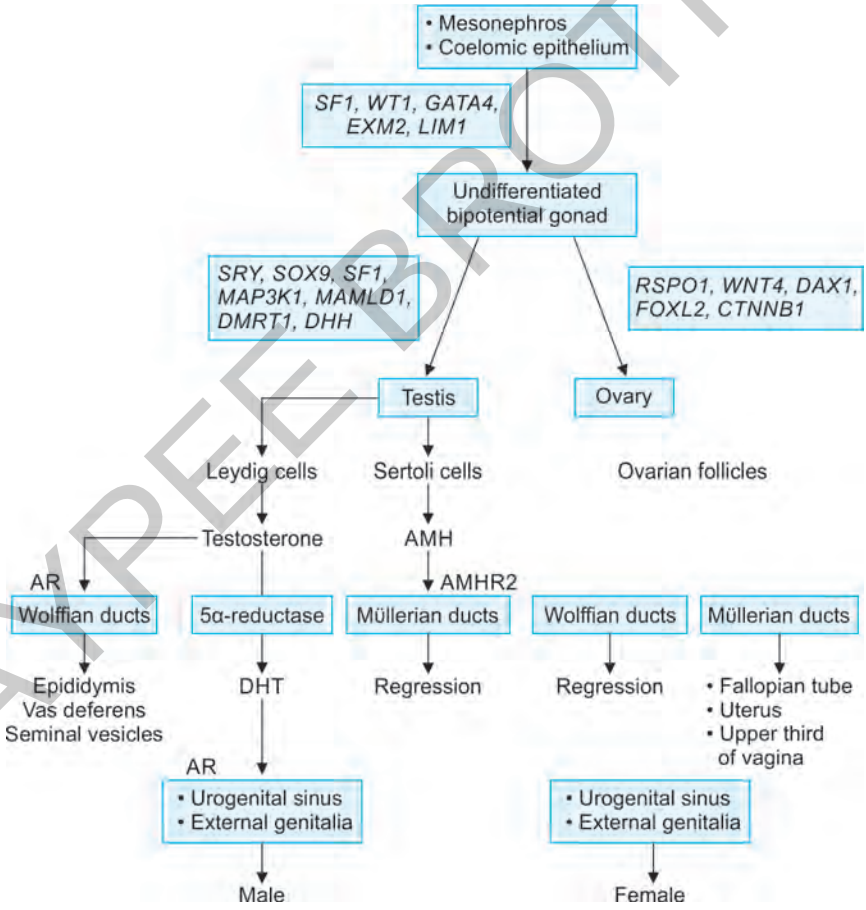

JAYPEE BROTHERS

BOX 1: Classification of DSD as per chromosomal sex.

46,XY DSD

- *Disorders of gonadal development:*
  - Complete or partial gonadal dysgenesis:
    - Denys–Drash syndrome (*WT1*—missense exon variant)
    - Frasier syndrome (*WT1*—canonical splice site variant)
    - Campomelic dysplasia (*SOX9*)
    - *SRY* (deletion/variation)
    - *DHH*
    - *SF1/NR5A1*
    - *GATA4*
- Ovotesticular DSD
- Testicular regression syndrome
- *Disorder of androgen synthesis/action:*
  - Disorder of androgen synthesis:
    - Smith–Lemli–Opitz syndrome (*DHCR7*)
    - Leydig cell hypoplasia (*LHCGR*)
    - Lipoid adrenal hyperplasia (*STAR*)
    - Side chain cleavage defect (*CYP11A1*)
    - 3β-hydroxysteroid dehydrogenase type 2 defect (*HSD3B2*)
    - 17α-hydroxylase/17,20 lyase defect (*CYP17A1*)
    - P450 oxidoreductase defect (*POR*)
    - 17β-hydroxysteroid dehydrogenase defect (*HSD17B3*)
    - 5α-reductase deficiency (*SRD5A2*)
  - Disorders of androgen action:
    - Androgen insensitivity syndrome [androgen receptor (*AR*)]
    - Drugs and environmental endocrine disruptors
- *Others:*
  - Persistent Müllerian duct syndrome
  - Syndromic forms associated with atypical genitalia (e.g., Aarskog, Robinow, Popliteal Pterygium, VACTERL, cloacal anomalies)
  - Aneuploidies associated with atypical genitalia (e.g., trisomy 13, trisomy 18, triploidy, 4p deletion, 13q deletion, monosomy 9p, Xq28 deletion)
  - Isolated hypospadias
  - Aphallia

46,XX DSD

- *Disorders of gonadal development (ovaries):*
  - Gonadal dysgenesis
  - Ovotesticular DSD
  - Testicular DSD
- *Disorders of androgen excess:*
  - Fetal:
    - 3β-hydroxysteroid dehydrogenase 2 defect (*HSD3B2*)
    - 21-hydroxylase defect (*CYP21A2*)
    - 11β-hydroxylase defect (*CYP11B1*)
    - P450 oxidoreductase defect (*POR*)
    - Glucocorticoid receptor defect (*NR3C1*)

Contd…

JAYPEE BROTHERS

Contd…

  - Fetoplacental:
    - Aromatase defect (*CYP19A1*)
    - P450 oxidoreductase defect (*POR*)
  - Maternal:
    - Virilizing tumors
    - Androgenic drugs
- *Others:*
  - Müllerian agenesis/hypoplasia (Mayer–Rokitansky–Küster–Hauser syndrome)
  - Uterine/vaginal anomalies

Sex chromosome DSD
- 45,XO (Turner syndrome)
- 45,XO/46,XY (mixed gonadal dysgenesis)
- 47,XXY (Klinefelter syndrome)

[CYP: cytochrome P450; DSD: disorders of sex development; LH: luteinizing hormone; StAR: steroidogenic acute regulatory (protein); VACTERL: vertebral anomalies, anal anomalies, cardiac defects, tracheoesophageal fistula, renal anomalies, and limb anomalies]

Q. What is the approach to a child with DSD? (Flowcharts 2A and B)

Evaluation of a case of DSD requires determination of the following:

- Are the adrenal glands affected?
  Disorders of sex development with adrenal steroidogenesis defects may present with life-threatening adrenal crisis. In infants and children, failing to thrive, recurrent vomiting, hyperpigmentation, salt craving, polyuria, and hypoglycemic seizures are indicative of underlying adrenal steroidogenesis defects. The important conditions in which adrenal glands are/may be affected include congenital adrenal hyperplasia (CAH), *NR5A1* (*SF1*) mutations, *NR0B1* (*DAX-1*) mutations, Smith–Lemli–Opitz syndrome, IMAGe (intrauterine growth restriction, metaphyseal dysplasia, adrenal hypoplasia congenita, and genital anomalies) syndrome, etc.
- Are the gonads palpable? On one side or both?
  When gonads are palpable on both sides, 46,XY DSD is likely and could be due to defects in androgen synthesis or action. When one gonad is palpable and the genitalia looks asymmetric, 45,X/46,XY gonadal dysgenesis or an ovotesticular DSD is likely. When bilateral gonads are not palpable, 46,XX CAH should be strongly suspected.
- Are Müllerian structures present?
  The presence of Müllerian structures could point toward 46,XX DSD, 46,XY gonadal dysgenesis, 45,X/46,XY gonadal dysgenesis or an ovotesticular DSD. When Müllerian structures are present, 46,XY DSD due to defects of androgen synthesis or action are unlikely.

JAYPEE BROTHERS

Flowchart 2A: Approach to atypical genitalia with nonpalpable gonads.

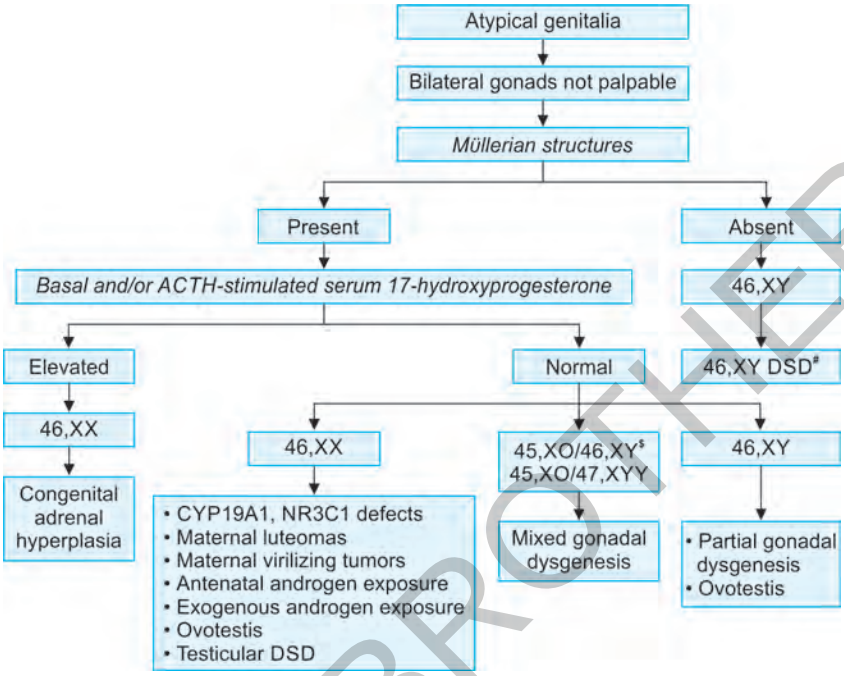

$45,XO/46,XY is the most commonly identified karyotype in patients with mixed gonadal dysgenesis.
#46,XY DSD due to disorders of androgen synthesis and action.
(ACTH: adrenocorticotropic hormone; DSD: disorder of sex development)

Flowchart 2B: Approach to atypical genitalia with palpable gonads.

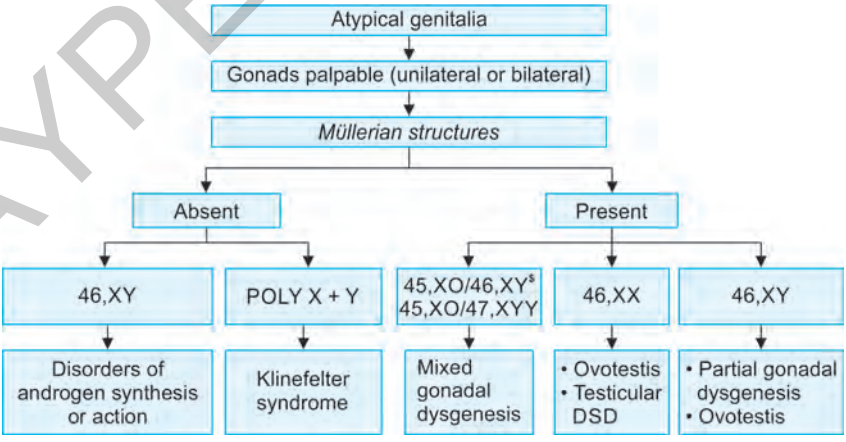

$45,XO/46,XY is the most commonly identified karyotype in patients with mixed gonadal dysgenesis.
(DSD: disorder of sex development)

JAYPEE BROTHERS

- What is the karyotype?
  Karyotype helps in categorizing the DSD as sex chromosome DSD, XY DSD or XX DSD. When the karyotype is XX, checking for *SRY* gene will be necessary for some of the etiologies.

Case Progression

Palpable gonads in the scrotum are testes, indicating that the baby likely has 46,XY karyotype. Inadequate masculinization in a genetically male baby may result from gonadal dysgenesis, androgen synthetic defects (steroidogenic), or defects in androgen action. Of these three, steroidogenic defects may pose life-threatening situation.

The presence of good weight gain possibly indicates adequate adrenal glucocorticoid (GC) and mineralocorticoid (MC) reserves, but testosterone biosynthetic defects need to be considered. Bilateral palpable testes which are well descended and normal in feel make gonadal dysgenesis unlikely. Thus, we should rule out defects of androgen synthesis and androgen action in this inadequately masculinized baby.

Q. Do all cases of DSD require investigations?

Any infant with genital appearance discordant with chromosomal sex needs detailed evaluation.

Based on clinical phenotype, in male-looking genitalia, evaluation is necessary in the following:

- Any degree of hypospadias with unilateral or bilateral undescended gonads
- Absence of one or both gonads with or without micropenis (SPL ≤ 2.5 cm in full term)
- Asymmetry of genitalia
- Proximal hypospadias (scrotal or perineal) with bilateral palpable gonads

External masculinization score (EMS) from 0 to 12 is assigned based on the presence of scrotal fusion, micropenis, location of urethral meatus, and position of gonads. A lower score indicates more severe underandrogenization and typically, EMS ≤ 10 indicates the need for evaluation.

In female-looking genitalia, the following indicate need for detailed evaluation:

- Clitoromegaly (clitoral length >9 mm or width >6 mm)
- Posterior labial fusion (anogenital ratio >0.5)
- Single opening (common urogenital sinus)
- Gonads palpable in labioscrotal fold or inguinal region

Q. What investigations are needed?

A stepwise approach to investigations is recommended.

JAYPEE BROTHERS

Expedite the determination of the presence of *SRY* gene by polymerase chain reaction (PCR) or fluorescent in situ hybridization (FISH). Peripheral blood karyotype (in at least 30 cells to detect mosaicism) will help to identify the chromosomal sex of the baby as it helps classify the DSD **(Box 1)**.

Check the presence of Müllerian structures and gonads by sonography or MRI pelvis. Identification of these structures, especially of the gonads, is not always easy, particularly in neonatal and early infancy period. Therefore, lack of detection does not necessarily entail their absence. In a 46,XY DSD, presence of Müllerian structures is suggestive of gonadal dysgenesis and absence of Müllerian structures is seen in disorders of androgen synthesis or action.

Hormonal evaluation is guided by the phenotypic sex in terms of assessment of gonadal functions and measurement of adrenal steroids.

Serum 17-hydroxyprogesterone (17OHP) should ideally be measured in all newborns as part of newborn screening program but especially in those with atypical genitalia or bilateral nonpalpable gonads. CAH 21-hydroxylase deficiency (CAH 21-OHD), the most common form of CAH, if undiagnosed, and hence untreated, can lead to life-threatening adrenal insufficiency within the first weeks of life. Other adrenal steroidogenesis defects can be diagnosed by evaluation of basal and/or ACTH-stimulated serum steroid panel by liquid chromatography coupled to mass spectrometry (LC-MS/MS) as it combines steroid hormones and their precursors in a single analysis. Commercially available 13 steroid panel includes cortisol, 11-deoxycortisol, 11-deoxycorticosterone, 21-deoxycortisol, corticosterone, cortisone, androstenedione, dehydroepiandrosterone sulfate (DHEAS), pregnenolone, 17-hydroxy pregnenolone, progesterone, 17OHP, and testosterone.

With regard to testing of gonadal functions, in XY,DSD cases, besides serum anti-Müllerian hormone (AMH) and inhibin B, estimation of unstimulated follicle-stimulating hormone (FSH), luteinizing hormone (LH), total testosterone (T), 5α-dihydrotestosterone (DHT), and androstenedione (D4A) are helpful during the period of "mini-puberty," a period of transient activation of the hypothalamic–pituitary–gonadal (HPG) axis that typically lasts from around 4 weeks of postnatal age to about 6 months in boys. An LH concentration above 0.3 mIU/mL demonstrates that the infant has entered "mini-puberty." If LH is low and the infant is younger than 14 days, testing should be repeated later, when the child is more likely to be in mini-puberty. Premature infants may take longer to enter the "mini-puberty" phase. During mini-puberty, circulating levels of T help to rule out testosterone biosynthesis defect and the value of T/D4A ratios of >0.8 and the value T/DHT ratio of <10 is helpful in ruling out 17β-HSD3 deficiency and 5α-reductase 2 deficiency, respectively. It is important that levels of

JAYPEE BROTHERS

all three hormones, D4A, T, and DHT, should be performed at the same reputable reference laboratory, ideally by LC-MS/MS.

Beyond the period of mini puberty, human chorionic gonadotropin (hCG) stimulation could be performed to check the Leydig cell function (For hCG stimulation test, *See* Appendix 2). As genetic tests and estimation of serum AMH have become more readily available, hCG stimulation test has become less useful.

Serum AMH levels have clear sexual dimorphism (boys >30 ng/mL; girls <10 ng/mL) until puberty. In 46,XX infant an elevated AMH level indicates the presence of Sertoli cells and suggests an XX testicular or ovotesticular DSD. In 46,XY infant with atypical genitalia, low AMH level is suggestive of gonadal dysgenesis affecting Leydig and Sertoli cells, while normal AMH levels suggest disorder of androgen synthesis or action. Low AMH level but normal external genitalia are seen in 46,XY infants with persistent Müllerian duct syndrome (PMDS).

There are multitudes of genes associated with DSD **(Table 1)**. If the clinical and hormonal profile does not suggest a specific genetic diagnosis, multigene sequencing with a DSD gene panel or comprehensive sequencing methods such as whole-exome or whole-genome sequencing can be done as these are becoming increasingly available and cost-effective.

TABLE 1: Genes involved in disorders of sex development.

Gene inheritance	***Gonads***	***Associated features/variants***
Causes of 46,XY DSD		
Disorders of gonadal (testicular) development: Single-gene disorders		
WT1 AD	Dysgenetic testes	Denys–Drash syndrome, Frasier syndrome
NR5A1/SF1 AD/AR (SLD)	Dysgenetic testes (variable)	More severe phenotypes include primary adrenal failure; milder phenotypes have isolated partial gonadal dysgenesis or impaired androgenization or both
GATA4 AD (SLD)	Dysgenetic testes (variable)	Cardiac defects (e.g., septal defects, tetralogy of Fallot)
ZFPM2 (FOG2) AD	Dysgenetic testes (variable)	Congenital heart defects, learning and language difficulties
CBX2 AR	Ovaries	
SRY Y-linked	Dysgenetic testes or ovotestes	

Contd…

JAYPEE BROTHERS

Contd…

Gene inheritance	***Gonads***	***Associated features/variants***
Causes of 46,XY DSD		
Disorders of gonadal (testicular) development: Single-gene disorders		
SOX9 AD	Dysgenetic testes or ovotestes	Campomelic dysplasia
SOX8 AD, de novo	Dysgenetic testes (variable)	
MAP3K1 AD	Dysgenetic testes (variable)	
NR3A2 (ESR2) AD/AR	Dysgenetic testes	Variable (anal atresia, blepharophimosis, dysmorphic features)
DMRT1 AD	Dysgenetic testes	
TSPYL1 AD	Dysgenetic testes	Sudden infant death
DHH AR	Dysgenetic testes (Leydig)	Minifascicular neuropathy in several patients
SAMD9 AD, de novo	Dysgenetic testes (Leydig)	MIRAGE syndrome (myelodysplasia, infections, restriction of growth, adrenal hypoplasia, genital phenotypes, enteropathy)
ARX X-linked	Dysgenetic testes (Leydig)	X-linked lissencephaly, epilepsy, temperature instability
MAMLD1 X-linked	Dysgenetic testes (Leydig)	
Disorders of gonadal (testicular) development: Chromosomal changes involving candidate genes		
DMRT1 Monosomic deletion	Dysgenetic testes	Intellectual disability
ATRX X-linked	Dysgenetic testes	Alpha thalassemia, intellectual disability
NR0B1/DAX1 dupXp21 (X-linked)	Dysgenetic testes or ovaries	
WNT4 dup1p35	Dysgenetic testes	Intellectual disability
Disorders of hormone synthesis and action		
DHCR7 AR	Testes	Smith-Lemli-Opitz syndrome: coarse facies, second-third toe syndactyly, failure to thrive, developmental delay, cardiac and visceral abnormalities

Contd…

JAYPEE BROTHERS

Contd…

Gene inheritance	***Gonads***	***Associated features/variants***
Causes of 46,XY DSD		
Disorders of hormone synthesis and action		
LHCGR AR	Testes	Leydig cell hypoplasia
STAR AR	Testes	Lipoid CAH (primary adrenal failure), pubertal failure
CYP11A1 AR	Testes	CAH (primary adrenal failure), pubertal failure
HSD3B2 AR	Testes	CAH, primary adrenal failure
CYP17A1 AR	Testes	CAH, hypertension
POR AR	Testes	Mixed features of 21-hydroxylase deficiency, 17α-hydroxylase/17,20-lyase deficiency, and aromatase deficiency; sometimes associated with Antley-Bixler craniosynostosis
AKR1C2 AR	Testes	Methemoglobinemia
HSD17B3 AR	Testes	Partial androgenization at puberty, ↑ ratio of androstenedione to testosterone
SRD5A2 AR	Testes	Partial androgenization at puberty, ↑ ratio of testosterone to DHT
AR X-linked	Testes	Phenotypic spectrum from complete AIS (female external genitalia) to partial AIS (ambiguous) to normal male genitalia/ infertility
AMH AR	Testes	Persistent Müllerian duct syndrome (PMDS)
AMHR AR	Testes	Male external genitalia, bilateral cryptorchidism
Causes of 46,XX DSD		
Disorders of gonadal (ovarian) development		
SRY Translocation	Testes or ovotestes	
SOX9 dup17q24 or deletion of regulatory region	Not determined	

Contd…

JAYPEE BROTHERS

Contd…

Gene inheritance	***Gonads***	***Associated features/variants***
Causes of 46,XX DSD		
Disorders of gonadal (ovarian) development		
SOX3 dup Xq27 or deletion of regulatory region	Testes (variable)	
NR5A1/SF1 AD/de novo	Testes or ovotestes	
NR2F2 AD/de novo	Testes or ovotestes	Cardiac defects, diaphragmatic hernia, BPES
RSPO1 AR	Testes or ovotestes	Palmar-plantar hyperkeratosis, squamous cell carcinoma
WNT4 AR	Testes or ovotestes	SERKAL syndrome
Androgen excess		
HSD3B2 AR	Ovaries	CAH, primary adrenal failure, partial androgenization
CYP21A2 AR	Ovaries	CAH, phenotypic spectrum from severe salt-losing forms associated with adrenal failure to simple virilizing forms with compensated adrenal function
CYP11B1 AR	Ovaries	CAH, hypertension, hypokalemia
POR AR	Ovaries	Mixed features of 21-hydroxylase deficiency, 17α-hydroxylase/17,20-lyase deficiency and aromatase deficiency; associated with Antley-Bixler craniosynostosis
CYP19A1 AR	Ovaries	Maternal androgenization during pregnancy, absent breast development at puberty except in partial cases
NR3C1 AR	Ovaries	↑ ACTH, 17OHP, cortisol, mineralocorticoids, and androgens; failure of dexamethasone suppression

[ACTH: adrenocorticotropic hormone; AD: autosomal dominant (often de novo mutation); AIS: androgen insensitivity syndrome; AR: autosomal recessive; BPES: blepharophimosis-ptosis-epicanthus inversus syndrome; CAH: congenital adrenal hyperplasia; CYP: cytochrome P450 enzyme; DHEA: dehydroepiandrosterone; DHT: dihydrotestosterone; DSDs: disorders of sex development; 17OHP: 17-hydroxyprogesterone; LHCGR: luteinizing hormone (LH) or human chorionic gonadotropin (hCG) receptor; SERKAL: sex-reversal with kidney, adrenal, and lung dysgenesis; SLD: sex-limited dominant]

JAYPEE BROTHERS

for detailed information on pediatric books, visit our website www.jaypeebrothers.com, for detailed information on pedia

Case Based Reviews in Pediatric Endocrinology

Salient Features

- Extensively revised, updated, and expanded 2nd edition
- Case-based format with clear diagnostic algorithms and up-to-date treatment protocols
- Covers the entire spectrum of endocrine conditions in infants, children, and adolescents, including growth, puberty, obesity, diabetes, fluid and electrolyte disorders, calcium metabolism, thyroid and adrenal disorders, and differences of sex development
- New chapters/cases added for lipid disorders, maturity-onset diabetes of the young (MODY), polycystic ovarian syndrome (PCOS), monogenic hypertension, endocrine complications in children with neoplasia, adrenal insufficiency, thyroid nodules, and bone health
- Dedicated sections on endocrine disorders presenting in neonates, radiological and nuclear imaging, and protocols for dynamic endocrine assays
- Contributing authors include experienced national and international experts in pediatric endocrinology and other fields.



Vandana Jain is Professor, Division of Pediatric Endocrinology, Department of Pediatrics, All India Institute of Medical Sciences (AIIMS), New Delhi, India. She did MD Pediatrics from Maulana Azad Medical College, New Delhi, in 2001, and joined AIIMS, New Delhi, as Faculty in 2005. She did an observership in Pediatric Endocrinology at the University of Michigan, Ann Arbor, USA, as recipient of the prestigious LWPES International Scholar Award in 2008. She is a FAIMER Fellow in Medical Education, and has Specialty Certification in Endocrinology and Diabetes (SCE) from the Federation of Royal Colleges of Physicians, UK. She is the lead faculty for the DM Pediatric Endocrinology program at AIIMS, New Delhi. Her research interests are growth and body composition in low birth weight infants, obesity, and differences of sex development. She has conducted several government funded research projects, and has more than 135 peer-reviewed publications in national and international journals. She serves as an Expert Member in various national committees on growth, nutrition, and metabolic health in children and adolescents.



Ram K Menon is a Professor of Pediatrics and Professor of Molecular and Integrative Physiology at the University of Michigan, MI, USA. From 2002 to 2022, he served as the Director of Pediatric Endocrinology at the University of Michigan. He is currently the Director of the Pediatric Endocrinology Training Program at the University of Michigan. Since 2002 he has also served as the Director of the Endocrine Follow-up Coordinating Center for the State of Michigan's Newborn Screening Program. He received his medical education from the University of Delhi and the All India Institute of Medical Sciences, New Delhi, India. He pursued postgraduate training in pediatric endocrinology at the Royal Free Hospital, London, UK and the Children's Hospital Medical Center, Cincinnati, USA. His research interests are to understand the molecular mechanisms involved in regulation of the growth hormone receptor/insulin-like growth factor-1 axis. He has authored over 100 peer-reviewed publications and 50 reviews and book chapters. He served on the Pediatric Endocrinology Sub-Board of the American Board of Pediatrics as a member and subsequently as Chair. He is certified by the American Board of Pediatrics in Pediatrics and Pediatric Endocrinology.

Printed in India

Available at all medical bookstores
or buy online at www.jaypeebrothers.com



JAYPEE BROTHERS
Medical Publishers (P) Ltd.
EMCA House, 23/23-B, Ansari Road,
Daryaganj, New Delhi - 110 002, INDIA
www.jaypeebrothers.com

Join us on facebook.com/JaypeeMedicalPublishers

Shelving Recommendation
PEDIATRICS/ENDOCRINOLOGY

ISBN 978-93-5696-912-4