books, visit our website www.jaypeebrothers.com, for detailed information on radiology books, visit our website www.jaypeebrothers.com, for detailed information on radiology books

AIIMS-MAMC-PGI IMAGING SERIES

DIAGNOSTIC RADIOLOGY

Gastrointestinal and Hepatobiliary Imaging

Editors
Raju Sharma
Gaurav Shanker Pradhan
Manavjit Singh Sandhu

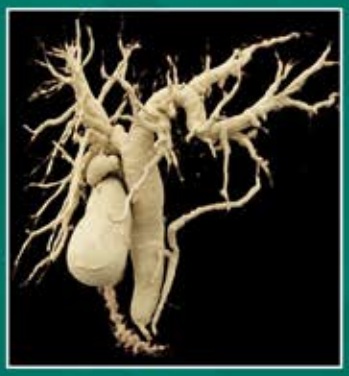







5th Edition

Associate Editors
Shivanand Gamanagatti
Ankur Goyal
Rashmi Dixit
Anjali Prakash
Mandeep Kang
Naveen Kalra

JAYPEE

Contents

Section 1: Bowel

1. Imaging Approach to Dysphagia **3**

Alpana Manchanda, Jyoti Kumar, Gaurav Shanker Pradhan

• Epidemiology 3; • Physiology of Swallowing 3; Pathogenesis of Dysphagia 4;
• Causes of Dysphagia 5; • Imaging Techniques in the Evaluation of Dysphagia 5;
• Functional Oropharyngeal Abnormalities 11; • Structural Oropharyngeal Abnormalities 11;
• Esophageal Motility Disorders 14; • Primary Motility Disorder 14; • Secondary Motility Disorder 18;
• Structural Esophageal Dysphagia 18; • Infectious Esophagitis 20; • Inflammatory Esophagitis 21;
• Esophageal Neoplasms 25; • Malignant Esophageal Neoplasms 27; • Leiomyosarcoma 29;
• Lymphoma 30; • Spindle Cell Carcinoma 31; • Primary Malignant Melanoma 31;
• Small Cell Carcinoma 32; • Staging of Esophageal Cancer 32; • Foreign Bodies 37;
• Extrinsic Narrowing 39

2. Imaging Approach to Gastric and Duodenal Pathologies **43**

Gaurav Shanker Pradhan, Rashmi Dixit, Radhika Batra

Stomach 43

• Gastric Neoplasms 43; • Inflammatory and Infectious Conditions 60; • Vascular Conditions 61;
• Emergency Conditions Affecting the Stomach 61; • Other Gastric Lesions 63;
• Postoperative Imaging of the Stomach 64

Duodenum 66

• Tumors of the Duodenum 66; • Infectious and Inflammatory Conditions 70;
• Traumatic and Vascular Conditions 71; • Anatomic Conditions 72

3. Ulceroconstrictive Diseases of the Gut **77**

Devasenathipathy Kandasamy, Manisha Jana, Ankita Aggarwal

• Plain Radiograph 77; • Barium Studies 77; • Contrast-enhanced CT and CT Enteroclysis/CT Enterography 78;
• MRI/MRE 79; • Ultrasonography and Contrast-enhanced Ultrasonography 79; • Abdominal Tuberculosis 80;
• Inflammatory Bowel Disease 87; • Newer Techniques to Differentiate Inflammatory versus Fibrotic Strictures 94;
• Imaging Features to Differentiate Intestinal TB from CD 95; • Ulcerative Colitis 95; • Miscellaneous Diseases 97

4. Tumors of the Small Bowel and Appendix **103**

Rashmi Dixit, Gaurav Shanker Pradhan, Anju Garg

Small Bowel Tumors 103

• Small Bowel Carcinogenesis: Pathogenesis 103; • Diagnostic Techniques 103; • Benign Tumors and Polyps 104;
• Polyposis Syndromes Involving the Small Bowel 107; • Malignant Tumors 108;
• Neuroendocrine Tumors 111; • Gastrointestinal Stromal Tumors 114; • Lymphoma 120;
• Kaposi's Sarcoma 128; • Leiomyosarcoma 128; • Metastatic Neoplasms 128

Appendiceal Neoplasms 131

• Epithelial Neoplasms 131; • Neuroendocrine Tumors 133; • Appendiceal Lymphoma 134;
• Differential Diagnosis 134

5. Colorectal Tumors **137**
Ajay Gulati, Naveen Kalra, Mandeep Kang, Mahesh Prakash

• Epidemiology 137; • Risk Factors 137; • Pathogenesis 138; • Clinical Features 138; • Pathology 138;
• Route of Spread 139; • Staging 139; • Role of Radiology 140; • Diagnostic Modalities 141;
• Recent Advances 157; • American College of Radiology Recommendations for Colorectal Cancer Staging 157;
• Other Epithelial Tumors of Colon 158; • Nonepithelial Tumors of Colon 158; • Secondary Tumors of Colon 159;
• Postoperative Colon and Recurrent Cancer 160

6. Imaging of Ischemic Bowel Diseases **164**
Ajay Gulati, Naveen Kalra, Arun Sharma, Mandeep Kang

• Anatomy of Splanchnic Circulation 164; • Etiology 166; • Pathophysiology of Ischemic Bowel Disease 166;
• Acute Mesenteric Ischemia 167; • Chronic Mesenteric Ischemia 176; • Colonic Ischemia 179

7. Gastrointestinal Hemorrhage: Imaging and Interventions **184**
Shivanand Gamanagatti, Devasenathipathy Kandasamy, Stuti Chandola

• Terminologies and Classification 184; • Clinical Presentation 185; • Etiologies 185;
• Evaluation and Algorithmic Approach 185; • Imaging Modalities 186;
• Interventional Radiology in Gastrointestinal Hemorrhage 192; • Transarterial Embolization 193;
• Hardware used in Transarterial Embolization 196; • Percutaneous Approach 201

Section 2: Liver

8. Diffuse Liver Diseases **207**
Surabhi Vyas, Ashu Seith Bhalla, Stanzin Spalkit, Smriti Hari

• Steatotic Liver Disease 207; • Hepatitis 216; • Iron Overload (Hemochromatosis and Hemosiderosis) 216;
• Storage Disorders 220; • Miscellaneous 220; • Cirrhosis 222

9. Nonneoplastic Focal Lesions of Liver **229**
Sapna Singh, Anjali Prakash, Satyam

• Developmental Lesions 229; • Infective Lesions 231; • Miscellaneous Lesions 251

10. Neoplastic Focal Lesions in Noncirrhotic Liver **255**
Ankur Goyal, Shrea Gulati, Sanjay Kumar Meena, Raju Sharma

• Benign Neoplastic Liver Lesions 255; • Malignant Liver Lesions 268; • Rare Neoplastic Liver Lesions 279;
• Neoplastic Liver Lesions in Pediatric Patients 281

11. Focal Lesions in Cirrhotic Liver: LI-RADS **288**
Raju Sharma, Shivanand Gamanagatti, Anjali Sah, Anuradha Sharma

• Liver Imaging Reporting and Data System 288; • Imaging Modalities 288;
• LI-RADS Surveillance Ultrasound (V2024) 290; • LI-RADS Contrast-enhanced Ultrasound (V2017) 291;
• LI-RADS Computed Tomography/Magnetic Resonance Imaging (V2018) 294;
• Limitations of LI-RADS 303; • Focal Lesions in Cirrhotic Liver 305

12. Interventional Radiology Treatment and Response Assessment of Liver Tumors **321**
Shivanand Gamanagatti, Rajendra Behera, Anuradha Sharma

• Treatment of Malignant Tumors 322; • Treatment of Metastatic Diseases of Liver 346;
• Treatment of Benign Liver Tumors 346

13. Imaging in Liver Transplant **353**

Chandan Jyoti Das, Sanchita Gupta, Krithika Rangarajan

• Indications and Contraindications for Liver Transplant 353; • Patient Selection 353;
• Hepatocellular Carcinoma 354; • Preoperative Imaging Modalities 355; • Preoperative Imaging Evaluation 355;
• Vascular Anatomy 356; • Postoperative Evaluation 360; • Imaging of Post-transplant Complications 361

14. Imaging and Interventions in Hepatic Venous Outflow Tract Obstruction **368**

Naveen Kalra, Sreedhara BC, Ujjwal Gorsi, Mandeep Garg

• Clinical Presentation 368; • Etiopathogenesis 368; • Diagnostic Techniques 369;
• Evaluation of Hepatic Veins in Budd–Chiari Syndrome 370; • Evaluation of Inferior Vena Cava in Budd–Chiari Syndrome 372; • Assessment of Liver Parenchyma in Budd–Chiari Syndrome 374;
• Management of Budd–Chiari Syndrome 377

Section 3: Biliary Tree

15. Inflammatory Disorders of Gallbladder and Biliary Tract **387**

Anjali Prakash, Sapna Singh, Rashmi Dixit, Deeksha Bhalla

• Imaging Approach 387; • Other Relevant Investigations 387; • Inflammatory Pathology of Gallbladder 389;
• Acute Calculous Cholecystitis 389; • Chronic Cholecystitis 390; • Nongallstone-associated Disorders 394;
• Inflammatory Disorders of Biliary Tree 397; • Miscellaneous Cholangitis 401

16. Malignant Pathologies of Gallbladder and Biliary Tree **403**

Pankaj Gupta, Ujjwal Gorsi, Naveen Kalra, Ajay Gulati

• Gallbladder Carcinoma 403; • Other Malignant Gallbladder Neoplasms 411; • Cholangiocarcinoma 411;
• Radiomics and Artificial Intelligence in BTC 415

17. Biliary Interventions **419**

Mandeep Kang, Harish Bhujade, Naveen Kalra, Anupam Lal

• Percutaneous Transhepatic Cholangiography 419; • Percutaneous Transhepatic Biliary Drainage 420;
• Patient Preparation 420; • Intraluminal Procedures through Percutaneous Transhepatic Biliary Drainage 426;
• Percutaneous Cholecystostomy 429

Section 4: Pancreas

18. Acute Pancreatitis: Imaging and Interventions **435**

Ankur Goyal, Sanchita Gupta, Raju Sharma

• Etiology and Pathophysiology 435; • Clinical Perspective 435; • Imaging 437;
• Complications of Acute Pancreatitis 441; • Image-guided Interventions in Acute Pancreatitis 453;
• Prevention of Recurrent Attacks 461

19. Chronic Pancreatitis and Its Variants **466**

Pankaj Gupta, Anupam Lal, Manphool Singhal, Mandeep Kang

• Definition of Chronic Pancreatitis 466; • Etiopathogenesis 466; • Classification of Chronic Pancreatitis 467;
• Diagnosis 467; • Imaging Modalities in Chronic Pancreatitis Diagnosis 467;
• Reporting Standards for CP Using CT, MRI, and MRCP 475; • Variants of Chronic Pancreatitis 475;
• Chronic Pancreatitis in Cystic Fibrosis 477; • Hereditary Pancreatitis 478;
• Chronic Pancreatitis and Pancreatic Ductal Adenocarcinoma 478

20. Pancreatic Cancer Imaging **483**

Ankur Goyal, Raju Sharma, Amarinder Singh Malhi, Dipin Sudhakaran

• Imaging Modalities 484; • Imaging Findings 488; • Pancreatic Cancer Variants 496;
• Differential Diagnoses 496; • Staging of Pancreatic Cancer 499; • Sampling 504; • Biomarkers 506;
• Follow-up Imaging 507; • Structured Reporting 507; • Role of Artificial Intelligence 507

21. Cystic Pancreatic Tumors and Neuroendocrine Tumors of Pancreas **512**

Jyoti Kumar, Alpana Manchanda, Swati Gupta

Cystic Pancreatic Tumors 512

• Imaging Modalities 512; • Clinical Presentation 512; • Classification 513;
• Uncommon Cystic Pancreatic Tumors 522

Pancreatic Neuroendocrine Neoplasms 522

• Specific Features of Functioning Pancreatic Neuroendocrine Neoplasms 525

Section 5: Miscellaneous

22. Nontraumatic Acute Abdomen **533**

Madhurima Sharma, Mandeep Kang, Anindita Sinha, Uma Debi

• Plain Radiographs in Evaluation of the Acute Abdomen 534; • Ultrasonography 536;
• Computed Tomography 536; • Magnetic Resonance Imaging 537;
• Role of Cross-sectional Imaging in Specific Disease Entities 537; • Miscellaneous 549

23. Imaging in Abdominal Trauma **554**

Atin Kumar, Shivanand Gamanagatti, Chandrashekhara SH

• Plain Radiography 554; • Ultrasonography 554; • Computed Tomography 555;
• Magnetic Resonance Imaging 556; • Digital Subtraction Angiography 557;
• Imaging and Management Protocols 557; • Diagnostic Imaging 557; • Spleen 562;
• Liver and Biliary Tract 563; • Pancreas 566; • Urinary Tract 567; • Adrenal 567;
• Hollow Viscus, Omental, and Mesenteric Injury 568; • Diaphragm 570; • Retroperitoneum 571;
• Abdominal Wall Injury 571; • Penetrating Abdominal Trauma 571

24. Imaging of Peritoneum and Mesentery **574**

Anju Garg, Anjali Prakash, Alpana Manchanda

• Imaging Modalities 574; • Radiomics 575; • Embryology 575; • Anatomy of the Peritoneum 575;
• Peritoneal Spaces 579; • Peritoneal Fluid Dynamics 581; • Ascites 581; • Pneumoperitoneum 582;
• Internal Hernias 582; • Peritoneal Infections and Inflammation 582; • Mesenteric Lymphadenopathy 593;
• Neoplastic Disease of Peritoneum 594; • Secondary Peritoneal Neoplasms 601;
• Miscellaneous Lesions of the Peritoneum 610

25. Imaging of Spleen **615**

Mukesh Kumar Yadav, Priyanka Naranje, Ekta Dhamija

• Introduction and Anatomy 615; • Imaging Modalities 616; • Splenic Size 621;
• Normal Variants/Developmental Anomalies 623; • Cystic Lesions of Spleen 625;
• Infectious Diseases of Spleen 628; • Splenic Neoplasms 635;
• Splenic Interventions Fine-needle aspiration Cytology and Biopsy of Spleen 642

26. Imaging of the Postoperative Abdomen **649**

Harish Bhujade, Mandeep Kang, Nidhi Prabhakar, Anmol Bhatia

• Imaging Modalities 649; • CT Protocol 649; • Normal Radiological Findings in the Postoperative Abdomen 650;
• Postoperative Complications 651; • Normal Postoperative Anatomy and Complications Specific to Procedure 657;
• Hepatobiliary Surgeries 661; • Early Postoperative Complications 662; • Late Postoperative Complications 662;
• Pancreatic Surgeries 664

27. Portal Hypertension: Imaging and Intervention **669**

Shivanand Gamanagatti, Dipin Sudhakaran, Smita Manchanda

Imaging of Portal Hypertension 669

• Causes of Portal Hypertension 669; • Anatomy of Portal System 669;
• Hemodynamic Measurement of Portal Pressure 676; • Morphologic Signs of Portal Hypertension 676;
• Varices 677; • Specific Situations 681; • Prehepatic Causes 682

Radiological Interventions in Portal Hypertension 686

Index **701**

CHAPTER 10

Ankur Goyal, Shrea Gulati,
Sanjay Kumar Meena, Raju Sharma

Neoplastic Focal Lesions in Noncirrhotic Liver

JAYPEE BROTHERS

INTRODUCTION

Focal liver lesions in noncirrhotic liver present a diverse array of diagnostic and therapeutic challenges, necessitating a nuanced understanding of their etiology, classification, diagnostic modalities, and management strategies. They may be symptomatic or incidentally detected. The gamut of radiological investigations such as ultrasonography (US), contrast-enhanced ultrasound (CEUS), computed tomography (CT), and magnetic resonance imaging (MRI) play a crucial role in the characterization of these lesions. While hepatocellular cancer (HCC) is the most feared focal lesion in patients with underlying liver cirrhosis, a variety of neoplastic lesions may be seen in the noncirrhotic liver. The management necessitates a multidisciplinary approach, encompassing radiologists, hepatologists, surgeons, and oncologists. This chapter outlines the approach toward a focal neoplastic lesion in the noncirrhotic liver. The lesions will be divided into benign, malignant, and rare neoplastic lesions **(Box 1)** followed by a brief overview of pediatric neoplastic liver lesions.

BOX 1 **Classification of neoplastic lesions in noncirrhotic liver.**

- *Benign lesions*:
  - Hepatic hemangioma
  - Focal nodular hyperplasia
  - Hepatocellular adenoma
  - Mucinous cystic neoplasm
- *Malignant lesions*:
  - Hepatocellular cancer
  - Fibrolamellar hepatocellular cancer
  - Mass-forming intrahepatic cholangiocarcinoma
  - Epithelioid hemangioendothelioma
  - Angiosarcoma
  - Metastasis
  - Hepatic lymphoma
- *Rare neoplastic lesions*:
  - Perivascular epithelioid cell tumor
  - Lipoma
  - Teratoma
  - Neurofibroma
  - Inflammatory pseudotumor
  - Primary hepatic neuroendocrine tumor
- *Pediatric neoplastic liver lesions*:
  - Hepatoblastoma
  - Mesenchymal hamartoma
  - Infantile hepatic hemangioma

BENIGN NEOPLASTIC LIVER LESIONS

Hepatic Hemangioma

Hemangioma is the most common solid-appearing lesion of the liver with an incidence of 20%.[1] It is often incidentally found on imaging, being two to five times more common in females, often attributed to the hormonal characteristics.[2] Though traditionally considered to be the most common benign neoplasm, currently, it is no longer considered neoplastic, rather it belongs to the category of low-flow venous malformations according to the International Society for the Study of Vascular Anomalies 2018 (ISSVA 2018). These lesions are often asymptomatic and associated with low risk of complications usually not requiring surgical resection. The typical forms are usually well-defined round lesions seen in the peripheral parenchyma or along the hepatic veins and include cavernous/typical hemangiomas and flash-filling hemangiomas (FFH).[3]

Cavernous (Typical) Hemangioma

Cavernous (typical) hemangioma is the most common subtype of hemangioma named after the cavernous vascular spaces seen on histopathological examination. Smaller lesions show typical findings on US in the form of a homogeneously hyperechoic lesion with posterior acoustic enhancement; however, larger lesions may appear heterogeneous due to thrombosis or fibrosis. US has a sensitivity of 96% and a specificity of 60% and is diagnostic in case of small lesions (<3 cm) showing typical features.[4] However, hypervascular metastasis and even HCC may appear similar and thus, diagnosis of hemangioma cannot be made on US alone in the presence of a primary malignancy or chronic liver disease (CLD).[5] CEUS shows a characteristic peripheral nodular enhancement in the early phase followed by centripetal filling-in and is thus never hypoenhancing in any phase (compared to the rest of the liver). This feature is especially useful in the diagnosis of hypoechoic hepatic hemangioma (HH) as well as in distinguishing hemangiomas from echogenic metastases which may occur in gastrointestinal and hypervascular primary malignancies **(Figs. 1A and B)**.[6] The findings on multiphasic cross-sectional modalities follow the blood pool in each phase. On unenhanced CT, hemangiomas are hypodense; on the arterial phase, the typical pattern is a peripheral discontinuous nodular enhancement followed by progressive slow centripetal filling **(Figs. 2A to D)**. In the late phases, the lesion gets completely filled and appears isodense/hyperdense to the background liver. Atypical forms, however, can show areas of thrombosis, hemorrhage, fibrosis, cystic degeneration, and calcification.[3] MRI is the best imaging modality in the diagnosis of HH with a sensitivity of 90–100% and a specificity of 91–99%.[7] MRI reveals a well-defined, lobulated, smooth homogenous lesion, brightly hyperintense on T2-weighted images (similar to fluid) described as the classical "light bulb sign."[8] This is considered as one of the hallmark MR features for diagnosing a hemangioma. The high T2 signal of these lesions causes them to appear bright on diffusion-weighted images (DWI) as well as the apparent diffusion coefficient maps—"T2 shine-through effect."[3] The absence of hepatocytes in these lesions makes them appear hypointense in the hepatobiliary phase. Since malignant lesions can also appear hyperintense on T2-weighted images, increasing the echo time causes the signal from malignant lesions to decrease and HH to increase, helping in differentiation.[5] While HH shows peripheral nodular enhancement in the arterial phase and retention in the delayed phase, hypervascular neoplastic lesions show arterial enhancement and washout in the delayed phase, allowing differentiation.

Flash-filling Hemangiomas

Flash-filling hemangiomas are also referred to as rapidly filling or (relatively) high-flow hemangiomas and previously termed capillary hemangiomas. Lesions are usually smaller (<1 cm) and have smaller vascular spaces. On CT and MRI, these show intense homogenous enhancement in the arterial phase, with attenuation matching the aorta in each phase **(Figs. 3A to C)**. FFH may be associated with arterioportal shunting with surrounding perilesional enhancement corresponding to transient hepatic attenuation differences (THAD).[9]

Hepatic hemangioma can show atypical findings on imaging **(Table 1 and Figs. 4A to H)**, in which case differentiation from close mimickers may be difficult. Multiple hemangiomas may be seen in 10–50% of the cases. Diffuse HH, characterized by multiple hemangiomas is a rare condition, characterized by entire liver studded with innumerable HH, which is seen more frequently in newborns, where the entire liver involvement results in arteriovenous shunting and high-output cardiac failure. Two morphological patterns are described, a multinodular form characterized by multiple small discrete and coalescent

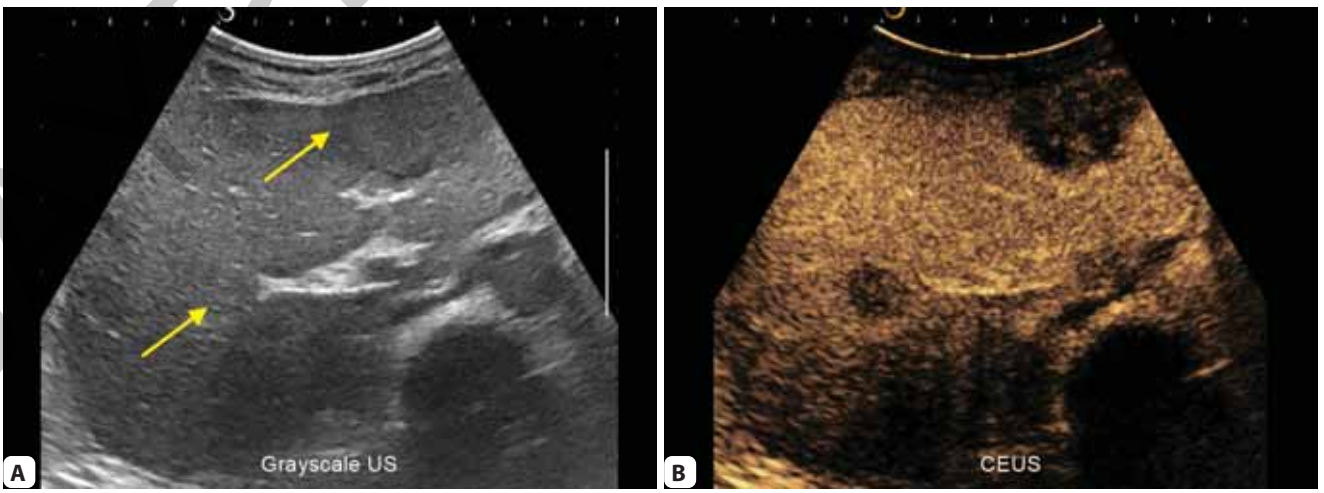

FIGS. 1A AND B: Metastases from colon cancer on contrast-enhanced ultrasound (CEUS): (A) Grayscale ultrasound (US) shows multiple ill-defined lesions which are isoechoic-to-mildly hyperechoic (arrows). The larger lesion shows a hypoechoic halo. (B) CEUS depicts these lesions to be hypoenhancing as compared to surrounding liver parenchyma, helping in differentiation from hemangioma.

JAYPEE BROTHERS

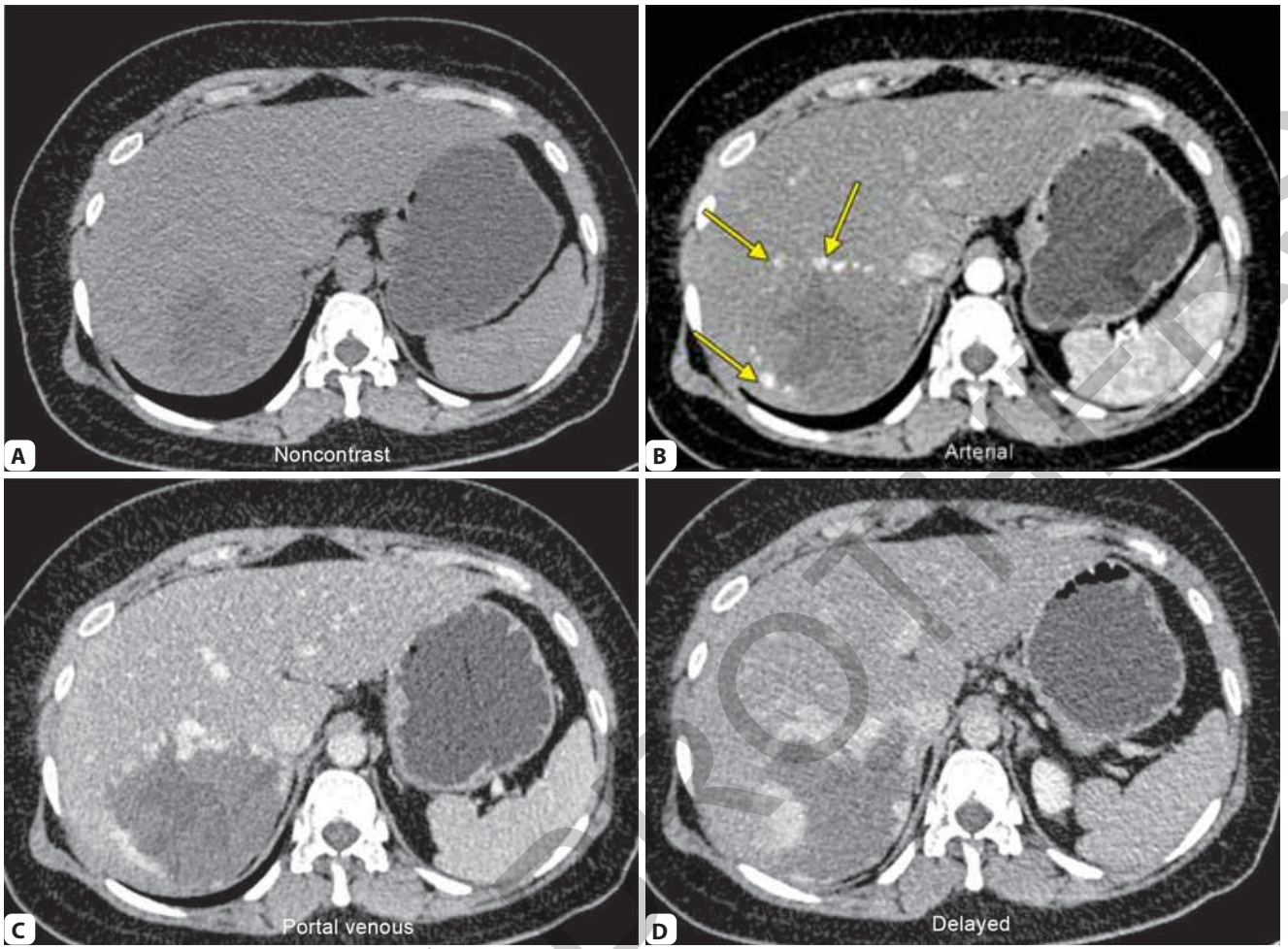

FIGS. 2A TO D: Hemangioma: Axial computed tomography (CT) (A) unenhanced image shows a hypodense lesion in segment VII of the liver. (B) Arterial phase shows peripheral discontinuous nodular enhancement; (C) venous and (D) delayed phase images show progressive centripetal filling in with the enhancement matching that of the blood pool in each phase.

nodules and a diffuse pattern consisting innumerable poorly defined lesions replacing the entire liver.[10] Coexistent hemangioma and focal nodular hyperplasia (FNH) can be seen in 20% of the cases with the association being stronger in patients with multiple FNH.[11] The proposed mechanism is that FNH develops as a hyperplastic response to altered blood supply which occurs in case of hemangiomas. The association also tends to be common in women who are taking oral contraceptive pills (OCPs).

Focal Nodular Hyperplasia

Focal nodular hyperplasia is a benign lesion characterized by hepatocyte hyperplasia without normal development of portal tracts, occurring in the background of a normal liver. It is the second most common incidental liver lesion after hemangioma. The lesion is almost eight times more common in women and commonly occurs between the third and fifth decades.[12] While the exact pathogenesis in not well understood, it is believed to be a hyperplastic response to abnormal blood flow.[13] Most lesions are asymptomatic and they have no malignant potential. There is very low risk of complications such as rupture or hemorrhage.[14] Therefore, asymptomatic FNH does not require any treatment or imaging follow-up in patients without any underlying liver disease or known malignancy.[15] US reveals a solitary well-circumscribed, unencapsulated lobulated lesion, usually isoechoic to the background liver parenchyma. Color and power Doppler may demonstrate a central feeding artery with "spoke wheel pattern" of branching vessels in the radiating septae.[16] CEUS has a good diagnostic accuracy of 87% for FNH and may show a typical centrifugal pattern of enhancement with spoke wheel pattern or an eccentric feeding vessel in the arterial phase.[17] They are often termed "stealth lesions" as they are isodense-to-mildly hypodense on unenhanced CT and isointense on T1 and iso-to-mildly hyperintense on T2-weighted images, thus making detection difficult.[18,19] Owing to the prominent arterial supply, these lesions show marked homogenous enhancement on the arterial phase and become isodense or isointense on the venous phase images with a central scar **(Figs. 5A to F)**. The central scar is composed of fibrous and myxoid tissue and shows T2 hyperintensity and delayed enhancement at 2–5 minutes (detectable in

JAYPEE BROTHERS

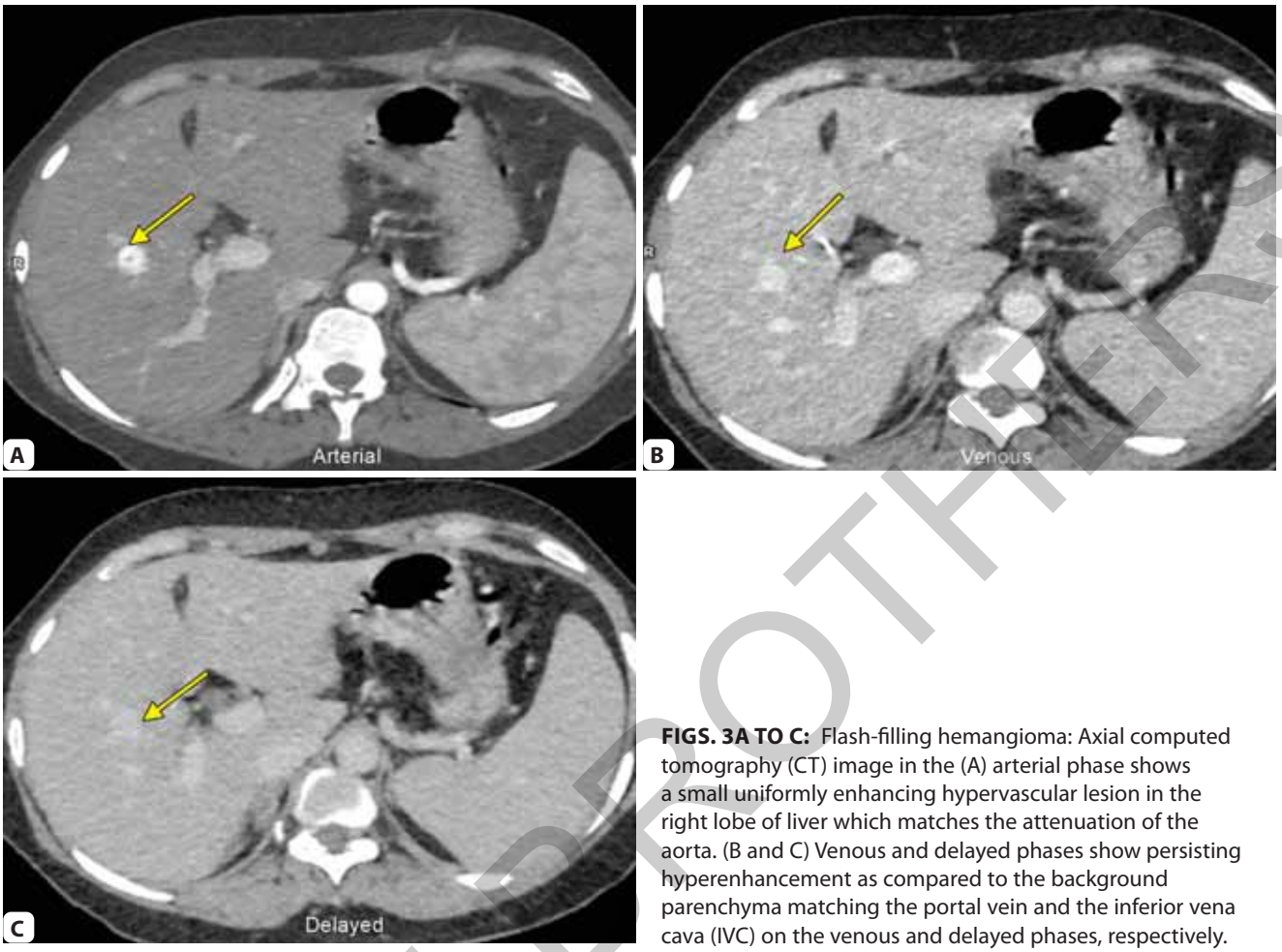

FIGS. 3A TO C: Flash-filling hemangioma: Axial computed tomography (CT) image in the (A) arterial phase shows a small uniformly enhancing hypervascular lesion in the right lobe of liver which matches the attenuation of the aorta. (B and C) Venous and delayed phases show persisting hyperenhancement as compared to the background parenchyma matching the portal vein and the inferior vena cava (IVC) on the venous and delayed phases, respectively.

TABLE 1: Variant/Atypical findings in liver hemangiomas.

Atypical findings in liver hemangiomas	Comments
Echogenic rim on ultrasound	Most common atypical finding
Centrifugal progression of enhancement (inside-out enhancement)	Explained by central vascular spaces and peripheral fibrosis
Sclerosing/Hyalinized hemangioma	• Show central areas of sclerosis • Irregular shaped, associated capsular retraction, wedge-shaped surrounding THED • *Differentials*: Metastasis, cholangiocarcinoma
Giant hemangioma	• Size > 5 cm, may be symptomatic • US—heterogenous, CT—central areas hypodense on CT • Progressive enhancement seen on multiphasic imaging, but complete filling in is not seen due to cystic degeneration/liquefaction, central septae T1/T2 hypointense • *Complications*: Intralesional hemorrhage, intraperitoneal rupture, Kasabach–Merritt syndrome
Calcifications	• Calcified HH show poor enhancement • *Differentials*: Granulomatous infections, parasitic infections, benign and malignant neoplasms (metastasis, adenoma, mucinous cystic neoplasm, fibrolamellar carcinoma, and cholangiocarcinoma)
Fluid–fluid levels	Can mimic complicated cysts, mucinous cystic neoplasm, and necrotic metastasis
Multicystic hemangioma	Often misdiagnosed as mucinous cystic neoplasm
Exophytic pedunculated hemangiomas	• May be misdiagnosed as tumors from other organs • *Complication*: Lesion may twist around the pedicle causing infarction/hemorrhage

Continued

JAYPEE BROTHERS

Continued

Atypical findings in liver hemangiomas	Comments
Hemangiomas with capsular retraction	• Described in sclerosed hemangiomas (70% cases) • *Differentials*: Metastasis, cholangiocarcinoma, epithelioid hemangioendothelioma
Hemangioma with biliary dilatation	Centrally located hemangiomas can have ductal dilatation caused by the mass effect exerted by the lesion
Hemangiomas with arterio-portal/arteriovenous shunts	• Associated with flash-filling hemangiomas • Surrounding areas of THED

(CT: computed tomography; HH: hepatic hemangioma; THED: transient hepatic enhancement difference; US: ultrasound)

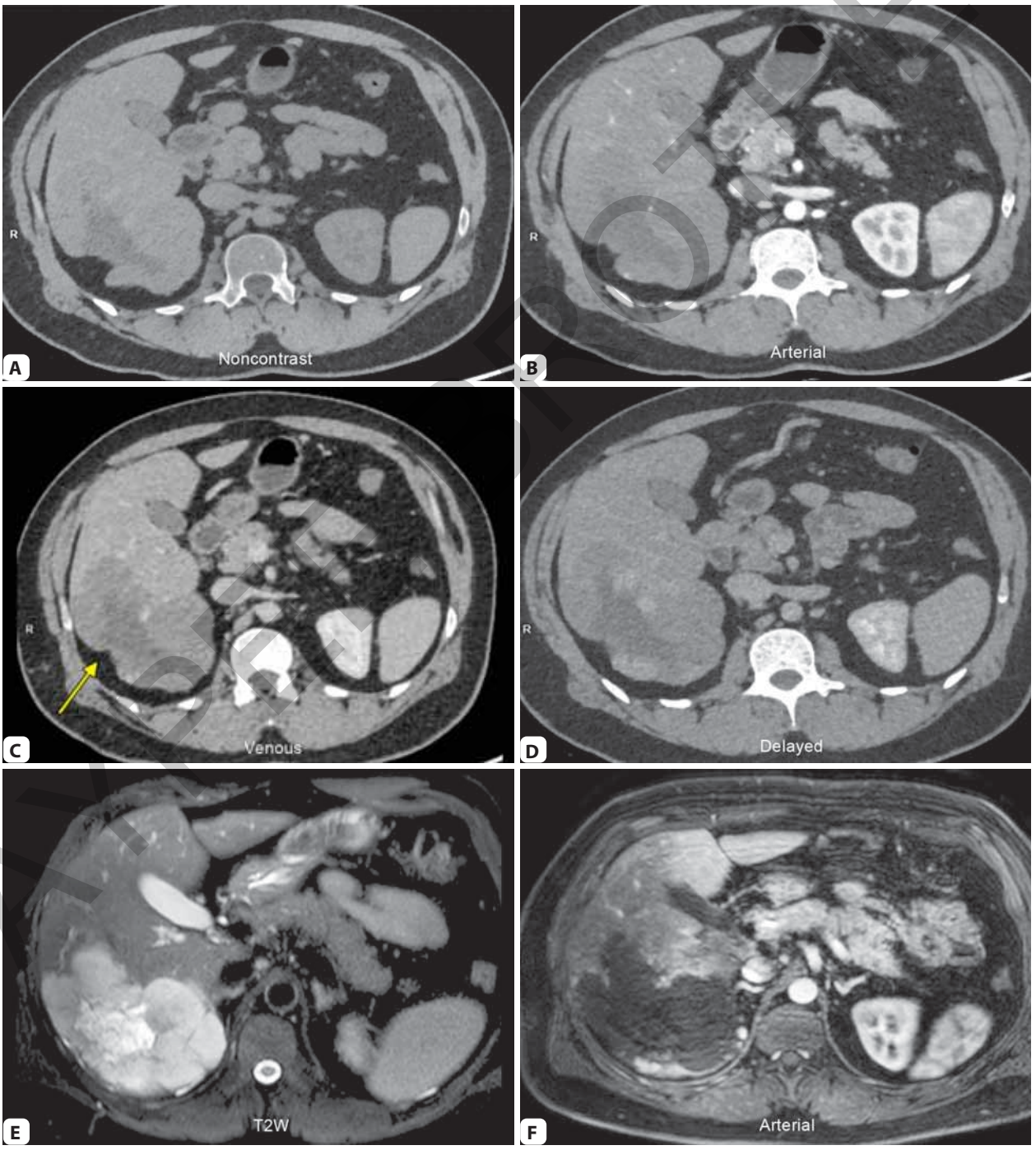

FIGS. 4A TO H: *Continued*

JAYPEE BROTHERS

Continued

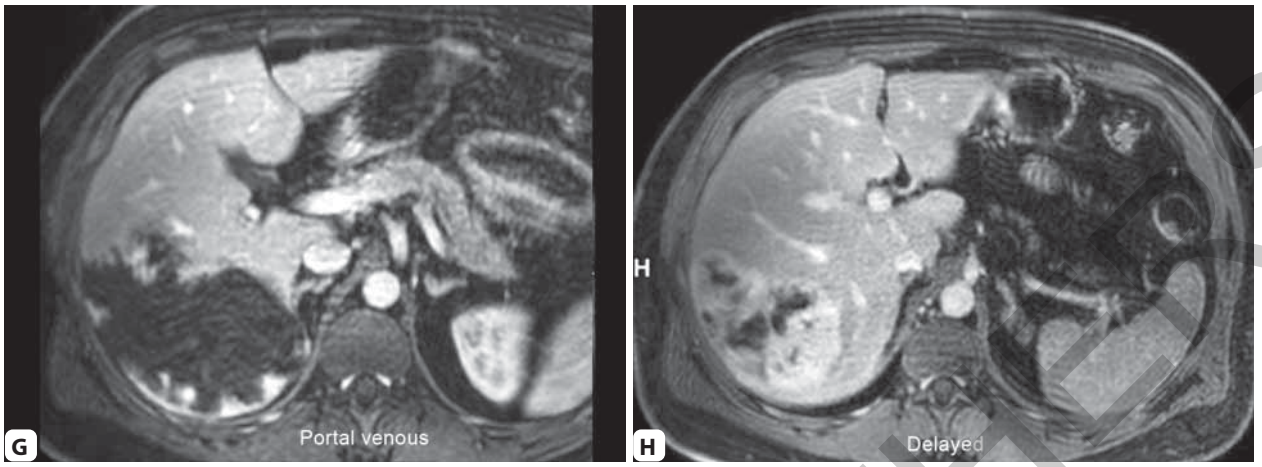

FIGS. 4A TO H: Sclerosing hemangioma: (A) Axial CT images in the (B) arterial phase show a large well-defined lesion with lobulated margins in segments VI and VII of the liver showing peripheral discontinuous nodular enhancement and (C) venous and (D) delayed phases show progressive filling in. There is overlying capsular retraction seen (arrow in C). Axial MR images of the same patient (E) T2W image shows the lesion to be hyperintense with central area of greater hyperintensity. (F) Arterial phase shows peripheral discontinuous nodular enhancement. (G) Venous and (H) Delayed phases show progressive filling in. The contrast enhancement matches that of blood pool in each phase. The lesion shows less enhancement and less hyperintensity of T2W images compared to a typical hemangioma.

(CT: computed tomography; MRI: magnetic resonance imaging; T2W: T2 weighted)

60% of the lesions on CT and 80% of the lesion on MRI).[18] Since a central scar can be seen in fibrolamellar carcinoma (FLC), differentiating the two entities is important **(Table 2)**. The hepatobiliary-specific MR contrast agents such as gadobenate dimeglumine and gadoxetic acid are useful in the diagnosis of FNH. These lesions show retention of contrast and T1 hyperintensity in the hepatobiliary phase due to the presence of functioning hepatocytes with the expression of organic anionic transporter peptide (OATP) receptors and abnormal biliary channels which do not communicate with the normal surrounding biliary system. This helps in the differentiation from hypervascular metastasis, hepatic adenomas (HCAs), and HCC.[20] The caveat here is that some HCAs (inflammatory type and beta-catenin activated) and some well-differentiated HCCs can appear isointense or hyperintense in the delayed phase after hepatobiliary contrast administration.[21]

Focal nodular hyperplasia-like lesions may be seen in patients with underlying vascular disturbances—Budd–Chiari syndrome, cardiogenic congestive hepatopathy, congenital absence of the portal vein, Fontan-associated liver disease, cavernous transformation of portal vein, hereditary hemorrhagic telangiectasia, nodular regenerative hyperplasia, and in patients on certain chemotherapeutic drugs such as oxaliplatin **(Figs. 6A to C)**.[12] These lesions are radiologically, microscopically, and immunohistochemically identical to FNH, except that they occur in a background of an abnormal liver caused by abnormalities in hepatic inflow, outflow, and microvascular disturbances. These may be a source of diagnostic confusion and need to be differentiated from malignancies, since these are benign, silent lesions and are managed conservatively.

Hepatocellular Adenoma

Hepatocellular/liver cell adenoma comprises a group of varied hepatic neoplasms characterized by proliferation of mature hepatocytes occurring in a background of a noncirrhotic liver. This entity is categorized into specific subtypes based on novel molecular signatures and histopathological findings. The updated classification described eight subtypes of HCA: Inflammatory, hepatocyte nuclear factor 1α (HNF-1α) inactivated, β-catenin mutated exon 3, β-catenin mutated exon 7/8, mixed inflammatory and β-catenin mutated exon 3, mixed inflammatory and β-catenin mutated exon7/8, sonic hedgehog (SHH), and unclassified **(Table 3)**.[22,23] The risk factors include obesity, alcohol consumption, anabolic steroid use, OCP, glycogen storage diseases, and McCune–Albright syndrome. The highest incidence is seen in women of reproductive age group. Hepatic adenomatosis requires the presence of more than 10 adenomas **(Figs. 7A to F)**.[24] While most HCAs are asymptomatic and incidentally detected, they are prone to complications such as hemorrhage and malignant transformation which vary depending on the size and the molecular subtype.[25] The risk factors for malignant transformation include male sex, size > 5 cm, β-catenin mutations, and telomerase reverse transcriptase (TERT) promoter mutations.

Hepatocyte Nuclear Factor 1α Inactivated Hepatocellular Adenoma

This group of tumors is usually sporadic and comprises 30–35% of HCAs. Familial hepatic adenomatosis has been related to germline mutations of HNF-1α and maturity-onset

JAYPEE BROTHERS

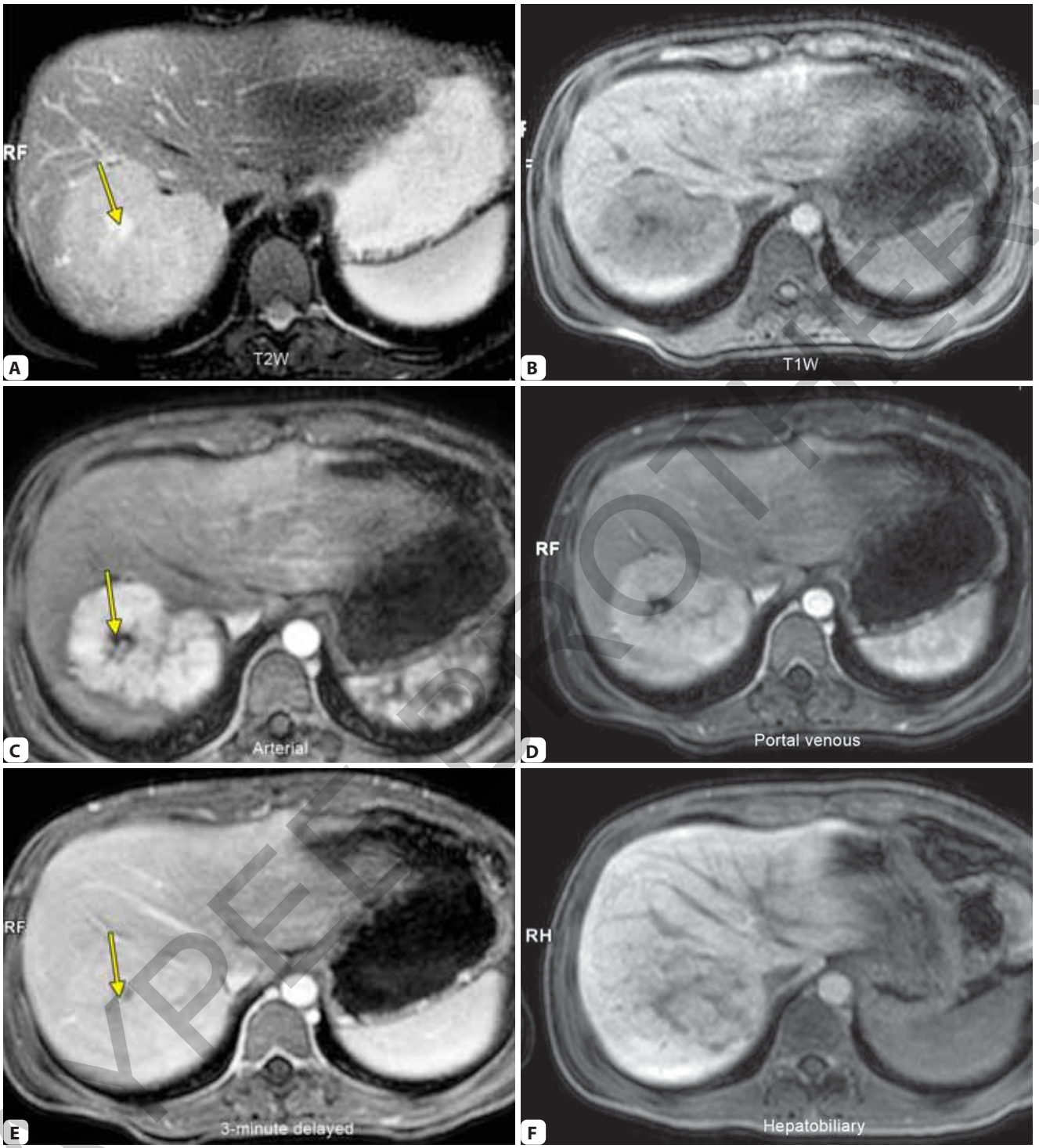

FIGS. 5A TO F: Focal nodular hyperplasia: Axial MRI shows a well-circumscribed lesion in segment VII of the liver appearing (A) T2 mildly hyperintense with central hyperintense scar (arrows in A, C and E) and (B) T1 hypointense. Late arterial phase MRI (C) shows intense nonrim APHE with central nonenhancing scar; (D) portal venous phase showing persistent enhancement of the lesion; (E) 3-minute delayed phase showing persistent enhancement in the lesion with filling into the scar; and (F) hepatobiliary phase showing retention of contrast at 1 hour.

(APHE: arterial phase hyperenhancement; MRI: magnetic resonance imaging; T1W: T1 weighted; T2W: T2 weighted)

JAYPEE BROTHERS

TABLE 2: Comparison of FNH and FLC.

	FNH	FLC
Entity	Benign—hyperplasia of hepatocytes	Malignant
Arterial phase	Hyperenhancing	Hyperenhancing
Venous phase	Isodense to liver	Washout may be seen
T1-weighted MRI	Isointense	Hypointense
T2-weighted MRI	Iso- to mildly hyperintense	Hyperintense
Hepatobiliary phase	Retention of contrast	No retention of contrast
Diffusion restriction	Usually absent	Present
Uptake on Tc-m99 labeled colloid scan	Present	Absent
Central scar	Present	Present
T2 signal of scar	Hyperintense	Hypointense
Scar size	<2 cm	>2 cm
Scar calcification	Absent	Present in 35–70%
Scar enhancement	Delayed enhancement	May be seen

(FLC: fibrolamellar carcinoma; FNH: focal nodular hyperplasia; MRI: magnetic resonance imaging)

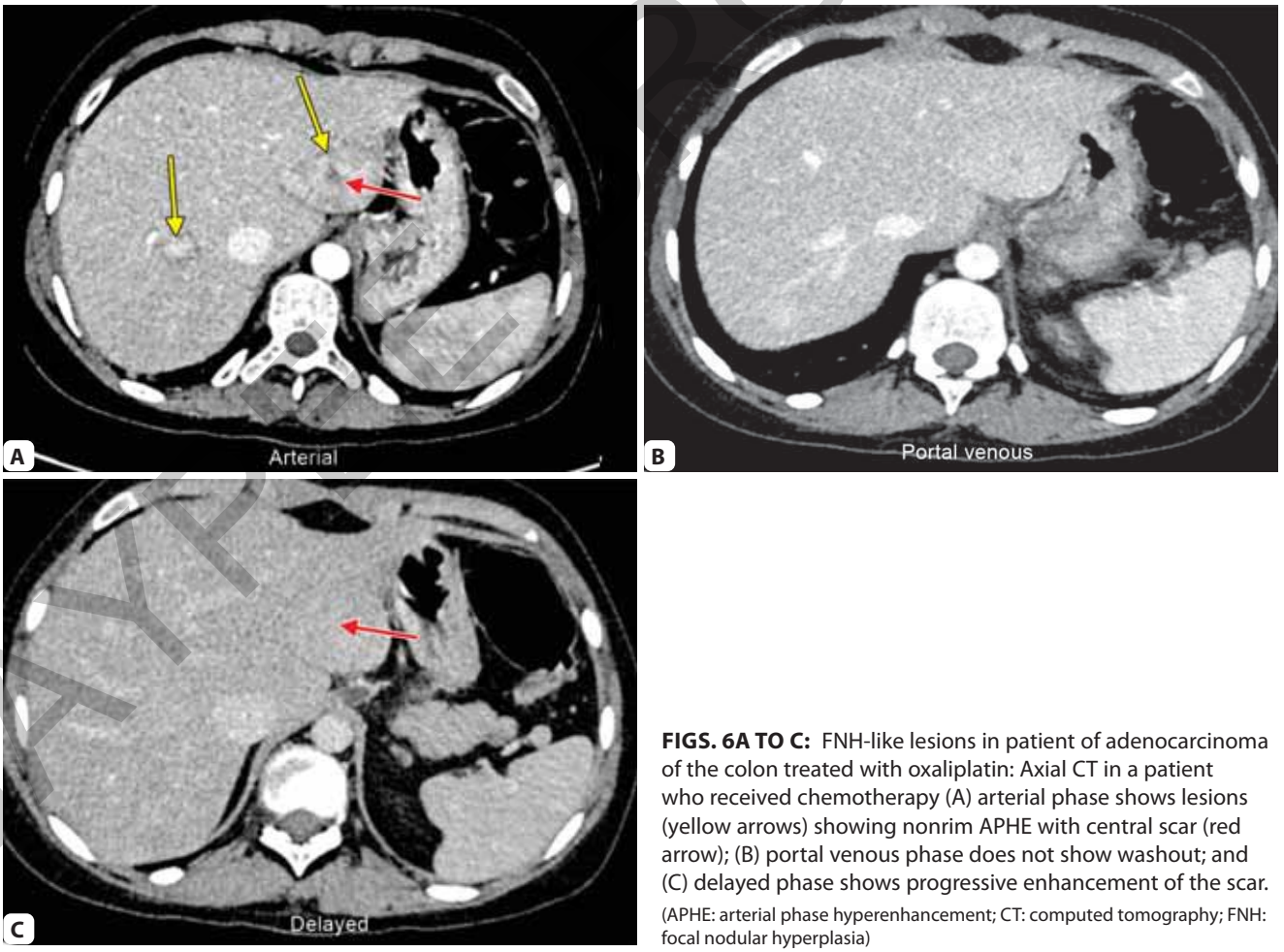

FIGS. 6A TO C: FNH-like lesions in patient of adenocarcinoma of the colon treated with oxaliplatin: Axial CT in a patient who received chemotherapy (A) arterial phase shows lesions (yellow arrows) showing nonrim APHE with central scar (red arrow); (B) portal venous phase does not show washout; and (C) delayed phase shows progressive enhancement of the scar.

(APHE: arterial phase hyperenhancement; CT: computed tomography; FNH: focal nodular hyperplasia)

JAYPEE BROTHERS

TABLE 3: Summary of subtypes of HCA.

Subtype of HCA	Epidemiology and risk factors	Imaging features	Risk of malignancy	Risk of bleeding
Inflammatory	• *Most common* • *Risk factors*: Obesity, OCP, fatty liver, alcohol, and glycogen storage disorder	• Atoll sign • Crescent sign • Can show contrast retention in hepatobiliary phase	Low	High
HNF-1α inactivated	• OCP use • More common in females	• Uniform signal loss on opposed-phase imaging • Hypointense in hepatobiliary phase	Low	Low
β-catenin mutated exon 3	Males, androgen use	• Hyperintense signal on T1 and T2—hemorrhage • May show washout in portal venous, delayed enhancing capsule • Contrast retention in the hepatobiliary phase	Highest	Low
β-catenin mutated exon 7/8	• OCP use • More common in females	No specific imaging features, hypointense on hepatobiliary phase	Low	High
Mixed inflammatory and β-catenin mutated exon 3	• OCP use • More common in females	Features of both β-catenin and inflammatory	High	Low
Mixed inflammatory and β-catenin mutated exon 7/8	• OCP use • More common in females • Obesity alcohol use	Features of both β-catenin and inflammatory	Low	Low
SHH	• OCP use • Obesity	• Hyperintense signal on T1 and T2—hemorrhage • Hypointense on hepatobiliary phase	Low	Highest
Unclassified	OCP use	No specific imaging features	Medium	Medium

(HCA: hepatocellular adenoma; HNF-1α: hepatocyte nuclear factor 1 alpha; OCP: oral contraceptive pill; SHH: sonic hedgehog)

diabetes of the young 3 (MODY-3). The molecular hallmark of these lesions is biallelic inactivation of HNF-1α and loss of liver fatty acid-binding protein (LFABP) expression and macrovesicular fat at immunohistochemistry and histopathology. The nonfunctioning HNF-1α protein results in lipogenesis, causing deposition of intracellular fat which manifests on MRI as loss of signal on the opposed-phase T1-weighted MR images **(Figs. 8A to F)**.[26] They show isointense-to-mildly hyperintense signal on T2-weighted images and nonretention of contrast in the hepatobiliary phase attributed to the decreased OATP1B1/3 expression. Postcontrast studies show arterial phase hyperenhancement (APHE) which persists in the portal venous and the delayed phase images.[27] The incidence of complications such as hemorrhage and malignant transformation is low. US displays these lesions to be hyperechoic, owing to the presence of intracellular fat, thereby closely mimicking hemangiomas. On CEUS, they show peak enhancement in the arterial phase and appear isoechoic to the background liver during portal venous and delayed phases.[28] This subtype is intensely avid on fluorodeoxyglucose positron emission tomography (FDG-PET) with maximal standardized uptake values (SUV_{max}) being as high as 12.5, attributed to the overexpression of glucose transporters.[29]

Inflammatory Hepatocellular Adenoma

This variety of HCA is the most common subtype (5–40%) with the risk factors being high body mass index (BMI), OCP usage, fatty liver, alcohol use, and glycogen storage disorder. These tumors have sustained activation of the interleukin 6/Janus kinase/signal transduced and activation and hence, patients may have inflammatory symptoms such as fever, elevated total leukocyte count, elevated fibrinogen level, and C-reactive protein.[30] On histology, the patchy inflammatory infiltrate stains are positive for serum amyloid A and C-reactive protein. On MRI, the "atoll sign"—hyperintense signal along the periphery of the lesion on T2-weighted image is characteristic of inflammatory HCAs.[31,32] The peripheral rim represents the atoll, the lesion represents the lagoon, and the background liver represents the ocean. This sign has an excellent specificity of 97% for the inflammatory subtype.[33] Another sign described is the "crescent sign"—partial rim which appears hyperintense on T2-weighted image and shows APHE and persistence on the portal venous and delayed phases, which represents focal sinusoidal dilatation.[26,32] These lesions have an increased tendency to undergo hemorrhage. Owing to the expression of OATP receptors, inflammatory HCAs may

JAYPEE BROTHERS

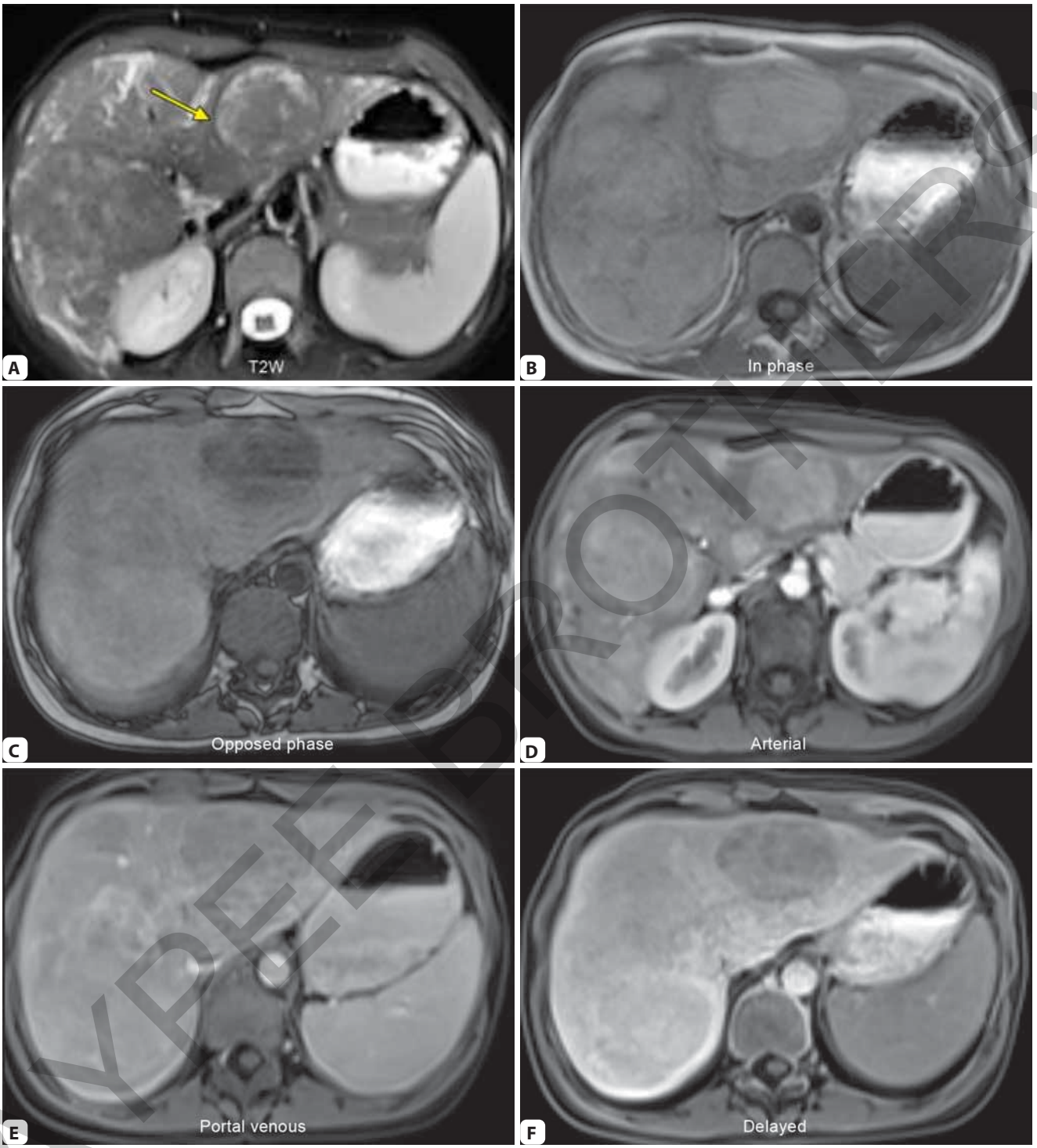

FIGS. 7A TO F: Hepatic adenomatosis: (A) T2-weighted (T2W) image shows a circumscribed mildly hyperintense lesion in the left lobe of the liver (arrow). Multiple similar lesions were seen in both lobes of the liver. (B) In-phase image shows the lesion to be hyperintense with (C) opposed-phase image showing signal drop, suggesting intravoxel fat. (D) Arterial phase demonstrates nonrim arterial phase hyperenhancement (APHE) within the lesion. (E) Portal venous phase shows washout and (F) hepatobiliary phase acquired at 1 hour does not show retention of contrast. These features were suggestive of hepatic adenoma and since the patient had multiple lesions in both lobes (>10), a final diagnosis of adenomatosis was made.

JAYPEE BROTHERS

or detailed information on radiology books, visit our website www.jaypeebrothers.com, for detailed information on radiology books, visit our website www.jaypeebrothers.com, fo



DIAGNOSTIC RADIOLOGY

Gastrointestinal and Hepatobiliary Imaging

In the rapidly evolving world of "Radiology", where advancements are a constant, three renowned institutions—All India Institute of Medical Sciences (AIIMS, New Delhi), Maulana Azad Medical College (MAMC, New Delhi), and Postgraduate Institute of Medical Education and Research (PGIMER, Chandigarh)—embarked on a unique initiative in 1996. To address the need for continuous learning, they jointly launched a series of imaging courses. A crucial element of this endeavor was the publication of comprehensive books covering all organ systems. The primary goal was to equip both postgraduate students and practicing radiologists with a concise yet thorough overview of the field, keeping them abreast of the latest advancements. The coronavirus disease (COVID) pandemic put an unavoidable halt to these courses and we are pleased to reinitiate this venture.

The first series, encompassing seven imaging courses, concluded successfully in 2000. The following series ran from 2002 to 2004, with the third spanning 2008–2013 and the fourth series concluded in 2020. All the continuing medical education (CME) programs garnered wide participation and positive feedback from attendees. The accompanying books also achieved widespread popularity, attracting a large readership.

After a 4-year hiatus, the three institutes have joined forces once again to launch the much-awaited fifth series on imaging. The inaugural book of this series delves into the "Gastrointestinal and Hepatobiliary" systems. This comprehensive volume features numerous chapters, with exciting new additions. Each chapter has been meticulously revised and updated to reflect the latest breakthroughs in the field.

We are confident that readers will find this book immensely beneficial. It is designed to serve a dual purpose: as a comprehensive text for trainees and as a reference for practicing radiologists. We extend our heartfelt gratitude to the contributing authors and our publishing partners for their unwavering support and dedication throughout this project.



Raju Sharma
AIIMS, New Delhi



Gaurav Shanker Pradhan
MAMC, New Delhi



Manavjit Singh Sandhu
PGIMER, Chandigarh

Printed in India

Available at all medical bookstores
or buy online at www.jaypeebrothers.com

JAYPEE BROTHERS
Medical Publishers (P) Ltd.
EMCA House, 23/23-B, Ansari Road,
Daryaganj, New Delhi - 110 002, INDIA
www.jaypeebrothers.com

Join us on facebook.com/JaypeeMedicalPublishers

Shelving Recommendation
RADIOLOGY

ISBN 978-93-5696-917-9

9 789356 969179