iled information on anatomy books, visit our website www.jaypeebrothers.com, for detailed information on anatomy books, visit our website www.jaypeebrothers.com



Manual of Histology

As per the Latest Competency-Based Medical Education Curriculum (NMC)

Mangala Kohli
Reeha Mahajan

Foreword
Krishna Garg

2nd Edition

diginerve®
A Jaypee Initiative
Download the App
Video Lectures | Notes | Question Bank | Dr. Wise AI Chatbot

JAYPEE

Contents

1. Introduction to Histology 1
2. Epithelium 7
3. Glandular Tissue 20
4. Connective Tissue 31
5. Cartilage 52
6. Bone 58
7. Muscular Tissue 64
8. Lymphatic System 72
9. Cardiovascular System 81
10. Integumentary System 93
11. Respiratory System 99
12. Alimentary System 107
13. Urinary System 131
14. Male Reproductive System 141
15. Female Reproductive System 150
16. Endocrine System 163
17. Nervous System 174
18. Special Senses 192

References *199*

Chapter 9

Cardiovascular System

JAYPEE BROTHERS

COMPETENCY

- **AN69.1:** Identify elastic and muscular blood vessels, capillaries under the microscope
- **AN69.2:** Describe the various types and structure-function correlation of blood vessel

LEARNING OBJECTIVES

At the end of this chapter, the students will be able to:

- Identify the structure of various types of the blood vessels in the slides under the microscope.
- Correlate the structure of the various types of blood vessels with their function.
- Identify the sites of presence of the various types of blood vessels based on their structure and function.

INTRODUCTION

In this system there is a central pumping organ called 'Heart' and tubular channels called 'Vessels'. The distributing vessels which carry blood from the heart to different parts of the body are called 'arteries' and the draining vessels which carry blood towards the heart from the different parts of body are called 'veins'. The microscopic vessels connecting the smallest arteries (arterioles) and the smallest veins (venules) are called 'capillaries'.

Histologically there are three main types of blood vessels:

1. **Arteries**
   i. Large or elastic artery
   ii. Medium sized or muscular artery
   iii. Smallest artery or arteriole
2. **Capillaries**
3. **Veins**
   i. Smallest vein or venule
   ii. Medium sized vein
   iii. Large vein.

STRUCTURE

All blood vessels have the same basic structure. Each vessel has three coats or tunics from within outwards:

i. **Tunica intima:** Consists of lining endothelium (simple squamous epithelium) and subendothelial connective tissue

ii. **Tunica media:** Consists of smooth muscle fibers and connective tissue
iii. **Tunica adventitia:** Consists of fibroelastic connective tissue.

Large/Elastic/Conducting Artery

It is thick-walled and thickness of its wall is about one-tenth of the luminal diameter.

- **Tunica intima** presents endothelium and subendothelial connective tissue. Subendothelium contains fibrocytes, macrophages and smooth muscle-like cells called myointimal cells. The fibers (collagen and elastic) are longitudinally oriented. Tunica intima is demarcated from tunica media by a poorly defined fenestrated internal elastic lamina.
- **Tunica media** presents about 40–70 layers of fenestrated elastic laminae arranged circularly, hence the name elastic artery. Between elastic laminae, it contains smooth muscle cells and collagen fibers. The outermost elastic lamina is thickened and called external elastic lamina.
- **Tunica adventitia** presents fibroelastic connective tissue containing small blood vessels (vasa vasorum) and unmyelinated nerve fibers.

For example: (1) Aorta and its branches and (2) Pulmonary trunk and its branches.

Towards old age, gradual changes take place like thickening of tunica intima and formation of fibro-fatty plaques in it, accumulation of lipid in the myointimal cells and macrophages and calcification of tunica media. These changes are described as atheroma or atherosclerosis resulting into gradual narrowing of the lumen. It involves coronary and cerebral arteries too leading into infarction and stroke respectively.

Medium-sized/Muscular/Distributing Artery

Its wall thickness is about one-fourth of the luminal diameter.

- **Tunica intima** presents endothelium and internal elastic lamina, no subendothelium. Internal elastic lamina shows wavy folds due to contraction of smooth muscle in the tunica media.
- **Tunica media** presents mainly the smooth muscle cells arranged circularly (about 40 layers) hence the name muscular artery. It also contains collagen and elastic fibers intermixed with smooth muscle cells.
- **Tunica adventitia** presents three parts: (i) Inner part shows more elastic fibers than collagen fibers and it includes external elastic lamina, (ii) Middle part has collagen and elastic fibers running longitudinally and (iii) Outer part has loose connective tissue that merges with the surrounding areolar tissue and contains vasa vasorum and unmyelinated nerve fibers.

For example: Branches of external carotid artery, radial and ulnar arteries etc.

Arteriole

The small vessel having diameter less than 0.5 mm. Wall thickness is equal or more than the luminal diameter.

- **Tunica intima** presents only endothelial lining, no subendothelium or internal elastic lamina.
- **Tunica media** presents 1–5 layers of circularly arranged smooth muscle cells.
- **Tunica adventitia** is thin and contains sympathetic nerve fibers that control the size of lumen by contracting the smooth muscle cells.

The terminal branches of arterioles are called metarterioles. They have smaller lumen and only few smooth muscle cells.

Capillaries

Arterioles break up into small vessels called capillaries. They are referred to as exchange vessels because they are involved in exchange of gases, nutrients and metabolites between blood and tissue. The lumen is about 7–9 μm.

Tunica intima presents only 2–3 endothelial cells lining the lumen on cross section. Pericytes or adventitial cells are occasionally seen in the basement membrane of the endothelium and form the **Tunica media**. These cells contain contractile filaments in the cytoplasm. **Tunica adventitia** presents a thin layer of collagen fibers.

Capillaries are of three types depending on the nature of endothelium:

i. **Continuous/Somatic capillary:** It is commonest type present in connective tissue, muscle, brain, lung, etc. The endothelial cells form a continuous lining of the capillary

JAYPEE BROTHERS

ii. **Fenestrated/Visceral capillary:** It presents tiny pores in the endothelial cells which take part in rapid exchange of substances between tissues and blood, e.g., Kidney, intestinal villi, endocrine glands, etc.
iii. **Sinusoidal capillary:** It is present in liver and haemopoietic organs like red bone marrow and spleen. It is tortuous having irregular lumen (30–40 μm) which is lined by discontinuous endothelium. There are gaps between the endothelial cells that permit passage of blood cells. Phagocytic cells may be seen in the wall, e.g., Kupffer's cells in liver.

Venules

They receive blood from capillaries and have larger lumen (0.5–1 mm) than arterioles. They have a thin wall and a large collapsed lumen.

- **Tunica intima** presents endothelium.
- **Tunica media** presents one or two layers of smooth muscle cells.
- **Tunica adventitia** presents a thick layer of connective tissue rich in collagen fibers.

Medium-sized Veins

They have thin wall and collapsed lumen.

- **Tunica intima** presents endothelium and a thin layer of subendothelium.
- **Tunica media** presents few circularly arranged smooth muscle cells in the connective tissue rich in collagen fibers. Elastic fibers are few.
- **Tunica adventitia** presents a loose fibroelastic connective tissue containing vasa vasorum and nerve fibers.

Large Veins

- **Tunica intima** well developed having endothelium and subendothelial connective tissue.
- **Tunica media** is thin having smooth muscle fibers arranged transversely and longitudinally.
- **Tunica adventitia** is well developed and thickest coat. It presents many longitudinal bundles of smooth muscle cells embedded in connective tissue.
- Medium and large sized veins are often provided with valves to prevent the reflux of blood.

For example: Superior and inferior vena cava.

JAYPEE BROTHERS

Elastic Artery

Thick-walled. Thickness of wall is very less than diameter of lumen. Endothelium and subendothelial tissue.
Poorly defined fenestrated internal elastic lamina.
Tunica media presents many circular layers of fenestrated elastic laminae or plates. Between laminae lie smooth muscle cells and collagen fibers.
Outer most elastic lamina forms external elastic lamina.
Tunica adventitia shows fibroelastic tissue having vasa vasorum and unmyelinated nerve fibers.

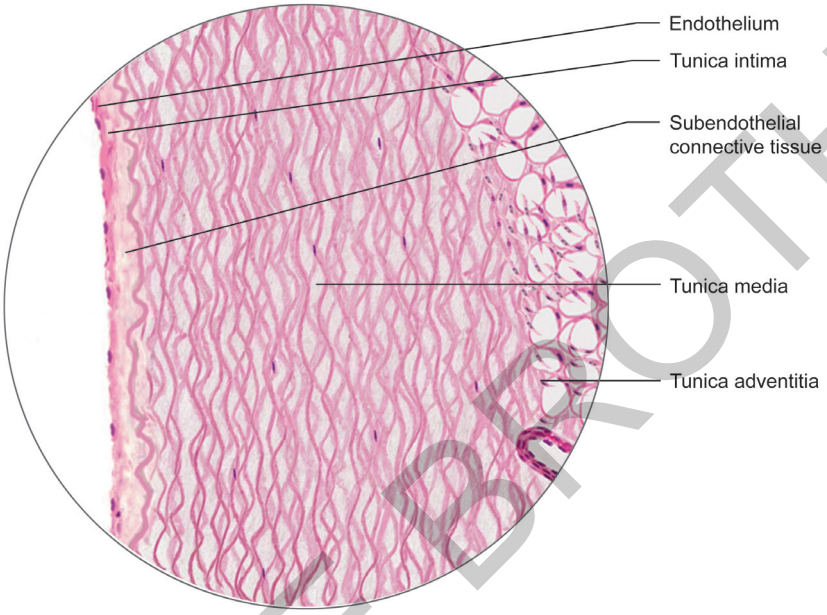

Fig. 1: Elastic artery (To be drawn by students).

JAYPEE BROTHERS

Muscular Artery

Thickness of wall is less than diameter of lumen.
Tunica intima presents endothelium and a prominent internal elastic lamina and no subendothelium.
Tunica media presents many circular layers of smooth muscle cells between smooth muscle cells lie elastic and collagen fibers. External elastic lamina is present.
Tunica adventitia presents fibroelastic tissue having vasa vasorum and unmyelinated nerve fibers.

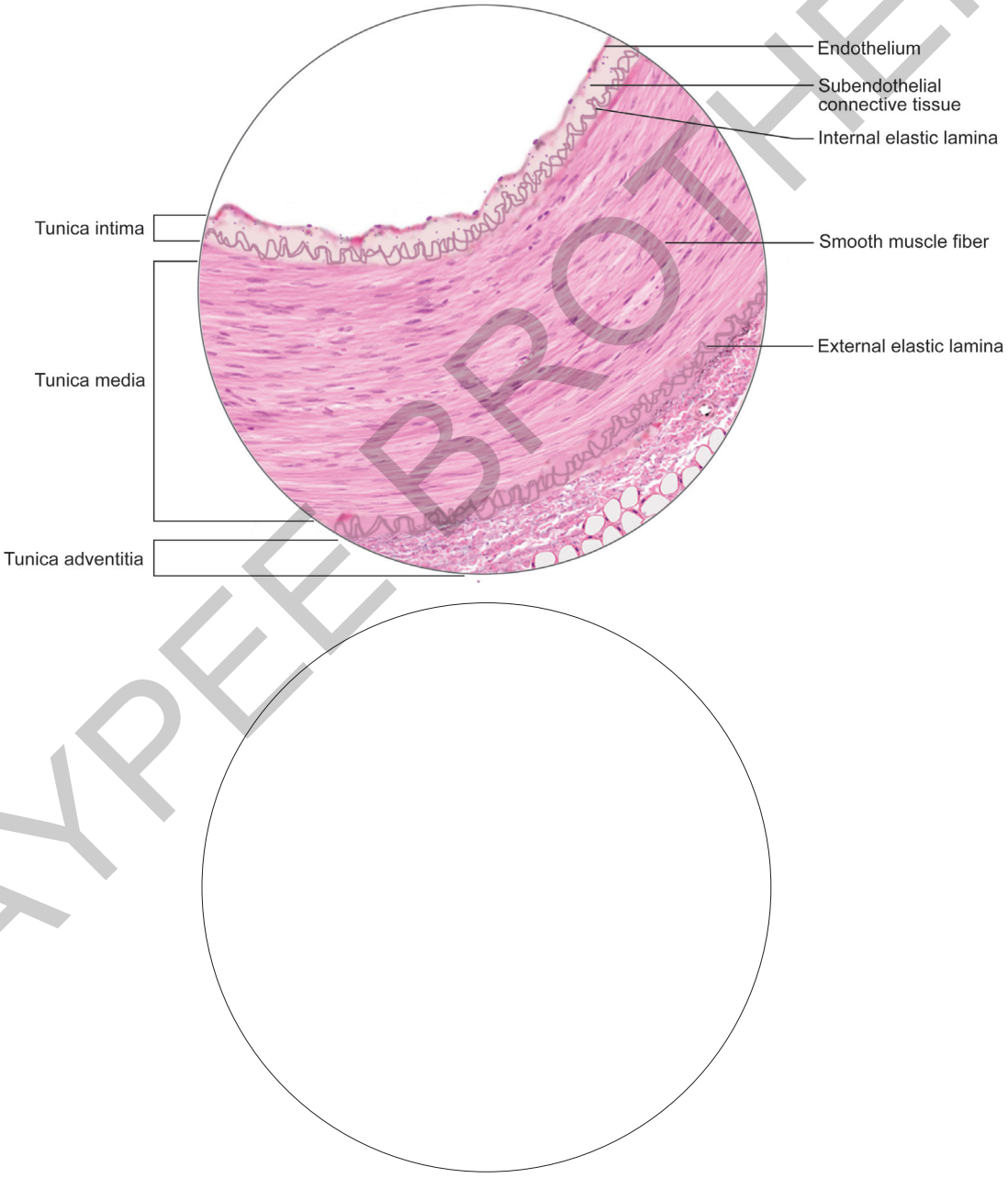

Fig. 2: Muscular artery (To be drawn by students).

JAYPEE BROTHERS

Arteriole

The thickness of wall is equal or more than the luminal diameter.
Tunica intima presents only endothelial lining, no subendothelium or internal elastic lamina.
Tunica media presents 1–5 layers of circularly arranged smooth muscle cells.
Tunica adventitia is thin and contains sympathetic nerve fibers.

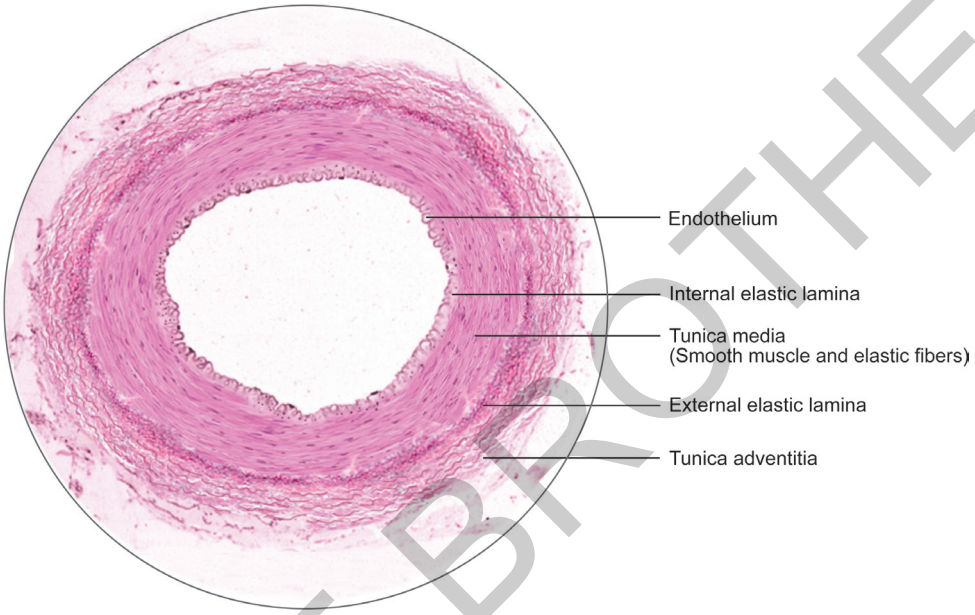

Fig. 3: Arteriole (To be drawn by students).

JAYPEE BROTHERS

Capillaries

Lumen is very small.
Tunica intima presents only 2–3 endothelial cells lining the lumen in cross section.
Pericytes or adventitial cells are occasionally seen in the basement membrane of the endothelium and form the tunica media.
Tunica adventitia presents a thin layer of collagen fibers.

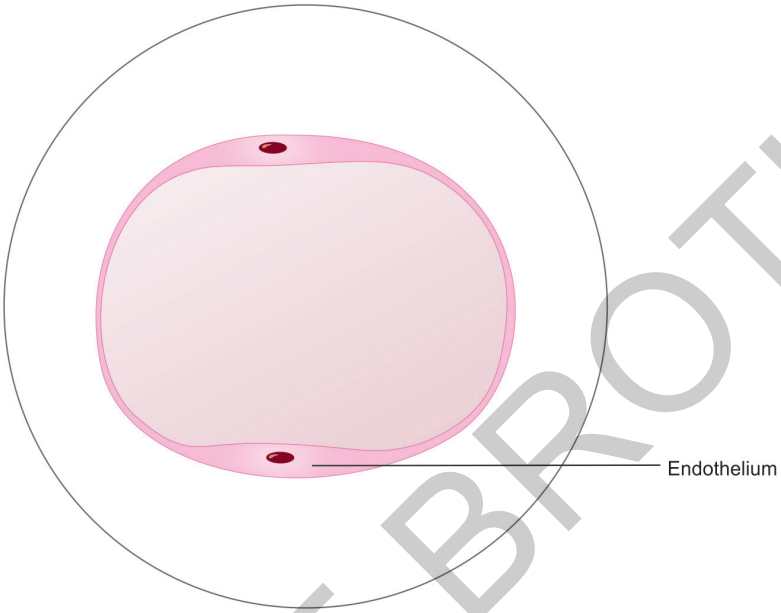

Fig. 4A: Continuous capillary (To be drawn by students).

JAYPEE BROTHERS

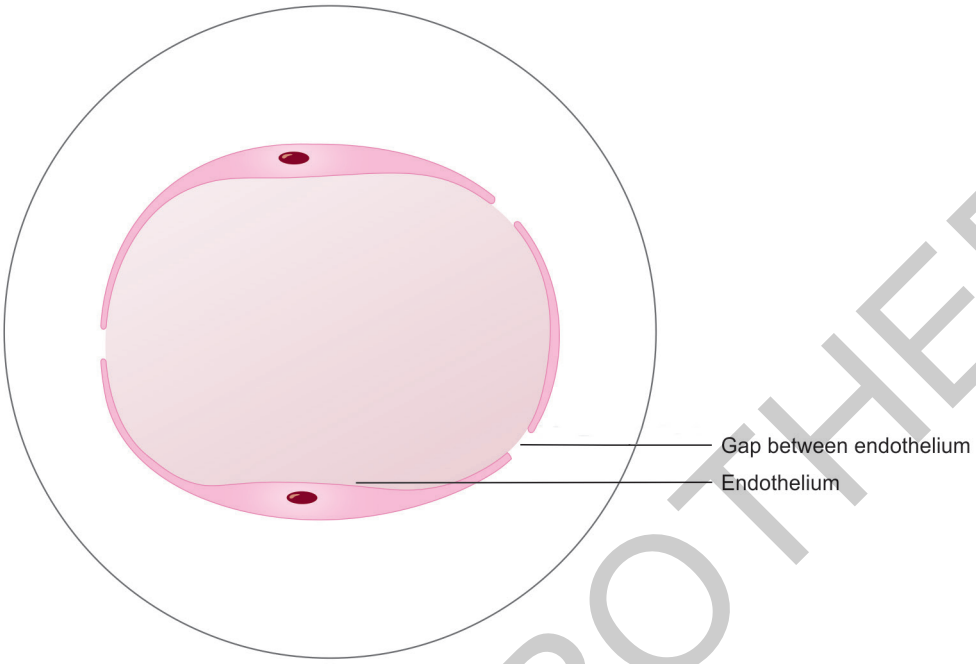



Fig. 4B: Fenestrated capillary (To be drawn by students).

JAYPEE BROTHERS

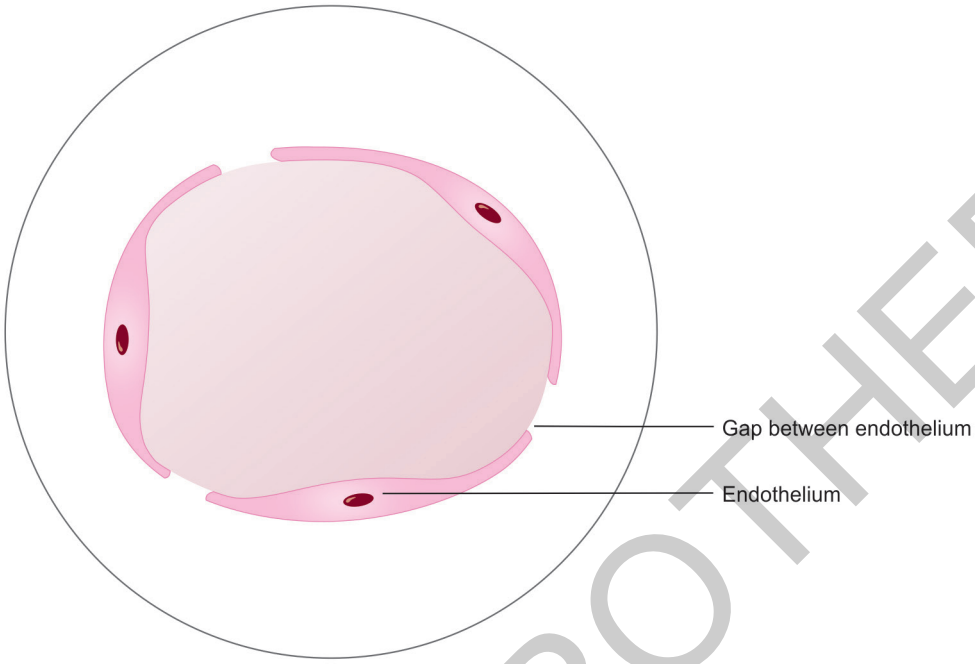



Fig. 4C: Sinusoidal capillary (To be drawn by students).

JAYPEE BROTHERS

Venule

Thin wall and a large collapsed lumen.
Tunica intima presents endothelium.
Tunica media presents 2–3 layers of smooth muscle cells.
Tunica adventitia presents a thick layer of connective tissue rich in collagen fibers.

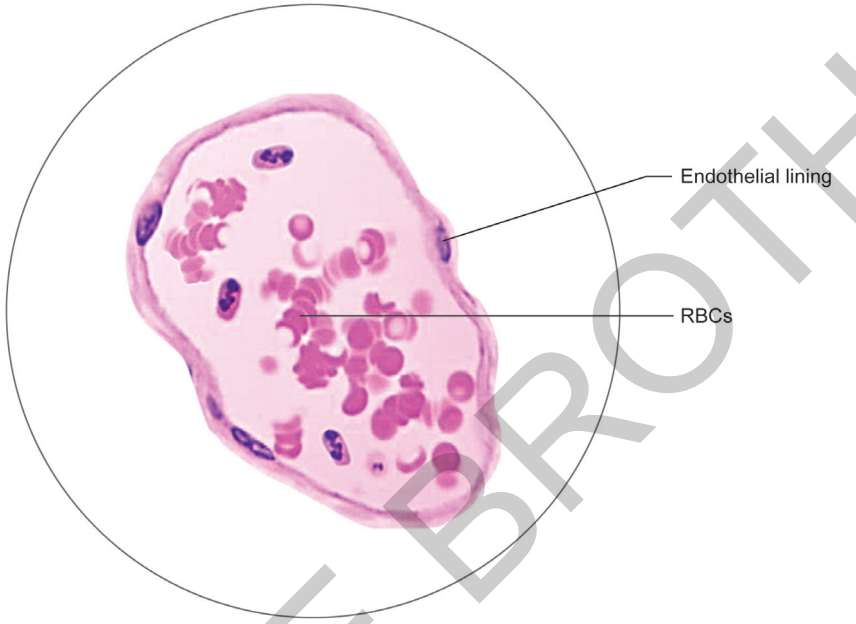

Fig. 5: Venule (To be drawn by students).

JAYPEE BROTHERS

Large Vein

They have thin wall and collapsed lumen.
Tunica intima presents endothelium and a thin layer of subendothelium.
Tunica media presents few circularly arranged smooth muscle cells with collagen and elastic fibers in between.
Tunica adventitia presents fibroelastic tissue with vasa vasorum and nerve fibers.
Tunica adventitia is well-developed thickest coat and presents many longitudinal bundles of smooth muscle cells in connective tissue.

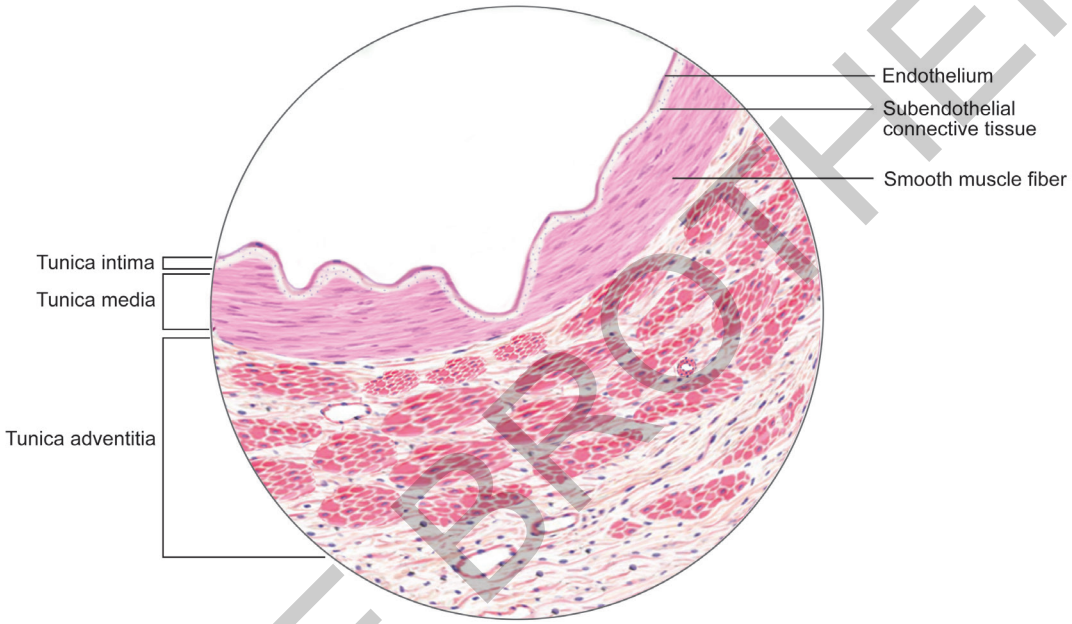

Fig. 6: Large vein (To be drawn by students).

JAYPEE BROTHERS

Clinical Correlation/Vertical Integration

- The endothelium also has an antithrombogenic action, preventing blood coagulation. When endothelial cells are damaged by atherosclerotic lesions, for example, the uncovered subendothelial connective tissue induces the aggregation of blood platelets. This aggregation initiates a cascade of events that produces fibrin from blood fibrinogen. An intravascular coagulum, or **thrombus** (plural, thrombi), is formed that may grow until there is complete obstruction of the local blood flow. From this thrombus, solid masses called **emboli** (singular, embolus) may detach and be carried by the blood to obstruct distant blood vessels. In both cases, the vascular flow may stop, a potentially life-threatening condition. Thus, the integrity of the endothelial layer, which prevents contact between platelets and the subendothelial connective tissue, is an important antithrombogenic mechanism.
- In aging, the extracellular matrix is disordered by an increased secretion of collagen types I and III and of some glycosaminoglycans. Changes in the molecular conformation of elastin and other glycoproteins also occur and may facilitate deposition of **lipoproteins** and calcium ions in the tissue with subsequent calcification. Modifications of the components of the extracellular matrix associated with other more complex factors may lead to the formation of an **atherosclerotic plaque.**
- Arteries undergo progressive and gradual changes from birth to death, and it is difficult to say where the normal growth processes end and the processes of involution begin. Each artery exhibits its own aging pattern.
- Atherosclerotic lesions are characterized by focal thickening of the intima, proliferation of smooth muscle cells and increased deposition of extracellular connective tissue elements, and lipoproteins in the subendothelial layer. Monocytes are attracted to these areas where they differentiate into macrophages characterized by the extensive uptake of atherogenic lipoproteins by receptor-mediated endocytosis. When heavily loaded with lipid, these cells are referred to as **foam cells** and form the macroscopically visible fatty streaks and plaques that characterize **atherosclerosis.** These changes may extend to the inner part of the tunica media, and the thickening may become so great as to occlude the vessel. Coronary arteries are among those most predisposed to atherosclerosis. Uniform thickening of the intima is believed to be a normal phenomenon of aging.
- Some arteries irrigate only specific areas of certain organs, and obstruction of the blood supply results in **necrosis** (death of tissues from a lack of metabolites). These **infarcts** commonly occur in the heart, kidneys, cerebrum, and certain other organs. In other regions (such as the skin), arteries anastomose frequently, and the obstruction of one artery does not lead to tissue necrosis, because the blood flow is maintained.
- When the media of an artery is weakened by an embryonic defect, disease, or lesion, the wall of the artery may dilate extensively. Progression of this process of dilatation leads to the development of an **aneurysm.** Rupture of the aneurysm brings severe consequences and may cause death.
- Junctions between endothelial cells of venules are the loosest. At these locations there is a characteristic loss of fluid from the circulatory system during the inflammatory response, leading to edema.

JAYPEE BROTHERS

detailed information on anatomy books, visit our website www.jaypeebrothers.com, for detailed information on anatomy books, visit our website www.jaypeebrothers

Manual of Histology

Manual of Histology is one of its kind and would be very useful for first-year MBBS, BDS, BPT, BOT, and BSc Nursing students for practicing their microanatomical diagrams which are the keystones for histology learning.

Salient Features

- This book emphasizes on the practical knowledge of microanatomy of various tissues and organs of the human body, which is in accordance with the Competency-Based Medical Education (CBME) curriculum
- It provides informative tools for memorizing and application of learnt facts in an interesting manner.
- The main highlights of the book are the colored illustrative diagrams provided as reference to guide the students for drawing the diagrams correctly.
- The key points are also mentioned against each diagram to help the students in drawing the correct diagram in the space provided, which will also form the foundation for pathology learning.
- This book will also help students in quick revision of microanatomical facts before examination.



Mangala Kohli MBBS MS MIMSA FIMSA is Dean, International Studies and Affairs, FH Medical College, Agra, Uttar Pradesh, India. She is former Director Professor and Head, Department of Anatomy, Vardhman Mahavir Medical College and Safdarjung Hospital, New Delhi, India. She has 43 years of experience in undergraduate and postgraduate medical teaching. She has rendered her services as Assistant Director General in Medical Education, Physical Medicine and Rehabilitation, Paramedical Sciences and Nursing Education in Directorate General of Health Services, Ministry of Health and Family Welfare, Government of India. She is a graduate and postgraduate from Lady Hardinge Medical College, University of Delhi. She is the sole visionary and founder of NEET in the country for undergraduate, postgraduate, and superspeciality courses. She has received various prestigious awards for academics and social service including Fellowship Award from International Medical Sciences Academy and Henry Gray "Anatomist of the Year Award" for excellent contribution in the field of Anatomy. She has received the "Award of Excellence" from International Multidisciplinary Research Foundation and National Healthcare Excellence Award in the international youth conference 2019 and many best paper awards at national and international levels. She has organized the 67th National Conference of Anatomical Society of India "NATCON67" as organizing chairperson. She has been the organizer for 42 national and international symposia and various cadaveric workshops. She has created a platform "Dialogue with Organs" for adolescent and Allied Health Force for skill development. She is a member of various reputed organizations and scientific bodies and an editorial board member for various medical journals. She has provided community health services as a medical practitioner for 13 years. She has been instrumental in tissue, organ, and body donation awareness activities conducted in collaboration with National Organ and Tissue Transplant Organisation (NOTTO) and is a pioneer in cadaveric skin retrieval and transplantation in North India.



Reeha Mahajan MBBS MD is Associate Professor, Department of Anatomy, All India Institute of Medical Sciences, Vijaypur, Jammu, India. She has extensive teaching experience at various reputed institutes of the country, namely Lady Hardinge Medical College, New Delhi, and BJ Medical College, Pune. She has also served as Assistant Professor at Amity Institute of Physiotherapy and visiting faculty at Banarsidas Chandiwala Institute of Physiotherapy and ISIC Institute of Rehabilitation Sciences, New Delhi. She is a graduate and postgraduate from Government Medical College, Jammu. She has published two books in the field of Anatomy and 17 publications in indexed and peer-reviewed national as well as international journals. She is the Research and Development Head of Noble Citizen Foundation. She has organized the 67th National Conference of Anatomical Society of India "NATCON67" as organizing secretary. She is also the organizer for the pre-conference CME of NATCON67 on Organ and Body donation. She is a life member of the Epidemiological Foundation of India. She is a member of the editorial board of International Journal of Clinical and Experimental Medicine Research and a reviewer of Journal of Clinical and Diagnostic Research, Journal of Pharmaceutical Research International, and National Journal of Clinical Anatomy. She is a member of the National Advisory Board for the Inderbir Singh's Textbook of Human Histology (10th Edition) and Inderbir Singh's Textbook of Human Embryology (13th Edition) and a reviewer of Grant's Dissector (South-East Asia edition).

Printed in India

Available at all medical bookstores or buy online at www.ejaypee.com

JAYPEE BROTHERS
Medical Publishers (P) Ltd.
EMCA House, 23/23-B, Ansari Road,
Daryaganj, New Delhi - 110 002, INDIA
www.jaypeebrothers.com

Join us on facebook.com/JaypeeMedicalPublishers
Follow us on instagram.com/JaypeeMedicalPublishers

Shelving Recommendation
ANATOMY

ISBN 978-93-5696-918-6