others.com, for detailed information on anesthesia books, visit our website www.jaypeebrothers.com, for detailed information on anesthesia books

Interventional Pain Management

A Practical Approach









Editors
Dwarkadas K Baheti
Sanjay Bakshi
Sanjeeva Gupta
Raghbir Singh P Gehdoo

Complimentary Online
16 Videos Duration
(48 minutes approx.)

Foreword
Subhash Jain

3rd Edition

JAYPEE

Contents

SECTION 1: Basics of Interventional Pain Management

1. **Understanding Magnetic Resonance Imaging for Spinal and Pelvic Pain 3**
   Neemish N Kamat
2. **Radiological Anatomy of Spine 13**
   Amit Bharath, Harun Gupta
3. **Understanding of Radiological–Spinal Imaging for Pain Physicians 22**
   Sarath Bethapudi, Harun Gupta
4. **Role of Electrodiagnosis in the Management of Pain 31**
   Khushnuma Mansukhani
5. **Pharmacotherapy of Drugs Used in Interventional Pain Treatment Procedures 38**
   Raghbir Singh P Gehdoo
6. **Radiofrequency Lesioning in Pain Management: Principles and Clinical Applications 44**
   Kailash Kothari
7. **Metaphors and Analogies for Patients and Healthcare Professionals 51**
   Sanjeeva Gupta, Risha Gupta, Manohar L Sharma, Prit Anand Singh, Dwarkadas K Baheti

SECTION 2: Documentation and Protocols

8. **Informed Consent Form for Pain Block (Interventional Pain Treatment Procedures) 65**
   Dwarkadas K Baheti
9. **Role of Investigations in Pain Block 68**
   Dwarkadas K Baheti
10. **Protocol for Pain Block: A Suggested Format 74**
    Dwarkadas K Baheti
11. **Evaluation of the Chronic Pain Patient 76**
    Evan C Grant, Julia M Webb, Pratik J Gandhi, Jacob R Peacock, Alex Moroz
12. **Stimulation-guided Pain Mapping 82**
    Sanjeeva Gupta

SECTION 3: Head and Neck

13. **Trigeminal Nerve Block 87**
    Ramkumar Kalaiyarasan, Manohar L Sharma
14. **Maxillary Nerve Block 98**
    Kristina Natan

JAYPEE BROTHERS

15 **Mandibular Nerve Block** 112
Yashwant L Nankar

16. **Sphenopalatine Ganglion Block** 116
Yashwant L Nankar

17. **Glossopharyngeal Nerve Block** 121
George C Chang Chien, Jianguo Cheng

18. **Stellate Ganglion Block** 127
Preeti P Doshi

19. **Occipital Nerve Stimulation** 137
Vijay B Bandikatla, Chaitanya Veera, Nikhitha Peechera

SECTION 4: Chest and Thorax

20. **Suprascapular Nerve Block** 149
Vijay B Bandikatla, Chaitanya Veera, Nikhitha Peechera

21. **Intercostal Nerve Block** 158
Gerard DeGregoris III

22. **Intrapleural Block** 163
Dwarkadas K Baheti

23. **T2/T3 Sympathetic Block** 167
Prakash Deshmukh

SECTION 5: Abdomen and Pelvis

24. **Celiac Plexus Block** 177
Dwarkadas K Baheti

25. **Splanchnic Nerve Block** 185
Dhruv Bibra, GP Dureja

26. **Lumbar Sympathetic Block** 198
Neel Mehta, Rajiv Shah, Sadiah Siddiqui

27. **Superior Hypogastric Plexus Block** 201
Dwarkadas K Baheti

28. **Ganglion Impar Block** 204
George C Chang Chien, Harpreet Singh, Bruce M Vrooman

SECTION 6: Spine and Back

29. **Cervical Epidural Block: Interlaminar Approach** 211
Rishi Khanna, James Taylor

30. **Cervical Transforaminal Epidural Block** 218
Shoji Ishigami, Steve M Aydin

JAYPEE BROTHERS

31. **Cervical Medial Branch Block** 224
Sanjeeva Gupta, Sanjay Varma, Risha Gupta

32. **Cervical Medial Branch Blocks and Radiofrequency Neurotomy** 234
Shruti G Kapoor, Samir N Shah

33. **Thoracic Paravertebral Block** 238
Lisa V Doan

34. **Lumbar and Caudal Epidural Blocks** 244
Sanjay Bakshi, Gerard W Abrahamsen

35. **Lumbar Facet Joint, Medial Branch, and Radiofrequency Procedures** 255
Annu H Navani, Irina Melnik, Richard Derby, Jeong-Eun Lee

36. **Lumbar Plexus Block** 269
Mohammed Piracha, Kingsuk Ganguly, Neel Mehta

37. **Sacroiliac Joint Radiofrequency Denervation** 274
Sanjeeva Gupta

38. **Sciatic Nerve Block (Subgluteal)** 279
Yashwant L Nankar

39. **Coccygeal Nerve Block** 284
Yashwant L Nankar

40. **Obturator Nerve Block** 289
Beatriz Nistal-Nuño, Arthur Atchabahian

41. **Piriformis Muscle Injection** 297
Yashwant L Nankar

42. **Popliteal Nerve Block of Sciatic Nerve** 301
Yashwant L Nankar

43. **Ilioinguinal Nerve Block** 305
Beamy S Sharma, Arthur Atchabahian

44. **Genicular Nerve Block and Motor-Sparing Neural Ablation Techniques for Persistent Knee Pain** 312
Annie Wong, Prit Anand Singh

SECTION 7: Advanced Pain Management

45. **Percutaneous Adhesiolysis in Chronic Low Back Pain** 321
Laxmaiah Manchikanti, Mahendra Sanapati, Gabor B Racz

46. **Epiduroscopy for Patients with Lumbosacral Radicular Pain** 342
Jan Willem Kallewaard, Sanjeeva Gupta, Jonathan Richardson

47. **Spinal Cord Stimulation** 349
Sanjay Bakshi, Gerard W Abrahamsen

48. **Diskography** 359
Eric Lee, Corey Hunter, Sudhir Diwan

JAYPEE BROTHERS

49. Intradiskal Electrothermal Therapy 367
Anil K Sharma

50. Vertebroplasty and Kyphoplasty 374
Kevin H Trinh, Steve M Aydin

51. Nucleoplasty 379
Kyriacos Kyriakides

52. Ozone Nucleolysis 384
Gautam Das

53. Percutaneous Transforaminal Endoscopic Lumbar Diskectomy 394
Girish Datar

54. Intrathecal Implantable Devices 406
Samyadev Datta

55. Percutaneous Cervical Cordotomy for Cancer Pain 416
Ramkumar Kalaiyarasan, Manohar L Sharma

56. Subarachnoid or Intrathecal Neurolysis 429
Kritika M Doshi

57. Radiofrequency Ablation of Spinal Metastasis 434
Samyadev Datta

58. Cryoablation in Pain Management 442
Amod Manocha, Shefali Panjwani, Puneet Sharma

SECTION 8: Ultrasound-guided Procedures

59. Which One is Better: Ultrasonography or Fluoroscopy? 455
Omobonike O Olowosuko, Steve M Aydin

60. Introduction to Ultrasound in Interventional Pain Medicine 459
Ritesh Roy, Gaurav Agarwal

61. Ultrasound-guided Greater Occipital and Third Occipital Nerve Block 462
Surbhi Bhagat, Kritika M Doshi

62. Ultrasound-guided Cervical Medial Branch Block 467
Surbhi Bhagat, Kritika M Doshi

63. Ultrasound-guided Shoulder Injections 472
Thomas P Lione, Steve M Aydin

64. Ultrasound-guided Lumbar Medial Branch Block 477
Kritika M Doshi, Surbhi Bhagat

65. Ultrasound-guided Sacroiliac Joint Injection 483
Kritika M Doshi, Surbhi Bhagat

66. Ultrasound-guided Hip Injections 487
Madouna G Hanna, Edward Papa, Steve M Aydin

JAYPEE BROTHERS

67. Ultrasound-guided Knee Injections 492
Edward Papa, Steve M Aydin

SECTION 9: Alternate Therapies

68. Dry Needling and Ultrasound-guided Dry Needling 499
Sushama R Phanse, Madhavi Joshi

69. Myofascial Pain Syndrome and Trigger Point Injections 511
Vince Z Si, Mona Mirchandani, Kevin K Bernard, Emilia Ravski, Dellene E Troy, Christopher V Boudakian, Nayeema Chowdhury, Jason D Freeman

SECTION 10: Miscellaneous

70. Understanding Implications and Handling of Medicolegal Aspects for Pain Physicians 529
Manjiri N Ranade

Index 545

JAYPEE BROTHERS

Video Contents

Chapter 13: Trigeminal Nerve Block

Ramkumar Kalaiyarasan, Manohar L Sharma

Video 1: Trigeminal Ganglion Block RF

Chapter 15: Mandibular Nerve Block

Yashwant L Nankar

Video 2: Mandibular Nerve Block

Part 1

Part 2

Chapter 18: Stellate Ganglion Block

Preeti P Doshi

Video 3: Stellate Ganglion

Chapter 22: Intrapleural Block

Dwarkadas K Baheti

Video 4: Intra pleural Block

Chapter 23: T2/T3 Sympathetic Block

Prakash Deshmukh

Video 5: T2-3 Sympathetic Block

Chapter 24: Celiac Plexus Block

Dwarkadas K Baheti

Video 6: CT Guided Neurolytic Coeliac Plexus Block

Chapter 34: Lumbar and Caudal Epidural Blocks

Sanjay Bakshi, Gerard W Abrahamsen

Video 7: Trans Foraminal Lumbar Epidural

JAYPEE BROTHERS

Video 8: Lumbar Epidural-inter Laminar



Video 9: Caudal Epidural



Chapter 35: Lumbar Facet Joint, Medial Branch, and Radiofrequency Procedures

Annu H Navani, Irina Melnik, Richard Derby, Jeong-Eun Lee

Video 10: Median Branch Block (Lumbar)



Chapter 39: Coccygeal Nerve Block

Yashwant L Nankar

Video 11: Coccygeal Nerve Block



Chapter 41: Piriformis Muscle Injection

Yashwant L Nankar

Video 12: Piriformis Muscle Injection



Chapter 42: Popliteal Nerve Block of Sciatic Nerve

Yashwant L Nankar

Video 13: Popliteal Nerve Block of Sciatic Nerve



Chapter 56: Subarachnoid or Intrathecal Neurolysis

Kritika M Doshi

Video 14: Intra Thecal Neurolysis



Chapter 68: Dry Needling and Ultrasound-guided Dry Needling

Sushama R Phanse, Madhavi Joshi

Video 15: US Guided Dry Needling Twitch



Chapter 69: Myofascial Pain Syndrome and Trigger Point Injections

Vince Z Si, Mona Mirchandani, Kevin K Bernard, Emilia Ravski, Dellene E Troy, Christopher V Boudakian, Nayeema Chowdhury, Jason D Freeman

Video 16: Trigger point injection



JAYPEE BROTHERS

CHAPTER 2

Radiological Anatomy of Spine

Amit Bharath, Harun Gupta

ABSTRACT

Magnetic resonance imaging (MRI) is the diagnostic tool of choice for spinal imaging, and computed tomography (CT) is increasingly being used for spinal intervention. Selective nerve blocks require an excellent understanding of spinal anatomy to ensure that the correct nerve root is targeted. This chapter reviews the salient anatomical features of different imaging modalities used to image the spine.

INTRODUCTION

There have been tremendous advancements in the quality and diagnostic yield of spinal imaging. In the past, X-rays and myelography were commonplace but now MRI is the diagnostic tool of choice, and CT is increasingly being used for spinal intervention. Spinal intervention requires an excellent understanding of spinal anatomy to ensure a safe approach and correct anatomical area to be targeted. Plain radiography, fluoroscopy, and CT are all forms of ionizing radiation; these imaging modalities provide excellent visualization of osseous structures, but they should be used with some caution as they can increase the long-term risk of cancer. MRI uses magnetic field and no nonionizing radiation and is superior to CT for assessing spinal soft-tissue and marrow abnormalities. An in-depth analysis of the flaws and benefits and the technical aspects of the different imaging modalities has not been done and is well covered in the radiology literature. The chapter covers the merits of particular modalities to illustrate the relevant spinal anatomy.

The vertebral column (or spine) forms the central axis of the skeleton. It has a great structural strength as well as considerable flexibility. These two properties of the spine arise from the number, morphology and articulations of its constituent bony elements, the vertebrae. The spine is normally made up of 33 vertebrae, divided into 5 distinct anatomical groups such as cervical, thoracic, lumbar, sacral, and coccygeal. In the adult spine, there are four curvatures in the anteroposterior plane. There is anterior flexion or concavity in the thoracic and sacrococcygeal parts of the spine, which is known as kyphosis, and anterior extension or convexity in the cervical and lumbar regions, which is known as lordosis. There are eight pairs of cervical nerve root; all cervical nerves except C8 emerge above their corresponding vertebrae, while the C8 nerve emerges below the C7 vertebra. Elsewhere in the spine, the nerve emerges below the vertebra with the same name (i.e., the L4 nerve root will exit at the level of L4/5 disk).[1-3]

Vertebrae are typically composed of a ventral body and a dorsal vertebral or neural arch. These two structures enclose the vertebral foramen; the foramen of vertebrae form the vertebral canal **(Figs. 1A to C)**. The contents of the vertebral canal include the dorsal root ganglia, epidural fat, spinal nerves, and blood vessels. Three osseous processes emerge from the vertebral arch—a posterior midline process known as the spinous process and two lateral processes known as the transverse processes. The part of the neural arch between the spinous process and the transverse processes is known as the lamina and the part between the transverse process and the vertebral body is called the pedicle. The root of the transverse process is formed at the junction of the pedicle and the lamina; it is here where the articular facets of the neural arch lie.

JAYPEE BROTHERS

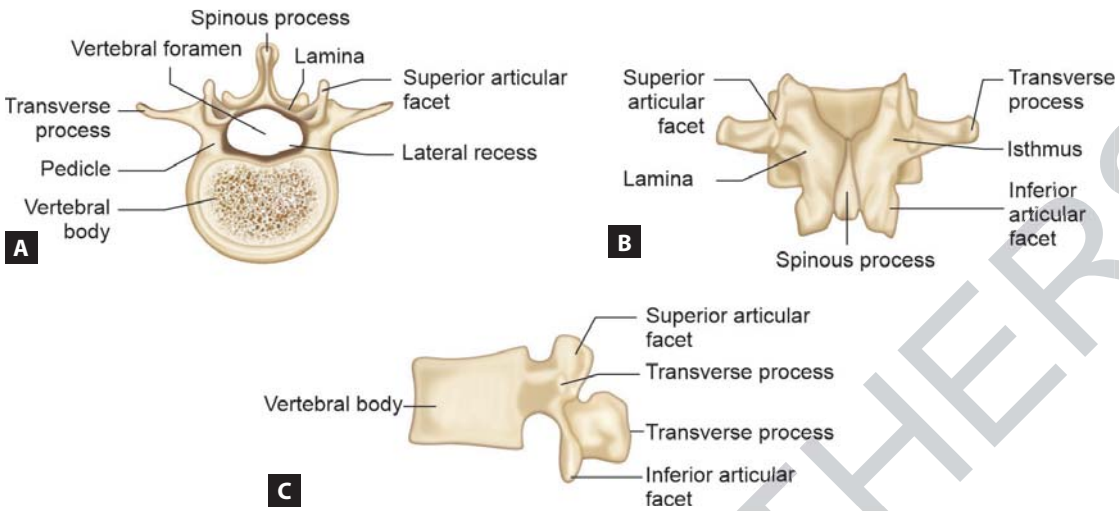

Figs. 1A to C: Line diagrams of typical lumbar vertebra with (A) superior, (B) posterior, and (C) lateral views.

There are two superior and two inferior articular facets in each neural arch, one pair of superior and inferior facets on either side.

FACET JOINTS

The joints between the superior articular facet of one vertebra and the inferior articular facet of the vertebra above are known as the zygapophyseal joints or more simply the facet joints. The facet joints are true synovial joints. The articular surfaces are covered by hyaline cartilage, which allows a sliding motion to occur in the posterior arch of the spinal column. The articular capsules are thin and have an inner synovial and an outer fibrous membrane. The anterior aspect of the facet joints and the lamina are covered by strong bands of fibrous tissue, called the ligamenta flava. They are attached above to the front of the upper lamina and below to the back of the lower lamina. They extend from the facet joints to the midline where they partially fuse. Cartilage loss from degenerative disease within the facet joint, in conjunction with disk height loss from degeneration, leads to inward buckling of the ligamentum flavum, which may cause central canal, lateral recess or exit foraminal stenosis.

The intervertebral foramen is the space formed between pedicles of two adjacent vertebrae; this is where the spinal nerve exits the vertebral canal. The facet joints themselves have a nerve supply from the nerve of their own segmental level and from the nerve of the segment above. One nerve thus supplies two joints, and this may be important when considering nerve root pain, which can be referred from facet joints.

INTERVERTEBRAL DISKS

The main structural articulation through which most of the weight is transferred between the spine occurs via the vertebral bodies and the intervening disks. The intervertebral disk is a secondary cartilaginous joint or symphysis. The vertebral bodies and disk are bounded anteriorly by the anterior longitudinal ligament, which extends from the basiocciput of the skull to the upper part of the sacrum. The anterior longitudinal ligament has strong attachments to the periosteum of the anterior aspects of the vertebral bodies but is less strongly attached to the disks. The posterior longitudinal ligament extends from the posterior aspect of the body of the axis to the anterior wall of the upper sacral canal. Intervertebral disks consist of a central gelatinous substance, composed of water and proteoglycans, called the nucleus pulposus.

This is surrounded by a ring called the annulus fibrosus, which has a narrow outer collagenous zone, and a wider inner fibrocartilaginous zone. The nucleus pulposus accounts for 15% of the whole disk. At birth, it is 90% water and this decreases to 70% in old age. Although CT scans delineate intervertebral disks and disk disease, MRI is far superior. It can be used to assess the disk structure and accurately evaluate spinal stenosis. MRI physics is a complicated and vast topic in itself; there are many different sequences which can now be used

JAYPEE BROTHERS

to assess the different spinal conditions. Essentially, there are two main sequences: T1 and T2, which can be distinguished by the color of the cerebrospinal fluid (CSF). CSF is low signal (dark) on T1 and high signal (bright) on T2. Fat, protein, and blood are bright on T1 and fluid is bright on T2. On MRI, a normal disk has a lower signal (darker) than normal adjacent bone marrow on T1-weighted (T1W) images. On T2-weighted (T2W) images, the nucleus pulposus is bright as it is filled with fluid and proteoglycans, and the outer fibrocartilaginous annulus fibrosis is dark. With age and degeneration, the disk loses its fluid and proteoglycans; in doing so, it becomes darker on T2W imaging whilst also losing its height and disrupting its internal architecture.

CERVICAL VERTEBRAE

The cervical spine consists of seven vertebrae **(Figs. 2 to 8)**. It is the most flexible part of the spine and the most complex. The cervical spine's range of motion is approximately 80–90° of flexion, 70° of extension, 20–45° of lateral flexion, and up to 90° of rotation to both sides. The cervical vertebrae have a lateral process, which is perforated by a foramen. The vertebral artery, accompanying sympathetic fibers, and the vertebral venous plexus lie in the foramen. The spinous processes are usually bifid with the exception of the C7 vertebrae. The vertebrae of C3-C7 have a similar morphology. A typical cervical vertebral body is kidney-shaped. On each side, it is projected up into a posterolateral lip (the uncus), and its lower margin is beveled reciprocally with this. The C3-C7 vertebral bodies articulate with one another at this point. This articulation is known as the uncovertebral joint or joint of Luschka.

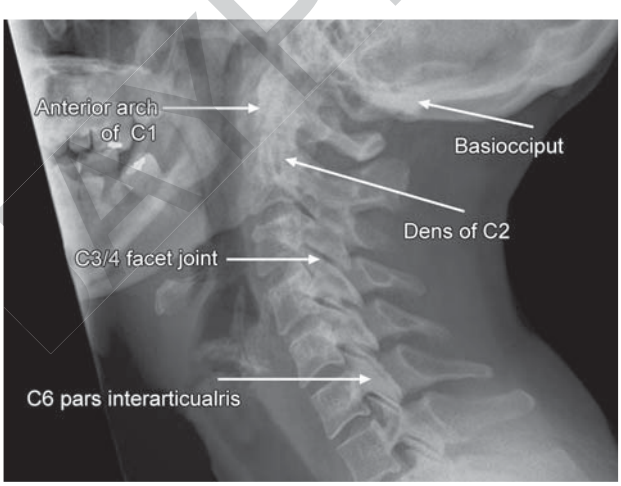

Fig. 2: Plain radiograph of cervical spine (lateral view).

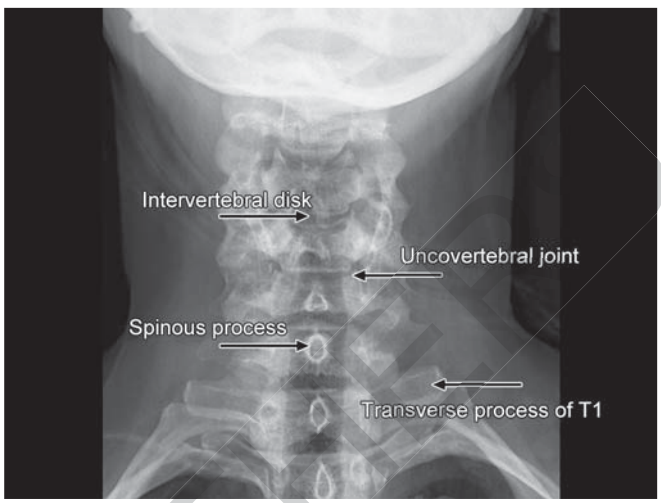

Fig. 3: Plain radiograph of cervical spine (anteroposterior view).

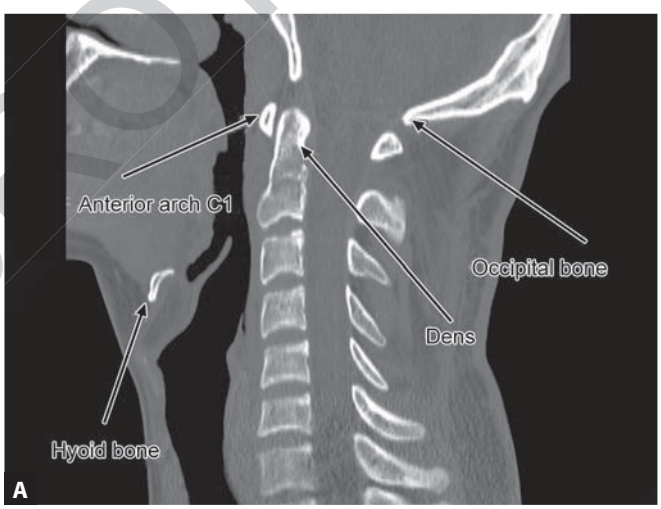

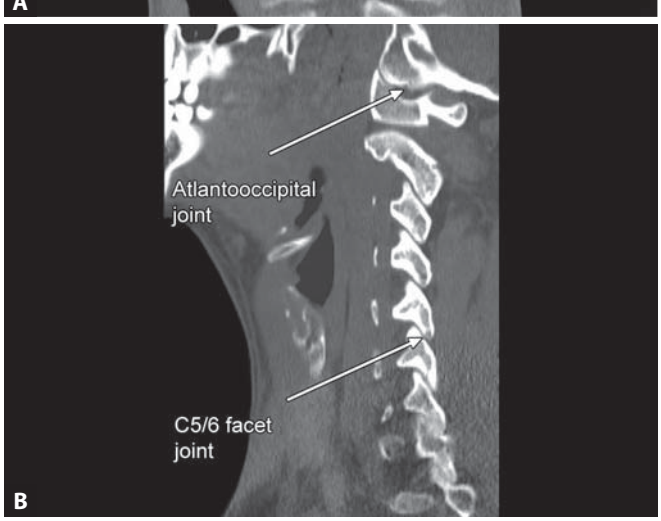

Figs. 4A and B: CT scan of cervical spine (sagittal reformat image).

PEER REVIEW

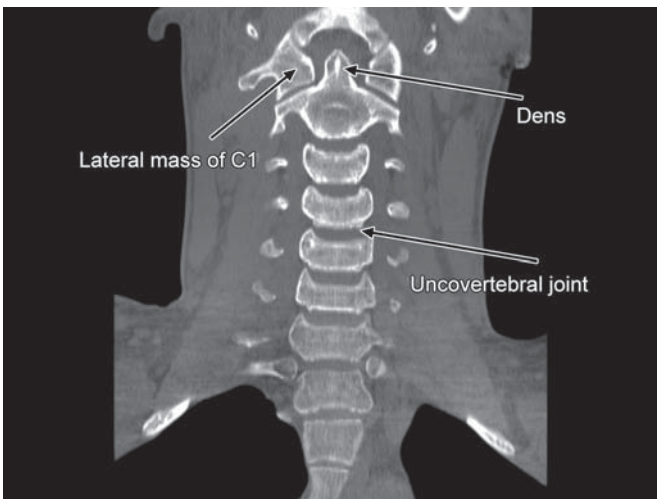

Fig. 5: CT scan of cervical spine (coronal reformat image).

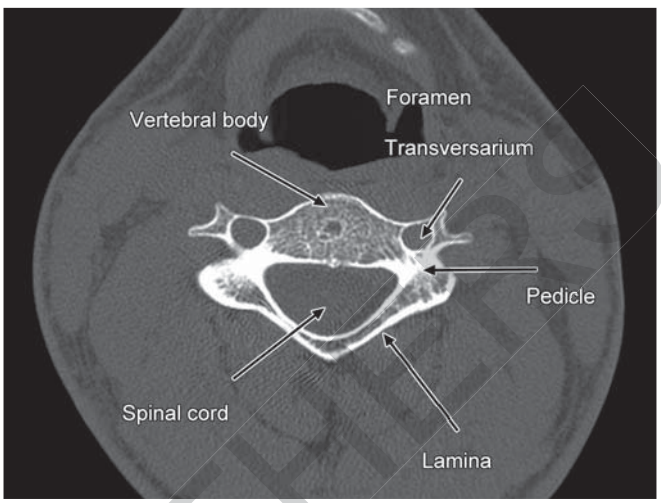

Fig. 6: CT scan of cervical spine (axial image).

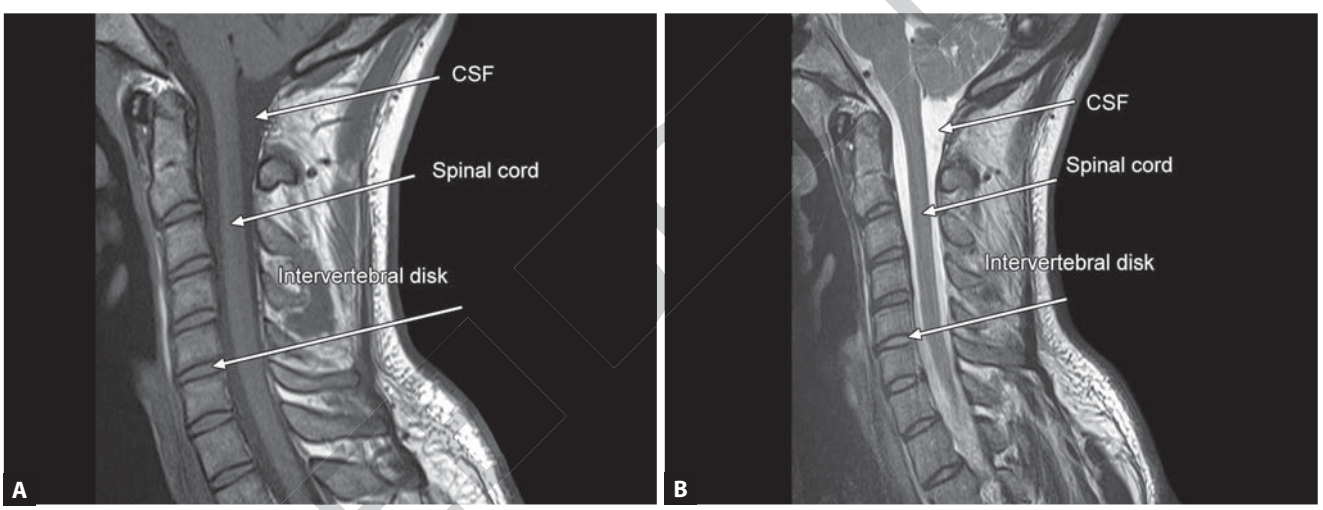

Figs. 7A and B: (A) MRI scan of cervical spine (sagittal T1 sequence image); (B) MRI scan of cervical spine (sagittal T2 sequence image). (CSF: cerebrospinal fluid)

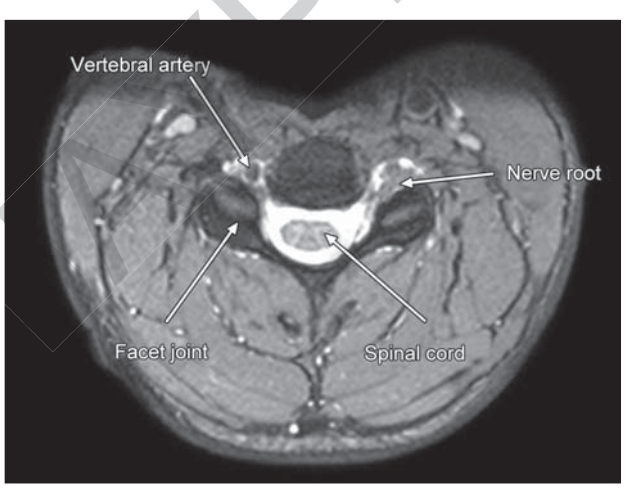

Fig. 8: MRI scan of cervical spine (axial T2 sequence image).

The first cervical vertebra is called the atlas. It is an atypical vertebra, which looks more like a ring; the vertebral body of C1 has been replaced by a small anterior tubercle to allow space for the dens of C2. The vertebral arches and articular facets are also modified to form lateral masses. The upper surface of the lateral mass is kidney-shaped and concave to articulate with the occipital condyle, while the lower surface is round and almost flat to accommodate the lateral atlantoaxial joint. The lateral masses of C1 and C2 lie anterior, compared with the facet joints of the other cervical vertebrae.[1-3]

The second cervical vertebra is also atypical. It is characterized by the odontoid process or dens, which is a large vertical spinous process arising from the body of

C2. The dens is nonweight bearing and articulates with the back of the arch of C1 at the median atlantoaxial joint allowing rotation. The axis articulation with C3 is the same as the other normal cervical vertebrae consisting of the vertebral body disk articulation, the uncovertebral and the facet joints. The facet joints are oriented approximately 45° superiorly from the transverse plane in the upper cervical spine, and they assume a more vertical orientation toward C7.

THORACIC VERTEBRAE

There are 12 thoracic vertebrae **(Figs. 9 to 15)**. The unique feature of thoracic vertebrae is the presence of a pair of semicircular demifacets on each side of the vertebral body, where the ribs articulate. The ribs articulate with the inferior demifacet and the transverse process of the associated vertebral body and the superior demifacet of the vertebra below (i.e., the 5th rib articulates with the inferior demifacet and transverse process of the 5th thoracic vertebra and the superior demifacet of the 6th thoracic vertebra). The upper demifacet is larger and lies at the junction of the vertebral body and the upper border of its pedicle. The smaller lower facet is at the lower border of the body. The thoracic vertebral body is heart-shaped and the vertebral foramen is almost round. The 10th, 11th, and 12th ribs have only single demifacets on each side of their bodies for articulation with the ribs.

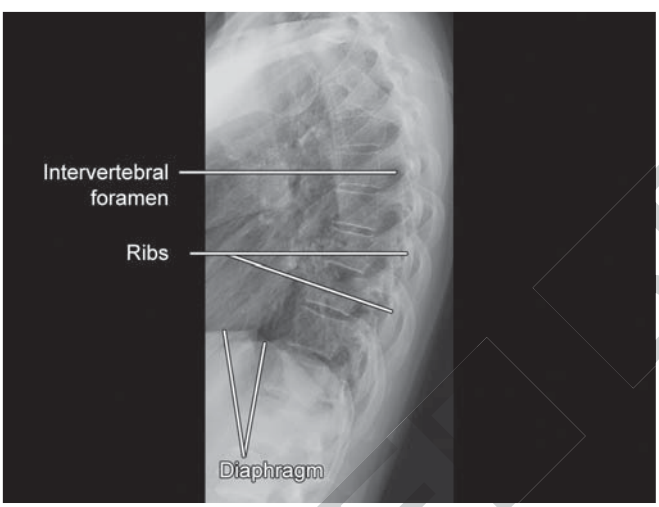

Fig. 9: Plain radiograph of thoracic spine (lateral view).

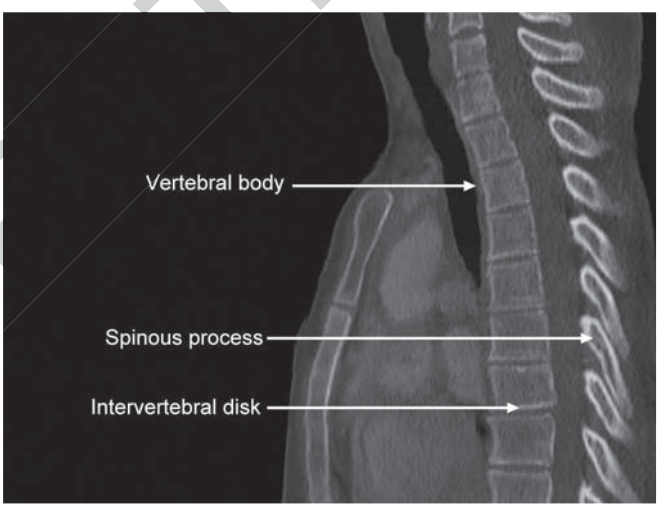

Fig. 11: CT scan of thoracic spine (sagittal reformat image).

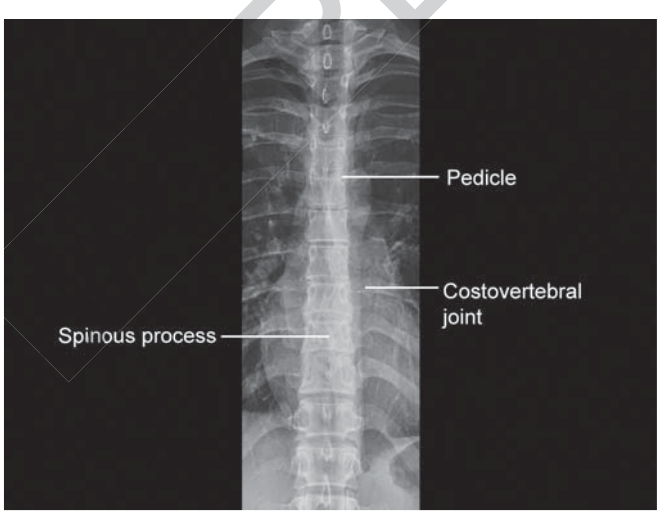

Fig. 10: Plain radiograph of thoracic spine (anteroposterior view).

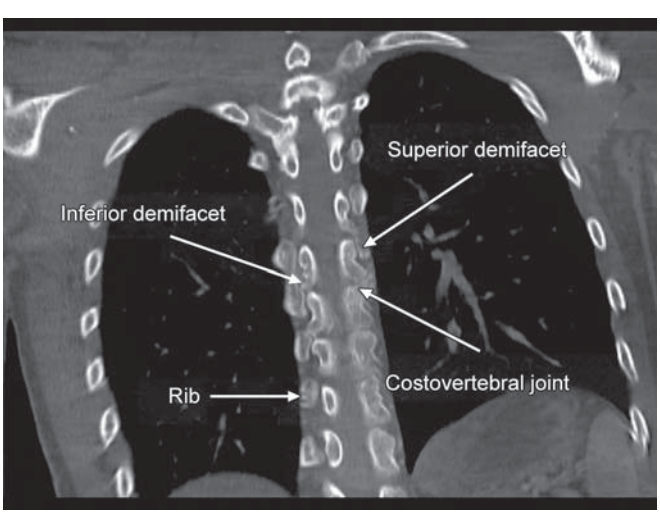

Fig. 12: CT scan of thoracic spine (coronal reformat image).

PEER REVIEWERS

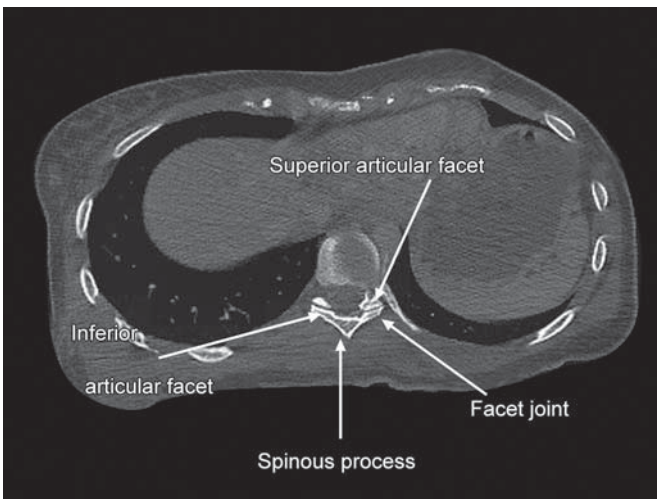

Fig. 13: CT scan of thoracic spine (axial image).

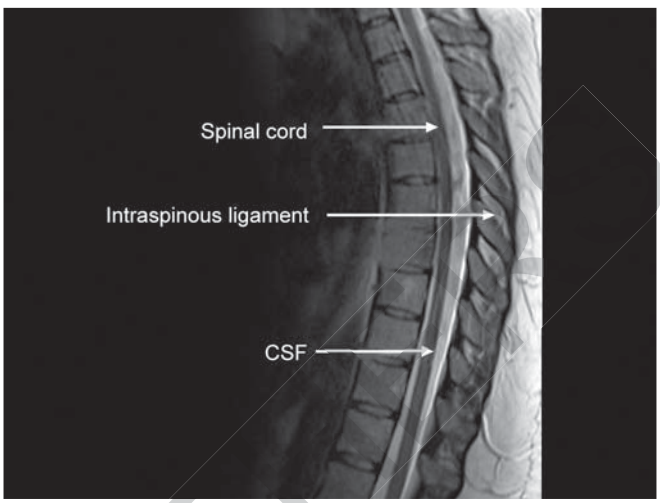

Fig. 15: MRI scan of thoracic spine (axial T2 sequence view). (CSF: cerebrospinal fluid)

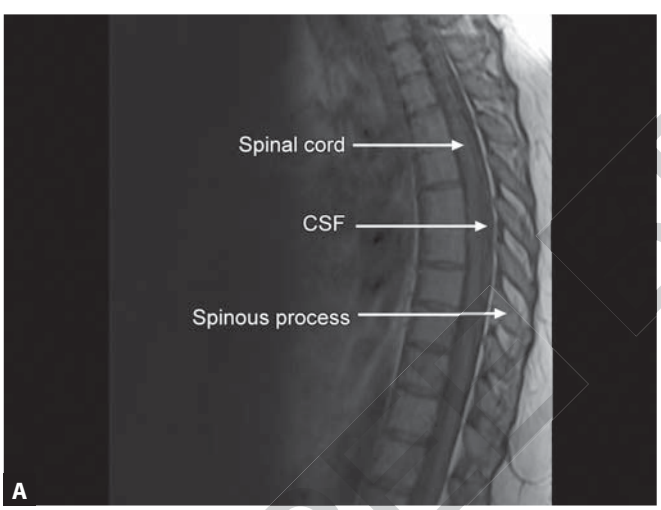

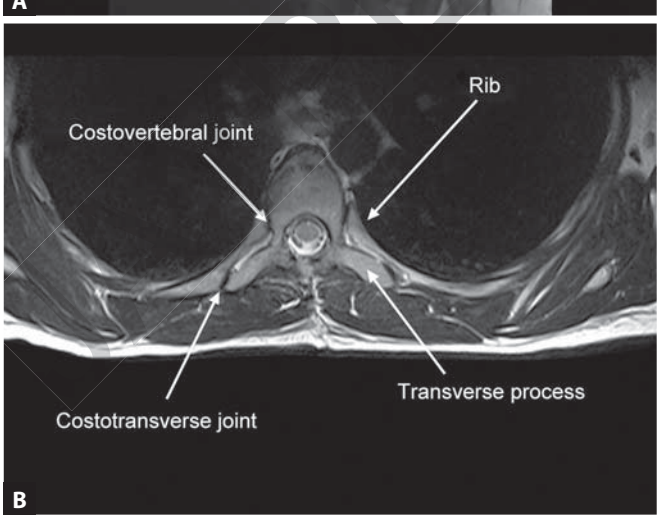

Figs. 14A and B: (A) MRI scan of thoracic spine (sagittal T1 sequence image); (B) MRI scan of thoracic spine (sagittal T2 sequence image). (CSF: cerebrospinal fluid)

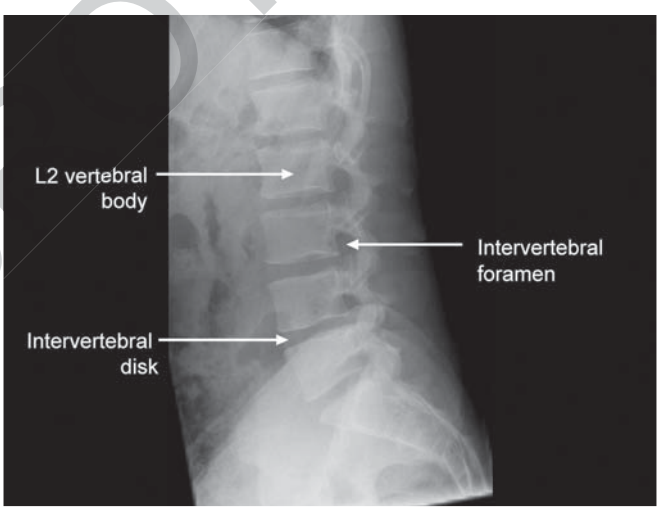

Fig. 16: Plain radiograph of lumbar spine (lateral view).

The superior articular facets of the thoracic vertebrae project up from the junction of the pedicle and the lamina. They face posteriorly and slightly laterally. The inferior articular facets face anteriorly and slightly medially. This arrangement permits some rotation between adjacent bodies.

LUMBAR VERTEBRAE

The normal appearance of the lumbar spine includes a gradual widening of interpedicle distance and an increase in disk height from the L1/2 to the L4/5 disk. The L5/S1 disk is usually slightly narrower. The lumbar vertebrae are characterized by large kidney-shaped vertebral bodies. The transverse and spinous processes are relatively short **(Figs. 16 to 22)**.

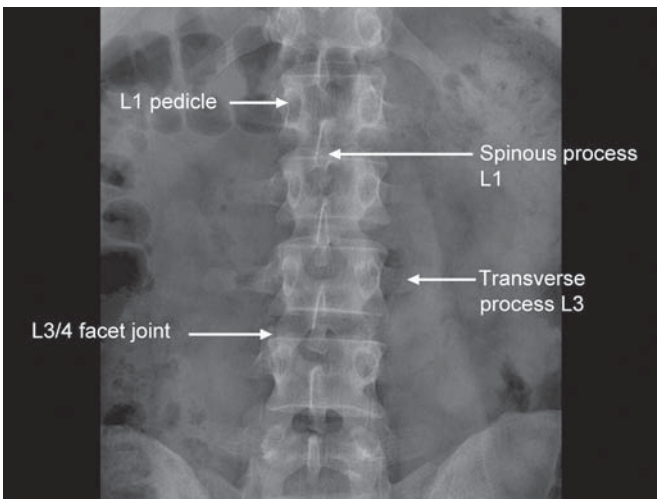

Fig. 17: Plain radiograph of lumbar spine (anteroposterior view).

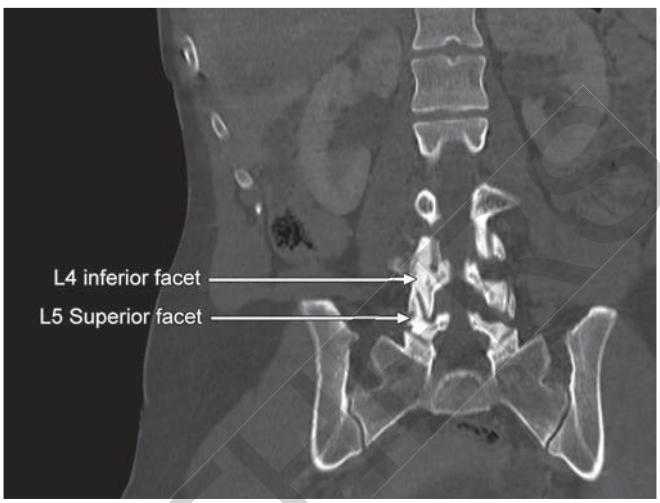

Fig. 19: CT scan of lumbar spine (coronal reformat image).

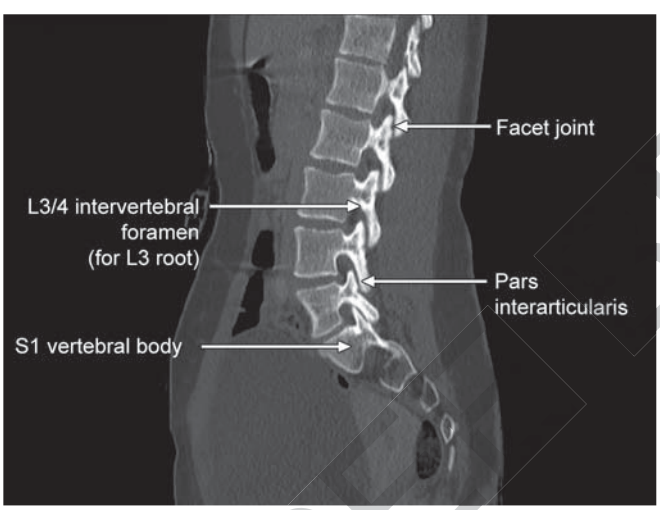

Fig. 18: CT scan of lumbar spine (sagittal reformat image).

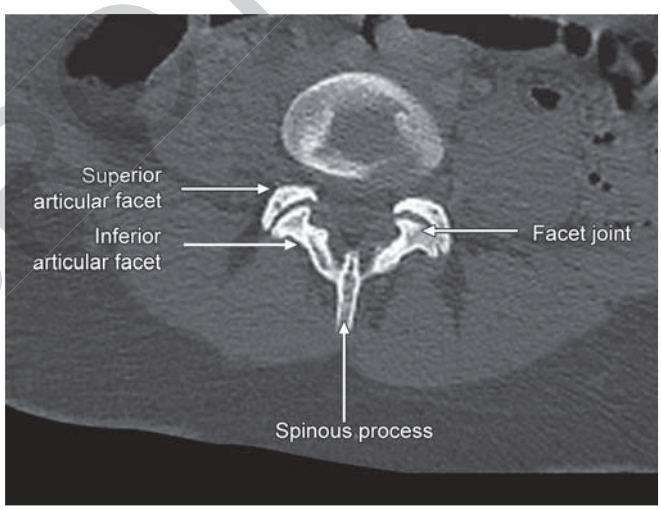

Fig. 20: CT scan of lumbar spine (axial image).

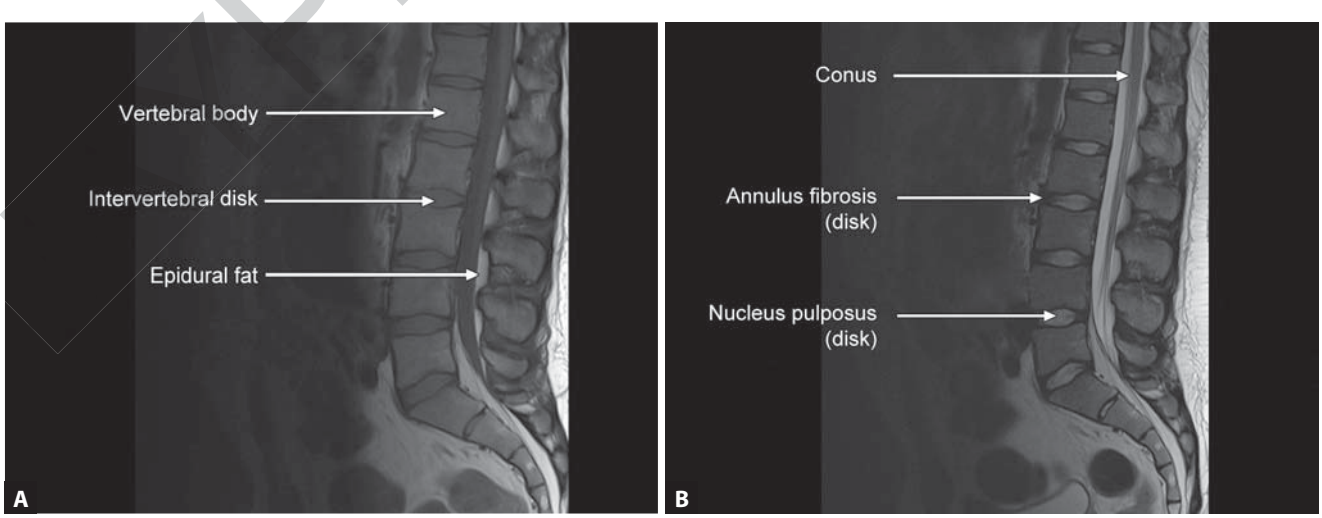

Figs. 21A and B: (A) MRI scan of lumbar spine (sagittal T1 sequence image); (B) MRI scan of lumbar spine (sagittal T2 sequence image).

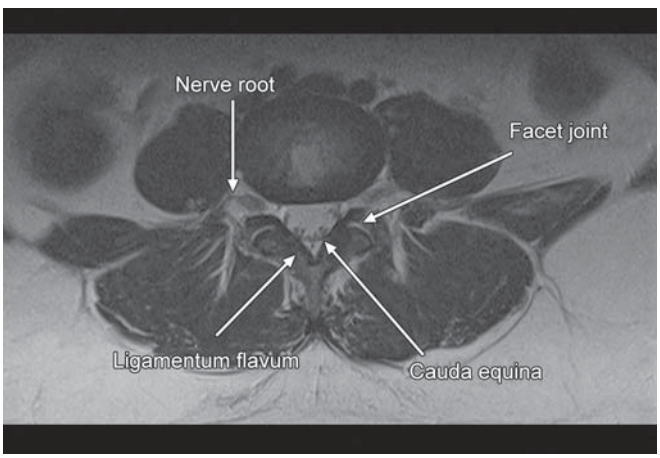

Fig. 22: MRI scan of lumbar spine (axial T2 sequence image).

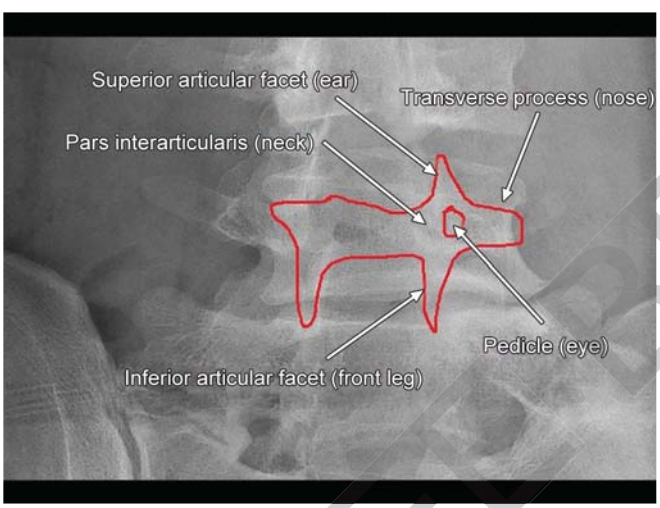

Fig. 23: Plain radiograph of lumbar spine (oblique "Scottie dog" view).

The articular processes are characteristic. The upper pair rises up and carries the articular facets, which face dorsomedial and are concave in the anteroposterior direction. The lower pair of articular processes project down; they face ventrolateral and are convex in the anteroposterior direction. This configuration is accentuated between L5 and S1, where the inferior articular process of L5 faces well forward and is received by the backward-facing facet of S1. This locks L5 in place and prevents it from sliding forward on S1.

On oblique radiographs, the posterior elements form the appearance of a "Scottie dog" **(Fig. 23)**.

Nose is the transverse process, eye is the pedicle, ear is the superior articular process, neck is pars interarticularis, and front leg is inferior articular process.

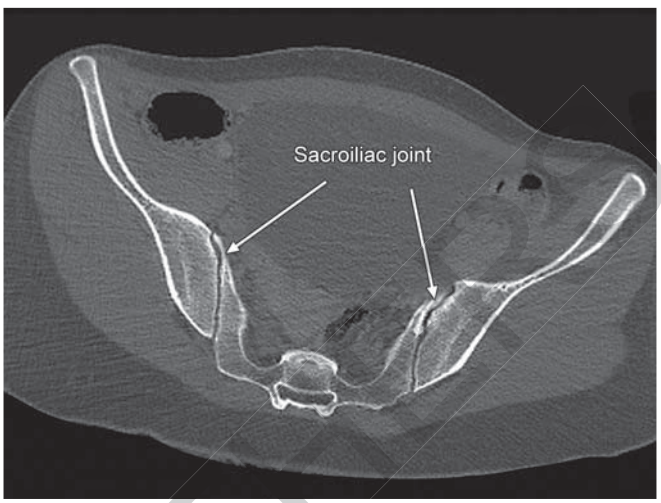

Fig. 24: CT scan of sacroiliac joint (axial image).

Lumbosacral transitional vertebrae are congenital anomalies defined as either sacralization of the lowest lumbar segment or lumbarization of the most superior sacral segment of the spine. Lumbosacral transitional vertebrae are common in the general population, with a reported prevalence of 4–30%. Correctly identifying a transitional vertebra is essential because there are important clinical implications. Inaccurate identification may lead to surgical and procedural errors and poor correlation with clinical symptoms. Additionally, some clinicians believe that low back pain is caused by transitional vertebrae; this is termed "Bertolotti syndrome".[4]

SACRUM AND SACROILIAC JOINT

The sacrum is a triangular bone made up of five fused sacral vertebrae. It is curved with a concavity toward the pelvis. The body of S1 is wide, and it articulates with L5 above; it tapers to an apex to articulate with the coccyx. It articulates with the body of the ileum on its lateral aspect to form the posterior wall of the pelvis. In addition to its characteristic shape, it contains anterior and posterior foramina through which the respective anterior and posterior rami of the spinal nerves pass. MRI is the fastest, cheapest, and most specific way in making the diagnosis of sacral insufficiency fractures, which are usually imperceptible on plain film and subtle on CT **(Figs. 24 and 25)**.

The sacroiliac joint is a synovial joint. With age, fibrous adhesions and gradual joint space narrowing occur. The joint is very stable permitting very little movement;

JAYPEE BROTHERS



Fig. 25: CT scan of sacroiliac joint (coronal reformat image).

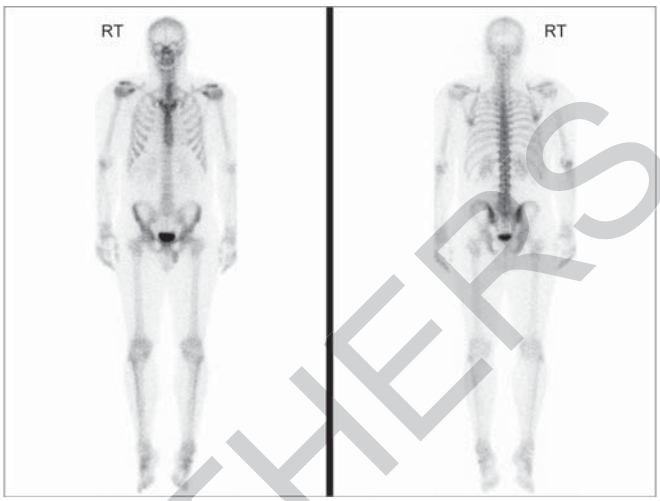

Fig. 26: Isotope bone scan.

the stability of the sacroiliac joint depends entirely on the sacroiliac ligaments.

SPINAL CORD

The spinal cord proper extends from the level of the foramen magnum in the skull to the level of L1/2 in the adult where it tapers in a cone-shaped ending called the conus medullaris. A stalk of pia mater, the filum terminale attaches from the conus medullaris to the dura mater at S2. The spinal nerve roots of the lumbar and sacral segments slope steeply downward forming the cauda equina. The space below the L2 vertebra, typically at L4, is considered safe to sample CSF since only nerve roots and not spinal cord are found there. Similarly, a lower lumbar posterior disk herniation can impinge upon individual nerve roots or the entire cauda equina to cause radiculopathy or cauda equina syndrome.[2,3]

RADIONUCLIDE IMAGING

The spine is also often imaged with gamma cameras, using radioactive technetium-99m–labeled diphosphonates. There is symmetric distribution of activity throughout the skeletal system in healthy adults **(Fig. 26)**. Urinary bladder activity, faint renal activity, and minimal soft-tissue activity are also normally present. In the neck, activity in the facet joints of the cervical vertebrae in patients with asymptomatic degenerative changes is frequently seen. Bone scintigraphy scans, as they are known, are not specific but they are extremely sensitive for picking up many pathologic conditions, such as metastatic disease, trauma, and infection as well as Paget disease and spondylolysis. Abnormalities that extend beyond the vertebral body are invariably due to osteophytes, whereas abnormalities that are confined to the articular facets are nearly always benign in origin. Radiotracer accumulation in both the vertebral body and pedicles usually indicates metastatic disease, whereas abnormalities that involve the vertebral body and facets, but spare the pedicles, are usually benign.

CONCLUSION

Interventional pain management requires the ability to interpret various different imaging modalities, including plain radiography, fluoroscopy, CT, and MRI. This chapter has given an overview of the basic radiological anatomy, which is required by the interventional pain physician. By actively studying the anatomical imaging in a clinical context, the pain physicians will increase the efficacy and accuracy of their interventions, which in turn will further help with the interpretation of imaging studies.

REFERENCES

1. Baheti DK, Bakshi S, Gupta S, Gehdoo RP. Interventional Pain Management: A Practical Approach. New Delhi: Jaypee Brothers Medical Publishers (P) Ltd.; 2009.
2. Stoller DW. Magnetic Resonance Imaging in Orthopaedics and Sports Medicine, 3rd edition. New York: Lippincott Williams and Wilkins; 2006.
3. Sinnatamby CS, Last RJ. Last's Anatomy: Regional and Applied, 12th edition. New York: Churchill Livingstone; 2011.
4. Jain A, Agarwal A, Jain S, Shamshery C. Bertolotti syndrome: a diagnostic and management dilemma for pain physicians. Korean J Pain. 2013;26(4):368-73.

JAYPEE BROTHERS

for detailed information on anesthesia books, visit our website www.jaypeebrothers.com, for detailed information on anesthesia books, visit our wel

Salient Features

- The third edition of this book has been presented with updated information with newer images
- Four new chapters have been added including a new chapter on "Medico-legal Aspects for Pain Physicians"
- The updated information of contents and new images has resulted in increase in number of pages from 510 to 544
- This is the only one book which has DVD of demonstration of "Procedures done in Pain Management." The videos are from experts in the field and are self-explanatory
- Only one book for all which includes students, practicing pain physicians, teachers, and for reference
- The description of procedures is given in simple language which students from vernacular medium will also understand and follow easily
- Every procedure including under ultrasound guided is more practical for students to perform.



Dwarkadas K Baheti MD did his MD from PGIMER, Chandigarh, India. Presently, he is a consultant of "Anesthesiologist and Pain Physician" at Bombay Hospital and Research Centre and Pain Physician at Lilavati, Shushrusha and Raheja hospitals, Mumbai, Maharashtra, India. He is on editorial board of Indian Society for Study of Pain and Bombay Hospital Journal—An indexed journal and Executive President, Pain Management and Research Foundation, India. He is the Editor-in-Chief for World Clinic Anesthesiology, Critical Care, Pain Issues on Pain Management, Analgesia and Anesthesia for Labor Analgesia (I & II) and Pediatric Anesthesia (I & II). He has edited "Interventional Pain Management—A Practical Approach 2009 and Symptom-oriented Pain Management." He is a pioneer in social campaign of Pain Awareness Program in India; is first to perform Epiduroscopy in India, and has the largest series of Neurolytic Celiac Plexus Block from India (300+). He has designed "Blunt Tip Needle for Sympathetic blocks." He is formerly a Professor and Head of Department of Anesthesia and Pain, Bombay Hospital Institute of Medical Sciences, Mumbai, Maharashtra, India; was a recognized teacher to Maharashtra University of Health Sciences and College of Physician; is the Past President of Indian Society for Study of Pain (2001). He was an International Scholar to Cleveland Clinic Foundation and was UICC fellow to Memorial Sloan Kettering Cancer Center, USA. Dr Baheti was the Secretary General to Global Update on Pain (2000, 2003, and 2006) and Organizing Chairman to Global Update on Pain 2009, 2012, and 2015. He has organized, chaired, and lectured at many national and international meetings. He was the Course Director and organized many Hands-on Cadaver Workshops.



Sanjay Bakshi MD MBA has been in private practice in New York since 1996. Prior to that he was an attending physician at Johns Hopkins in Baltimore, Maryland, USA, where he also completed his fellowship in pain management in 1995. He is board certified in Anesthesia and Pain Management. He is actively involved in teaching and has published book chapters and articles in pain management. During his residency, he received the Dripps award for the outstanding anesthesia resident. Dr Bakshi's area of expertise is primarily in minimally invasive therapies for the treatment of pain of spinal origin. Other pain management physicians visit him to see his techniques. He is an instructor for cadaver workshops for pain management fellows and attending physicians in pain management. Dr Bakshi has appeared numerous times on television (including Fox 5, ABC, CBS, Ch 7 news) as well as in the press discussing various interventional pain management techniques. He is the Editor of book "Interventional Pain Management: A Practical Approach 2009," and "Symptom-oriented Pain Management," Jaypee Brothers Medical Publishers (P) Ltd., New Delhi, India.



Sanjeeva Gupta MBBS MD Dip NB FRCA FIPP FFPMRCA did his MD from PGIMER, Chandigarh, India. After completing FRCA from London, he trained in Oxford and Cambridge and has been a Consultant in Pain Medicine at the Bradford Teaching Hospitals, UK, since 1999. Dr Gupta is at present the Educational Meetings Advisor to the Faculty of Pain Medicine of the Royal Collage of Anesthetists, London; Director of the Imaging and Investigations in Pain Medicine course at Bradford; Co-director of the annual Leeds Cadaver Course; Faculty of the International Spinal Intervention Society European Cadaver Courses; and International Advisor to the Global Update in Pain Meetings at Mumbai. He is also an Editor of Practical Management of Complex Cancer Pain (Oxford University Press) among other books. His main interests are Precision Spinal Pain Diagnosis and Management, Radiofrequency techniques in pain management, CRPS, and Neuropathic pain.



Raghbir Singh P Gehdoo MD DA passed DA and MD in 1984 and 1986, respectively from Dr VM Medical College, Solapur, Maharashtra, India. At present, he is working as a Professor in Anesthesiology in Tata Memorial Hospital, Mumbai since 1992. He is the Secretary of Indian Society for Study of Pain (An Indian Chapter of IASP) since 2001. He was the Scientific Chairman for all the three Global Update on Pain conferences held in Mumbai in the year 2000, 2003, and 2006. He has about 145 presentations in different national anesthesia and pain conferences. He has been a PG guide for MD and DA courses as well as Examiner for the examinations, for last 12 years. He is the only Indian to represent in the Asia-Pacific Meet held at Cambodia in March 2007 about the Formulations of International Guidelines for the neuropathic pain management. Dr Gehdoo is one of the Editor of book "Interventional Pain Management: A Practical Approach 2009 and 2016" published by Jaypee Brothers Medical Publishers (P) Ltd., New Delhi, India.

Printed in India

Available at all medical bookstores or buy online at www.ejaypee.com

JAYPEE BROTHERS
Medical Publishers (P) Ltd.
EMCA House, 23/23-B, Ansari Road,
Daryaganj, New Delhi - 110 002, INDIA
www.jaypeebrothers.com

Join us on facebook.com/JaypeeMedicalPublishers
Follow us on instagram.com/JaypeeMedicalPublishers

Shelving Recommendation
ANESTHESIOLOGY

ISBN 978-93-5696-943-8