eebrothers.com, for detailed information on obstetrics & gynecology books, visit our website www.jaypeebrothers.com, for detailed information on obstetrics & gynecology book

2nd Edition

Color Doppler in Obstetrics & Gynecology

Text and Atlas

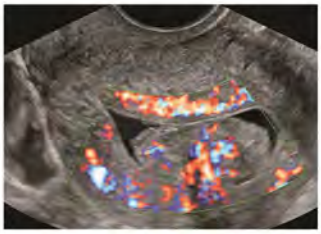
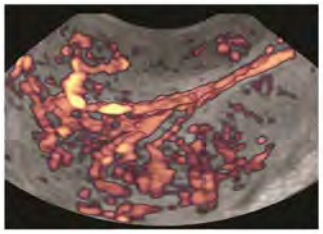
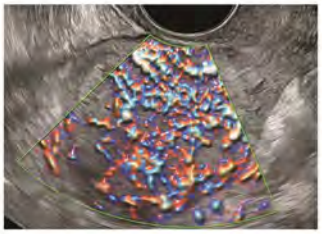

Editors
Sonal Panchal
Chaitanya Nagori

JAYPEE

Contents

1. Doppler Basics for a Gynecologist 1
- What is Doppler? *1*
- Color Doppler *2*
- Power Doppler *2*
- Spectral Doppler *4*
- Color/Power Doppler Settings *5*
- Settings for Pulsed Wave Doppler *8*
- Setting the Speed of the Trace *12*
- Artifacts *12*
- Safety of Doppler *13*

2. Endometrial Lesions and Doppler 15
- Inflammatory Lesions *16*
- Abnormal Response to Hormones *21*
- Endometrial Metaplasia *23*
- Neoplastic Lesions *24*

3. Doppler in Myometrial Lesions 33
- Scan Routes And Modalities *33*
- Assessment of the Uterus on Transvaginal Scan *33*
- Measurements *35*
- Doppler Studies *41*
- Adenomyosis *44*
- Fibroids *50*
- Disseminated Peritoneal Leiomyomatosis *54*
- Benign Metastasizing Leiomyoma *54*
- Enhanced Myometrial Vascularity *55*

4. Role of Doppler in Diagnosing Gynecological Malignancies 59
- Angiogenesis in Malignancies *59*
- Uterine Malignancies *60*

5. Doppler for Differential Diagnosis of Adnexal Lesions 75
- Ovary *75*
- Ovarian Neoplasms *88*

6. Sonoendocrinology 95
- Androgen *95*
- Anti-Müllerian Hormone *97*
- Follicle-stimulating Hormone *97*
- Luteinizing Hormone *98*
- Estrogen *100*
- Progesterone *100*

7. Ultrasound and a Treatment Cycle 112
- Baseline Scan *112*
- Preovulatory Scan *116*
- Midluteal Phase *122*

8. Doppler in Normal and Abnormal Early Pregnancy 127
- Pregnancies with Abnormal Prognosis *131*
- Trophoblastic Diseases *145*

9. Doppler in Fetal Echocardiography 151
- Equipment Settings *151*
- M Mode Study *151*
- Four-chamber View *152*
- Left Ventricular Outflow Tract *155*
- Right Ventricular Outflow Tract *156*
- Three-vessel View *156*
- Short Axis View *157*
- Arch/Longitudinal Views *157*
- Fetal Circulation *159*
- Abnormalities Seen on Three-vessel View: Role of Doppler *174*

10. Role of Doppler in Fetal Growth Restriction and Pregnancy-induced Hypertension 178
- Uteroplacental Vascular Changes and Effect on Fetal Metabolism *181*
- Technique of Doppler Assessment *184*
- Silent Period of Increased Resistance *185*
- Early-onset Fetal Growth Restriction *192*
- Late-onset Fetal Growth Restriction *192*
- Obstetric Management Depending on Doppler Findings *193*

11. Fetal Anemia: Role of Doppler 198
- Pathophysiology of Signs and Symptoms of Fetal Anemia *199*
- Diagnosis *199*
- B-Mode Signs of Fetal Anemia *199*
- Role of Doppler in Fetal Anemia *200*
- Limitations of Middle Cerebral Artery Peak Systolic Volume as a Predictor of Fetal Anemia *203*

12. Doppler for Diagnosis of Congenital Fetal Abnormalities 205
- Doppler for Diagnosis of Structural Abnormalities *205*

Index 223

5

CHAPTER

Doppler for Differential Diagnosis of Adnexal Lesions

Sonal Panchal

JAYPEE BROTHERS

INTRODUCTION

The uterus, ovaries, and tubes are the pelvic organs that consist of the female genital tract. The adnexa comprises the ovaries, fallopian tubes, and ligaments. These organs host several lesions arising out of normal physiology, arising out of abnormal physiology, and pathological of inflammatory or neoplastic origin chiefly. To be easily able to classify these, several different consensus and classifications have been developed. International Ovarian Tumor Analysis (IOTA)[1] is the most systematic consensus for differential diagnosis of ovarian lesions and also for calculating the risk of malignancy. Though as the scope of this chapter is to discuss the role of color Doppler for differential diagnosis of adnexal lesions, we shall not discuss IOTA in detail, but we shall take it as a reference wherever relevant. For ease of discussion, we shall divide this chapter into ovarian and tubal lesions.

OVARY

The ovary is an organ that changes its morphology several times during the menstrual cycle. Cystic structures with different morphologies appear and disappear. This is absolutely physiological when these are follicles, corpus luteum, luteinized unruptured follicles, or follicular cysts. But there may be pathological cysts also appearing in the ovary. It is therefore very important to differentiate between the physiological and pathological cysts in the ovaries. Of course, majority of the ovarian lesions are chiefly cystic with or without solid components, but these also may be solid masses. So let us start with the physiological cystic structures and let us then discuss what are the pathological cystic structures that simulate those structures and how to differentiate those.

It is known that the ovary at the start of the menstrual cycle has multiple small follicles—antral follicles. These follicles grow as the cycle progresses and then one/two follicles grow to dominance (>10 mm). Dominant follicle may progress to maturity or may rupture. After rupture, it converts into corpus luteum. And then if the cycle is not a conception cycle, the corpus luteum gradually regresses.

The follicle is a round cystic [unilocular cystic (IOTA)] structure with thin walls and anechoic contents with no solid components or internal echogenicities **(Fig. 1)**. It is seen in the proliferative phase of the menstrual cycle. A mature follicle (18–24 mm in diameter) normally shows perifollicular vascularity covering two-thirds to three-fourths of its circumference with low resistance flow[2] **(Fig. 2)**. The low resistance flow in the perifollicular vessels can be correlated with the rising estrogen levels. Lesions that appear similar to follicle, thin-walled, anechoic contents with no internal echogenicities or solid components, may be a simple cyst or a follicular cyst **(Table 1)**. On B-mode ultrasound, the follicle cannot be differentiated from a simple cyst or follicular cyst. Simple cysts in the ovaries can be of any size but typically these are hormonally inactive and do not show any vascularity around. Unlike follicles, these cysts do not change the morphology or disappear even in the luteal phase of the cycle. Another lesion that has a similar appearance is popularly known as a follicular cyst. When a follicle keeps on growing beyond 25 mm in diameter, it is usually called a follicular cyst **(Fig. 3)**. A follicle that gradually loses its sensitivity to follicle-stimulating hormone (FSH), the estrogen production is reduced from the granulosa cells of the same. This is when this follicular structure is known as a follicular cyst. As is known that the perifollicular vascularity with the low resistance flow of the follicle is correlated with estrogen production, the decreased

estrogen production evidently reflects higher perifollicular flow resistance. A follicular cyst is a physiological cyst and has a tendency to regress in the course of time (4–6 weeks).

At this point, it is important to differentiate the ovarian from extraovarian lesions. The sliding organ sign[3] or the Timor-Tristch sign differentiates between the ovarian and extraovarian lesions. On the scanner screen when the ovary and the lesion are seen adjacent to each other, the probe is pushed in and out pressing and depressing on the point of apposition of the lesion and the ovary **(Fig. 4)**. If this maneuver separates the lesion from the ovary, the lesion is extraovarian, but if this is not possible, the lesion may be intraovarian or extraovarian but adherent to the ovary. If the rim or a beak of ovarian tissue **(Figs. 5A and B)** is seen around the lesion, it is intraovarian; if not, it is extraovarian but adherent to the ovary.

The extraovarian lesion that may mimic the ultrasound morphology of the follicle is a paraovarian cyst **(Fig. 6)**. As a rule, uncomplicated paraovarian cysts are never adherent to any of the surrounding structures or do not show any internal echogenicities. If it does, then infection or rarely a malignant change is suspected in the paraovarian cyst. It must be remembered that uncomplicated paraovarian cysts are always avascular. If the vascularity is seen around the paraovarian cyst, a strong suspicion of infection or malignancy arises. However, when a paraovarian cyst is suspected, rotation of the probe is a must before confirmation of diagnosis.

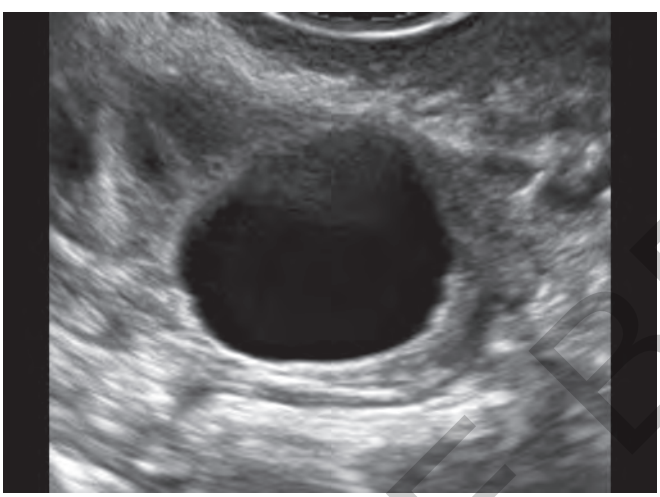

Fig. 1: B-mode ultrasound image of unilocular cyst with clear contents and thin walls.

TABLE 1: Differential diagnosis of clear, nonseptated ovarian cystic lesions (unilocular cystic lesions).

Feature	*Follicle*	*Follicular cyst*	*Simple cyst*
Size	Up to 24 mm	≥25 mm	>25 mm, often >50 mm
Phase of cycle	Proliferative	Late proliferative or secretory	Any phase of the cycle
Vascularity	Low resistance ring of color	Scanty, high resistance	No flow
Natural course	Convert into CL	Regresses	Persists

(CL: corpus luteum)

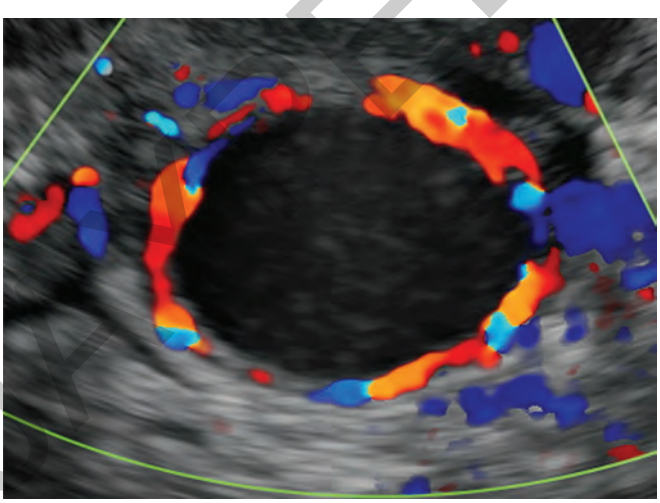

Fig. 2: Color Doppler image of a unilocular cystic structure with smooth walls and anechoic contents. The rich vascular ring suggests it is a mature follicle.

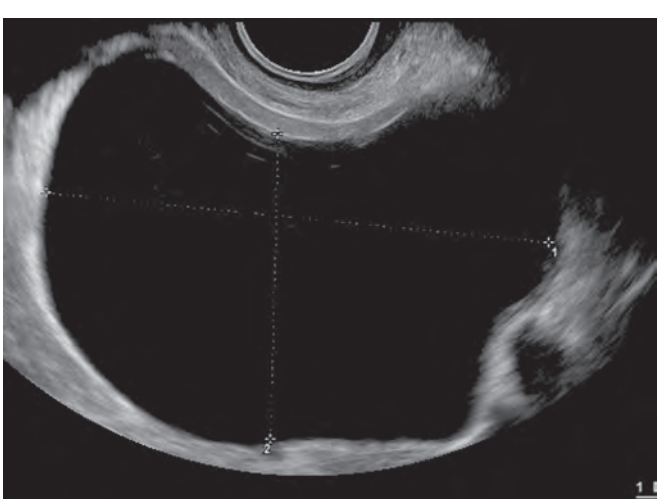

Fig. 3: Large intraovarian unilocular cyst—follicular cyst.

JAYPEE BROTHERS

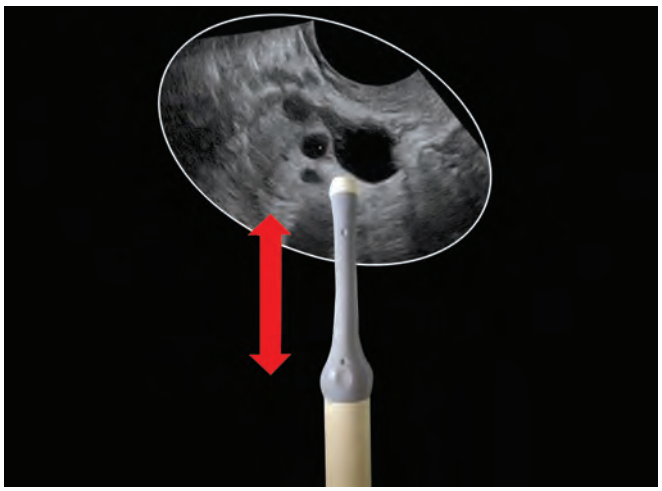

Fig. 4: Ultrasound image of a unilocular cystic lesion and closely placed ovary. The figure also shows positioning of the probe and the arrow shows the movement direction of the probe.

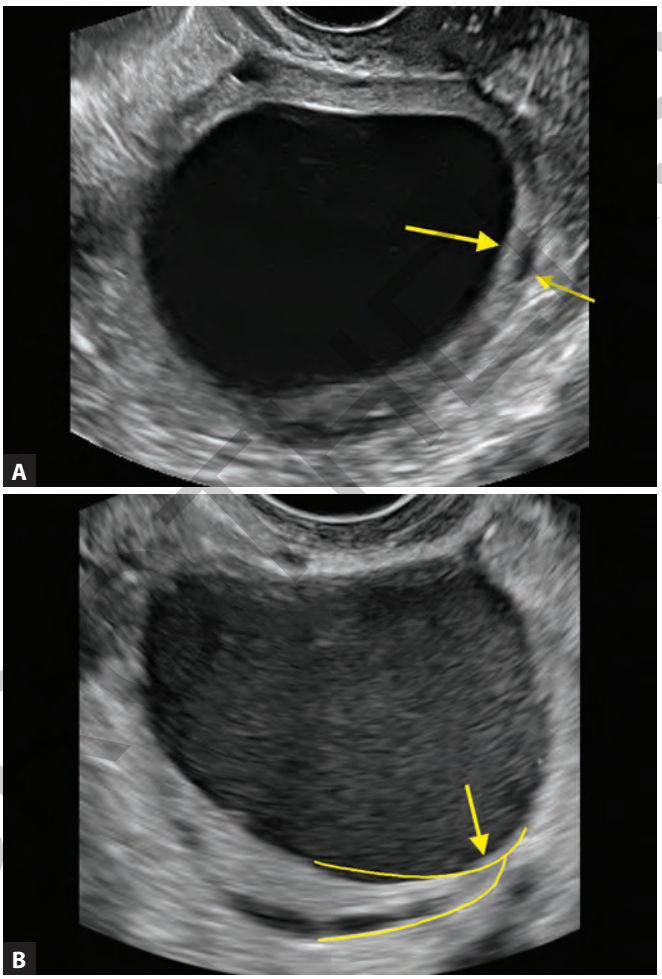

Figs. 5A and B: (A) Unilocular cystic lesion seen on B-mode ultrasound with surrounding rim of ovarian tissue as indicated by the arrows; (B) Unilocular cystic lesion with the beak of ovarian tissue outlined by yellow line and marked by arrow.

If this cystic lesion changes shape (elongates) on the rotation of the probe, it may be hydrosalpinx and not a paraovarian cyst. Hydrosalpinx will be discussed later in this chapter.

When multiple follicles have grown together, as may happen in patients on ovulation induction treatment, these may get placed close to each other, appear polygonal in shape, and may also sometimes appear like a septated cystic lesion, with anechoic contents [multilocular cystic lesion (IOTA)]. On Doppler, blood flow is seen in the follicular walls, as seen in a single follicle and this may be mistaken for a multilocular cystic lesion with vascularity in septae **(Fig. 7)**. Benign serous cystadenoma is an ovarian lesion that has a very similar ultrasound morphology. Serous cystadenoma presents as a multilocular cystic lesion wherein the septae are thin and are typically avascular. Benign serous cystadenoma has walls, thinner than 3 mm in thickness, septae thinner than 3 mm, no internal echogenicities, no papillarities, and no solid projections[4] **(Fig. 8)**. The vascularity is limited to the periphery and the resistance index of these vessels is always >0.5. Development of septal vascularity and internal echogenicities or papillarities may be the few earliest signs of conversion of this benign serous cystadenoma to malignant.

Very interestingly, multiple Nabothian cysts often appear like multiple follicles at times **(Fig. 9)**. Of course, confirming the organ of origin will clear this confusion. Another extraovarian cystic lesion that has no internal echogenicities, but may have septae and mimic the above-described lesions is a peritoneal inclusion cyst **(Fig. 10)**. It is extraovarian, irregular in shape, changes shape on probe pressure, has thin septae that are mobile, may have parietal papillae, appearing like papillarities, and also may have one of the ovaries lying close to it, but typically shows no vascularity on Doppler. It typically has no floating bowel loops, unlike free fluid in the pelvis **(Fig. 11)**.

Unilocular or multilocular cystic structures may also show internal echogenicities. The physiological lesions in this group are corpus luteum, hemorrhagic cyst, and luteinized unruptured follicle. The corpus luteum is a thick-walled cystic structure with blood and blood products in the lumen. With the rupture of the follicle, the walls break, and with that the vessels in the follicular wall rupture, resulting in hemorrhage **(Fig. 12)**.

JAYPEE BROTHERS

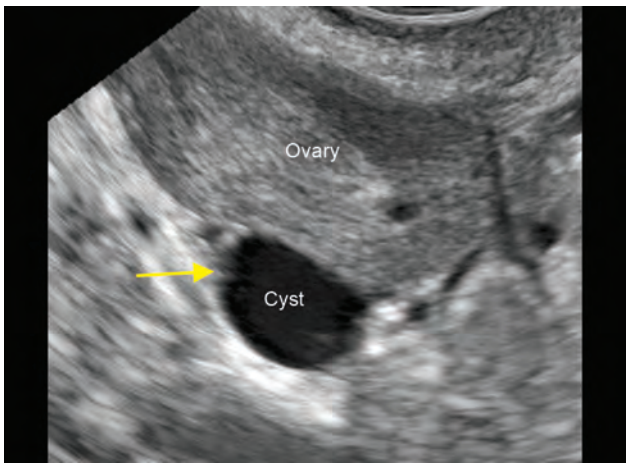

Fig. 6: Paraovarian cyst marked by an arrow on the B-mode ultrasound image.

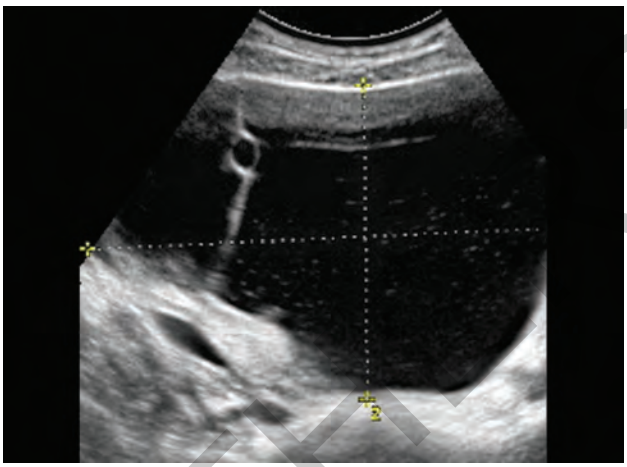

Fig. 8: Multilocular intraovarian cystic lesion with anechoic contents and thin septa—possibly benign serous cystadenoma.

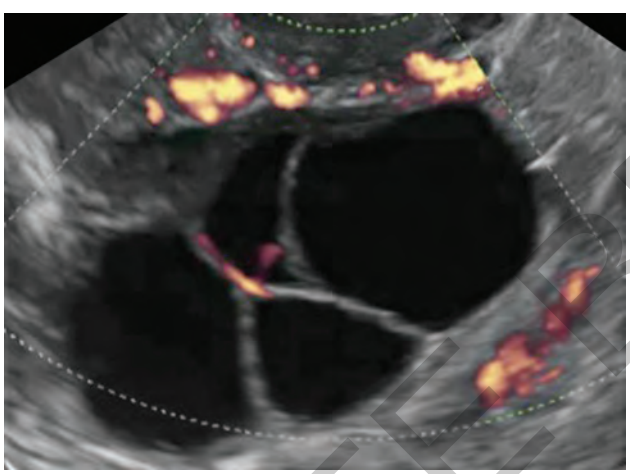

Fig. 7: Power Doppler ultrasound image showing multiple follicles mimicking multilocular cyst with blood flow in the follicular walls mimicking septal blood flow of multilocular lesion.

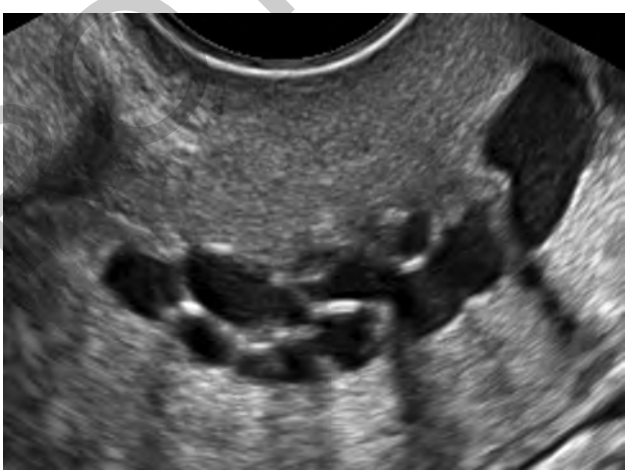

Fig. 9: B-mode ultrasound image showing multiple Nabothian cysts.

The lesions that appear similar on ultrasound are hemorrhagic cysts, luteinized unruptured follicles, and endometriomas **(Table 2)**. Though infected simple cysts or infected paraovarian cysts may also appear similar to these lesions. These lesions have thick walls, at times shaggy. The contents have internal echogenicities, but no solid components or septae [unilocular cystic lesions with internal echogenicities (IOTA)]. Fibrin strands need to be differentiated from septae. On rotation of the probe, at some point of rotation, the concavity of the margins, also known as the retraction sign, excludes the possibility of septum **(Fig. 13)**. If a septum-echogenicity on rotation of the probe shows concavity at least on one side, it indicates that it is a retracted fibrin strand and is not a

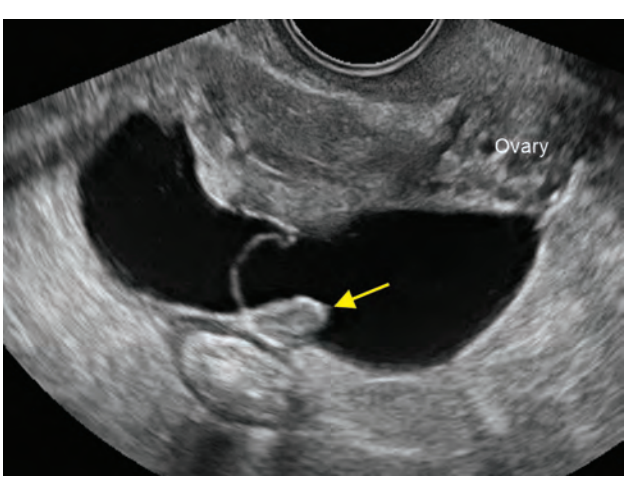

Fig. 10: Peritoneal inclusion cyst with curved septum, arrow showing parietal papilla and ovary is seen by the side of the cystic lesion.

JAYPEE BROTHERS

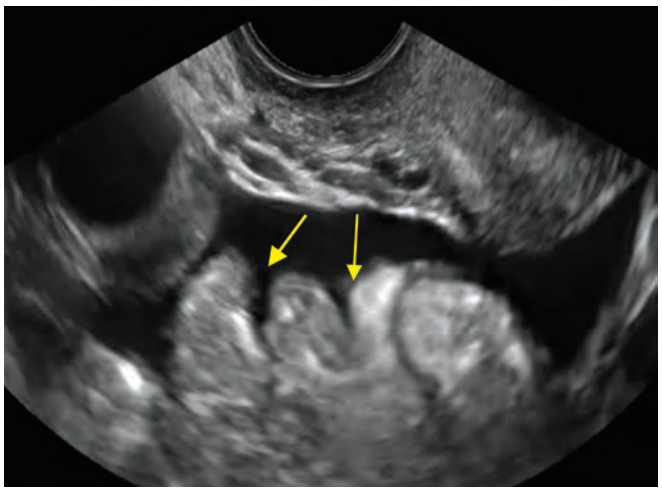

Fig. 11: B-mode image showing free fluid in pelvis with floating bowel loops as marked by the arrows.

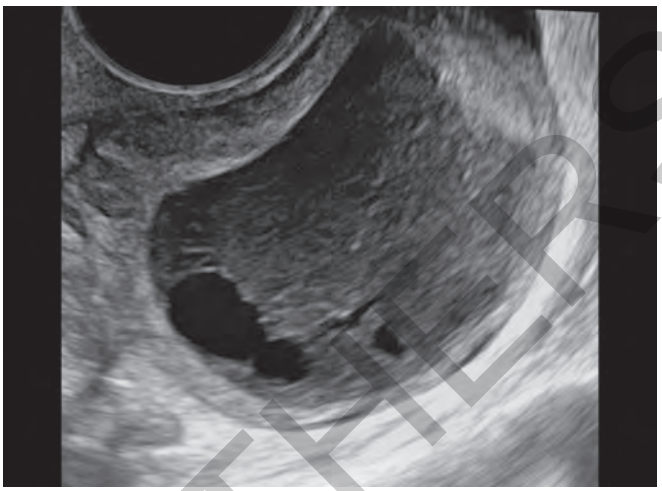

Fig. 12: B-mode image of corpus luteum with thick walls and hemorrhagic contents.

TABLE 2: Ovarian lesions with thick walls and internal echogenicities.

Feature	*Corpus luteum*	*LUF*	*Hemorrhagic cyst*	*Endometrioma*
Walls	Thick, isoechoic, shaggy	Thick, hyperechoic	Thick, isoechoic shaggy	Thick, isoechoic shaggy, hyperechoic flecks
Contents	Fishnet, fibrin stands, ground glass, isoechoic, solid debris	Low level echoes	Fishnet, fibrin stands, ground glass, isoechoic, solid debris	Ground glass, fluid level, solid looking debris, fibrin strands, fishnet
Vascularity	Ring of color, low resistance	High resistance, not abundant	No vascularity	Short coursed vessels
Phase of cycle	Luteal	Luteal	Proliferative	Any phase

(LUF: luteinized unruptured follicle).

septum. These lesions may have debris. Solid projections need to be excluded in this group of lesions. Debris can be differentiated from the solid components by the in and out movement of the probe. This if leads to movement of the contents in relation to the cystic wall, it is debris, otherwise it is a solid component. More often, debris tends to settle dependent on gravity, whereas solid components have convex margins in the lumen **(Figs. 14A and B)**.

The corpus luteum typically has thick, crenulated, or shaggy isoechoic walls **(Fig. 15)**. It is first thought of when this lesion is seen in the luteal phase of the cycle. Contents of the cyst show heterogeneous echogenicity with or without fibrin strands. This is described as a typical appearance of the corpus luteum. But the corpus luteum has variable appearances. The contents may have a fishnet appearance, ground glass appearance **(Figs. 16A and B)**,

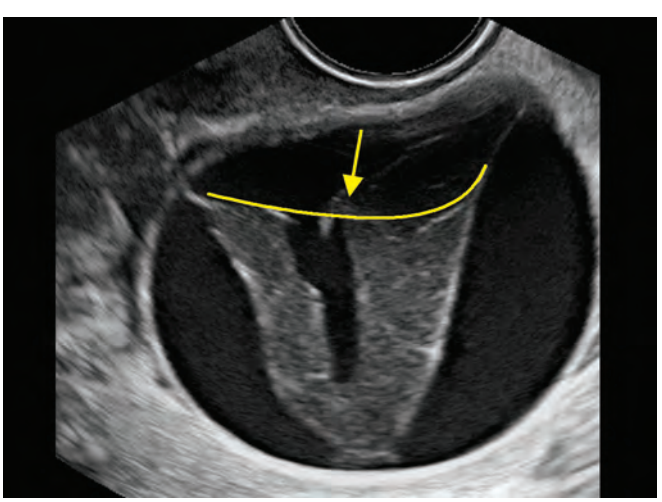

Fig. 13: B-mode image of retracted fibrin strand in a cystic lesion with hemorrhage inside.

JAYPEE BROTHERS

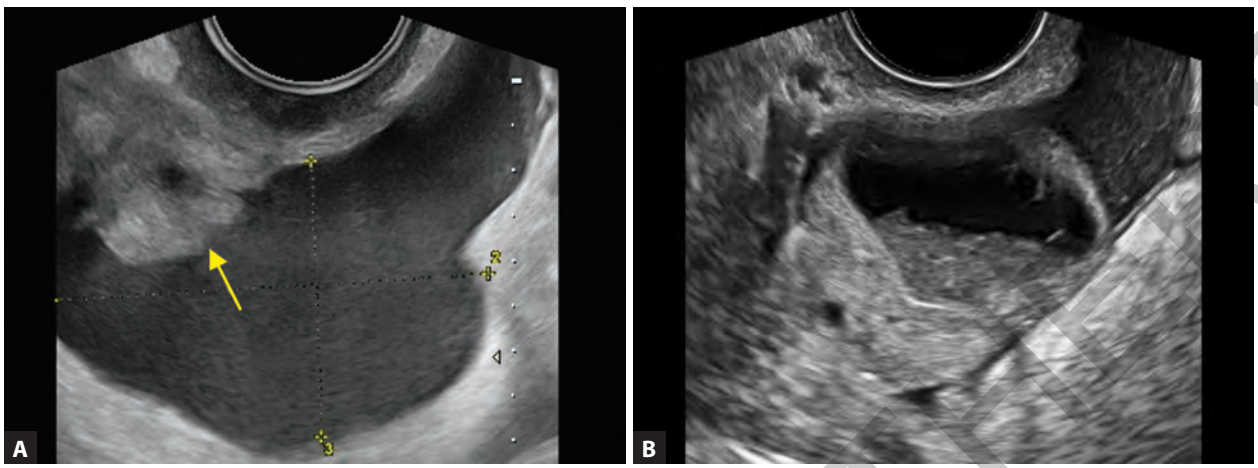

Figs. 14A and B: (A) B-mode image of a unilocular solid lesion with the solid component (arrow) showing convex margins in the lumen; (B) B-mode ultrasound image of a unilocular cystic lesion with echogenic debris settled posteriorly.

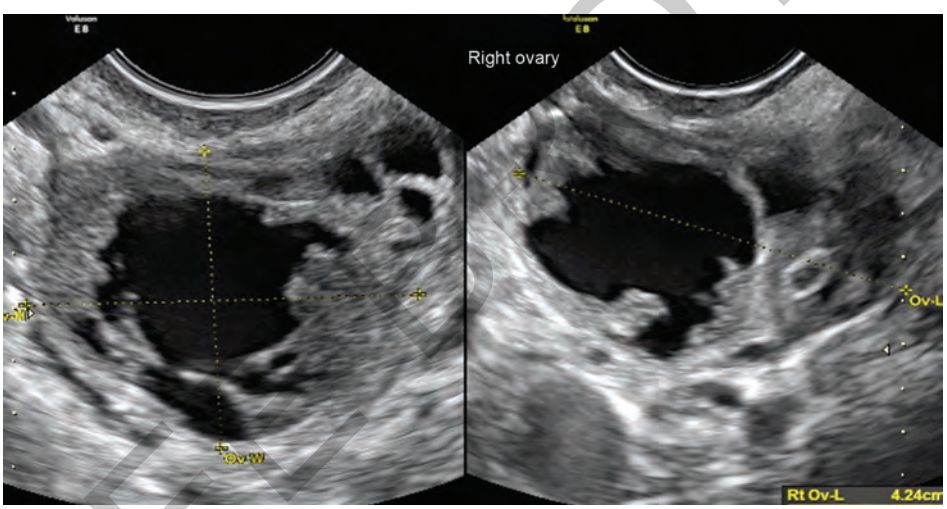

Fig. 15: Corpus luteum with thick, crenulated, or shaggy isoechoic walls.

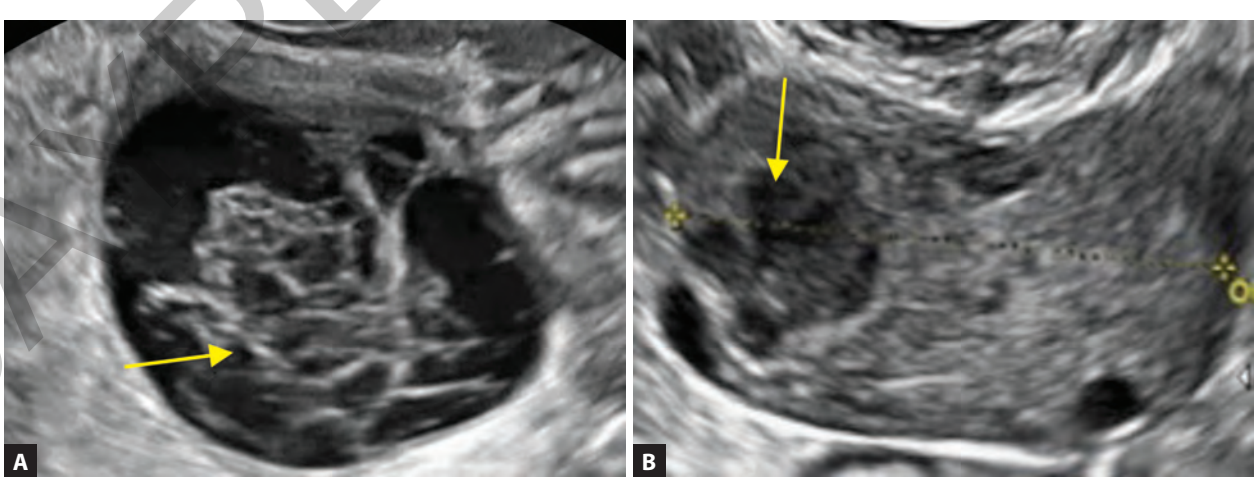

Figs. 16A and B: (A) Corpus luteum with fishnet appearance; (B) Corpus luteum with ground glass appearance as marked by arrows.

JAYPEE BROTHERS

or may even show debris **(Fig. 14B)**. The consistent feature of a healthy corpus luteum is low resistance flow [resistance index (RI) <0.5], with blood flows covering the corpus luteum almost completely **(Fig. 17)**.

When such a lesion is seen in the proliferative phase, the possibility of a hemorrhagic cyst is thought as the first possibility. As the name suggests, it is a cyst containing blood, fresh or degenerated. It is usually a nonresolved hormonally inactive corpus luteum and therefore shows no flow. Lace-like echo pattern **(Fig. 18)** is very typical of a hemorrhagic cyst but may show fibrin strands, ground glass appearance, or debris, similar to corpus luteum. It changes its echogenicity over time due to fibrinolysis of the clot. A hemorrhagic cyst is a physiological cyst and has a tendency to regress and disappear in 4–6 weeks.[5] If such a lesion seen in the early proliferative phase shows scanty or high resistance flow, it is a regressing corpus luteum, and if it is seen in the secretory phase, it is an inadequate/failing corpus luteum.

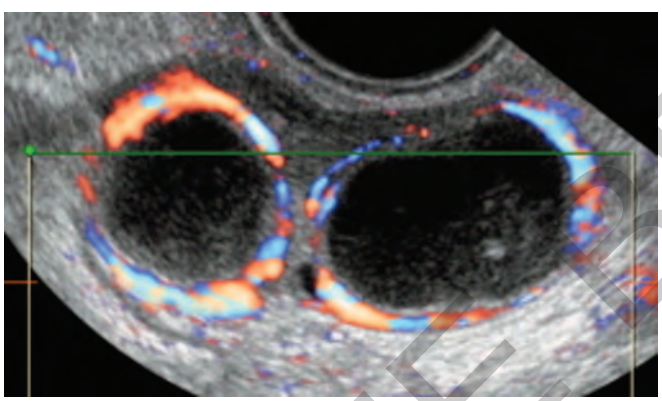

Fig. 17: Two corpus luteum showing ring of color—peripheral vascularity on high definition (HD) flow.

The next intraovarian lesion in the same morphological group is a *luteinized unruptured follicle*. It typically has thick but not shaggy walls. The walls of luteinized unruptured follicles are typically hyperechoic. Being an unruptured follicle, the internal echogenicities are typically not like that of the corpus luteum. There are no fibrin strands or fishnet appearance. It shows low-level echogenicities **(Fig. 19)**. On Doppler, the lesion shows peripheral vascularity with high resistance flow, with RI usually between 0.50 and 0.60.[6]

Endometrioma is ovarian endometriosis. These may be bilateral and are typically tender on probe pressure. Endometriomas may have thick walls, often shaggy. Of course, ground glass is the appearance typically described for endometriomas **(Fig. 20)** and is due to thick chocolate sauce-like contents in the cyst, but interestingly at least 40% of endometriomas may not have a typical appearance. Hyperechoic flecks are typically seen in the walls and are thought to be due to hemosiderin or cholesterol deposits[7] **(Fig. 21)**. Blood clots may appear like solid components at times. The degenerated blood products and fresh bleed from the endometrial lining in the cyst lead to the layering effect **(Fig. 22)**. This results in a vertical fluid level seen on the longitudinal scan, which typically has an echogenic fluid layer posteriorly and an anechoic layer anteriorly.[8] Though this appearance may disappear on the rotation of the probe or may also not be seen on a transabdominal scan.

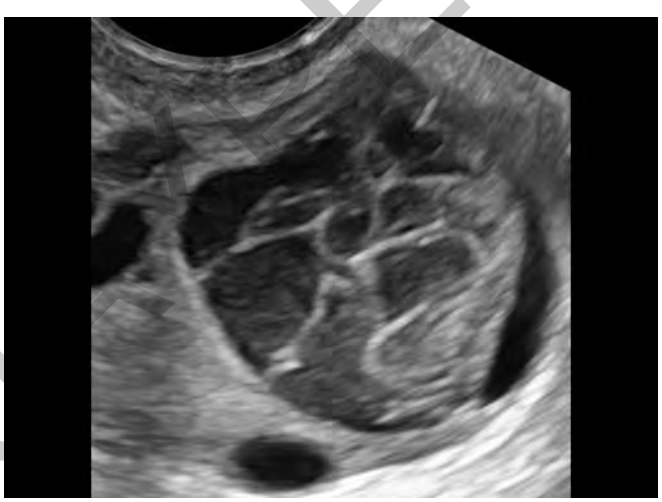

Fig. 18: Lace-like echo pattern of hemorrhagic cyst on B-mode ultrasound.

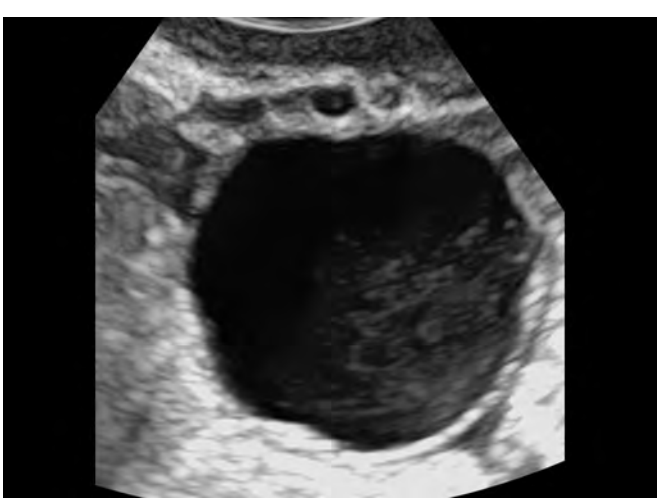

Fig. 19: Luteinized unruptured follicle—low level echogenicities.

JAYPEE BROTHERS

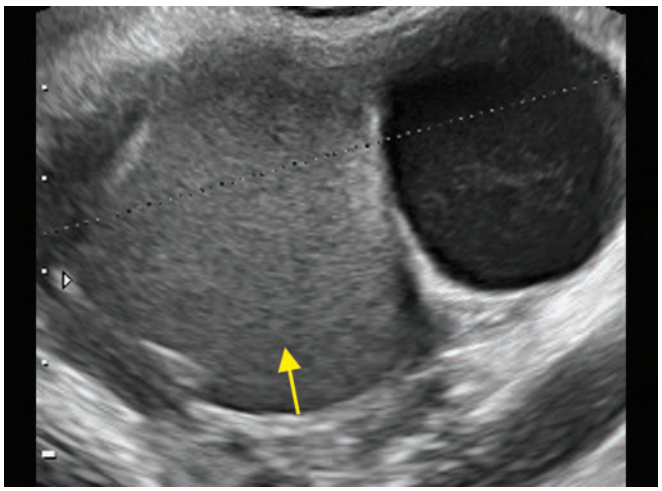

Fig. 20: Endometrioma on B-mode ultrasound with ground glass echogenicities.

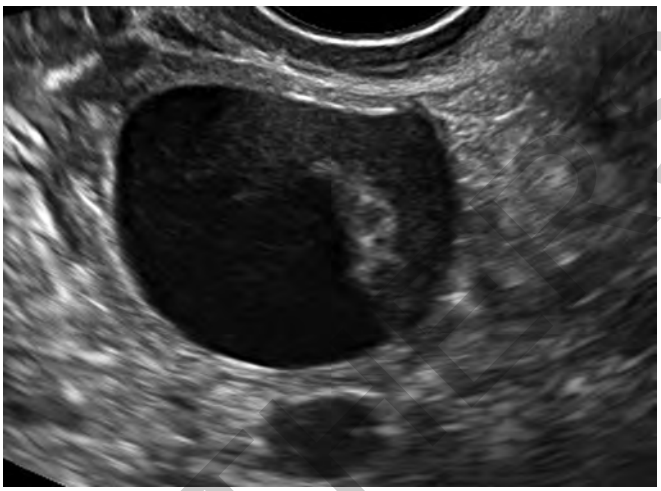

Fig. 22: Endometrioma showing fluid of different echogenicities—layering effect.

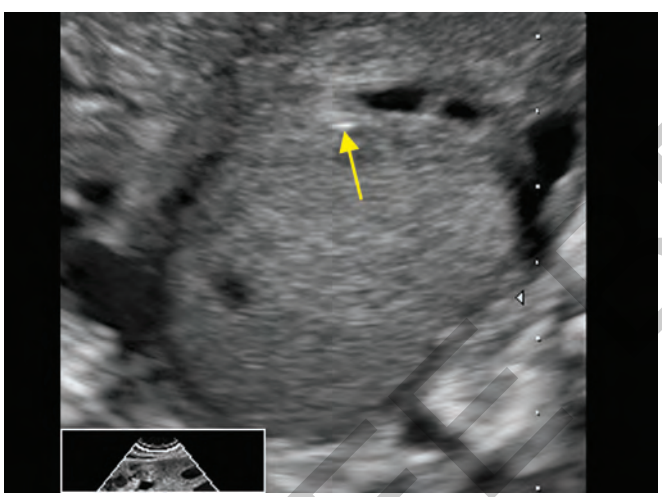

Fig. 21: Endometrioma with ground glass echogenicity and hyperechoic flecks in the wall marked by an arrow.

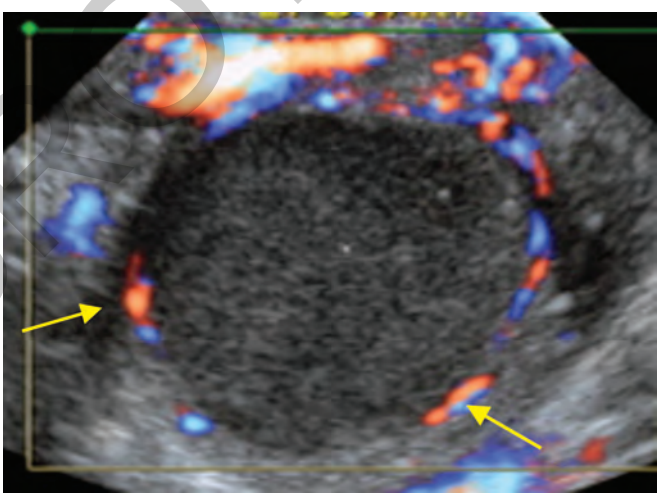

Fig. 23: High definition (HD) flow showing short-coursed vessels as marked by arrows.

Dynamic examination is very important for the diagnosis of endometriomas. As described earlier, probe movement may cause pain, when pressed on the lesion. These lesions are often fixed or adherent to surrounding structures and show negative sliding organ sign. The probe movement in relation to the lesion also leads to movements in the chocolate sauce-like thick fluid content of the endometrioma, leading to an acoustic streaming sign. However, acoustic streaming cannot discriminate reliably between endometriomas and other adnexal lesions.[9] Scattered vascularity at ovarian hilus with moderate vascular impedance has been described in endometriomas. The ovarian hilar RI varies between 0.40 and 0.56. It is higher during menstruation and in symptomatic patients.[10]

Avascular lesions indicate scarification and are less convenient for the delivery of medication and therefore should be considered for surgical therapy.[11] Kurjak et al. have shown a sensitivity of 83.9%, specificity of 97.1%, positive predictive value (PPV) 82%, and negative predictive value (NPV) 97.5% of vaginal sonography for characterization of endometriomas. If CA125 >35 IU/mL was added as a cutoff to these parameters, the sensitivity and specificity reached 99.04% and 99.64% and PPV and NPV reached 98.10% and 99.82%, respectively.[11] Similar results were also confirmed by several other workers.

Endometriomas typically show short-coursed vessels. The vessels are seen approaching the lesion wall, but do not run long with the wall **(Fig. 23)**. These vessels

JAYPEE BROTHERS

show variable resistance depending on the phase of the menstrual cycle. These vessels show low resistance vascularity (RI 0.4) in the menstrual period but is high (RI 0.4–0.56) in the preovulatory and secretory periods. The more vascular the lesion is, the better the response to the medical line of treatment. 3D power Doppler (PD) shows a well-perfused lesion with regularly placed vessels with a short course, with minimal variability in diameter. This gives a "bird's nest" appearance[12] **(Fig. 24)**.

When a patient with endometrioma gets pregnancy, there is a possibility that the endometrial lining in the cyst also undergoes decidualization and in that case, the endometrial lining may get thickened and may also show solid projections. These projections show marked vascularity and may mimic malignancy.

Ovarian ectopic though rare may present as similar lesions. This is a roundish mass with thick walls and a gestational sac seen as an anechoic center. If it shows the presence of yolk sac and/or fetal pole, it is easy to diagnose. When these are not seen, it appears very similar to the corpus luteum both on B mode and also on Doppler due to its ring of vascularity with low resistance. It is the hypoechogenicity of the lesion walls, due to decidual reaction **(Fig. 25)**, along with the history of missed periods and positive urine pregnancy test or high serum beta-human chorionic gonadotropin (hCG) levels that may be indicative. Tenderness on probe pressure, minimal free fluid, and spotting or fainting attacks may be additional supportive signs. Indirect signs of ectopic pregnancy may be seen in the uterus as a thickened endometrium with decidual reaction at times, but typically showing symmetrical thickness of endometrial leaves **(Fig. 26)**. In an intrauterine pregnancy, the endometrial leaves have asymmetrical thickness. Apart from diagnosis, Doppler plays an important role in the conservative or medical line of management and follow-up in cases of ectopic pregnancy.

Apart from these lesions, ovaries and adnexa may present with inflammatory lesions and neoplasms. Ovaries are also likely to undergo hyperstimulation and torsion or rarely torsion of the fallopian tube is also known.

The inflammatory lesions in the ovaries and adnexa may be acute or chronic.

Acute inflammation of the ovary acute oophoritis is almost always a consequence of acutely inflamed fallopian tube, acute salpingitis, and/or pelvic inflammatory disease (PID). PID usually presents as free fluid in the pelvis that is usually anechoic but in the presence of

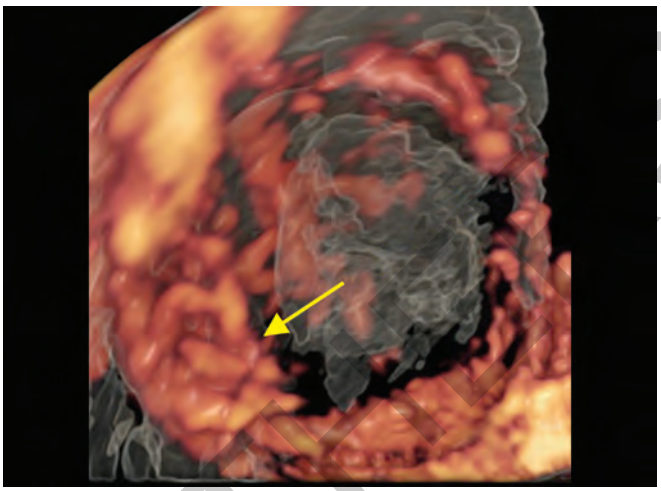

Fig. 24: 3D power Doppler image of endometrioma showing crisscrossing of the vessels—Bird's nest appearance.

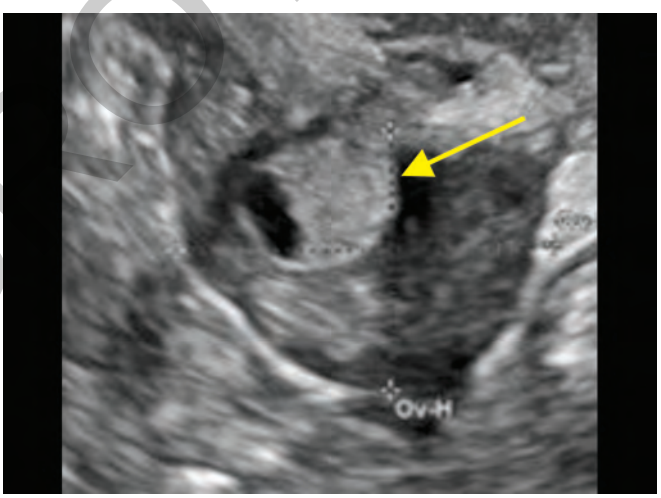

Fig. 25: B-mode ultrasound image of the ovary with ovarian ectopic pregnancy.

fulminant infection and pus formation, it may show low-level echogenicities **(Fig. 27)**. In case of this being blood, the low-level echogenicities in the fluid may also be seen with thin linear freely mobile echogenicities due to fibrin bands **(Fig. 28)**. Though it is very important to mention here that some amount of free fluid in the pelvis is normal in periovulatory period of the menstrual cycle, which may be due to high estrogen levels or fresh rupture of the follicle. The fluid then may persist till the late luteal phase. Retrograde menstruation may also show fluid in the pelvis during the early proliferative phase.

Acute PID may present with systemic signs of inflammation and also with pain on probe pressure at the site of primary inflammation that may be the ovary

JAYPEE BROTHERS

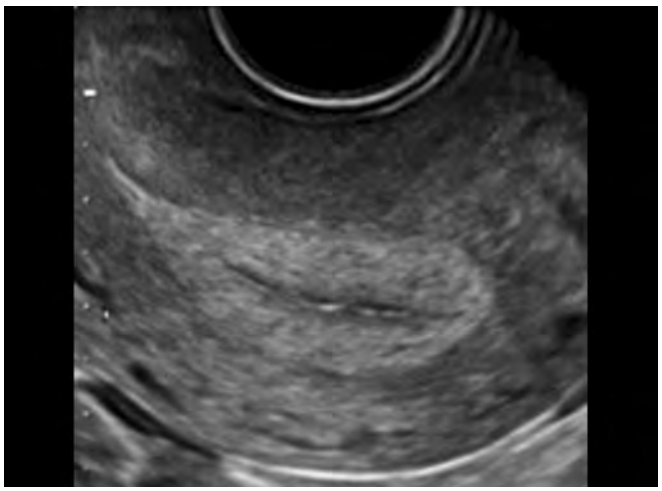

Fig. 26: B-mode image of the uterus showing hyperechoic secretory endometrium with symmetrical leaves of endometrium.

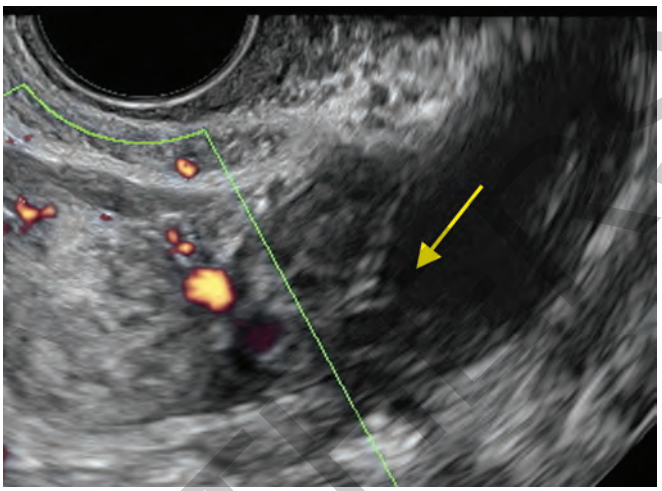

Fig. 28: Free fluid with low level echogenicities and also thin linear echogenicities—fibrin strands suggesting blood in pelvis.

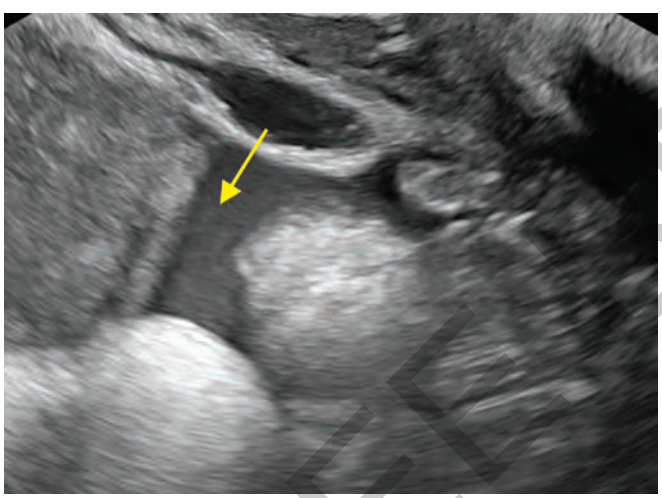

Fig. 27: Free fluid with low level echogenicities suggestive of thick fluid may be pus.



Fig. 29: B-mode ultrasound showing adnexal soft tissue band on transverse section.

or the tube. Acute salpingitis, though is not always easy to diagnose, and close observation of the adnexal soft tissue band extending from the uterus to the ovary may aid in the diagnosis of the same **(Fig. 29)**. Thickening of this band to >10 mm, when measured perpendicular to its long axis, may be the clue. This is due to the thickening of the tubal walls in acute inflammation. Thickened tubes can also be documented when there is free fluid around. This soft tissue band normally consists of tubes, vessels, and ligaments, and therefore normally shows vessels, running parallel to its long axis on color Doppler. In case of inflammation, color Doppler will show small vessels in a direction, not parallel to the long axis of the adnexal soft tissue band **(Figs. 30A and B)**. These vessels typically show RI <0.5 due to inflammatory neoangiogenesis.

Acute oophoritis leads to mild enlargement of the ovary due to edema, but this is difficult to document if the ovary was not measured earlier, or may also be because the size of the ovary changes in the different phases of the cycle due to the development of follicles or corpus luteum or their regression. Though more reliable ultrasound sign may be hypoechoic ovarian stroma (in relation to normal myometrium) due to severe edema and follicles may be pushed to the periphery **(Fig. 31)**. On color Doppler, the stroma shows abundant vascularity with low resistance flow (RI <0.5) **(Fig. 32)**. This can be differentiated from

JAYPEE BROTHERS

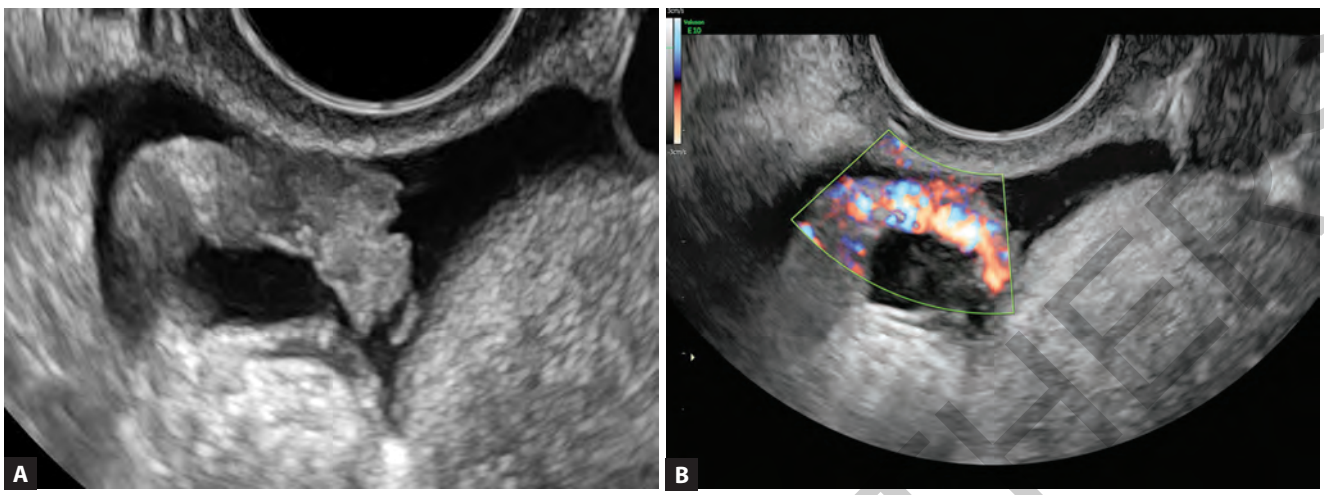

Figs. 30A and B: (A) B-mode ultrasound image showing free fluid in pelvis with thickened fallopian tube suggestive of acute salpingitis; (B) High definition (HD) Doppler showing marked vascularity with blood vessels oriented perpendicular to its long axis.

polycystic ovaries where the ovarian stroma shows abundant vascularity, by the fact that patients with polycystic ovaries, typically show hyperechoic stroma.

Inflammation of the tube and marked thickening of the tubal walls may lead to tubal obstruction and collection of the tubal secretions in the tubal lumen, leading to hydrosalpinx. Hydrosalpinx may also be a result of the involvement of the tubal fimbria in the inflammatory process and formation of adhesions. Hydrosalpinx may present differently on B-mode ultrasound, depending on its severity and acute or chronic nature. Especially in acute inflammations, it may have thick walls that may be appreciated on the long axis as tubular lesions with anechoic fluid content and thick irregular walls due to thickened haustra **(Fig. 33)**. On the transverse section, this gives a "cogwheel" appearance as the thickened haustra then appear like papillarities **(Fig. 34)**. On color Doppler, the walls show low resistance vascularity (RI <0.5) **(Fig. 35)**. With marked distention of the tubes due to hydrosalpinx, the tubes on the transverse section may appear like an extraovarian cystic lesion, which may need to be differentiated from paraovarian cyst. On rotation of the probe, this leads to a change in the shape of the lesion. It may show a beak-like projection or may elongate to make a sausage-shaped lesion. This is typical of a hydrosalpinx **(Fig. 36)**. Another typical ultrasound sign of hydrosalpinx is incomplete septum **(Fig. 37)**. Though the latter two features may be seen in the bowel loop. It is peristalsis seen in the bowel loop that can be used as a differentiating sign. The iliac vessels are large comparatively and are also seen

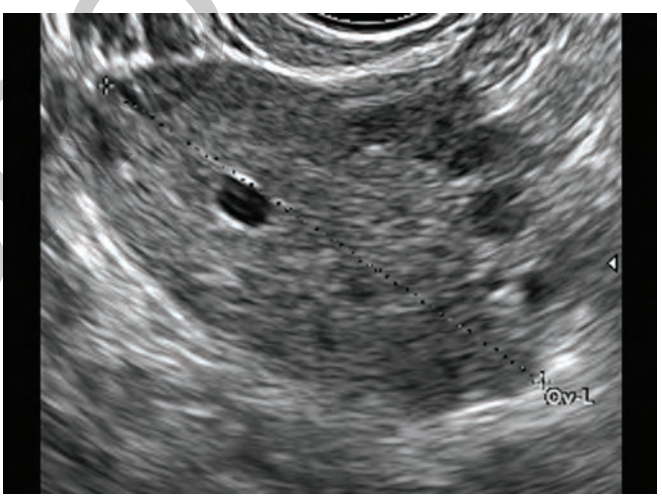

Fig. 31: B-mode ultrasound image with hypoechoic ovarian stroma.

as round structures on the transverse section and elongate on the rotation of the probe **(Fig. 38)**. Doppler is the modality to differentiate the two. Though it is important to remember that with large hydrosalpinx, due to movement of the fluid in it sometimes, Doppler may show color and care must be taken not to misinterpret this as a vessel. Acute salpingitis is often associated with ascites.

Inflammations, involving both fallopian tube and ovary, may lead to adhesion of the two and formation of tubo-ovarian mass **(Fig. 39)**. The ovary and the tube may be identified separately but cannot be separated from each other. Whereas, at times the inflammation may be more severe and the tubal and ovarian margins cannot be

JAYPEE BROTHERS

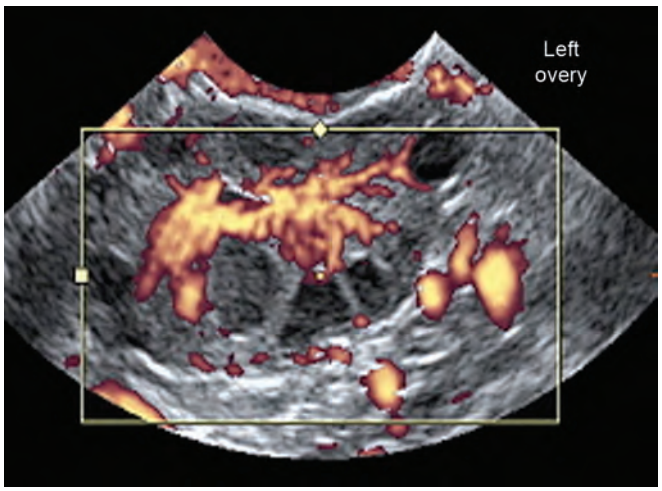

Fig. 32: Power Doppler showing hypervascularity in this ovary.



Fig. 34: Transverse section of hydrosalpinx—cogwheel appearance.

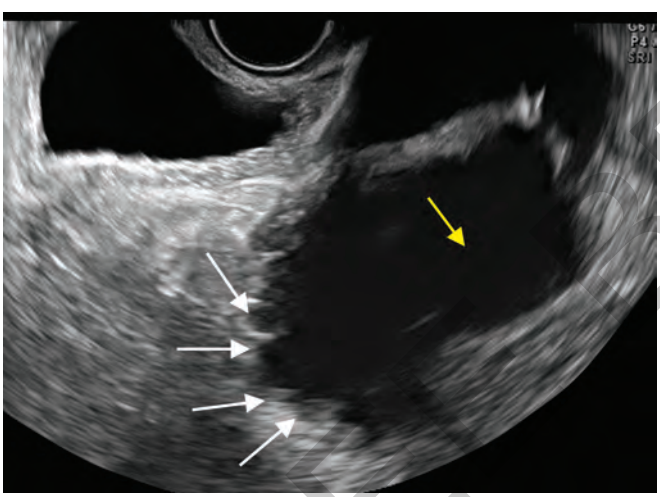

Fig. 33: Cystic lesion (hydrosalpinx) shown by the arrow with irregular margins as marked by white arrows due to thickened haustra.

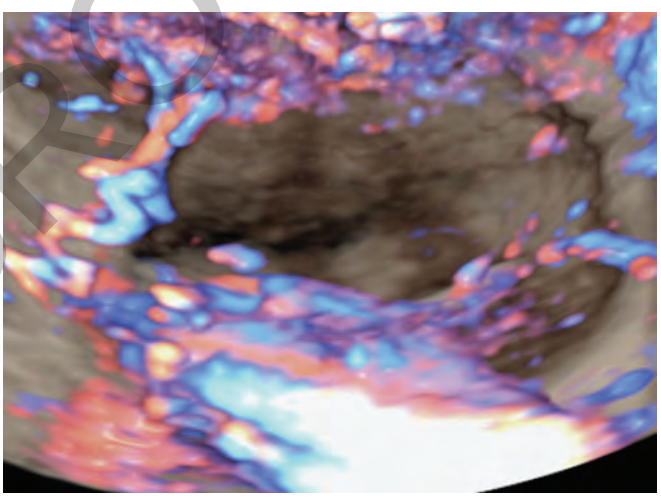

Fig. 35: 3D power Doppler with high definition (HD) flow showing hypervascularity in an acute hydrosalpinx.

identified. There is disruption of the normal anatomical structure of both and this is a tubo-ovarian abscess **(Fig. 40)**. Tubo-ovarian abscess is a complex mass with cystic and solid components with variable degrees of vascularity seen on color Doppler or PD. The resistance of these vessels may be variable, depending on whether these are pre-existing vessels or neoangiogenesis of inflammation and also depending on whether the inflammation is acute or chronic. Chronic inflammations are more commonly associated with adhesions and therefore it is important to establish the mobility of the uterus, ovaries, and bowel in each case.

When endometrioma is present in the ovary or there is evidence of endometriosis, the hydrosalpinx may be suspected due to the extension of endometriosis. Hydrosalpinx is considered a soft marker of endometriosis.[13] And hydrosalpinx may also be due to adhesions as a result of previous surgeries.

Ovarian hyperstimulation is a commonly found condition in today's era of assisted reproductive techniques (ARTs). Usually, it is a result of high doses of gonadotropins used for ovulation induction, but rarely it is also seen as a result of hyper-response to clomiphene citrate stimulation. The development of multiple follicles,

JAYPEE BROTHERS

or detailed information on obstetrics & gynecology books, visit our website **www.jaypeebrothers.com,** for detailed information on obstetrics & gynecology books, visit our website

Color Doppler in Obstetrics & Gynecology
Text and Atlas

This book "Color Doppler in Obstetrics and Gynecology: Text and Atlas" is specifically designed for obstetricians and gynecologists, who are practicing ultrasound also. In fact, ultrasound is an inevitable modality for obstetricians and gynecologists and Doppler is a valuable addition to it, for obstetric, gynec and infertility. But it has been observed that this technology is not fully exploited because of inadequate know-how of the subject. A simple explanation and presentation of Doppler technology and findings therefore can be of great help to the obstetricians and gynecologists to use Doppler at its best and arrive to correct diagnosis. And all efforts have been made therefore to include all the common pathologies of obstetrics and gynecology in this book, for the diagnosis of which Doppler can make a difference. Presenting for all my friends "a ready reckoner and handbook" of color Doppler.

Sonal Panchal MD PhD is an Ultrasound Consultant at Dr Nagori's Institute for Infertility and IVF, Ahmedabad, Gujarat, India. She is a versatile ultrasound specialist dedicated to the subject for more than twenty years. She has a high reputation for innovative thinking and insight into obstetric, gynecological and infertility related ultrasound. She has been one of the pioneers for the use of Doppler and 3D 4D ultrasound in this field. She is a popular teacher in the field in India and abroad and is known for her to the point presentations with crystal clear science-based explanations. She is the National Academic director for the Indian branch of the Ian Donald Interuniversity School of Medical Ultrasound. She is awarded a "Professor" Dubrovnik International University, Croatia. She has authored and contributed in several books including her most popular title "Ultrasound in Infertility and Gynecology" published by Jaypee Brothers Medical Publishers.

Chaitanya Nagori MD DGO is the Director of Dr Nagori's Institute for Infertility and IVF, Ahmedabad, Gujarat, India. He is a successful infertility consultant for more than 25 years and is known for a very high success rate in his practice and for his pioneering work in the application of Doppler in Infertility monitoring. He is a core academician and a teacher of high repute. He is a synonym for to-the-point teaching, with crisp and clear concepts. He is a contributor and author of several books and had several research publications, one of the most popular ones being "Handbook of Infertility and Ultrasound for Practicing Gynecologist" published by Jaypee Brothers Medical Publishers.

Printed in India

Available at all medical bookstores or buy online at www.jaypeebrothers.com

JAYPEE BROTHERS
Medical Publishers (P) Ltd.
EMCA House, 23/23-B, Ansari Road,
Daryaganj, New Delhi - 110 002, INDIA
www.jaypeebrothers.com

Join us on facebook.com/JaypeeMedicalPublishers

Shelving Recommendation
OBSTETRICS & GYNECOLOGY

ISBN 978-93-5696-960-5