hers.com, for detailed information on pathology books, visit our website www.jaypeebrothers.com, for detailed information on pathology books

3rd Edition



Access Whole Slide Imaging as Digital Slides Details Inside

# Fine Needle Aspiration Cytology

## Interpretation and Diagnostic Difficulties

Pranab Dey

JAYPEE

# Contents


**Chapter 1 Introduction and Basic Techniques of Fine Needle Aspiration Cytology 1**

- **History of Fine Needle Aspiration Cytology 1**
- **Advantages 1**
- **Limitations 2**
- **Complications 2**
  Needle Tract Seeding 2
- **Contraindications 3**
- **Equipment 3**
- **Fine Needle Aspiration Cytology Clinic 4**
- **Fine Needle Aspiration Technique 4**
  Smear Preparation 6
  Labeling 7
- **Post-fine Needle Aspiration Cytology Care 7**
- **Operator of Fine Needle Aspiration Cytology: Who should Do it? 8**
- **Staining of the Smear 8**
  Staining 8
  Cellblock 10
  Liquid-based Cytology 10
  Ancillary Techniques 10
  Suboptimal Material 10
- **Laboratory Safety 11**
  Universal Precautions 11
- **Waste Disposal in the FNAC Clinic 11**
- **Quality Control in Fine Needle Aspiration Cytology Laboratory 12**
  Internal Quality Control 12
  External Quality Assurance 12

**Chapter 2 Fine Needle Aspiration Cytology of Deep-seated Lesions 14**

Fluoroscopy-guided FNAC 15
USG Guidance 15
Computed Tomographic Scan-guided FNAC 16
Endoscopic Ultrasound-guided FNAC 17

- **Ancillary Techniques on EUS-FNAC 18**
  Advanced EUS-FNAC 18
  Magnetic Resonance Imaging Guidance 18
- **Mammographically-guided FNAC 18**
- **Complications of Guided FNAC in Deep-seated Lesions 19**
  Transrectal FNAC of the Prostate 19

**Chapter 3 Evaluation of Aspiration Cytology Smears 21**

- **Evaluation of Fine Needle Aspiration Cytology Smear 21**
  Cellularity 21
  Cell Arrangement 21
  Single Cells 21
  Clusters 22
  Sheet 22
  Follicular Pattern 22
  Glandular Arrangement 22
  Rosettes 23
  Papillary Clusters 23
  Other Patterns 24
- **Cell Morphology 24**
- **Cytoplasm 25**

- **Nucleus 28**
  Nuclear Pleomorphism 28
  Nucleoli 28
  Nuclear Margin 28
  Chromatin Pattern 29
  Intranuclear Inclusion 29
  Mitosis 29
- **Background of the Smear 30**
  Final Reporting 32
- **Diagnostic Difficulties 32**
- **Medicolegal Aspects 35**
- **What to Do in Legal Case? 36**

**Chapter 4 Ancillary Techniques in Aspiration Cytology 37**

- **Immunocytochemistry 37**
  Advantages of Cytology Materials for Immunocytochemistry 37
  Samples for Immunocytochemistry 37
  Different Cell-specific Markers 38
  Practical Diagnostic Problems 43
  Receptors for Therapy 45
  Antibodies Directed to Anti-infective Agent 45
- **Flow Cytometry 46**
  Applications 46
  Molecular Genetics 47
- **Fluorescent in situ Hybridization 47**
  Principle 47
  Advantages of Fluorescent in situ Hybridization 47
  Limitations of Fluorescent in situ Hybridization 48
  Applications 48
  Types of Fluorescent in situ Hybridization 48
- **Polymerase Chain Reaction 48**
  Applications 49
- **Next-generation Sequencing 49**
  Advantages 49
  Types 49
  Limitations 50
  Applications of Next-generation Sequencing 50
- **Electron Microscopy 50**
  Applications 50

**Chapter 5 Head, Neck, and Orbital Lesion 53**

- **Cystic Lesions of Head and Neck Regions 53**
  Branchial Cyst 53
  Thyroglossal Cysts 55
  Epidermal Inclusion Cyst 55
  Cystic Hygroma 56
  Mucocele 56
  Lymphadenopathy 56
  Paravertebral Lesion 57
  Base of the Skull 57
  Paraganglioma 57
  Nasopharyngeal Carcinoma 60
  Ameloblastoma 61
  Parathyroid Tumors 63
  Interpretation and Diagnostic Problems 63
  Meningioma 64
  Olfactory Neuroblastoma 64
- **Orbital Lesions 66**
  Techniques 66
  Complications 67
  Eyelid Lesion 67
  Malignant Neoplasm of Eyelid 67
  Lesions of Lacrimal Gland 68
- **Intraorbital Tumors 69**
  Retinoblastoma 69
  Rhabdomyosarcoma 70
  Malignant Melanoma 71
  Lymphoma 71
  Optic Glioma 72
  Metastatic Malignancy 72

**Chapter 6 Salivary Gland 75**

- **Indications of FNAC of the Salivary Glands 75**
- **Contraindications of Salivary Gland FNAC 75**

- **Complications of Salivary Gland FNAC 76**
- **Anatomy and Histology of the Salivary Gland 76**
  Parotid glands 76
  Submandibular Salivary Gland 76
  Sublingual Gland 76
- **Histology 77**
- **Normal Salivary Gland Cells 77**
- **FNAC of Salivary Gland: Technical Consideration 78**
- **Clinical Consideration 78**
- **Diagnostic Accuracy 79**
- **Overview of the Diagnostic Challenges 80**
- **Salivary Gland Lesions 85**
  Non-neoplastic Conditions 85
  Neoplastic Lesions 90
- **Benign Neoplasm 90**
  Pleomorphic Adenoma 90
  Warthin's Tumor 96
  Basal Cell Adenoma 99
  Oncocytoma 100
  Myoepithelial Tumors 102
- **Malignant Neoplasm 103**
  Adenoid Cystic Carcinoma 103
  Acinic Cell Carcinoma 105
  Mucoepidermoid Carcinoma 108
  Polymorphous Adenocarcinoma 111
  Epithelial–myoepithelial Carcinoma 112
  Carcinoma ex Pleomorphic Adenoma 114
  Myoepithelial Carcinoma 114
  Salivary Duct Carcinoma 114
- **Adenocarcinoma not otherwise Specified 114**
- **Lymphoma of the Salivary Gland 115**
- **Other Recently Described Salivary Gland Tumors 116**
  Mammary Analog Secretory Carcinoma 116
  Sclerosing Polycystic Adenoma 118
  Cribriform Adenocarcinoma of Minor Salivary Glands 118
- **Metastatic Carcinoma 118**
- **Approach to Salivary Gland Lesions 118**

**Chapter 7 Thyroid 123**

- **Evaluation of Clinical History and Other Investigations before FNAC 123**
  Clinical History and Physical Examination 123
  Physical Examination 124
  Other Investigations 124
  Thyroid Imaging, Reporting and Data System 124
- **Techniques 124**
  Fine-needle Aspiration Cytology-induced Artifact 126
  Ultrasound-guided Fine-needle Aspiration Cytology 126
  Complications 126
  Optimal Material 127
  Diagnostic Accuracy 127
  Anatomy and Histology 128
  Approach to the Analysis of FNAC Smear of Thyroid 128
  Microscopic Examination 128
  Terminology 132
- **Diseases of Thyroid 132**
- **Non-neoplastic Lesions 133**
  Follicular Nodular Disease (Colloid goiter) 133
  Diffuse Toxic Goiter (Graves' Disease) 135
- **Thyroiditis 136**
  Acute Thyroiditis 136
  Granulomatous Thyroiditis 136
  Chronic Lymphocytic Thyroiditis (Hashimoto's Thyroiditis) 137
  Riedel's Thyroiditis 140

- **Neoplastic Lesions 141**
  Follicular Neoplasm 141
- **Variants of Follicular Adenoma 144**
  Oncocytic Neoplasm 144
  Hyalinizing Trabecular Adenoma 147
  Papillary Thyroid Carcinoma 147
  Medullary Carcinoma 155
  Anaplastic Carcinoma 159
  Poorly Differentiated Carcinoma 161
- **Lymphomas 163**
  Metastatic Malignant Tumors 163
  Rare Tumor of Thyroid 165
- **Ancillary Techniques 166**
  Different Ancillary Tests in Thyroid 167
  Molecular Tests in Thyroid 167
- **Management of Post-FNAC Diagnosis of Thyroid Lesion 168**

**Chapter 8 Breast 174**

- **Indications of FNAC of Breast 174**
  Indications for Image-guided FNAC of Breast 175
  Contraindications and Complications 175
- **Diagnostic Accuracy 175**
- **Limitations of Fine Needle Aspiration Cytology 175**
- **Diagnostic Pitfalls 176**
  False-negative Diagnosis 176
- **False-positive Diagnosis 177**
  Clinical History 177
  Triple Test 178
  Core Needle Biopsy versus FNAC 178
  Mammography 179
  Adequacy of the Sample 179
  Histology of Breast 180
  Normal Cytology of Breast 180
  Approach to FNAC of Breast Lesions 181
  Reporting of Breast FNAC 182
  Yokohama System for Reporting Fine Needle Aspiration Cytology of the Breast 184
  World Health Organization Classification of Breast Lesions 184
- **Benign Lesions of Breast 184**
  Mastitis 184
  Granulomatous Mastitis 186
  Cytology 186
  Interpretation and Diagnostic Problems 186
  Idiopathic Granulomatous Mastitis 186
  Chronic Subareolar Abscess 186
  Silicone Mastitis 187
  Fat Necrosis 187
  Radiation-induced Changes 188
  Collagenous Spherulosis 188
  Lipoma 189
  Galactocele 189
  Lactating Adenoma and Lactational Breast 189
  Mucocele of Breast 190
  Pseudoangiomatous Stromal Hyperplasia 190
  Fibroadenoma 190
  Fibrocystic Diseases 193
  Proliferative Breast Disease 194
  Proliferative Breast Disease with Atypia 195
- **Malignant Lesions of Breast 198**
  Ductal Carcinoma in situ 198
  Phyllodes Tumor 200
  Interpretation and Diagnostic Problems 202
  Interpretation and Diagnostic Problems 203
  Carcinoma of Breast 204
  Infiltrating Duct Carcinoma 204
  Medullary Carcinoma 207
  Mucinous Carcinoma (Colloid Carcinoma) 208
  Apocrine Carcinoma 210

Tubular Carcinoma 211
Metaplastic Carcinoma 212
Invasive Lobular Carcinoma 212
Paget's Disease 214
Inflammatory Carcinoma 214
- **Other Uncommon Malignancies 215**

Adenoid Cystic Carcinoma of Breast 215
Signet Ring Carcinoma 215
Squamous Cell Carcinoma of Breast 216
Non-Hodgkin's Lymphoma 217
Sarcoma of Breast 218
Accessory Breast 218
Male Breast Lesions 218
Carcinoma in Male Breast 219
- **Ancillary Investigations on Breast Aspiration Material 219**

Hormone Receptor Status 219
Molecular Classification of Breast Carcinoma 221
Nipple Discharge 221

**Chapter 9 Lymph Node 229**
- **Contraindication 230**
- **Complications 230**
- **Limitations 230**
- **Approach to Lymph Node Fine-needle Aspiration Cytology 230**

Clinical History 230
Physical Findings 230
Techniques 231
Diagnostic Accuracy 231
Ancillary Tests in Lymph Node 232
Genetic Abnormalities 233
- **Normal Anatomy and Histology of the Lymph Node 235**

Lymphoid Cells 235
Normal Component of a Lymph Node 237
Reactive Lymphoid Hyperplasia 237
Acute Lymphadenitis 239
Granulomatous Lymphadenitis 239
Tuberculosis 239
Sarcoidosis 242
Lepromatous Lymphadenitis 243
Leishmania Lymphadenitis 243
Filarial Lymphadenitis 244
Toxoplasma Lymphadenitis 245
Cat Scratch Disease 245
Infectious Mononucleosis 246
Rosai–Dorfman Disease 246
Kimura's Disease 248
Kikuchi's Disease 248
HIV Lymphadenopathy 249
Kaposi's Sarcoma 250
Post-transplant Lymphoproliferative Disorders 250
Dermatopathic Lymphadenitis 251
Interpretation and Diagnostic Problems 251
Castleman's Disease 251
Metastatic Malignancy 252
Others 255
Lymphomas 256
Reporting Lymph Nodal Neoplasm 257
Sydney System of Reporting Fine Needle Aspiration Cytology of the Lymph Node 257
Lymphoma Classification 258
B-cell Small Lymphocytic Lymphoma 259
Mantle Cell Lymphoma 261
Follicular Lymphoma 262
Lymphoplasmacytic Lymphoma 265
Marginal Zone Lymphoma 267
Hairy Cell Leukemia 267
Approach to Small B Cell Lymphomas 268
- **Lymphomas of Large Cells 269**

Diffuse Large B Cell Lymphoma 269
Immunophenotype of DLBCL 271
Mediastinal Large B Cell Lymphoma 271

Burkitt's Lymphoma 273
T Cell Lymphoma 275
T Lymphoblastic Lymphoma 275
Anaplastic Large Cell Lymphoma 275
Peripheral T Cell Lymphoma, Unspecified 276
Angioimmunoblastic T Cell Lymphoma 277
Mycosis Fungoides and Sezary Syndrome 278
Hodgkin's Lymphoma 279
Nodular Lymphocytic Predominant Hodgkin's Lymphoma 282
Histiocytic and Dendritic Neoplasms 283
Langerhans' Cell Histiocytosis 284
Interpretation and Diagnostic Difficulties 285
Leukemic Infiltration 285

**Chapter 10 Lung 293**

- **Techniques 293**
- **Contraindications 294**
- **Complications 294**
- **Diagnostic Accuracy and Pitfalls 295**
  Ancillary Tests 298
  Immunocytochemistry 298
  Molecular Genetics 298
- **Normal Anatomy and Histology of Lungs 299**
  Normal and Benign Cells 300
- **Lung Lesions 302**
  Inflammatory Lesions 302
  Specific Infections 302
  Fungal Infections 304
  Parasite 309
- **Benign Noninfective Condition of Lung 309**
  Pulmonary Hamartoma 309
  Endobronchial Papilloma 310
  Myofibroblastic Tumor 310
  Pulmonary Amyloidosis 310
  Wegner's Granulomatosis 311
- **Lung Carcinomas 311**
  World Health Organization Reporting System of Lung Cytopathology 312
  Classification of Lung Cancer 312
  Small Diagnostic Samples 313
  Important Recommendations of World Health Organization 2022 313
  Terminology for Small Biopsy and Cytology 313
  Molecular Pathology of Lung Adenocarcinoma 313
  Squamous Cell Carcinoma 315
  Adenocarcinoma 318
  Adenocarcinoma with Lepidic Growth Pattern 320
  Small Cell Carcinoma 322
  Undifferentiated Large Cell Carcinoma 324
  Carcinoid 326
- **Rare and Uncommon Tumors of Lung 328**
  Adenoid Cystic Carcinoma 328
  Mucoepidermoid Carcinoma 328
  Pleuropulmonary Blastoma 328
  Sarcoma 329
  Lymphomas 330
- **Metastatic Malignancies 330**
  Mesothelioma in Pleura 331

**Chapter 11 Mediastinum 338**

- **Anatomy of the Mediastinum and General Considerations 338**
- **Clinical History 338**
- **Radiological Localization 338**
- **Techniques 339**
- **Contraindication 339**
- **Complications 339**
- **Lesions 339**
  Mediastinal Cystic Lesions 339
  Thymoma 340
  New in World Health Organization 2021 Classification of Thymoma 341
  Thymic Carcinoma 345

Thymic Carcinoid 346
Atypical Carcinoid 346
- **Germ Cell Tumors 347**
Mature Cystic Teratoma 347
Immature Teratoma 347
Germinomas 347
Embryonal Carcinoma 348
Yolk Sac Tumor 348
- **Lymphomas 349**
Non-Hodgkin's Lymphoma 349
Large Cell Non-Hodgkin's Lymphoma 349
Lymphoblastic Lymphoma 349
Anaplastic Large Cell Lymphomas 350
Hodgkin's Lymphoma 350
Neurogenic Tumor 351
Neuroblastoma 351
Ganglioneuroblastoma 352
Peripheral Nerve Sheath Tumor 352
Malignant Peripheral Nerve Sheath Tumors 352
Paraganglioma 353
Metastatic Carcinoma 353
- **Approach to the Diagnosis of Mediastinal Tumors 353**

**Chapter 12 Liver and Spleen 358**
- **Imaging and Technical Consideration 358**
- **Complications 358**
- **Contraindications 359**
- **Diagnostic Accuracy 359**
- **Normal Anatomy and Histology 359**
Histology 359
Normal Cells 360
- **Liver Lesions 361**
- **Non-neoplastic Lesions 361**
Diffuse Parenchymal Lesions of Liver 361
- **Space-occupying Benign Lesions 362**
Cysts 362
Granulomatous Reaction in Liver 363
Cavernous Hemangioma of Liver 364
- **Benign Lesion 364**
Focal Nodular Hyperplasia 364
Liver Cell Adenomas 364
Biliary Cystadenoma 365
Hepatic Angiomyolipoma 365
Mesenchymal Hamartoma of Liver 366
- **Malignant Tumor 366**
Hepatocellular Carcinoma 366
Intrahepatic Cholangiocarcinoma 374
Hepatoblastoma 374
- **Primary Sarcomas 376**
Angiosarcoma 376
Epithelioid Hemangioendothelioma 377
Undifferentiated Sarcoma (Embryonal Sarcoma) of Liver 377
Metastatic Malignancies 378
Malignant Lymphoma 380
- **Normal Cytology 381**
- **Non-neoplastic Process 381**
Granulomatous Infection 381
- **Accumulation of Abnormal Material and Storage Disease 382**
- **Neoplasm 382**
Lymphoma 382
Sarcomas 382
Metastatic Tumor 382

**Chapter 13 Pancreas, Gallbladder, and Gastrointestinal Tract 385**
- **Pancreas: FNAC Procedure 385**
Techniques 385
Complications and Contraindications 386
Diagnostic Accuracy 386
Normal Anatomy and Histology 386

Normal Cells 387
Cysts of Pancreas 387
Cytology 387
Pancreatic True Cyst 388
- **Pancreatitis 388**
Acute Pancreatitis 388
Chronic Pancreatitis 388
Neoplastic Lesion of Pancreas 389
Papanicolaou Society of Cytopathology Reporting of Pancreatobiliary System 389
Serous Cystadenoma 390
Mucinous Cystic Neoplasia 390
Ductal Adenocarcinoma 392
Adenosquamous Carcinoma 395
Signet Ring Carcinoma 395
Pancreatic Acinar Carcinoma 395
Pancreatic Neuroendocrine Neoplasms 396
Pancreatic Endocrine Tumor 397
Neuroendocrine Carcinoma 399
Solid and Cystic Papillary Neoplasm of Pancreas 399
- **Pancreatoblastoma 401**
Metastatic Tumor in Pancreas 402
Pancreatic Lymphoma 402
- **Gastrointestinal Tumors 402**
Adenocarcinoma 402
Signet Ring Cell Adenocarcinoma 402
Carcinoid Tumors of the Small Intestine 403
Gastrointestinal Stromal Tumor 404
Primary Small Intestinal Lymphomas 406

**Chapter 14 Kidney and Adrenal 409**
- **Technique 409**
- **Complications 409**
- **Adequacy Criteria and Diagnostic Accuracy 409**
Normal Cells 410
Renal Lesions 410
Xanthogranulomatous Inflammation 411
Renal Neoplasms 411
- **Benign Tumors of Kidney 412**
Angiomyolipoma 412
Metanephric Adenoma 413
Papillary Adenoma (Cortical Adenoma) 413
Renal Oncocytoma 414
Renal Cell Carcinoma 415
Papillary Carcinoma 417
Nuclear Grading of Renal Cell Carcinoma 418
Urothelial Carcinoma 419
Medullary Carcinoma 420
Metastatic Tumors of Kidney 421
Renal Lymphoma 421
- **Pediatric Renal Tumors 421**
Nephroblastoma (Wilms' Tumor) 421
Congenital Mesoblastic Nephroma 425
Rhabdoid Tumor 425
Clear Cell Sarcoma 426
- **Adrenal Gland 426**
Fine Needle Aspiration Cytology Technique 427
Anatomy and Histology 427
- **Lesions of Adrenal 427**
Adrenal Cyst 427
Adrenal Myelolipoma 428
Adrenocortical Hyperplasia and Neoplasm 428
Adrenal Adenoma 428
Pheochromocytoma 430
Metastatic Tumors 432
Retroperitoneal Lesions 433
Inflammatory Lesions 434
Non-neoplastic Noninflammatory Lesions 434
Soft Tissue Tumors 434
Germ Cell Tumors 434
Lymph Node 435
Metastatic Tumors 435

**Chapter 15 Gonads and Prostate 437**

- **Testis 437**
  - Anatomy and Histology of Testis 437
  - Normal Cells of Testis 437
- **Peritesticular Lesions 438**
  - Hydrocele 438
  - Spermatocele 438
- **Inflammation 438**
  - Acute Epididymitis 438
  - Chronic Epididymitis 438
  - Spermatocytic Granuloma 439
- **Testicular Tumors 441**
  - Neoplasm of Testis 441
  - Seminoma 441
- **Embryonal Carcinoma 443**
  - Cytology 443
  - Yolk Sac Tumor 444
  - Choriocarcinoma 445
  - Other Tumors of Testis 445
- **Female Genital System 445**
  - Cervical Carcinoma 445
  - Endometrial Tumors 445
- **Ovary 446**
- **Non-neoplastic Cyst 447**
  - Follicular Cyst or Cystic Follicle 447
  - Corpus Luteal Cyst 447
- **Endometriotic Cyst 447**
- **Ovarian Tumor 448**
  - Serous Adenoma and Adenocarcinoma of Ovary 448
  - Serous Adenocarcinoma 448
  - Mucinous Cystadenoma and Cystadenocarcinoma 449
  - Endometrioid Carcinoma 450
  - Clear Cell Carcinoma 450
  - Germ Cell Tumor 451
  - Mature Teratoma 451
  - Immature Teratoma 451
  - Carcinoid Tumors of Ovary 452
  - Dysgerminoma 452
  - Yolk Sac Tumor 452
- **Sex Cord Stromal Tumor 453**
  - Granulosa Cell Tumor 453
  - Sertoli Cell Tumor 454
  - Fibroma and Thecoma 454
  - Metastatic Tumors of Ovary 454
- **Prostate 455**
  - Normal Cells in Prostate Fine Needle Aspiration Cytology 455
- **Inflammation 455**
  - Benign Prostatic Hyperplasia 455
  - Carcinoma 456

**Chapter 16 Soft Tissue Lesions 461**

- **Complications 461**
- **Diagnostic Accuracy and Pitfalls 461**
  - FNAC Technique and Prerequisites for Interpretation of Smear 462
  - Ancillary Techniques 462
  - Diagnosis 463
  - Grading 463
- **Lipoma and its Variants 464**
  - Spindle Cell Lipoma 465
  - Pleomorphic Lipoma 466
  - Angiolipoma 467
  - Hibernoma 467
  - Myelolipoma 468
- **Liposarcomas 468**
  - Well-differentiated Liposarcoma 468
  - Myxoid Liposarcoma 469
  - Pleomorphic Liposarcoma 469
  - Round Cell Liposarcoma 471
- **Fibroblastic/Myofibroblastic Lesion 471**
  - Fibromatosis 471
  - Nodular Fasciitis 473
  - Myositis Ossificans 473
  - Solitary Fibrous Tumor 473
  - Dermatofibrosarcoma Protuberans 475
  - Infantile Myofibroblastoma 475
  - Fibrosarcoma 475

- **So-called "Fibrohistiocytic Tumors" 477**
  Giant Cell Tumor of Tendon Sheath 477
  Malignant Fibrous Histiocytoma 478
  Pleomorphic MFH 478
- **Tumors of Nerve Sheath 479**
  Benign Peripheral Nerve Sheath Tumor 479
  Malignant Peripheral Nerve Sheath Tumor 480
- **Tumors of Muscle Origin 482**
  Rhabdomyoma 482
  Rhabdomyosarcoma 482
  Leiomyosarcomas 484
- **Tumor of Vascular Origin 485**
  Hemangiopericytoma 485
- **Glomus Tumor 485**
  Cytology 485
- **Hemangioma 486**
  Cytology 486
- **Angiosarcoma 486**
  Cytology 486
- **Tumor of Uncertain Histogenesis 486**
  Synovial Sarcoma 486
  Monophasic Synovial Cell Sarcoma 488
  Clear Cell Sarcoma 488
  Epithelioid Sarcoma 488
  Alveolar Soft Part Sarcoma 490
  Granular Cell Tumor 490

**Chapter 17 Skin 495**

- **Non-neoplastic Lesions of Skin 495**
  Inflammation 495
  Rare Non-neoplastic Benign Diseases of Skin 496
- **Epidermal Inclusion Cyst 497**
- **Neoplastic Lesions of Skin 498**
  Benign Tumor of Skin Adnexa 498
  Malignant Tumors of Skin 500

**Chapter 18 Bone 509**

- **Biopsy of Bony Lesions 509**
- **Diagnostic Accuracy 509**
- **Complications 509**
- **Technique 509**
- **Normal Cells 510**
- **Infections 510**
  Osteomyelitis 510
- **Neoplastic Lesions of Bone 511**
- **Bone-forming Tumor 511**
  Osteoblastoma 511
  Osteoid Osteoma 511
  Osteosarcoma 511
- **Cartilage-forming Tumor 514**
  Chondroma 514
  Chondroblastoma 514
  Chondromyxoid Fibroma 515
  Chondrosarcoma 516
  Variants of Chondrosarcoma 518
- **Giant Cell Tumor, Chordoma, and Other Tumors 519**
  Giant Cell Tumor of Bone 519
  Chordoma 521
- **Ewing's Sarcoma and Peripheral Neuroectodermal Tumor 522**
- **Non-Hodgkin's Lymphoma 524**
- **Plasma Cell Neoplasm 524**
- **Langerhans' Cell Histiocytosis 526**
- **Metastatic Carcinoma 527**
- **Other Bone Lesions 528**
  Aneurysmal Bone Cyst 528
  Adamantinoma 528

**Chapter 19 Round Cell Tumor 531**

- **Diagnostic Approach 531**
- **Clinical Features and Imaging 531**
  Cytogenetics 531
  Immunocytochemistry 532
  Electron Microscopy 533
  Cytomorphology 533
- **Important Cytological Features 537**

**Chapter 20 Central Nervous System 539**
- **Cytology of Normal Brain Tissue 539**
  Neurons 539
  Glial Cells 539
- **Neoplastic Lesions 540**
  Astrocytomas 540
  Oligodendroglioma 541
  Ependymoma 541
  Myxopapillary Ependymoma 542
  Medulloblastoma 542
  Pituitary Adenoma 542
  Craniopharyngioma 542
  Lymphoma 542
  Metastatic Carcinoma 543
- **Infections 543**

**Chapter 21 Review of Cytology Cases 545**
- **Cases with History 545**
- **Answers of the Cases 586**

***Index*** ***591***

**Digital Slides** ***For Details See Inside Front Cover***

CHAPTER

4

# Ancillary Techniques in Aspiration Cytology

JAYPEE BROTHERS

## INTRODUCTION

Various ancillary techniques are essential parts of fine needle aspiration cytology (FNAC). These techniques help in diagnosis, management, and prognosis of the disease. The following ancillary techniques are used in FNAC:

- Immunocytochemistry (IC)
- Flow cytometry (FCM)
- Fluorescent in situ hybridization (FISH)
- Polymerase chain reaction (PCR)
- Next-generation sequencing (NGS)
- Electron microscopy (EM)

## IMMUNOCYTOCHEMISTRY

The application of IC is presently an integral part of diagnosis. The use of various monoclonal antibodies provides us with valuable information about the type of tumor **(Box 4.1)**. IC particularly helps us in the identification of the poorly differentiated malignant tumor. It also helps in the exact categorization of carcinoma and probable tissue of origin in case of metastatic tumors. IC is mandatory to determine the subtype of lymphomas.

**BOX 4.1: Applications of immunocytochemistry.**

- Diagnosis and typing of malignancy
- Subtyping of lymphomas
- Exact typing of carcinoma
- Diagnosis of exact typing of malignant round cell tumors
- Origin of primary tumors
- Hormone or receptor expression such as estrogen, progesterone receptors, and human epidermal growth factor receptor 2 (HER2) in breast carcinoma
- Studying cell proliferation markers
- Diagnosis of infective agents

### Advantages of Cytology Materials for Immunocytochemistry

The specific advantages of IC in the FNAC samples are as follows:

- Easy to procure the sample
- No need for antigen retrieval
- IC can be done on the scanty material.
- Multiple antibodies can be applied on the cell-block sections.

### Samples for Immunocytochemistry

Immunocytochemistry can be done on FNAC material in the following ways:

- Direct smear preparation
- Cytospin preparation
- Liquid-based cytology (LBC)
- Cell-block

*Fixation*: This is the easiest way for IC. However, the panel of IC cannot be done on direct smears due to the limitation of the number of smears. FNAC material can be collected in citrated buffer solution and multiple wet-fixed slides can be prepared from cytospin for the application of a panel of antibodies for IC. Except for some amount of artifact, overall cytospin preparation gives good results for IC. FNAC material can be collected in the methanol or ethanol-based fixative in LBC and multiple smears can be made, if necessary. Smears of LBC have a clean background and concentrated cells in a small area. LBC preparation provides good results for IC.[1] However, LBC preparation is costly. Out of all these sampling methods, the cell-block is the most recommended technique for IC. FNAC material is collected in buffered formalin solution for cell-block preparation **(Flowchart 4.1)**.

The main advantages of cell-block technique include: (1) Preparation of multiple sections, (2) no background

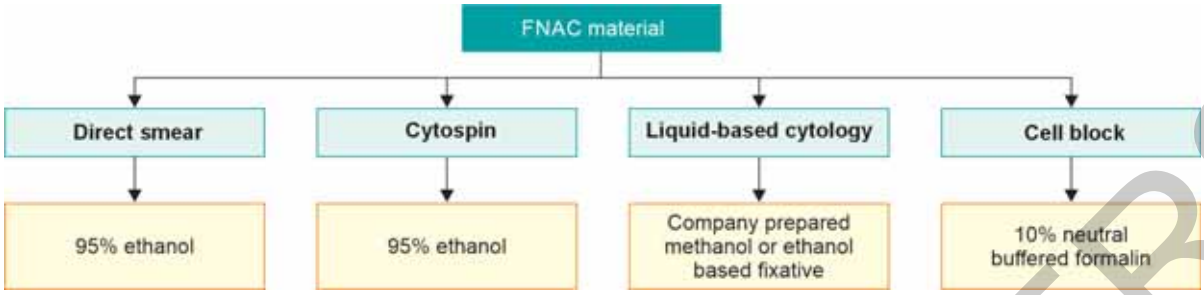


**FLOWCHART 4.1:** Fixatives of choice in different sample preparation for immunocytochemistry.
(FNAC: fine needle aspiration cytology)

**TABLE 4.1: Comparison of different sampling methods for immunocytochemistry.**

| Technique | Advantages | Disadvantages |
|---|---|---|
| Direct smear | • Easy to prepare the smear<br>• When no other slides are available, one can do immunostain on direct smear | • Background staining artifact<br>• Limited antibody panel |
| Cytospin | • Multiple smears can be made<br>• Panel of antibodies can be used<br>• Overall good result | • Bloody and mucoid materials are not fit for processing<br>• Difficult on scanty cellularity |
| Liquid-based cytology (LBC) | • Multiple smears can be made<br>• Clear background<br>• Monolayered cells in limited area | Costly and limited access |
| Cell-block | • Preparation of multiple sections<br>• No background staining<br>• To keep the material for archival use | Time consuming and takes 1 day to make a Cell-block |

staining, and (3) archival use of the material. **Table 4.1** shows comparison of different preparation techniques.

*Control*: In each time, a proper positive and negative control should be used for IC. For cell-block sections, one should have control slide from cell-block and for cytospin, the control slide should be from cytospin smear only.

*Interpretation*: FNAC slides should be properly interpreted as both false-positive or false-negative interpretation may occur.

- *False positive*: The causes of false-positive reporting include:
  - Poorly fixed cells
  - Using too high antibody titer
  - Crushed cells
  - Acute background inflammation because polymorphs contain peroxidize enzymes
  - Insufficient blocking of endogenous peroxide
  - Less specific antibody
  - Necrotic or cell debris in the background
  - Other technical problems such as forgetting one step or using the wrong antibody
- *False negative*: Similarly, false negative interpretation may occur due to:
  - Using too low antibody titer
  - Fragile cell cytoplasm
  - IC on poorly fixed cells
  - Insufficient retrieval of antigen

## Different Cell-specific Markers

### *Epithelial Markers*

- *Cytokeratin (CK)*: It is one of the most important types of intermediate filaments.
  - Expression: All types of epithelial cells in the body express CK and depending on the molecular weight they are classified into 20 different types.
  - Applications:
    - *Confirmation of carcinoma*: CK is a reliable marker of epithelial cells, particularly to distinguish epithelial tumors from lymphomas, melanomas, and sarcomas. However, certain sarcomas are positive for CK such as synovial sarcoma, epithelioid sarcoma, and Ewing's sarcoma (EWS).
    - *Primary source of tumor*: CKs are often tissue specific and the tumor cells retain the specific type of CK originated from that tissue. Therefore, the demonstration of certain type of CK is important to identify the specific type of tumor. It has been noted that CK7, CK20, and CK5/6 have the remarkable value to differentiate different types of carcinoma.[2-4] Most of the adenocarcinomas in our body express CK8, CK18, and CK19, whereas the cells of squamous

JAYPEE BROTHERS

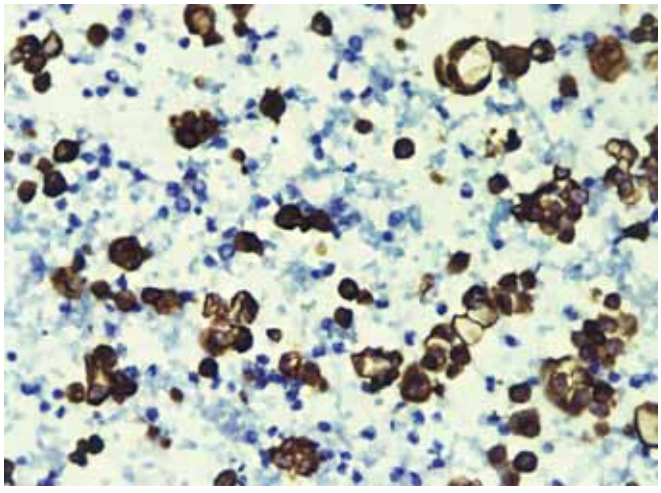

**FIG. 4.1:** Cytokeratin 5 positivity in squamous cell carcinoma (Cell-block immunostain × MP).

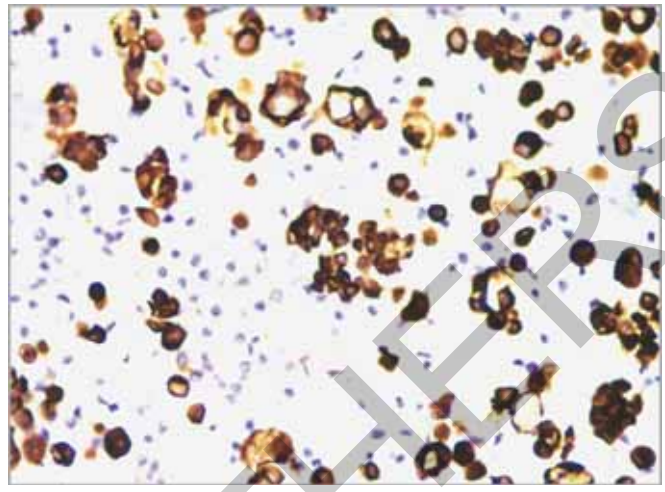

**FIG. 4.2:** Cytokeratin 7 positivity in adenocarcinoma (Cell-block immunostain × MP).

cell carcinomas and basal cell carcinomas are positive for CK5/6. Squamous cell carcinoma of lung is positive for CK5/6 **(Fig. 4.1)**. All cases of breast carcinoma, adenocarcinomas of lung, endometrial, and ovary are positive for CK7 and negative for CK20 **(Fig. 4.2)**. Majority of the cases of colorectal carcinoma, some cases of gastric adenocarcinomas, and Merkel cell carcinomas are CK20 positive and CK7 negative. Cases of adrenal cortical carcinoma, hepatocellular carcinoma, prostatic carcinomas, and renal cell carcinoma are negative for both CK7 and CK20. Therefore, a panel of CK7, CK20, and CK5/6 immunostain may help to find out the probable origin of metastatic tumor of unknown primary cases **(Table 4.2)**.

**TABLE 4.2: Cytokeratin (CK) subtypes in different tumors.**

| Tumors | CK7 | CK20 | CK5/6 |
|---|---|---|---|
| Adenocarcinoma of lung | + | – | – |
| Squamous cell carcinoma of lung | – | – | + |
| Adenocarcinoma of colon | – | + | – |
| Adenocarcinoma stomach | + | Focal + | – |
| Transitional cell carcinoma | + | Focal + | – |
| Invasive carcinoma of breast | + | – | + (in basal type) |
| Renal cell carcinoma, clear cell | – | – | – |
| Ovarian adenocarcinoma (nonmucinous) | + | – | – |
| Small cell carcinoma of lung | – | – | – |
| Adenocarcinoma of pancreas and bile duct | + | Focal + | – |
| Prostate | – | – | – |
| Hepatocellular carcinoma | – | – | – |

- *Epithelial membrane antigen (EMA)*: It is a complex membrane glycoprotein. It was originally isolated from milk fat globulin. EMA has no relation with keratin family of antigen.[5]
  - Expression: EMA is present in almost all the epithelial cells of the body except hepatocellular carcinomas and adrenocortical carcinomas.
  - Applications: EMA is used to identify the epithelial malignancy. However, it is not entirely specific for epithelial cells and is also positive in mesothelial cells, meningeal cells, large cell anaplastic lymphoma, plasmacytoma, some T-cell lymphomas, and certain mesenchymal tumors (epithelioid sarcoma and synovial sarcoma).[6]
- *Carcinoembryonic antigen (CEA)*:
  - Distribution: CEA is usually present in a scanty amount in normal epithelial cells and large amount in adenocarcinoma of gastrointestinal tract and lung.
  - Application: It is a useful marker to differentiate between metastatic carcinoma and malignant mesothelioma in the serous cavity.

### Mesenchymal Markers

- *Vimentin*:
  - Expression: Vimentin is usually expressed in mesenchymal cells such as fibroblast, endothelial cells, and smooth muscle.
  - Application: Vimentin is mainly positive in various sarcomas **(Fig. 4.3)**. It is not a reliable marker of mesenchymal cells because of low specificity as vimentin has also been demonstrated in epithelial

JAYPEE BROTHERS

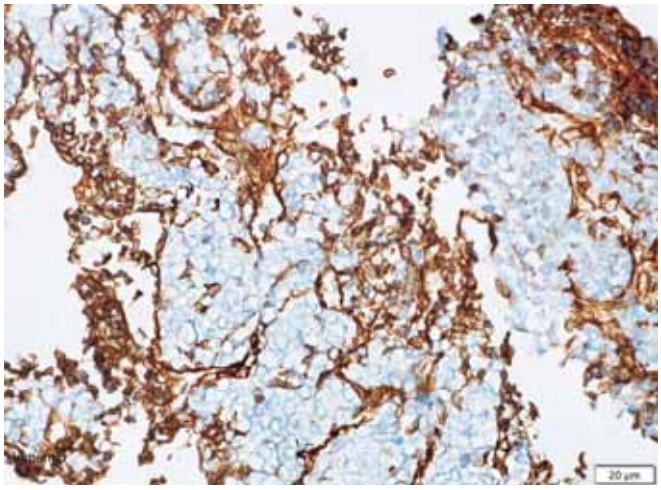

**FIG. 4.3:** Strong cytoplasmic and membrane positivity of vimentin in a sarcoma (cell-block immunostain × MP).

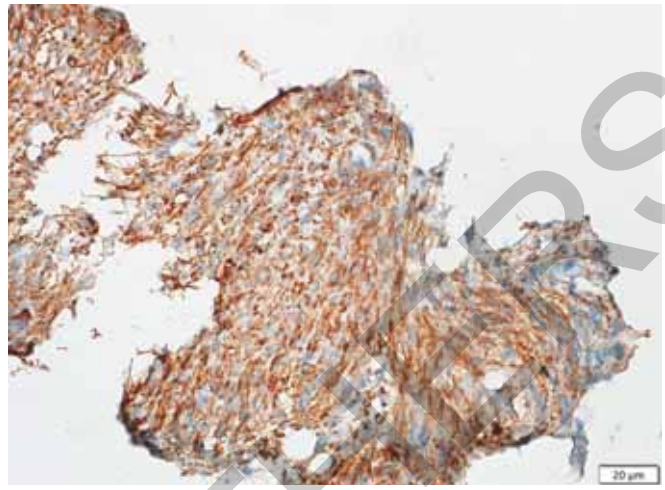

**FIG. 4.4:** Caldesmon positivity in a smooth muscle tumor (cell-block immunostain × MP).

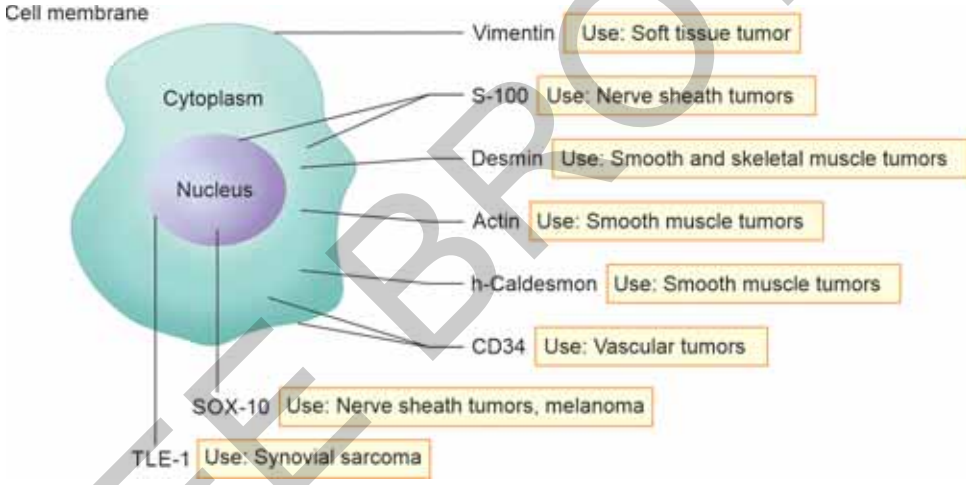


**FIG. 4.5:** Localization and use of various mesenchymal markers.
(TLE-1: transducer-like enhancer 1)

neoplasms such as in renal cell carcinoma, lymphomas, and mesothelial cells.

- *Desmin*:
  - Expression: Desmin is a member of intermediate filament proteins and is expressed in smooth muscle, skeletal muscle, and cardiac muscle.
  - Application: Desmin expression is a reliable marker of rhabdomyosarcoma (RMS) and leiomyosarcoma.[7]
- *h-Caldesmon*: It is an isotype of caldesmon.
  - Application: It is specific for smooth muscle tumor **(Fig. 4.4)**.
- *Actin*: It is the contractile protein of muscle and is present in smooth muscle cells and myofibroblasts.
- *Myo D1 and myogenin*: These are the reliable markers of skeletal muscles.
- *SOX10*: It is a marker of nerve sheath tumor and malignant melanoma.
- *CD207*: It is also known as langerin and is positive in Langerhans cell histiocytosis.
- *CD34*:
  - Expression: CD34 is expressed in the endothelial cells of lymphovascular tissues. The lymphoid progenitors are also positive for CD34.
  - Application: Identification of the vascular tumor and also immature lymphoid cells
- *Transducer-like enhancer of split 1 (TLE-1)*: It is mainly expressed in synovial sarcoma.

**Figure 4.5** shows localization and use of the various mesenchymal markers.

JAYPEE BROTHERS

### Lymphoid Markers

Various lymphoid markers are used for the classification of non-Hodgkin lymphoma (NHL) and Hodgkin lymphoma (HL). Leukocyte common antigen (LCA) is present in the lymphoid cells and is used to identify the broad group of lymphoma.[8] It has been shown that LCA has highly variable positivity in plasmacytoid lymphoma and T-cell NHL.[9] Therefore in problematic cases, particularly in the case of suspected anaplastic large cell lymphoma (ALCL), a full panel of other lymphoma markers along with CD30 should be applied. To demonstrate monoclonality in a suspected case of NHL, kappa and lambda light chain immunostaining may be necessary to show light chain restriction.

### Neuroendocrine Markers

- *Chromogranin*:
  - Expression: Chromogranin is located in the matrices of neurosecretory granules and is ubiquitous and distributed in all the neuroendocrine tissues of the body such as anterior pituitary gland, thyroid, adrenal medulla, and pancreatic islets.
  - Application: Antibody to chromogranin is very specific for neuroendocrine differentiation of a tumor **(Fig. 4.6)**. However, the intensity of chromogranin stain depends on the relative abundance of endocrine granules and so it is a less sensitive marker of neuroendocrine tumor.
- *Synaptophysin*: It is present in the presynaptic vesicles of neurons and is a marker of neuroendocrine and neuroectodermal tumors.

### Melanoma Markers

- *HMB-45*:
  - *Expression*: HMB-45 is an oncofetal glycoconjugate, associated with immature melanosomes.
  - *Application*: It is a specific marker of melanoma. Neural crest-derived tumors, occasional carcinomas, and immunoblastic lymphomas are also positive for HMB-45 **(Fig. 4.7)**.[10]
- *Melan A*: It is a melanocyte-associated marker and is highly sensitive for detection of melanoma. Peripheral nerve sheath tumor, angiomyolipoma, and steroid-producing cells of adrenal cortex are also positive for Melan A.[11]
- *S-100 protein*:
  - Expression: S-100 protein is a calcium-flux determinant. This is present in the nucleus and cytoplasm of glial cells, Schwann cells, normal melanocytes, adipocytes, salivary gland cells, myoepithelial cells, and Langerhans histiocytes.
  - Application: Tumors developed from melanocytes, Langerhans' cells, and myoepithelial cells are also positive for S-100 protein.[12] S-100 protein expression is applied in the identification of malignant melanoma, peripheral nerve sheath tumors, granular cell tumor, and melanoma of soft parts (clear cell sarcoma) **(Fig. 4.8)**.

### Germ Cell Markers

- *Placental alkaline phosphatase (PLAP)*:
  - Expression: PLAP is expressed in normal placenta. It is an oncofetal antigen and is expressed in all

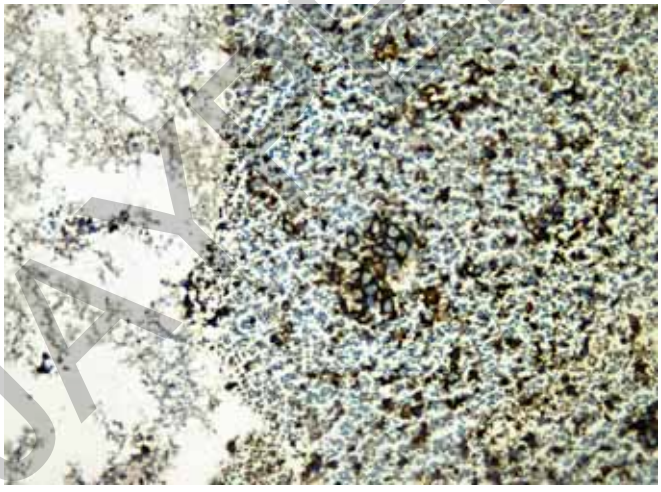

**FIG. 4.6:** Chromogranin positivity in small cell carcinoma of lung (cell-block immunostian × MP).

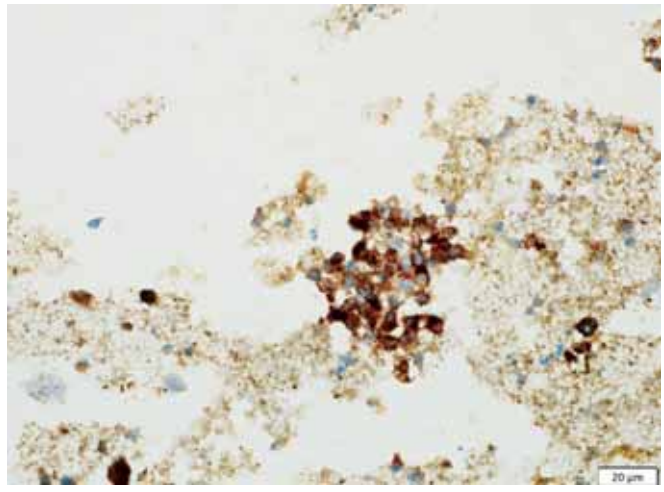

**FIG. 4.7:** HMB-45 positive cells in a melanoma of eye (cell-block immunostian × MP).

JAYPEE BROTHERS

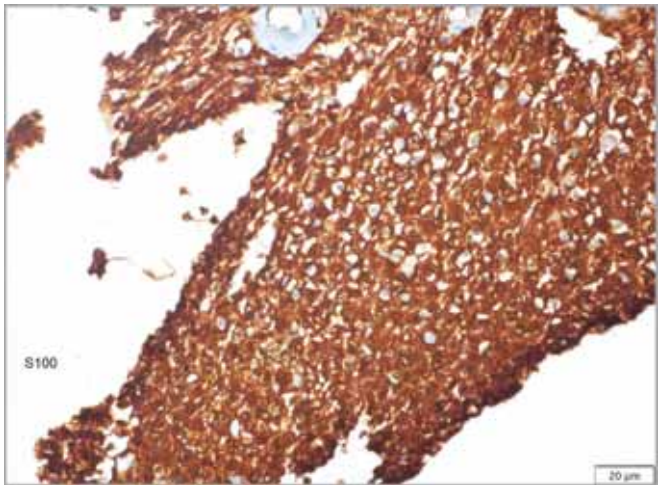


**FIG. 4.8:** S-100 positive cells in a granular cell tumor (cell-block immunostian × MP).

germ cell tumors[13] and certain genitourinary, gastrointestinal, and pulmonary carcinomas.
    - Applications: PLAP may be used to differentiate germ cell tumor from other undifferentiated malignancy. PLAP is consistently demonstrated in both seminoma and embryonal carcinoma. Therefore, it is widely used to differentiate germ cell tumors from other nongerm cell somatic tumors. It has been shown that somatic tumors that are PLAP positive also uniformly show positivity for EMA and negativity for CD30.
- *Sal-like protein 4 (SALL4)*: It is a reliable germ cell marker that is positive in embryonal carcinoma, dysgerminoma/seminoma, and yolk sac tumor.
- *Octamer-binding transcription factor 4 (OCT-4)*: It is expressed in dysgerminoma/seminoma and embryonal carcinoma.
- *CD117*: This is also known as C-kit. CD117 is expressed in gastrointestinal stromal tumors (GISTs), granulocytic sarcomas, melanomas seminomas, small cell carcinomas, and primitive neuroectodermal tumors (PNETs).[14] However in the differential diagnosis of spindle cell mesenchymal tumor in gastrointestinal tract (GIT), CD117 is used for the confirmation of GIST.[15]
- *Human chorionic gonadotropin (HCG)*: It is normally secreted by the syncytiotrophoblast cell of the placenta. The beta subunit of HCG is hormone specific. HCG usually shows intense positivity in choriocarcinoma.

## Mesothelial Markers

- *Calretinin*:
    - Expression: Calretinin is a calcium-binding protein. It is present in the mesothelial cells and is also expressed in a wide variety of other cells including steroid-producing cells of ovary and testis, renal tubular cells, and lipocytes.
    - Applications: It is considered as a mesothelial-specific marker and stains—both reactive and malignant mesothelial cells. The sensitivity and specificity of calretinin are about 100% and 80%, respectively.[16] Occasionally, the cells of adenocarcinoma may also show calretinin positivity.[17] However, calretinin positivity pattern is less intense and focal in adenocarcinoma cells.
- *Human bone marrow endothelial cell marker-1 (HBME-1)*: This monoclonal antibody is raised against the cell surface microvillus of the mesothelial cells. HBME-1 stains intensely around the periphery of the mesothelial cells. The specificity of HBME-1 is about 80%. However, a significant population of adenocarcinoma cells also shows HBME-1 positivity.[18]
- *Wilms' tumor gene 1 (WT-1)*:
    - Expression: Wilms' tumor gene is present in chromosome 11 and acts as a tumor suppressor. WT-1 is a transcription factor isolated in the cells of the kidney. It is expressed in the cytoplasm and nucleus of the mesothelial cells.
    - Application: The *WT-1* gene product is used to identify the mesothelial cells and also desmoplastic small round cell tumors (DSRCT), and ovarian serous carcinoma.[19] Therefore, the usefulness of WT-1 is to some extent restricted to differentiate adenocarcinoma from mesothelioma.
- *D2-40*: It was initially used as a marker of lymphatic endothelial cells. However, it is a relatively sensitive (85%) and specific (95%) marker of mesothelial cells.[20]

## Other Important Markers

- *Prostate-specific antigen (PSA)*: PSA and androgen receptor (AR) are positive in normal, hyperplastic, and neoplastic prostate tissue. PSA is not entirely specific for prostate and is also positive in breast carcinoma and salivary gland tumors.[21]
- *AR*: It is present in the nucleus of the prostate epithelial cells and is considered as a reliable indicator of prostate origin of cells. However, salivary gland tumor also shows AR positivity.[22]
- *Thyroid transcription factor (TTF)*:
    - Expression: TTF is a tissue-specific transcription factor and is expressed in follicular epithelial cells of the thyroid and bronchial epithelial cells of lung.
    - Application: TTF-1 is applied to identify the adenocarcinomas of lung and the tumors that are developed from thyroid follicular cells. TTF is occasionally expressed in ovarian neuroendocrine carcinomas and carcinoid of lung.[23]

JAYPEE BROTHERS

- *Estrogen and progesterone receptors (ER and PR)*: These two hormonal receptors are present in the nucleus of the breast and endometrial adenocarcinomas. They may help in identification of metastatic carcinoma of the breast in selective condition.
- *MIC2 (CD99)*: CD99, a membranocytoplasmic protein, is also known as MIC2 or p30/32 protein. This is expressed in PNETs and Ewing's sarcomas.[24] Other than neuroectodermal lineage, CD99 is also positive in alveolar RMS, lymphoblastic lymphomas, and certain neuroendocrine carcinomas.[25]
- *Neuroblastoma 84 (NB84)*: This monoclonal antibody is developed against neuroblastomatoma tumor tissue. NB84 reactivity is seen in all the cases of neuroblastoma. However, the cases of PNET and DSRCT are also positive for NB84.[26]

## Practical Diagnostic Problems

### *Undifferentiated Small Cell Malignancies*

Undifferentiated small cell malignancies include NHL, RMS, NB, PNET/EWS, DSRCT, and carcinomas. These tumors may often create diagnostic difficulties on FNAC. The judicious use of proper panel of IC may be helpful in diagnosis of such malignancies on FNAC **(Flowchart 4.1)**. CD45 is a useful marker to differentiate NHL from all other malignancies. CK positivity and further desmin-negative tumor indicates carcinoma. Further, CK5/6, 7, TTF-1, and p63 immunostain can differentiate squamous cell carcinoma and adenocarcinomas. Small cell carcinoma of lung is positive for chromogranin and also CK. DSRCT is positive for both CK and desmin markers. CK-negative and further desmin-positive tumor indicates RMS. CK and desmin-negative but HMB-45-positive tumor means malignant melanoma. CD99 and NB84 may be helpful to distinguish PNET/EWS and NB **(Flowchart 4.2)**.

### *Pleomorphic Tumors*

Pleomorphic undifferentiated tumors include undifferentiated carcinoma, pleomorphic RMS and leiomyosarcoma, malignant melanoma, malignant fibrous histiocytoma (MFH), angiosarcoma, and ALCL. CK positivity helps to discriminate carcinoma from other pleomorphic malignancies **(Flowchart 4.3)**. Similarly,

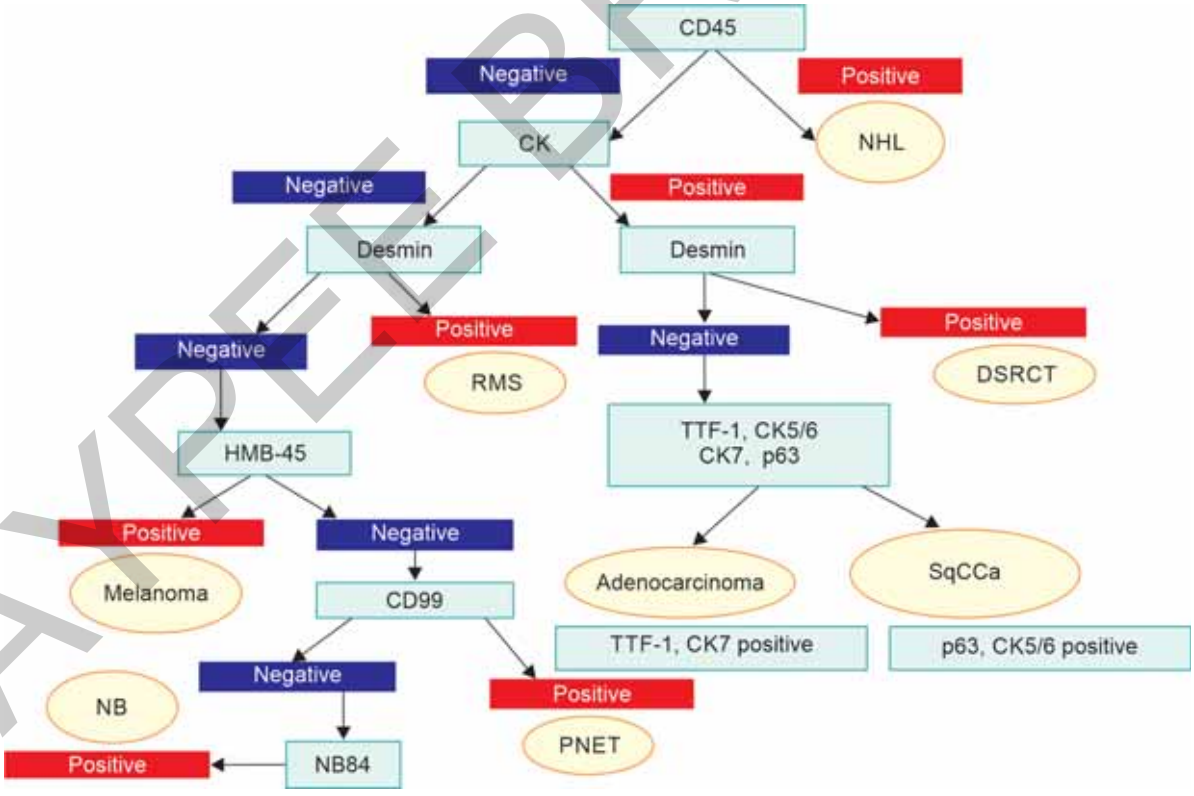


**FLOWCHART 4.2:** Algorithmic approach of undifferentiated small cell malignancies.

(CK: cytokeratin; DSRCT: desmoplastic small round cell tumor; NB: neuroblastoma; NHL: non-Hodgkin lymphoma; PNET: primitive neuroectodermal tumor; RMS: rhabdomyosarcoma; TTF: thyroid transcription factor)

JAYPEE BROTHERS

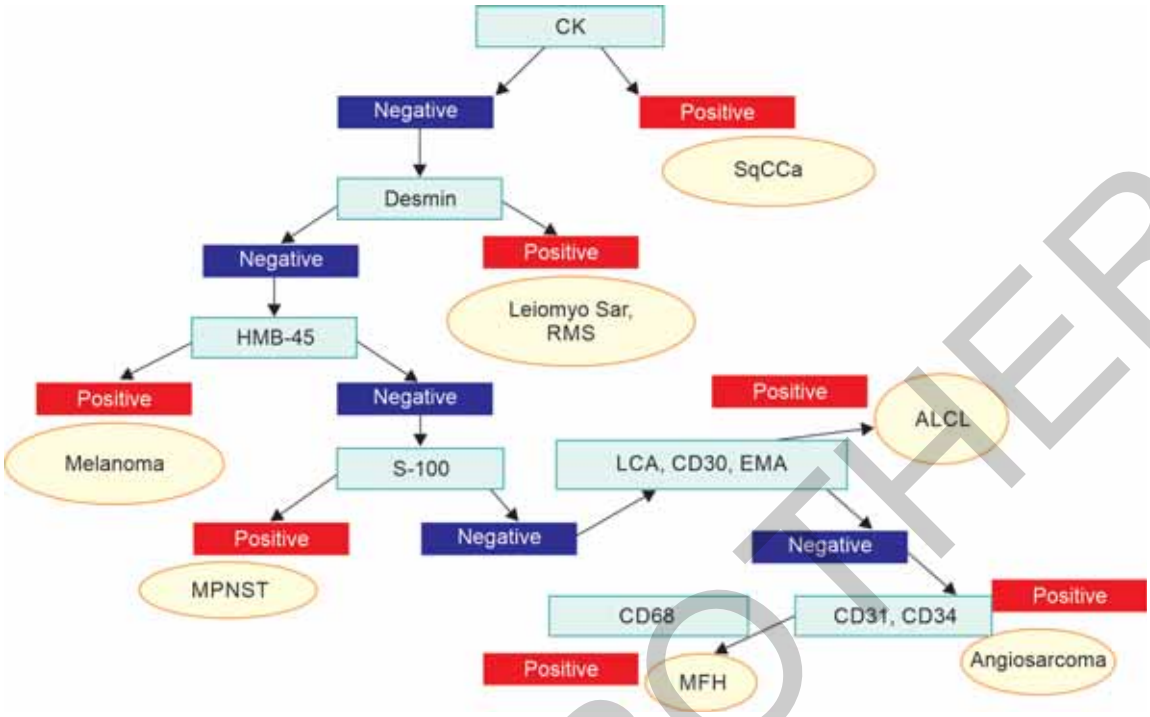


**FLOWCHART 4.3:** Algorithmic approach in pleomorphic sarcoma.
(ALCL: anaplastic large cell lymphoma; CK: cytokeratin; EMA: epithelial membrane antigen; LCA: leukocyte common antigen; MFH: malignant fibrous histiocytoma; MPNST: malignant peripheral nerve sheath tumor; RMS: rhabdomyosarcoma)

cases of pleomorphic RMS and leiomyosarcomas are positive for desmin. Malignant melanoma cases are HMB-45 positive and negative for CK and desmin. HMB-45-negative and S-100-positive pleomorphic tumors indicate malignant peripheral nerve sheath tumor (MPNST). ALCL cases are positive for LCA, CD30, and also EMA. LCA positivity in ALCL is not consistent and not reliable. Vascular tumors such as angiosarcomas are positive for CD31 and CD34. These tumors are negative for CK, desmin, HMB-45, and S-100 markers.

### *Metastasis from Unknown Primary*

Immunocytochemistry is very helpful in diagnosing cases of metastatic carcinoma. A panel of CK, EMA, vimentin, desmin, MIC2 (CD99), and HMB-45 initially helps to recognize the exact nature of the tumor. Now to diagnose the types of carcinoma, detailed panel of CK subtypes including CK5, 6, 7, and 20 are helpful. Squamous cell carcinoma strongly expresses the CK5, CK14, and CK17, as well as CK6 and CK16. In general, CK5 and CK6 positivity helps to distinguish a poorly differentiated squamous cell carcinoma from a poorly differentiated adenocarcinoma. Dual use of CK7 and CK20 on the FNAC sample is helpful to detect the primary location of adenocarcinomas. Colorectal adenocarcinomas exhibit a CK7–/CK20+ expression in majority of the cases. Ovary and endometrial carcinomas are always positive for CK7 and negative for CK20. Both ductal and lobular carcinomas of breast are positive for CK7 and CK19 and negative for CK20 and CK5/6. A combined marker positivity of CK7, along with ER and PR positivity and CK20 negativity are helpful markers to differentiate metastatic breast carcinoma from other adenocarcinomas.

After the initial result of CK subtypes, more site-specific markers may be applied to find out the precise location of the primary site of metastatic carcinoma. **Table 4.3** enumerates the positivity of various antibodies in different malignancies in different primary sites.

### *Lymphoma Subtyping (Box 4.2)*

After studying the cell morphology, the panel of markers should be used.[27] The panel of B-cell markers includes CD10, CD20, kappa, and lambda. Panel of T-cell markers consists of CD2, CD3, CD4, CD5, CD7, and CD8. In addition, secondary panel of B cells includes CD5 and CD23 and T cell includes CD30. The panel of HL includes CD15, CD30, CD20, and CD45. In addition, terminal deoxynucleotidyl transferase (TdT) should be used in suspected cases of lymphoblastic lymphoma.

JAYPEE BROTHERS

**TABLE 4.3: Site-specific antibody.**

| Organ or cell type | Antibodies |
|---|---|
| Thyroid | TTF-1, thyroglobulin, and calcitonin |
| Breast | Estrogen and progesterone receptors, EMA, and gross cystic disease fluid protein 15 |
| Lung | TTF, CK7 positive, and CK20 negative |
| Pancreas | CK7, CK20, and CA 19-9 positive |
| Liver | Hep Par-1, alpha fetoprotein, and CK7 and CK20 negative |
| Colon | CEA, CK7 negative, and CK20 positive |
| Mesothelial cells | Calretinin, WT-1, and CK5 and 6 positive |
| Prostate | PSA, AR, CK7, and CK20 negative |
| Germ cell | PLAP, Beta HCG, alpha fetoprotein, SALL4, and OCT-4 |

(AR: androgen receptor; CEA: carcinoembryonic antigen; CK: cytokeratin; EMA: epithelial membrane antigen; HCG: human chorionic gonadotropin OCT-4: octamer-binding transcription factor 4; PLAP: placental alkaline phosphatase; PSA: prostate-specific antigen; SALL4: sal-like protein 4; TTF-1: thyroid transcription factor 1; WT-1: Wilms tumor 1)

**BOX 4.2: Panel of antibodies for lymphoma.**

- *LCA (CD45)*: Positive for most of the lymphoid tumors
- *B-cell markers*: Positive for CD19, 20, 23, 10, and 5
- *T-cell markers*: Positive for CD3, 4, 5, 7, and 8
- *Hodgkin's lymphoma*: Positive for CD15 and CD30
- *NK cell*: Positive for CD3 and CD56+; Negative for CD19, CD10, and CD23
- *Plasma cell*: Positive for CD138

(LCA: leukocyte common antigen; NK: natural killer)

## Receptors for Therapy

Presently, molecular-targeted therapy is applied for various malignancies. Either receptor blockers or monoclonal antibodies are used against various receptors that are related with tumor growth.[28] The common antireceptor therapies are used against C-kit in GIST, epithelial growth factor receptor (EGFR) in adenocarcinomas of lung, and human epidermal growth factor receptor 2 (HER2) in breast cancer.

- *ER and PR*: ER and PR receptors, the nuclear receptors, can be successfully assessed on cell-block section or thin-layer preparation **(Figs. 4.9 and 4.10)**.[29] ER/PR nuclear positivity is related to antiestrogen hormone therapy of breast cancer and >10% positivity of tumor cells gives response to antihormonal therapy.
- *HER2/Neu*: This oncogene is over expressed in 10–20% of breast carcinoma. All types of formalin-fixed smears can provide the *HER2* expression status. Overexpression of *HER2/Neu* is manifested as intense staining of cell membranes. Information about *HER2/Neu* expression status is needed for anti-*HER2* therapy.
- *EGFR*: This receptor is located on the cell membrane and is intimately related with carcinogenesis. EGFR expression of the cells in head, neck, colon, and lung carcinoma can be demonstrated on IC.

## Antibodies Directed to Anti-infective Agent

Immunocytochemistry may be helpful to identify various infective agents such as cytomegalovirus, chlamydia, herpes simplex virus, and human papillomavirus.

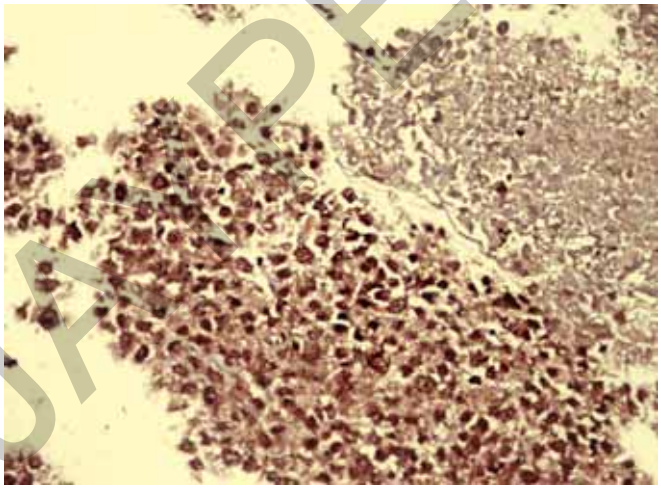

**FIG. 4.9:** Estrogen receptor positivity in infiltrating duct carcinoma of breast (cell-block immunostain × MP).

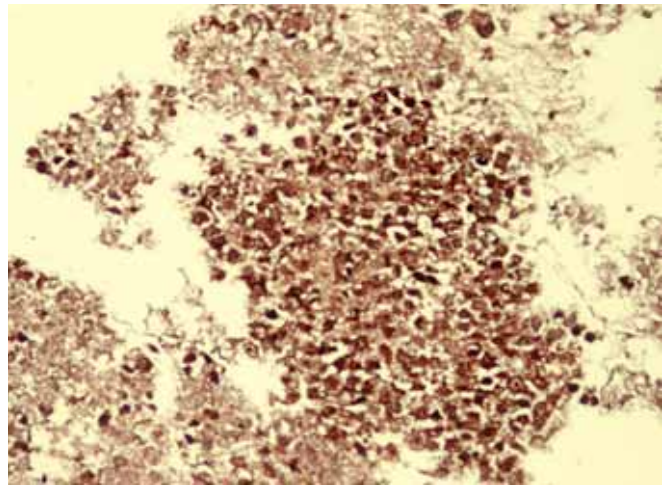

**FIG. 4.10:** Progesterone receptor positivity in infiltrating duct carcinoma of breast (cell-block immunostain × MP).

JAYPEE BROTHERS

## FLOW CYTOMETRY

Flow cytometry helps to study the different characteristics of the single cell in the fluid stream. The single cell suspension is made from the FNAC material and the cells are stained with a fluorescent dye that binds with the specific components of the cell such as cell surface antigen or receptors. The cells are flowed in front of the laser beam and the emitted fluorescence is recorded in photomultiplier tube and is converted into digital signal. In case of deoxyribonucleic acid (DNA) FCM, a DNA-binding dye is used that stoichiometrically binds with DNA and the emitted fluorescence is similarly recorded. The intensity of this digital signal is graded on a relative scale known as channel. The results are then displayed as histogram or two-dimensional dot plots. **Figure 4.11** highlights the basic principles and optic of the flow cytometer.

- The FNAC sample is collected in citrated buffer solution and is processed immediately or alternatively can be kept in –70°.
- FNAC material for FCM has some special advantages over the histopathology tissue. FNAC sample for FCM is easy to process and requires less disaggregation, and thereby single cell preparation is easier to make for FCM and multiple areas from the tumor or lymph nodes can be collected by FNAC.

### Applications

Flow cytometry of FNAC material is commonly used in clinical laboratory for immunophenotyping, DNA content analysis, and cell cycle analysis.[30]

#### *Immunophenotyping*

Flow cytometric immunophenotyping (FCI) is very effective for the demonstration of various CD markers on the cell surface of the lymphoid cells **(Box 4.3)**. This has great impact in the subclassification of lymphomas and leukemia.

#### Diagnosis of Lymphoma

In case of morphologically unequivocal cases of NHL, the demonstration of monoclonality may help to confirm the diagnosis. In case of B-NHL, the neoplastic lymphoid cells show either lambda or kappa light chains expression and light chain restriction may be demonstrable by measurement of kappa/lambda ratio. In FCM, the kappa/lambda ratio >4:1 or >1:2 is usually considered as an evidence of monoclonality **(Fig. 4.12)**. The demonstration of T-cell monoclonality by FCM is difficult. However, the aberrant expression of CD2, CD5, and CD7 expression and dual expression of CD4 and CD8 may suggest T-NHL.[31]

#### Sub-classification

Immunophenotyping of lymphoma with the help of FCI is presently more popular than IC because FCI has certain advantages over IC **(Box 4.3)**. The most

**BOX 4.3: Pros and cons of FCI over IC.**

*Advantages*:

- Relatively faster technique
- Large panel of CD markers can be used
- Dual expression of CD markers can be demonstrated
- Quantitation of CD-positive cells

*Disadvantages*:

- Morphology of the cells not visible
- Archival preservation not possible
- Admixture of benign cells
- Costly

(FCI: flow cytometric immunophenotyping; IC: immunocytochemistry)

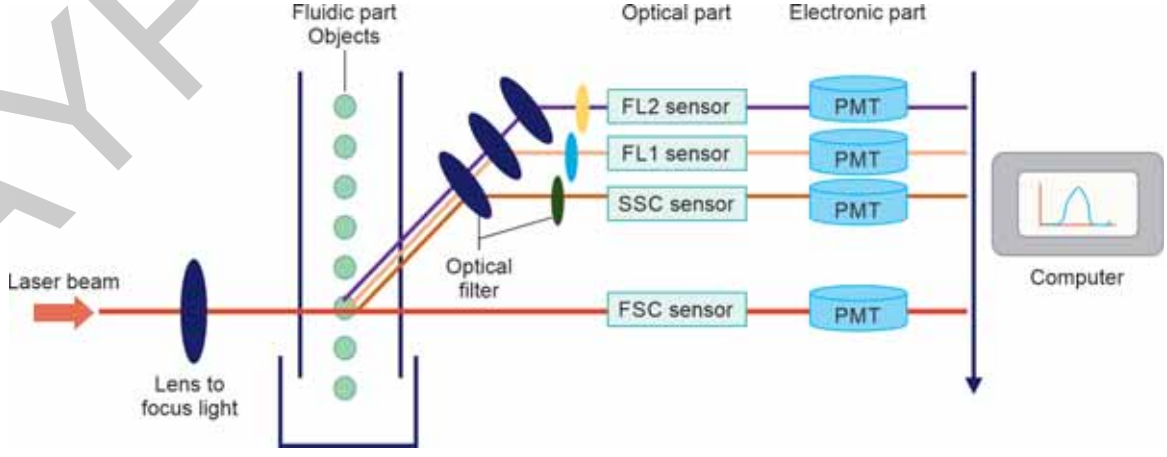


**FIG. 4.11:** Schematic diagram highlighting the basic principles and optic of the flow cytometer.
(FSC: forward scatter; PMT: photomultiplier tube; SSC: side scatter)

JAYPEE BROTHERS

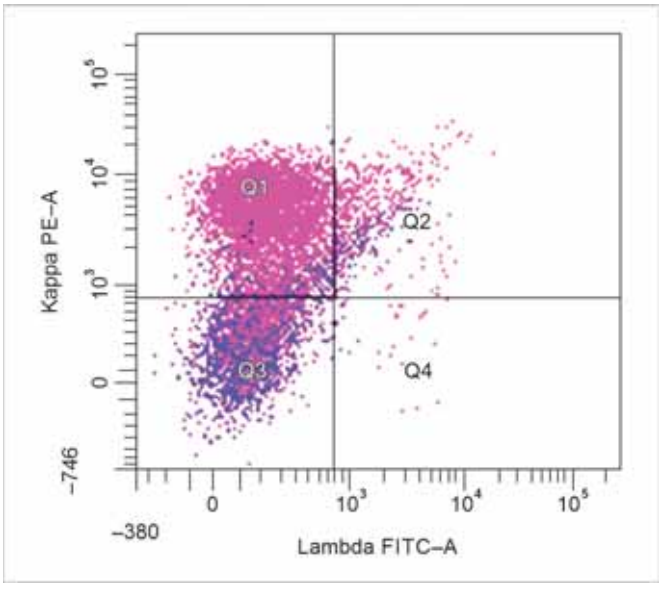


**FIG. 4.12:** Light chain restriction (only kappa light chain is expressed here) indicating the possibility of lymphoma.

important advantages of FCI include rapidity of the technique, application of large panel of CD markers, and demonstration of dual expression of markers on the same cell. Moreover, many other additional features such as DNA ploidy and cell cycle analysis can be done simultaneously along with immunophenotyping.

### Major Limitations of Flow Cytometric Immunophenotyping

- *Loss of morphology*: The individual cell morphology is not visible on FCM and therefore, it is not possible to correlate it with immunophenotyping markers.
- *Admixed other cells*: The target lymphoid cells may be admixed with other cells such as stromal cells and vascular endothelial cells. This may dilute the sample and reduce the sensitivity of the technique.
- *Scanty cells of interest*: It is difficult to diagnose and do immunophenotyping of HL in FCI because the number of R–S cells is not so high to detect among the vast population of reactive lymphoid cells.
- *Absence of light chain restriction*: All cases of B-NHL may not always show light chain restriction. This may be due to failed expression of light chain on the surface of the cell.
- *High cost of the instrument*: FCM is very costly to afford in routine laboratory.

## Molecular Genetics

There is massive development of cytogenetic techniques in last few decades. These sophisticated cytogenetic techniques include FISH, PCR-comparative genomic hybridization (CGH), microsatellite analysis, telomerase quantitation, serial analysis of gene expression (SAGE), etc.

## FLUORESCENT IN SITU HYBRIDIZATION (BOX 4.4)

Fluorescent in situ hybridization is also known as "interphase cytogenetics" as the technique can be applied to the interphase cell nucleus. Here, specific DNA probes are used for chromosome- and gene-specific loci to visualize and quantitate genetic and chromosomal alterations.

### Principle (Fig. 4.13)

In this technique, the double-stranded DNA is made into single-stranded DNA by heat denaturation. Then, a complementary single-stranded DNA labeled with fluorescent dye is hybridized with the target DNA and is examined in the fluorescent microscope.[32]

### Advantages of Fluorescent in situ Hybridization

The FISH technique has several advantages such as:

- High resolution capability
- It demonstrates the specific location of the DNA sequence directly in the chromosome.

**BOX 4.4: Fluorescent in situ hybridization (FISH).**

Specific deoxyribonucleic acid (DNA) probes tagged with fluorochrome dye to visualize genetic and chromosomal alterations.

*Advantages*:

- High-resolution capability
- Specific location of DNA sequence directly in the chromosome
- Archival material can be used
- No cell culture technique
- Rapid and less laborious

*Applications*:

- Various chromosomal translocations can be recognized
  - Diagnosis:
    - Synovial sarcoma: t(X;18)
    - EWS: t(11;22)
    - Mantle cell lymphoma: t(11;14)
- Whole chromosome number: Gain of chromosomes 7 and 8 in prostatic carcinoma
- Gene amplification:
  - *HER2/Neu* in breast carcinoma
  - *N-Myc* in neuroblastoma

JAYPEE BROTHERS

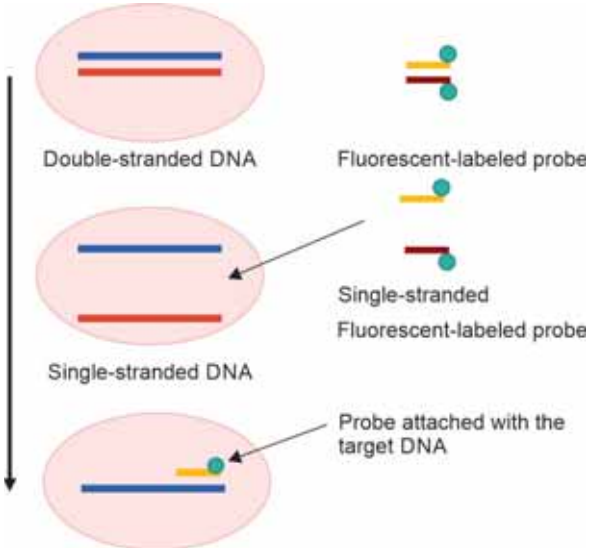


**FIG. 4.13:** Schematic diagram of the basic principle of fluorescent in situ hybridization technique.

*Note*: Arrow indicates the introduction of the probes and its subsequent attachment with the single stranded DNA.

(DNA: deoxyribonucleic acid)

- FISH can be done on archival material and no cell culture technique is needed for FISH technique.
- Rapid and less laborious than the other molecular techniques such as PCR
- FISH can be done on a scanty FNAC sample.

### Limitations of Fluorescent in situ Hybridization

- Only known chromosomal abnormalities can be detected by FISH.
- Allele-specific information is not obtained in FISH.
- FISH is not a good screening test.

### Applications

Fluorescent in situ hybridization is applied mainly for:

- *Diagnosis of various hematolymphoid neoplasms*: FISH can be used to detect chromosomal translocation in various lymphomas. Utility of FISH has been demonstrated in mantle cell lymphoma that show characteristic translocation of t(11;14).[33] Similarly, t(14;18) is a diagnostic marker of follicular lymphoma.
- *Diagnosis and prognosis of solid tumors*: Clinical utility of FISH has been demonstrated in the diagnosis of various solid tumors. In EWS, the characteristic translocation of t(11;22) involving the *FLI1* and *EWSR1* genes can be demonstrated on FNAC sample with the help of FISH. In synovial sarcoma, typical translocation of t(X;18) is noted in almost 70% cases. The demonstration of such translocation by FISH is a helpful feature in diagnosing difficult cases of synovial sarcoma on FNAC sample.[34] Gain of chromosome 7 and 8 in prostatic carcinoma is related with poor prognosis and these abnormalities can be demonstrated with the help of FISH.[35] Similarly, oncogene amplification such as *HER2* or *N-myc* can be demonstrated on FNAC material.
- *Targeted therapy*: Gene amplification (such as *HER2* gene) can be detected by FISH and this may be helpful in specific therapy.
- *Disease monitoring*: FISH can be used to detect minimal residual disease. In head-neck carcinoma, the demonstration of genetic abnormality on the resection margin by FISH may be helpful to assess the resection free tumor margin.

### Types of Fluorescent in situ Hybridization

The different types of FISH are as follows:[32]

- *Three-dimensional FISH*: It is helpful to assess the topology of the gene within the nucleus.
- *Four-dimensional FISH*: It helps in the visualization of genomic organization in the living cell.
- *Multicoloured FISH (M-FISH)*: In this, different colored fluorochrome dyes are used to paint different chromosomes.
- *CGH*: It helps to assess the loss or gain of genes of the tumor.

## POLYMERASE CHAIN REACTION

Polymerase chain reaction helps to amplify the specific target portion of DNA **(Box 4.5)**. At first by applying heat, double-stranded DNA is made single stranded. Two oligonucleotide strands or primers are used that are complementary to the 3' ends of each strand of DNA. The primers are attached to the 3' end of the DNA strand. With the help of Taq polymerase and nucleotides, the DNA strands are extended by incorporating nucleotides **(Fig. 4.14)**.

There are various types of PCR such as reverse transcriptase PCR (RT-PCR), in situ PCR, real-time PCR, and nested PCR. In case of RT-PCR, cDNA is made from RNA and then cDNA is amplified by PCR technique. In case of in situ PCR, the nucleic acid in the fixed cell is amplified instead of cells in solution. In real-time PCR, the amount of product can be monitored during each cycle of PCR with the help of a fluorescent dye and therefore the total amount of the product can be quantified appropriately.

JAYPEE BROTHERS

## Applications

*Tumor*: With the help of highly specific primers, various chromosomal translocations can be detected by PCR[32,36] that may be helpful to diagnose malignancy or have prognostic implications. Characteristic chromosomal translocations of different SRCT have been identified with the help of RT-PCR against tumor-specific translocations in FNAC material.[37] The t(X;18)(p11;q11) reciprocal translocation causes a chimeric fusion gene *SYT-SSX* in synovial sarcoma. *SYT-SSX* fusion transcript genes may be identified in FNAC material with the help of RT-PCR.[38] PCR technology has also been used to identify Ras mutation in pancreatic carcinoma.[39]

**BOX 4.5: Polymerase chain reaction (PCR).**

PCR helps to amplify the specific target portion of DNA

*Principle*:

- Double-stranded DNA is made single-stranded by applying heat
- Primers are used that are complementary to the 3′ ends of each strand of DNA
- With the help of Taq polymerase and nucleotides, the DNA strands are extended

*Types of PCR*:

- Reverse transcriptase PCR (RT-PCR)
- In situ PCR
- Real-time PCR
- Nested PCR

*Applications*:

- *Tumor*: Chromosomal translocations to diagnose malignancy
- *Infection*: Identifying bacterial, viral, and fungal infections

(DNA: deoxyribonucleic acid; RT: reverse transcriptase)

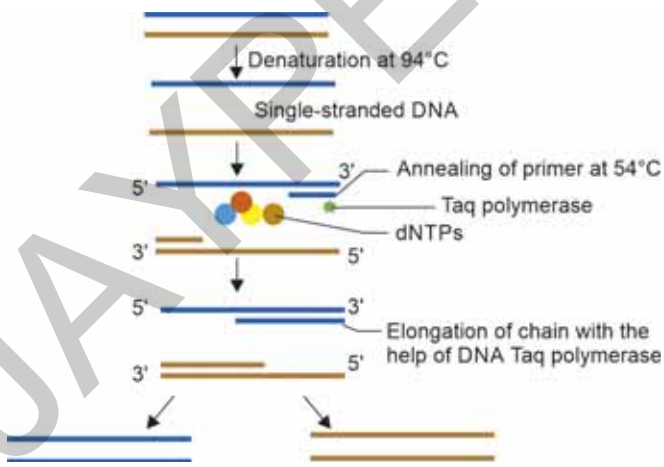


**FIG. 4.14:** Schematic diagram of basic principle of polymerase chain reaction.

(DNA: deoxyribonucleic acid; dNTPs: deoxynucleotide triphosphate)

*Infection*: FNAC material has been subjected to PCR analysis for the diagnosis of tuberculosis. PCR can diagnose the infection in early and latent phase which is not possible with the conventional laboratory techniques.[40] Moreover, PCR is a sensitive technique compared to Z–N stain for acid fast bacilli on smear and culture.[41]

Overall sensitivity and specificity of PCR in FNAC material of tuberculous lymphadentis are 84% and 75%, respectively. However, the combined use of FNAC smear and PCR increases the sensitivity and specificity to 84% and 100%, respectively.[42] Large varieties of viral infections including human papillomavirus (HPV), cytomegalovirus (CMV), Epstein–Barr virus (EBV), etc. can be detected with the help of PCR technology by using suitable primers specific for viral DNA amplification.[43]

*Genetic disease*: PCR is helpful to identify the various genetic diseases such as Down syndrome, sickle cell anemia, and cystic fibrosis.

# NEXT-GENERATION SEQUENCING

Next-generation sequencing is an advanced technique that helps to do parallel DNA sequencing from a very large number of DNA fragments. It works extremely rapidly compared to the standard Sanger-sequencing technique **(Box 4.6)**.[32] FNAC material can be used for NGS to assess the various mutational changes.[44,45]

## Advantages

The advantages of NGS over traditional sequencing are as follows:

- NGS is very rapid compared to Sanger sequencing.
- It is relatively cheaper.
- NGS is a reliable technology with 99.9% accuracy.
- De novo sequencing bypasses the need of gel electrophoresis.

## Types

The various types of DNA sequencing technique are as follows:

- *First-generation sequencing*:
  - Sanger sequencing
  - Chemical degradation technique by Maxim and Gilbert
- *Second-generation sequencing*:
  - Pyrosequencing
  - Illumina Solexa
- *Third-generation sequencing*:
  - Ion semiconductor sequencing
  - Single-molecule, real-time (SMRT) sequencing

JAYPEE BROTHERS

**BOX 4.6: Next-generation sequencing (NGS): An advanced technique that helps to do parallel DNA sequencing from very large number of DNA fragments.**

*Advantages*:
- Rapid
- Cheap
- A reliable technology with 99.9% accuracy
- De novo sequencing bypasses the need of gel electrophoresis

*Types*:
- Pyrosequencing
- Illumina Solexa
- Ion semiconductor sequencing
- Single-molecule, real-time sequencing (SMRT)
- Nanopore technology

*Limitations*:
- *Cost*: The initial cost of the machine is high.
- *Technical knowledge*: Good technical knowledge is required
- *Infrastructure*: Adequate infrastructure is needed
- *Intra-tumor heterogeneity*: Due to tumor heterogeneity, the mutational changes may be missed

*Applications of NGS*:
- Screening of the whole genome
- Detection of the spectrum of mutational changes
- Research study on cancer genome

- *Fourth-generation sequencing*:
- Nanopore technology

## Limitations

- *Cost*: Initial cost of the machine is high.
- *Technical knowledge*: Good technical knowledge is required.
- *Infrastructure*: Adequate infrastructure is needed.
- *Intratumor heterogeneity*: In the FNAC sample, only a tiny tissue part is taken and due to tumor heterogeneity, the mutational changes may be missed.

## Applications of Next-generation Sequencing

- *Screening of the whole genome*: With the help of NGS, both the coding and noncoding part of the whole genome can be sequenced. The data on the noncoding part of the chromosome may throw more light in the cell development.
- *Detection of the spectrum of mutational changes*: Multiple small mutational changes can be detected by NGS.
- *Research study on cancer genome*: The novel genetic changes along with clinical correlation may give rise to the understanding of the pathogenesis of the diseases and prognosis.

# ELECTRON MICROSCOPY

Electron microscopy is a valuable tool in the diagnosis of difficult lesions in FNAC **(Box 4.7)**.[46] However in comparison to IC, this technique is grossly underutilized. The limited use of EM in FNAC may be due to high cost and technical limitations. The other limitations of EM include (1) entrapped non-neoplastic cell within tumor tissue may be the potential source of misinterpretation, (2) lack of specific ultrastructural feature of the cell type in small tissue sample, and (3) only a tiny fraction of tumor tissue can be studied.

Sample for EM tissue is usually collected in a small tube containing 4% glutaraldehyde solution. The small pellet is made by the process of centrifugation followed by processing for the EM.

## Applications

Electron microscopy is used mainly to confirm the diagnosis of undifferentiated malignancies or morphologically equivocal cases. The broad classification of tumors in epithelial, melanomas, neuroendocrine origin, nerve sheath origin, and vascular origin may

**BOX 4.7: Electron microscopy: Ultrastructural study of cells with the help of electron beam rather than light.**

*Collection*: 4% glutaraldehyde solution

*Limitations*:
- Entrapped non-neoplastic cell within tumor tissue
- Lack of specific ultrastructural features in small tissue sample
- A tiny fraction of tumor tissue can be studied.
- High cost of the instrument

*Application*:
- To diagnose undifferentiated malignant tumors such as:
  - Undifferentiated squamous cell carcinoma
  - Melanoma
  - Muscle tumor
  - Nerve sheath tumor
  - Vascular tumor
- Malignant small round cell tumor: Neuroblastoma, rhabdomyosarcoma, and EWS/PNET
- Specific tumors: Langerhans cell histiocytosis

(EWS/PNET: Ewing's sarcoma/primitive neuroectodermal tumor)

JAYPEE BROTHERS

be identified with the help of EM **(Table 4.4)**. The presence of intercellular junction and desmosomes usually indicate epithelial tumor. The demonstration of actin, myosin filament, and Z band are seen in tumors of muscular origin. The demonstration of dense core neurosecretory granules in the cytoplasm indicates neuroendocrine tumors. Similarly, melanocytic tumor contains melanosomes in the cytoplasm. EM also helps in the identification of specific types of tumor. The detection of Birbeck granules in the cytoplasm of the tumor cells is diagnostic of Langerhans cell histiocytosis.

**TABLE 4.4: Electron microscopic finding in various tumors.**

| Tumors | Diagnosis |
|---|---|
| Neuroendocrine tumors | Presence of dense core neurosecretory granules |
| Epithelial tumors | Intercellular junction and desmosomes |
| Muscle tumors | • Aggregates of thick (myosin) and thin (actin) filaments<br>• Electron dense z filaments |
| Melanocytic tumors | Presence of melanosomes |
| Neural tumors | • Mesoaxons<br>• Interdigitating cell processes |
| Vascular tumors | Weibel–Palade bodies |

## REFERENCES


1. Dey P, Luthra UK, George J, Zuhairy F, George SS, Haji BI. Comparison of Thin Prep and conventional preparations on fine needle aspiration cytology material. Acta Cytol. 2000;44(1): 46-50.
2. Chu PG, Weiss LM. Keratin expression in human tissues and neoplasms. Histopathology. 2002;40(5):403-39.
3. Herzig KH, Altmannsberger M, Folsch UR. Intermediate filaments in rat pancreatic acinar tumors, human ductal carcinomas, and other gastrointestinal malignancies. Gastroenterology. 1994;106(5):1326-32.
4. Dey P, Togra J, Mitra S. Intermediate filament: structure, function, and applications in cytology. Diagn Cytopathol. 2014;42(7): 628-35.
5. Pinkus GS, Kurtin PJ. Epithelial membrane antigen-a diagnostic discriminant in surgical pathology: immunohistochemical profile in epithelial, mesenchymal, and hematopoietic neoplasms using paraffin sections and monoclonal antibodies. Hum Pathol. 1985;16(9):929-40.
6. Schnitt SJ, Vogel H. Meningiomas. Diagnostic value of immunoperoxidase staining for epithelial membrane antigen. Am J Surg Pathol. 1986;10(9):640-9.
7. Truong LD, Rangdaeng S, Cagle P, Ro JY, Hawkins H, Font RL. The diagnostic utility of desmin. A study of 584 cases and review of the literature. Am J Clin Pathol. 1990;93(3):305-14.
8. Salter DM, Krajewski AS, Dewar AE. Immunohistochemical staining of non-Hodgkin's lymphoma with monoclonal antibodies specific for the leucocyte common antigen. J Pathol. 1985;146(4):345-53.
9. Wick MR. Immunohistology of neuroendocrine and neuro-ectodermal tumors. Semin Diagn Pathol. 2000;17(3):194-203.
10. Friedman HD, Tatum AH. HMB-45-positive malignant lymphoma. A case report with literature review of aberrant HMB-45 reactivity. Arch Pathol Lab Med. 1991;115(8):826-30.
11. Busam KJ, Iversen K, Coplan KA, Old LJ, Stockert E, Chen YT, et al. Immunoreactivity for A103, an antibody to melan-A (Mart-1), in adrenocortical and other steroid tumors. Am J Surg Pathol. 1998;22(1):57-63.
12. Loeffel SC, Gillespie GY, Mirmiran SA, Miller EW, Golden P, Askin FB, et al. Cellular immunolocalization of S-100 protein within fixed tissue sections by monoclonal antibodies. Arch Pathol Lab Med. 1985;109(2):117-22.
13. Niehans GA, Manivel JC, Copland GT, Scheithauer BW, Wick MR. Immunohistochemistry of germ cell and trophoblastic neoplasms. Cancer. 1988;62(6):1113-23.
14. Tsuura Y, Hiraki H, Watanabe K, Igarashi S, Shimamura K, Fukuda T, et al. Preferential localization of c-kit product in tissue mast cells, basal cells of skin, epithelial cells of breast, small cell lung carcinoma and seminoma/dysgerminoma in human: immunohistochemical study on formalin-fixed, paraffin-embedded tissues. Virchows Arch. 1994;424(2):135-41.
15. Hornick JL, Fletcher CD. Immunohistochemical staining for KIT (CD117) in soft tissue sarcomas is very limited in distribution. Am J Clin Pathol. 2002;117(2):188-93.
16. Yaziji H, Battifora H, Barry TS, Hwang HC, Bacchi CE, McIntosh MW, et al. Evaluation of 12 antibodies for distinguishing epithelioid mesothelioma from adenocarcinoma: identification of a three-antibody immunohistochemical panel with maximal sensitivity and specificity. Mod Pathol. 2006;19(4):514-23.
17. Doglioni C, Dei Tos AP, Laurino L, Iuzzolino P, Chiarelli C, Celio MR, et al. Calretinin: a novel immunocytochemical marker for mesothelioma. Am J Surg Pathol. 1996;20(9):1037-46.
18. Politi E, Kandaraki C, Apostolopoulou C, Kyritsi T, Koutselini H. Immunocytochemical panel for distinguishing between carcinoma and reactive mesothelial cells in body cavity fluids. Diagn Cytopathol. 2005;32(3):151-5.
19. Hecht JL, Lee BH, Pinkus JL, Pinkus GS. The value of Wilms tumor susceptibility gene 1 in cytologic preparations as a marker for malignant mesothelioma. Cancer. 2002;96(2):105-9.
20. Saad RS, Lindner JL, Lin X, Liu YL, Silverman JF. The diagnostic utility of D2-40 for malignant mesothelioma versus pulmonary carcinoma with pleural involvement. Diagn Cytopathol. 2006;34(12):801-6.
21. Bodey B, Bodey B Jr, Kaiser HE. Immunocytochemical detection of prostate specific antigen expression in human breast carcinoma cells. Anticancer Res. 1997;17(4A):2577-81.
22. Nasser SM, Faquin WC, Dayal Y. Expression of androgen, estrogen, and progesterone receptors in salivary gland tumors. Frequent expression of androgen receptor in a subset of malignant salivary gland tumors. Am J Clin Pathol. 2003;119(6):801-6.
23. Kaufmann O, Dietel M. Thyroid transcription factor-1 is the superior immunohistochemical marker for pulmonary adenocarcinomas and large cell carcinomas compared to surfactant proteins A and B. Histopathology. 2000;36(1):8-16.


JAYPEE BROTHERS

24. Lumadue JA, Askin FB, Perlman EJ. MIC2 analysis of small cell carcinoma. Am J Clin Pathol. 1994;102(5):692-4.
25. Riopel M, Dickman PS, Link MP, Perlman EJ. MIC2 analysis in pediatric lymphomas and leukemias. Hum Pathol. 1994;25(4):396-9.
26. Miettinen M, Chatten J, Paetau A, Stevenson A. Monoclonal antibody NB84 in the differential diagnosis of neuroblastoma and other small round cell tumors. Am J Surg Pathol. 1998;22(3):327-32.
27. Skoog L, Tani E. Immunocytochemistry: an indispensable technique in routine cytology. Cytopathology. 2011;22(4): 215-29.
28. Scott AM, Wolchok JD, Old LJ. Antibody therapy of cancer. Nat Rev Cancer. 2012;12(4):278-87.
29. Lofgren L, Skoog L, von Schoultz E, Tani E, Isaksson E, Fernstad R, et al. Hormone receptor status in breast cancer—a comparison between surgical specimens and fine needle aspiration biopsies. Cytopathology. 2003;14(3):136-42.
30. Dey P. Diagnostic flow cytometry in cytology. Singapore: Springer Nature; 2021.
31. Dey P. Role of ancillary techniques in diagnosing and subclassifying non-Hodgkin's lymphomas on fine needle aspiration cytology. Cytopathology. 2006;17(5):275-87.
32. Dey P. Basic and advanced laboratory techniques in histopathology and cytology, 2nd edition. Singapore: Springer Nature; 2023.
33. Remstein ED, Kurtin PJ, Buno I, Bailey RJ, Proffitt J, Wyatt WA, et al. Diagnostic utility of fluorescence in situ hybridization in mantle-cell lymphoma. Br J Haematol. 2000;110(4):856-62.
34. Desmaze C, Brizard F, Turc-Carel C, Melot T, Delattre O, Thomas G, et al. Multiple chromosomal mechanisms generate an EWS/FLI1 or an EWS/ERG fusion gene in Ewing tumors. Cancer Genet Cytogenet. 1997;97(1):12-9.
35. Barranco MA, Alcaraz A, Corral JM, Solé M, Mallofré C, Llopis J, et al. Numeric alterations in chromosomes 7 and 8 detected by fluorescent in situ hybridization correlate with high-grade localized prostate cancer. Eur Urol. 1998;34(5):419-25.
36. O'Leary JJ, Engels K, Dada MA. The polymerase chain reaction in pathology. J Clin Pathol. 1997;50(10):805-10.
37. Gautam U, Srinivasan R, Rajwanshi A, Bansal D, Marwaha RK, Vasishtha RK. Reverse transcriptase-polymerase chain reaction as an ancillary molecular technique in the diagnosis of small blue round cell tumors by fine-needle aspiration cytology. Am J Clin Pathol. 2010;133(4):633-45.
38. Srinivasan R, Gautam U, Gupta R, Rajwanshi A, Vasistha RK. Synovial sarcoma: diagnosis on fine-needle aspiration by morphology and molecular analysis. Cancer. 2009;117(2):128-36.
39. Shibata D, Almoguera C, Forrester K, Dunitz J, Martin SE, Cosgrove MM, et al. Detection of c-Kras mutations in fine needle aspirates from human pancreatic adenocarcinomas. Cancer Res. 1990;50(4):1279-83.
40. Kim DW, Jung SJ, Ha TK, Park HK. Individual and combined diagnostic accuracy of ultrasound diagnosis, ultrasound-guided fine-needle aspiration and polymerase chain reaction in identifying tuberculous lymph nodes in the neck. Ultrasound Med Biol. 2013;39(12):2308-14.
41. Kim SS, Chung SM, Kim JN, Lee MA, Ha EH. Application of PCR from the fine needle aspirates for the diagnosis of cervical tuberculous lymphadenitis. J Korean Med Sci. 1996;11(2):127-32.
42. Manitchotpisit B, Kunachak S, Kulapraditharom B, Sura T. Combined use of fine needle aspiration cytology and polymerase chain reaction in the diagnosis of cervical tuberculous lymphadenitis. J Med Assoc Thai. 1999;82(4):363-8.
43. Barwad A, Sood S, Gupta N, Rajwanshi A, Panda N, Srinivasan R. Human papilloma virus associated head and neck cancer: A PCR-based study. Diagn Cytopathol. 2012;40(10):893-7.
44. Qiu T, Guo H, Zhao H, Wang L, Zhang Z. Next-generation sequencing for molecular diagnosis of lung adenocarcinoma specimens obtained by fine needle aspiration cytology. Sci Rep. 2015;5:11317.
45. Vigliar E, Malapelle U, de Luca C, Bellevicine C, Troncone G. Challenges and opportunities of next-generation sequencing: a cytopathologist's perspective. Cytopathology. 2015;26(5): 271-83.
46. Berkman WA, Chowdhury L, Brown NL, Padleckas R. Value of electron microscopy in cytologic diagnosis of fine-needle biopsy. AJR Am J Roentgenol. 1983;140(6):1253-8.

JAYPEE BROTHERS

For detailed information on pathology books, visit our website www.jaypeebrothers.com, for detailed information on pathology books, visit our website

# Fine Needle Aspiration Cytology

## Interpretation and Diagnostic Difficulties

***Salient Features***

- In this book, the author has described the characteristic diagnostic features and differential diagnosis of various lesions on fine needle aspiration cytology.
- Detailed cytology, immunocytochemistry, and molecular genetics of all the lesions have also been discussed.
- This book contains all the recent information in the field of cytology and a large number of whole slide imaging (Digital Slides).
- This is a simple, concise, and illustrative book.
- There are a large number of tables, boxes, and microphotographs in every chapter.
- The review section of the book is helpful for self-assessment.
- This is a complete book on fine needle aspiration cytology and will be very helpful to all the students and practicing cytologists.

**Pranab Dey** is the former Professor of Cytology in Postgraduate Institute of Medical Education and Research, Chandigarh, India. Currently, he is working as Director of Pathology and Transfusion Medicine in National Institute of Medical Sciences (NIMS), Jaipur, Rajasthan, India.

He is one of the eminent cytologists in India. He is also the author of the book "Diagnostic Cytology". He has been actively engaged in teaching and research in Cytology for more than two decades. He has a large number of research works and reviews in various international journals of pathology and cytology.

*Printed in India*

**Available at all medical bookstores or buy online at www.jaypeebrothers.com**

**JAYPEE BROTHERS**
**Medical Publishers (P) Ltd.**
**EMCA House, 23/23-B, Ansari Road, Daryaganj, New Delhi - 110 002, INDIA**
**www.jaypeebrothers.com**

Join us on facebook.com/JaypeeMedicalPublishers

Shelving Recommendation
**PATHOLOGY**

ISBN 978-93-5696-966-7