eebrothers.com, for detailed information on pathology books, visit our website www.jaypeebrothers.com, for detailed information on pathology books

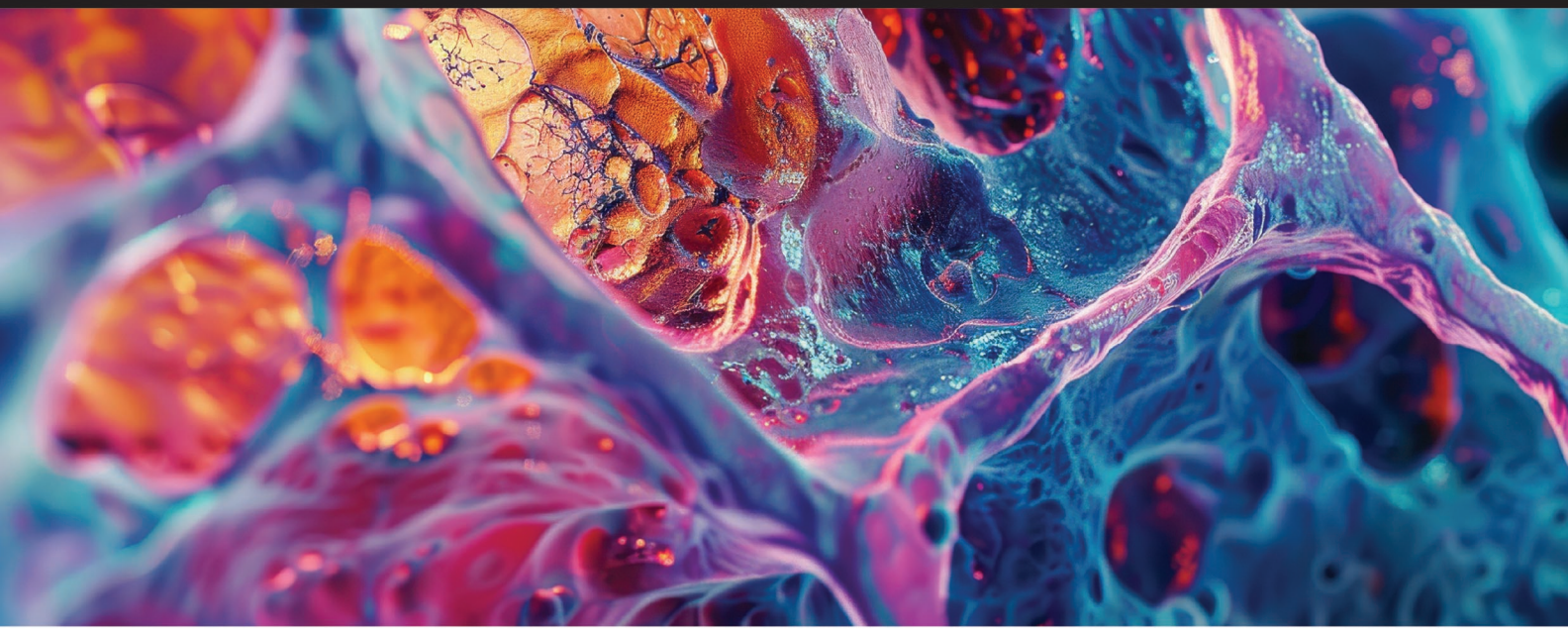

Comprehensive Workbook of
Practical Pathology

As per the Revised Competency-based Medical Education Curriculum 2024 (NMC)

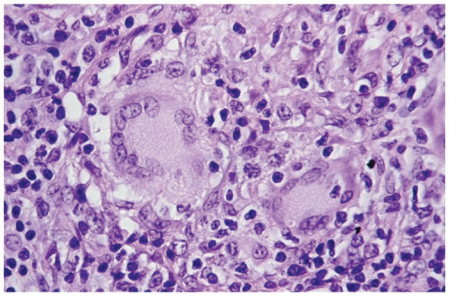
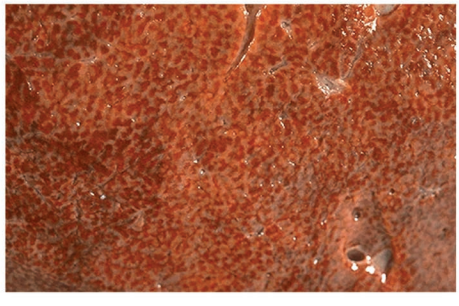
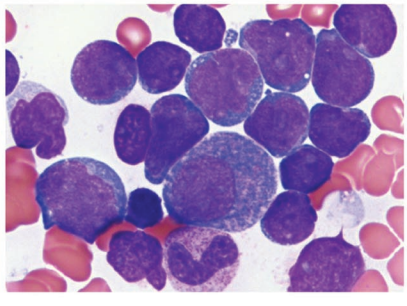

diginerve®
A Jaypee Initiative
• Video Lectures • Dr. Wise AI Chatbot
• Question Bank • Notes
Download App

ML Gupta

2nd Edition

JAYPEE

Contents

1. Cell Injuries and their Manifestations 1
2. Inflammation 8
3. Infarction 16
4. Neoplasia 21
5. Amyloidosis 28
6. Blood Sample Collection 33
7. Hematological Tests 40
8. Microcytic Anemia 55
9. Macrocytic Anemia 61
10. Hemolytic Anemia 67
11. Tumors of Lymph Node 76
12. Tuberculous Lymphadenitis 85
13. Coagulation Disorders 90
14. Blood Components 101
15. Blood Group and Cross Match 108
16. Urine Examination 117
17. Semen Analysis and Thyroid Function Tests 133
18. Liver Function Tests 144
19. Kidney Function Test 153
20. Gastrointestinal Disorders 162
21. Liver Diseases and Tumors 173
22. Lung Disorders 180
23. Disorders of Pericardium 187
24. Disorders of Kidney 193
25. Disorders of Male Genital Tract 202
26. Disorders of Female Genital Tract 209
27. Phyllodes Tumor 219
28. Breast Tumors 223
29. Disorders of Adrenal Gland 229
30. Disorders of Bone 238
31. Tumors of Skin 250
32. CSF Examination 259

Inflammation

2

EXERCISE

COMPETENCY

PA3.4: Identify and describe acute and chronic inflammation in gross and microscopic specimens
2.1 Acute appendicitis
2.2 Chronic cholecystitis

INFLAMMATION

- It is the local response of living mammalian tissue to injury due to any injurious agent.
- It is a body defense reaction to eliminate/limit the spread of injurious agents.

Signs of Inflammation

Five Cardinal Signs of Inflammation

1. Rubor (Redness)
2. Tumor (Swelling)
3. Calor (Heat)
4. Dolor (Pain)
5. Functio lesa (Loss of function)

Types of Inflammation

- **Acute inflammation:** It is an early body reaction of short duration and rapid onset.
- **Chronic inflammation:** It may follow after acute inflammation, if acute inflammation persist for long duration or it may be chronic since beginning, and persist for long duration due to stimulus of chronic inflammation.

Acute Inflammatory Cells

- Circulating leukocytes (neutrophils, lymphocytes, monocytes, eosinophils, basophils)
- Plasma cells
- Tissue macrophages

Morphological Types of Inflammation

- **Serous inflammation:** It is characterized by collection of watery low protein content fluid derived from plasma or serous lining of serous cavities. For example, burn, viral vesicle
- **Fibrinous inflammation:** Deposition of fibrin at inflammatory site is known as fibrinous inflammation. It is seen in case of severe injury.
- **Pseudomembranous inflammation:** Inflammation of mucus membrane with diphtheria leads to necrosis of mucosa by diphtheria toxins. Denuded epithelium and plasma form a membrane (false membrane)

JAYPEE BROTHERS

- **Suppuration (abscess formation):** Intense inflammation leads to collection of neutrophils, necrotic debris and edematous fluid forming purulent exudative fluid. It is seen in inflammation associated with pyogenic bacteria. For example, boils, carbuncle, furuncle. When collected in a closed cavity, it results in abscess formation
- **Ulcer:** Breech in the continuity of skin or mucus membrane is called ulcer. For example, typhoid, tuberculosis, amebiasis, varicose ulcer
- **Cellulitis:** It is spreading soft tissue inflammation, because of hyaluronidase enzyme released by some bacteria. Hyaluronidase facilitates the spread on inflammation faster.
- **Bacterial infections of blood:** Blood is a liquid tissue therefore, inflammation leads systemic effects. Injurious agents may reach to the circulation directly from environment of any other lesion at different site.

2.1 ACUTE APPENDICITIS

Appendix is a vestigial organ. It varies in length from 4 to 20 cm. Acute appendicitis is an acute inflammation of appendix. It typically affects those in their second or third decade.

Etiology

It is caused by direct **luminal obstruction**, usually secondary to a faecolith or lymphoid hyperplasia, impacted stool or, rarely, an appendiceal or cecal tumor. Obstruction of lumen leads to increased intraluminal pressure which leads to ischemic injury. Stasis of luminal contents favor bacterial proliferation and triggers inflammatory response including tissue edema and neutrophilic infiltration.

Clinical Presentation

- The main symptom of appendicitis is **abdominal pain**. This is initially **periumbilical**, dull, and poorly localized, but later **migrates to the right iliac fossa**, where it is well-localized and sharp.
- **Vomiting, anorexia, nausea,** diarrhea, or constipation.

Differential Diagnosis

- **Gynecological:** Ovarian cyst rupture, ectopic pregnancy, pelvic inflammatory disease
- **Renal:** Ureteric stones, urinary tract infection, pyelonephritis
- **Gastrointestinal:** Mesenteric adenitis, diverticular disease, inflammatory bowel disease, or Meckel's diverticulum.
- **Genitourinary:** Testicular torsion, epididymo-orchitis

Laboratory Tests

- **Urinalysis** should be done for all patients with suspected appendicitis to exclude any renal or urological cause. For any woman of reproductive age, **a pregnancy test** is also essential.
- **Routine blood**: CBC and CRP, (to assess for raised inflammatory markers)

Complications

- Perforation
- Pylephlebitis with portal venous thrombosis
- Liver abscess
- Bacteremia

Gross Appearance

Appendix appears swollen. Outer surface shows congestion and prominent blood vessels. It may be covered with serofibrinous purulent exudates. On cutting the specimen, lumen may show presence of fecolith, worms, stone or tumor.

Microscopic Examination

Neutrophilic infiltration is seen throughout all the layers especially mucosa, submucosa and muscularis propria, with lymphoid tissue proliferation.

Focal superficial ulceration of mucosa may be seen.

JAYPEE BROTHERS

Exercise 2.1



Inflamed appendix

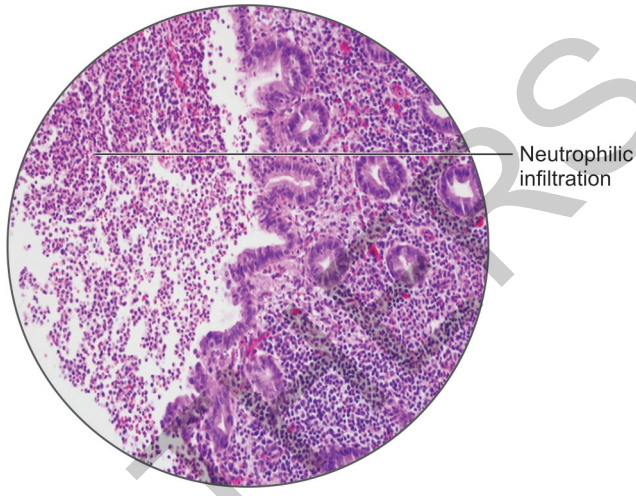

Acute appendicitis

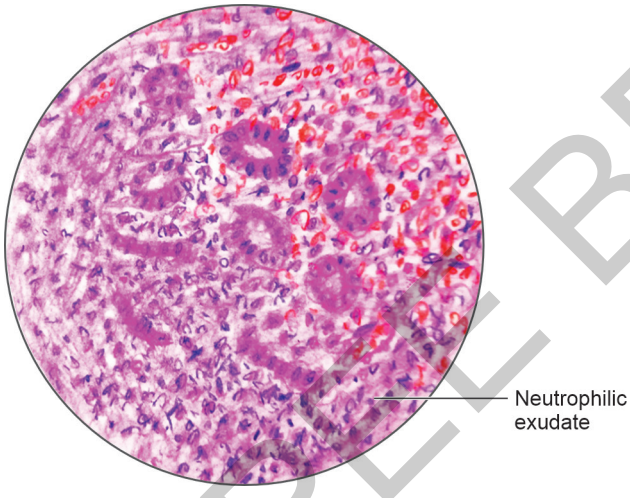

Acute appendicitis



Draw a labeled diagram

JAYPEE BROTHERS

CHRONIC INFLAMMATION

It is defined as inflammation of prolonged duration, in which active inflammation, tissue injury and healing proceed simultaneously.

Characteristic Features

- Mononuclear infiltrate is composed of lymphocytes, macrophages and plasma cells
- Tissue destruction
- Repair, i.e., angiogenesis and fibrosis

Types

- Acute inflammation progresses to chronic inflammation, because of:
  - Persistence of injurious agent
  - Interference in normal process of healing.

For example, peptic ulcer
- Chronic inflammation, since beginning when:
  - Caused by less noxious injurious agent
  - Inflammation fails to resolve. For example:
    - Viral infections
    - Microbial infection (TB, syphilis, fungal)
    - Toxic agents (nondegradable)
      - Exogenous - Silica
      - Endogenous - Atherosclerosis
    - Autoimmune diseases

Chronic Inflammatory Cells

1. **Macrophages:** Macrophages are monocytes in bloodstream. Macrophages are labeled by different names in the tissue, e.g., Kupffer cells in liver
   Migration of macrophage is governed by chemotactic factors. Macrophages are activated by interferon, endotoxin and fibronectin.
2. **Lymphocytes:** Mobilization of lymphocytes takes place by
   - Immune stimuli like antibody mediated and cell mediated
   - Nonimmune stimuli like trauma and infarction

   Macrophage–lymphocyte interaction: Lymphocytes when activated, convert macrophages, into the activated macrophages with the help of γ interferon. Activated macrophage secretes cytokines (IL-1) which regulate T lymphocyte activity.
3. **Eosinophils:** Eosinophils move in response to chemotactic factor eotaxin (cytokine) released from leukocytes and epithelial cells. These cells are involved in IgE-mediated immune reaction and parasitic infections. Eosinophils contain major basic protein which is highly toxic to parasite and epithelial cells.
4. **Mast cells:** Mast cells express receptors for Fc portion of IgE antibody and release mediators when it binds with Fc portion of IgE.

2.2 CHRONIC CHOLECYSTITIS

Chronic cholecystitis is chronic inflammation of gallbladder, typically secondary to gallstones.

Etiopathogenesis

- Show female predominance, associated with cholelithiasis in > 90% of cases
- Risk factors correspond to those that increase risk of cholelithiasis: Female sex, obesity, rapid weight loss, pregnancy and advanced age

Clinical Features

- Does not always cause clinical symptoms
- Can present with dull right upper quadrant pain that radiates to mid back or right scapula
- Murphy sign: Right upper abdominal pain with deep palpation
- Abdominal discomfort often related to fatty food ingestion
- Nausea, vomiting, bloating, flatulence

Gross Description

- Nearly normal to thickened gallbladder wall
- Gallbladder may appear shrunken due to marked fibrosis
- Severe cases show adhesions to adjacent organs
- Variable mucosal appearance—can be granular, ulcerated, polypoid

JAYPEE BROTHERS

Microscopic Features

- Variable mucosal changes: Normal, atrophic, ulcerated, hyperplastic
- Predominantly mononuclear infiltrates are seen in lamina propria, which may extend into the muscularis and pericholecystic tissues
- Inflammatory infiltrate predominantly consists of T lymphocytes, with some plasma cells, histiocytes and occasional eosinophils
- Hypertrophy of muscularis and variable degrees of mural fibrosis, elastosis, neural hyperplasia

Exercise 2.2

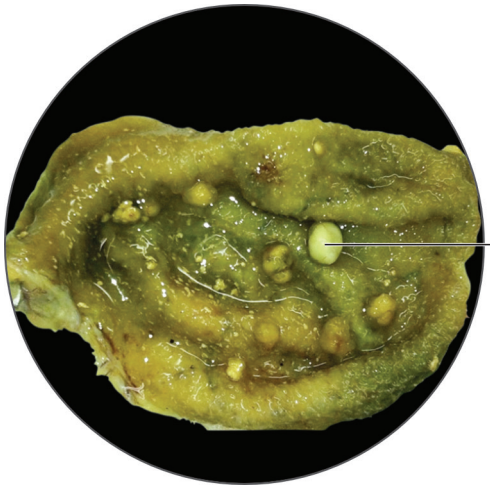

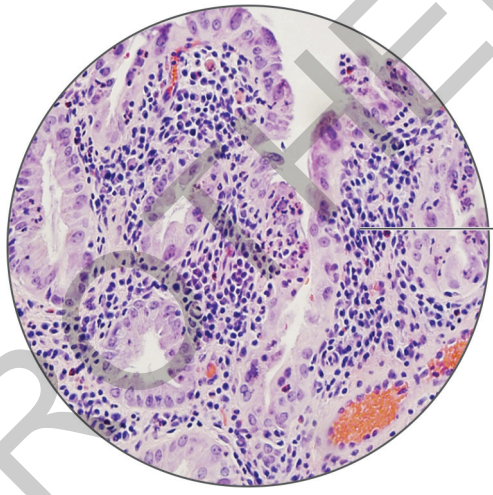

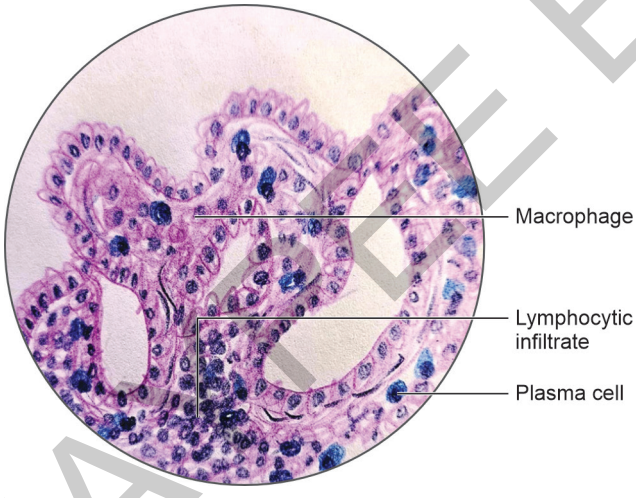

Chronic cholecystitis

Draw a labeled diagram

JAYPEE BROTHERS

VIVA VOCE QUESTIONS

1. Define inflammation and enumerate its cardinal signs.
2. What is acute appendicitis? How will you evaluate a case of acute appendicitis?
3. Describe gross and microscopic features of acute appendicitis.
4. How do you characterize a chronic inflammation?
5. Enumerate various inflammatory cells in chronic inflammation and describe their role.
6. What is chronic cholecystitis? Describe clinical features and its causes.
7. Describe gross and microscopic features of chronic cholecystitis.

JAYPEE BROTHERS

JAYPEE BROTHERS

JAYPEE BROTHERS

for detailed information on pathology books, visit our website www.jaypeebrothers.com, for detailed information on pathology books, visit our website

Comprehensive Workbook of
Practical Pathology

This meticulously structured workbook offers 2nd MBBS students an in-depth understanding of pathological principles, disease mechanisms, and diagnostic procedures. With a focus on hands-on practical knowledge, it combines detailed illustrations, high-yield concepts, and clear step-by-step methodologies to help students master gross examination, microscopic examination, and clinical correlations. Special emphasis is placed on hematology, covering blood cell morphology, common hematological disorders, and techniques like blood smear examination, helping students develop a strong foundation in diagnosing blood-related diseases.

Perfect for examination preparation, this resource is designed to strengthen your analytical skills and deepen your comprehension of pathology as it applies to real-world medical practice and help you ace your practicals, viva, and exams with confidence.

The 1st edition of my Comprehensive Workbook of Practical Pathology received an overwhelmingly positive response from students and educators alike. It was praised for its clarity, concise explanations, structured approach, and high-quality histological images, making pathology practicals more engaging and easier to understand. Encouraged by this appreciation, I am proud to launch the 2nd edition, with the objectives of the New Competency Based Medical Education Curriculum (CBME) Guidelines, 2024 – National Medical Commission, which builds upon the strengths of the first while incorporating new case studies, updated images, and enhanced explanations to provide an even more comprehensive and student-friendly learning experience.

I extend my heartfelt gratitude to all the students, faculty, and readers who supported the first edition, and we look forward to making this new edition an even greater success in your pathology journey.

ML Gupta MBBS MD (Pathology) is a distinguished academician and renowned pathologist with extensive experience in teaching, research, and clinical pathology. With a passion for medical education, he has dedicated his career to simplifying complex pathological concepts for undergraduate and postgraduate students.

He has been actively involved in curriculum development, practical training, and diagnostic pathology, making significant contributions to medical education. His expertise is reflected in his publications, which are known for their clarity, structured approach, and clinical relevance.

Through this Pathology Practical Workbook, Dr Gupta aims to bridge the gap between theory and practical applications, helping 2nd MBBS students develop a strong foundation in pathology.

Printed in India

Available at all medical bookstores or buy online at www.ejaypee.com

JAYPEE BROTHERS
Medical Publishers (P) Ltd.
EMCA House, 23/23-B, Ansari Road,
Daryaganj, New Delhi - 110 002, INDIA
www.jaypeebrothers.com

Join us on facebook.com/JaypeeMedicalPublishers
Follow us on instagram.com/JaypeeMedicalPublishers

Shelving Recommendation
PATHOLOGY

ISBN 978-93-6616-026-9