eebrothers.com, for detailed information on medicine books, visit our website www.jaypeebrothers.com, for detailed information on medicine books

ADVANCING STROKE CARE IN INDIA

Principles and Practices



Editor-in-Chief
Nirmal Surya

Editor
Pawan Ojha

JAYPEE

Contents

1. **Diagnosis of Acute Ischemic Stroke—Minimalistic Approach** 1
   PK Maheshwari, Akhilesh Kumar Singh, Navneet Agrawal

2. **Localization of Stroke from Clinical Phenotype** 11
   Soumyadeep Ghosh, Subhra Sankar Sen, Uddalak Chakraborty, Biman Kanti Ray

3. **Arterial Imaging in Stroke** 22
   Sambha Murthy Krishna Mohan Mavuru, Amit Kulkarni, Pratik Kishore, PN Sylaja

4. **Uncommon Causes of Stroke** 40
   Pawan Ojha, Harshil Bagadia, Salil Uppal, Trilochan Shrivastava

5. **Secondary Prevention of Stroke** 54
   Mrinal Kanti Roy, Debaleena Mukherjee

6. **Intravenous Thrombolysis in Acute Ischemic Stroke** 75
   Uddalak Chakraborty, Arpan Dutta

7. **Interventional Treatment for Acute Stroke** 90
   Subhadeep Gupta, Uddalak Chakraborty, Soumozit Banerjee, Deep Das

8. **Intracerebral Hemorrhage** 111
   Girish Menon Ramachandran, Ajay Hegde, Anand Alurkar

9. **Subarachnoid Hemorrhage—Physician's Perspective** 125
   Pavithra Ravi, Mugundhan Krishnan, Sathish Kumar Mallikarjuna

10. **Cerebral Venous Thrombosis** 139
    Shrivarthan R, Guhan Ramamurthy, Balamurugan N

11. **Cerebral Small Vessel Disease and Vascular Dementia** 153
    Lakshmi Narasimhan Ranganathan, Shripal Shah, Rithvik Ramesh, Ch Anuhya

12. **Stroke in Pregnancy** 165
    Vijaya Pamidimukkal, Monika Singla

13. Pediatric Stroke **180**
Minal Vikram Kekatpure, KP Vinayan

14. Stroke Rehabilitation **208**
Nirmal Surya, Hitav Someshwar, Jayanta Roy

15. Stroke Center Accreditation in India **220**
Arvind Sharma, Neeraj Lal, VG Pradeep Kumar, Bhupendra Kumar Rana

Index ***233***

12
CHAPTER

Stroke in Pregnancy

Vijaya Pamidimukkal, Monika Singla

ABSTRACT

Stroke is a significant cause of maternal morbidity and mortality, though it remains rare during pregnancy. Strokes in pregnant women are often linked to pregnancy-specific conditions, which can be managed to reduce stroke risk, making it a largely preventable event. The incidence of stroke is rising in certain populations due to factors like increasing maternal age, underlying health conditions, obesity, and hypertension. Although rare, a stroke during pregnancy can have serious consequences for both the mother and the fetus, with the highest risk occurring during the third trimester and up to six weeks postpartum. During this period, hypertensive disorders of pregnancy (such as preeclampsia and eclampsia) and gestational hypercoagulability are most common. Pregnancy-related physiological changes increase susceptibility to stroke by affecting the cardiovascular and hemostatic systems. Increased clotting factors elevate the risk of ischemic strokes, while heightened blood volume and cardiac output can contribute to hypertension and vascular complications. Pregnancy-related changes in blood pressure and vessel elasticity further increase the risk of hemorrhagic strokes, especially in women with preeclampsia. Strokes during pregnancy are typically classified as ischemic or hemorrhagic. Ischemic strokes, caused by blocked blood flow to the brain, are often linked to hypercoagulability and hypertension. Hemorrhagic strokes result from ruptured blood vessels, leading to bleeding in the brain. Factors like preeclampsia, aneurysms, and arteriovenous malformations can exacerbate hemorrhagic strokes, with increased intracranial pressure worsening brain injury. This review will examine the causes, risk factors, clinical features, diagnostic methods, management strategies, and maternal and fetal outcomes associated with stroke during pregnancy.

JAYPEE BROTHERS

INTRODUCTION

Affecting one in four adults, stroke is a major cause of death and disability around the world.[1] Stroke in young is on the rise and in young females, pregnancy confers threefold higher risk.[2] The incidence of pregnancy-related strokes has recently been estimated to be 34 in 100,000 pregnancies.[3]

Stroke during pregnancy is a serious condition with significant implications for maternal and fetal health, morbidity, and mortality. It occurs most frequently during the third trimester and the postpartum period (6 weeks following delivery), coinciding with the highest incidence of hypertensive disorders and hypercoagulability associated with pregnancy.[4,5] Most strokes in general population are ischemic (80–85%); but in pregnancy, ischemia, hemorrhage, and subarachnoid hemorrhage (SAH) are similar in contribution to etiology with intracerebral hemorrhage (ICH) being the single greatest cause of maternal death from stroke.[3,5,6]

Recent studies showed the postpartum stroke is on the rise attributed to factors like older maternal age, obesity, and increase in incidence of hypertensive disorders of pregnancy.[7] The unique physiology and pathophysiology of pregnancy contribute to maternal stroke risks and can result in unusual stroke mechanisms and presentations. The neurologist should be familiar with rapid recognition and management of maternal stroke as well as in primary and secondary prevention.[8,9]

RISK FACTORS OF STROKE IN PREGNANCY[2,10,11]

Stroke in pregnancy can be due to ischemia, hemorrhage, or venous occlusion. Most often, it occurs close to the time of delivery (40%) and in the early postpartum (50%) with a lower incidence (10%) earlier in pregnancy.[4,12] In general, the cause of stroke in pregnancy may be related to preexisting maternal risk factors like systemic hypertension and arteriovenous malformation (AVM). Some risk factors are related to physiological changes in pregnancy (e.g., increase blood volume, hypercoagulability) or disorders of pregnancy (e.g., eclampsia, HELLP syndrome).[13] **Figure 1** shows maternal, fetal, and placental risk factors related with stroke. **Box 1** shows the risk factors related with stroke during pregnancy and nonpregnant women.

PATHOPHYSIOLOGY OF MATERNAL STROKE

The pathophysiology of stroke during pregnancy is complex, involving multiple adaptive and maladaptive changes in the maternal vasculature, immune system, and coagulation pathways **(Fig. 2)**.

Cardiovascular Adaptation[14]

- *Cardiac output and remodeling*: During pregnancy, cardiac output increases by up to 50%, that can predispose pregnant women to arrhythmias, especially in those with pre-existing cardiac conditions.
- *Vasodilation and increased venous capacitance*: Elevated levels of progesterone and relaxin during pregnancy promote systemic vasodilation, increased vascular compliance, and venous capacitance. This contributes to venous stasis, particularly in late pregnancy when the gravid uterus compresses the pelvic veins, increasing the risk of venous thromboembolism (VTE).

JAYPEE BROTHERS

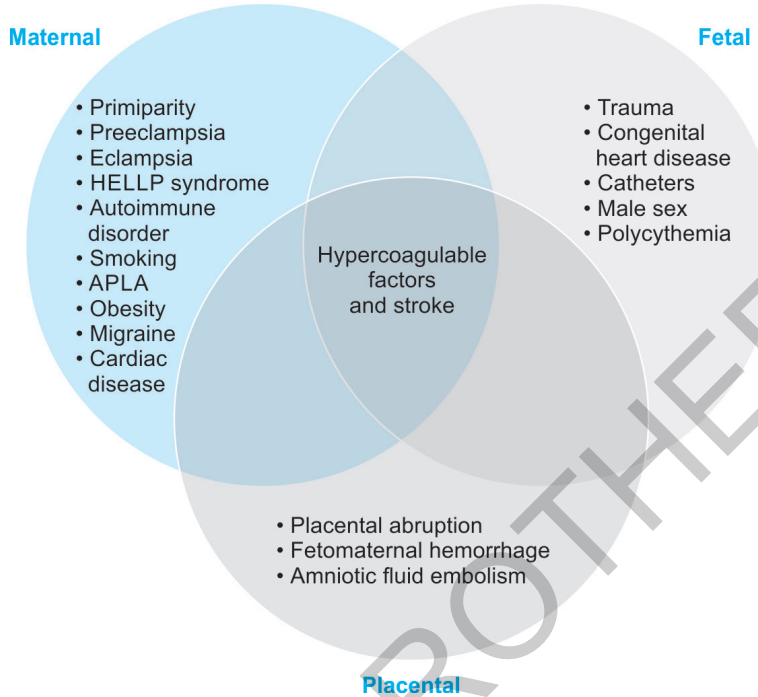

FIG. 1: Maternal, fetal, and placental risk factors related with stroke in pregnancy.
(APLA: antiphospholipid antibody; HELLP: hemolysis, elevated liver enzymes, and low platelets)

BOX 1 Risk factors related with stroke during pregnancy and nonpregnant state.

Nonpregnancy related:
- Chronic hypertension
- Older age
- Migraine—history of migraines, particularly those with aura
- Antiphospholipid syndrome
- Obesity—endothelial dysfunction
- *Cardiac disease*: Pre-existing heart conditions, such as atrial fibrillation, congenital heart defects, and valve disease
- Smoking
- Infection
- Chronic kidney disease
- Genetic stroke syndromes (e.g., moyamoya syndrome)
- Arteriovenous malformation
- *Diabetes*: Pregestational diabetes—contributes to endothelial dysfunction
- Primary hypercoagulable states
- Sickle cell disease
- Systemic lupus erythematosus

Pregnancy-related:
- *Hypertensive disorders of pregnancy*:
  - Gestational hypertension
  - Preeclampsia/eclampsia
  - HELLP (hemolysis, elevated liver enzymes, and low platelets) syndrome (Severe form of preeclampsia)
- Hypercoagulable state and dehydration—cerebral venous thrombosis
- Hyperemesis gravidarum
- Gestational diabetes mellitus
- Cesarean delivery
- Assisted reproductive technology
- Metastatic choriocarcinoma
- Peripartum cardiomyopathy

JAYPEE BROTHERS

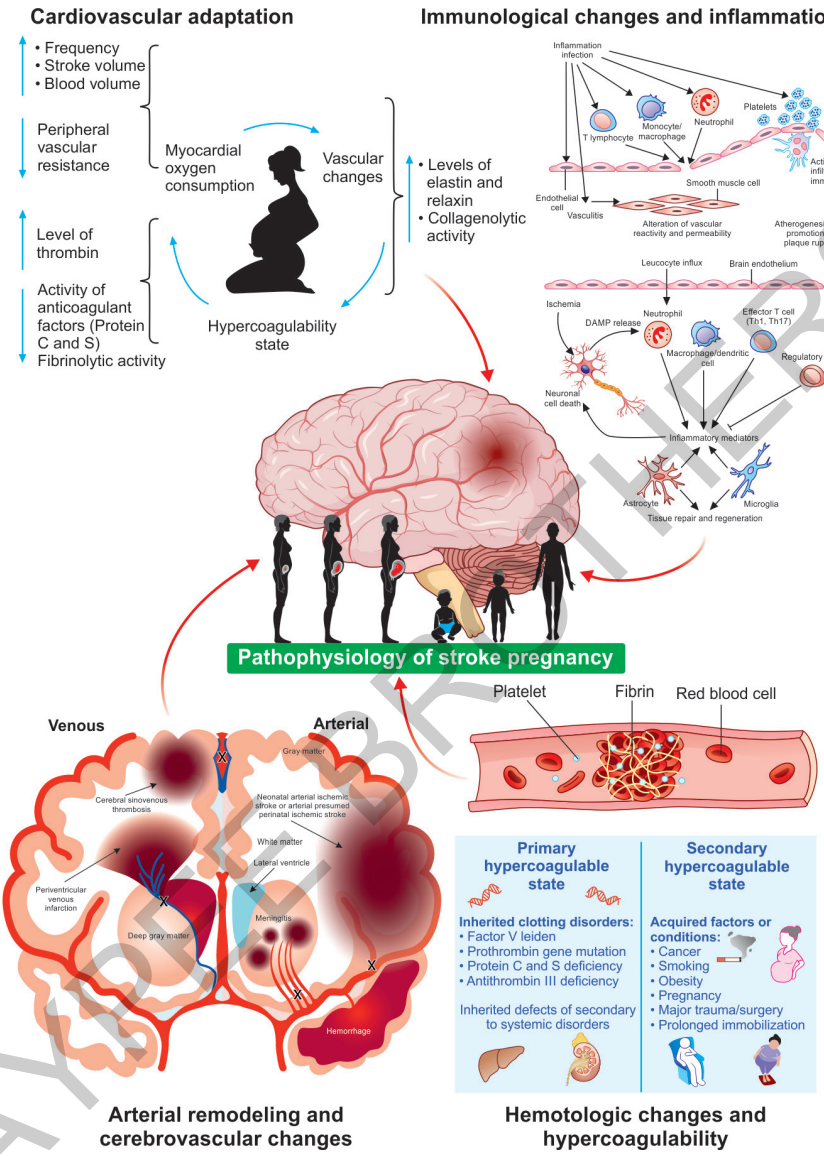

FIG. 2: Pathophysiology of stroke in pregnancy.

- *Sympathetic activation*: Pregnancy induces heightened sympathetic vasomotor activity, in women with hypertensive disorders, that leads to increased vascular tone and contributes to complications such as reversible cerebral vasoconstriction syndrome (RCVS).

Hematologic Changes and Hypercoagulability

- *Dilutional anemia and coagulation shifts*: Pregnancy causes volume expansion, leading to dilutional anemia (lower hematocrit levels) and changes in clotting factor levels.

JAYPEE BROTHERS

- *Procoagulant state*: The procoagulant state of pregnancy increases the risk of both venous and arterial thromboembolic events. The placenta secretes antifibrinolytic factors (plasminogen activator inhibitors), fibrinogen increases, fibrinolytic activity decreases, increase in factors VIII, IX, X, protein S decreases, functional protein C resistance, prothrombin fragments increase, this contributes to an elevated risk for ischemic stroke.[15]

Immunologic Changes and Inflammation

- *Inflammatory cytokines*: Pregnancy is characterized by dynamic immunomodulation. In the first trimester, there are elevated levels of cytokines such as IL-6, C-reactive protein, elevated T-helper (TH) 1 activity, and tumor necrosis factor-α. These cytokines can adversely affect endothelial function, increasing the likelihood of thrombus formation and ischemic stroke.[16]
- *Postpartum inflammation*: As pregnancy progresses toward labor, a pro-inflammatory state emerges with upregulation of nuclear factor kappa B (NF-κB). This inflammatory state may play a role in the pathogenesis of preeclampsia, preterm birth, and peripartum cardiomyopathy, the risk factors for stroke.[17]

Arterial Remodeling and Cerebrovascular Changes[18]

- *Arterial stiffness*: Maternal arterial stiffness increases significantly during pregnancy, particularly in the third trimester. Increased stiffness of the carotid artery correlates with elevated systolic blood pressure.
- *Cerebral arterial remodeling*: During pregnancy, the cerebral vasculature undergoes adaptive remodeling. This includes dilation of arterioles and an enhanced ability to resist systemic vasoconstrictors. Failure to adaptations during hypertensive pregnancy disorders may lead to cerebral edema, vasogenic edema, and cerebral vasoconstriction.
- *Blood–brain barrier (BBB) and pregnancy*: Pregnancy-associated changes in vascular permeability can lead to increased permeability of the BBB.

ACUTE ISCHEMIC STROKE MANAGEMENT DURING PREGNANCY AND POSTPARTUM

The highest incidence of ischemic stroke in pregnancy occurs during the puerperium followed by the third trimester.

Maternal health is vital for fetal wellbeing—All decisions need to consider the combination of benefits and risks to both mother and baby. So the initial questions to be addressed should be *"What would I do if she was not a pregnant"* (best practices in stroke care) and *"What would I do if she is pregnant without stroke"* (best obstetrical care). This is the basis for approach to stroke in pregnancy—first the ideal investigation or treatment plan outside the pregnancy and second what needs to be modified due to pregnancy.

Interdisciplinary team approach is preferred to address the complex care management and decisions (neurologists, vascular specialists, obstetricians, fetal medicine specialists, and anesthesiologists) in consultation with patient and family.

JAYPEE BROTHERS

The factors to be considered:

- Type of stroke and stroke etiology
- Window period and stroke severity
- Diagnostic imaging
- Acute treatments—IV thrombolysis and endovascular thrombectomy (EVT)
- Stage of pregnancy

Type of Stroke and Stroke Etiology

Most commonly due to cardioembolism caused by paradoxical embolism in the setting of patent foramen ovale or pulmonary shunt, preexisting cardiac disease, or peripartum cardiomyopathy, other causes of arterial ischemic stroke include cervical artery dissection, posterior reversible encephalopathy syndrome (PRES), arterial vasospasm in association with RCVS **(Figs. 3A and B)**, arterial thrombosis due to thrombophilias, or rarer conditions such as moyamoya vasculopathy.

Window Period and Stroke Severity

Any pregnant and postpartum patient presenting with acute focal neurological deficit should be assessed clinical examination and NIHSS scoring in accordance with current guidelines.

Diagnostic Imaging

When an acute stroke is suspected given the severe maternal risk caused by potential delay in diagnosis when compared to the minimal risk to the fetus with computed tomography (CT) imaging, it is recommended to conduct a CT scan of the head within minutes of hospital arrival, without first establishing pregnancy but universal covering of abdomen with lead apron.

Immediate brain imaging is critical in decision making, NCCT scan is the fastest and most accessible modality of choice. The dose of ionizing radiation to the fetus from a noncontrast head CT is 0.001–0.01 mGy, far below the 50 mGy

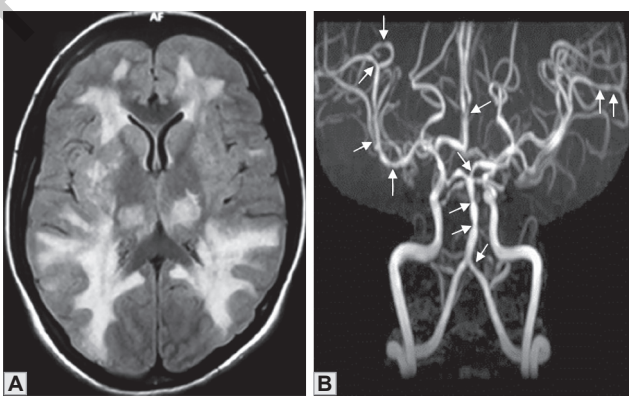

FIGS. 3A AND B: (A) PRES; and (B) RCVS: Intracranial angiography shows multifocal narrowing of intracranial vessels (arrows) with dilatation giving beaded appearance of cerebral arteries.

(PRES: posterior reversible encephalopathy syndrome; RCVS: reversible cerebral vasoconstriction syndrome)

JAYPEE BROTHERS

threshold above which adverse fetal effects become a concern, CT angiography should be obtained when large vessel occlusion or rupture of a vascular lesion is suspected. Despite, a theoretical risk of neonatal hypothyroidism is not demonstrated in human studies.

Stroke MRI brain is even safer if immediately available to diagnose especially in extended window period of >4½ hours, but Gadolinium contrast is contraindicated during pregnancy. Time of flight MRI angiography can be used to assess large vessel occlusion.

Hyperacute Stroke Treatments: IV Thrombolysis and Endovascular Therapies

Acute therapies: Case series showed that IV thrombolysis and mechanical thrombectomy can be performed safely and successfully in otherwise eligible pregnant patients.[19,20] Alteplase and tenecteplase, which have a molecular weight of 59 kDa, do not cross the placenta, and therefore do not pose direct intracranial or systemic bleeding risks to the fetus. Although the involvement of an obstetrician is essential to assess pregnancy-related bleeding risks like placental abruption which need management. According to the American Heart Association and American Stroke Association guidelines, thrombolysis is not contraindicated during pregnancy when deficits are disabling and bleeding risks are manageable. While data on thrombolytics in the postpartum period are limited, they may be considered on a case-by-case basis.

Endovascular thrombectomy: Pregnancy should not be considered a contraindication to angiography and EVT for proximal large-vessel occlusions causing acute disabling stroke.[21]

For patients with large-vessel occlusions eligible for and with rapid access to EVT, proceeding directly to EVT without administering intravenous alteplase could be considered. Efforts to reduce the risk of fetal injury such as abdominal shielding and judicious use of X-ray exposures are reasonable.

Stage of Pregnancy

Gestational age should be established where possible, this will allow for the provision of appropriate risk/benefit information on available management strategies and information on the potential impacts to both mother and fetus.

CEREBRAL VENOUS THROMBOSIS IN PREGNANCY: PATHOPHYSIOLOGY, RISK FACTORS, DIAGNOSIS, AND TREATMENT

Cerebral venous thrombosis (CVT) is responsible for one-third of pregnancy-related strokes, with 75% of cases occurring in the postpartum period. It occurs due to clot in the cerebral venous system or dural sinuses, leading to venous congestion, cerebral edema, and potentially, venous hemorrhagic infarction. This condition can be challenging to diagnose and manage, given its variable presentation and the complexities of treatment during pregnancy.[22]

JAYPEE BROTHERS

Cerebral venous thrombosis risk factors include obesity, preeclampsia, infection, dehydration, i.e., hyperemesis gravidarum. Patients typically present with headaches, blurred vision, seizures, focal neurological deficits, and altered sensorium. It is important to rule out underlying thrombophilias like antiphospholipid antibody (APLA) syndrome in addition to pregnancy-related hypercoagulable state.

Papilledema may be observed during the physical examination, indicating raised intracranial pressure. The diagnosis of CVT is typically based on clinical suspicion and confirmed by imaging. A noncontrast CT scan usually shows bilateral hemorrhagic infarcts with empty delta sign. Magnetic resonance imaging (MRI) and magnetic resonance venography (MRV) can be confirmatory.

The standard treatment for CVT involves therapeutic anticoagulation that prevents clot propagation and promotes recanalization of the affected venous sinuses. The choice of anticoagulant must consider the safety profile during pregnancy and breastfeeding. Low-molecular-weight heparin (LMWH) is typically preferred in pregnancy due to its lower risk of placental transfer and hemorrhage, whereas warfarin is avoided during pregnancy due to teratogenic risks.

In cases of severe hemorrhagic conversion or unresponsive to anticoagulation, mechanical thrombectomy may be considered rarely. This intervention carries significant risks, especially in pregnant women, and is typically reserved for patients with large venous infarcts or significant hemorrhagic transformation.[23]

Case Report

A 35-year-old female, 10 days after her delivery, presented with sudden onset of headache and generalized tonic–clonic movements, followed by loss of consciousness. It was followed by weakness of left side. Her MRI brain done showed acute hemorrhagic infarct in right frontal lobe with surrounding mild perilesional edema. MR venography showed superior sagittal sinus thrombosis. She was started on antiedema measures and anticoagulation in form of heparin infusion with close monitoring of APTT. After 2 weeks of therapy, her edema improved significantly and was discharged in stable condition **(Figs. 4A and B)**.

Prognosis and Considerations for Future Pregnancies

Pregnancy is not contraindicated in women with a history of CVT, and women with prior CVT can have successful subsequent pregnancies with appropriate management. However, prophylactic anticoagulation is typically recommended during subsequent pregnancies and in the postpartum period to prevent recurrent thrombosis.

HEMORRHAGIC STROKE IN PREGNANCY AND POSTPARTUM PERIOD

Hemorrhagic stroke (HS) during pregnancy accounts for approximately 50% of pregnancy-related strokes, with a substantial risk of adverse outcomes for both the mother and the fetus.

JAYPEE BROTHERS

Etiology of Hemorrhagic Stroke in Pregnancy

The major causes of HS during pregnancy can be broadly classified into ICH due to hypertensive disorders, subarachnoid hemorrhage due to aneurysmal rupture, vascular malformations, pituitary apoplexy, and other systemic conditions **(Figs. 5A to C)**.

Hemorrhagic stroke must be ruled out immediately in any pregnant patient presenting with thunderclap headache, vomiting, acute neurological deficits, or loss of consciousness. The management requires close collaboration between neurologists, neurosurgeon, neurocritical care specialists, neuroradiologists, anesthesiologists, and obstetricians. In some cases, concurrent cesarean delivery and neurosurgical procedures may be required.

Emergency treatment includes blood pressure management, reversal of coagulopathy, control of the bleeding source through a endovascular or

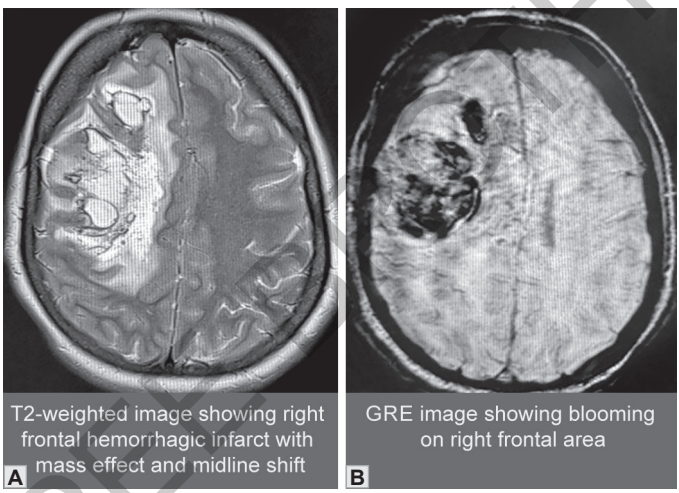

FIGS. 4A AND B: MRI findings are consistent with possibility of right cortical venous sinus thrombosis.

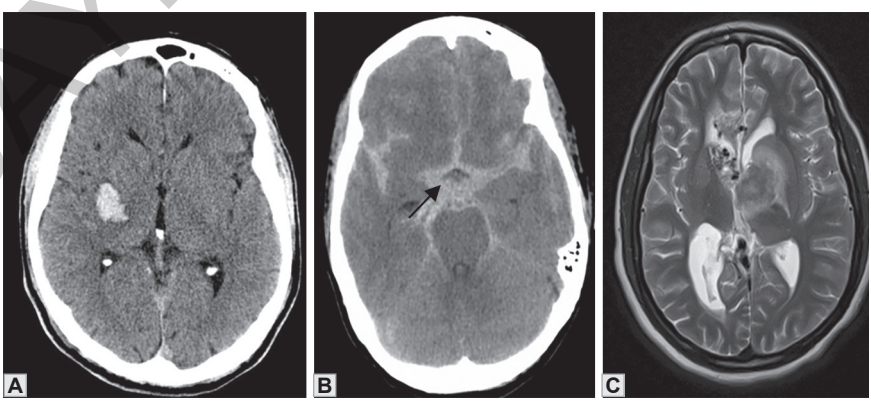

FIGS. 5A TO C: (A) Intracerebral hemorrhage; (B) NCCT showing subarachnoid blood around circle of Willis s/o SAH; and (C) Arteriovenous malformation.

JAYPEE BROTHERS

neurosurgical interventions, and avoidance of complications like raised ICP, vasospasm, seizures, etc.

Preeclampsia and Eclampsia

Preeclampsia and eclampsia can lead to endothelial dysfunction and vasospasm, increasing the risk of cerebrovascular accidents, including HS. Eclampsia, characterized by seizures, further heightens the risk of hemorrhagic events, including cerebral hemorrhage, RCVS, and PRES, during pregnancy.[24,25]

Intracerebral hemorrhage: Hypertensive ICH occurs in the settings of pre-eclampsia, eclampsia, and HELLP syndrome. Protocols should be in place to acutely manage severe hypertension (i.e., SBP ≥ 160 mm Hg or DBP ≥ 110 mm Hg). In the setting of preeclampsia or severe hypertension with neurological symptoms, the goal is to achieve an urgent and sustained reduction of systolic and diastolic blood pressure to <160/110 mm Hg to reduce the risk of maternal stroke.[13]

Arteriovenous Malformation

Arteriovenous malformations are a congenital vascular anomaly where abnormal connections between arteries and veins bypass the capillary system, often resulting in blood flow that is prone to rupture. During pregnancy, the risk of hemorrhage from an AVM does not increase significantly compared to non-pregnant women, though pregnancy itself may exacerbate the likelihood of rupture, particularly during the later stages. Studies show that AVM bleeds during pregnancy have a higher risk of rebleeding during the pregnancy compared to nonpregnant individuals, with a particularly elevated risk on the day of delivery, though this risk does not vary between vaginal and cesarean deliveries.[26]

Ruptured Arteriovenous Malformations

For ruptured AVMs, treatment should be based on the best available options for the patient, irrespective of her pregnancy status. This may involve surgical resection or endovascular embolization, depending on the location, size, and accessibility of the AVM.

Ruptured Cerebral Aneurysm

Aneurysms can rupture during pregnancy due to the physiological changes that occur, such as increased blood volume and hormonal fluctuations. The risk of aneurysmal rupture rises with gestational age and peaks between 30 and 34 weeks. If left untreated, ruptured aneurysms during pregnancy carry a high maternal mortality rate of approximately 63%, with fetal mortality at 27%. Early surgical intervention, such as coiling or clipping, significantly lowers these risks, reducing maternal mortality to 11% and fetal mortality to 5%.[27]

Ruptured Aneurysms with Subarachnoid Hemorrhage

A ruptured aneurysm with SAH should be treated urgently using standard practices for aneurysm management, including either endovascular coiling or surgical clipping. These procedures should be performed soon after the

JAYPEE BROTHERS

diagnosis, as delayed treatment increases the risk of maternal and fetal morbidity. If the fetus is viable, a concurrent cesarean delivery can be planned alongside the resection of the vascular abnormality.

Case

A 24-year-old female patient primigravida with 5 months gestation came with c/o sudden onset of headache with brief loss of consciousness. It was followed by 5 episodes of vomiting. CT head showed right Sylvian fissure and interhemispheric fissure bleed s/o SAH. DSA showed right anterior communicating artery (ACoM) aneurysm. Family was explained regarding the risk of radiation exposure and if need to plan for termination of pregnancy. ACoM aneurysm coiling was performed. Family planned to continue with her pregnancy. Her pregnancy continued uneventfully and she delivered healthy baby at term with elective caesarian section **(Figs. 6A to C)**.

Unruptured Aneurysms

Unruptured aneurysms may be incidentally discovered in pregnant women, especially those presenting with headache. While the risk of bleeding during delivery is generally similar for both cesarean and vaginal delivery, management should focus on monitoring the aneurysm carefully. In many cases, the management of unruptured aneurysms can be conservative, with close follow-up.

Other Vascular Anomalies

Other vascular abnormalities, such as moyamoya disease, cavernous angiomas, and rare tumor-related hemorrhages like pituitary apoplexy, also contribute to the risk of HS during pregnancy. These conditions can lead to vascular fragility or impaired drainage, increasing susceptibility to bleeding.

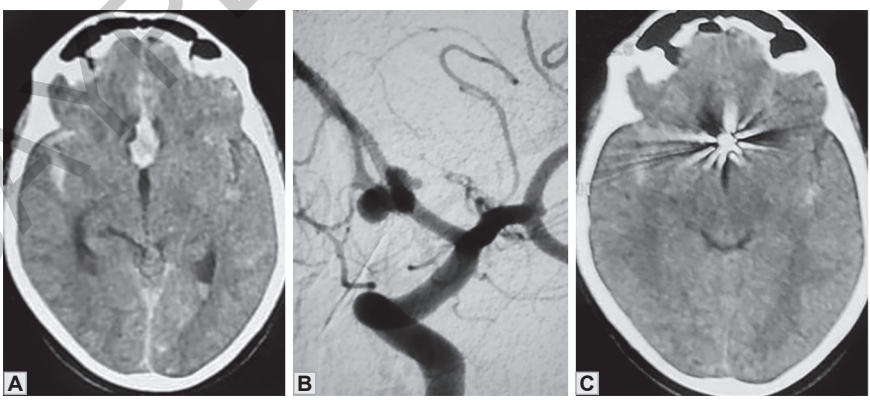

FIGS. 6A TO C: (A) NCCT head suggestive of SAH, (B) Right ACoM aneurysm, (C) CT head-post ACoM aneurysm coiling.

(ACoM: anterior communicating artery; NCCT: noncontrast computed tomography; SAH: subarachnoid hemorrhage)

JAYPEE BROTHERS

Challenges in Diagnosis and Treatment

Management of acute HS in pregnancy requires a multidisciplinary approach that balances maternal survival with fetal outcomes. The management of these conditions is guided by the standard practices for treating the specific causes of HS, with consideration for the altered physiology of pregnancy.

Diagnosing HS in pregnancy can be challenging. Safety of CT and MRI for both the mother and the fetus must be carefully considered, with CT scans often being the first line of imaging in acute settings due to their speed. Treatment choices in pregnancy must account for the safety of both the mother and the fetus.

Prognosis and Outcomes

The prognosis of HS in pregnancy depends on several factors, including the timing of diagnosis, the type of hemorrhage, the underlying cause, and the rapidity of intervention. The maternal and fetal mortality rates are highest in cases where there is delayed or inadequate treatment. However, with early identification and appropriate management, many women can have favorable outcomes.

Conclusion

Hemorrhagic stroke in pregnancy is a high-risk event that requires swift and specialized care. Although the underlying causes vary, conditions like ruptured cerebral aneurysms, arteriovenous malformations, and hypertensive disorders like preeclampsia contribute significantly to maternal and fetal morbidity. Early diagnosis, prompt surgical intervention, and multidisciplinary management strategies are essential to improving outcomes.

PROGNOSIS OF PREGNANCY-RELATED STROKES

- *Maternal prognosis*: Early diagnosis and appropriate management can significantly improve maternal outcomes. However, stroke during pregnancy is associated with high morbidity, including long-term disability in some cases.
- *Fetal prognosis*: The fetal outcome largely depends on the timing and severity of the stroke. Preterm delivery, low birth weight, and fetal distress are common in severe cases. Prompt management can spare them from significant harm.

OBSTETRIC MANAGEMENT OF WOMEN WITH STROKE DURING PREGNANCY

Obstetric management of women with stroke during pregnancy requires a comprehensive approach, balancing maternal and fetal health. A history of stroke is not an absolute contraindication to vaginal delivery, but careful consideration of the stroke's etiology and the risks associated with Valsalva maneuvers during labor is essential. Vaginal delivery may be appropriate if the

JAYPEE BROTHERS

for detailed information on medicine books, visit our website www.jaypeebrothers.com, for detailed information on medicine books, visit our website

Advancing Stroke Care in India
Principles and Practices

Stroke remains a leading cause of death and disability worldwide, with significant implications for India. The book *"Advancing Stroke Care in India: Principles and Practices"*, compiled by the Indian Stroke Association and the Association of Physicians of India, serves as a vital guide to improving stroke care in India. It covers acute stroke management, including intravenous thrombolysis and strategies for resource-limited settings, and provides practical insights into diagnosing and treating subarachnoid hemorrhage. Clinical stroke localization, advancements in arterial imaging, and rare causes like cerebral sinus thrombosis are also addressed. Special populations, such as pregnant women and children, receive dedicated attention, along with chapters on secondary prevention, long-term complications like vascular dementia, and holistic rehabilitation strategies. With contributions from leading experts, this evidence-based resource is invaluable for healthcare professionals committed to enhancing stroke care in India.



Nirmal Surya MBBS MD DNB FIAN FAAN MNAMS is a distinguished Neurologist and a prominent figure in the field of neurorehabilitation. He is the Chairman of Surya Neuro Center and serves as the Founder Trustee and Chairman of the Epilepsy Foundation India. Dr Surya is a Fellow of the Indian Academy of Neurology and a Fellow of the American Academy of Neurology, reflecting his commitment to advancing neurological practice and research. He holds several leadership positions, including President of the Indian Stroke Association (ISA) and the Indian Federation of Neuro-Rehabilitation (IFNR), as well as Secretary General and Regional Vice President of the World Federation of Neuro-Rehabilitation (WFNR). As President of the ISA, Dr Surya has launched the Mission Brain Attack, a nationwide initiative aimed at raising awareness about stroke, its prevention, and the importance of timely treatment. His efforts have significantly contributed to educating the public and healthcare professionals about the critical nature of stroke care. He has also served as Past President of the Indian Academy of Neurology (IAN). Through his extensive work, Dr Surya continues to inspire advancements in neurorehabilitation and improve patient care in India and beyond.

Printed in India

Available at all medical bookstores or buy online at www.ejaypee.com

JAYPEE BROTHERS
Medical Publishers (P) Ltd.
EMCA House, 23/23-B, Ansari Road,
Daryaganj, New Delhi - 110 002, INDIA
www.jaypeebrothers.com

Join us on facebook.com/JaypeeMedicalPublishers
Follow us on instagram.com/JaypeeMedicalPublishers

Shelving Recommendations
MEDICINE & NEUROLOGY

ISBN 978-93-6616-065-8