ebsite www.ejaypee.com, for detailed information on nursing books, visit our website www.ejaypee.com, for detailed information on nursing books, visit our website www.ejaypee.com,



St. Stephen's Hospital
College of Nursing

GNM Exam Essentials

A Question Bank with Smart Answer Guide

1st Year

Based on Indian Nursing Council Syllabus

Key Features:

- Includes important content
- Important diagrams and flowcharts
- Multiple choice questions with answer key
- Short and long answer questions from every unit
- Various other state question paper subject wise

N Grace Amitha

Edited by
Esther P Manohar

Forewords
Deepika C Khakha
Sudhir C Joseph
Feba Geevarghese
Manju Chhugani

JAYPEE

CONTENTS

SECTION 1: ANATOMY AND PHYSIOLOGY

1. Introduction to Human Body 5
2. Detailed Structure of Body 7
3. Blood 13
4. The Circulatory System 17
5. The Lymphatic System 25
6. The Respiratory System 28
7. The Digestive System 34
8. The Excretory System 45
9. The Endocrine System 48
10. The Reproductive System 53
11. The Nervous System 58
12. The Sense Organs 68
13. The Skeleton 77
14. The Muscular System 88

SECTION 2: MICROBIOLOGY

15. Introduction 95
16. Microorganisms 101
17. Infection and its Transmission 104
18. Immunity 108
19. Control and Destruction of Microbes 111
20. Practical Microbiology 118

SECTION 3: PSYCHOLOGY AND SOCIOLOGY

21. Introduction 127
22. Structure of the Mind 129
23. Psychology of Human Behavior 132
24. Learning 149
25. Personality 162
26. Intelligence 166

SECTION 4: SOCIOLOGY

27. Introduction 172
28. Individual 175
29. The Family 178

30. Society 187
31. The Community 202

SECTION 5: NURSING FOUNDATIONS AND FIRST AID

Nursing Foundations 207
32. Nursing Foundations 211
33. Nursing Care of the Patient 217
34. Basic Nursing Care and Meeting Needs of the Patient 221
35. Assessment of Patient 240
36. Infection Control 252
37. Therapeutic Nursing Care 260
38. Introduction to Clinical Pharmacology 270
39 First Aid 277
40 Procedures and Techniques in First Aid 279
41. First Aid in Emergencies 281
42. Community Emergencies and Community Resources 286

SECTION 6: COMMUNITY HEALTH NURSING-I

43. Introduction to Community Health Nursing 291
44. Community Health Nursing 295
45. Health Assessment 301
46. Principles of Epidemiology and Epidemiological Methods 303
47. Family Health Nursing Care 315
48. Family Health Care Settings Home Visit 320
49. Referral System 326
50. Records and Reports 329
51. Minor Ailments 332

SECTION 7: ENVIRONMENTAL HYGIENE

52. Introduction 335
53. Environmental Factors Contributing to Health 338
54. Community Organizations to Promote Environmental Health 350

SECTION 8: HEALTH EDUCATION AND COMMUNICATION SKILLS

55. Communication Skills 357
56. Health Education 360
57. Counseling 362
58. Methods and Media of Health Education 366

SECTION 9: NUTRITION

59. Introduction 373
60. Classification of Food 375
61. Normal Dietary Requirements 380
62. Food Preparation, Preservation and Storage 386
63. Therapeutic Diet 391
64. Community Nutrition 393
Annexure I: Suggested Reading 399
Annexure II: Multiple Choice Questions with Answer Key 403
Glossary 435
Miscellaneous 437
Annexure III: Suggested Reading 443

13 UNIT

The Skeleton

JAYPEE BROTHRS

Learning Objective

- Describe the structure and functions of skeleton system.

MICROSCOPIC AND MACROSCOPIC STRUCTURE OF BONE (FIG. 1)

Bone is a strong and durable type of connective tissue. Its major constituent (65%) is a mixture of calcium salts mainly calcium phosphate. This inorganic matrix gives bone great hardness, but on its own would be brittle and prone to shattering. The remaining third is organic material, called osteoid, which is composed mainly of collagen. Collagen is very strong and gives bone slight flexibility. The cellular component of bone contributes less than 2% of bone mass.

The basic microscopic unit of bone is an osteon (or Haversian system). Osteons are roughly cylindrical structures that can measure several millimeters long and around 0.2 mm in diameter. Each osteon consists of lamellae of compact bone tissue that surround a central canal (Haversian canal).

Bone Cells

There are three types of bone cell:

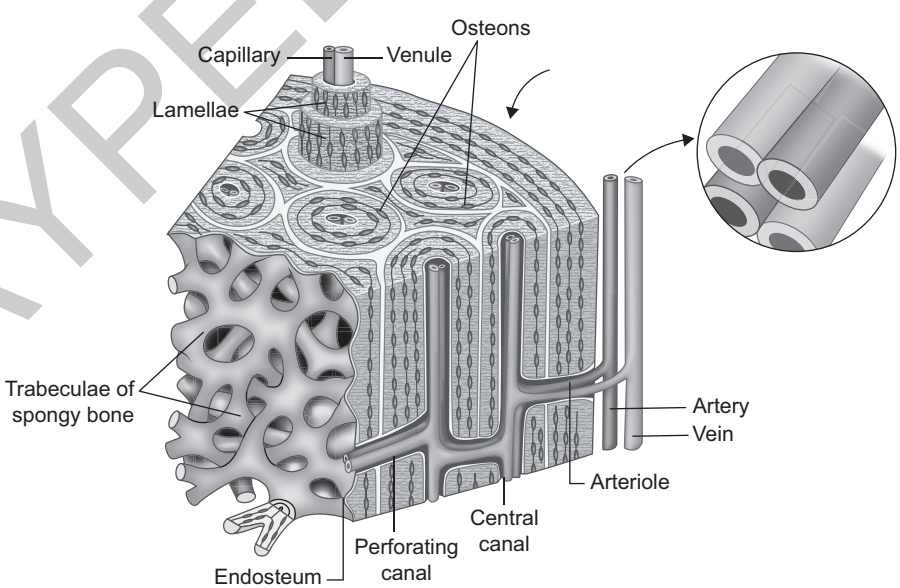

Fig. 1: The microscopic and macroscopic structure of a bone.

1. *Osteoblasts*

These bone-forming cells are responsible for the deposition of both inorganic salts and osteoid in bone tissue. They are therefore present at sites where bone is growing, repairing or remodeling:

- In the deeper layers of periosteum
- In the centers of ossification of immature bone
- At the ends of the diaphysis adjacent to the epiphyseal cartilages of long bones
- At the site of a fracture

As they deposit new bone tissue around themselves, they eventually become trapped in tiny pockets in the growing bone, and differentiate into osteocytes.

2. *Osteocytes*

These are mature bone cells that monitor and maintain bone tissue, and are nourished by tissue fluid in the canaliculi that radiate from the central canals.

3. *Osteoclasts*

These cells break down bone, releasing calcium and phosphate. They are very large cells with up to 50 nuclei, which have formed from the fusion of many monocytes. The continuous remodeling of healthy bone tissue is the result of balanced activity of the bone's osteoblast and osteoclast populations.

Osteoclasts are found in areas of the bone where there is active growth, repair or remodeling:

- Under the periosteum, maintaining bone shape during growth and to remove excess callus formed during healing of fractures.
- Round the walls of the medullary canal during growth and to canalize callus during healing.

THE INNOMINATE BONE (FIG. 2)

The innominate bone, also known as the hip bone, is a large, irregularly shaped bone that forms part of the pelvis. It consists of three fused bones—the ilium, ischium, and pubis. Together, these three bones make up the innominate bone, which joins with the sacrum posteriorly to form the bony pelvis. The main structures and features of the innominate bone are:

Ilium

The ilium is the largest and most superiorly positioned of the three bones that make up the innominate bone. It has a wing-like shape and forms the prominent, curved upper portion of the pelvis. The ilium consists of a body (alae) and a superiorly projecting crest called the iliac crest. The iliac crest serves as an attachment site for muscles and ligaments and provides support for the abdominal wall.

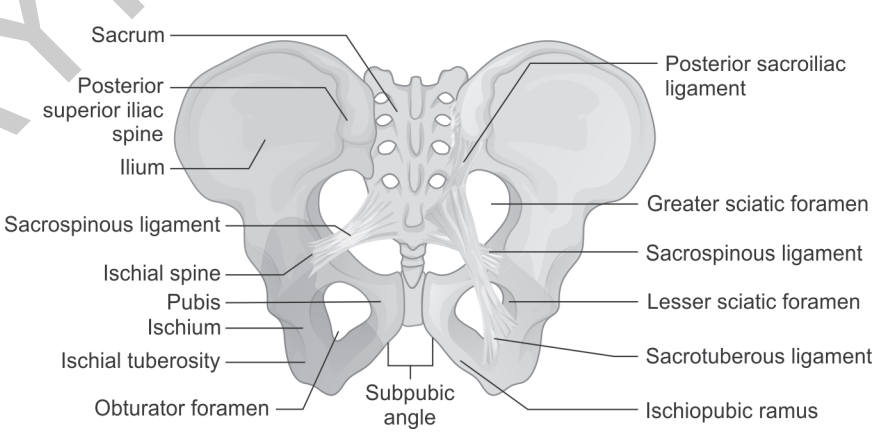

Fig. 2: Structure of a pelvis.

JAYPEE BROTHRS

The anterior portion of the ilium has a rounded prominence called the anterior superior iliac spine (ASIS), while the posterior portion has a similar projection called the posterior superior iliac spine (PSIS). These serve as important landmarks for anatomical reference.

The ilium also features a shallow, cup-shaped cavity called the acetabulum, which forms the socket of the hip joint and articulates with the head of the femur (thigh bone).

Ischium

The ischium is located inferiorly and posteriorly to the ilium. It consists of a body and a curved projection called the ischial tuberosity. The ischial tuberosity is the bony prominence on which a person sits when sitting down and is commonly referred to as the "sitting bone." The ischial spine is a small, pointed projection located superiorly to the ischial tuberosity and serves as an attachment site for ligaments.

Pubis

The pubis is located anteriorly and inferiorly to the ilium and ischium. It consists of a body and two rami: superior and inferior. The pubic symphysis is the cartilaginous joint between the two pubic bones of the innominate bones, located in the midline of the pelvis. The pubic arch is the angle formed by the convergence of the two pubic rami anteriorly. It varies in width between males and females and is an important anatomical feature in determining pelvic sexual dimorphism.

Acetabulum

The acetabulum is a concave, cup-shaped depression located at the junction of the ilium, ischium, and pubis. It serves as the socket of the hip joint and articulates with the rounded head of the femur to form the hip joint, allowing for a wide range of motion.

Together, the ilium, ischium, and pubis fuse during development to form the innominate bone, which contributes to the overall structure and stability of the pelvis and provides attachment sites for various muscles, ligaments, and other structures.

LABELLED DIAGRAM OF THE SKULL (FIG. 3)

In the neurocranium there are—one occipital bone, two temporal bones, two parietal bones, one sphenoid bone, one ethmoid bone and one frontal bone.

- **Occipital bone:** The rear bone of the skull, which forms the base of the skull and the rounded bulb at the nape of the neck. It contains the foramen magnum, which is the large opening in the skull that allows the spinal cord to pass through.
- **Sphenoid bone:** A butterfly-shaped bone located in the anterior part of the neurocranium and among the bones that form the orbit. The pituitary gland rests in the hypophyseal fossa in this bone.
- **Frontal bone:** It is the bone of the forehead and forms part of the orbital cavities (eye sockets) and prominent ridges above the eyes. It also articulates with the zygomatic, nasal, and maxilla bones.

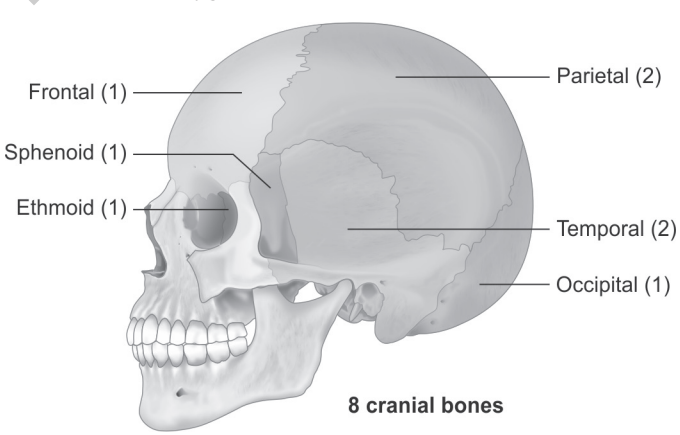

Fig. 3: Labelled diagram of a skull.

JAYPEE BROTHERS

- **Ethmoid bone**: Forms a small area in the floor of the anterior cranial fossa. It also forms the narrow roof of the nasal cavity.
- **Parietal bones**: Border the frontal bone through the coronal sutures.
- **Temporal bones**: They lie one on each side of the head. The zygomatic process articulates with zygomatic bone to form the zygomatic arch (cheek bone). The mastoid part contains the mastoid process. The petrous portion contains the organs of hearing and balance. The temporal bone articulates with the mandible at the temporomandibular joint. The bones of the facial skeleton (13) are—vomer (1), inferior nasal conchae (2), nasal bones (2), maxilla (1), mandible (1), palatine bones (2), zygomatic bones (2), and lacrimal bones (2).

Functions of the Skull

- Physical protection for the brain
- Bony eye sockets protect the eyes and provides attachments for muscles
- Temporal bone protects the delicate inner ear structures
- Contributing to phonation by acoustic resonance within the cavities and sinuses.
- Attachment for neck muscles
- Maxilla and mandible provide alveolar ridges where the teeth are embedded
- Attach facial muscles and muscles of mastication that help in chewing
- Enable stereoscopic vision and sound localization
- Form nasal and oral cavities that allow better olfaction, taste and digestion

CIRCLE OF WILLIS (FIG. 4)

The circle of Willis is a part of the cerebral circulation and is composed of the following arteries:

- Anterior cerebral artery (left and right)
- Anterior communicating artery
- Internal carotid artery (left and right)
- Posterior cerebral artery (left and right)
- Posterior communicating artery (left and right)

The middle cerebral arteries, supplying the brain, are not considered part of the circle of Willis. The posterior communicating artery is given off as a branch of the internal carotid artery just before it divides into its terminal branches—the anterior and middle cerebral arteries. The anterior cerebral artery forms the anterolateral portion of the circle of Willis, while the middle cerebral artery does not contribute to the circle. The right and left posterior cerebral arteries arise from the basilar artery, which is formed by the left and right vertebral arteries. The vertebral arteries arise from the subclavian

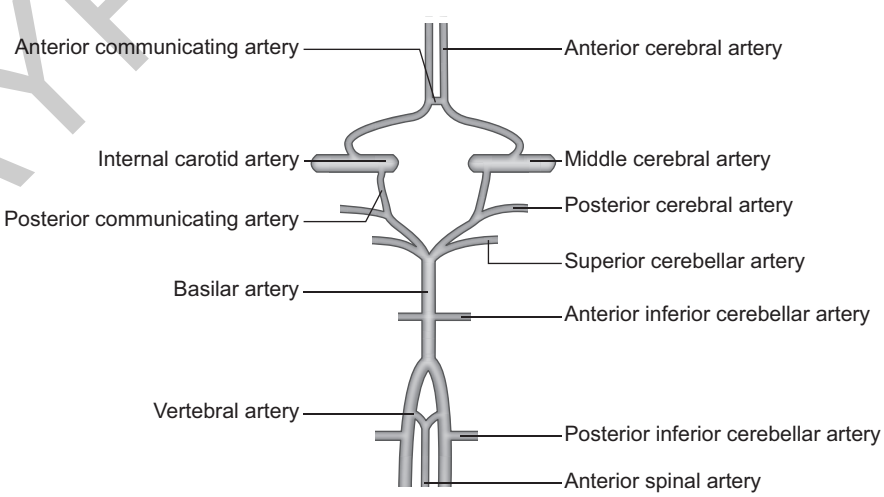

Fig. 4: The circle of willis.

JAYPEE BROTHRS

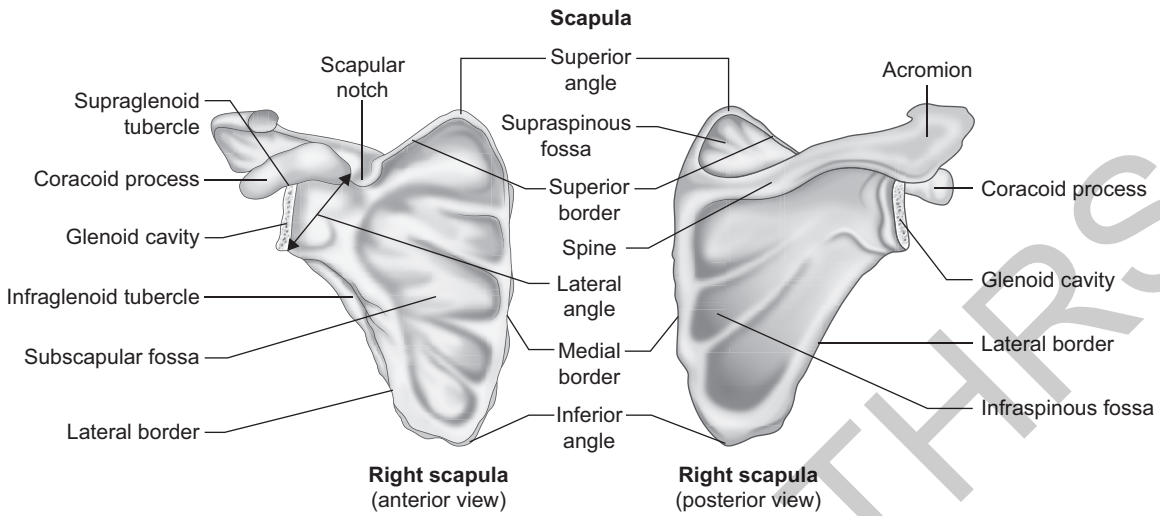

Fig. 5: Posterior view of the right scapula.

arteries. The anterior communicating artery connects the two anterior cerebral arteries and could be said to arise from either the left or right side.

Functions of Circle of Willis

- **Blood flow:** Blood flow from the arteries to both the front and back hemispheres of brain.
- **Protection:** They serve as safety mechanism in blood flow. If a blood flowing from one side of the brain to the other in a situation is reduced, the change in pressure can cause blood flow forward or backward in circle of Willis to compensate, thus preventing stroke.
- **Communication:** It connects the blood supply of the forebrain and hindbrain.

POSTERIOR VIEW OF THE RIGHT SCAPULA (FIG. 5)

The scapula is a flat, triangular shaped bone lying on the posterior chest wall superficial to the ribs and separated by muscles.

At the lateral angle is a shallow surface called glenoid cavity which articulates with the head of humerus to form the shoulder joint. The supraspinatus and infraspinatus muscles attach at their fossae. Acromion is a lateral extension of the scapula that forms the highest point of the shoulder. It articulates with the clavicle to form the acromioclavicular joint. The coracoid process a projection from the bone gives attachment to muscles that move the shoulder joint.

KNEE JOINT (FIG. 6)

The knee joint is a hinge type synovial joint, which mainly allows for flexion and extension and a small degree of medial and lateral rotation. It is formed by articulations between the patella, femur and tibia.

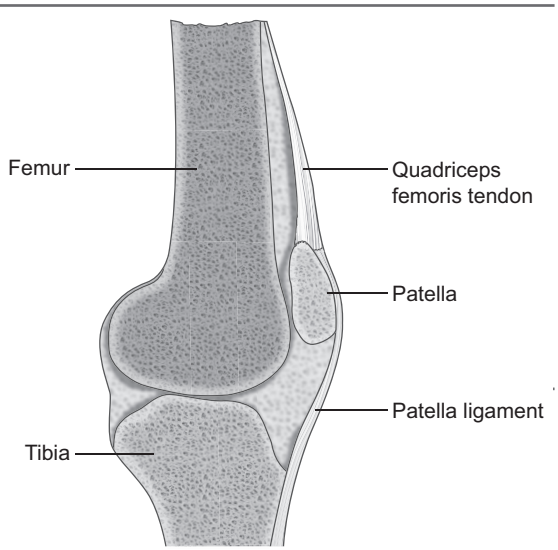

Fig. 6: Picture showing the structure of a Knee Joint.

Articulating Surface

The knee joint consists of two articulations—tibiofemoral and patellofemoral. The joint surfaces are lined with hyaline cartilage and are enclosed within a single joint cavity.

JAYPEE BROTHRS

- Tibiofemoral—medial and lateral condyles of the femur articulate with the tibial condyles. It is the weight-bearing component of the knee joint.
- Patellofemoral—anterior aspect of the distal femur articulates with the patella. It allows the tendon of the quadriceps femoris (knee extensor) to be inserted directly over the knee increasing the efficiency of the muscle.

As the patella is both formed and resides within the quadriceps femoris tendon, it provides a fulcrum to increase power of the knee extensor and serves as a stabilizing structure that reduces frictional forces placed on femoral condyles.

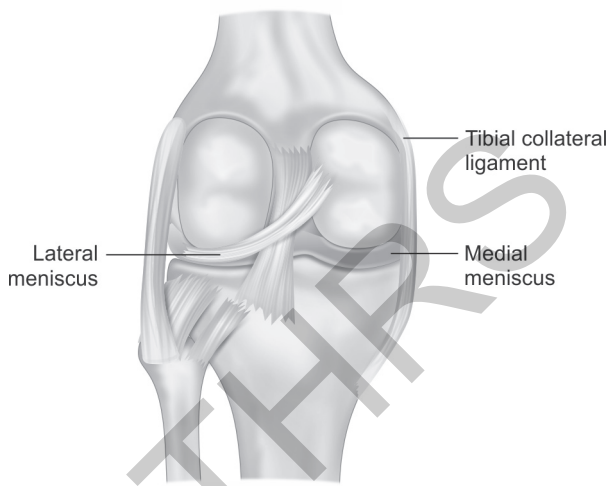

Fig. 7: Picture showing meniscus.

Menisci (Fig. 7)

The medial and lateral menisci are C-shaped fibrocartilage rings located within the knee joint. They serve two main functions:

- Deepens the articular surface of the tibia—increasing the stability ofkthe joint.
- Acts as shock absorbers—increasing surface area to further dissipate forces that are transmitted across the joint. They are attached at both ends to the intercondylar area of the tibia.
  - The medial meniscus is also fixed to the medial collateral ligament and the joint capsule. Damage to the medial collateral ligament is often associated with a medial meniscal tear.
  - The lateral meniscus is smaller and does not have any additional attachments, rendering it more mobile.

Bursae

A bursa is a sac-like structure containing a small amount of synovial fluid. It functions to decrease friction between tendons, bone, and skin during movement.

There are four main bursae found in the knee joint:

1. **Suprapatellar bursa:** Located between the quadriceps femoris and the femur.
2. **Prepatellar bursa:** Located between the apex of the patella and the skin.
3. **Infrapatellar bursa:** Split into deep and superficial. The deep bursa lies between the tibia and the patella ligament. The superficial lies between the patella ligament and the skin.
4. **Semimembranosus bursa:** Located posterior to the knee joint, between the semimembranosus muscle and the medial head of the gastrocnemius.

Ligaments(Fig. 8)

The major ligaments in the knee joint are:

- **Patellar ligament:** A continuation of the quadriceps femoris tendon distal to the patella. It attaches to the tibial tuberosity.
- **Collateral ligaments:** Two strap-like ligaments. They act to stabilize the hinge motion of the knee, preventing excessive medial or lateral movement.
- **Medial collateral ligament:** Wide and flat ligament, found on the medial side of the joint. Proximally, it attaches to the medial epicondyle of the femur, distally it attaches to the medial condyle of the tibia.
- **Lateral collateral ligament:** Thinner and rounder than the medial collateral ligament. It attached proximally to the lateral epicondyle of the femur and distally to a depression on the lateral surface of the fibular head.

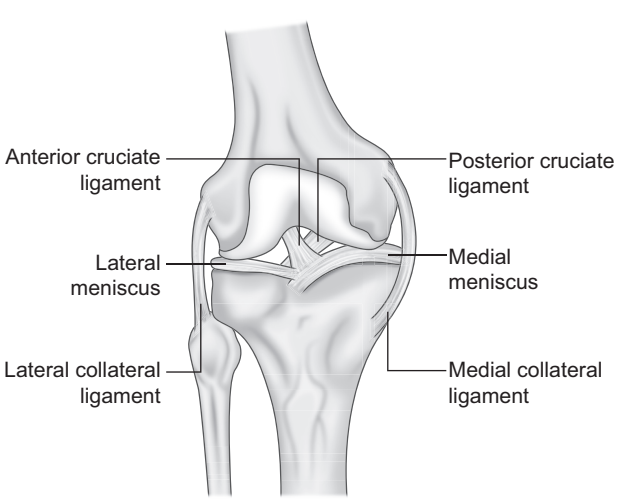

Fig. 8: Picture showing various Ligaments.

- **Cruciate ligaments:** These two ligaments connect the femur and the tibia. In doing so, they cross each other, hence the term 'cruciate' (Latin for like a cross).

JAYPEE BROTHERS

- **Anterior cruciate ligament:** Attaches at the anterior intercondylar region of the tibia where it blends with the medial meniscus. It ascends posteriorly to attach to the femur in the intercondylar fossa. It prevents anterior dislocation of the tibia onto the femur.
- **Posterior cruciate ligament:** Attaches at the posterior intercondylar region of the tibia and ascends anteriorly to attach to the anteromedial femoral condyle. It prevents posterior dislocation of the tibia onto the femur.

Movements

There are four main movements that the knee joint permits:
1. Extension
2. Flexion
3. Lateral rotation
4. Medial rotation

SUPERIOR VIEW OF ATLAS (FIG. 9)

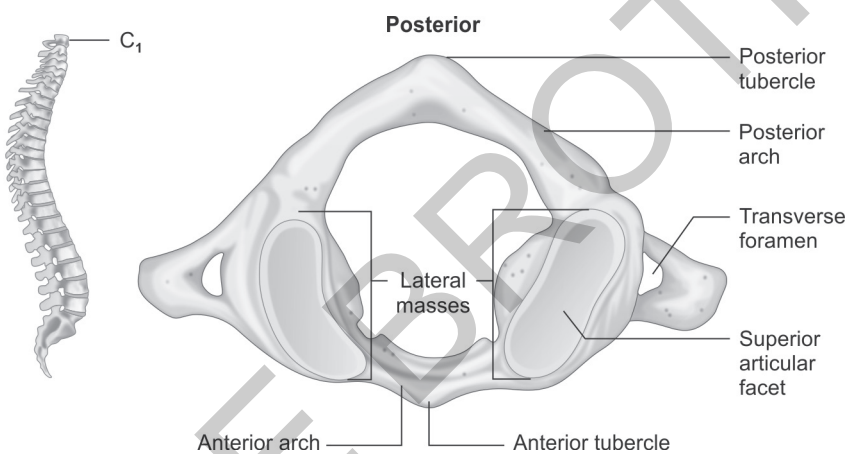

Fig. 9: Picture showing superior liew of atlas.

STRUCTURE OF SYNOVIAL JOINT (FIG. 10)

Synovial joints are characterized the presence of a space or capsule between the articulating bones. The ends of the bones are held close together by a sleeve of fibrous tissue, and the capsule is lubricated with a small amount of fluid. Most synovial joints permit a range of movement.

Characteristics of a Synovial Joint

All synovial joints have certain characteristics in common.

Articular or Hyaline Cartilage

The parts of the bones which are in contact are always covered with hyaline cartilage. This provides a smooth articular surface and is strong enough to absorb compression forces and bear the weight of the body. Cartilage has no blood supply and receives its nourishment from synovial fluid.

Capsule or Capsular Ligament

The joint is surrounded and enclosed by a sleeve of fibrous tissue which holds the bones together. It is sufficiently loose to allow freedom of movement but strong enough to protect it from injury.

Synovial Membrane

This is composed of epithelial cells and is found:
- Lining the capsule

JAYPEE BROTHRS

- Covering those parts of the bones within the joint not covered by articular cartilage
- Covering all intracapsular structures that do not bear weight.

Synovial Fluid

This is a thick sticky fluid, of egg-white consistency, secreted by synovial membranes into the synovial cavity, and it:

- Provides nutrients for the structures within the joint cavity
- Contains phagocytes, which remove microbes and cellular debris
- Acts as lubricant
- Maintain joint stability
- Prevents the ends of the bones from being separated

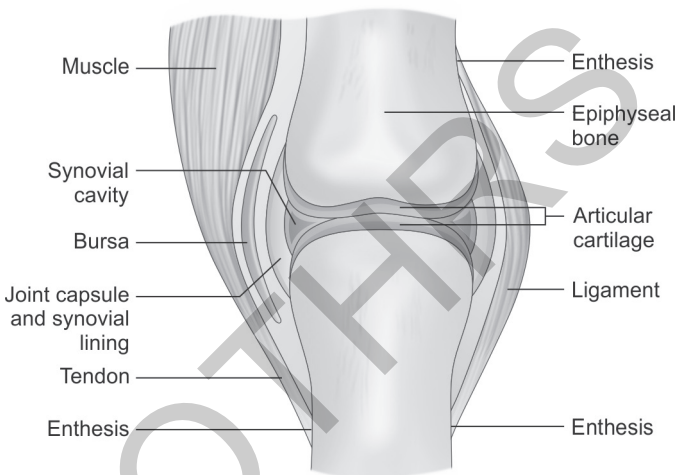

Fig. 10: The structure of a synovial joint.

Other Intracapsular Structures

Some joints have structures within the capsule, but outside the synovial membrane, which assist in maintenance of stability.

Extracapsular Structures

- Ligaments that blend with the capsule provide additional stability at most joints.
- Muscles or their tendons also provide stability and stretch across the joints they move. When the muscle contracts it shortens, pulling one bone towards the other.

Nerve and Blood Supply

Nerves and blood vessels crossing a joint usually supply the capsule and the muscles that move it.

CLASSIFICATION OF SYNOVIAL JOINTS

Synovial Joint (Freely Movable Joint)

A joint in which there is a space between articulating bones is called as synovial joint. The space or cavity is also called as synovial cavity.

Ball and Socket Joint

It consists of a ball like surface of one bone fitted into a cup like depression of another bone. Such joints allow abduction, adduction, rotation, flexion, extension.
For example: Hip joint, shoulder joint.

Hinge Joint

In this, the convex surface of one bone fits into the concave surface of another bone. It allows movement in a single plane such as flexion, extension, etc.
For example: Elbow joint, interphalangeal joints, knee joint.

Gliding Joint

This joint allows movement in two planes, i.e., side to side and back and forth movement.
For example: Joints between carpel bones, clavicle, and scapula.

JAYPEE BROTHERS

Pivot Joint

It is rounded, pointed or conical surface of one bone articulates within a ring formed partly by bone and partly by a ligament. The primary movement permitted is rotation.
For example: Joints between atlas and axis, radius and ulna.

Condyloid and Saddle Joint

In this, oval-shaped condyle of one bone fits into an elliptical cavity of another bone. It allows side to side and back and forth movements.
For example: Joints at the wrist between the radius and carpals, between the trapezium and metacarpal of the thumb.

TYPES OF MUSCLE TISSUE

Smooth Muscle

Smooth muscle is a type of muscle tissue that is utilized by different systems for the application of pressure to organs and vessels. It is composed of cells that are narrow and spindle-shaped with a single nucleus that is located centrally. The cells of smooth muscles are made up of fibers of myosin and actin that run through the cells and are backed by a framework of various proteins, wherein the filaments are arranged in a stacked pattern across the cell.

Cardiac Muscle

The cardiac muscle tissues function to cause continuous pumping of the heart through involuntary movements. This is one of the striking features of cardiac muscles that sets it apart from the muscle tissues which is under one's control. It is able to do so through specialized cells known as the pacemaker cells which govern the heart's contractions.

The nervous system transmits signals to the specialized cells, which indicates them to increase or decrease the heart rate. The pacemaker cells are linked to the cardiac muscle cells, which enables them to transmit signals which cause a wave of contractions in the cardiac muscles that in turn generates a heartbeat.

Skeletal Muscle

Skeletal muscle is a muscle tissue that is attached to the bones and is involved in the functioning of different parts of the body. These muscles are also called voluntary muscles as they come under the control of the nervous system in the body.

STRUCTURE OF SKELETAL MUSCLE TISSUE (FIG. 11)

This muscle is attached to the bones by an elastic tissue or collagen fibers called tendons. These tendons are comprised of connective tissues. The skeletal muscles consist of a bundle of muscle fibers namely fascicule. Each muscle fiber is

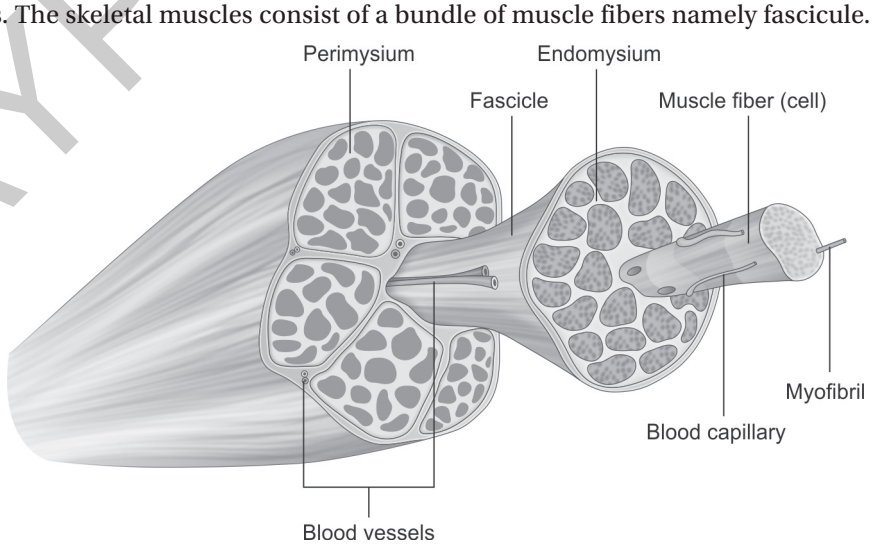

Fig. 11: Structure of a skeletal muscle tissue.

JAYPEE BROTHRS

lined by plasma membrane namely sarcolemma reticulum. It encloses a cytoplasm called sarcoplasm which has the endoplasmic reticulum. The muscle fibers consist of myofibrils, which have two important proteins, namely actin and myosin in it. The fascicule is enclosed by perimysium and the endomysium is the connective tissue that encloses the muscle fibers.

Types of Skeletal Muscle

There are two types of skeletal muscles named as red and white muscles.

Red Muscles

Red muscles are due to the red pigment called myoglobin, which is in high amounts in the human body. These muscles are smaller in diameter and have a large number of mitochondria in it. The myoglobin stores the oxygen, which is used by the mitochondria for the synthesis of ATP. Red muscles have a large number of blood capillaries in it.

White Muscles

Unlike the red muscles, the white muscles are bigger in diameter and have a small amount of myoglobin in it. They also have less number of mitochondria in it.

Functions of Skeletal Muscle

Following are the important skeletal muscle functions:

- The skeletal muscles are responsible for body movements such as typing, breathing, extending the arm, writing, etc. The muscles contract which pulls the tendons on the bones and causes movement.
- The body posture is maintained by the skeletal muscles. The gluteal muscle is responsible for the erect posture of the body. The Sartorius muscles in thighs are responsible for body movement.
- The skeletal muscles protect the internal organs and tissues from any injury and also provide support to these delicate organs and tissues.
- These also support the entry and exit points of the body. The sphincter muscles are present around the anus, mouth and the urinary tract. These muscles contract which reduces the size of the openings and facilitates the swallowing of food, defecation, and urination.
- The skeletal muscles also regulate body temperature. After a strenuous exercise, the body feels hot. This is due to the contraction of skeletal muscles which converts energy into heat.



KEY POINTS

1. Bone is a strong and durable type of connective tissue. Its major constituent (65%) is a mixture of calcium salts, mainly calcium phosphate.
2. Osteocytes: These are mature bone cells that monitor and maintain bone tissue, and are nourished by tissue fluid in the canaliculi that radiate from the central canals.
3. The innominate bone, also known as the hip bone or os coxae, is a large, irregularly shaped bone that forms part of the pelvis.
4. The human skull is the bone structure that forms the head in the human skeleton. It consists of 22 bones, which are joined together primarily by sutures.
5. The knee joint is a hinge type synovial joint, which mainly allows for flexion and extension and a small degree of medial and lateral rotation.
6. A bursa is a sac-like structure containing a small amount of synovial fluid. It functions to decrease friction between tendons, bone, and skin during movement.
7. Synovial joints are characterized the presence of a space or capsule between the articulating bones.
8. Smooth muscle is a type of muscle tissue that is utilized by different systems for the application of pressure to organs and vessels.

JAYPEE BROTHERS

CONCEPT REVIEW

Short Answer Questions

1. Draw the structure of bone.
2. Draw a labeled diagram of skull.
3. Describe about circle of Willis.
4. Discuss the structure and classification of synovial joint.

Long Answer Questions

1. Discuss about the innominate bone.
2. Discuss the types of muscles with diagram.

JAYPEE BROTHRS

for detailed information on nursing books, visit our website www.ejaypee.com, for detailed information on nursing books, visit our website www.ejaypee.com, for detailed informatio

GNM Exam Essentials

A Question Bank with Smart Answer Guide

1st Year

Salient Features

- The textbook is structured in a uniform and systematic manner across all chapters. Each chapter begins with clearly stated learning objectives and key terms, which effectively guide learners and simplify the teaching-learning process.
- This book serves as a well-organized, informative, and student-friendly companion for both students and teachers, facilitating effective learning and helping students progress smoothly through the subject matter.
- An extensive review of literature has been undertaken to incorporate up-to-date and relevant information wherever necessary. Attractive and well-placed illustrations help reduce the monotony of continuous text and aid in grasping difficult concepts with ease. Meaningful flowcharts are provided at appropriate points to support quick revision and long-term retention of key ideas.
- Important points are highlighted, giving students the impression of guided learning support. Additionally, objective and subjective questions and sample question papers for each subject from various states are also included to assist students in effective examination preparation.

N Grace Amitha RN RM MSc (N) is a dedicated nursing professional and Senior Tutor presently working at St. Stephen's Hospital College of Nursing, Delhi, India. She pursued her BSc (Hons) Nursing from Rufaida College of Nursing, Jamia Hamdard University. With 2 years of clinical experience at AIIMS, New Delhi, and through unceasing quest for higher education, the author has strengthened both knowledge and vision by pursuing Masters degree in Obstetrics and Gynecology from Rufaida College of Nursing, Jamia Hamdard University. With 4.5 years of teaching experience, she offers a robust combination of clinical proficiency and academic distinction to the field of nursing education. She is appreciated for her student-centered approach, clarity in teaching, and commitment to nurturing competent and compassionate students. In recognition of her outstanding mentorship, she has received the Best Mentor Award. She is a contributor to 17th South Asian Edition, Myles Textbook for Obstetrics and Gynecology Nursing and has published various research studies in national and international journals. She has also presented papers at national and international forums and actively serves as a guide and co-guide for students' research work. Her areas of research interest include obstetrics and gynecology, with a special focus on the psychiatric aspects of maternal health. Her passion for obstetrics nursing, research, and lifelong learning is reflected in her continuous efforts to simplify complex concepts and bridge theory with clinical practice. She maintains that genuine education encompasses more than the mere acquisition of information; it fundamentally influences thought processes, practices, and objectives. This book offers not only insight but also articulates a vision for substantive and enduring learning.

Esther P Manohar RN RM MSc (N) is presently serving as a Senior Tutor at St. Stephen's Hospital College of Nursing, Delhi, India. She began her nursing journey after completing her Diploma in General Nursing and Midwifery from St. Stephen's Hospital College of Nursing, Delhi, where she received the Best Outgoing Graduate Award. In 2010, she commenced her professional career as a Staff Nurse at St. Stephen's Hospital. Driven by her passion for academic and clinical excellence, she pursued higher education, earning her Post Basic BSc Nursing from Choithram College of Nursing, Indore, followed by an MSc Nursing degree from Rufaida College of Nursing, Jamia Hamdard, Delhi. Her specialization lies in Medical-Surgical Nursing, with a superspecialty focus on Cardiothoracic and Vascular Surgery Nursing. She has contributed significantly to the field of nursing through national and international publications and has presented paper at national-level conference. Her extensive clinical experience spans the Intensive Care Unit (ICU) and the Gastroenterology Department, enriching her expertise in critical care and specialized nursing practices. She is an active member of professional organizations such as the Trained Nurses' Association of India (TNAI) and the Christian Medical Association of India (CMAI), reflecting her commitment to professional growth and collaborative healthcare advancement.

Scan for more nursing titles...

Buy from ejaypee

JAYPEE BROTHERS

ISBN 978-93-6616-102-0

9 789366 161020