tailed information on pediatrics books, visit our website www.ejaypee.com, for detailed information on pediatrics books, visit our website www.ejaypee.com

Lessons from the Grand Rounds

A Pediatric Series



STEER

Sensitizing to Think
Enabling Excellence and Rationality

YK Amdekar
RD Khare
RR Chokhani

JAYPEE

Contents

1. Evaluate Seriousness 1

2. Provisional Diagnosis 5

3. History 27

4. General Examination 43

5. Growth 45

6. Fever 66

7. Cough 90

8. Abdominal Symptoms 128

Index 161

CHAPTER 7

Cough

Cough is one of the most common symptoms encountered in pediatrics. Children could present with isolated cough or with cough as a part of a symptom complex of cough with or without cold, fever and breathlessness. These complaints are often recurrent, in varying combinations and the possible diagnosis may range from benign viral infections to serious infections like tuberculosis (TB). What is important to realize is that many causes of cough are noninfective, the most common of them being hyper-reactive airway disease including asthma. In elucidating the cause, investigations have their limitations. An X-ray chest is only occasionally useful in diagnosing the cause of cough (e.g., inhaled foreign body). In fact, most children with significant cough have a normal chest X-ray. Similarly, the utility of complete blood count (CBC) in differentiating infection from no infection and further, viral from bacterial infection, is limited. Routine investigations do not help in diagnosing asthma, while special investigations have limitations of availability and interpretation. Further, cough is distressing not only to the child but much more to the parents and even the physician, as no cough remedies really work. Most market preparations of cough syrups contain an irrational combination of expectorant, cough suppressant, bronchodilator, mucolytic, and antihistamine. Unless the physician analyses the cause of cough, it cannot simply be resolved by such mixtures. In fact, most of us would not be aware of the ingredients of cough syrups that we regularly prescribe.

No wonder cough in a child is a challenge; it is only a systematic clinical approach comprising of a detailed history followed by a thorough clinical examination that is the key to a confident diagnosis and rational management of cough in children.

JAYPEE BROTHERS

RESPIRATORY MICROANATOMY

The common symptoms that help localize the disease process to the respiratory system are cold, cough, and breathlessness (and occasionally chest pain). Though fever is another common symptom associated with these, it is a "general" symptom and not specific to the respiratory system and hence, has to be analyzed separately (see section on fever). While a "true cold" localizes the disease to the nose, cough, and breathlessness could arise from different microanatomical parts of the respiratory system. For the clinician, the respiratory system could be subdivided into the airway, the lung parenchyma, the interstitium, the pleura, and the mediastinum. Thus, when faced with a respiratory problem, we should attempt to localize it to one of these micro anatomical parts.

Airway

The hallmark of airway disease is significant cough.

Cough is a reflex intended to drive away an irritant from the airways and keep the airway clean of secretions.

Thus, when cough is the predominant symptom, the anatomic seat of the disease is "the airway". Larger the airway involved, higher is the intensity of cough. For clinicians, the airway can be further subdivided into upper airway (nose, pharynx, larynx, and trachea), lower large airway (bronchi) and lower small airway (bronchioles). So the cough can be further localized to one of these anatomical sites based on different specific features of the cough itself and based on a constellation of associated clinical features that are specific to each anatomical site.

Specific Features of Cough

A dry cough could mean an upper airway disease or due to bronchospasm as in asthma wherein viscid secretions in constricted bronchi sound like dry cough.

A wet cough always suggests lower airway disease and is recognized as rattling in the chest that suggests bronchitis. Most children cannot expectorate even if they have a wet cough, with the exception of bronchiectasis.

A loud dry barking or brassy cough suggests tracheal involvement, whereas hoarseness suggests laryngeal involvement.

Dry hacking cough suggests pharyngitis.

A honking cough suggests a habit cough. This is absent at night.

Constellation of associated clinical features suggesting anatomical origin:

Upper airway (e.g., croup): A loud dry barking, brassy or hoarse cough with stridor and suprasternal retractions.

Lower large airway (e.g., bronchitis/asthma): An intense, periodic, often nocturnal dry cough, which may be accompanied with tachypnea. Cough is more prominent than tachypnoea and there are subcostal retractions. Rhonchi are prominent and there may be crepitations which are inspiratory in timing caused by opening of the airways.

Lower small airway (e.g., bronchiolitis): Absence of cough or cough of low intensity, i.e., more tachypnea than cough. Infants with "bronchiolitis" who have a significant cough are most

JAYPEE BROTHERS

likely to have hyper-reactive airway disease that may be triggered by a viral infection. The significant cough in such cases suggests that the inflammation has extended to the bronchi (and is not limited to bronchioles). In classic bronchiolitis, in spite of the marked tachypnoea, there are minimal or almost no chest retractions. This is due to hyperinflation of the chest because of which intercostal muscles remain fully stretched and cannot retract. Hyperinflation is noted on percussion, suggestive of air trapping.

Cough can also arise out of parenchymal, interstitial, and pleural diseases. However, it is not the dominant complaint; instead, other symptoms may be more prominent (see below). Besides, the specific characteristics of the cough (e.g., type, timing, intensity, etc.) are different. Thus, based on such details and based on the chief complaints of the patient, the microanatomical origin of the cough can be determined.

Lung Parenchyma

The hallmark of parenchymal lung disease is breathlessness, often with fever. Breathlessness can also be a feature of airway, interstitial, or pleural disease. To decide the microanatomy of breathlessness we need to know—(1) specific characteristics of the breathlessness, (2) clinical signs, and (3) the associated clinical features of disease of each of these anatomical sites.

In parenchymal lung disease, the breathlessness is subacute in onset (usually on a background of fever), is accompanied with intercostal retractions, and may be, a "grunt".

Intercostal retractions are a result of poor compliance of the diseased lung parenchyma (difficult to expand the lung), and grunt is an auto-PEEP—an attempt to improve oxygenation by increasing end-expiratory pressure.

Of course, both intercostal retractions and grunting could also be seen in severe respiratory distress due to any cause.

The other clinical signs of parenchymal lung disease (consolidation) could be reduced movement in the affected area, impaired note, bronchial breathing, and localized crepitations. However, we realize that none of these signs are specific to a pathology; a large cavity or a pleural effusion could also give rise to similar signs. Hence, more than physical signs themselves, it is the distribution of signs that is important. In parenchymal lung disease, these signs follow a lobar distribution, i.e., the signs are found over an area representing the surface anatomy of individual lobes of the lungs. Thus, on the right side, signs restricted to upper half of the chest anteriorly represent upper lobe disease, signs restricted to lower half of the chest anteriorly represent middle lobe disease, while signs distributed only posteriorly all over represent lower lobe disease. Similarly, on the left side, since there is no middle lobe, upper lobe disease gives rise to signs anteriorly in the upper half of the chest, while lower lobe disease gives rise to signs posteriorly. In the axillae, each lobe is reflected in the upper, middle, and lower one-third, respectively, on both sides.

Pneumonia is primarily an inflammation of the alveoli; in an early stage, pneumonia presents with fever without significant cough, but as it starts resolving, breakdown of the inflammatory lesion brings on cough. Therefore, in the beginning of the illness in (bacterial) pneumonia, *fever is more prominent while cough is not; in fact, it comes up and becomes significant a little later* in the disease.

JAYPEE BROTHERS

Pleura

The hallmark of pleural disease is localized chest pain followed by breathlessness.

Pleural pathology can lead to a dry cough in the beginning of the illness; at this stage it is likely to be accompanied with pleural chest pain (localized chest pain aggravated by deep breathing/coughing, relieved by lying on the affected side as a result of splinting). As the pathology progresses and leads to a pleural effusion, the pain may subside, and breathlessness may follow. Typically, this breathlessness is without any chest retractions.

The two most common classic clinical settings in which clinicians are likely to encounter pleural disease are:

1. Secondary to underlying parenchymal disease—synpneumonic pleural effusion. In such cases, the clinical features of the primary underlying disease would dominate, partly modified by overlapping of features of secondary pleural disease. Such a scenario is seen most often in bacterial infections, and only occasionally in TB.
2. Primarily pleural disease (e.g., TB pleural effusion, in which the primary focus is subclinical), which is typically acute and often sufficiently large to cause breathlessness. Smaller effusion may not cause breathlessness.

The other clinical signs would be a pleural rub initially (difficult to appreciate), and as fluid accumulates, decreased movement, impaired note and reduced vocal resonance later. Again, more important than the signs would be their distribution; these signs would show a pleural distribution, i.e., they would be found all over the front, sides, and back, below a particular intercostal space, as against the lobar distribution of signs of parenchymal disease noted above.

Interstitium

The hallmark of chronic interstitial lung disease is gradual onset, subtle, slowly progressive breathlessness with restriction of physical activity. However, acute interstitial pneumonia presents with acute breathlessness with generalized signs, and is commonly due to viral infection, often referred to as bronchopneumonia.

Other clinical features include minimal cough, which is gradual in onset, slowly progressive, and chronic. Over time, the child fails to thrive. Physical examination of the chest may reveal only subtle tachypnea, without retractions; or additionally, crepitations which are generalized in their distribution.

Clinical Implications

From the discussion above, it follows that when a child exhibits generalized (bilateral) signs, it indicates either airway or interstitial involvement whereas localized (unilateral) signs indicate parenchymal or pleural involvement. Since viral infections lead to a generalized involvement, the more widespread the signs the more likely it is to be a viral infection, whereas bacterial infections lead to localized involvement. In children, bronchitis is usually secondary to allergic inflammation or a viral infection; it is rarely due to a bacterial infection. Mycoplasma infection is an exception to this rule; these infections are bacterial infections that behave like a viral infection—generalized signs, significant cough.

JAYPEE BROTHERS

Respiratory System—Microanatomy

- ***Airway***—significant ***cough***, often generalized signs
  - ***Upper***—dry (hacking) cough, hoarseness, stridor, and suprasternal retraction
  - ***Lower large***—wet cough >> tachypnea, wheeze, subcostal retraction
  - ***Lower small—tachypnea >> cough*** (mild), no chest retractions
- ***Lung parenchyma***—cough not predominant, grunt, intercostal retractions, often localized signs ***(lobar distribution)***
- ***Pleura***—pain, tachypnea, no chest retractions, localized, ***pleural distribution of clinical signs***
- ***Interstitium***—mild cough, tachypnea, generalized signs

Combination disorders

Generalized airway + lung + interstitium – ***viral infection***
Localized – pleuroparenchymal – ***bacterial infection***

JAYPEE BROTHERS

COUGH RULES

Confirm Symptoms, Clarify Terminology

Often, cough and cold are terms that could be used loosely by parents. Therefore, we need to clarify with them as to exactly what they mean by these complaints. It is not uncommon that when they complain of "cough", they may actually mean sticky material vomited out (my child brings out a lot of "cough"), which could, in reality, be just mucinous material from the stomach. Similarly, some refer to sticky nasal discharge as "cough coming out of the nose". On other occasions, they may complain that the "chest is full"; they may be meaning just noisy breathing (which is often due to a compliant chest wall) or rattling of the chest (a vibratory feel when the infant is held by the chest). At times, patients use "medical terminology" which they may have picked up with incomplete understanding from the earlier physician—"she has congestion"; however, we cannot afford to take such data verbatim. If details of the complaints are not carefully analyzed, we run the risk of "interpreting wrong data".

If the complaint is a cold, again one needs to confirm whether they mean a running nose or blocked nose or just noisy breathing. If the nose is really running, the type of discharge is somewhat important. While watery running nose always indicates a viral infection or allergic rhinitis, thicker white or yellow mucoid discharge does not necessarily mean a bacterial infection. Purulent discharge, often green and foul smelling, suggests bacterial infection. It may not be easy to clinically define which discharge is purulent, so other parameters like continued fever, activity of the child and prolonged duration of symptoms are important to decide need for an antibiotic. In other words, a decision to prescribe an antibiotic in upper respiratory infection (URI) needs great caution and analysis.

Sanguinous (blood stained) discharge, when unilateral, suggests a foreign body.

Noisy breathing is extremely common in newborns and young infants, who may actually have no "cold" whatsoever, nor any respiratory problem. Such infants are happy and they feed well.

Clinical Approach to Cough

Like any other symptom, one needs to get details about the ODP.

Onset, Duration, and Progress

Onset of cough may offer a clue to the probable diagnosis. Sudden onset of cough denotes an inhaled foreign body, an acute onset of cough over hours suggests an allergic process as seen in asthma, whereas a subacute onset over days indicates an infection such as any viral respiratory infection or whooping cough.

The progression of cough also helps in deciding a probable etiology. Episodic, nocturnal cough is seen in asthma or postnasal drip, while a gradually worsening cough with a whoop is seen in pertussis (whooping cough). Nocturnal cough has to be further explored. Cough that occurs soon after the child lies down in the supine position is likely to be due to post nasal drip, whereas one that occurs a few hours later, in the wee hours of the morning is likely to be due to hyper-reactive airway disease.

JAYPEE BROTHERS

Other Important Questions to be Asked

- Past h/o recurrent cough—strong pointer to hyper-reactive airway disease
- Family h/o cough
  - *At present:* s/o contagious infection—viral/pertussis
  - *In the past:* s/o atopy in family

  One often needs to ask leading questions like anybody in the family suffering from sneezing early in morning, or "sinus trouble" or skin itching or frequent "bad throat" or asthma, to elicit family history of atopy. Otherwise, it is often denied at the first instance.
- H/o associated symptoms and their sequence of appearance

Fever

If the illness starts with significant fever, it denotes an infection, viral, or bacterial. At times, a viral infection may start with a prodrome of cold, cough for 1–2 days followed by significant fever.

Thus, *short duration cough* can be practically divided into two groups:

1. *With fever:* Viral respiratory infection (often with a cold as well)
2. *Without fever:* Hyper-reactive airway disease

We must note that mild fever is possible simply because of inflammation even in hyper-reactive airway disease but fever is never a predominant symptom.

A viral infection can trigger off an episode of cough/wheezing in a child with hyperreactive airway disease, thus in a child with history suggestive of Reactive Airway Disease, presence of high fever in some of the episodes of cough does not change the diagnosis.

Cold

Cough associated with cold denotes probable viral infection or allergy.

Breathlessness

Cough with breathlessness, but without fever, indicates hyper-reactive airway disease (significant cough); while, cough (not a major symptom) with breathlessness and fever may be due to pneumonia. Similarly, mild or no cough associated with cold, breathlessness, and fever (often mild) is typical of acute bronchiolitis.

H/o Snoring/Mouth Breathing

This indicates adenoid hypertrophy, which could be secondary to recurrent allergic inflammation.

Vomiting

It is a common accompaniment of cough, especially in younger children. Though it could be the cause (as in aspiration), more often than not, it is the effect of significant cough. Contrary to common belief, aspiration can exist without overt vomiting.

JAYPEE BROTHERS

Questions to be Asked in Cough

In a nutshell, the following questions must be asked while taking the history of a child with cough as dominant complaint (besides asking all the relevant details of cough):

- Is there any past history of cough?
- Is there any personal or family history of atopy?
- Is there h/o significant fever with each episode of cough?
- Is there any history of snoring/mouth breathing?
- Was the baby born full term? Any neonatal interventions done?

Clinical Implications

From the discussion above, it follows that the most common causes of significant short duration cough in routine office practice are viral respiratory infections and hyper-reactive airway disease (asthma). Thus, more severe the cough, less likely it is to be a bacterial infection, the exceptions being pertussis and URIs like adenoiditis/sinusitis. Therefore, it follows that in a child with severe cough as the only/dominant complaint, antibiotic is rarely necessary and an X-ray chest (typically used to diagnose parenchymal infections) is rarely useful, exception being a child with an inhaled foreign body.

Cough Rules

- ***Clarify terms***—cold, cough, and noisy breathing
- Cough as a ***predominant*** symptom:
  - ***Without fever—HRAD***
  - ***With fever—acute viral infection or wheeze-associated lower respiratory infection (WALRI) (both often with cold)***
- Mostly not acute bacterial infection so ***more*** the ***cough, lesser*** the need for ***antibiotic*** and chest X-ray (exception inhaled FB)
- At times, acute bacterial URTI (adenoiditis and rhinosinusitis)
- ***Acute-onset cough worsening*** over a week—***pertussis*** (enquire history of contact)

JAYPEE BROTHERS

APPROACH TO RECURRENT OR PERSISTENT COUGH

Recurrent cough is a common symptom in office practice. While it is important to try and differentiate between recurrent and persistent cough, it is more important to differentiate between a recurrent and persistent pathology. This may not be easy, unless there is a long enough symptom-free period. Recurrent cough may represent both—a recurrent infective pathology such as recurrent viral infections or a persistent pathology such as asthma. *In fact, the most common cause of recurrent cough in pediatrics is hyper-reactive airway disease or asthma*. Thus, a sound clinical evaluation is necessary to differentiate various similar looking conditions.

Approach

While evaluating children with recurrent cough, we need to broadly try and divide them into two groups with significant fever in each episode/most episodes and without significant fever or only occasional fever.

With Fever

Significant fever denotes an infection, so recurrent cough with significant fever in each episode/most episodes, obviously denotes recurrent infections. The next step is to try and decide whether these infections are bacterial or viral (see section on fever). History suggestive of generalized involvement in the form of running nose, cough, fever, body ache, GI complaints, etc., suggests a viral infection. Such a child with recurrent viral infections always has a normal growth as seen on his growth chart over time and does not need any investigations. All one needs to do is to reassure the parents that this phase will pass off. Recurrent viral infections are common in toddlers as they join play group that exposes them to repeated contact with viral infections.

If the history is suggestive of bacterial infections (high fever poorly responsive to antipyretic, child sick in inter febrile period, and specific symptoms suggestive of localized involvement of any one anatomical site), one needs to decide whether these recurrent bacterial infections are localized to the upper respiratory tract or lower. Symptoms such as purulent nasal discharge with snoring and mouth breathing/severe throat pain/earache suggest URIs, while breathlessness and wet cough suggest lower respiratory infections. In either case, there has to be a background underlying cause for the recurrence, which may be evident clinically or may need investigations. Recurrent upper respiratory bacterial infections are often a result of underlying rhinosinusitis or persistent focus in tonsils while recurrent lower respiratory bacterial infections are usually due to more serious underlying defects such as cystic fibrosis and immune deficiency. Recurrent respiratory bacterial infections involving both upper and lower respiratory tract may be due ciliary dysfunction as in Kartagener's syndrome. Further, if the recurrent infections are lower respiratory, they are very likely to lead to growth failure as seen on the growth chart.

JAYPEE BROTHERS

Without Fever

This group constitutes the noninfective causes of recurrent cough. The most common cause of such a cough is hyper-reactive airway disease, which may be atopic or nonatopic. So we need to find out about personal and/or family history of atopy. If it exists, this child is likely to have atopic HRAD (asthma). Nonatopic HRAD may be seen in the form of a transient wheezer (which may be due to prematurity, neonatal respiratory insults like meconium aspiration syndrome, and mechanical ventilation in neonatal period, etc.), a child with wheeze associated lower respiratory infection—WALRI, or as asthma mimics such as congenital cardiac or respiratory defects.

Approach to Recurrent/Persistent Cough

Significant fever → Generalized ***Viral*** → No inv. Reassure parents

Significant fever → Localized ***Bacterial*** → ***URI*** → ***Adenoids*** ***Tonsillitis*** ***Sinusitis*** → ***Investigate***

Significant fever → Localized ***Bacterial*** → ***LRI*** → ***CF*** ***Immune def*** ***Ciliary defect, TB*** → ***Investigate***

No fever/occasional Episodic, nocturnal ***Hyper-reactive airway disease***

Atopic ***Asthma*** h/o allergy personal/family

Nonatopic Aspiration Prematurity FB L → R Shunt

Deteriorating health → ***Investigate***

JAYPEE BROTHERS

COUGH AND WHEEZING IN THE YOUNG INFANT/CHILD

In infants and young children, cough is often accompanied with noisy breathing that may be either wheezing or misinterpreted as wheezing (when there are nasopharyngeal sounds conducted to the chest). Even if wheezing is not noted with each episode, such episodic bouts of cough suggest the possibility of a wheeze. Thus, cough and wheeze may often represent the same disease, whether or not one notices both each time.

Infants and young children with recurrent wheezing can be broadly grouped into three categories.

Transient Early Wheezers

These children may start wheezing early in life. They often have a predisposing factor such as prematurity, neonatal respiratory intervention, or insult, etc. The frequency of their wheezing peaks around the age of 1–2 years after which it declines and they gradually settle down around 3 years of age or thereafter. During the individual episodes, inhaled bronchodilators may be tried and may help. However, these children do not need long-term inhaled corticosteroids, nor are they likely to help modify the course, if used.

Nonatopic Wheezers

These are children who do not have a personal or family history of atopy. But they wheeze in response to various stimuli, the most common among them being viral infections. Hence, typically, they start wheezing shortly after joining playschool which is when they start getting exposed to frequent viral infections. They peak between 3 and 4 years and then gradually settle down. Again, during the individual episodes, inhaled bronchodilators may be tried and may help. However, these children do not need long-term inhaled corticosteroids, nor are they likely to help modify the course, if used. However, leukotriene inhibitors (montelukast) is considered to be helpful and may be tried.

Atopic Wheezers (Persistent Wheezers)

These are children who have personal or family history of atopy, and may start wheezing at any age, in response to various triggers, and may continue to wheeze even beyond early childhood. These are the ones who are likely to have asthma.

Late-onset Asthma

One more subset has been recently added. These children start wheezing later in childhood beyond 7–8 years of age, and are likely to continue as asthmatics later in life.

One-point Evaluation

When a young child <1–2 years of age is seen for the first time for wheezing, at that point it may not be clear as to which of the above groups he belongs to. To help decide this, the past and the future trend is important. The trend so far can be obtained from the history and if necessary, the child can be observed and followed for another 3–6 months to decide the future trend and then decide on the label and definitive long-term treatment if necessary.

JAYPEE BROTHERS

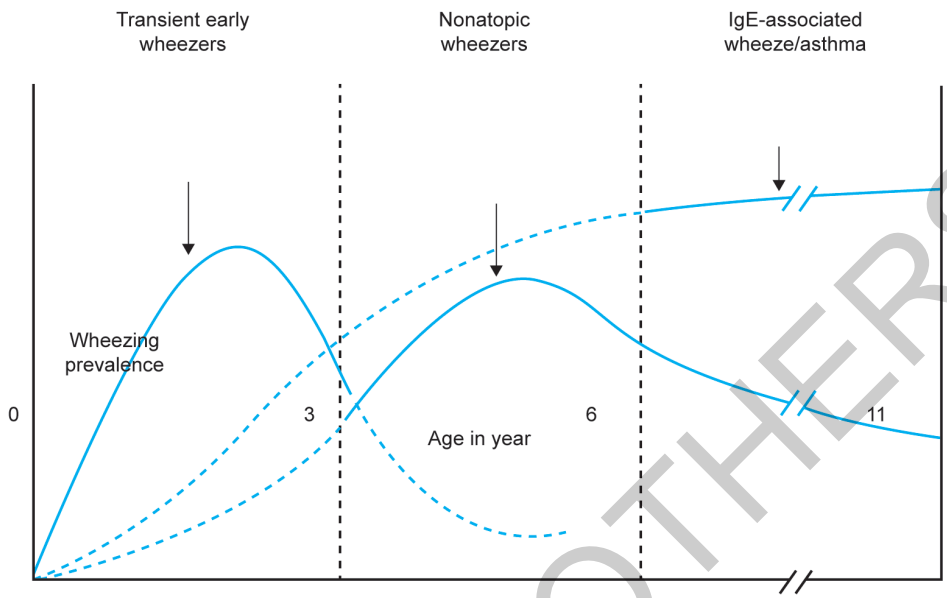

Stein et al., 1997: Martinez and Helms, 1998.

JAYPEE BROTHERS

TREATMENT OF COUGH

It is important to diagnose the cause of cough to be able to provide the correct treatment.

Treatment of the Cause

If the cause is curable, treatment of the cause will automatically relieve the cough. Thus, cough following a bacterial pneumonia does not need a cough syrup; the antibiotic treatment of the pneumonia itself will relieve the cough over time. On similar lines, if the cause of the cough is asthma, treatment of the underlying inflammation (inhaled medications) is necessary. Unless this is done, any amount of cough syrups will not help.

Symptomatic Relief

If the cause is not treatable, as in the case of a viral infection, one attempts to provide symptomatic relief. Need for treatment depends on the amount of discomfort that the infant or child is experiencing. Thus, it is important to realize that by symptomatic treatment, we need to relieve the distress or discomfort arising out of the cough, rather than attempting to eliminate cough itself. A majority of children with significant cough are uncomfortable particularly while sleeping, since the cough worsens in the lying down position; they may be relatively fine at other times. Thus, they need relief at a specific time only. Therefore, it is clear that drugs should not be prescribed on a round the clock basis, i.e., three to four times a day, but should be administered only on a SOS basis. One must try nonpharmacological interventions such as propped-up position, comfortable clothing, well-ventilated environment, and sips of warm drink before considering need for a drug. Expectorants and combination drugs are not recommended.

Efficacy

There is considerable debate whether cough syrups really work. In clinical practice, one needs to have a practical approach. Hence, to begin with, one must question the need of the cough syrup; it is possible that home remedies such as mixture of ginger, lemon, and tulsi in honey could be as good (and safer). At the other extreme, it is not that one should never use a cough syrup; however, one must have realistic expectations with respect to the speed and extent of relief from cough.

Choosing Cough Syrups

Irrational Formulations

It is not uncommon to find cough syrups with contradictory ingredients, i.e., the same syrup has a cough suppressant and an expectorant. Others contain either too less or too much of different ingredients making dosage titration difficult. In fact, many have an added antipyretic; such multiple ingredient cough syrups are irrational and should not be used.

Since infants and young children cannot really expectorate, expectorants such as guaifenesin are not useful at all in young children. Similarly, mucolytics have no conclusively proved role in children, except may be, in special situations. Thus, these ingredients may add to the cost, without adding much to the benefit.

JAYPEE BROTHERS

Rational Formulations

As a corollary, ideal cough syrups should have a single ingredient, or at the most two—(1) a cough suppressant and (2) an antihistamine, in the right quantity relative to each other.

The best choice lies between a bronchodilator such as salbutamol or terbutaline for spasmodic cough and a cough suppressant such as dextromethorphan or pholcodine for other types of cough. Oral bronchodilators have an erratic action in infants and toddlers, and therefore, need to be monitored not only for side effects but for benefit as well. Cough sedatives such as dextromethorphan or pholcodine should be used with caution. Codeine is an excellent and powerful cough suppressant but is likely to result in constipation. First-generation antihistamines may also be considered for relief of discomfort; since they sedate the child, he/she thereby does not perceive the irritation in the airways and therefore, does not cough.

When used judiciously on a SOS basis, all these drugs are safe enough, though their benefits are limited.

It is best that we familiarize ourselves with the ingredients of the cough syrup that we usually prescribe; we should choose just a few preparations from amongst the many that are available.

Failure to Respond

It is also important to realize that many common conditions that cause cough in children may take up to 10–14 days to subside. At the same time, while a distressing cough is a nuisance, by itself it is not medically serious. Therefore, one must avoid the temptation to keep changing cough syrups. At the same time, any cough that persists for >2 weeks needs a proper evaluation and one cannot just go on treating with cough syrups. TB must be considered in a child with persistent cough and relevant details must be sought such as low grade fever, recent loss of weight, and contact with TB disease.

Treatment of "Cold"

"Cold", i.e., running nose (rhinorrhea) or nasal obstruction may be treated with antihistamines or adrenergic drugs (nasal decongestants). Oral phenylephrine and antihistamines are the preferred pharmacologic agents that may be used. Again, they have a limited beneficial effect. Pseudoephedrine use can be dangerous in children.

Decongestants can be in the form of nasal drops (e.g., xylometazoline, oxymetazoline, etc.); they run the risk of rebound congestion and are therefore rarely recommended. Instead, it is recommended to use saline nasal drops to relieve nasal obstruction; they are safe, can be used at any age, and as many times a day as needed.

Treatment in Newborns

As mentioned earlier, cough and cold in newborns have to be reconfirmed to be really present before deciding on further action. Significant cough in newborns is rare, and if really present, indicates serious illness. Nose block that interferes with sucking (feeding) or sleeping peacefully can be treated with saline nasal drops and partially propped up position. Cough

JAYPEE BROTHERS

and cold syrups should be avoided in newborns and young infants because they may hardly provide any benefit, and yet, have a high propensity for ill effects such as excessive sedation or irritability.

Antibiotics

Significant cough as the chief or only complaint is rarely due to bacterial infection (except pertussis). Hence, in the absence of a thoughtful detailed analysis, one ends up using antibiotics as cough syrups, when there is no bacterial infection whatsoever.

JAYPEE BROTHERS

APPROACH TO RESPIRATORY DISTRESS

The common conditions that one encounters with respiratory distress in routine office practice are pneumonia, bronchiolitis, asthma, and croup. Occasionally, a child with metabolic acidosis or a child with neuromuscular respiratory muscle involvement may also present with tachypnea and may be confused with other causes of respiratory distress. Clinically, it is possible to reasonably differentiate between these conditions by merely considering the presence or absence of symptoms such as fever and cough, and a few signs like site of predominant chest retractions, audible sounds while breathing and some auscultatory signs, as per the table below.

Respiratory Distress

	Chest retraction	*Sound*	*Fever*	*Cough*	*Chest signs*
Pneumonia	Intercostals	Grunt	+ +	+	Creps, BBS
Asthma	Subcostal	Wheeze	–	+ + +	Rhonchi
Bronchiolitis	–	–	+	+/–	Emphysema
Group	Suprasternal	Stridor	+	+	–
Metabolic acidosis	–	–	–	–	–
Muscle paralysis	–	Low voice	–	–	–

JAYPEE BROTHERS

Case Scenario 20

- *A 2-year-old child presents with fever and cough—6 days*
- *Analysis?*

How do we analyze this, what further questions do we ask?

Is it possible that just by a good history we can arrive at a probable diagnosis?

Applying our first rule of history taking when there are multiple symptoms, we ask the following two questions:

1. **What is the predominant symptom?**
2. **What is the sequence of symptoms?**

- *Predominant symptom—cough:* The predominant symptom is cough. This tells us that this is an airway disease, so we have the first component of our provisional diagnosis, i.e., the anatomy.
- *Sequence of symptoms—cough D1, fever D3:* The sequence of symptoms is cough on D1, followed by fever on D3. Usually, infections start with significant fever or if there is a prodrome for a day or two, it is followed by significant fever. So, the next question logically is:

What is the intensity of fever?

- *Intensity of fever—mild, occasional*
  - The fever is mild and occasional. This is unlike an acute infection. Nevertheless, there is some fever, which denotes inflammation. Hence this could be noninfective inflammation. So, we have a noninfective inflammatory airway disease.
  - We have learnt that when cough is the predominant symptom, we must always ask for past history of cough.
- *Past h/o frequent cough—present*
  - There is past history of cough, which is a highly sensitive and specific marker for hyper-reactive airway disease. So, we now have a diagnosis of hyper-reactive airway disease, which is indeed a noninfective inflammatory airway disease.
  - Lastly, we need to decide whether this Reactive Airway Disease is atopic or nonatopic. So the next question is:

Is there any personal or family history of atopy?

- Family h/o atopy—present

Since, there is a family history of atopy in this case, it is likely to be atopic. However, we need to follow up this child to determine the trend and then decide on long-term management.

We realize that we have made a reasonably reliable clinical diagnosis; we do not need any investigations, either for the diagnosis nor to decide further management. It is important to note that each specific question sequentially helped us to define the anatomy, pathology, and probable etiology to make a complete diagnosis.

JAYPEE BROTHERS

Case Scenario 20

- A 2-year-old child presents with fever and cough—6 days
- Analysis?
- ***Predominant*** symptom—cough
- ***Sequence*** of symptoms—cough D1, fever D3
- ***Past h/o*** atopy—present
- Intensity of fever—mild, occasional
- ***HRAD***—determine the trend, and follow-up to find out whether it is atopic or nonatopic
- ***No test necessary***

JAYPEE BROTHERS

Case Scenario 21

- *A 2-year-old child with fever, cold, and cough—4 days*
- *Analysis?*

This looks like a straightforward respiratory infection is not it? Bacterial or viral?

How do we confirm and what further questions do we ask?

Once again, applying our first rule of history taking when there are multiple symptoms, we ask:

What is the predominant symptom?

- *Predominant symptom—fever*
- *Considered viral upper respiratory tract infection (URTI)*

The predominant symptom is fever. This suggests that it is likely to be an infection. Since the associated symptoms are apparently cold and cough, the localization is the nose as well as the lower airway, i.e., it is a generalized infection of the airway. Hence, the probable diagnosis is a viral infection.

However, we have a surprise on follow up.

- *Fever continued, repeat examination D4—follicles on tonsils*

We find that the fever continues to be high even on D4, and now on examination, we find follicles on the tonsils suggesting acute tonsillitis.

Where did we go wrong in our initial assessment and analysis? Any thoughts?

- *Detailed enquiry—no nasal symptoms*

On asking details, and clarifying what the patient means by cold and cough, we discover that there is no "cold"; there are no nasal symptoms. Similarly, the so called "cough" is some sticky substance brought up once, but the child is not coughing at all. This changes the interpretation totally; our original analysis of "generalized" involvement of airway is now retrospectively wrong. In fact, there was no localization of fever then. Hence, subsequently, now on Day 4, if there is localization in the form of follicles on the tonsils, it is not a surprise but the norm, so to say—localization of infections usually takes 3–4 days.

Is change in the diagnosis rational?

Have we done any harm because of the "delayed" diagnosis?

During the evolution of any illness, if at any point we realize an "error" of either commission or omission; it is rational to correct ourselves, even if it means change of diagnosis/action plan. As far as the "delay" in diagnosis is concerned, we have already discussed earlier that while waiting for evolution (and localization) of disease, all we have to do is to ensure that it is safe to wait. In this case of tonsillitis, even if specific antibiotic is started after 4 days of onset of fever (or sometimes, even later, in other instances), it does not increase the risk of complications. This is so, because we are already monitoring (following up) for acute complications while waiting, and the risk of long-term complications such as rheumatic fever does not increase even if antibiotic therapy is delayed for as long as 9 days.

JAYPEE BROTHERS

Case Scenario 21

- A 2-year-old child with fever, cold, and cough—4 days
- Analysis?
- ***Predominant*** symptom—fever
- Considered viral URTI
- Fever continued, repeat examination Day 4—follicles on tonsils
- ***Detailed enquiry—nasal symptoms negligible***
- Diagnosis changed from acute viral to bacterial infection
- Rationality in waiting for evolution and change in diagnosis

JAYPEE BROTHERS

Case Scenario 22

- *A 2-year-old child presents with fever and cough—6 days*
- *Analysis?*

Prima facie, the presenting complaints look identical to Case 20. However, by now, we know very well that when there are multiple symptoms, we ask:

What is the predominant symptom?

- *Predominant symptom—fever and cough both*

Since fever is predominant, this is an infection. Since cough is also predominant, the anatomic localization is the airway. Thus, this seems to be an infection involving the airway.

Now, we have already learnt that when cough is a predominant symptom, we will always ask for past history of cough.

- *Past h/o frequent cold and cough—present*
- *Family h/o atopy—present*

This being a strong marker of hyper-reactive airway disease, we now conclude that we are dealing with an infection involving the airway in a child with Reactive Airway Disease. Since there is family history of atopy, there is a strong likelihood of this HRAD being atopic. Since this child with probable atopic HRAD has come with an infection this time, the next thing to determine is whether the frequent past episodes of cough were infective or not. So the next logical question is:

How many of the past episodes were associated with fever?

- *Past h/o fever accompanying cough—present each time*

This tells us that this child has been having recurrent infections in addition to his atopic HRAD. Now we need to decide whether these infections were viral or bacterial.

- *Nasal symptoms—snoring, mouth breathing+*
- *Determine trend of fever and cough during each episode—both abate together after antibiotic; however, mouth breathing and snoring continue.*

Since the nasal symptoms suggest nasal obstruction, these infections seem to be localized to the nose. Localized infections are likely to be bacterial. This is further corroborated by the trend of fever and cough during each episode. Typically, in viral infections in children with HRAD, the fever subsides in 2–3 days, but the cough continues for more than a week and then subsides gradually. Whereas, in this child both fever and cough subside together after antibiotic suggesting bacterial infections. Hence, the final diagnosis in this child is allergic rhinosinusitis with recurrent bacterial infection.

JAYPEE BROTHERS

Case Scenario 22

- A 2-year-old child presents with fever, cough—6 days
- Analysis?
- ***Predominant*** symptom—fever and cough both
  Past h/o frequent cold and cough—present
  Family h/o atopy—present
- ***Past h/o fever accompanying cough***—present each time
- ***Nasal symptoms***—snoring, mouth breathing +
- ***Determine trend*** of fever and cough during each episode both abate together after an antibiotic, however, mouth breathing and snoring continue.
- ***Allergic rhinosinusitis with recurrent bacterial infection***

JAYPEE BROTHERS

Case Scenario 23

- *A 2-year-old child presents with fever and cough—6 days*
- *Analysis?*

We note that though the presenting complaints are seemingly similar, how each case unfolds differently as we ask important relevant questions. By now, we are itching to ask:

What is the predominant complaint?

What is the sequence of complaints?

- *Predominant symptom—fever*
- *Sequence—fever followed by mild cough*

Since the predominant symptom is fever, this child has an infection. But we note that for the first few days this fever is not accompanied with any other symptoms and mild cough has developed as a localizing symptom a few days later, suggesting that the infection is now localizing to the respiratory system. Since the cough is not predominant, it is likely to be arising from an area other than the airway. At this point, for the sake of analysis, this could be either viral or bacterial infection. Differentiation could be by analyzing the fever in depth (*see* Chapter 6 Fever), or by additional history and subsequent examination.

- *Past h/o similar complaints—none*
- *Any cold or nasal symptoms—none*

Since there is no past history of similar complaints, there is no background of frequent infections or of hyper-reactive airway disease. Absence of cold makes a viral infection less likely.

- *O/E—localizing signs in chest*

In a viral infection, one expects generalized signs. The presence of localizing signs suggests a bacterial infection, so that the final diagnosis in this child is an acute bacterial pneumonia.

We make a note that we can suspect and diagnose pneumonia by intelligent analysis of details in the history and by the distribution of signs rather than the signs itself. This case demonstrates that one can suspect acute bacterial pneumonia prior to onset of breathlessness, because it is only when the disease worsens that breathlessness comes on.

Further, it is worth noting that cough is not a predominant symptom in case of acute bacterial pneumonia to begin with, exceptions being intracellular infection causing pneumonia (mycoplasma and chlamydia) and viral pneumonia. This is because common bacterial pneumonia is a lung parenchymal disease while intracellular infections and viruses involve the airway besides lung parenchyma. In fact, as acute bacterial pneumonia starts resolving after appropriate antibiotic, fever is controlled but cough becomes more prominent.

JAYPEE BROTHERS

Case Scenario 23

- 2-year-old child presents with fever and cough—6 days
- Analysis?
- ***Predominant*** symptom—fever
- ***Sequence***—fever followed by mild cough
- ***Past h/o*** similar complaints—none
- ***Any cold or nasal symptoms***—none
- ***O/E***—localizing signs in chest
- ***Acute bacterial pneumonia***

JAYPEE BROTHERS

Case Scenario 24

- *A 2-year-old child presents with fever and cough—6 days*
- *Analysis?*

Let us look at another variation of similar presenting complaints.

- *Predominant symptom—none, both are mild.*

What could this be…is this an infection at all, or is it noninfective?

Let us analyze.

So this child has mild fever and mild cough. Mild fever suggests inflammation, which could be noninfective or due to subacute/chronic/low-grade infection. Mild cough suggests that it is primarily not an airway disease. Now we get further details.

- *Past history—fever and cough, off and on for 15 days*

Fever off and on, for the past 15 days, further strengthens the analysis that this could be a subacute/chronic infection; usually, noninfective inflammatory fevers are high grade. Cough off and on, could suggest allergic cough which waxes and wanes. However, allergic cough arises out of an airway disease primarily, and hence, the intensity of the cough is quite significant. Thus, that seems to be unlikely. In that case, it probably represents a pathology that is slowly progressive. In conjunction with our analysis of the fever, it probably represents a slowly progressive subacute/chronic infection. Such infections usually are not viral. It could either be an atypical bacterial or a tuberculous infection. Since atypical bacterial infections also behave like viral infections, in the sense that they lead to airway disease and significant cough, this is likely to be tuberculous infection.

This is the way we would have analyzed this case. But the case seems to have progressed differently, while being treated by the previous doctor.

- *Progress—fever and cough continued—chest X-ray: Pneumonia—failed two sets of antibiotics over next 2 weeks, symptoms continue.*
- *CT scan—pneumonia; bronchoalveolar lavage (BAL) –ve*

On the face of it, this looks like a resistant pneumonia….what are our thoughts? Do we accept a diagnosis of (bacterial) pneumonia?

How should we proceed further?

Actually, to begin with, a diagnosis of acute bacterial pneumonia, is not tenable from this history. This child did not have high fever, and was not breathless. Further, when he did not respond to treatment, one could argue that it was a drug-resistant infection. However, this is ruled out because when an infection fails to respond, it should complicate/progress with time; in this child, there are no local complications in spite of a poor response to antibiotics, as revealed by the CT scan. The scan being reported as pneumonia is a mere reflection of the fact that it demonstrates the structural changes inflicted by the pathology (in this case, consolidation), but not the etiology. CT scan was not indicated in this child; in fact, CT scan is rarely required in common respiratory diseases in children.

JAYPEE BROTHERS

Thus, this was indeed a chronic slowly progressive infective pneumonia which was tuberculous in origin. Failure to analyze and interpret the clinical story correctly can lead to erroneous management strategies.

Case Scenario 24

- A 2-year-old child presents with fever and cough—6 days
- Analysis?
- ***Predominant*** symptom—none, both are mild
- ***Past history***—fever and cough, off and on × 15 days
- ***Progress***—fever and cough continued—chest X-ray pneumonia—failed two sets of antibiotics over next 2 weeks, symptoms continue
- CT scan—pneumonia; BAL -ve
- ***Chronic slowly progressive infective pneumonia***—no local complications in spite of poor response to antibiotics
- ***Tuberculosis***

JAYPEE BROTHERS

Case Scenario 25

- *A 2-year-old child presents with fever and cough—6 days*
- *Analysis?*
- *Predominant symptom—fever and cough both*

In this yet another variation of similar looking complaints, we note that the predominant complaints are both fever and cough. Since fever is predominant, this is an infection. Since cough is also predominant, the anatomic localization is the airway. Thus, this seems to be an infection involving the airway.

Now, we have already learnt that when cough is a predominant symptom, we will always ask for past history of cough.

- *Past h/o similar illness—present*

Does this suggest hyper-reactive airway disease?

In this case, we have got a past history of a similar illness, and not just cough. This means that this child has been having repeated episodes of fever and cough, suggesting frequent infections and not hyper-reactive airway disease. We now have to decide whether these infections could have been viral or bacterial. For that we need to ask for history suggestive of localized or generalized involvement of the respiratory tract.

- *Family h/o similar illness—none*
- *Nasal symptoms—none*
- *Growth—failure to thrive*

When there is no family history of similar illness, it suggests that there is no contact, which makes a viral infection less likely. Since there are no nasal symptoms, there is no upper respiratory localization. Determining lower respiratory localization on history largely depends on history of breathlessness accompanying significant fever, with may be, absence of upper respiratory localization. But in this case, there is failure to thrive, which indirectly but surely suggests bacterial lower respiratory infections, irrespective of other history.

Recurrent bacterial infections involving lower respiratory tract are always due to a generalized underlying abnormality of a serious nature; hence, these children present with failure to thrive. On the other hand, recurrent bacterial infections involving the upper respiratory tract are also due to an underlying abnormality, but it is a localized structural abnormality; hence, these children do not present with significant failure to thrive.

So we now have a child who has come with an infection of the airway, and has had frequent lower respiratory infections in the past. Any such child with recurrent bacterial infections must have an underlying cause which predisposes him/her to these infections. Recurrent bacterial involvement of the lower airway commonly occurs in cystic fibrosis, or an immune defect such as B-cell antibody deficiency. Hence, this child should be investigated further for these conditions.

JAYPEE BROTHERS

Case Scenario 25

- A 2-year-old child presents with fever and cough—6 days
- Analysis?
- ***Predominant*** symptom—fever and cough both
- ***Past h/o*** similar illness—none
- ***Family h/o*** similar illness—none
- Nasal symptoms—none
- ***Growth—failure to thrive***
- ***Progressive recurrent bacterial lower respiratory tract infection (LRTI)***
- Search for background cause—***cystic fibrosis***

JAYPEE BROTHERS

Case Scenario 26

- *A 2-year-old child presents with cough and fever—6 days*
- *Analysis?*
- *Predominant symptom—cough*
- *Past h/o frequent cough—none*

Is this case identical to Case 20?

What is the difference?

There are subtle but important differences as we will note.

We note that since the predominant symptom is cough, this is an airway disease. But there is associated fever as well, suggesting either noninfective inflammation or an infection. However, there is no past history of frequent cough, suggesting that this child may not have hyper-reactive airway disease (of course, it is possible that this is the first episode of what would subsequently turn out to be Reactive Airway Disease, but excluding that possibility, our inference is reasonably correct). So we conclude that this is an airway disease, may be infective, in a child who does not have HRAD.

- *Family h/o cough—present*

For a moment, we are taken aback. We just inferred that this child may not have HRAD, and now we have a family history of cough. Here, it is important to note that family history of cough now is different from family history of atopy. Therefore, what this may mean is that presently there is a contact in the family with a similar illness. Thus, this could be an infection, viral, or bacterial. If bacterial, it is a contagious infection.

- *Any noisy breathing—none*

This rules out nasal obstruction and upper respiratory bacterial infections that lead to significant cough. Since there is no mention of a running nose, we move away from a viral respiratory infection.

- *Progress over last 6 days—cough worsening*

In a child who does not seem to have hyper-reactive airway disease, the fever and cough should start getting better by Day 5 on an average. In this case, the cough is getting worse, suggesting progression. Hence, so far, our analysis suggests that this is an airway infection acquired from a family contact which is progressive and does not seem to be viral.

- *Complete blood count—nonspecific, chest X-ray normal*

A nonspecific CBC neither rules in, nor rules out any infection. A normal chest X-ray in conjunction with the above analysis rules out a parenchymal infection.

- *Details of family history of cough—prolonged cough in two family members for last 3 weeks*

Now, there is no doubt that this progressive bacterial airway infection acquired from family contacts is pertussis.

JAYPEE BROTHERS

Case Scenario 26

- A 2-year-old child presents with fever and cough—6 days
- Analysis?
- ***Predominant*** symptom—cough
- ***Past h/o*** frequent cough—none
- ***Family h/o*** cough—present
- Any noisy breathing—none
- ***Progress*** over last 6 d—cough worsening
- CBC—nonspecific, chest X-ray normal
- ***Details*** of family history of cough—prolonged cough in two family members for last 3 weeks
- ***Pertussis***

JAYPEE BROTHERS

Case Scenario 27

- *A 2-year-old child presents with cough—6 days*
- *Analysis?*
- *Any other symptoms—none*
- *Any nasal symptoms—none*
- *Past h/o frequent cough—none*
- *Family history of atopy—none*

How does one analyze this?

From what we have learnt so far, this does not seem to be Reactive Airway Disease (no past or family history), nor is it an airway infection (no fever), nor a viral infection (no cold and no fever).

So what could this be?

While this applies to every symptom, it is particularly important that whenever there is a single symptom, one must get every detail including onset, duration, and progress of the symptom.

- *Onset of cough—sudden*

Sudden onset of any symptom suggests a mechanical, allergic, vascular, or neurologic etiology. Pertaining to cough, this suggests a mechanical or allergic origin. As discussed earlier, since there is no past history of cough, it is unlikely to be allergic (though theoretically, this could be the first episode). Hence, it is likely to be a mechanical cause like an inhaled foreign body.

As far as duration and progress are concerned, we confirm that the child has significant persistent cough ever since it started.

- *Chest X-ray—emphysema R midzone*

This child was subsequently subjected to a bronchoscopy and a vegetable foreign body was removed.

Case Scenario 27

- 2-year-old child presents with cough—6 days
- Analysis?
- Any other symptoms—none
- Any nasal symptoms—none
- ***Past h/o*** frequent cough—none
- ***Family history*** of atopy—none
- ***Onset*** of cough—***sudden***
- Chest X-ray—emphysema R midzone
- ***Inhaled FB***

JAYPEE BROTHERS

Case Scenario 28

- *A 6-year-old child, c/o cough for 6 months—multiple investigations negative, inhalers—no benefit*
- *Analysis?*

Could this be tuberculosis?

Could this be immunodeficiency?

How do we answer these questions and how do we proceed?

Since this is a single symptom, we must get details about onset, duration, and progress, and ask for associated complaints that the patient may not have reported.

In this child, the cough started insidiously over a few days and since then, is persistent, every day, without any improvement or worsening.

What associated symptoms are we looking for?

Since the complaint is for 6 months, we need to ask for associated constitutional symptoms that may be subtle and may not be reported by the patient.

- *Persistent, not recurrent*
- *Associated symptoms—none*

What do we make of this?

What is surprising is that for a disease that has gone on for 6 months without responding to any treatment, there has been no worsening or complications. Further, absence of any associated constitutional symptoms over such a long time span suggests that the condition is limited to the respiratory tract without any systemic spillover.

What could such a condition be?

- *Active, playful all along—No ill health*
- *Does not cough at night (sleep) or while playing*

Infections progress or complicate, allergic or atopic conditions wax and wane, therefore this does not seem to fit into any disease process. Therefore this could be habit cough or psychogenic cough.

This case illustrates the importance of finding out the functional disturbance caused by disease.

This is an important fourth component of clinical diagnosis—first three being anatomical, pathological, and etiological diagnosis. Once we know that this chronic cough has not affected the child's routine life or health, we are in a position to avoid lots of unnecessary investigations and drug therapy.

JAYPEE BROTHERS

Case Scenario 28

- A 6-year-old child, c/o cough for 6 months—multiple investigations negative, inhalers—no benefit
- Analysis?
- ***Persistent***, not recurrent
- Associated symptoms—none
- Active, playful all along—***no ill health***
- Does not cough at night (sleep) or while playing
- ***Habit cough***

JAYPEE BROTHERS

Case Scenario 29

- *A 5-year-old male, c/o fever with breathlessness—1 day*
- *O/E—respiratory distress, SpO_2—90%*
- *X-ray chest—right paracardiac opacity*
- *Admitted in pediatric intensive care unit (PICU), ventilated, stabilized quickly*
- *CT scan s/o pneumonia*
- *Now, stable—continues to be admitted to complete the course of vancomycin*
- *Comments? Anatomy, pathology, and etiology?*

What is the anatomy of the disease?

Is it pneumonia?

This child has presented with the complaints of fever with breathlessness for a day. It means that the child has developed both complaints within <24 hours of each other. Acute-onset breathlessness is commonly an airway disease (inhaled foreign body, asthma) and can also be a pleural disease (pneumothorax, allergic pleural effusion). However, parenchymal disease gives rise to gradual onset breathlessness. When high fever is followed by breathlessness as happens in a typical case of pneumonia, the breathlessness develops over a day or two after 2–3 days of high fever. The exception to this is a small infant or neonate with pneumonia. Hence, clinically, the anatomy in this child is either the airway or the pleura, but not the parenchyma.

Even if we analyze according to pathology, anything that is acute is allergic (asthma, allergic pleural effusion), mechanical (inhaled foreign body, pneumothorax), or vascular (embolism). Thus we come to the same differential diagnosis.

The X-ray does not show any pleural pathology. It demonstrates a right paracardiac opacity, which was reported to be pneumonia.

Can it still be pneumonia? We just argued against it.

The X-ray seems to contradict our analysis. Should we rely on the X-ray more than our analysis?

The mere presence of a radiological opacity cannot be labeled as pneumonia, unless one demonstrates clinical findings consistent with pneumonia. In this case, there is no mention of any such findings. Further, in order to diagnose such a shadow as pneumonia, one should be able to demonstrate an air bronchogram in majority of the cases. It is well known that atelectatic bronchopulmonary segments secondary to airway disease could give rise to a similar appearance, and therefore, this could be an airway disease. Thus, even though there is no pleural disease (as seen on X-ray), our earlier analysis can still stand, and this could be an airway disease. Further, the fact that this child presented with breathlessness does not correlate with the small opacity seen on X-ray and suggests a much more widespread disease. Therefore, it is more likely that this is an airway disease with a small opacity on X-ray.

This child was indeed confirmed to be suffering from bronchial asthma.

JAYPEE BROTHERS

Where did the treating physician go wrong?

- *Low fever, breathlessness over half an hour*
- *Past h/o frequent cough, personal, and family h/o atopy*

One must always take a detailed history and clarify complaints. Even if the treating physician did get carried away by the X-ray, the above discussed analysis should make us rethink and prompt us to go back to the details in the history. Indeed, this child had just a low fever, and he became breathless over half an hour. The past history was highly suggestive of hyper-reactive airway disease, and there was a personal and family history of atopy to favor a diagnosis of asthma.

So this child had actually presented with an acute attack of asthma. However, on encountering a breathless child who was hypoxic, clinical examination was sidelined and an X-ray was asked for. Since it was not correlated clinically, it misled. Meanwhile, since the hypoxia did not improve in a short time with administration of oxygen, the treating physician panicked and ventilated the child. Rapid improvement after ventilation is also against parenchymal disease and suggests airway disease. The child was fortunate not to land up with complications which are known to occur when asthmatics are ventilated.

This case reiterates the importance of getting detailed history of origin, duration, and progress of each symptom and further stresses the need to correlate laboratory findings with the clinical profile and not treat reports blindly.

Case Scenario 29

- A 5-year-old male, c/o fever with breathlessness—1 day
- ***O/E:*** Respiratory distress, SpO_2 90%
- ***X-ray chest***—right paracardiac opacity
- Admitted in PICU, ventilated, and stabilized quickly
- CT scan s/o pneumonia
- Now, stable—continues to be admitted to finish the course of vancomycin
- ***Comments? anatomy, pathology, and etiology?***
- ***Low fever, breathlessness over half an hour***
- ***Past h/o frequent cough, personal, and family h/o atopy***
- ***Asthma with collapse***

JAYPEE BROTHERS

Case Scenario 30

- *A 13-year-old female, c/o fever with chills (103–104°C), which started 8 days back; started on amoxycillin 500 mg tds by FP on D3 of fever; the next day developed left-sided chest pain which has increased in intensity, spread to left shoulder, and still persists. The intensity of fever has partially decreased.*
- *O/E:*
  - *In pain, but not toxic*
  - *L infrascapular and infra-axillary → decreased movements, dull note, reduced air entry—mild pain while percussing*
- *Total leukocyte count (TLC)—16,200 N 73 L 26 E 1*

Analysis?

Do you think this child has pneumonia? is it a pleural effusion?

What is the anatomy of the disease?

This child started with high fever, and the fever persisted for 3 days without any localizing symptoms. This suggests an infection/inflammation. At this point the family physician started an antibiotic. The subsequent symptoms suggest a pleural disease; in other words, the infection/inflammation was getting localized to the pleura. So the anatomy of the disease is pleura.

The X-ray chest shows a moderate left-sided effusion.

What is the pathology?

In bacterial infections, involvement of the pleura is secondary to underlying parenchymal involvement. This phase of parenchymal involvement (in the form of breathlessness) is not evident from this child's clinical course. Further, the examination reveals a pleural distribution of clinical signs, suggesting a pleural pathology. This suggests that the pleura is primarily involved; whenever, the pleura is involved secondary to underlying parenchymal disease, the clinical signs of the primary involvement dominate. Hence, this seems to be primary pleural inflammation.

What could be the etiology?

This is a well-nourished older child with primary pleural inflammatory disease. Tuberculous infection is known to lead to an allergic inflammation of the pleura, which can explain the high fever and the primary pleural involvement.

But this child has significant leukocytosis.

Doesn't that favor a bacterial infection?

Leukocytosis merely suggests acute stress/acute inflammation. The inflammation need not be bacterial in origin.

JAYPEE BROTHERS

- *Pleural tap—50 mL, cloudy*
  - *White blood cell (WBCs)—1,000/cmm, 70% poly, Proteins 6.3 g/dL*
  - *Lactate dehydrogenase (LDH)—3,098 U/L*
  - *Adenosine deaminase (ADA)—negative*

How do we analyze this report?

Doesn't a negative ADA go against the diagnosis of TB?

All that this report shows is that the pleural fluid is an exudate. It is only the clinical correlation that can define the etiology. This child was treated with antitubercular therapy (ATT) and responded well. Incidentally, an ultrasonography (USG) was also done which revealed free fluid and no loculations, again favoring a tuberculous disease. This case illustrates the immense importance of clinical correlation; unless this is done, laboratory reports can easily mislead.

Case Scenario 30

- A 13-year-old female, c/o fever with chills (103–104°C), which started 8 days back; started on Mox 500 tds by FP on Day 3 of fever; the next day developed left-sided chest pain which has increased in intensity, spread to left shoulder, and still persists.
- The intensity of fever has partially decreased.
- O/E—
  - In pain, but not toxic
  - L Infrascapular and infra-axillary: Decreased movements, dull note, and reduced air entry
  - Mild pain while percussing
- TLC—16,200 N 73 L 26 E 1
- Analysis?



JAYPEE BROTHERS

Case Scenario 30 (Contd.)

- ***Anatomy—pleura***
- ***Pathology—Pleural effusion (inflammatory) without pneumonia***
- ***Pleurla tap***—50 mL, cloudy
  - WBCs—1,000/cmm, 70% poly, Proteins 6.3 g/dL
  - LDH—3,098 U/L
  - ADA—negative
- ***USG***—free fluid in pleural cavity, no loculations
- ***Etiology—infection (tuberculosis)***

Pleural effusion in tuberculosis is usually allergic in nature, secondary to a small subclinical parenchymal focus that is often not evident even on a chest X-ray. The host's immune system decides the type of presentation. In an older healthy child, pleural disease presents as a large effusion with acute breathlessness while in an undernourished child, the immune response may not be as strong and the child may present with a slow development of a small effusion.

JAYPEE BROTHERS

for detailed information on pediatrics books, visit our website www.ejaypee.com, for detailed information on pediatrics books, visit our website www.ejaypee

Lessons from the Grand Rounds

STEER

Sensitizing to Think, Enabling Excellence and Rationality

STEER is a live interactive 6-hour module which **S**ensitizes the attendee to **T**hink thereby **E**nabling **E**xcellence and **R**ationality. More than 150 such live programs have been conducted so far all over the country and even abroad. Attendees of these programs requested a print format of the module to help them revise the concepts, which led to the production of this book. It attempts to reproduce the live interactive program—it tries to create an interaction with the readers by asking questions that are interspersed within the text describing the slides. Whenever the reader comes to a question, he/she is expected to pause, think, and formulate his/her own answer before going ahead and reading what the authors think is the answer. Like the live program, the book begins with how one should start with any patient, followed by important principles of history analysis, assessment of growth, fever, cough, and abdominal symptoms. Other systems like cardiovascular, neurological, endocrine, etc., are covered in the program STEER 2. Look out for the corresponding book "STEER 2" in the future!

Other books by the same authors:

- Lessons from the Grand Rounds 1
- Lessons from the Grand Rounds 2
- Lessons from the Grand Rounds for Office Practice
- Even When There is a Doctor

YK Amdekar MD DCH is a Senior Consultant Pediatrician with close to 60 years of experience. Presently he is a Senior Faculty, SRCC Children's Hospital, Mumbai, Maharashtra, India. He graduated from Grant Medical College, Mumbai, Maharashtra, India, joined the same institute as Faculty and went on to be Professor, Department of Pediatrics. Besides practicing as a visiting consultant at Jaslok and Breach Candy Hospitals in Mumbai for more than 40 years, he has also served as the President of the Indian Academy of Pediatrics in 1995 and as the Medical Superintendent of Bai Jerbai Wadia Children's Hospital, Parel, Mumbai, for many years. Aptly described as "teacher of teachers", his zeal and enthusiasm for teaching and his clarity of concept are unparalleled. He has been a guide to hundreds of postgraduate students and practicing pediatricians, and in his inimitable style, he has always focused on stimulating the learner to think, rather than imparting textual knowledge. Accordingly, he has devised many modules and written many books which emphasize clinical analysis.

RD Khare MD DCH graduated from Grant Medical College, Mumbai, Maharashtra, India, subsequently joined KJ Somaiya Medical College, Mumbai as Faculty, and also went on to be Professor, Department of Pediatrics. Presently, he is a Senior Consultant Pediatrician visiting Holy Family Hospital in Mumbai and is now in practice for more than 50 years. He has also trained numerous postgraduates and has been an examiner for DCH and MD examinations. He was one of the founder members who devised the Asthma Training Module for the first time. He is a regular Faculty at the "Thursday Clinics" which are being conducted by Dr Amdekar and his team, for postgraduates, every week since the year 2000, without a break. He is also a coauthor of many books with Dr Amdekar.

RR Chokhani MD DCH graduated from Grant Medical College, Mumbai, Maharashtra, India, as Dr Amdekar's student and went on to join him and Dr Khare in their joint clinical practice. Besides, he is also practicing as a visiting Consultant at PD Hinduja Hospital, Mumbai. He has been an integral part of many academic activities of Dr Amdekar and Dr Khare and has also been a coauthor of many of their books. He has served as the President of the Indian Academy of Pediatrics, Mumbai. He is an examiner not only for various postgraduate examinations but also for the MRCPCH Clinical Examinations conducted by the Royal College of Paediatrics and Child Health, UK.

Shelving Recommendation
PEDIATRICS

ISBN 978-93-6616-197-6

9 789366 161976

Buy from ejaypee

JAYPEE BROTHERS