d information on ophthalmology books, visit our website www.jaypeebrothers.com, for detailed information on ophthalmology books, visit our website www.jaypeebrothers.com



Solved Papers
Ophthalmology
for PG Students
A must for MS, DNB & DO

Smiti Rani Srivastava

Foreword
Asim Kumar Ghosh

JAYPEE

Contents

1. **Anatomy and Physiology** 1
   Arpita De, Tanweesha Chakraborty, Oindrila Chakraborty, Tiyasha Koner
2. **Optics and Refraction** 34
   Arpita De, Tanweesha Chakraborty, Oindrila Chakraborty, Mariam
3. **Eyelid** 97
   Prabrisha Banerjee, Koustav Bhunia
4. **Orbit** 115
   Prabrisha Banerjee, Puja Chowdhury, Koustav Bhunia
5. **Lacrimal Apparatus** 131
   Shashwat Bhattacharyya, Puja Chowdhury
6. **Conjunctiva** 141
   Smiti Rani Srivastava, Rituparna Ghosh
7. **Dry Eye** 157
   Smiti Rani Srivastava, Rituparna Ghosh, Puja Chowdhury
8. **Episclera and Sclera** 165
   Smiti Rani Srivastava, Rituparna Ghosh
9. **Cornea** 170
   Sony Sinha, Smiti Rani Srivastava
10. **Refractive Surgery** 183
    Prateek Nishant, Sony Sinha
11. **Lens** 189
    Smiti Rani Srivastava, Rituparna Ghosh, Erum Hayet
12. **Glaucoma** 219
    Sandip Samaddar, Niranjan Karthik, Rituparna Ghosh, Arun Kumar Singh
13. **Uvea** 271
    Sangeeta Roy, Smiti Rani Srivastava
14. **Ocular Tumors** 290
    Rituparna Ghosh, Rituparna Sarkar
15. **Diseases of the Retina** 299
    Rupak Roy, Soumava Mandal, Sangeeta Roy, Ekta Bharti
16. **Retinal Detachment** 312
    Soumava Mandal, Rupak Roy, Sangeeta Roy, Debleena Mitra
17. **Vitreous Disorders** 327
    Soumava Mandal, Rupak Roy, Ekta Bharti, Ayantika Das

18. Diseases of Macula **334**
Rupak Roy, Kshitiz Kumar, Soumava Mandal, Sangeeta Roy, Ekta Bharti, Bratatee Roy

19. Strabismus **367**
Suman Mukherjee, Anchal Mitra, Erum Hayet

20. Neuro-Ophthalmology **386**
Suman Mukherjee, Soumyajit Guha, Rituparna Sarkar, Tiyasha Koner

21. Ocular Injuries **412**
Rajkumari Bigyabati

22. Community Ophthalmology **446**
Sinjita Dutta

23. Ocular Therapeutics and Laser **460**
Shashwat Bhattacharyya, Tanweesha Chakraborty, Oindrila Chakraborty

24. Ocular Manifestations of Systemic Diseases **482**
Smiti Rani Srivastava, Rajkumari Bigyabati, Rituparna Sarkar

25. Miscellaneous **499**
Smiti Rani Srivastava, Rituparna Ghosh, Rituparna Sarkar

Index *525*

3

CHAPTER

Eyelid

Prabrisha Banerjee, Koustav Bhunia

QUESTIONS

1. **Describe the anatomy and development of eyelids with a labelled diagram. (10) (DNB 2024)**
2. **Discuss meibomian gland dysfunction. (10) (DNB 2018)**
3. **Trichiasis—Short Note (5) (BHU MS 2018)**
4. **Lagophthalmos—Short Note (5) (BHU MS 2017)**
5. **Mention principles of ptosis surgery. How will you manage a case of congenital ptosis with Marcus Gunn Jaw-Winking Phenomenon? (5+5) (DNB 2020)**
6. **Discuss the management of congenital ptosis with Marcus Gunn Jaw-Winking Phenomenon. (5) (DNB 2020)**
7. **Describe sling surgery for ptosis. (10) (TNMGRMU MS 2021)**
8. **Discuss entropion. (10) (RGUHS MS 2018)**
9. **Describe surgical management of entropion. (10) (BHU MS 2020)**
10. **Cicatricial entropion—Short Note (5) (TNMGRMU MS 2019)**
11. **Describe the classification and surgical management of ectropion. (10) (TNMGRMU 2022/BHU 2018)**
12. **A 75-year-old female presented with an ulcerated lesion in the medial side of the left lower eyelid for 2 years, size 15 mm × 10 mm. Discuss its differential diagnosis and management. (10) (DNB 2019)**
13. **Lid tumor excision. (10) (BHU MS 2021)**
14. **Write briefly on eyelid coloboma. (10) (DNB 2019)**

1. Describe the anatomy and development of eyelids with a labelled diagram. (10) (DNB 2024)

In a young adult:

- The interpalpebral fissure height is approximately 10-11 mm
- The horizontal fissure length is 30-32 mm
- The upper and the lower lid meet at the medial canthus and the lateral canthus at an angle of 60°.
- Lateral canthus rests against the globe, but the medial canthus is displaced away by the lacus lacrimalis comprising the caruncle and the plica semilunaris.
- The lateral canthal angle lies 2 mm higher than the medial canthal angle.
- The upper eyelid covers 2 mm of the cornea in primary gaze, and the lower lid rests on the inferior limbus.
- The eyelid consists of the following structural planes
  - The skin and subcutaneous fascia
  - The orbicularis oculi muscle
  - The orbital septum

JAYPEE BROTHERS

- The eyelid retractors
- The tarsal plates and conjunctiva

- The attachment of superficial fibers of the levator palpebral superioris muscle to the orbicularis muscle and the subcutaneous tissue gives rise to the skin crease (6-7 mm in males, 7-8 mm in females).
- The eyelid skin is very thin and devoid of any subcutaneous fat.
- The orbicularis muscle consists of three parts, namely, orbital, pre-septal, and pre-tarsal
  - Orbital part – originates from the frontal process of the maxilla, orbital process of the frontal bone and the medial canthal ligament, passes around the orbital margins and inserts just below the points of origin. It helps in the forced closure of the eyelids.
  - Pre-septal part – lies over the orbital septum. The upper eyelid has a superficial and deep head originating from the medial palpebral ligament and the posterior lacrimal crest. The fibers pass over the septum superiorly and inferiorly and insert at the lateral palpebral raphe.
  - Pre-tarsal part – lies over the tarsal plate. The upper and lower lid muscles originate from a superficial head (from the medial palpebral ligament) and a deep head (from the lacrimal fascia and posterior lacrimal crest). The fibers pass laterally and are inserted into Whitnall's tubercle. The muscle fibers arising from the posterior lacrimal crest (Horner's muscle) help in the drainage of tears.
  - The palpebral part helps in the gentle closing of the eyelids.
- Orbital Septum – multi-layered fibrous membrane which inserts superiorly into the periosteum over the superior orbital rim. It merges with the fibers of levator aponeurosis above the superior tarsal border.
- Orbital Fat – there are 2 pockets of fat; nasal and central in the upper lid posterior to the orbital septum and 3 pockets of fat in the lower lid.
- Retractors – levator palpebral superioris originates from the lesser wing of sphenoid. The muscular part is 40 mm, runs horizontally, the aponeurotic part is 20 mm in length becomes vertical after crossing Whitnall's ligament. It inserts onto the tarsal plate, the medial horn into the posterior lacrimal crest and the lateral horn at Whitnall's tubercle. Few fibers insert into the skin and form the skin crease, and in the superior fornix. It is supplied by the Oculomotor nerve. Capsulopalpebral fascia acts as lower lid retractor. The other lid retractors are Muller muscle for the upper lid and inferior tarsal muscle for the lower lid.
- Tarsal plates – the upper tarsal plate measures 11 mm, while the lower tarsal plate is 3-4 mm. The tarsal plate contains meibomian glands.
- Conjunctiva – lines the posterior surface of the lid, composed of non-keratinizing squamous epithelium. Harbors the accessory lacrimal glands.
- Blood supply – The eyelid is mainly supplied by the supraorbital and lacrimal arteries.
- Lymphatics – Medial side drains into the submandibular glands, lateral part drains into the superficial preauricular glands and deep cervical nodes.
- The structures of upper and lower eyelid are given in **Figures 1 and 2**, respectively.

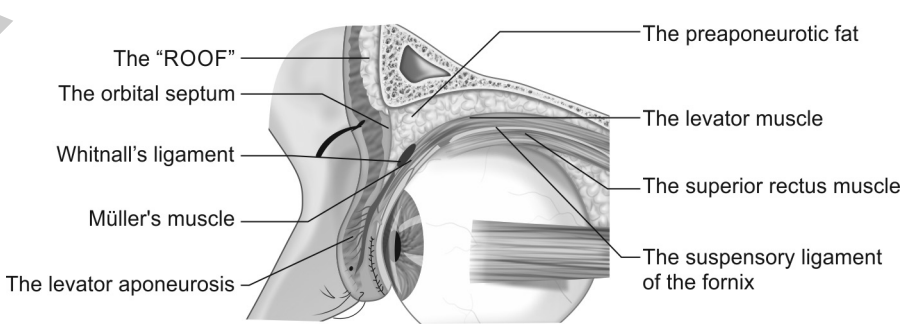

Fig. 1: Anatomy of upper eyelid.

JAYPEE BROTHERS

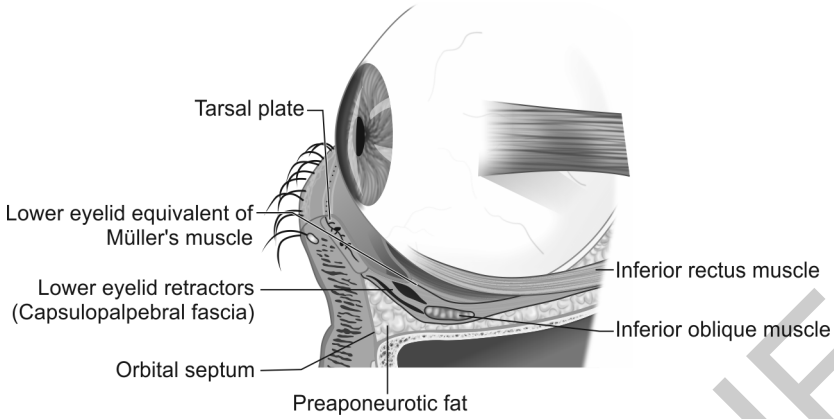

Fig. 2: Anatomy of the lower eyelid.

2. Discuss meibomian gland dysfunction. (10) (DNB 2018)

Definition- It is the chronic, diffuse abnormality of the meibomian glands, commonly characterized by terminal duct obstructions and/or qualitative/quantitative alterations of its secretions leading to a spectrum of ocular surface diseases.

- According to the International Workshop on Meibomian Gland Dysfunction, MGD can be an obstructive disease or it can be caused by a hyposecretory state.
- Obstructive MGD can be cicatricial secondary to trachoma, mucous membrane pemphigoid, or atopy) and non-cicatricial secondary to seborrheic dermatitis, rosacea, or atopy.
- Pathophysiology—Obstruction is the most common cause of MGD. The underlying pathophysiology is epithelial hyperkeratinization, which causes duct obstruction, leading to meibum stasis, cystic dilation, and eventually acinar atrophy due to disuse, and gland dropout.
  - *Aging:* Meibomian gland acinar epithelial cell atrophy and decreased lipid production occurs with aging.
  - *Microbiome: Staphylococcus epidermidis*, *Staphylococcus aureus*, and *Propionibacterium acnes* are most commonly involved. These bacteria produce lipolytic enzymes and release inflammatory mediators, leading to lipolysis in the tear film.
  - *Environmental stress:* Low-humidity environments cause increased meibum production. This leads to ductal dilation and a decrease in the number of functioning meibocytes, causing gland atrophy and hyposecretion.
  - *Hormonal effects:* Androgens stimulate meibum secretion and suppress inflammation, while estrogens tend to increase inflammation.
  - *Contact lens use:* Contact lenses result in irreversible meibomian gland dropout in the long run.
  - *Medications:* Medications like β-blockers and carbonic anhydrase inhibitors, and retinoic acid leads to hyposecretion.
  - *Congenital:* Reduced number of or absent meibomian glands is seen in patients with Turner syndrome, ectrodactyly with ectodermal dysplasia and cleft lip and palate (ECC syndrome), and anhidrotic ectodermal dysplastic syndrome, and in distichiasis.
- High delivery state of MGD occurs due to release of a large lipid volume at the lid margin. Seborrheic dermatitis and acne rosacea are 2 common causes of high-delivery MGD.
- Symptoms:
  - Burning
  - Foreign-body sensation
  - Redness of the eyelids
  - Conjunctival injection
  - Filmy vision

JAYPEE BROTHERS

- Clinical signs:
  - Seborrheic and eczematoid changes of the anterior eyelid margin
  - Telangiectatic blood vessels and metaplasia of the eyelid margins
  - Pouting of the meibomian gland orifices
  - Foamy discharge and irregularity at the posterior eyelid margin
  - Turbid, cheesy, or toothpaste-like meibomian secretions
  - Posteriorly displaced meibomian gland orifices
- Evaluation

  Tear film volume
  - Tear osmolarity
  - Tear film break-up time (TBUT)
  - Schirmer test
  - Corneal and conjunctival staining
  - *Slit lamp assisted grading recommendations:* Photographic assessment for comparison with healthy controls and other set of patients used for developing grading scales
  - *Lipid layer thickness (LLT):* Lipiview interferometer used, LLT cutoff < 60nm used
  - *In vivo confocal microscopy (IVCM):* gland dilatation, acinar diameters calculated; high sensitivity and specificity
  - *Noncontact infrared meibography:* Infrared light used; objective and repeatable; drug and age-related gland loss identified.

  Staging of MGD are mentioned in **Table 1**.

TABLE 1: Staging of MGD.

Stage	*MGD Grade*	*Symptoms*	*Corneal Staining*
1	+ (minimally altered expressibility and secretion quality)	None	None
2	++ (mildly altered expressibility and secretion quality)	Minimal to mild	None to limited
3	+++ (moderately altered expressibility and secretion quality)	Mild-to-moderate	Mainly peripheral
4	++++ (severely altered expressibility and secretion quality)	Marked	Peripheral and Central

- Management
  - Optimization of working environment, reduction in screen time, regular warm compress.
  - Expression of accumulated secretions.
  - Topical azithromycin – broad spectrum macrolide antibiotic with anti-inflammatory property.
  - Artificial lubricants for use.
  - Topical emollients help stabilize tear film
  - Topical Cyclosporine A 0.05%, or topical steroid in severe stages, helps reduce inflammation.
  - Increase in dietary omega 3-fatty acid intake (1.5 gm daily).
  - Oral tetracyclines in severe MGD.
  - Intraductal probing – aids in mechanical opening and dilatation of the blocked meibomian gland orifices and ducts. Initially, 1 to 2 mm Maskin probes aid in dilating the ducts, followed by 4 to 6 mm probes to achieve ductal patency.
  - Electronic Heating Device - This delivers heat simultaneously to the palpebral conjunctiva of both upper and lower lids. Concurrently, it also helps express meibomian gland content by providing pressure to the outer eyelid surfaces in a pulsatile manner. Example: LipiFlow (Johnson and Johnson), Systane iLux and Systane iLux MGD Thermal Pulsation Systems (Alcon) are handheld devices.

JAYPEE BROTHERS

3. Trichiasis—Short Note (5) (BHU MS 2018)

- Trichiasis is defined as inward growth of normal lashes.
- In trichiasis, the lash follicle is normal, but the direction of lash growth is abnormal.
- There may be misdirection of the follicles in associated inflammation.
- Trichiasis may be classified as major (> 5 cilia), or minor (< 5 cilia)
- Causes—Chronic blepharitis, chemical injury, thermal burns, Herpes Zoster, eyelid trauma, eyelid surgery, atopic disease, vernal keratoconjunctivitis, cicatricial conjunctival diseases, meibomitis, eyelid tumors, trachoma
- Eyelids should be looked for scarring, symblepharon, margin keratinization and the cornea should be stained to detect keratopathy.
- Complications—Ocular irritation, lacrimation, punctate epithelial erosion, corneal abrasion, corneal ulcer, pannus formation
- Management:
  - Manual epilation of trichiatic lashes and bandage contact lens offer short-term relief.
  - Electrolysis with radiofrequency needle causes permanent destruction of the roots of the trichiatic lashes. (Contraindicated in patients with pacemaker). However, there are chances of recurrence and patients may require multiple sittings.
  - Argon laser ablation is useful for a few darkly pigmented trichiatic lashes.
  - Cryotherapy—Reduction of the temperature to -25 degrees destroys the lash bulb without inducing tissue necrosis. A double freeze-thaw technique is used. It leads to hypopigmentation of the skin. Risk of recurrence is present.
  - Trephination/Eyelash bulb extirpation – less commonly used.
  - Surgical excision—Localized area of trichiatic lashes with eyelid laxity can be managed with wedge excision and direct closure.

4. Lagophthalmos—Short Note (5) (BHU MS 2017)

- Lagophthalmos is defined as incomplete closure of the eyes.
- The underlying pathophysiology includes facial nerve palsy, proptosis, eyelid retraction, and anterior lamellar shortening due to scarring.
- Facial nerve palsy is the most common etiology of lagophthalmos.
- Facial nerve palsy can be idiopathic (Bell's palsy) or secondary to infection (viral, bacterial, mastoiditis), trauma, tumor (cerebropontine tumors, parotid tumor), iatrogenic (parotid surgery, mastoid surgery, excision of cerebropontine tumors).
- Evaluation comprises
  - Detailed history—onset, duration, past surgery, trauma, pain and discharge in ear, hearing loss, neurosensory deficits, past medical history like diabetes mellitus, myasthenia gravis, sarcoidosis, past history of Botulinum toxin injection.
  - Upper motor neuron disease—will spare the frontalis muscle
  - Lower motor neuron disease—will lead to loss of forehead furrows, brow ptosis, upper lid retraction, lagophthalmos, reduced blink rate, lower lid ectropion, loss of nasolabial fold, oral droop, and difficulty in speech.
  - Lagophthalmos is measured as the vertical height at the greatest distance of the palpebral fissure.
  - Bell's phenomenon should be documented.
  - Nocturnal exposure of cornea should be enquired.
  - Corneal sensation.
  - Corneal staining to detect exposure keratopathy.
  - Tear film assessment.
  - Other facial muscles should be assessed.
  - Examination of other cranial nerves.
  - To look for signs of aberrant regeneration, hemifacial spasm

JAYPEE BROTHERS

- Investigation—Computed tomography (CT) of brain with contrast helps to detect space-occupying lesions, magnetic resonance imaging (MRI) brain with contrast aids in detecting neurovascular conflict.
- Management
  - Initially, in the acute phase, artificial tears are prescribed to maintain the tear film. Taping of the eyelids with ointment at night is advocated. Patient is advised physiotherapy.
  - Severe lagophthalmos, poor Bell's phenomenon, reduced corneal sensation, and dry eyes are indications for surgical intervention in the form of lateral tarsorrhaphy.
  - If there is nil or mild improvement in the eyelid closure after six months, gold weight/platinum weight implant is applied.
  - In mild-to-moderate lid retraction cases, Muller muscle and levator palpebral superioris recession is the treatment of choice.
  - Lower lid ectropion can be corrected by lateral tarsal strip with or without a spacer graft depending on the severity.
- In lagophthalmos secondary to proptosis, the underlying cause should be diagnosed and treated.
- In anterior lamellar scarring, hyaluronic acid gel filler can be useful. In anterior lamellar shortening, a full-thickness skin graft is needed.

5. Mention principles of ptosis surgery. How will you manage a case of congenital ptosis with Marcus Gunn Jaw-Winking Phenomenon? (5+5) (DNB 2020)

6. Discuss the management of congenital ptosis with Marcus Gunn Jaw-Winking Phenomenon. (5) (DNB 2020)

- Ptosis or blepharoptosis is defined as drooping of the upper eyelid in the primary gaze.
- There are mainly two components of ptosis surgery:
  1. Functional— improvement in superior visual field prevention of amblyopia
  2. Cosmetic—achieving a good eyelid contour symmetrical palpebral fissure height in both eyes
- Congenital ptosis with Marcus Gunn Jaw-Winking Phenomenon
- Margus Gunn Jaw Winking Syndrome (MGJWS) is associated with 2%-13% cases of congenital ptosis.
- It is mostly unilateral but can be bilateral rarely.
- It manifests as a coordinated synkinetic movement of the upper eyelid and the jaw due to an abnormal connection between the motor branches of the trigeminal nerve and the superior division of oculomotor nerve.
- There are 2 types of trigemino-oculomotor synkinesis as follows:
  - External pterygoid-levator synkinesis: Lid elevates when the mouth is widely open.
  - Internal pterygoid-levator synkinesis: Lid elevates on teeth clenching
- It is often associated with strabismus, monocular elevation deficiency.
- Detailed history and reviewing past photographs are highly recommended.
- Ocular examination:
  - Visual acuity and refraction.
  - Cover test for unveiling hypotropia and rule out any component of pseudoptosis.
  - Extraocular motility.
  - Pupillary examination.
  - Examination to look for any giant papillary conjunctivitis or symblepharon.
  - Corneal sensation and dry eye evaluation.
  - Fundus examination.
- Ptosis evaluation:
  - *Palpebral fissure height (PFH):* Vertical aperture height between upper and lower lid in the pupillary plane with eyes in primary gaze. Normal value is 9-10 mm.
  - *Margin-reflex distance 1 (MRD1):* The distance between upper eyelid margin and corneal light reflex. Normal value is 4 mm.

JAYPEE BROTHERS

- The difference of 2 mm in MRD 1 between the 2 eyes = mild ptosis, difference of 3 mm = moderate ptosis and 4 mm = severe ptosis respectively.
  - Levator action—amount of excursion measured after negating frontalis action when the eyelid moves from extreme downgaze to extreme upgaze. It is graded as:-
    Less than 4 mm – Poor
    5 to 9 mm – Fair
    9 to 11 mm – Good
    Greater than 12 mm – Excellent
    Iliff test: If the upper lid returns to its original position immediately after eversion of the upper lid, then the LPS action is considered to be good.
  - Margin crease distance (MCD): Distance between the lid margin and skin crease in downgaze. Normal MCD is 7 to 8 mm in men and 8 to 10 mm in women. In congenital ptosis, MCD is usually absent or faint.
  - Lagophthalmos
  - Bell's phenomenon
  - The lid excursion should be measured and graded as mild = 2 mm, moderate = 2 mm to 5 mm, and severe = higher than 5 mm
- The indications for ptosis correction in a pre-school child are
  - Anisometropia
  - Amblyopia
- In cases with strabismus, first strabismus surgery is done, followed by ptosis correction.
- It is important to ascertain if the ptosis or the wink is the main concern of the patient and the parents.
- In MGJWS with mild-to-moderate excursions, frontalis sling surgery is preferred.
- In MGJWS with severe excursions, or in case the patient and parents are more concerned about the wink, levator extirpation with frontalis sling surgery is performed.
- In amblyopic children, the patching should be continued after the ptosis correction.

7. Describe sling surgery for ptosis. (10) (TNMGRMU MS 2021)

- The tarsofrontalis sling surgery is aimed to harness the action of the frontalis muscle to elevate the eyelids.
- Normally, the frontalis muscle contributes 10 mm to 15 mm of elevation.
- Indications for sling surgery:
  - Poor Levator function
  - Marcus Gunn Jaw-Winking Syndrome
  - Blepharophimosis
  - Ptosis in Third Nerve Palsy
  - Myasthenia Gravis
  - Chronic Progressive External Ophthalmoplegia
- The various materials used for the sling can be classified as mentioned in **Table 2**:

TABLE 2: Classification of various materials used for the sling.

Autogenous	***Allogenic***	***Synthetic***
Fascia lata	Banked fascia lata	Silicon rod
Palmaris longus tendon		Prolene
Temporalis fascia		Mersilene Mesh
		Gortex

- Techniques:
  - Fox pentagon technique:
    - General anesthesia is used for children, local anesthesia for adults.

JAYPEE BROTHERS

- Two eyelid markings are made 2 mm from the lid margin at the medial and lateral limbus.
- Two eyebrow markings are made just above the eyebrows corresponding to the medial and lateral canthus. A central forehead marking is made in the pupillary plane 1cm above the eyebrow.
- Stab incisions are made on the markings.
- The silicon rod is passed through the forehead, medial eyebrow, medial pre tarsal orbicularis, lateral pretarsal orbicularis, lateral eyebrow, and both the ends are placed inside a sleeve and buried at the forehead wound **(Fig. 3)**

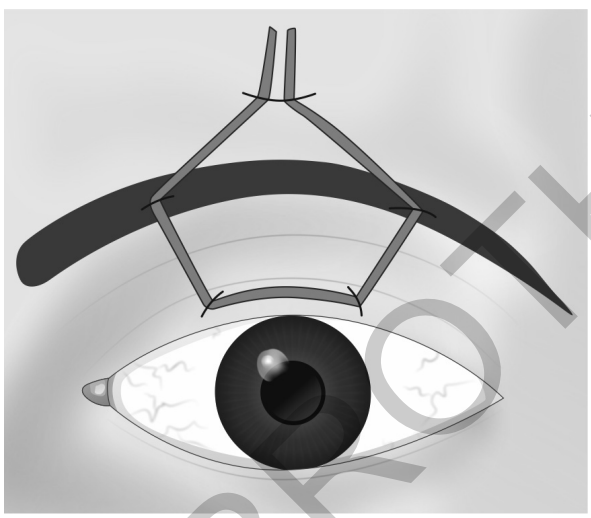

Fig. 3: Fox pentagon frontalis sling surgery.

- Crawford technique-
  - Double triangle technique **(Fig. 4)**
  - Usually done with autogenous fascia lata.
  - The child must be more than 3 years of age for the legs to develop completely for harvesting fascia lata.

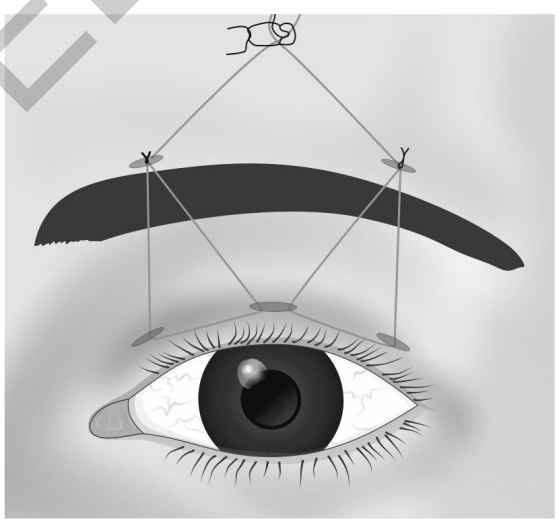

Fig. 4: Crawford technique.

- Complications—undercorrection, overcorrection, lagophthalmos, exposure keratopathy, eyelid contour defects, granuloma, silicone rod exposure, and extrusion.

JAYPEE BROTHERS

8. Discuss entropion. (10) (RGUHS MS 2018)

9. Describe surgical management of entropion. (10) (BHU MS 2020)

10. Cicatricial entropion—Short Note (5) (TNMGRMU MS 2019)

- Entropion is defined as inward turning of the eyelid margin.
- It can be unilateral or bilateral.
- There are 4 types of entropion:
  - Involutional
  - Cicatricial
  - Acute spastic
  - Congenital
- Involutional entropion
  - Caused by horizontal laxity of the eyelid, attenuation or disinsertion of eyelid retractors, and overriding by the preseptal orbicularis oculi muscle over the pretarsal muscle fibers.
  - Enophthalmos due to orbital fat atrophy is a contributing factor.
- Cicatricial entropion
  - Transconjunctival scarring leads to the cicatricial entropion.
  - It is caused by chemical injury, burn injury, trauma, eyelid surgery, topical glaucoma medications, Stevens Johnson syndrome, ocular pemphigoid, Herpes zoster infection, and trachoma.
- Acute spastic entropion
  - This is seen in patients with reflex blepharospasm.
  - Initially this is reversible once the underlying cause of ocular irritation is treated.
  - Untreated cases may become permanent and need surgical correction.
- Congenital entropion
  - This is the rarest form.
  - The underlying pathogenesis includes abnormal insertion of the lower lid retractors, posterior lamella insufficiency, and kinking of the tarsal plate.
  - This needs surgical correction.
- Symptoms – watering, ocular irritation due to the rubbing of the eyelashes and the lid margin against the ocular surface, photophobia
- Evaluation –
  - The eyelid should be assessed for horizontal lid laxity
  - *Snap back test:* The middle portion of the lower eyelid is fully displaced by pulling it down. After releasing the lid, it should immediately return to its original position in a healthy lower eyelid.
  - The grading scale depends on how long the lower lid takes to spring back into the globe.
  - *Grade 0:* Takes less than 2 seconds
  - *Grade I:* Takes 2 or 3 seconds
  - *Grade II:* Takes 4 or 5 seconds
  - *Grade III:* Takes more than 5 seconds but returns to its normal position with blinking
  - *Grade IV:* Never returns back to the normal position
  - *Pinch test:* The patient is asked to look up with an open mouth. The skin of the lower eyelid below the lashes is grasped and the distance the lid can be distracted from the globe is measured.
  - A healthy lid will not distract more than 6 mm from the globe.
  - Punctum is assessed to look for punctal entropion.
  - Eyelid distraction test – to assess the medial and lateral canthal laxity. Distraction of the lateral canthal more than 2 mm shows canthal laxity. Medial canthal laxity is examined by the displacement of the lower punctum from its resting position and graded as grade 0 (at plica semilunaris), grade 2 (medial limbus), and grade 4 (mid pupil).

JAYPEE BROTHERS

- The signs for lower lid retractor disinsertion should be examined. The eyelid margin rolls over the inferior limbus in such cases and poor movement of the eyelid when the patient looks down.
- Ocular surface examination for associated trichiasis, posterior lamellar scarring, lid margin keratinization, punctate keratopathy, epithelial defect and corneal abrasion.

- Grade of entropion:
  - *Grade 1:* Inward turning of the posterior lamella
  - *Grade 2:* Inward turning of the grey line
  - *Grade 3:* Inward turning of the anterior lamella
- Management
  - The stimulus inducing acute spastic entropion should be addressed.
  - Acute spastic entropion due to blepharospasm can be managed with botulinum toxin injection at the initial stages.
  - Elderly patients with involutional entropion can get temporary relief with botulinum toxin injection and taping of lower lid.
- Surgical management
- Involutional entropion –
  - Everting suture – prevents upward movement of preseptal orbicularis fibers, tightens lower lid retractors **(Fig. 5)**.

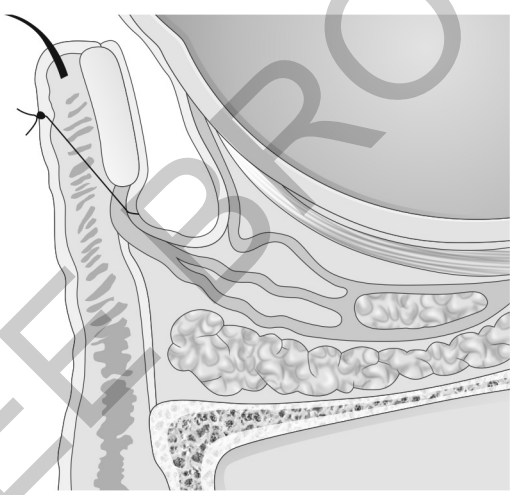

Fig. 5: Everting suture.

  - Weis procedure—the full thickness eyelid split below tarsal plate creates a scar that prevents overriding of the preseptal fibers of the orbicularis and the everting sutures tighten the lower lid retractors **(Fig. 6)**

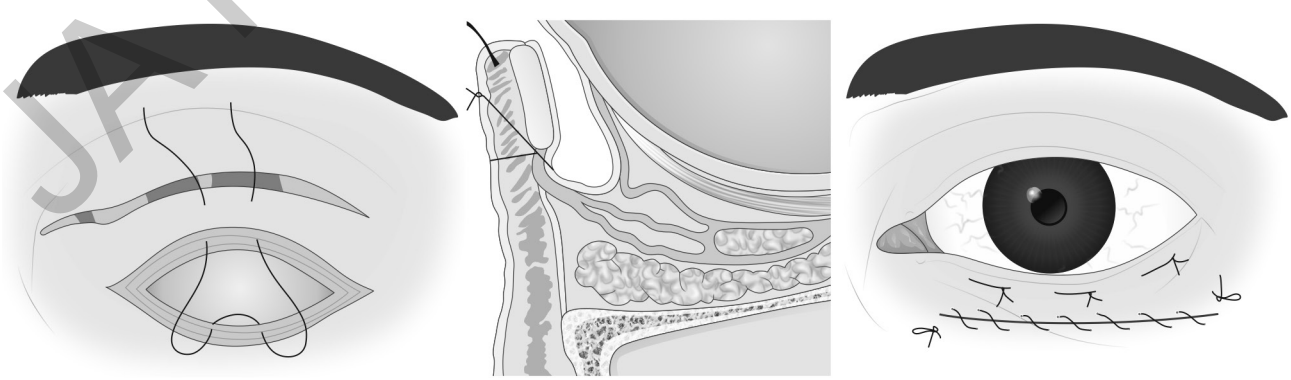

Fig. 6: Weiss procedure.

JAYPEE BROTHERS

- Lateral tarsal strip—for significant horizontal eyelid laxity, canthal laxity, lateral tarsal strip is performed with everting sutures.
- Quickert procedure—comprises traverse lid splitting, horizontal lid shortening and everting sutures. It provides long-term cure for entropion.
- Jones procedure—lower lid retractor plication. It is indicated in lower lid retractor disinsertion and recurrent entropion **(Fig. 7)**.

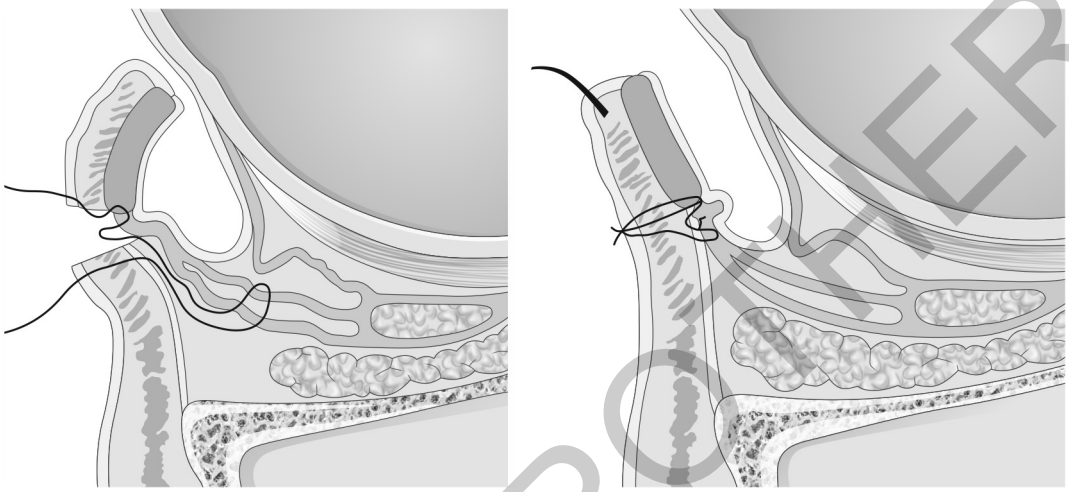

Fig. 7: Jones procedure.

- Cicatricial entropion—
  - Mild lower lid cicatricial entropion can be treated with tarsal fracture and everting sutures. Lower lid should not be retracted more than 1.5mm below limbus **(Fig. 8)**.

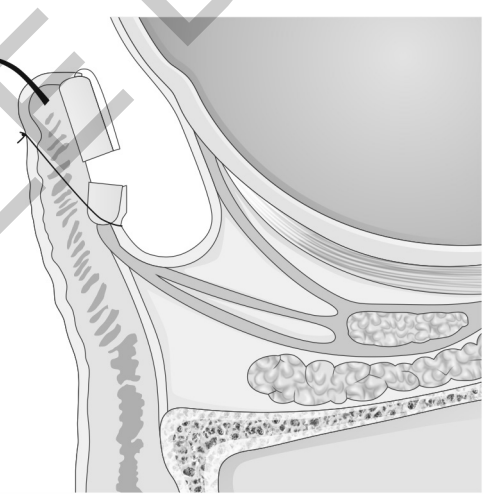

Fig. 8: Tarsal fracture.

  - For moderate to severe cases where lower lid retraction is more than 1.5 mm below – posterior lamellar graft is needed.
  - Oral mucus membrane or hard palate graft are usually used **(Fig. 9)**.

JAYPEE BROTHERS

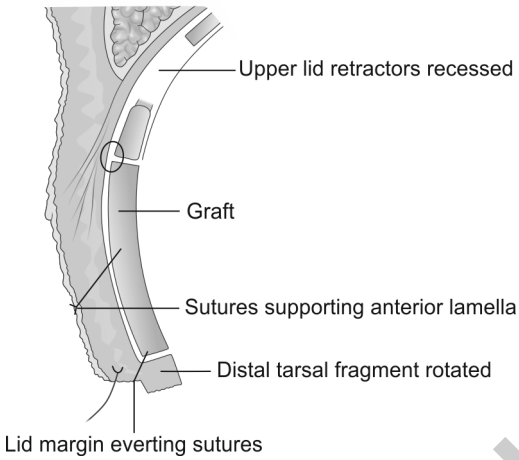

Fig. 9: Posterior lamellar graft.

- In upper lid entropion, mild-to-moderate entropion is corrected with anterior lamellar repositioning with or without eyelid split.
- In presence of tarsal scarring or severe entropion, posterior lamellar graft is the treatment of choice.
- Lid margin rotation is done in cases of entropion associated with eyelid margin keratinization.

- Congenital entropion is managed with posterior lamellar grafts usually under general anesthesia. Epiblepharon cases are usually observed as they resolve spontaneously with age. In non-resolving cases, Hotz procedure is done.
- *Complications:* Wound dehiscence, infection, hematoma, overcorrection, undercorrection, recurrence, scarring, lateral canthal deformity.

11. Describe the classification and surgical management of ectropion.

(10) (TNMGRMU 2022/BHU 2018)

- Ectropion is defined as eyelid malposition in which eyelid margin is turned away from the globe.
- Lower lid is commonly involved.
- The types of ectropion are:
  - Involutional ectropion
  - Paralytic ectropion
  - Cicatricial ectropion
  - Mechanical ectropion
  - Congenital ectropion
- Involutional ectropion:
  - Occurs due to senile changes, horizontal lid laxity, and disinsertion of lower lid retractor.
  - There can be associated medial canthal and lateral canthal laxity.
- Paralytic ectropion:
  - Seen in facial nerve palsy
  - Poor tone of orbicularis muscle
  - Associated with lagophthalmos
  - Punctal eversion is commonly seen
- Cicatricial ectropion:
  - Occurs secondary to scarring and shortening of anterior lamella.
  - Mainly seen in trauma, chemical injury, burn, atopic dermatitis, and post blepharoplasty, eyelid reconstruction, or orbital surgery.
  - Lamellar ichthyosis also presents with cicatricial ectropion.

JAYPEE BROTHERS

for detailed information on ophthalmology books, visit our website www.jaypeebrothers.com, for detailed information on ophthalmology books, visit our website www.jaypeebrot

Solved Papers
Ophthalmology
for PG Students

Salient Features

- Solved Papers in Ophthalmology is meant for MS, DNB, and DO Ophthalmology students
- It is a must-read for students appearing for their final MS, DNB, and DO examinations
- The questions over the last 5 years that have appeared in different universities across the country have been classified chapter-wise
- The answers provided are in line with standard ophthalmology textbooks, in a simple point-wise manner with schematic diagrams and flowcharts
- The question-answer format can be easily revised before the examinations and represented in the answer within the limited time of the examinations.



Smiti Rani Srivastava MBBS (Hons) MS MRCS FRCS (Glasgow) is a distinguished ophthalmologist and currently serves as Professor and Head of the Department of Ophthalmology at the Institute of Post Graduate Medical Education & Research (IPGME&R) and SSKM Hospital, Kolkata, West Bengal, India. A graduate with honors from Rajendra Medical College and Hospital, Ranchi, Jharkhand, India, she pursued MS in Ophthalmology from Kolkata. She further attained Membership of the Royal College of Surgeons (MRCS) and later earned Fellowship of the Royal College of Surgeons (FRCS), Glasgow, underscoring her expertise in the field. Prior to her current role, she served at the Regional Institute of Ophthalmology (RIO), Kolkata, focusing on cataract and pediatric ophthalmology. During the COVID-19 pandemic, she played a pivotal role in IPGME&R SSKM Hospital's Mucormycosis Core Team, contributing significantly to the medical and surgical treatment of disease when the institute was designated as a state center of mucormycosis management. Dr Srivastava is an avid researcher with numerous publications in national and international journals, particularly in the field of mucormycosis and pediatric ophthalmology. Additionally, she has been the Principal Investigator for a research project on Congenital Ocular Disorders and their Association with Genetic Variants under the aegis of the Medical Research Unit, IPGME&R. She has presented in national and international forums and has been a peer reviewer in national and international indexed journals. Drawing upon her extensive clinical and academic experience as a passionate undergraduate and postgraduate teacher, Dr Srivastava hopes this book will be a valuable resource for students preparing for the final MS, DNB, and DO examinations in ophthalmology.

Printed in India

Available at all medical bookstores or buy online at www.ejaypee.com

JAYPEE BROTHERS
Medical Publishers (P) Ltd.
EMCA House, 23/23-B, Ansari Road,
Daryaganj, New Delhi - 110 002, INDIA
www.jaypeebrothers.com

Join us on facebook.com/JaypeeMedicalPublishers
Follow us on instagram.com/JaypeeMedicalPublishers

Shelving Recommendation
OPHTHALMOLOGY

ISBN 978-93-6616-230-0