tailed information on ophthalmology books, visit our website www.jaypeebrothers.com, for detailed information on ophthalmology books, visit our website www.jaypeebrothers.com

Complimentary Online 57 Videos Duration 4 hours 3 minutes

OCULUS RES GESTAE

A NEOPHYTE'S ANIMATIVE & VIDEOGRAPHIC COMPENDIUM



Editors-in-Chief

Prasanna Venkatesh Ramesh

Shruthy Vaishali Ramesh

Forewords

Lalit Verma • S Natarajan • Shibal Bhartiya • Mohan Rajan
VR Vijayaraghavan • P Sathyan • Diva Kant Misra

JAYPEE

Contents

1. **Anatomy of Limbus** 1
   Zain Khatib
2. **Lens Embryology and Growth** 2
   Nilesh Kumar
3. **Physiology of Eye and Vision** 20
   Mary Stephen, Kalyan Basa, Karthikeyan Mahalingam
4. **Refraction Part 1** 30
   Zain Khatib
5. **Refraction Part 2** 31
   Zain Khatib
6. **Basic Concepts Related to Strabismus** 32
   Zain Khatib
7. **Evaluation of a Case of Squint** 33
   Zain Khatib
8. **Strabismus** 34
   Gunjan Saluja
9. **Ocular Surface Disorders** 54
   Ritu Singh
10. **Corneal Lacerations and Management Protocols** 58
    Sunandini Bose
11. **Keratoconus** 70
    Sai Thaejesvi, Prasanna Venkatesh Ramesh, Shruthy Vaishali Ramesh, Navaneeth Krishna MP, Ashik Azad, Pavithra P
12. **Posterior Polar Cataract** 74
    Lipi Mittal, Sandeep Choudhary, Mayank Sharma
13. **Pediatric Cataract** 79
    Rajat Kapoor, Bhavatharini M
14. **Mastering the Art of Capsulorhexis: A Transition to Forceps Continuous Curvilinear Capsulorhexis** 88
    Shivani P Pattnaik, Kumar Doctor
15. **Tips and Tricks in Phacoemulsification** 93
    Ankita Mulchandani
16. **Argentinian Flag Sign Management** 101
    Anuj Kodnani

17. 2.5-mm Blunt Tip Chopper to the Rescue **102**
Anuj Kodnani

18. CM-T Flex IOL and XNIT **103**
Madanagopalan VG, Nivean M

19. Decoding Secondary Glaucomas **104**
Rinal Pandit

20. Secondary Angle-closure Glaucomas **107**
Rinal Pandit

21. Insights into Intraocular Pressure and Glaucoma Dynamics **109**
Nitika Beri

22. Recent Advances in Medical Management **111**
Rinal Pandit

23. Disorders of Vitreous **113**
Kushal S Delhiwala

24. Retinopathy of Prematurity **118**
Puja Maitra, Aditya Maitray, Manan Balvant Mistry

25. Diabetic Eye Disease **125**
Aman Khanna, Gaurav M Kohli, Tanya Jain, Pratik Shenoy, Pallavi Goel

26. Current Approaches in the Diagnosis and Management of Sub-internal Limiting Membrane Hemorrhage **144**
Dhaivat Shah

27. Optical Coherence Tomography Biomarkers in Diabetic Macular Edema **149**
Isha Acharya, Himanshu Prakash

28. Ocular Ultrasonography in Retinal Disorders **160**
Mousumi Banerjee

29. Vitrectomy **168**
N Shastikaa, Prasanna Venkatesh Ramesh, Shruthy Vaishali Ramesh, Anugraha Balamurugan, Ashik Azad, Navaneeth Krishna MP, Ajanya K Aradhya

30. Vogt–Koyanagi–Harada Disease **171**
Sameeksha Agrawal, Ankit Agrawal

31. Optic Neuritis **174**
Sameer Chaudhary, Deepika Beeraka

32. Thyroid Eye Disease **184**
Ankita Aishwarya Agrawal, Rachna Agrawal, Ankit Agrawal

33. Laser-induced Ocular Injuries **188**
Kshitij Raizada

Index *193*

Video Contents

Chapter 1: Anatomy of Limbus

Video 1: Anatomy of Limbus.

Chapter 3: Physiology of Eye and Vision

Video 1: Video demonstrating the parts of the eye.

Video 2: Video explaining the mechanism for aqueous humor formation.

Video 3: Video explaining the aqueous humor outflow. The aqueous humor is produced from nonpigmented epithelium of ciliary body and pass through posterior chamber into anterior chamber via pupil. With aqueous convection current, the aqueous humor produced pass to the angle and involves in two drainage pathways. Conventional trabecular pathway, where via trabecular meshwork pass through Schlemm's canal and drains to venous circulation. Uveoscleral outflow passes along the surface of iris and uveal tissue to pass through suprachoroidal space and drains to venous circulation.

Video 4: Self-explanatory video explaining the major factors which play a crucial role in maintaining corneal transparency and metabolism. The individual layers are explained in detail.

Video 5: Self-explanatory video of the lens metabolism and the various pathways which provides nutrient support to the lens.

Video 6: Video explaining the break of rhodopsin with light into opsin and retinal which then joins to form rhodopsin after passing through a cyclical change.

Video 7: Video demonstration of the three components of binocular single vision. Simultaneous binocular perception is represented by two dissimilar objects (cage in one eye and bird in one eye) seen by individual eyes which appear as single image (bird inside the cage). Fusion is represented by ability of human eyes to fuse two similar images (one image with hat and other image with shoe) with minor difference to form a single composite image (image with both hat and shoe). Stereopsis is the ability to obtain depth by superimposition of two pictures of same objects taken at slightly different angle (bucket handle orientation).



Video 8: Videographic representation of visual pathway starting from the light rays falling in retina till visual cortex. Retinal fibers are divided into nasal (decussate to opposite side) and temporal (passes in same side) go through optic nerve to reach optic chiasma and optic tract. From lateral geniculate body via optic radiations, the fibers will reach the occipital lobe. The various levels of damage in visual pathway are represented in the video. Damage of same side optic nerve results in total blindness of that side, lesion at optic chiasma leads to bitemporal hemianopia, with homonymous hemianopia in lesion posterior to optic chiasma.



Video 9: Videographic representation of the pupillary pathway where in light falls on the photoreceptors, the impulse passes through optic nerve, optic tract to reach pretectal nucleus from there both sides of Edinger–Westphal nucleus gets stimulated which via ciliary ganglion tends to cause pupillary constriction in both eyes resulting in both direct and consensual light reflex.



Chapter 4: Refraction Part 1

Video 1: Refraction Part 1.



Chapter 5: Refraction Part 2

Video 1: Refraction Part 2.



Chapter 6: Basic Concepts Related to Strabismus

Video 1: Basic concepts related to strabismus.



Chapter 7: Evaluation of a Case of Squint

Video 1: Evaluation of a case of squint.



Chapter 8: Strabismus

Video 1: Demonstration of extraocular movements.



Video 2: Cover test [performed for tropia (manifest squint). On occluding the normal eye of patient, the squinting eye takes up fixation].



Video 3: Uncover test (performed for latent squint. On uncovering, the eye under cover moves to take up fixation).



Video 4: Krimsky test and prism bar cover test. The apex of prism is kept toward the direction of deviation. The test is done for both distance and near fixation. Cover test is performed gradually with increasing strength of prism till no refixation movement is obtained.



Video 5: Measurement of near point convergence and near point accommodation using RAF rule. (measured with the help of RAF rule) Near point of convergence is the nearest point at which the target appears double. Normal NPC is 8–10 cm. Near point of accommodation is the nearest point at which target appears blurred.



Video 6: Synaptophore.



Video 7: Four prism base-out test for microtropia.

Video 8: V-pattern.

Video 9: Diplopia charting and Hess chart.

Video 10: Forced duction test.

Video 11: Active force generation test.

Video 12: Superior oblique palsy and head tilt test.

Video 13: Torsion evaluation.

Video 14: Sixth nerve palsy.

Video 15: Duane's retraction syndrome.

Video 16: Brown's syndrome.

Chapter 10: Corneal Lacerations and Management Protocols

Video 1: Siedel test-graft dehiscence.

Video 2: Subtenon block.

Video 3: Partial corneal tear with foreign body removal.

Chapter 13: Pediatric Cataract

Video 1: Demonstrating steps of pediatric lens aspiration, IOL implantation, primary posterior capsulotomy, and anterior vitrectomy.

Chapter 14: Mastering the Art of Capsulorhexis: A Transition to Forceps Continuous Curvilinear Capsulorhexis

Video 1: Creating a perfect continuous curvilinear capsulorhexis (CCC) with cystitome.

Video 2: Forceps continuous curvilinear capsulorhexis (CCC).

Video 3: Physics of continuous curvilinear capsulorhexis (CCC).

Video 4: How to enter the eye like a Pro?

Video 5: Grasping correctly.

Video 6: *Hybrid approach:* Needle initiation, forceps completion of continuous curvilinear capsulorhexis (CCC).

Chapter 15: Tips and Tricks in Phacoemulsification

Video 1: How to make a cystitome.

Video 2: Tips and tricks in phacoemulsification.

Chapter 16: Argentinian Flag Sign Management

Video 1: Argentinian flag sign management.

Chapter 17: 2.5-mm Blunt Tip Chopper to the Rescue

Video 1: 2.5-mm blunt tip chopper to the rescue.

Chapter 18: CM-T Flex IOL and XNIT

Video 1: CM-T Flex IOL.

Video 2: XNIT.

Chapter 23: Disorders of Vitreous

Video 1: Mittendorf dot with cloquet canal remnant.

Video 2: Vitreous degeneration.

Video 3: Vitreous hemorrhage.

Video 4: Intravitreal triamcinolone acetonide (IVTA).

Video 5: Vitritis.

Chapter 28: Ocular Ultrasonography in Retinal Disorders

Video 1: Retinal detachment.

Video 2: Giant retinal tear.

Video 3: Vitreous hemorrhage.

Video 4: Tractional retinal detachment.

Chapter 31: Optic Neuritis

Video 1: Animation showing a case scenario of a typical case of optic neuritis—its presentation, clinical features, and management.

Chapter 33: Laser-induced Ocular Injuries

Video 1: Large retinal hole following injury by Q-Switched Nd:YAG laser.

CHAPTER 28

Ocular Ultrasonography in Retinal Disorders

Mousumi Banerjee

INTRODUCTION

Ocular ultrasonography (USG) is a painless, noninvasive, safe, rapid, cost-effective, rapidly evolving real-time diagnostic tool for precise diagnosis of ocular lesion. Henry Mundt and William Hughes described the use of one-dimensional acoustic display in which echoes are represented as vertical spikes from a baseline (A-scan) in 1956 for the first time. Baum and Greenwood (1958) codeveloped two-dimensional B scan USG in 1958 with the help of a water bath as a coupling agent between globe and probe.[1] Bronston and workers introduced the first handheld contact B scan without the need for a water bath.[2] Standardization of A-scan combined with contact B scan led to the development of Standardized Echography by Ossoinig, leading to highly accurate detection and differentiation of oculo-orbital disorders.[3]

PRINCIPLE OF ULTRASOUND (FLOWCHART 1)

With increase in frequency of USG, wavelength of USG decreases which determines the depth of tissue penetration and resolution. Wavelength of USG is directly proportional to the depth of tissue penetration and inversely proportional to resolution.

Thus, ocular USGs are of higher frequency (10 MHz) as it needs less tissue penetration and higher resolution. Recently, a high-frequency 20 MHz contact probe has been introduced.[4] 20 MHz USG has superior resolution and can detect details at the posterior pole and in the orbit, orbital fat imaging and differentiating lesions in the orbit, extraocular muscles, and optic nerve. However, 10 MHz has superior sensitivity and a closer focal distance, thus, better appreciates low intensity weakly reflective particles like detection of posterior

Flowchart 1: The principle of ultrasound imaging.

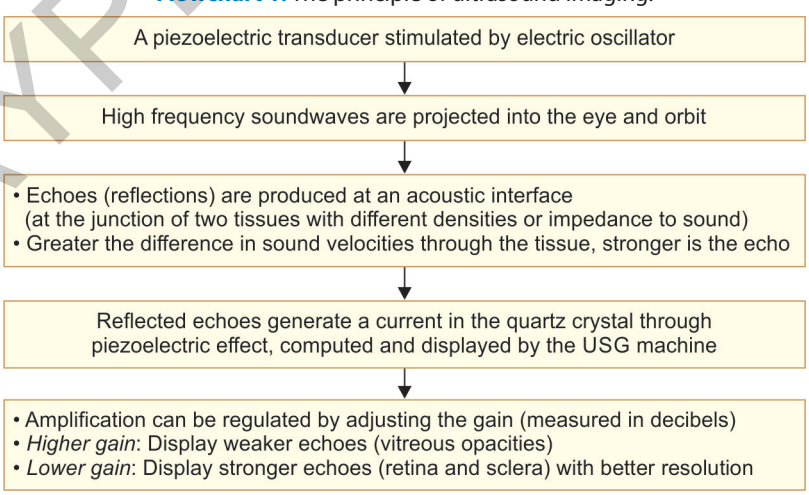

JAYPEE BROTHERS

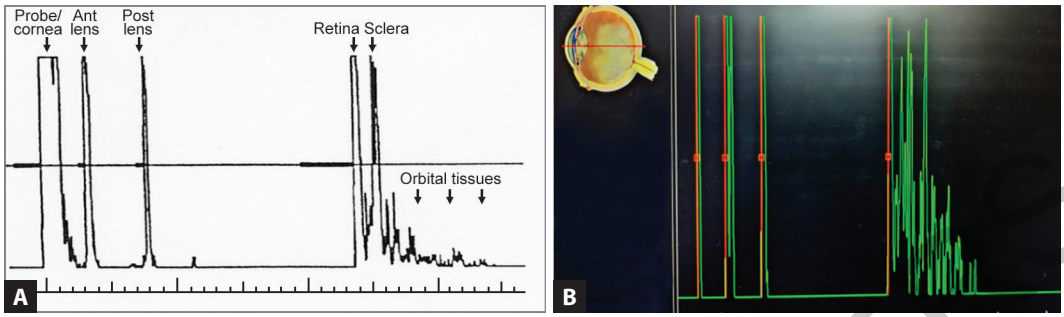

Figs. 1A and B: First spike: Probe interface meets the cornea. Second and third spike: Anterior and posterior lens surface respectively followed by flat line representing vitreous. Fourth and fifth spike: Retinal and sclera spike respectively followed by progressively reducing spikes representing orbital fat.

vitreous detachment (PVD), vitreous hemorrhage, and subtle vitreous change such as inflammatory cells, etc.[4]

TYPES OF OCULAR ULTRASONOGRAPHY SCANS

There are two main types of display modes currently used in ophthalmic practice: (1) Amplitude (A-scan) and (2) brightness (B-scan). C-scan has been described in literature to demonstrate the normal orbital fat and optic nerve, together with selected pathological conditions in the orbit. The C-scan facility permits imaging of the orbital contents in the coronal plane.[5]

A-Scan

A single sound beam is sent from the transducer and the returning echoes are converted into a series of spikes with height proportional to the strength of the echo. An ideal A-scan comprises five spikes followed by series of progressively reducing spike heights representing orbital fat **(Figs. 1A and B)**.

A-scan probe is a small pencil-sized probe with no mark emitting parallel and nonfocused ultrasound beam **(Fig. 2)**. The probe can be directly placed over the globe after instillation of topical anesthetics.



Fig. 2: Standardized A-scan probe of 8 MHz emitting parallel sound beam of 5 mm width at the highest decibel gain and 0.5 mm at the lowest.

B-Scan

Two-dimensional B scan can be performed either directly on the surface of the anesthetized eye using a protective cap or through the eyelids using a coupling jelly (transpalpebral approach). A gray-scale image representing the reflectivity of the structures is displayed on the screen. Low reflectivity is denoted by black whereas high reflectivity is depicted by white. Gain of the machine needs to be increased while visualizing low-reflective structures. Earlier USG machines used to have low gain, whereas recent machines have a maximum gain of 100 dB.

JAYPEE BROTHERS



Fig. 3: B-scan probe with a mark (red arrow) for beam orientation.

Orientation of the B-scan probe is of utmost importance for performing a B scan. B-scan probe is thicker with a mark at the top indicating beam orientation so that the area toward which the mark is directed appears at the top of the echogram on display screen **(Fig. 3)**. It emits focused sound beams at a frequency of 10 MHz. *Recent machines emit focused sound beams at a frequency of 12 MHz and 20 MHz.*

Based on the axis of the globe, which is being evaluated, three scan descriptions are used—(1) axial scan, (2) transverse scan, and (3) longitudinal scan **(Table 1)**.

SPECIAL EXAMINATION TECHNIQUES

There are three special examination techniques used together to derive an echographic diagnosis.

1. *Topographic echography:* Performed using B-scan probe. It helps in documenting shape, extent, location, and dimension of the mass lesion.
2. *Kinetic echography:* Determines the mobility and vascularity of the lesion. Example: Posterior vitreous detachment (PVD) has moderate—marked after movements, retinal detachment (RD) has moderate—none after movements based on the duration of detachment, while choroidal detachment (CD) has mild—none after movements.
3. *Quantitative echography:* Performed using A-scan probe. It consists of reflectivity, internal composition, and sound absorption.

INDICATIONS FOR OCULAR SONOGRAPHY

- Evaluation of details of intraocular structures obscured by opacities, e.g., corneal opacity, hyphema, dense cataract, vitreous hemorrhage, and retinoblastoma.
- Differentiation of solid and cystic masses
- Biometry (determination of axial length of the eyeball)
- Documentation of posteriorly dislocated crystalline lens, intraocular lens, intraocular foreign body, and ocular cysticercosis
- Choroidal lesions (melanoma and hemangioma), metastasis, macular lesions (e.g., osteoma by characteristic calcification)
- Detection of T sign in posterior scleritis
- Differentiating RD from PVD.
- Optic disc cupping, increased optic nerve sheath diameter in papilledema, calcification at optic nerve head in optic disc drusen.

DESCRIPTION OF OCULAR SONOGRAPHY IN VARIOUS VITREORETINAL CONDITIONS

Retinal Detachment (Videos 1 and 4)

Retinal detachment has moderate-to-high reflectivity in view of the higher thickness and multiple layers of neurosensory retina and is tethered posteriorly to both margins of optic disc and anteriorly to ora serrata with limited after movements which sometimes appear like whip-lash movement **(Figs. 4A and B)**.

JAYPEE BROTHERS

TABLE 1: Ultrasound biomicroscopy (UBM) scan orientations: Axial scan, transverse scan, and longitudinal scan.

Axial scan		
	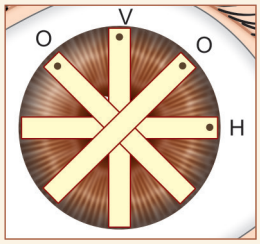	
The patient fixates in the primary gaze and the probe is placed on the globe and directed axially.	Depending on the clock hour location of the mark, three sections obtained: (1) Axial–horizontal, (2) axial–vertical, and (3) axial–oblique.	Demonstrates optic nerve head and posterior pole.
Transverse scan		
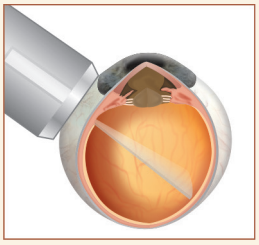	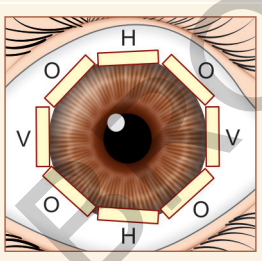	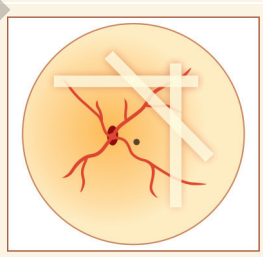
The mark on the probe is kept parallel to the limbus.	Depending on the clock hour location of the mark, three sections obtained: (1) Horizontal-transverse, (2) vertical-transverse, and (3) oblique-transverse.	Optic nerve head is not visualized. It depicts the lateral extent of a lesion.
Longitudinal scan		
	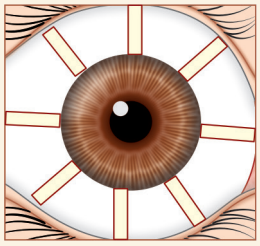	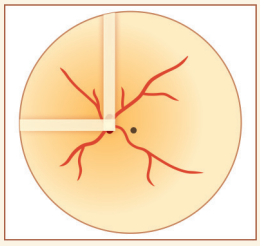
The mark on the probe is kept perpendicular to the limbus.	Depending on the clock hour location of the mark, three sections obtained: (1) Horizontal-longitudinal, (2) vertical-longitudinal, and (3) oblique-longitudinal.	Optic nerve head is visualized at the bottom of the scan. Demonstrates the antero-posterior extent of the lesion.

JAYPEE BROTHERS

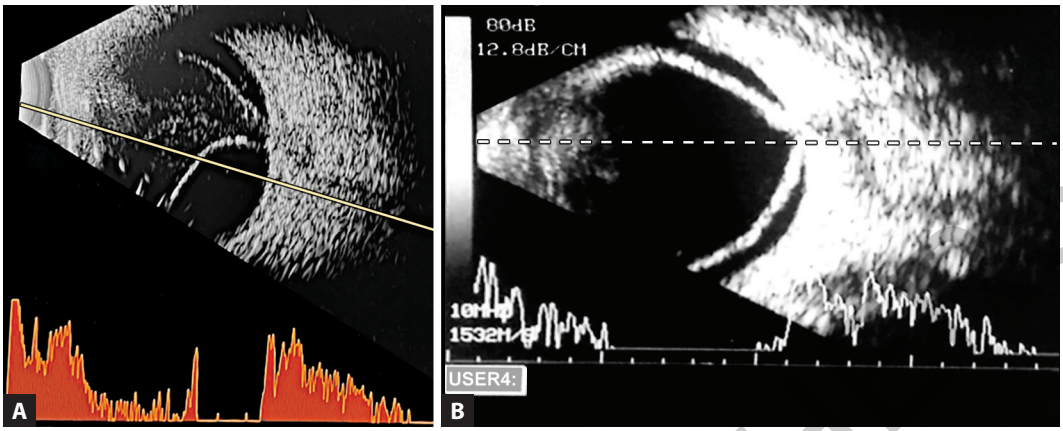

Figs. 4A and B: Ultrasound biomicroscopy (UBM) images showing retinal detachment.

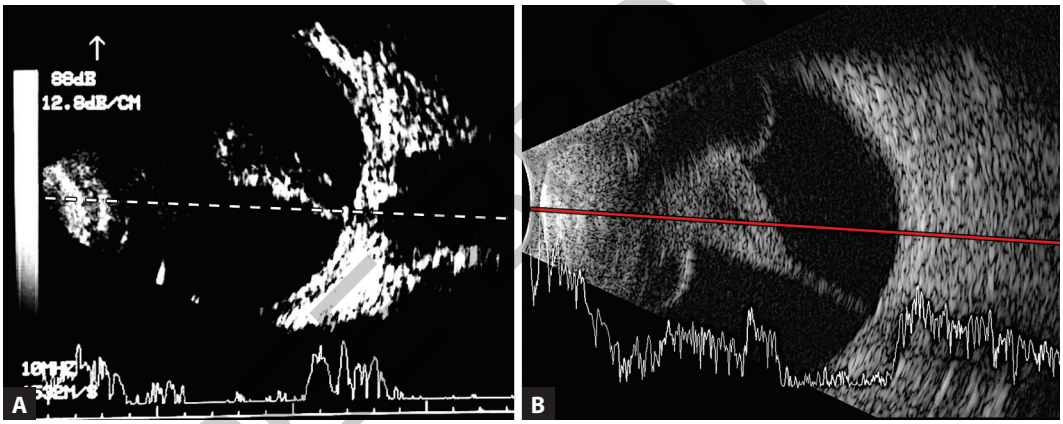

Figs. 5A and B: Ultrasound biomicroscopy (UBM) images of closed funnel retinal detachment.

Closed Funnel Retinal Detachment

Thick membrane is attached on both sides of the optic nerve with no after movements and a closed funnel configuration is noted **(Figs. 5A and B)**.

Giant Retinal Tear (Video 2)

A thick membrane is attached to the optic nerve with curled-up posterior flap of giant retinal tear rolled inward. A-scan depicts high amplitude spike corresponding to the rolled-up edge of the giant retinal tear **(Fig. 6)**.

Vitreous Hemorrhage with Posterior Vitreous Detachment (Video 3)

B-scan depicts bright dot-like echoes in the vitreous cavity corresponding to low-medium reflectivity spikes along the A-scan vector. A thin membrane with pinpoint attachment to the optic disc is noted having low-to-moderate reflectivity and good after movements. Dot-like echoes are also noted posterior to the membrane (subhyaloid hemorrhage) **(Fig. 7)**.

JAYPEE BROTHERS

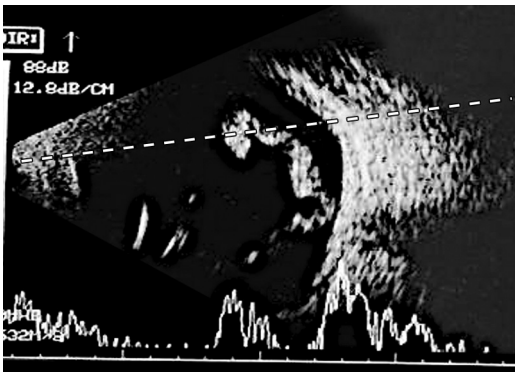

Fig. 6: Ultrasound biomicroscopy (UBM) image of a giant retinal tear, showing a thick membrane attached to the optic nerve with a curled posterior flap.

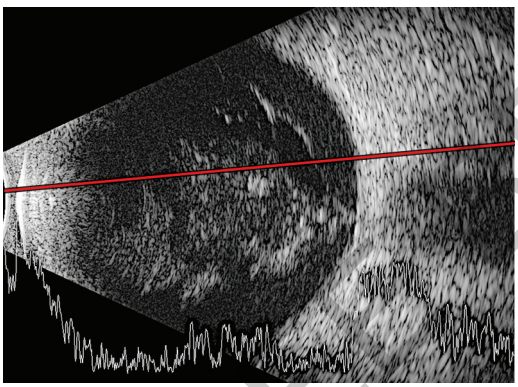

Fig. 7: Ultrasound biomicroscopy (UBM) image illustrating vitreous hemorrhage with posterior vitreous detachment.

Endophthalmitis

Multiple dot-like and pseudomembrane like echoes noted in the vitreous cavity corresponding to mild–moderate amplitude spikes on A-scan suggestive of endophthalmitis **(Fig. 8)**.

Choroidal Detachment

Left image ***(Fig. 9A)****:* A dome-shaped elevation with limited after-movement with dot-like echoes and apposed membranes

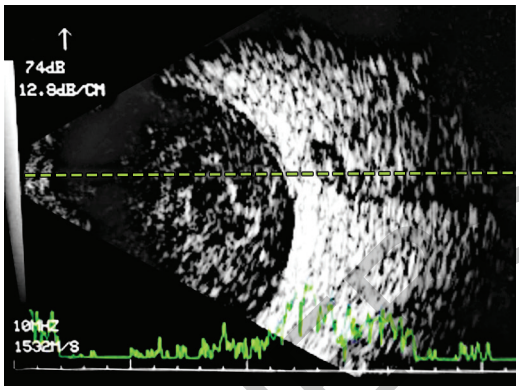

Fig. 8: Ultrasound biomicroscopy (UBM) image of endophthalmitis, showing dot-like echoes and pseudomembrane-like structures in the vitreous cavity, corresponding to mild–moderate amplitude spikes on the A-scan.

on USG suggestive of kissing choroidals in hemorrhagic CD.

Right image ***(Fig. 9B)****:* A dome-shaped echolucent elevation (serous CD) with no retinal apposition seen after drainage of the kissing choroidals.

Fundal Coloboma

Excavation of the ocular coats (white arrow) with a moderate amplitude spike corresponding with the detached intercalary membrane (red arrowhead) overlying the colobomatous area **(Fig. 10)**.

Optic Nerve Head Drusen

Anechoic on B-scan with localized hyperechoic focus at the optic nerve head corresponding to high reflectivity on A-scan vector **(Fig. 11)**.

Optic Nerve Head Cupping

A depression or bean pot-like configuration is noted at optic nerve head (red arrow) suggestive of glaucomatous optic nerve head cupping **(Fig. 12)**.

JAYPEE BROTHERS

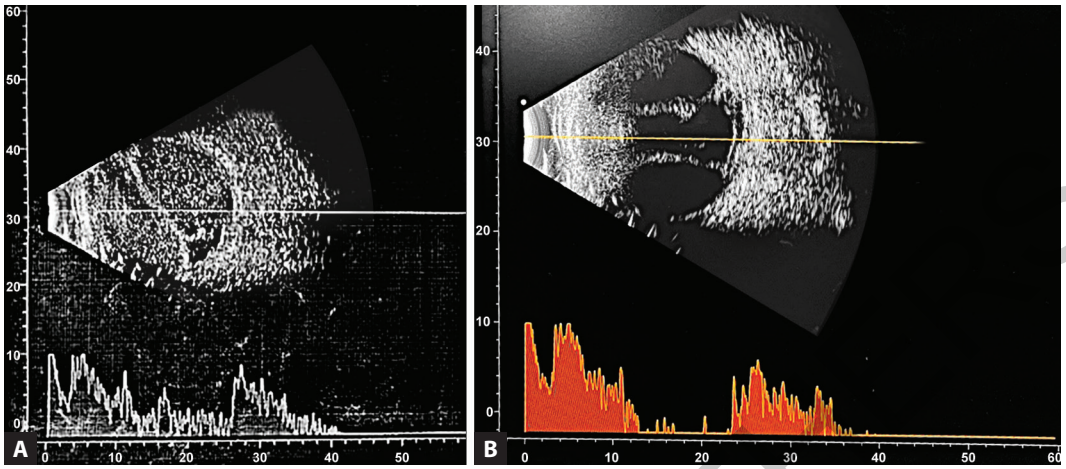

Figs. 9A and B: Ultrasound biomicroscopy (UBM) image of (A) Choroidal detachment—a dome-shaped elevation with limited after-movement and dot-like echoes, along with apposed membranes, indicating hemorrhagic choroidal detachment and kissing choroidals. (B) Serous choroidal detachment—a dome-shaped echolucent elevation with no retinal apposition seen after drainage of the kissing choroidals.

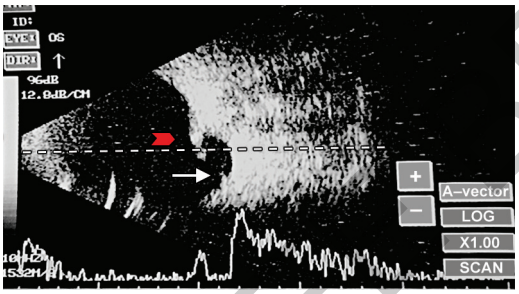

Fig. 10: Ultrasound biomicroscopy (UBM) image showing fundal coloboma, depicting ocular coat excavation (white arrow) and a moderate amplitude spike corresponding to the detached intercalary membrane (red arrowhead) overlying the colobomatous area.

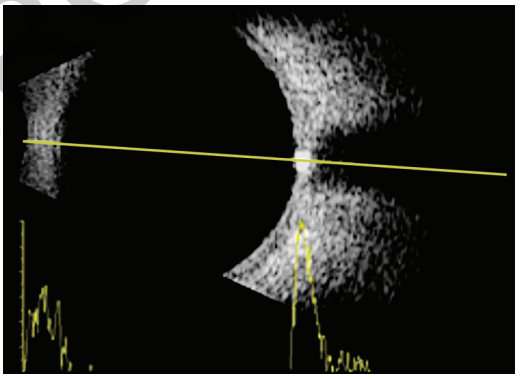

Fig. 11: Ultrasound biomicroscopy (UBM) image showing optic nerve head drusen, which appears anechoic on B-scan with a localized hyperechoic focus at the optic nerve head, corresponding to high reflectivity on A-scan.

Asteroid Hyalosis

Medium-to-high amplitude spikes noted in the vitreous cavity, localized to the core of the vitreous body with clear lucid interval noted in retrovitreal/preretinal space (red arrow) **(Fig. 13)**.

T-sign in Posterior Scleritis

A hypoechoic space in the subtenon space and around the optic nerve head giving the appearance of the letter "T". It indicates accumulation of fluid in the subtenon space **(Fig. 14)**.

JAYPEE BROTHERS

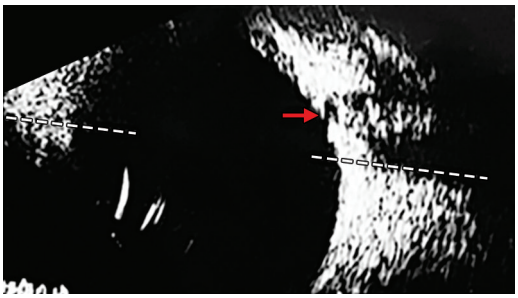

Fig. 12: Ultrasound biomicroscopy (UBM) image of optic nerve head cupping, demonstrating a depression or bean pot-like configuration at the optic nerve head (red arrow), suggestive of glaucomatous cupping.

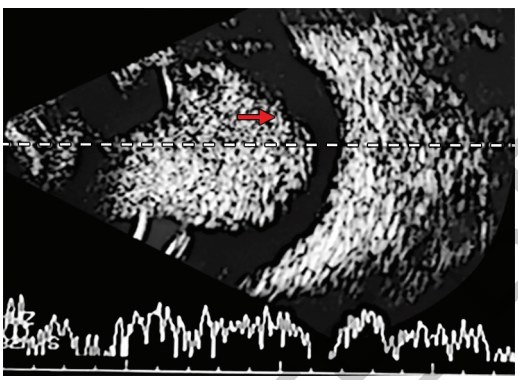

Fig. 13: Ultrasound biomicroscopy (UBM) image of asteroid hyalosis, showing medium-to-high amplitude spikes in the vitreous cavity, localized to the core of the vitreous body with a clear lucid interval in the retrovitreal/preretinal space (red arrow).

VIDEO LEGENDS

Video 1: Retinal detachment.
Video 2 Giant retinal tear.
Video 3: Vitreous hemorrhage.
Video 4: Tractional retinal detachment.

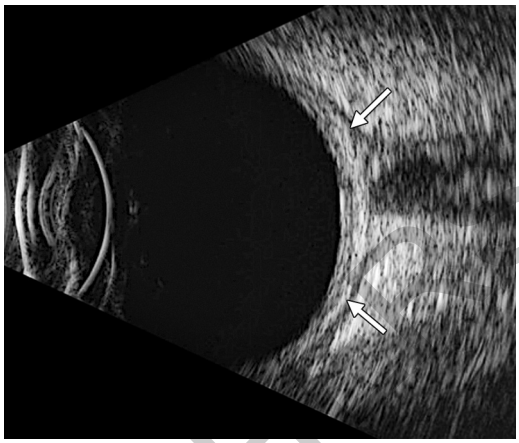

Fig. 14: Ultrasound biomicroscopy (UBM) image of T-sign in posterior scleritis, showing a hypoechoic space around the optic nerve head and in the subtenon space, forming the appearance of the letter "T", indicating fluid accumulation in the subtenon space.

REFERENCES

1. Baun G, Greenwood I. The application of ultrasonic locating techniques to ophthalmology. Arch ophthalmol. 1958; 60(2):263-79.
2. Ossoinig KC, Cennamo G, Byrne SF. Echographic differential diagnosis of optic nerve lesions. In: Thijssen JM, Verbeek AM (Eds). Ultrasonography in Ophthalmology, Dordrecht/Boston/Lancaster: Dr. W. Junk Publishers; 1981. p. 327.
3. Ossoinig KC. Standardized echography: Basic principles, clinical applications, and results. Int Ophthalmol Clin. 1979;19(1):127-210.
4. Hewick SA, Fairhead AC, Culy JC, Atta HR. A comparison of 10 MHz and 20 MHz ultrasound probes in imaging the eye and orbit. Br J Ophthalmol. 2004;88(4):551-5.
5. Restori M, Wright JE. C-scan ultrasonography in orbital diagnosis. Br J Ophthalmol. 1977; 61(12):735-40.

JAYPEE BROTHERS

for detailed information on ophthalmology books, visit our website www.jaypeebrothers.com, for detailed information on ophthalmology books, visit our website www.jaypeebrother

Oculus Res Gestae

A Neophyte's Animative & Videographic Compendium



Prasanna Venkatesh Ramesh MS (Gold Medal) DNB MNAMS FICO (Glaucoma) FAICO (Glaucoma) FAICO (Cataract/Phaco) (Gold Medal), Fellow in Glaucoma Surgery and Research (Dr Sathyan's) is DNB Coordinator, Medical Officer, Mahathma Eye Hospital Private Limited, Tiruchirappalli, Tamil Nadu, India. A distinguished Glaucoma Specialist, he is dedicated to advancing ophthalmic education and surgical techniques, particularly in minimally invasive glaucoma surgery (MIGS). As an Educator, Researcher, and Editor, he actively shapes ophthalmic education. His expertise in augmented reality and 3D imaging merges clinical skills with technology.

Through Oculus Res Gestae, Dr Prasanna combines clinical experience, research acumen, and storytelling to explore ophthalmology. His work reflects a commitment to refining surgical techniques and inspiring the next generation of eye-care professionals. By integrating innovation and education, he bridges the gap between theory and practice, creating a new reality in ophthalmic learning.



Shruthy Vaishali Ramesh MS (Gold Medal) DNB MNAMS FICO (Cataract/Phaco) FAICO (Cataract/Phaco) FRCOphth Fellowship in Comprehensive Ophthalmology and Phacoemulsification is an Ophthalmic Specialty Doctor at Blackpool Victoria Hospital, England, UK. An accomplished Ophthalmologist, she specializes in cataract and comprehensive ophthalmology, blending surgical precision with research and education. Committed to innovation and evidence-based practice, she actively contributes to mentoring, academic writing, and collaborative research, furthering advancements in surgical innovation and patient care while shaping ophthalmic education and practice.

Together, these visionary Editors have curated Oculus Res Gestae, a dynamic videographic and animative resource, essential for young ophthalmologists.

Printed in India

Available at all medical bookstores or buy online at www.ejaypee.com

JAYPEE BROTHERS
Medical Publishers (P) Ltd.
EMCA House, 23/23-B, Ansari Road,
Daryaganj, New Delhi - 110 002, INDIA
www.jaypeebrothers.com

Join us on facebook.com/JaypeeMedicalPublishers
Follow us on instagram.com/JaypeeMedicalPublishers

Shelving Recommendation
OPHTHALMOLOGY

ISBN 978-93-6616-348-2