site www.ejaypee.com, for detailed information on dental books, visit our website www.ejaypee.com, for detailed information on dental books, visit our website www.ejaypee.com,

Thoroughly revised multiple choice questions and fill in the blanks according to the latest syllabus of DCI

Includes 2024 Papers

Mastering the BDS IInd Year

Last 20 Years Solved Questions

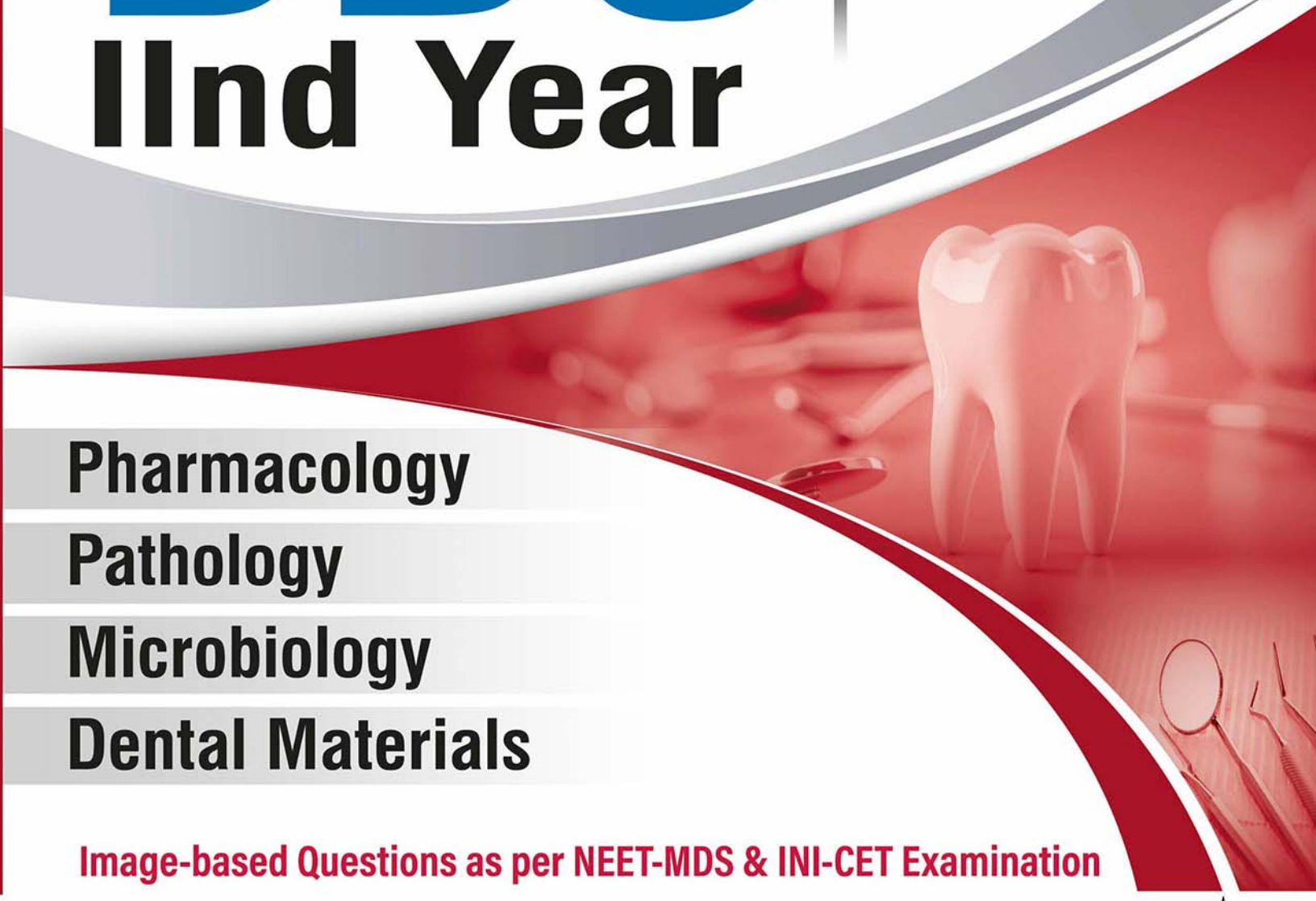

Pharmacology
Pathology
Microbiology
Dental Materials

Image-based Questions as per NEET-MDS & INI-CET Examination

Hemant Gupta

12th Edition

JAYPEE

CONTENTS

SECTION 1: PHARMACOLOGY

General Pharmacology

1. Introduction, Routes of Drug Administration 3
2. Pharmacokinetics 8
3. Pharmacodynamics 14
4. Aspects of Pharmacotherapy 17
5. Drug Dosage and Pharmacotherapeutics 20
6. Adverse Drug Effects 22

Autonomic Nervous System

7. Cholinergic System and Drugs 24
8. Anticholinergic System and Drugs 26
9. Adrenergic System and Drugs 27
10. Antiadrenergic Drugs and Drugs for Glaucoma 30

Autacoids and Related Drugs

11. Histamine and Antihistaminics 32
12. Nonsteroidal Anti-inflammatory Drugs and Antipyretic-analgesics 34
13. Antirheumatoid and Antigout Drugs 44

The Respiratory System

14. Drugs Used in Respiratory System 44

Hormones

15. Corticosteroids 48
16. Thyroid 50
17. Insulin and Oral Hypoglycemic Drugs 50
18. Sex Hormones 61
19. Drugs Affecting Calcium Balance 62

Drugs of Peripheral Nervous System

20. Skeletal Muscle Relaxants 64
21. Local Anesthetics 65

Central Nervous System

22. General Anesthetics 70
23. Sedative and Hypnotics 73
24. Antiepileptic Drugs 76
25. Antiparkinsonian Drugs 78
26. Opioid Analgesics and Antagonists 79
27. Ethyl and Methyl Alcohols 83
28. Antianxiety and Antidepressant Drugs 83
29. Drugs Used in Mental Illness: Antipsychotic and Antimanic Drugs 84

Cardiovascular System

30. Drugs Affecting Renin-angiotensin System and Plasmakinins 85
31. Cardiac Glycosides and Drugs for Heart Failure 87
32. Antianginal and Other Anti-ischemic Drugs 89
33. Antihypertensive Drugs 93
34. Shock 103
35. Drugs Acting on Kidney 105

Drugs Affecting Blood and Blood Formation

36. Hematinics 109
37. Coagulants and Anticoagulants 111

Gastrointestinal Drugs

38. Drugs for Peptic Ulcer 117
39. Emetics and Antiemetics 123
40. Drugs for Constipation and Diarrhea 126

Antimicrobial Drugs

41. Antimicrobial Drugs: General Considerations 128
42. Sulfonamides, Cotrimoxazole and Quinolones 131
43. Beta-lactam Antibiotics 134
44. Tetracyclines and Chloramphenicol (Broad Spectrum Antibiotics) 142
45. Aminoglycoside and Macrolide Antibiotics, Lincosamide, Glycopeptide and Other Antibacterial, Antibiotics; Urinary Antiseptics 146
46. Antitubercular Drugs 150
47. Antiamoebic Drugs 155
48. Antileprotic Drugs 158
49. Antifungal Drugs 159
50. Antiviral Drugs 161
51. Antihelminthic Drugs 163
52. Antimalarial Drugs 166
53. Drugs Acting on Skin and Mucous Membranes 169

Chemotherapy of Neoplastic Diseases

54. Anticancer Drugs 170

Miscellaneous Drugs

55. Chelating Agents 171
56. Vitamins 172
57. Antiseptics and Disinfectants 174
58. Drugs in Dentistry 176
59. Treatment of Different Diseases 192

Multiple Choice Questions as per DCI and Examination Papers of Various Universities *197*

Fill in the Blanks *222*

Name Two Most Suitable Drugs for Following *226*

Viva-Voce Questions for Practical Examination *228*

Additional Information *232*

Classification of Various Pharmacological Drugs *245*

One Liners *253*

SECTION 2: PATHOLOGY

1. Cell Injury and Cellular Adaptations 261
2. Immunopathology Including Amyloidosis 280
3. Hemodynamic Changes 294
4. Inflammation and Healing 311

5. Neoplasm 343
6. Hematopoietic System 363
7. The Oral Cavity and Salivary Glands 377
8. The Gastrointestinal System 389
9. Musculoskeletal System 390
10. Diabetes Mellitus 393
11. Hypertension 400
12. Genetic and Pediatric Diseases 400
13. Environmental and Nutritional Diseases 401
14. Hemostatic System, Bleeding Disorders and Transfusion Biology 406
15. Infectious and Parasitic Disease 408
16. The Lymphoid System 408
17. Diagnostic Cytopathology 409

Multiple Choice Questions as per DCI and Examination Papers of Various Universities *413*
Fill in the Blanks *427*
Viva-Voce Questions for Practical Examination *428*
Very Short Questions *433*
Additional Information *434*
One Liners *441*

SECTION 3: MICROBIOLOGY

1. Historical Introduction 447
2. Microscopy and Morphology of Bacteria 447
3. Culture Media 454
4. Culture Methods 458
5. Sterilization and Disinfection 460
6. Identification of Bacteria 473
7. Bacterial Genetics 474
8. Infection 474
9. Immunology 476
   i. Immunology 476
   ii. Antibodies or Immunoglobulins 480
   iii. Antigen-antibody Reactions 481
   iv. Structure and Functions of Immune System 485
   v. The Immune Response 488
   vi. Hypersensitivity 491
   vii. Autoimmunity 495
   viii. Transplantation and Tumor Immunity 495
   ix. Immunization, Immunizing Agents, Immunoprophylaxis and Immunotherapy 496
10. Bacteriology 497
   i. *Staphylococcus* 497
   ii. *Streptococcus* 501
   iii. *Pneumococcus* 506
   iv. *Neisseria* 507
   v. *Corynebacterium* 508
   vi. *Mycobacteria* 512
   vii. *Clostridium* 514
   viii. Nonsporing Anaerobes 519
   ix. Enterobacteriaceae I: *E. Coli, Klebsiella* and *Proteus* 520
   x. Enterobacteriaceae II: *Salmonella* 521
   xi. *Vibrio* 522
   Xii. *Actinomyces* 524
   Xiii. *Spirochetes* 525
11. Virology 528
   i. General Properties of Viruses 528
   ii. Laboratory Diagnosis of Viral Diseases 529
   iii. Bacteriophage 530
   iv. Herpes Virus 531
   v. Paramyxoviruses 532
   vi. Hepatitis Virus 533
   vii. Oncogenic Virus 539
   viii. Human Immunodeficiency Virus (HIV) 540
   ix. Corona Virus Infections Including Covid-19 547
   x. Miscellaneous 548
12. Mycology 551
13. Parasitology 560
   i. General Introduction: Parasitology 560
   ii. Entamoeba Histolytica 561
   iii. Malarial Parasite 563
   iv. Nematodes 569
   v. Cestodes—Tapeworms 573
14. Clinical Microbiology 574
   I. Normal Microbial Flora of Human Body 574
   ii. Sore Throat 575
   iii. Meningitis 576
   iv. Viral Encephalitis and Encephalopathy 578
   v. Diarrheal Diseases 579
   vi. Septicemia, Bacteremia and Toxemia 581
   vii. Pyrexia of Unknown Origin 582
   viii. Sexually Transmitted Diseases 583
   ix. Hospital Acquired Infections 584
   x. Antimicrobial Sensitivity Testing 586
   xi. Biomedical Waste Management 588
   xii. Dental Microbiology 590
15. Various Important Laboratory Tests 592
16. Miscellaneous 594

Multiple Choice Questions as per DCI and Examination Papers of Various Universities *595*
Fill in the Blanks *609*
Viva-Voce Questions for Practical Examination *610*
Very Short Questions *613*
Additional Information *614*
One Liners *630*

SECTION 4: DENTAL MATERIALS

1. Overview of Dentistry and Dental Materials 637
2. Structure and Properties of Dental Materials 639
3. Structure and Properties of Metals and Alloys 647
4. Biological Properties of Dental Materials 648
5. Tarnish and Corrosion 649
6. Base, Liner and Varnish 652
7. Dental Cements 654
8. Dental Amalgam 672
9. Direct Filling Gold 680
10. Resin-based Composites and Bonding Agents 686
11. Pit and Fissure Sealants 701
12. Endodontic Materials 702
13. Impression Materials 703
14. Model, Cast and Die Materials 721
15. Gypsum Products 723
16. Waxes in Dentistry 732
17. Dental Investments and Refractory Materials 738
18. Dental Casting and Metal Fabrication Procedures 746
19. Abrasion and Polishing 756

20. Metal Joining and Dental Lasers 761
21. Dental Casting Alloys 765
22. Dental Implant Materials 769
23. Wrought Metals and Alloys 776
24. Dental Ceramics 778
25. Denture Resins and Polymers 789
26. Maxillofacial Prosthetic Materials 803

Multiple Choice Questions as per DCI and Examination Papers of Various Universities *805*
Fill in the Blanks *827*
Viva-Voce Questions for Practical Examination *829*
Additional Information *834*
One Liners *844*
Image-based Questions **851**

SECTION 2

Pathology

1. Cell Injury and Cellular Adaptations
2. Immunopathology Including Amyloidosis
3. Hemodynamic Changes
4. Inflammation and Healing
5. Neoplasm
6. Hematopoietic System
7. The Oral Cavity and Salivary Glands
8. The Gastrointestinal System
9. Musculoskeletal System
10. Diabetes Mellitus
11. Hypertension
12. Genetic and Pediatric Diseases
13. Environmental and Nutritional Diseases
14. Hemostatic System, Bleeding Disorders and Transfusion Biology
15. Infectious and Parasitic Disease
16. The Lymphoid System
17. Diagnostic Cytopathology

Multiple Choice Questions as per DCI and Examination Papers of Various Universities

Fill in the Blanks

Viva-Voce Questions for Practical Examination

Very Short Questions

Additional Information

One Liners

JAYPEE BROTHERS

JAYPEE BROTHERS

PATHOLOGY

1. CELL INJURY AND CELLULAR ADAPTATIONS

Q.1. Write a short note on dystrophic calcification.

(Mar 2008, 3 Marks) (Mar 2010, 5 Marks)

Ans. Dystrophic calcification is characterized by deposition of calcium salts in dead or degenerated tissues with normal calcium metabolism and normal serum calcium levels.

Pathogenesis

The process of dystrophic calcification involves two phases, i.e., initiation and propagation.

- *Initiation:* Following the cell injury (i.e., degeneration or necrosis), there is occurence of the membrane damage and also the release of membrane phospholipids. Phosphatases which are associated with phospholipids leads to the generation of phosphate ions. It is also known that there is excess of the uptake of calcium by the injured mitochondria in degeneration and necrosis. So, calcium and phosphate so generated from these mechanisms form precipitates of calcium phosphate.
- *Propagation:* It is the phase in which minerals deposited in the initiation phase are propagated to form mineral crystals.

Histology

- With hematoxylin and eosin stain, the calcium salts have a basophilic, amorphous granular, sometimes clumped appearance.
- At times heterotrophic bone formation may occur.
- Progressive acquisition of outer layers may create lamellated configurations, called psammoma bodies.

Examples

Calcification in Dead Tissue

- Caseous necrosis in tuberculosis is the most common site for dystrophic calcification.
- Liquefactive necrosis may get calcified.
- Fat necrosis in breast or pancreatitis result in deposition of calcium salts.
- Calcification in breast cancer.
- Infarcts may sometimes undergo dystrophic calcification.

Calcification in Degenerated Tissue

- Dense old scars, atheromas and stroma of tumors may undergo calcification.
- Calcinosis cutis is a condition in which there are irregular nodular deposition of calcium salts in the skin and subcutaneous tissue.
- Senile degenerative changes: Dystrophic calcification in costal cartilages, tracheal or bronchial cartilages and pineal gland in brain.

Q.2. Write a short note on metaplasia.

(Apr 2007, 5 Marks) (Dec 2007, 3 Marks)

Or

Write a short answer on metaplasia.

(Sep 2018, 3 Marks)

Ans. Metaplasia

Meta means transformation and plasia means growth. Metaplasia is defined as reversible change of one type of epithelial or mesenchymal adult cells to another type of adult epithelial or mesenchymal cells usually in response to abnormal stimulus.

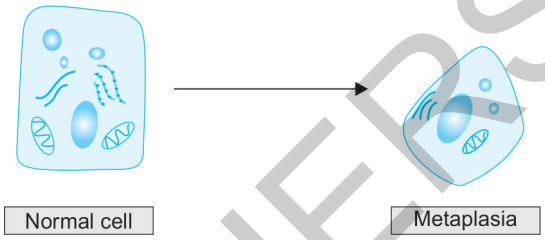

Fig. 1: Metaplasia.

Metaplasia is divided into two types

1. **Epithelial metaplasia:** This is more common type. The metaplastic change may be patchy or diffuse. Some common types of epithelial metaplasia are:
   - *Squamous metaplasia:* There is transformation of various types of epithelium into squamous epithelium due to chronic irritation.
     i. In bronchus (normally lined by stratified columnar ciliated epithelium) in chronic smokers.
     ii. In gallbladder, in prostrate in chronic prostatitis.
   - *Columnar metaplasia:* There is transformation of various epithelium into columnar epithelium.
     i. Intestinal metaplasia in healed chronic gastric ulcer.
     ii. Conservation of pseudostratified columnar epithelium into chronic bronchitis to columnar type.
2. **Mesenchymal metaplasia:** There is transformation of one adult type of mesenchymal tissue into another.
   - *Osseous metaplasia:* This is formation of bone in fibrous tissue, cartilage and myeloid tissue.
     i. Arterial wall in old age
     ii. In fibrous stroma of tumor.
     iii. In cartilage of larynx and bronchi in old age.
   - *Cartilaginous metaplasia*: In healing of fracture.

Q.3. Write a short note on dysplasia.

(Sep 2007, 5 Marks) (Dec 2015, 3 Marks)

Or

Write note on dysplasia. *(June 2015, 5 Marks)*

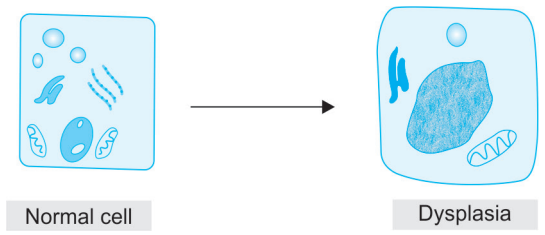

Fig. 2: Dysplasia.

Ans. Dysplasia means "disordered cellular development".

- It is also referred as atypical hyperplasia.
- Dysplasia occurs most often in epithelial cells.
- Causes of dysplasia includes diverse cellular insult including physical, chemical and biological.

JAYPEE BROTHERS

- Epithelial dysplasia is characterized by cellular proliferation and cytological changes.
- These changes include:
  - Increased number of layers of epithelial cells.
  - Disorderly arrangement of cells.
  - Loss of basal polarity, i.e., nuclei lying away from basement membrane.
  - Cellular and nuclear pleomorphism, i.e., altered cellular and nuclear size and shape.
  - Increased nuclear-cytoplasmic ratio.
  - Nuclear hyperchromatism, i.e., increased basophilia on staining with hematoxylin.
  - Increased mitotic activity, i.e., altered cell proliferation.
- Dysplasia occurs due to chronic irritation or prolonged inflammation.
- Dysplasia progresses into carcinoma.
- The two most common examples of dysplastic changes are: Uterine cervix and respiratory tract.

Q.4. Write difference between dystrophic and metastatic calcification. *(Jan 2024, 3 Marks) (Oct 2007, 5 Marks)*

Or

Write differences between metastatic and dystrophic calcification. *(Feb 2019, 3 Marks)*

Ans.

Features	Dystrophic calcification	Metastatic calcification
Definition	Deposition of calcium salts in dead and degenerated tissues	Deposition of calcium salts in normal tissues
Calcium metabolism	Normal	Deranged
Serum calcium level	Normal	Hypercalcemia
Causes	Necrosis, infarcts, thrombi, hematoma, dead parasites, old scars, atheromas, tumors, cysts, calcinosis cutis	Hyperparathyroidism, bony destruction lesions, immobilization, hypervitaminosis D, milk alkali syndrome
Pathogenesis	Formation of normal hydroxyapatite involving phase of initiation and propagation	Formed by relatively high pH at certain sites, for example in lungs, stomach, blood vessels and cornea

Q.5. Write a short note on fatty changes. *(Dec 2010, 5 Marks)*

Or

Write in short about fatty liver. *(May/June 2009, 8 Marks)*

Or

Write short note on fatty degeneration. *(Mar 2013, 3 Marks)*

Or

Write a note on fatty liver. *(Nov 2016, 5 Marks)*

Write short answer on pathogenesis of fatty change in liver. *(Nov 2019, 3 Marks)*

Ans. Fatty change is the intracellular accumulation of neutral fat within parenchymal cells.

- Fatty change neither involves degeneration nor it involve infiltration.
- Deposition of fat is in cytosol and it represent an acute increase in intracellular lipids.
- It is common in liver and can occur in any non-fatty tissues such as heart, skeletal muscle, kidney, liver, etc.

Fatty Liver

Pathogenesis

In fatty liver, accumulation of triglycerides can occur due to following defects in normal fat metabolism:

- Increased entry of free acids into liver.
- Increased synthesis of fatty acid by liver.
- Decreased oxidation of fatty acids into ketone bodies.
- Increased glycerophosphate causing increased esterification of fatty acids to triglycerides.
- Decreased synthesis of "lipid acceptor protein" so decreased formation of lipoprotein from triglycerides.
- Block in the excretion of lipoprotein from liver into plasma.

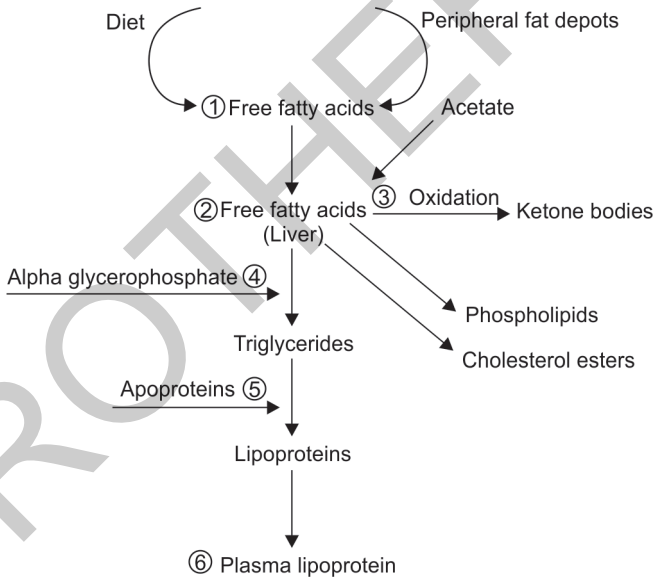

Fig. 3: Pathway of development of fatty liver.

Etiology

- Excess alcohol consumption
- Starvation
- Malnutrition
- Obesity
- Diabetes mellitus
- Chronic illness (tuberculosis)
- Late pregnancy
- Hepatotoxins such as CCl_4, ether
- Certain drugs such as steroid, tetracycline and aspirin
- Hypoxia in anemia and cardiac failure.

Gross Changes

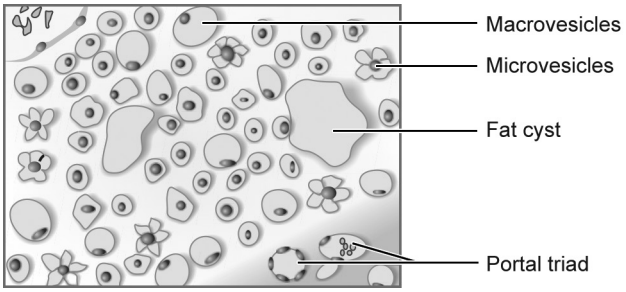

Fig. 4: Fatty liver *(For color version, see Plate 1).*

Grossly, the fatty liver is enlarged, pale, soft, yellowish with a tense glistening capsule and rounded margins. Focal fatty change is yellow mottling.

JAYPEE BROTHERS

Microscopically

- The lipid vacuoles are initially small and are present around nucleus.
- With progression of process, the vacuoles become large pushing the nucleus to periphery of cell.
- At times, the hepatocytes laden with large lipid vacuoles may rupture and lipid vacuoles coalesce to form fatty cysts.

Events in evaluation of fatty liver

Flowchart 1: Events in evaluation of fatty liver.

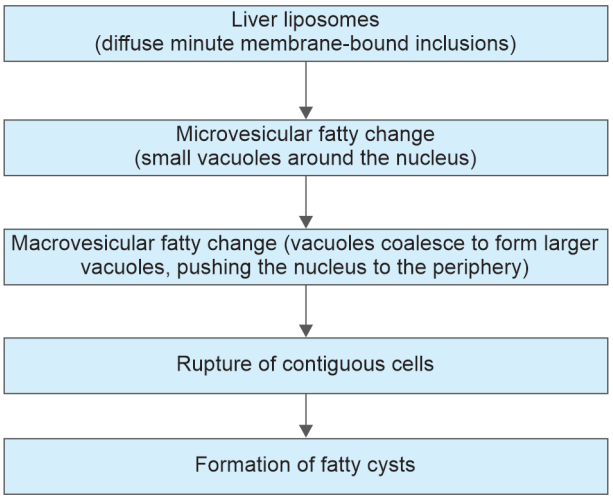

Q.6. Write a short note on gangrene.

(Sep 2013, 3 Marks) (Sep 2006, 5 Marks) (Feb 2014, 3 Marks) (Apr 2009, 5 Marks)

Or

Write in brief on gangrene. *(Jan 2012, 5 Marks)*

Or

Define gangrene and describe wet gangrene.

(Dec 2020, 3 Marks) (May 2018, 7 Marks)

Or

Write short answer on gangrene. *(Sep 2018, 3 Marks)*

Or

Define gangrene and its type in details.

(Oct 2019, 5 Marks)

Or

Write very short answer on gangrene.

(Oct 2021, 2 Marks)

Ans.

Gangrene

Gangrene is the necrosis of tissue which is associated with super added putrefaction, most often following coagulative necrosis due to ischemia, e.g., gangrene of bowl, gangrene of limb, etc. There are three main forms of gangrene, i.e., dry, wet and gas gangrene.

Dry Gangrene

- This form of gangrene begins in the distal part of limb due to ischemia. For example in toes and feet due to arteriosclerosis and ergot poisoning.
- Other causes of dry gangrene foot includes Buerger's disease, Raynaud's disease and trauma.
- Dry gangrene start in one of the toe which is farthest from the blood supply and have so small amount of blood that invading bacteria find it very hard to grow in necrotic area.
- Dry gangrene spread slowly upwards till it reaches a point where blood supply is adequate to keep tissue viable.
- Characteristic appearance of this gangrene is formation of line of separation between gangrenous and viable part.



Fig. 5: Dry gangrene.

Pathologic Changes

The affected part is dry, shrunken and dark black.

- The line of separation usually brings about complete separation.
- The line of separation consists of inflammatory granulation tissue.

Wet Gangrene

This occurs in naturally moist tissues and organs such as the bowel, mouth, lung, cervix, vulva, etc.

- Two other examples of clinical significance are:
  1. Diabetic foot due to high glucose content in necrosed tissue which favor growth of bacteria.
  2. Bed sore in bed ridden patient.
- Wet gangrene occurs due to blockage of venous and arterial blood flow. Affected part is stuffed with blood which favors rapid growth of putrefactive bacteria. Toxic products formed by bacteria get absorbed causing systemic manifestation of septicemia and finally death.

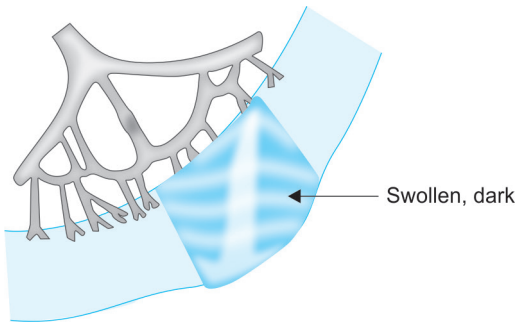

Fig. 6: Wet gangrene.

Pathologic Changes

- The affected part is soft, swollen, putrid, rotten and dark.
- No clear line of demarcation.

Histologically

- Presence of coagulative necrosis with stuffing of affected part with blood.
- Mucosa is ulcerated and sloughed.
- There is presence of intense acute inflammatory exudates and thrombosed vessels.
- Line of demarcation between gangrenous segment and viable bowel is not clear cut.

Gas Gangrene

- It is the special form of wet gangrene caused due to gas forming clostridia.

JAYPEE BROTHERS

- Clostridia gain entry from open contaminated wound into the tissues mainly in muscles.
- Clostridia produce various toxins which produces necrosis and edema locally and are also absorbed producing profound systemic manifestations.

Gross Changes

- The affected area is swollen, edematous, painful and crepitant due to accumulation of gas bubbles in tissues.
- The affected area becomes dark black and foul smelling.

Histologically

- Muscle fibers undergo coagulative necrosis along with liquefaction.
- Large number of gram-positive bacilli can be identified.
- At periphery, a zone of leukocyte infiltration, edema and congestion are found.
- Capillary and venous thrombi are commonly seen.

Q.7. Define necrosis. Describe all types of necrosis in detail. *(Aug 2012, 15 Marks)*

Or

Define necrosis and write in detail the types of necrosis. *(June 2015, 10 Marks)*

Or

Define necrosis and its types in detail. *(May 2018, 5 Marks)*

Or

Define necrosis and types of necrosis giving examples of each type briefly. *(Mar 2006, 15 Marks)*

Or

Write a short note on types of necrosis. *(Mar 2006, 5 Marks)*

Or

Define necrosis. Enumerate type and discuss caseous necrosis. *(Oct 2007, 15 Marks)*

Or

Define necrosis. Enumerate types of necrosis and describe caseous necrosis. *(Jan 2014, 10 Marks), (Oct 2019, 5 Marks)*

Or

Define and enumerate types of necrosis. Describe caseous necrosis. *(Aug 2017, 5 Marks)*

Or

Define necrosis and enumerate type of necrosis *(May 2020, 3 Marks)*

Ans. Necrosis is defined as focal death along with degradation of tissue by hydrolytic enzymes liberated by dead cell. It is invariably accompanied by inflammatory reaction.

Types of Necrosis

Morphologically necrosis is classified into five distinct types:

Types of necrosis	Features	Mechanism	Gross appearance	Microscopic features
Coagulative necrosis	• This is the most common type of necrosis caused by irreversible focal injury mostly from sudden cessation of blood flow • Organs commonly affected by heart, kidney and spleen • The best example is myocardial infarct	Decrease in the pH ⇓ Denaturation of structural and enzymatic proteins ⇓ Decrease in enzymatic proteins block proteolysis ⇓ Preservation of basic architecture of cell and tissue	• Focus of coagulative necrosis is pale, firm and slightly swollen and is called infarct • With progression affected area become yellowish, soft and shrunken	• Microscopically hallmark of coagulative necrosis is conversion of normal cells into "tombstones", i.e., outlines of cell are retained so that cell type can still be recognized but their cytoplasmic and nuclear details are lost • Necrosed cells are swollen and have more eosinophilic cytoplasm than normal. Cells show nuclear changes such as pyknosis, karyorrhexis and karyolysis • Necrosed focus is infiltrated by inflammatory cells and dead cells are phagocytosed leaving granular debris and fragments of cells

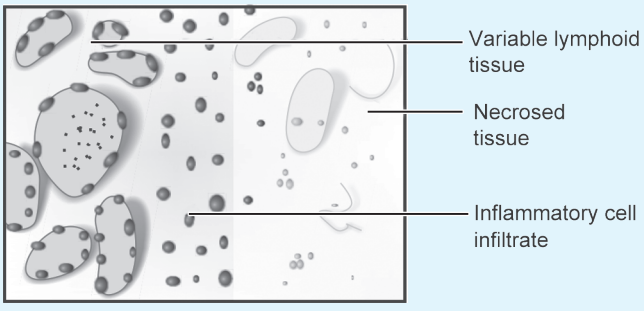

Fig. 7: Coagulative necrosis *(For color version, see Plate 1).*

Contd…

JAYPEE BROTHERS

Contd…

Types of necrosis	Features	Mechanism	Gross appearance	Microscopic features
Liquefaction necrosis	• When necrosed cells and tissues are converted into structure less fluids it is called as liquefactive necrosis • It occurs commonly due to ischemia and bacterial or fungal infections, due to degradation of tissues by action of powerful hydrolytic enzyme • The cellular structure of organ is lost and the tissue is digested, it is converted into a liquefied mass which appears creamy yellow in color and is called as pus • The common examples are infarct brain and abscess cavity	Bacterial infection and accumulation of inflammation cells ↓ Release of enzymes Autolysis and heterolysis	The affected area is set with liquefied center containing necrotic debris. It can later on lead to the formation of cystic wall **Affected organs:** • **Brain:** Soft necrotic region is present and the center demonstrates the liquefaction. Reason for the presence of liquefactive necrosis in brain is presence of the abundant lysosomal enzymes or the different hydrolases which are specific to the cells of the central nervous system • **Abscess anywhere:** Bacterial infection leads to the acute inflammatory reaction and the necrosis causes the release of liquid viscous material which is thick creamy yellow and is known as pus. Localized collection of pus is called as abscess	• Microscopically liquefied tissue has no structure. The cystic space contains necrotic debris and phagocytosed material and macrophage • The cyst wall is formed by proliferation of capillaries, inflammatory cell, glial cell in case of brain and proliferating fibroblast in case of abscess cavity
Caseous necrosis	• When the necrosed tissue is converted into soft cheese like mass which is called as caseous necrosis • Such necrosis occurs in case of granuloma production by tuberculosis, fungal infections It combines feature of both coagulative and liquefactive necrosis	It is due to delayed hypersensitivity reaction to mycobacterial capsular antigens	• Tuberculosis involves any of the organ, but commonly the lung and the lymph nodes are affected. • Necrotic region is generally yellowish white, soft, friable, granular and it resembles as the dry, clumpy cheese	• Microscopically the central part of granuloma shows finely granular structure less material which contains fragments of cells and nucleic acids • Surrounding tissue shows characteristic granulomatous inflammatory reaction consisting of epithelioid cells, Langhans and foreign body giant cells and peripheral mantle of lymphocytes • Sometimes dystrophic calcification can be seen
	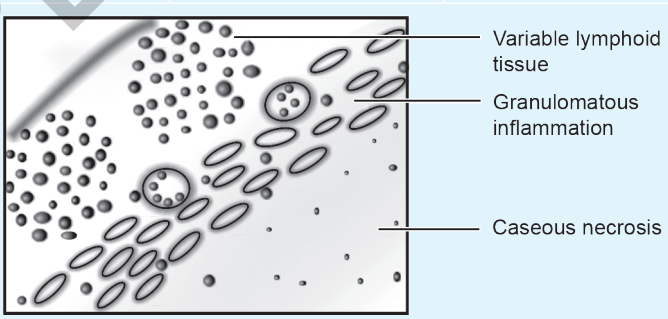			
Fat necrosis	• Fat necrosis means necrosis of fat cells or adipose tissue • It commonly occurs in acute pancreatitis and traumatic fat necrosis of breast	• Release of activated pancreatic lipases in pancreas and peritoneal cavity • Focal areas of destruction of fat and release of fatty acid • Released fatty acids combine with calcium • Produce chalky white areas	Fat necrosis appears as yellowish white and firm deposit. Formation of calcium soaps impart necrosed foci firmer and chalky white in appearance	Necrosed fat cells have cloudy appearance and are surrounded by an inflammatory reaction

Fig. 8: Caseous necrosis *(For color version, see Plate 1).*

Contd…

JAYPEE BROTHERS

Contd…

Types of necrosis	Features	Mechanism	Gross appearance	Microscopic features
	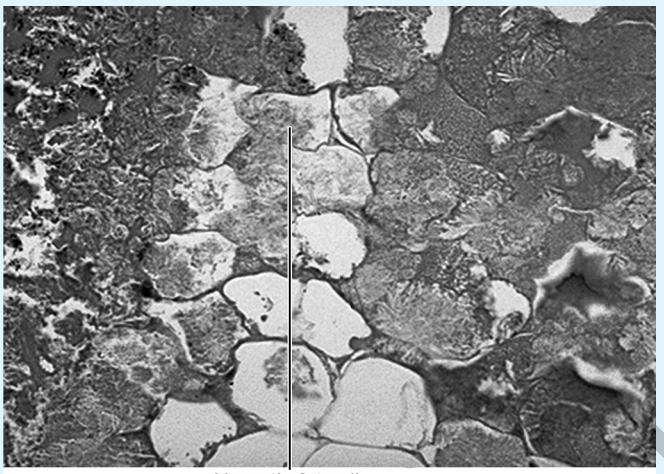 Necrotic fat cell			
	Fig. 9: Fat necrosis *(For color version, see Plate 1).*			
Fibrinoid necrosis	• It is characterized by deposition of fibrin like proteinaceous material which consists of the staining properties of fibrin. It obscures the underlying cellular detail. • Examples of fibrinoid necrosis are immunologic tissue injury such as autoimmune vasculitis, autoimmune disease, arthus reaction, etc.	The fibrinoid necrosis results due to the immunologic tissue injury.	–	• It is identified by brightly eosinophilic, hyaline like deposition in vessel wall • Necrotic focus is surrounded by nuclear debris of neutrophils • Local hemorrhage may occur due to rupture of blood vessel
	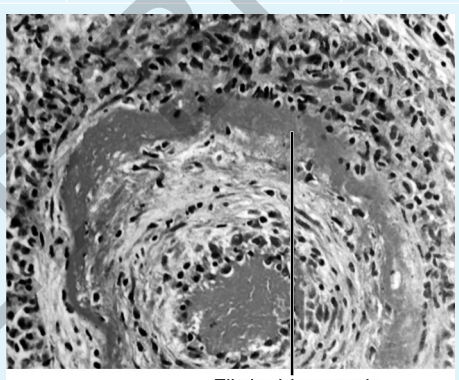 Fibrinoid necrosis			
	Fig. 10: Fibrinoid necrosis *(For color version, see Plate 1).*			

Q.8. Describe gangrene and necrosis.

(Apr 2008, 5 Marks), (Aug 2011, 15 Marks)

Ans. *For necrosis refer to Ans. 7 of same chapter.*

For gangrene refer to Ans. 6 of same chapter.

Q.9. Write briefly on caseation necrosis.

(Jun 2010, 2 Marks)

Ans. When the necrosed tissue is converted into soft cheese like mass which is called as caseous necrosis.

- Such necrosis occurs in case of granuloma production by tuberculosis, fungal infections.
- It combines feature of both coagulative and liquefactive necrosis.

Pathogenesis

It is due to delayed hypersensitivity reaction to mycobacterial capsular antigens.

Gross Appearance

Caseous necrosed tissue looks soft, granular and yellowish and resemble as dry cheese. Its appearance is due to histotoxic effects of lipopolysaccharides present in capsule of *M. tuberculum*.

Microscopic Appearance

- Microscopically the central part of granuloma shows finely granular structure less material which contains fragments of cells and nucleic acids.
- Surrounding tissue shows characteristic granulomatous inflammatory reaction consisting of epithelioid cells, Langhans and foreign body giant cells and peripheral mantle of lymphocytes.
- Sometimes dystrophic calcification can be seen.

Q.10. Write short note on necrosis.

(Sep 2013, 4 Marks) (Dec 2010, 5 Marks) (Feb 2006, 5 Marks)

JAYPEE BROTHERS

Or

Write short answer on necrosis.

(Apr 2022, 3 Marks) (Apr 2019, 3 Marks)

Ans. Necrosis is defined as focal death along with degradation of tissue by hydrolytic enzymes liberated by dead cells. It is invariably accompanied by inflammatory reaction.

- Necrosis can be caused by ischemia, infection, poisoning, etc. and is invariably pathological.
- Necrosis usually precipitates an inflammatory response and is accompanied by cell swelling, lysis and lysosomal leakage. Self-digestion of cells by enzymes liberated from its own lysosomes is known as autolysis.

Events in Necrosis

Flowchart 2: Events in necrosis.

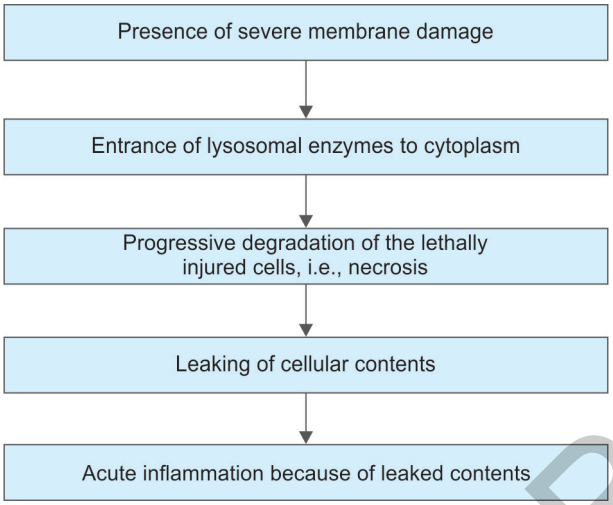

Various Cytoplasmic and Nuclear Changes in Necrosis

Cytoplasmic Changes

- Increased eosinophilia of the cytoplasm because:
  - Loss of normal cytoplasmic basophilia caused by the loss of RNA
  - Denaturation of cytoplasmic proteins which then bind strongly to the eosin dye.
- Presence of glassy homogenous cytoplasm due to loss of glycogen.
- There is swelling as well as vacuolation of the cytoplasm.
- Swelling of cell and organelle may eventually lead to discontinuities in cell and organelle membranes and finally it rupture.
- There is formation of myelin figures, i.e., phospholipid masses derived from damaged cell membranes.

Nuclear Changes

The changes in nucleus appear in one of the following three patterns:

1. Shrinkage of nucleus and increased basophilia, i.e., pyknosis
2. Nuclear fragmentation, i.e., karyorrhexis
3. Nucleus undergo dissolution, i.e., karyolysis.

Types of Necrosis

For details refer to Ans. 7 of same chapter.

Q.11. Write the method of spread of gas gangrene and write the staining and morphology of organism producing it. *(Feb 2005, 3 Marks) (Sep 2009, 5 Marks)*

Ans.

Method of Spread of Gas Gangrene

Clostridia release collagenase and hyaluronidase that degrade extracellular matrix proteins and contribute to bacterial invasiveness, but their most powerful virulence factors are many toxins they produce. *C. perfringens* secretes 12 toxins, the most important of which is alpha toxin.

Alpha toxin is a phospholipase C that degrades lecithin, a major component of cell membrane, and so destroys red blood cells, platelets, and muscle cells, causing myonecrosis.

The alpha toxin also has a sphingomyelinase activity that contributes to nerve sheath damage. The O toxin binds cholesterol and forms a membrane-destabilizing pore that causes leukocyte lysis in the lesions of gas gangrene.

Morphology of Organism

Clostridium perfringens leads to gas gangrene. Morphology of *C. perfringens* is:

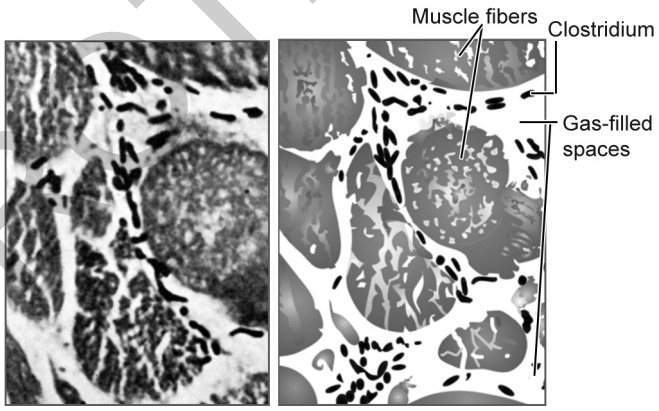

Fig. 11: Gas gangrene *(For color version, see Plate 1).*

- It is a plump, gram-positive bacillus with straight, parallel side, rounded or truncated ends about 4 to 6 microns × 1 micron.
- It may occur singly or in chain.
- It is pleomorphic.
- It is capsulated and non-motile.
- It is filamentous and involution forms are common.

Staining of Organism

C. perfringens is stained by Gram stain and is a gram-positive organism.

Q.12. Write a short note on Zenker's degeneration. *(Apr 2010, 5 Marks)*

Ans.

Zenker's Degeneration

- Hyaline degeneration of voluntary muscles is also called as Zenker's degeneration.
- It is intracellular hyaline change associated with heterogeneous pathologic condition.
- It occurs in rectus abdominalis muscle in typhoid fever.
- The muscle losses its fibrillar staining and becomes glossy and hyaline.

JAYPEE BROTHERS

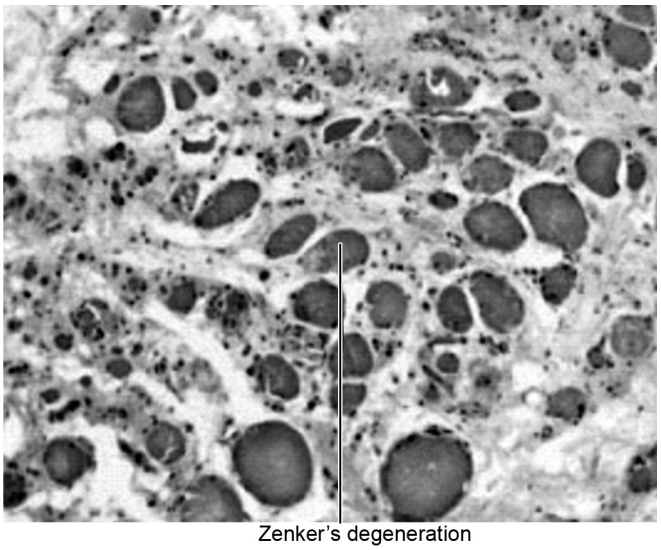

Fig. 12: Zenker's degeneration *(For color version, see Plate 1).*

Q.13. Write a short note on apoptosis.

(May 2018, 5 Marks) (Mar 2006, 5 Marks)

Or

Write in short about apoptosis.

(May/June 2009, 7 Marks)

Or

Write note on apoptosis. *(Jan 2012, 3 Marks)*

Ans. Apoptosis is a form of coordinated and internally programmed cell death.

Morphologic Changes

Following are the morphological changes in apoptosis which are seen in electron microscope:

- *Cell shrinkage:* The cell is smaller in size; the cytoplasm is dense; and the organelles, although relatively normal, are more tightly packed.
- *Chromatin condensation:* This is the most characteristic feature of apoptosis. The chromatin aggregates peripherally, under the nuclear membrane, into well-delimited dense masses of various shapes and sizes. The nucleus itself may break up, producing two or more fragments.
- *Formation of cytoplasmic blebs and apoptotic bodies:* The apoptotic cell first shows extensive surface blebbing, then undergoes fragmentation into a number of membrane-bound apoptotic bodies composed of cytoplasm and tightly packed organelles, with or without a nuclear fragment.
- *Phagocytosis of apoptotic cells or bodies* by adjacent healthy cells, either parenchymal cells or macrophages. The apoptotic bodies are rapidly degraded within lysosomes, and the adjacent cells migrate or proliferate to replace the space occupied by the now deleted apoptotic cell.

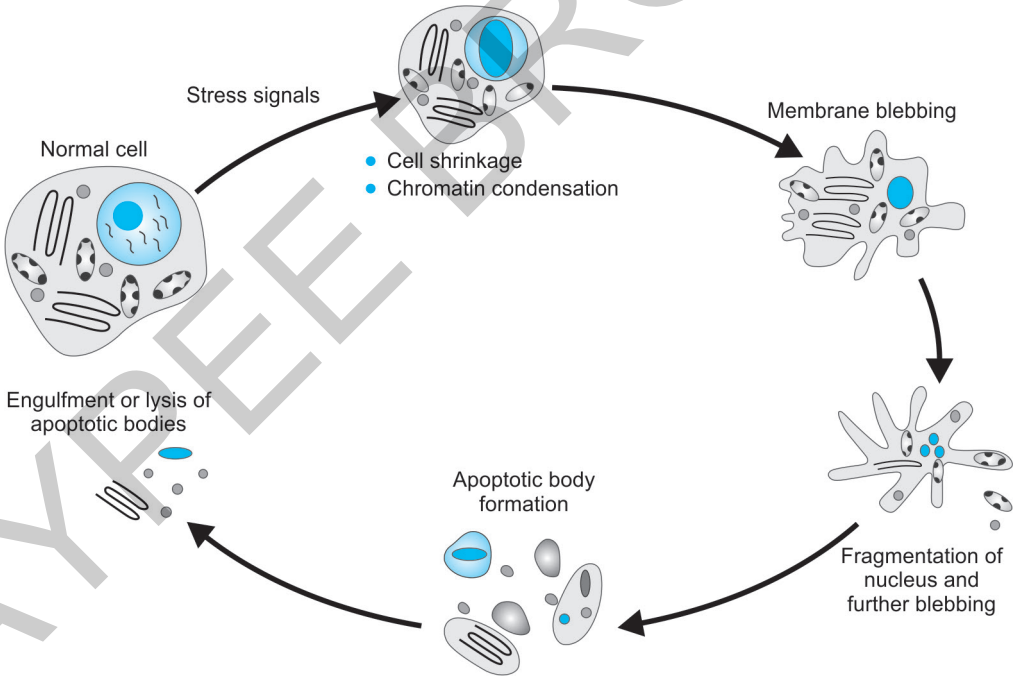

Fig. 13: Sequence of morphological changes in apoptosis.

Molecular Mechanism of Apoptosis

- **Initiators of apoptosis:** Stimulation of signaling programmed cell death act either at cell membrane or intracellularly. This includes:
  - Absence of stimuli required for normal cell survival.
  - Activators of programmed cell death.
  - Intracellular stimuli including heat, radiation, hypoxia, etc.
- **Regulators of apoptosis:** As the cell is involved in apoptosis by above mentioned signals, the next phase is regulation in which certain proteins convert death signals to final programmed cell death and determine the outcome. Regulator proteins are:
  - *BCL-2:* It is a gene which is located in outer mitochondrial membrane and may regulate apoptotic process by binding to some other proteins, e.g., as BCL-2 bind to BAX or BAD it promote apoptosis while as it bind to BCL-XL it inhibit apoptosis.
  - *Other apoptotic regulator proteins:* Beside BCL-2 other regulatory proteins of apoptosis are TP53 protein, BAX and certain viruses.

JAYPEE BROTHERS

Flowchart 3: Molecular mechanism of apoptosis.

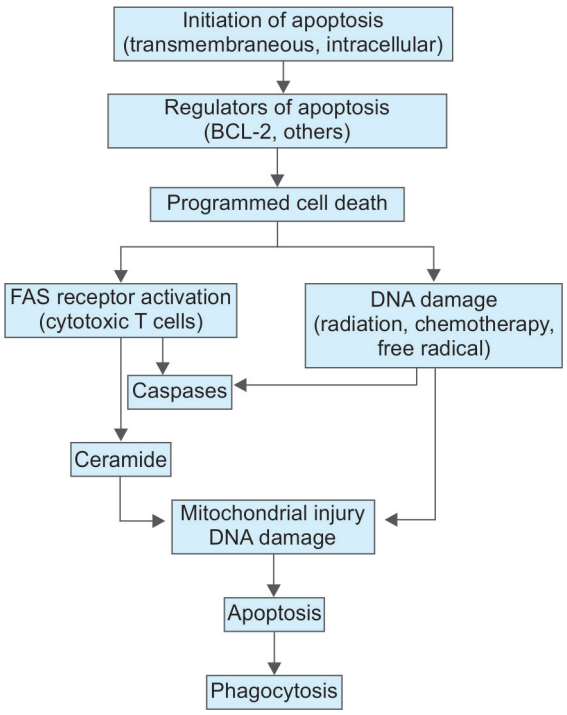

- **Programmed cell death:** Final outcome of apoptotic regulators in programmed cell death involves following pathways:
  - *FAS receptor activation:* Cell surface receptor FAS is present in cytotoxic T cells. On coming in contact with target cells FAS receptor is activated. This activates caspases and lead to proteolysis and further apoptosis.
  - *Ceramide generation:* Due to the hydrolysis of phospholipid, i.e., sphingomyelin of plasma membrane ceramide gets generated. Ceramide is implicated in mitochondrial injury and further apoptosis.
  - *DNA damage:* Damage to DNA by ionizing radiation, chemotherapeutic agents, activation oxygen species leads to apoptosis. DNA damage affect TP53 which induces synthesis of cell death promoting protein BAX and further apoptosis.
- **Phagocytosis:** Dead apoptotic cells and their fragments possess cell surface receptors which facilitates their identification by adjacent phagocytes. Phagocytes engulf the apoptotic cells and clear the area.

Diagnosis of Apoptosis

- Agarose gel electrophoresis shows step ladder pattern
- Terminal deoxynucleotidyl transferase biotin-dUTP nick end labeling (TUNEL) technique for in vivo detection
- H&E stain, Feulgen and acridine orange staining of apoptotic cells
- Measurement of cytosolic cytochrome C and activated caspase
- Expression of phosphatidyl serine on the outer leaflet of the plasma membrane by apoptotic cells enables their recognition by using the dye annexin V.

Disorders Associated with Apoptosis

- Disorders associated with decreased apoptosis, i.e., cancer, autoimmunity
- Disorders associated with increased apoptosis:
  a. Neurodegenerative diseases, i.e., Alzheimer, Huntington, Parkinson disease
  b. Ischemic injury in stroke and myocardial infarction
  c. Death of virus-infected cells as in AIDS.

Q.14. Write a short note on pathological calcification.

(Dec 2018, 5 Marks) (Mar 2007, 5 Marks)

Or

Write very short answer on pathological calcification.

(Oct 2021, 2 Marks)

Ans. Pathologic calcification is the abnormal deposition of the calcium in various tumors and organs of the body:

They are of two types:

1. Dystrophic calcification
2. Metastatic calcification

Dystrophic Calcification

- It is a type of pathologic calcification in which calcium salts are deposited in the dead or degenerating tissue of the body.
- It is not associated with increased level of serum calcium and is related to change in local environment.
- This is the most frequent type of pathological calcification found in wide variety of tissues.
- In mouth area of dystrophic calcification are found in gingiva, tongue, cheek and pulp.
- One of the most common intraoral dystrophic calcification found in the pulp of the teeth is "Pulp Stone".

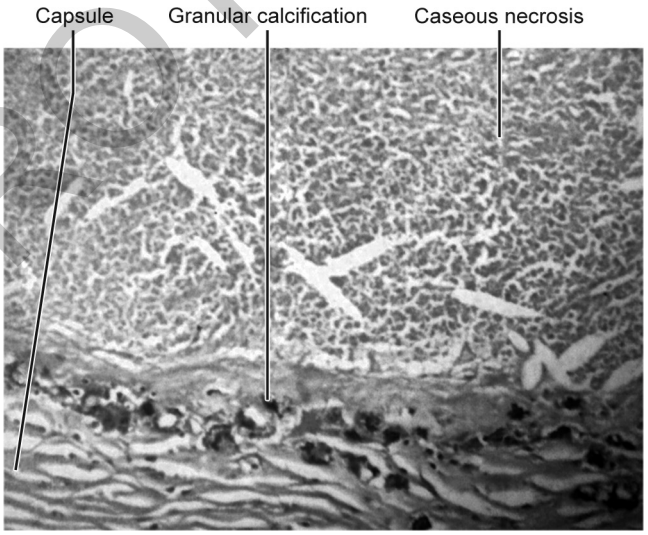

Fig. 14: Dystrophic calcification *(For color version, see Plate 2).*

Metastatic Calcification

- Abnormal deposition of calcium in the tissue due to increase in amount of serum calcium.

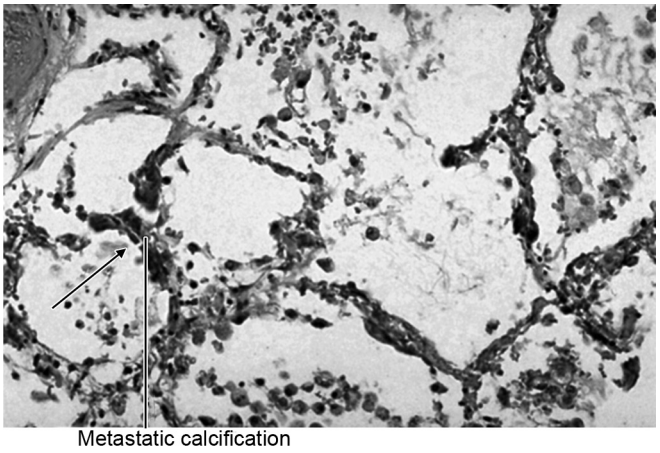

Fig. 15: Metastatic calcification *(For color version, see Plate 2).*

JAYPEE BROTHERS

- It occurs particularly in diseases like hyperparathyroidism which depletes the bone calcium and causes high level of blood calcium.
- Metastatic calcification also occurs in hypervitaminosis D. In this type of calcification deposit of calcium occurs in kidney, lung, gastric mucosa and media of blood vessels.

Gross Pathology of Pathological Calcification

Pathologic calcification appears as fine white granules or clumps of gritty deposits.

Microscopical Picture of Pathological Calcification

- In hematoxylin and eosin (H&E) stained sections it appear as intracellular or extracellular basophilic amorphous granular deposits.

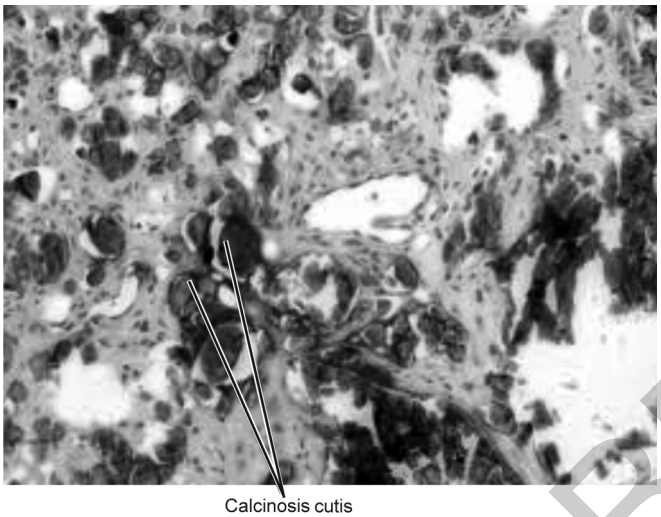

Fig. 16: Calcinosis cutis *(For color version, see Plate 2).*

- At times single necrotic cells act as seeds which get encrusted with lamellar mineral deposits, i.e., psammoma body called so due to resemblance to grains of sand and commonly seen in some papillary cancers, i.e., thyroid and meningiomas.
- Calcium and iron salts may gather about long slender spicules of asbestos in lung, creating beaded, dumb-bell forms called asbestos bodies.

Q.15. Write a short note on free radical injury.

(Apr 2007, 5 Marks)

Ans. Free radicals are the chemical species with an unpaired electron in their outer orbit. These free radicals react with both inorganic and the organic molecules which are present in membranes and nucleic acids.

Causes of Free Radical Injury

Free radical generation is induced by:

- Absorption of radiant energy, i.e., UV rays, X-rays.
- Enzymatic metabolism of exogenous chemical/drugs, i.e., CCl_4 to CCl^-_3
- Reduction-oxidation reaction processes that occur during normal metabolism, i.e., formation of superoxide anion (O_2^-). hydrogen peroxide (H_2O_2) hydroxyl ion (OH^-).
- Reactions involving transition metals, i.e., iron (Fenton reaction), copper, etc.
- Reactions involving nitric oxide (NO) which acts as a free radical and can be converted to highly reactive peroxynitrite anion ($ONOO^-$ as well as NO_2 and NO_3^-).

Effects of Free Radical Injury

The hydroxyl radical is the most reactive species. It may produce membrane damage by the following mechanisms:

- *Lipid peroxidation:* Polyunsaturated fatty acids of membrane are attacked repeatedly and severely by oxygen derived free radicals to yield highly destructive polyunsaturated fatty acid radicals, i.e., lipid hydroperoxy radicals and lipid. This reaction is termed as lipid peroxidation. Lipid peroxidation is propagated to other sites causing widespread membrane damage and destruction of organelles.
- *Oxidation of proteins:* Oxygen derived free radicals cause cell injury by oxidation of protein macromolecules of cells, cross linking of labile amino acids as well as by fragmentation of polypeptides directly. The end result is degradation of cytosolic neutral proteases and cell destruction.
- *DNA damage:* Free radicals cause breaks in the single strands of nuclear and mitochondrial DNA. Thus results in cell injury, it may also cause malignant transformation of cells.
- *Cytoskeletal damage:* Reactive oxygen species are also known to interact with cytoskeletal elements and interfere in mitochondrial aerobic phosphorylation and thus cause ATP depletion.

  The antioxidants are used to inactivate the free radicals.

Inactivation of Free Radicals

Inactivation of free radicals is done by:

- Antioxidants, i.e., vitamins A, C, E and β carotene.
- Iron and copper binding proteins, i.e., transferrin, ferritin. lactoferrin, ceruloplasmin
- Enzymes such as catalase, superoxide dismutase, glutathione peroxidase.

Q.16. Write the differences between necrosis and degeneration.

(Oct 2006, 3 Marks) (Mar 2009, 5 Marks)

Ans.

Necrosis	Degeneration
• It is defined as the focal death along with degradation of tissue by hydrolytic enzymes liberated by the cell	• It is a retrogressive change and is described as visible change in the living cell. It indicates cellular damage
• Irreversible cell injury	• Reversible cell injury
• Lethal cell injury	• Nonlethal cell injury
Includes: • Cell digestion by lytic enzymes • Denaturation of protein	**Includes:** • Cellular swelling • Fatty changes • Hyaline changes • Mucoid changes
Causes • Coagulation necrosis ischemia • Liquefaction necrosis ischemia and bacterial or fungal infection • Caseous necrosis tuberculosis • Fat necrosis lipase enzyme action • Focal necrosis immunological tissue injury	**Causes** Cellular swelling: • Bacterial toxins, chemicals like carbolic acid. Metabolic poison (diabetic coma) • Fatty changes excess alcohol consumption, starvation, malnutrition, diabetes mellitus Hyaline changes: • Heterogeneous pathological conditions • Mucoid changes inflammation

Q.17. Write the differences between apoptosis and necrosis.

(Feb 2016, 5 Marks) (Mar 2007, 3 Marks)

Or

Define apoptosis. Differentiate between apoptosis and necrosis *(May 2019, 3 Marks)*

JAYPEE BROTHERS

Ans. Apoptosis is a form of coordinated and internally programmed cell death.

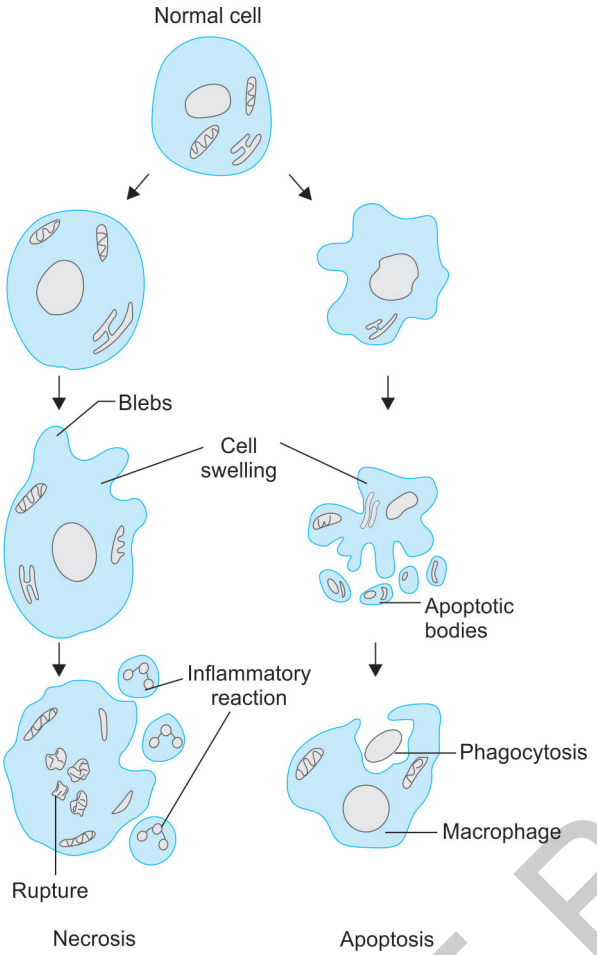

Fig. 17: Necrosis and apoptosis.

Features	Apoptosis	Necrosis
Definition	Apoptosis is a form of coordinated and internally programmed cell death	It is defined as the focal death along with degradation of tissue by hydrolytic enzymes liberated by the cell
Causes	It can be physiological or pathological	It is always pathological
Involvement	It involves single or small group of cells	It involves large groups of cells
Inflammation	Absent	Present
Cellular change	Cell shrinkage is present	Cell swelling is present
Cell membrane	Bleb formation is seen	Membrane disruption is seen
Nucleus	Chromatin condensation followed by fragmentation	Nuclear pyknosis, karyolysis and karyorrhexis
Removal of cell	Macrophages phagocytose the apoptotic bodies	Enzymatic digestion or phagocytosis of cell debris by macrophages
Lysosomes/other organelles	Intact	Hydrolytic enzyme release due to rupture
Mechanism	Genetically coordinated	Due to ATP depletion, free radicals, mitochondrial damage, etc.
Agarose gel electrophoresis	It shows Stepladder DNA pattern	It shows Diffuse DNA pattern

Q.18. Write a short note on gas gangrene.

(Aug 2017, 5 Marks) (Oct 2007, 5 Marks) (Apr 2008, 5 Marks) (Nov 2008, 5 Marks)

Ans. Gas gangrene is a special form of wet gangrene caused by gas forming clostridia.

- This bacteria gain entry into the tissues through open contaminated wound, especially in the muscles, or as a complications of operations on colon which normally contain clostridia.
- Clostridia produce various toxins which produce necrosis and edema locally and are absorbed producing profound systemic manifestations.

Gross Changes

- The affected area is swollen, edematous, painful and crepitant due to accumulation of gas bubbles within the tissue.
- The affected tissue becomes dark black and foul smelling.

Microscopically

- Muscle fibers undergo coagulative necrosis with liquefaction.
- Large number of gram-positive bacilli can be identified.
- At the periphery, a zone of leukocyte infiltration, edema and congestion are found.
- Capillary and venous thrombi are common.

Q.19. Write difference between moist and dry gangrene.

(Sep 2007, 3 Marks) (Apr 2010, 5 Marks)

Ans.

Features	Dry gangrene	Moist gangrene
Site	Commonly limbs	Bowl is most commonly affected
Mechanism	Arterial occlusion	Mostly by venous occlusion less by arterial occlusion
Macroscopy	Organ dry, shrunken and black	Part moist, soft, swollen, rotten and dark
Putrefaction	Limited due to little blood supply	Marked due to stuffing of organ with blood
Line of demarcation	Present at the junction between healthy and gangrenous part	No clear line of demarcation
Bacterias	Fail to survive	Numerous present
Prognosis	Better	Poor

Q.20. Define necrosis. Name different types of necrosis. What are nuclear changes in necrosis. Describe labeled diagram of structure of tubercle.

(Oct 2008, 3 Marks)

Ans. Necrosis is defined as focal death along with degradation of tissue by hydrolytic enzymes liberated by cell.

Types of Necrosis

There are five types of necrosis:

1. Coagulative necrosis
2. Liquefaction necrosis
3. Caseous necrosis
4. Fat necrosis
5. Fibrinoid necrosis.

Nuclear Changes

The nuclear changes are:

- **Pyknosis:** Condensation of nuclear chromatin.

JAYPEE BROTHERS

- **Karyolysis:** This may either undergo dissolution.
- **Karyorrhexis:** Fragmentation into many granular clumps.

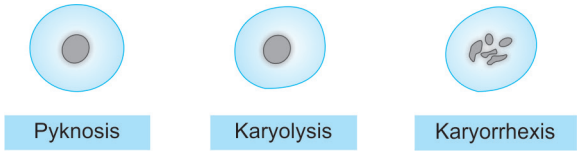

Fig. 18: Nuclear changes in necrosis.

Diagram of Structure of Tubercle

For diagram of tubercle refer to Ans. 20 of chapter INFLAMMATION and HEALING.

Q.21. Define cell injury. Write in brief about its pathogenesis.

(May/June 2009, 15 Marks)

Ans. If the limits of adaptive response to a stimulus are exceeded, or in certain instances when adaptation is not possible, a sequence of events follows, loosely termed cell injury.

Cell injury is reversible up to a certain point, but if the stimulus persists or is severe enough from the beginning, the cell reaches the "point of no return" and suffers irreversible cell injury and cell death.

I. Pathogenesis of Cell Injury

Pathogenesis of Ischemic and Hypoxic Injury

- Reversible cell injury.
- Irreversible cell injury.

Reversible cell injury

***See* Flowchart 4.**

Flowchart 4: Pathogenesis of reversible cell injury.

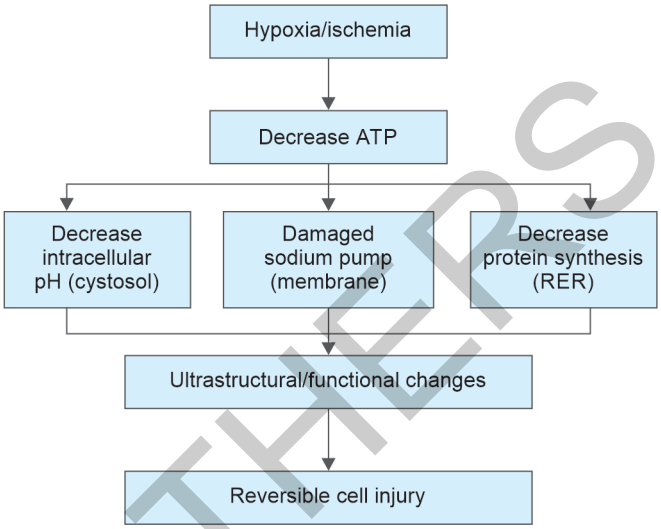

Irreversible Cell Injury

***See* Flowchart 5.**

Flowchart 5: Pathogenesis of irreversible cell injury.

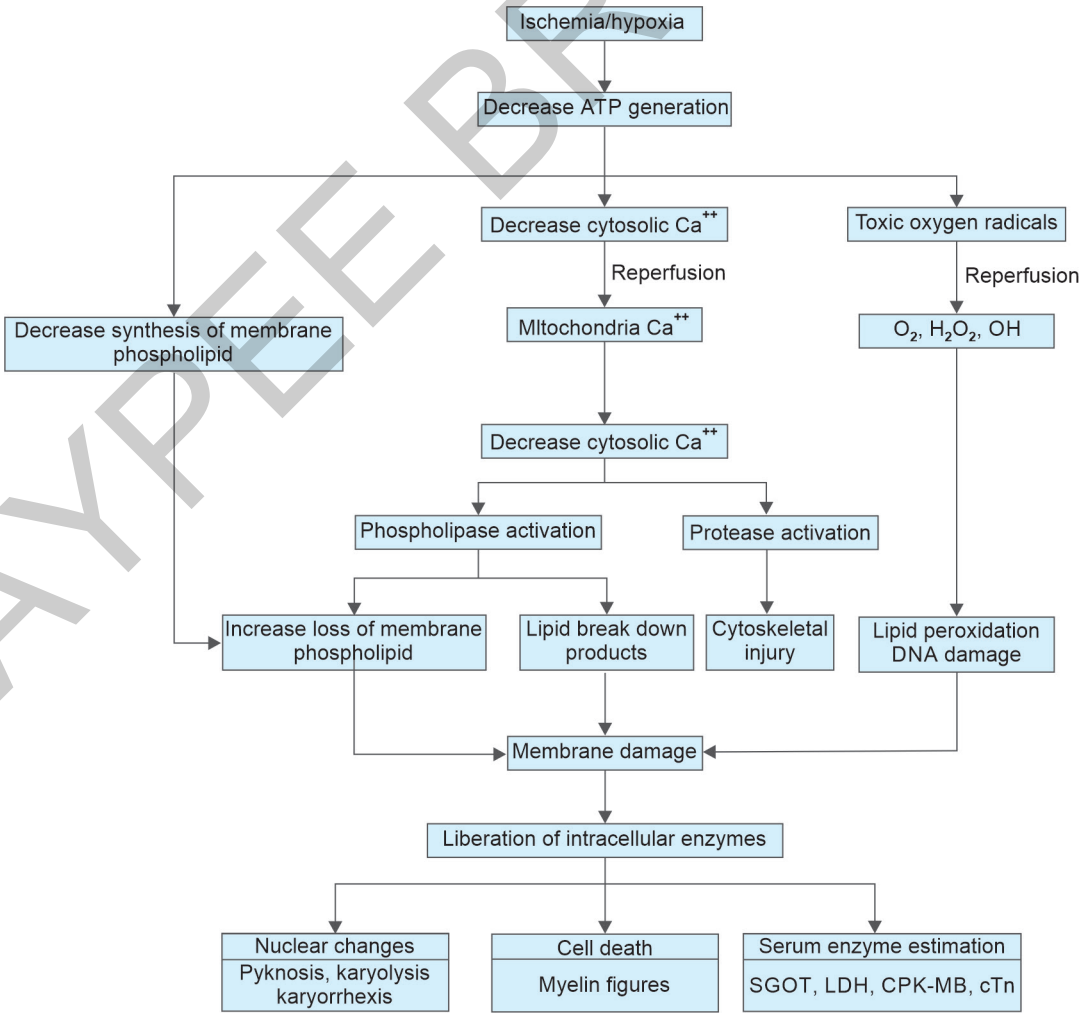

For theory of reversible and irreversible cell injury refer to Ans. 33 of same chapter.

JAYPEE BROTHERS

II. Free Radical Mediated Cell Injury

Following is the pathogenesis of free radical mediated cell injury

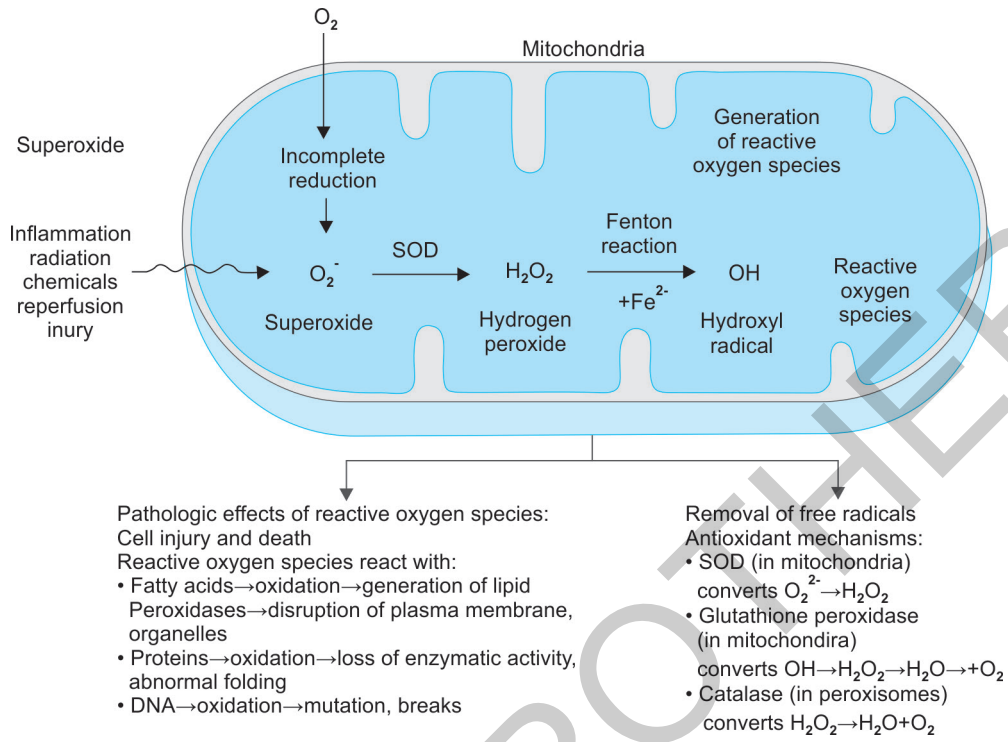

Fig. 19: Free radical mediated injury.

- Generation of oxygen free radicals begins within mitochondrial inner membrane when cytochrome oxidase catalyzes the four electron reduction of oxygen (O_2) to water (H_2O). Intermediate between reaction of O_2 to H_2O, three partially reduced species of oxygen are generated depending upon the number of electrons transferred. These are:
  - *Superoxide oxygen (O_2^-):* One electron
  - *Hydrogen peroxide (H_2O_2):* Two electrons
  - *Hydroxyl radical (OH^-):* Three electrons.
- A few other oxygen radicals which may be generated in reactions other than those during O_2 to H_2O are hypochlorous acid (HOCl), peroxynitrate ion (ONOO), nitric oxide (NO) generated by various body cells (endothelial cells, neurons, macrophages, etc.), and release of superoxide free radical in Fenton reaction.

Free Radical Generation

- The three partially reduced intermediate species between O_2 to H_2O are derived from enzymatic and non-enzymatic reaction as under:
  - *Superoxide (O_2^-):* Superoxide anion O_2^- may be generated by direct auto-oxidation of O_2 during mitochondrial electron transport reaction. Alternatively O_2^- is produced enzymatically by xanthine oxidase and cytochrome P450 in the mitochondria or cytosol. O_2^- so formed is catabolized to produce H_2O_2 by superoxide dismutase (SOD).
  - *Hydrogen peroxide (H_2O_2):* H_2O_2 is reduced to water enzymatically by catalase (in the peroxisomes) and glutathione peroxidase GSH (both in the cytosol and mitochondria).
  - *Hydroxyl radical (OH^-):* OH^- radical is formed by two ways in biologic processes by radiolysis of water and by reaction of H_2O_2 with ferrous (Fe^{++}) ions; the latter process is termed as Fenton reaction.

Free Radical Reactions

The hydroxyl radical is the most reactive species. Reactive oxygen species (ROS) produce membrane damage by the following mechanisms:

- ROS react with fatty acids and leads to oxidation which leads to generation of lipid peroxidases. This leads to disruption of plasma membrane and organelles.
- ROS reacts with proteins leading to oxidation of proteins and there is loss of enzymatic activity and abnormal folding of proteins.
- ROS reacts with DNA and leads to oxidation of DNA and there is mutation and breakage in single strand of mitochondrial and nuclear DNA.

III. Cell Injury by Chemicals

Chemicals induce cell injury by one of the following two mechanisms:

- *Direct cytotoxic effects:* Some chemicals combine with components of the cell and produce direct cytotoxicity without requiring metabolic activation. The cytotoxic damage is usually greatest to cells which are involved in the metabolism of such chemicals, e.g., in mercuric chloride poisoning, the greatest damage occurs to cells of the alimentary tract and kidney, cyanide kills the cell by poisoning mitochondrial cytochrome oxidase thus blocking oxidative phosphorylation.
- *Conversion to reactive toxic metabolites:* This mechanism involves metabolic activation to yield ultimate toxin that interacts with the target cells. The target cells in this group of chemicals may not be the same cell that metabolized the toxin. Example of cell injury by conversion of reactive metabolites is toxic liver necrosis caused by carbon tetrachloride.

JAYPEE BROTHERS

for detailed information on dental books, visit our website www.ejaypee.com, for detailed information on dental books, visit our website www.ejaypee.com, for detailed information o

Mastering the BDS IInd Year (Last 20 Years Solved Questions)

Salient Features

- Written in simple and lucid language.
- Provides broad coverage of all the subjects (General Pathology, Microbiology, General and Dental Pharmacology and Dental Material) of BDS IInd year.
- Includes vast topics in simple flowcharts, tables, and diagrammatic forms so as to make the content easy to understand and recall.
- Supports in quick revision during examinations.
- One weapon, three targets, i.e., BDS examination, PG entrance, and MDS examination (Basic Sciences): It is the only book written that can be used to clear university graduation exams and postgraduate entrance exams and crack basic sciences exam for postgraduate students.

The earlier editions have been immensely popular among the dental students, postgraduate aspirants, and dental practitioners. Other highlights of the 12th edition are:

- Exam-oriented book with unique collection of solved question papers of the last 20 years.
- Extensively revised and updated chapters to provide knowledge of the present era.
- Questions and Answers related to COVID-19 from university papers are covered.
- In Pharmacology, the classification of drugs is mentioned separately at the end of the section.
- Various recent advances are updated as per their recent revision.
- Consists of solved multiple choice questions (MCQs) and fill in the blanks, which are added by the Dental Council of India (DCI) in the latest curriculum.
- Pharmacology, Pathology, Microbiology, and Dental Material are thoroughly revised. Various answers of previous editions have been changed in the latest edition due to change in various concepts and inculcation of new researches.
- Includes Viva-Voce questions with answers which aid students to enhance their skills in practical examinations.
- One-liners are added for quick revision of dental postgraduate entrance examinations such as NEET, PGI, AIIMS, etc.
- Contains illustrations and high-quality photographs with explanatory legends for easy explanation of text.
- Provides recent and internationally accepted classification systems by eminent professional bodies, WHO, CDC, National Health Programs/guidelines such as ICMR, NCDC, RNTCP, NACO, etc.
- Includes solved papers of year 2023 and December 2024, with better and improved answers.
- Explains questions in a point-wise manner for clear overview and eye-catching remembrance.
- Illustrates hematoxylin and eosin (H&E) stained histological photographs in color plates which help students to understand the Pathology section.
- The text, MCQs, and Fill in the Blanks aid students in preparation of Viva-Voce and provide basics for competitive examination.
- Incorporates a clinical overview in various chapters for highlighting the clinical applications.
- A highly structured, user-friendly, systemic, and attractive layout with enriched illustrations.

Most of the features of previous editions are saved

- Content is more but with less pages—Gives a handy look which saves the time of the student.
- Concise, bullet format, and to-the-point text which is easy to read during BDS and MDS basic sciences examination.
- Language is simple and lucid which makes the understanding easy.
- MCQs, fill in the blanks, viva-voce questions, additional matter and one liners are present at the end of each subject.

Hemant Gupta MDS (Oral and Maxillofacial Pathology, Microbiology and Forensic Odontology) has two decades of experience of authorship. He is the CEO of Shivom Multispeciality Dental Clinic, Indore, Madhya Pradesh, India. He is a general practitioner and also a consultant as oral cancer diagnostician at various clinics and hospitals. He is an eminent as well as dedicated clinician, practitioner, instructor, and consultant. He has also specialized in pathology techniques such as immunohistochemistry. He has published research papers in various indexed journals of national repute. He has experience of coaching dental students at a personal level, which helps them to build up the basics in dentistry and also to clear the various university examinations. His pioneer work in Forensic Odontology is on Ameloglyphics.

Dr Gupta has also authored several other popular books which are extremely appreciated among the BDS and MBBS students:

1. Mastering the BDS Ist Year
2. Mastering the BDS IIIrd Year
3. Mastering the BDS Final Year–Part I
4. Mastering the BDS Final Year–Part II
5. Mastering the MBBS Ist Year

Buy from ejaypee

JAYPEE BROTHERS

Shelving Recommendation
DENTISTRY

ISBN 978-93-6616-404-5

9 789366 164045