tal books, visit our website www.jaypeebrothers.com, for detailed information on dental books, visit our website www.jaypeebrothers.com, for detailed information on dental books

Available only with Genuine Book
Complimentary Online
18 Videos (2 hrs)

Textbook of
OPERATIVE DENTISTRY



Nisha Garg
Amit Garg

5th Edition

Foreword
Hyeon-Cheol Henry Kim

JAYPEE

Contents

1. **Introduction to Operative Dentistry 1**
Nisha Garg
- Introduction *1*
- Definitions *1*
- History *1*
- Indications of Operative Dentistry *1*
- Objectives/Purpose of Operative Dentistry *3*
- Scope of Operative Dentistry *3*
- Recent Advancements *3*

2. **Tooth Nomenclature 5**
Amit Garg
- Introduction *5*
- Stages of Tooth Evolution *5*
- Types of Dentition *5*
- Types of Dentition in Humans *6*
- Tooth Notation Systems *6*

3. **Structure of Teeth 11**
Amit Garg
- Introduction *11*
- Enamel *11*
- Dentin *14*
- Dental Pulp *17*
- Periradicular Tissue *18*

4. **Physiology of Tooth Form 21**
Amit Garg
- Introduction *21*
- Types of Teeth and their Functions *21*
- Functions of Teeth *21*
- Protective Functional form of the Teeth *22*

5. **Occlusion in Operative Dentistry 26**
Nisha Garg
- Introduction *26*
- Anterior-posterior Interarch Relationship *27*
- Interarch Tooth Relationships *27*
- Features of an Ideal Occlusion *28*
- Factors of Occlusion Affecting Operative Dentistry *28*
- Mandibular Movements *28*
- Occlusal Schemes *30*
- Significance of Occlusion in Operative Dentistry *31*
- Occlusal Interferences *32*
- Occlusion Indicators *33*
- Trauma from Occlusion *34*

6. **Instruments Used in Operative Dentistry 37**
Nisha Garg
- Introduction *37*
- History *37*
- Materials Used for Manufacturing Cutting Instruments *37*
- Heat Treatment of Materials *38*
- Classification *38*
- Nomenclature by GV Black *38*
- Parts of Hand Cutting Instruments *38*
- Balancing *39*
- Instrument Formula *39*
- Different Instrument Designs *40*
- Instrument Motions *41*
- Description of Various Instruments *41*
- Hand Cutting Instruments *43*
- Restorative Instruments *46*
- Instrument Grasps *47*
- Finger Rests *48*
- Guards *49*
- Methods of Use of Instruments *49*
- Sharpening of Hand Instruments *50*
- Rotary Cutting Instruments *51*
- Handpieces *51*
- Dental Burs *53*
- Factors Affecting Cutting Efficiency of Bur *57*
- Recent Advances in Rotary Instruments *59*
- Abrasive Instruments and Materials in Conservative Dentistry *60*
- Finishing and Polishing Instruments *62*
- Hazards and Precautions with Rotary Cutting Instruments *64*

7. **Dental Caries 66**
Nisha Garg
- Introduction *66*
- Definitions *66*
- Theories *66*
- Etiology of Dental Caries *67*
- Clinical Presentation of Dental Caries *70*
- Calcium Ion Migration in Carious Process *70*
- Histopathology of Dental Caries *71*
- Classification of Dental Caries *72*
- Diagnosis of Dental Caries *75*

- Recurrent Caries (Secondary Caries) *80*
- Root Caries *81*
- Caries Risk Assessment *82*
- Caries Activity Tests *83*
- Prevention of Dental Caries *83*
- Current Methods of Caries Prevention *88*
- Management of Dental Caries *89*

8. Principles of Tooth Preparation.....92
Nisha Garg
- Definition *92*
- Purpose of Tooth Preparation *92*
- Indications of Restorative Intervention *92*
- Objectives of Tooth Preparation *92*
- Terminology *92*
- Number of Line and Point Angles *94*
- Stages of Cavity Preparation *96*
- Initial Cavity Preparation Stage *97*
- Final Stages of Tooth Preparation *101*

9. Patient Evaluation, Diagnosis and Treatment Planning 104
Amit Garg
- Introduction *104*
- Patient Evaluation *104*
- Clinical Evaluation *105*
- Treatment Planning *107*
- Quadrant Dentistry *107*
- Treatment Record/Documentation *107*

10. Infection Control in Operative Dentistry.....109
Amit Garg
- Introduction *109*
- Rationale for Infection Control *109*
- Objective of Infection Control *110*
- Universal Precautions *110*
- Classification of Instruments *111*
- Instrument Processing Procedures/ Decontamination Cycle *112*
- Sterilization of Dental Handpiece *115*
- Disinfection *116*
- Sterilization of Dental Unit Waterlines *116*
- Infection Control Checklist *116*

11. Pain Management in Operative Dentistry.....119
Amit Garg
- Introduction *119*
- Definition *119*
- Method of Control of Pain in Restorative Dentistry *119*
- Pain Management Protocol *119*
- Recent Advances in Local Anesthesia *121*
- Other Methods of Pain Control *123*

12. Patient and Operator Position 124
Nisha Garg
- Introduction *124*
- Operating Stool *124*
- Considerations for Dentists while Treating Patients *124*
- Dental Chair Positions *125*
- Four Handed Dentistry *126*
- Zones of Working Area/Activity *126*
- Visibility *127*
- Loupes *128*
- Surgical Operating Microscope *129*
- Endoscope *130*
- Orascope *130*
- Role of Magnification in Conservative Dentistry *130*

13. Isolation of Operating Field.....132
Nisha Garg
- Introduction *132*
- Components of Oral Environment Need to be Controlled During Operative Procedures *132*
- Methods of Moisture Control *132*
- Isolation with Rubber Dam *133*
- Pharmacological Means *142*
- Gingival Tissue Management *143*

14. Gingival Tissue Management.....144
Nisha Garg, Amit Garg
- Introduction *144*
- Definition *144*
- Indications of Gingival Tissue Management *144*
- Contraindications of Gingival Tissue Management *144*
- Advantages *144*
- Methods of Gingival Tissue Management *144*

15. Matricing 151
Nisha Garg
- Introduction *151*
- Matricing *151*
- Parts of Matrix *152*
- Functions of a Matrix *152*
- Ideal Requirements of a Matrix *152*
- Classification *152*
- Ivory Matrix Holder (Retainer) No. 1 *152*
- Tofflemire Universal Matrix Band Retainer *153*
- Ivory Matrix Band Retainer No. 8 *153*
- Steele's Siqveland Self-adjusting Matrix Holder for Tapering Teeth *156*
- Compound Supported Matrix *156*
- T-Shaped Matrix Band *157*
- S-Shaped Matrix Band *157*
- Aluminum or Copper Collar/Band *158*
- Transparent Crown Forms Matrices *159*

- Window Matrix 159
- Anatomic Matrix 159
- Clear Plastic Matrix Strips 159
- Aluminum Foil Incisor Corner Matrix 160
- Preformed Transparent Cervical Matrix 160
- Matrix Retainerless System 160
- Recent Advances in Matrix Systems for Class II Composite Restorations 161
- Sectional Matrices and Contact Rings 162
- Anterior Matrix Systems for Composite Restorations 164

16. Separation of Teeth.....167
Nisha Garg
- Introduction 167
- Reason for Tooth Separation 167
- Methods of Tooth Separation 167
- Rapid or Immediate Tooth Separation 167
- Slow or Delayed Separation 171

17. Pulp Protection 173
Nisha Garg 173
- Introduction 173
- Pulpal Irritants 173
- Effect of Caries on Dental Pulp 173
- Effect of Tooth Preparation on Dental Pulp 174
- Importance of Remaining Dentin Thickness 174
- Need for Pulp Protection 174
- Materials Used for Pulp Protection 175
- Cavity Sealers 175
- Cavity Liners 176
- Base 176
- Guidelines of Using Liners, Bases, and Varnishes for Different Restorative Materials 176
- Management of Shallow, Moderate, and Deep Caries 176
- Management of Deep Carious Lesion 177
- Prevention of Pulpal Damage Due to Operative Procedure 180

18. Interim Restorations 183
Nisha Garg
- Introduction 183
- Objectives of Interim Restorations 183
- Requirements of Interim Restoration 183
- Purposes of Interim Restoration 183
- Materials 184
- For Intracoronal Preparations 184
- For Extracoronal Preparations 188

19. Adhesion in Operative Dentistry.....190
Nisha Garg
- Introduction 190
- Indications for Use of Adhesives 190
- Advantages of Adhesives 190
- History 190
- Definitions 191
- Enamel Bonding 192
- Dentin Bonding 194
- Dentin Adhesive Systems 195
- Evolution of Dentin-bonding Agents 196
- Hybridization 200
- Smear Layer 200
- Classification of Modern Adhesives 201
- Glass Ionomer-based Adhesive System 202
- Failure of Dentin Bonding 202

20. Composite Restorations.....205
Nisha Garg
- Introduction 205
- Definition 205
- History 206
- Composition of Dental Composites 206
- Classification of Composites 208
- Types of Composites 209
- Recent Advances in Composites 210
- Properties of Composite 213
- Degree of Conversion in Composites 215
- Steps of Clinical Procedure for Composite Restoration 217
- Tooth Preparations for Anterior Composite Restorations 223
- Tooth Preparation for Posterior Composite Restoration 226
- Stamp Technique of Restoration 234
- Failures of Composite Restorations 234
- Repair of Composite Restorations 238

21. Indirect Aesthetic Restorations.....240
Nisha Garg
- Introduction 240
- Indirect Resin Composite 240
- Classification of Indirect Composites 241
- Dental Ceramics 242
- Veneers 244
- Recent Advances in Dental Veneers 246
- Indirect Composite Inlays and Onlays 246
- Etched Posterior Porcelain Restorations 246
- Tooth Preparation for Indirect Composite Inlays and Onlays 247
- All-ceramic Crowns 249
- Techniques Used for Fabrication of Ceramic Restorations 251
- Repair of Veneers 252

22. Smile Designing in Operative Dentistry.....254
Nisha Garg
- Introduction 254
- Elements of Dental Aesthetics 254
- Facial Composition 254

- Dental Composition 256
- Hard Tissue Components of Smile Design 256
- Soft Tissue Component of Smile Design 261
- Aesthetics and Operative Dentistry 262
- Veneers 265

23. Glass Ionomer Cements.....269
Nisha Garg

- Introduction 269
- Classification of Glass Ionomer Cements 269
- History 269
- Composition 270
- Recent Advances in GIC 271
- Setting Reaction of Glass Ionomer Cement 272
- Properties of Glass Ionomer Cements 273
- Advantages of Glass Ionomer Cements 275
- Disadvantages of Glass Ionomer Cements 276
- Indications of Glass Ionomer Cement 276
- Contraindications of Glass Ionomer Cements 276
- Clinical Steps for Placement 277
- Atraumatic Restorative Treatment 279
- Sandwich Technique 279
- Tunnel Preparation 280

24. Minimally Intervention Dentistry 283
Nisha Garg

- Introduction 283
- Definition 283
- Principles of Minimal Intervention 283
- Early Diagnosis 283
- Caries Classification Based on Site and Size of Lesion Given by Mount and Hume 284
- Assessment of Caries Risk 284
- Decreasing the Risk of Further Demineralization and Arresting Active Lesion 285
- Remineralization of Initial Lesions and Reduction in Cariogenic Bacteria 285
- Different Remineralizing Agents 285
- Minimal Intervention of Cavitated Lesions 288
- Repair Instead of Replacement of the Restoration 290
- Disease Control 290

25. Noncarious Lesions of Teeth 292
Neetu Jindal, Nisha Garg

- Introduction 292
- Attrition 292
- Abrasion 293
- Erosion 294
- Abfraction 294
- Localized Nonhereditary Enamel Hypoplasia 295
- Localized Nonhereditary Enamel Hypocalcification 296
- Localized Nonhereditary Dentin Hypoplasia 296
- Localized Nonhereditary Dentin Hypocalcification 296
- Amelogenesis Imperfecta 296
- Dentinogenesis Imperfecta 296

26. Dentin Hypersensitivity.....299
Amit Garg, Neetu Jindal

- Introduction 299
- Definition 299
- Historic Review 299
- Theories of Dentin Hypersensitivity 299
- Incidence and Distribution 300
- Etiology and Predisposing Factors 300
- Differential Diagnosis 300
- Diagnosis 301
- Treatment 301
- Ideal Properties of a Desensitizing Agent 302
- Classification of Desensitizing Agents 302
- Recent Trends to Treat Dentin Hypersensitivity 303

27. Tooth Whitening.....305
Nisha Garg

- Introduction 305
- Classification of Discoloration 305
- Bleaching 307
- Bleaching Agents 307
- Mechanism of Bleaching 307
- Bleaching of Vital Teeth 307
- Vital Bleaching Techniques 308
- Bleaching of Nonvital Teeth 310
- Effects of Bleaching Agents on Tooth and its Supporting Structures 311

28. Amalgam Restorations 314
Nisha Garg

- Introduction 314
- Definitions 314
- History of Dental Amalgam 314
- Classification 315
- Composition 315
- Types 317
- Setting Reaction/Amalgamation Reaction 317
- Physical Properties 318
- Indications of Silver Amalgam 320
- Contraindications 320
- Advantages 320
- Disadvantages 320
- Recent Advances in Silver Amalgam 321
- Class I Cavity Preparation for Silver Amalgam 323
- Class II Cavity Preparation for Amalgam Restoration 325

- Class III Cavity Preparation for Amalgam Restoration *331*
- Class V Cavity Preparation *331*
- Class VI Cavity Preparation for Amalgam Restoration *332*
- Steps for Amalgam Restoration *332*
- Life of Amalgam Restorations *335*
- Failures of Amalgam Restoration *335*
- Reasons for Failure of Amalgam Restorations *337*
- Mercury Hygiene *339*
- Is Dental Amalgam Safe? *341*
- Amalgam Wars *341*
- Phase Down of Amalgam *341*

29. Pin-retained Restorations.....345
Nisha Garg
- Introduction *345*
- Definition *345*
- Advantages *345*
- Disadvantages *345*
- Indications *345*
- Contraindications *346*
- Types of Pins *346*
- Indirect Pins/Parallel Pins *346*
- Direct Pins/Nonparallel Pins *346*
- Types of Direct Pins *346*
- Principles and Techniques of Pin Placement *349*
- Factors Affecting Retention of Pins in Dentin and Amalgam *351*
- Pins and Stresses *352*
- Complications of Pin-retained Restorations *352*
- Other Means of Retention in Complex Amalgam Restorations *354*

30. Direct Filling Gold.....357
Nisha Garg
- Introduction *357*
- Properties of Gold *357*
- Advantages of Direct Filling Gold Restorations *357*
- Disadvantages of Direct Filling Restoration *358*
- Indications of Direct Filling Gold Restoration *358*
- Contraindications *358*
- Types of Gold *359*
- Storage of Gold *361*
- Degassing/Annealing *361*
- Principles of Tooth Preparations *362*
- Class I Tooth Preparation *362*
- Class II Tooth Preparation *362*
- Class III Tooth Preparation *362*
- Class V Tooth Preparation *364*
- Compaction of Direct Filling Gold *365*
- Steps of Direct Filling Gold Restoration *366*
- Future of Gold in Dentistry *366*

31. Cast Metal Restorations.....368
Nisha Garg
- Introduction *368*
- Components of Cast Gold Alloys *368*
- Classification of Cast Gold Alloys *369*
- Properties of Cast Gold Alloys *369*
- Definitions *370*
- Indications for Class II Gold Inlays *370*
- Contraindications *370*
- Advantages *370*
- Disadvantages *371*
- Basic Design of Cast Metal Inlay *371*
- Cavity Preparation for Class II Cast Metal Inlays *375*
- Modifications In Class II *377*
- Cast Metal Onlay *378*
- Technique of Making Cast Metal Restoration *380*
- Casting Defects *387*
- Pin-retained Cast Restorations *391*

32. Artificial Intelligence in Operative Dentistry.....394
Nisha Garg, Rajinder Bansal
- Introduction *394*
- History of Artificial Intelligence (AI) *394*
- Classification of Artificial Intelligence *395*
- Working of Artificial Intelligence *395*
- Applications of Artificial Intelligence in Conservative Dentistry *398*
- Role of Artificial Intelligence in Endodontics *398*

33. Evidence-based Dentistry.....400
Amit Garg
- Introduction *400*
- What is Evidence-based Dentistry? *400*
- Definition of Evidence-based Dentistry *401*
- Need of Evidence-based Dentistry *401*
- Steps of Evidence-based Dentistry *401*
- Application of Evidence-based Dentistry from Research Clinical Practice *402*
- Who Get Benefits from Evidence-based Dentistry? *402*

34. Nanotechnology in Dentistry.....404
Amit Garg
- Introduction *404*
- History *404*
- Definitions *404*
- Approaches in Nanotechnology *404*
- Nanotechnology in Dentistry *404*

- Applications of Nanotechnology in Dentistry *405*
- Barriers for Nanotechnology *407*

35. Lasers in Operative Dentistry.....409
Amit Garg

- Introduction *409*
- History *409*
- Classification of Laser *409*
- Principles of Laser Beam *410*
- Laser Physics *410*
- Laser Interaction with Biological Tissues *412*
- Laser Safety in Dental Practice *412*
- Applications of Lasers in Operative Dentistry *413*
- Advantages and Disadvantages of Lasers *415*

Annexures.....417

Annexure 1: Mechanical Properties of Different Restorative Materials *417*

- Compressive Stress *417*
- Tensile Stress *417*
- Shear Stress *417*
- Flexural (Bending) Stress *417*
- Elastic Modulus (Young's Modulus) *417*
- Impact Strength *418*
- Toughness *418*
- Hardness *418*
- Thermal Conductivity *418*
- Thermal Coefficient of Expansion *418*

Annexure 2: Case Record Sheet: Department of Conservative Dentistry and Endodontics *419*

Index *423*

CHAPTER 21

Indirect Aesthetic Restorations

Nisha Garg

Chapter Outline

- Introduction
- Indirect Resin Composite
- Classification of Indirect Composites
- Dental Ceramics
- Veneers
- Recent Advances in Dental Veneers
- Indirect Composite Inlays and Onlays
- Etched Posterior Porcelain Restorations
- Tooth Preparation for Indirect Composite Inlays and Onlays
- All-ceramic Crowns
- Techniques Used for Fabrication of Ceramic Restorations
- Repair of Veneers

INTRODUCTION

Aesthetic appeal plays a pivotal role in contemporary dentistry. An esthetic restorative material should mimic the natural tooth in terms of color, translucence, and texture while possessing sufficient strength and wear resistance, color stability, marginal adaptation, insolubility, durability and biocompatibility.

Though many materials are available for aesthetic restoration, the ***ideal restorative material should meet following requirements***:

i. Allow conservative tooth preparation.
ii. Restore the tooth's normal shape and function.
iii. Ensure optimal sealing and adaptability with tooth structure.
iv. Biocompatible.
v. Durable.

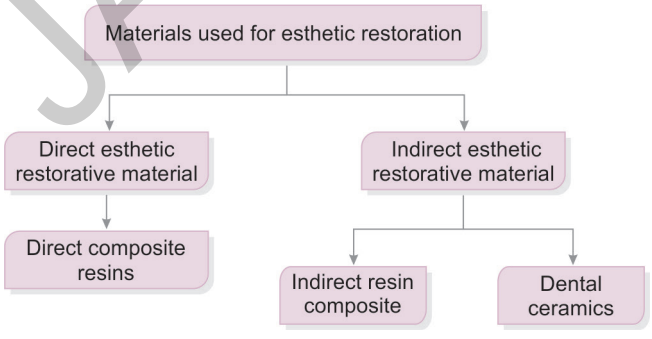

INDIRECT RESIN COMPOSITE

Dental resin composites were introduced initially as anterior restorative materials. Later, with developments of newer techniques, material modifications and nanotechnology, direct composite restorations became material of choice for posterior teeth as well. Newest direct composite resins have excellent optical and mechanical properties, and their use in larger posterior restorations is still a question due to problems associated with them, which led to development of indirect resin composite restorations.

Indirect composites are also referred as ***prosthetic composites or laboratory composites.*** Following shortcomings of direct resin composites lead to need of indirect resin composite restorations:

1. ***Incomplete polymerization:*** Degree of conversion in direct composites is 55–65% which can lead to polymerization shrinkage.
2. ***Polymerization shrinkage:*** It can cause gap formation between tooth and restoration interface resulting in microleakage, discoloration, and secondary caries, etc.
3. ***Depth of cure:*** It is difficult to cure direct composite if depth of cure is greater than 4 mm.
4. ***Inability to achieve optimal contacts and contours***
5. ***Excessive wear*** in stress-bearing areas.

JAYPEE BROTHERS

CLASSIFICATION OF INDIRECT COMPOSITES

1. Classification Based on Method of Fabrication

i. Direct-indirect/Semi-indirect Method

In this, after making preparation, a suitable separating media and matrix system is applied on the tooth for easy removal of the inlay after the initial intraoral curing. The composite material is condensed into the cavity. The restoration is then exposed to extraoral light or heat tempering in an oven (for example, DI-500 Oven from Coltene Whaledent at 110°C for 7 minutes).

ii. Indirect

In this, after the separating medium is applied to the die, composite material is packed in increments into the cavity and light cured for 40 seconds for each surface. Restoration is then removed and heat cured in an oven at 100°C for 15 minutes. Examples of indirect materials are ®t®SR-Isosit®, Clearfil CR Inlay®, Conquest®, Dentacolor®, and ®Visio-Gem®.

2. Classification Based on Method of Curing

i. Conventional Cured

In this technique, curing is done on a die of prepared tooth by the use of one method only, for example, light curing.

ii. Secondary Cured

In this technique, curing is done in two cycles. Initial curing is done at room temperature using light followed by additional curing using heat and light.

iii. Superficial Cured

In this technique, curing is done in one step only. Curing is done under very high temperature and pressure in one stage rather than light cure.

3. Classification Based on Evolution

i. First Generation

First generation of indirect restorations was composite based, introduced in early 1980. These materials were developed in an attempt to overcome polymerization shrinkage and wear seen with direct composite restorations. But these also had poor physical properties because of low filler and high matrix load. They include SR-Isosit system, Coltene and Kulzer system.

Advantages	*Disadvantages*
• Improved aesthetics • Improved anatomy and interproximal contact • Chair side repair • Ease of fabrication	• Low modulus of elasticity • Low wear resistance • Low flexural strength • Fracture of restoration and debonding because of poor bonding between restoration and cement

ii. Second Generation

They were introduced in mid 1990s to overcome the disadvantage of first-generation indirect restorations. Here, improvements were done in structure and composition, polymerization technique, and fiber reinforcement.

Structure and composition: The second-generation composites have "microhybrid" filler which is twice that of the organic matrix. This increase in filler load improved both mechanical properties and wear resistance, and reduced polymerization shrinkage. For example, are Artglass®, BelleGlass HP®, and Solidex®.

Polymerization techniques: Even extraoral curing did not result in optimum polymerization; therefore following special conditions like heat, vacuum, pressure, and oxygen-free environment are employed for polymerization of 2nd-generation indirect composites:

i. **Heat polymerization:** In this, temperature of 120–140°C is used for polymerization. This temperature is above the composite's glass transition temperature (Tg) which increases the polymer chain mobility, and thus additional cross-linking. Postcure heating of composite decreases amount of unreacted monomer after initial light curing by bonding of residual monomer to polymer network resulting in more polymerization and evaporation of unreacted monomers during heating process. Example of this type is Charisma®.

ii. **Nitrogen atmosphere:** Oxygen present in air tends to inhibit polymerization. Nitrogen atmosphere removes internal oxygen before composite begins to polymerize. This causes improved polymerization, aesthetics, wear resistance, and abrasion. For example, of composites cured by this method are BelleGlass sHP® and Sculpture Plus.

iii. **Soft start or slow curing:** In this, composite is cured at slower rate for better polymerization and to reduce P®®residual stresses. BelleGlass HP® and Cristobal® are cured by this method.

iv. **Electron beam irradiation**: In this method, polymers like polyethylene, polycarbonate, or polysulfone are subjected to electron beam irradiation. This result in chain breakage and chain linkage reactions causing dense packing and thus improving the mechanical properties.

v. **Fiber reinforcement**: Smith introduced fiber-reinforced composites in 1960s. Fibers stop the crack propagation and improve the properties of composites. The fibers can run in one direction (unidirectional) or parallel to each other/or in mesh-type architecture **(Fig. 21.1)**. Fiber reinforcement improves flexural strength, modulus of elasticity and fracture toughness, and decreases polymerization shrinkage of resin composites.

JAYPEE BROTHERS

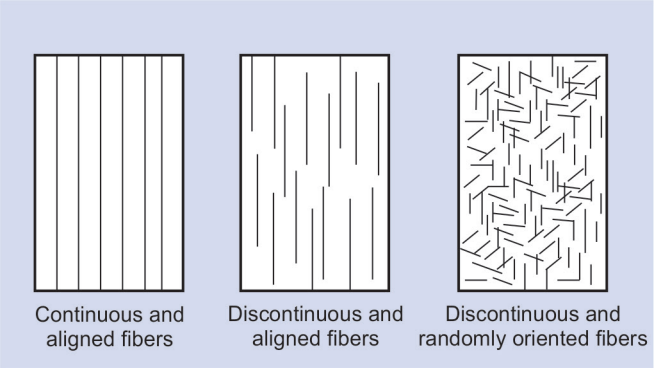

Fig. 21.1: Orientation of fibers in fiber-reinforced composites.

DENTAL CERAMICS

Ceramics include a variety of materials, from earthenware to porcelain, all made from feldspar, quartz, and clay. The differences between them lie in the proportions of these components and the firing methods used.

Dental ceramics are inorganic compounds with nonmetallic characteristics, typically made up of oxygen and one or more metallic or semi-metallic elements. They are specifically designed to create all or part of ceramic-based dental prostheses. These materials are known for being hard, rigid, and brittle, a result of their ionic and covalent interatomic bonding.

Second-generation indirect resin composites.

Sl. No.	*Name*	*Composition*	*Polymerization*	*Clinical significance*
1.	Artglass® (1995 by Kulzer)	• Filler 70% (barium silicate of 0.7 µ size) • Matrix 30% (organic resin)	Photocured in special unit using xenon stroboscopic light emitting high intensity for 20 milliseconds followed by darkness for 80 milliseconds. This nonexposure time allows cured composite to relax and make availability of carbon groups for reaction	Used for fabrication of inlays, onlays, veneers, and crowns
2.	Targis (1996 by Ivoclar Vivadent)	Filler 77% (barium glass particles of 1 µ size), spheroid silica (–0.25 µ), and colloidal silica (–0.015 to –0.05 µ)	Targis is coated with glycerin gel to prevent formation of oxygen inhibited surface layer and placed in curing unit with cycle as: Light emission for first 10 minutes, with increase of temperature to 95% for 25 minutes, and then cooling for 5 minutes	Targis is used to fabricate inlays, onlays, veneers, and anterior crowns
3.	BelleGlass HP® (1996 by Belle de St. Claire)	• Base and surface composites – Base composite has filler 78% (barium glass fillers of 0.6 µ size) – Surface composite has 75% filler (borosilicate) • Resin matrix of dentin has bis-GMA • Resin matrix of enamel is a combination of hydrocarbon saturated methacrylate diurethane of TEGDMA and dimethacrylate	Base composite is placed and cured with conventional light cure. Surface composite is heat cured in oven at 140°C at 80 psi for 20 minutes under nitrogen gas pressure	Small filler size offers good polishability and smoothness
4.	Sculpture Plus® by Pentron	• Filler silanated barium borosilicate glass, zirconia silicate, nanoparticulated silica • Matrix-difunctional methacrylates of GMA, Bis-GMA, UDMA, and HDDMA	Sculpture curing light is automatic light curing under pressure in nitrogen atmosphere. Two curing cycles are buildup cycle and final cycle when restoration is done	Restoration is fluorescent, color stable with high flexural strength
5.	Solidex® (Introduced by Shofu)	• Filler 53% (silicon dioxide and aluminum oxide and ceramic microfilaments) • Matrix 25% (multifunctional resin) • 22% conventional resin	Additional polymerization is done in solidite system with 4 halogen lamps for fast curing in 1–5 minutes	—

Contd…

JAYPEE BROTHERS

Contd…

Sl. No.	Name	Composition	Polymerization	Clinical significance
6.	Paradigm MZ 100 by 3 M ESPE	• Filler 85% ultrafine zirconia silica ceramic particles • Matrix consists of Bis-GMA and TEGDMA and tertiary initiator system	Made from Z100 resin under optimum process conditions so as to have optimum polymerization. Paradigm MZ100 blocks are made in cylindrical sizes equal to CEREC sizes	Substitute for CEREC restorations. Ultrafine zirconia silica filler offers optimum properties
7.	Vita Zeta® LC by Vita Zahnfabrik	• Filler 45% Feldspar frits and silicon dioxide • Matrix—Bis-GMA, TEGDMA, and UDMA	Additional light curing done at 40°C at wavelength of 350–500 nm	Used for veneers and crowns
8.	Gradia® (GC Corporation)	• Filler—silica powder, silicate glass powder, prepolymerized filler (75%) • Matrix—UDMA	Secondary light cure with alpha II for 5 minutes	—
9.	Estenia C and B (Kuraray)	• Filler—alumina ultrafine filler, glass filler 92% • Matrix—UDMA	Secondary light cure with alpha II for 5 minutes Secondary heat cure—KL 100 at 110°C for 15 minutes	—

Differences between direct and indirect resin composites.

Properties	Direct resin composite	Indirect resin composite
Polymerization shrinkage	More	Less
Microleakage around margins	More	Less
Residual stresses after curing	More	Less
Wear resistance	Less	More
Color stability	Less	More
Reproduction of contacts and contours	Difficult	Can be achieved
Tensile strength	70–80 N/mm^2	90–120 N/mm^2
Modulus of elasticity	4,000–5,500 N/mm^2	7,000–10,000 N/mm^2
Vickers hardness number	360–410 N/mm^2	500–600 N/mm^2

Indirect composite restorations have following advantages when compared to porcelain restorations:

- They are less brittle due to lower elastic moduli.
- They are simple to adjust, polish and repair in mouth.
- Their flexibility reduces stress on the underlying tooth structure.
- They are more cost-effective, and less likely to wear down opposing teeth compared to porcelain.

Indications

1. Aesthetic alternative for discolored, chopped, crooked teeth.
2. To restore traumatic fracture of incisal angles or cusps of teeth.
3. For aesthetic veneers, inlays, onlays or crowns.
4. As abutment retainers.

At a microstructural level, ceramics can be divided into four types:

1. Glass-based systems (mainly silica)
2. Glass-based systems with fillers (leucite or, lithium disilicate)
3. Crystalline-based systems with glass fillers (mainly alumina)
4. Polycrystalline solids (alumina and zirconia).

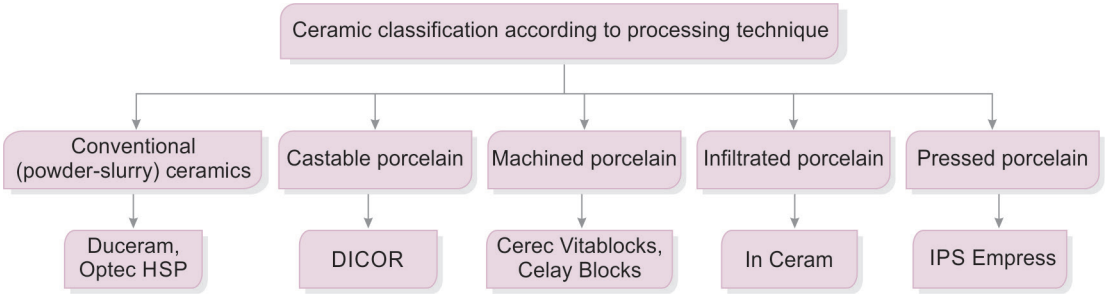

JAYPEE BROTHERS

VENEERS

Veneers can be classified according to material, preparation technique, application, and permanence.

- ***Based on materials***, they can be porcelain veneers and composite veneers.
- ***Based on preparation technique*** there are traditional veneers, which require tooth preparation, and no-prep veneers, which require minimal to no removal of tooth structure.
- ***Based on applications,*** there are direct veneers, made of composite resin and placed directly to the teeth in the clinic, and indirect veneers, fabricated in a dental laboratory from porcelain or composite.

I. Indirect Composite Veneers

Composite veneers can be processed in a laboratory to have improved physical and mechanical properties compared to traditional chairside composites. These can be produced using intense light, heat, vacuum, pressure, or a combination of these. Moreover, indirectly fabricated composite veneers offer superior shading and characterizing potentials as well as better control of facial contours.

Advantages	*Disadvantages*
Superior physical and mechanical properties	Limited bonding, so surface conditioning or sandblasting is required
Easy to finish and polish	Multiple large restorations compromise bonding
Can be easily repaired	
Given in cases which show attrition of anterior teeth	

Procedure

1st appointment:

1. Clean the tooth, select the shade of composite resin while the teeth are wet with saliva.
2. Prepare anterior teeth by removing small amounts of enamel with a medium grit flame or chamfer bur. If only minimal preparation is necessary to improve alignment and increase facial contour, remove only 0.25–0.50 mm of enamel from the facial area and none from the incisal area. If incisal reduction is necessary, remove 1–1.5 mm.
3. Make a full arch impression using vinyl polysiloxane impression material.
4. Place a provisional restoration if needed.

2nd appointment:

1. Check the fit of the veneer.
2. Since processed composites have less potential to form chemical bond with bonding medium, thus additional micromechanical features are added by surface conditioning or sandblasting.
3. Acid etch the palatal surface of veneer with 10% hydrofluoric acid gel for 30 seconds or lightly sandblast with a micro etchant or air abrasion and rinse thoroughly.
4. Clean the teeth with prophylaxis cup, rinse, and dry.
5. Etch the enamel using 37% phosphoric acid for 15 seconds to remove the smear layer and rinse thoroughly. Leave the tooth surface slightly moist for wet bonding.
6. Apply silane coupling agent to the internal surface of the veneers and air dry.
7. Coat a layer of hydrophilic primer and bonding agent and until the surface appears glossy without being wet. This shows that "hybrid" layer has been formed in the dentin and enamel is thoroughly coated with the resin in the primer.
8. Apply a thin layer of bonding resin onto the internal surface of the veneers.
9. Apply luting composite resin to the internal surface of veneers. Place the veneer on the prepared tooth and remove excess luting composite resin, and then light cure for 40 seconds on the facial and lingual surfaces of the tooth.
10. Remove excess composite resin with a No. 12 surgical blade or a scaler and finish the margins with 12- and 30-fluted carbide finishing burs, fine diamonds, rubber polishing cups, and finishing disks.

II. Porcelain Veneers

Porcelain is one of the most esthetic and biocompatible material available for dental restorations.

Indications (Fig. 21.2)

1. To improve discolorations like tetracycline stains, fluorosis, and devitalized teeth, etc.
2. Repair of chipped/fractured teeth
3. To close diastema between teeth
4. To correct malformations of anterior teeth like peg laterals
5. To improve aesthetics of anterior teeth
6. To lengthen anterior teeth
7. To correct enamel hypoplasia and hypocalcifications.

Contraindications

1. Inadequate enamel for bonding
2. In patients with bruxism and abnormal oral habits
3. Poor quality enamel available for bonding.

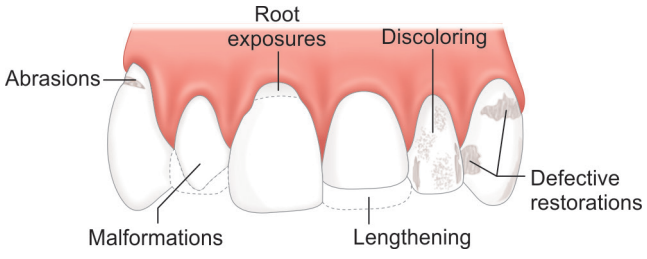

Fig. 21.2: Indications for porcelain laminate veneers.

JAYPEE BROTHERS

4. Severe crowding of teeth
5. Expensive
6. Deciduous teeth.

Advantages	*Disadvantages*
Excellent aesthetics and color matching	Fragile and brittle in nature
Chemically inert, so resistant to fluid absorption	Difficult to repair or modify after cementation
Biocompatible in nature	More expensive than amalgam or composite
Good abrasion resistance	Need special and expensive laboratory equipment
Durable, retain surface luster	Highly technique sensitive and need precise tooth preparation

Clinical Technique for Ceramic Veneer

It is performed in two appointments:

1st Appointment

1. **Tooth preparation:** Tooth preparation for porcelain veneer has following aspects:
   - **Labial reduction**:
     - Thickness of ceramic laminate ceramic veneer should be 0.5 mm, so, uniform reduction of 0.3–0.5 mm labial reduction should be carried out. For this, place depth grooves on enamel surface using depth cutting diamond.
     - Using tapered bur, reduce the facial enamel surface to the depth of the groove. Take care to limit the reduction within the enamel and it should follow the contour of the tooth.
   - **Interproximal reduction:** It is done by using tapered diamond extending interproximal margins halfway into contact areas. It is best if proximal finishing margins for the preparation do not extend beyond the contact point in the incisal third of the tooth.
   - **Incisal modification**: There are four types of incisal preparation designs **(Figs. 21.3A to D)**:
     a. **Window preparation/feathered incisal edge:** In this veneer is taken close to but not up to incisal edge. This has advantage of retaining natural enamel over incisal edge but has disadvantage of weakening of incisal edge.
     b. **Incisal bevel**: In this, buccopalatal bevel is prepared across full width of the preparation and there is some reduction of incisal length of the tooth. This gives better control over incisal aesthetics and positive seating of veneer.
     c. **Incisal lingual wrap preparation**: In this, prepare 0.5 mm depth cut grooves in incisal edge and then reduce the incisal tooth structure using tapered diamond. Then reduce mesioincisal and disto-incisal corners an additional 0.5 mm. then extend the incisal chamfer to palatal surface. Lingual chamfer line should avoid occlusal contact on interface of porcelain and tooth structure. Contact should either be all on ceramic or on tooth structure.
     d. **Incisal butt joint preparation**: In this, prepare 0.5 mm depth cut grooves in incisal edge and then reduce the incisal tooth structure using tapered diamond. Then round the facial incisal line.
   - **Cervical definition:** Place chamfer or beveled shoulder gingival finish line in enamel so as to have strongest bond to enamel.
2. **Impression**: If possible leave retraction cord in place during impression. Use polysiloxane or polyether material for impression because multiple pours are needed for laboratory procedures. To minimize tearing of impression in lingual areas, place soft wax in these areas.
3. **Provisional veneer**: These are made by composites, kept supragingival, out of occlusion and bonded by spot etching and bonding.

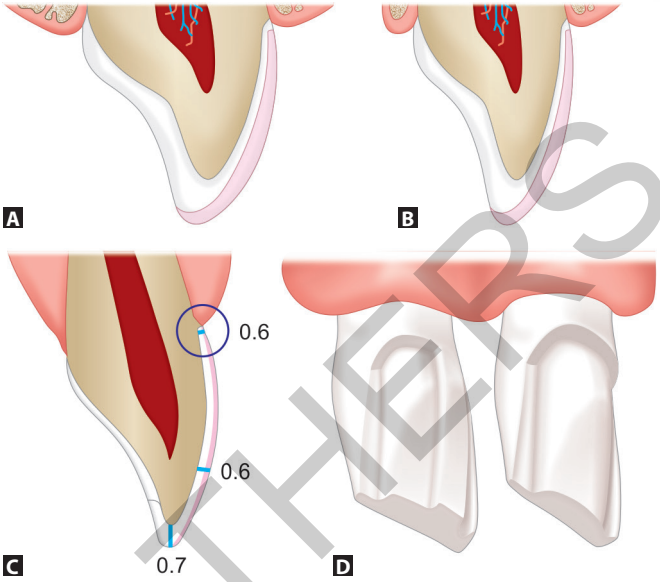

Figs. 21.3A to D: Incisal modifications for ceramic veneer. (A) Window preparation; (B) Incisal bevel; (C) Incisal lingual wrap preparation; (D) Incisal butt joint preparation.

2nd Appointment

1. **Try-in of veneers:** Place the veneers on color-contrast surfaces, inspect the veneer for any cracks and imperfections on the model to have an appropriate fit. Then, remove the provisional using hemostat, clean the tooth to obtain a smooth surface.
   Moisten the teeth and the internal surface of veneers with water, and place the veneers on tooth to check fit and color.
2. **Bonding procedure:** Bonding a veneer to the tooth surface is done by using adhesive techniques. These techniques include chemical bonding, like light-activated composite cements and coupling agents,

JAYPEE BROTHERS

micromechanical bonding, like acid etching, and combination of both.

Luting cements used here can be classified into two subtypes: cements associated with conventional or self-etching adhesives, and self-adhesive cements, which do not require any prior conditioning of the tooth structure.

Preparation of Tooth to Receive Veneer

1. Apply rubber dam for isolation and clean all tooth surfaces with rubber cup and pumice/water mix and rinse thoroughly.
2. Place mylar strip between adjacent teeth to minimize etching and placement of adhesive on adjacent teeth. In case of multiple teeth, place two veneers at a time, the usual sequence is both central first, then lateral and canine on one side and finally lateral and canine on opposite side.
3. Etch the prepared tooth surface using 37% phosphoric acid for 15–20 seconds rinse and dry it.
6. Apply two thin coats of bonding agent, air thin it and then light cure.

Preparation of Veneer

1. Etch the internal surface of veneer with 10% hydrofluoric acid for 90 seconds rinse and dry it.
2. Apply silane coupling agent on etched surface of veneer and allow it to set for 60 seconds. Do not rinse it. Place it in light proof box until ready to cement on tooth.

Seating of Restoration

1. Apply luting resin on to the prepared tooth and fitting surface of veneer and seat the veneer with firm finger pressure and hold in place while extra cement is removed.
2. Color stability of light curing resins is better than dual cure or self-cure resins. Dual cure resins contain tertiary amines which may undergo long-term color change with overall darkening, thus contraindicated with veneers due to their thin and translucent nature.
3. Light cure the resin cement for at least 60 seconds from facial, lingual and incisal surfaces.
4. Remove small excess of set bonding material using sharp carver. Finish margins of restoration and polish using rubber cup/silicon cusp disc and diamond polishing paste.

Figures 21.4 and 21.5 show management of diastema and malpositioned teeth with ceramic veneers.

RECENT ADVANCES IN DENTAL VENEERS

1. **e.max veneers:** Lithium disilicate, (first introduced in 1988) has evolved from a heat-pressed core material known as IPS Empress 2 to IPS e.max CAD, which was developed in 2006. In partially crystallized form, e.max CAD consists of 40% lithium metasilicate crystals, and in fully crystallized form, it consists of 70% fine-grain lithium disilicate crystals.
2. **Lumineers:** Lumineers consist of a thin shell-like porcelain material, custom-made for patients, and applied to the tooth surface with the help of a permanent bonding agent.
3. **Durathin veneers:** Durathin veneers are 0.3 mm thin, whereas traditional veneers have a thickness of approximately 0.5 mm.
4. **MAC veneers:** Micro advanced cosmetic (MAC) division veneers are made from pressed ceramics. These veneers are sturdier and thicker (0.8–1 mm) than conventional porcelain veneers.
5. **Edelweiss veneers:** Edelweiss veneer was the first of the "new generation" of prefabricated veneers. These veneers can be bonded to the tooth structure like a direct composite restoration, without the need for sandblasting, acid etching, or silane application.
6. **Componeers:** Componeer (Coltene, Altstätten, Switzerland) are thin, prefabricated, composite resin shells, measuring 0.3 mm cervically and 0.6–1.0 mm at the incisal edge. These are made from a prepolymerized hybrid composite resin called synergy D6 (Coltene). They can be bonded by using the same hybrid composite resin from which they are made, thus creating a monobloc for the restoration.

INDIRECT COMPOSITE INLAYS AND ONLAYS

Indirect composite inlay/onlay are indicated when there are esthetic and structural considerations, abrasion considerations, supragingival margins, and chairside repairs are needed.

Advantages of indirect composite inlays/onlays over direct resins restorations:

1. With indirect technique, one can achieve optimal contact, contour and control the cervical adaption of the restoration.
2. By processing and shaping of the composite in the laboratory, better material properties like density, wear resistance and water absorption are achieved.
3. Better sealed margins are achieved resulting in less microleakage, less chances of secondary caries and color changes than direct composites.

Disadvantages Compared to Ceramic Inlays

1. Lower wear resistance
2. Not suited for patient with high occlusal stresses.

ETCHED POSTERIOR PORCELAIN RESTORATIONS

Indications

Etched porcelain inlays are indicated when aesthetics, strength and conservative treatments are indicated like:

1. Small to moderate carious lesions.
2. Large amalgam or composite restorations involving proximal surfaces showing discoloration or compromised contacts.

JAYPEE BROTHERS

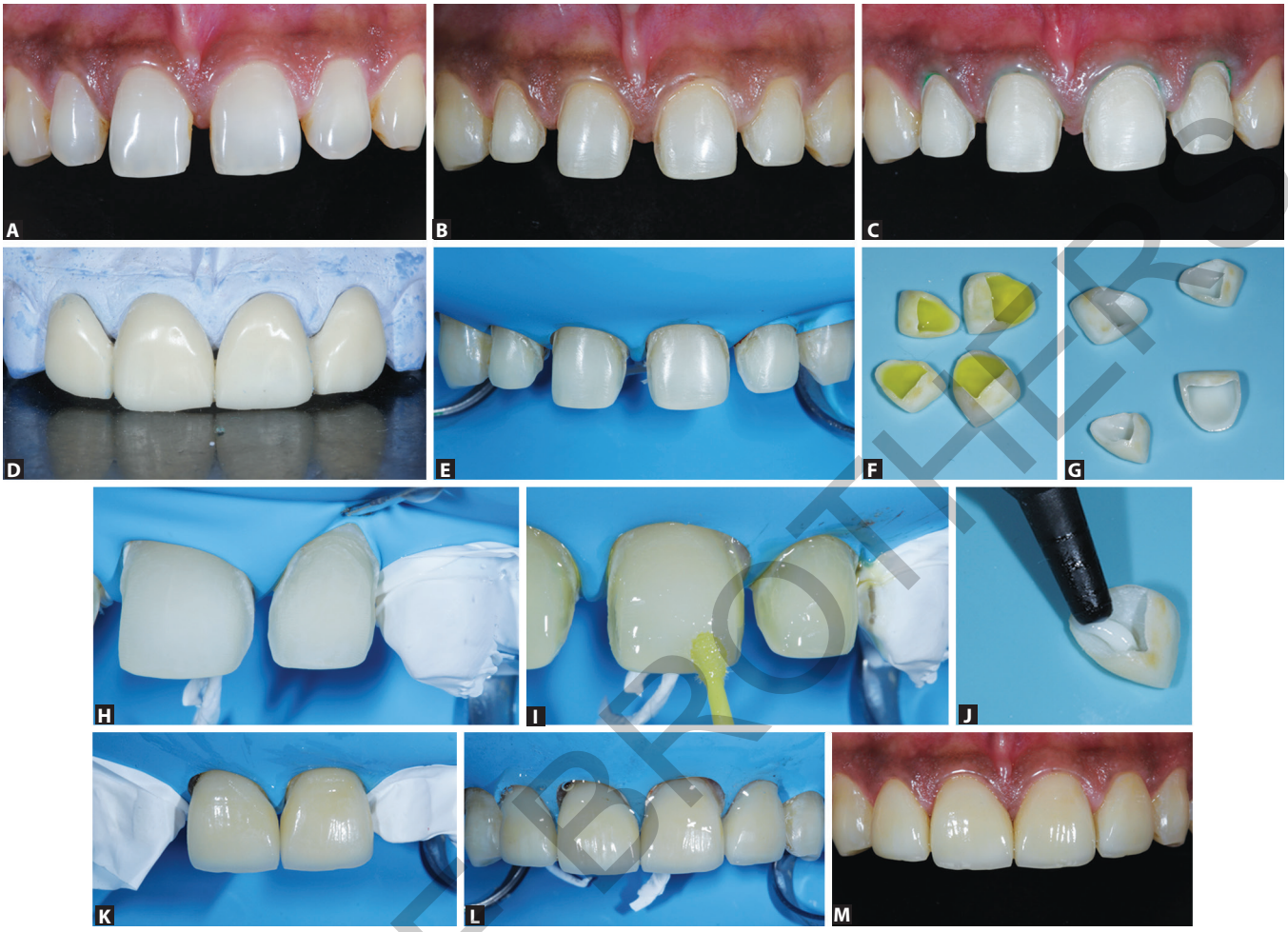

Figs. 21.4A to M: (A) Preoperative photograph; (B) Tooth preparation; (C) Application of retraction cord and taking impression; (D) Fabricated veneers; (E) Isolation of teeth for cementation; (F) Application of 10% hydrofluoric acid; (G) After rinsing, application of silanating agent; (H) Frosted appearance after etching; (I) Application of bonding agent on prepared tooth surface; (J) Application of luting cement on veneer; (K) Cementation of veneers on central incisors; (L) Cementation of veneers on lateral incisors; (M) Postoperative photograph.
(*Courtesy:* Priya Titus).

3. Large lesions with undermined enamel needing full coverage restoration. In such cases, the cross-linked resin-bonded. Porcelain restoration bonds to the remaining tooth structure forming a monobloc restoration.
4. In endodontically compromised tooth, an etched porcelain restoration is a conservative alternative to a full-coverage crown.
5. Undermined incisal edge/proximal surface requiring support to keep an otherwise pleasing intact tooth from fracturing.
6. Existing porcelain restorations on opposite tooth.
7. In patients who have allergy to metal.

Contraindications

1. Patients with poor oral hygiene and lack of motivation.
2. Very short heavily worn off teeth.
3. Teeth with insufficient tooth structure for bonding.
4. Preparations with excessive undercuts
5. When adequate isolation is not possible.
6. Young teeth with large pulp chambers

TOOTH PREPARATION FOR INDIRECT COMPOSITE INLAYS AND ONLAYS (FIGS. 21.6A AND B)

Give local anesthesia and isolate the tooth using rubber dam.

Outline Form

1. Outline form is usually guarded by the existing restorations and caries. It is grossly similar to that for cast metal inlays and onlays except that there are no bevels or secondary flares. For the creation of round internal angles, use tapered fissure bur with round tip. Hold the bur parallel to long axis of the tooth. Outline form should result in smooth curves surrounding the cusps.

JAYPEE BROTHERS



Figs. 21.5A to D: (A) Preoperative photograph; (B) Preparation of teeth for veneers; (C) Occlusal view of tooth preparations; (D) Postoperative photograph.
(Courtesy: Mohan Bhuvaneswaran).

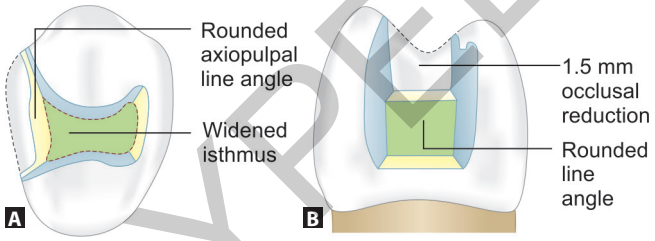

Figs. 21.6A and B: Tooth preparation for composite inlays and onlays.

2. To facilitate passive seating of the inlay, facial and lingual walls should have 6–8° of divergence.
3. Areas to be restored using inlay or onlay need 1.5 mm of clearance in all excursions to prevent fracture.
4. Extend the proximal box to allow a minimum of 0.5–1 mm of proximal clearance for proper finish of these margins and impression making.
5. Use butt joint for all cavosurface margins. Bevels are contraindicated because bulk is needed to prevent fracture.
6. Any undercut, if present, should be removed or blocked by glass ionomer lining. Margin of restoration should be kept supragingival, which will make isolation during the cementation easier and improve access for finishing
7. For pulp protection, place a resin-modified glass ionomer cement base if indicated.
8. Check the final tooth preparation after the removal of rubber dam. There should be 1.5 mm clearance to prevent fracture in all excursions.

Impression Making

An accurate elastomeric impression is taken to form a replica of the tooth, onto which composite restoration is made.

Die Fabrication and Composite Buildup

- Die is fabricated.
- Apply separating media and start placing composite on it. Composite is initially light cured for one minute on each surface. Successive layers are added and polymerized till full contour is built.
- Final curing of restoration is achieved by placing the restoration into curing oven at 100°C for 15 minutes.

JAYPEE BROTHERS

Then, allow it to cool and do final trimming and finishing on die.

Try in and Cementation

1. Once the inlay is fabricated, try it on the tooth under a dental dam isolation to avoid any gingival and salivary contamination.
2. Do pumice prophylaxis to remove any surface deposits.
3. Etch the prepared tooth surface using phosphoric acid for 15 seconds and wash and dry it. Apply two thin coats of bonding agents and light cure it. The chemical treatment of the tooth surface allows an adhesion of the composite by microlocking in the enamel and the hybrid layer in the dentin by tangling between the adhesive system.
4. Etch the internal surface of inlay/onlay with sandblasting with 50 µm aluminum oxide using an intraoral sandblasting device.
5. Apply silane coupling agent on etched surface of restoration.
6. Apply dual cure adhesive resin onto the fitting surface of restoration and on prepared tooth surface. Position the restoration onto the prepared tooth.
7. Remove excess of cement before polymerization using dental probe and light cure the resin cement for 90 seconds.

Final Finishing

1. Finish the occlusal margins with 12 fluted pear-shaped bur.
2. Finish the interproximal margins with 12 fluted flame Shaped bur and No. 12 scalpel blade.
3. Smoothen the restoration and polish it using composite finishing kit.

Table 21.1 summarizes various differences between ceramic and composite inlays.

TABLE 21.1: Differences between composite and ceramic inlays.

Composite inlays	*Ceramic inlays*
Good aesthetics	Excellent aesthetics
May stain with time	Does not stain
Relatively less expensive than ceramic	Expensive
Simple laboratory steps	Complex laboratory steps
Intraoral finishing and polishing is easier	Intraoral finishing and polishing is time-consuming
Easier adjustment and seating	Fragile and brittle, so prone to fracture while seating
Not abrasive to opposing enamel	Abrasive to opposing enamel
Intraoral repair is possible	Intraoral repair is not possible

Figures 21.7 to 21.9 showing indirect resin composite inlay restorations.

ALL-CERAMIC CROWNS

Now-a-days, popularity for all ceramic crowns has increased because these are stronger, more reliable, translucent and more aesthetically pleasing than traditional porcelain fused to metal crowns.

Indications

1. In areas with a high aesthetic demand where a more conservative restoration would be inadequate.
2. In teeth with proximal and/or facial caries that cannot be restored with composite resin.
3. In teeth with sufficient coronal structure to support the restoration especially in the incisal area.

Contraindications

1. When a more conservative restoration can be used.
2. In posterior teeth with increased occlusal load and reduced esthetic requirement where metal ceramics crowns are preferred.
3. If occlusal loading is unfavorable.
4. If sufficient enamel is not present to provide adequate bonding.

Advantages

1. Excellent aesthetics
2. Translucency similar to that of natural tooth structure
3. Biocompatibility
4. Lack of reinforcement by a metal substructure that permits slightly more conservative reduction of the facial surface than with the metal ceramic crown.

Disadvantages

1. Requires more tooth cutting because of the need for a shoulder type margin circumferentially.



Fig. 21.7: Indirect resin composite inlay restoration.

JAYPEE BROTHERS

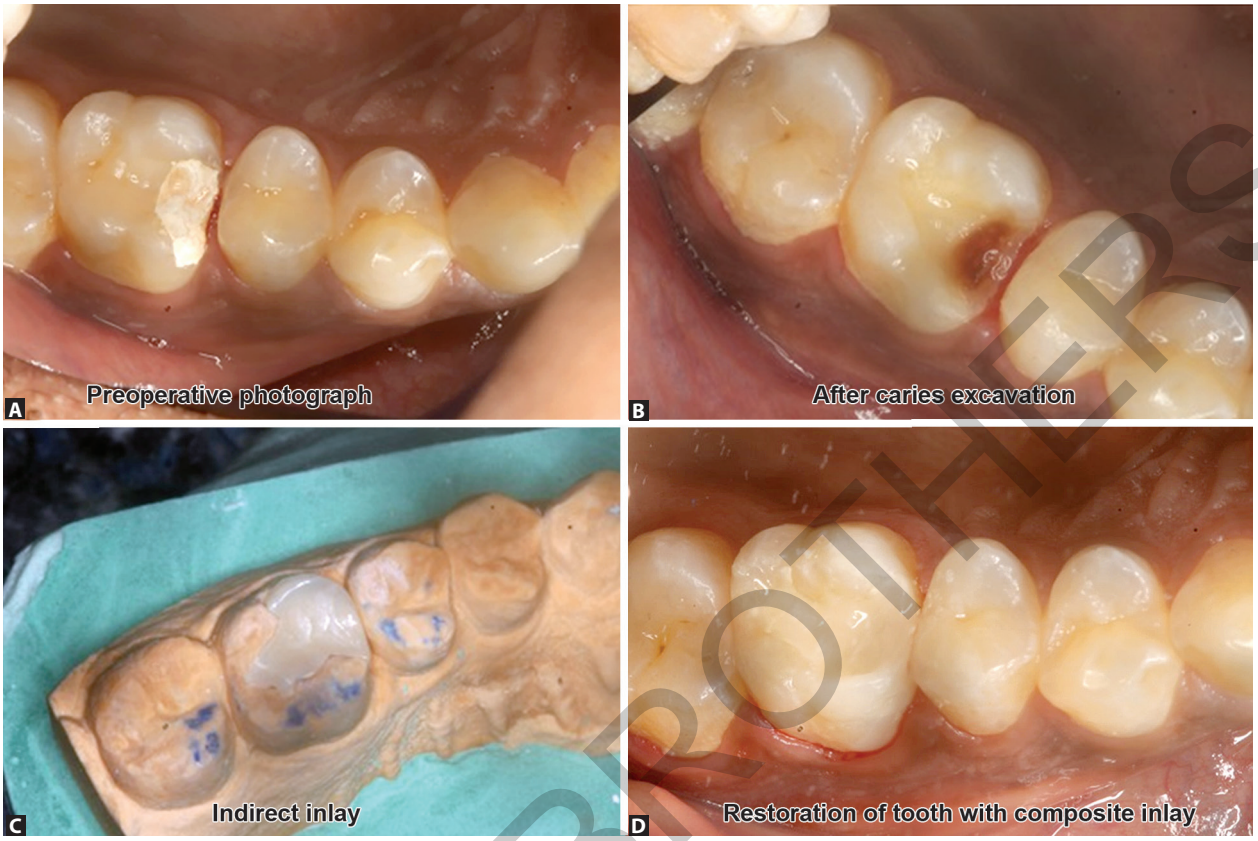

Figs. 21.8A to D: Management of carious 1st molar with indirect composite inlay. (*Courtesy:* Mohan Bhuvaneswaran)

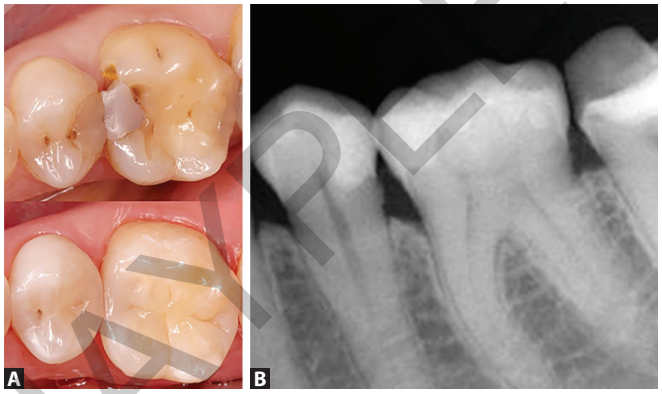

Figs. 21.9A and B: (A) Preoperative and postoperative photograph of composite inlay restoration; (B) X-ray after inlay restoration.

2. Proper preparation design is essential to ensure mechanical success.
3. Needs butt joint cavosurface angle to minimize the risk of fracture.
4. These restorations are not supportive as retainers for a fixed partial denture.

Tooth Preparation

1. Occlusal Reduction

i. There should be 1.5–2 mm of clearance incisally/occlusally for porcelain in all excursive movements of the mandible.
ii. Place depth grooves in the occlusal surface of approximately 1.3 mm depth (to compensate for additional loss of tooth structure during finishing).

2. Facial Reduction

i. Place depth grooves and reduce the facial surface. The depth of these grooves should be approximately 0.8 mm to allow finishing
ii. One depth groove is placed in the middle of the facial wall and one each in the mesiobuccal and distobuccal line angles.
iii. At a time, reduce half of the facial surface. Keep the cervical component parallel to path of withdrawal and an incisal component parallel to the original contour of the tooth.

JAYPEE BROTHERS

3. Lingual Reduction

i. Place 0.8 mm depth grooves and reduce the lingual surface.
ii. Use the football-shaped diamond for lingual reduction.
iii. Do the lingual reduction until a clearance of 1 mm in all mandibular excursive movements is achieved.

4. Shoulder Preparation

It is made from the center of the lingual wall toward the proximal, until the lingual shoulder meets the facial shoulder forming a uniform margin.

5. Chamfer Preparation

It is done for subgingival margins. Avoid making a sloping shoulder which may result in unfavorable loading of the porcelain and thus tensile failure. Take care that no unsupported enamel remains to avoid fracture. The completed chamfer should be 1 mm wide, smooth, continuous, and free of any rough edges.

6. Finishing

1. Finish and smoothen the prepared surfaces.
2. There should not be sharp line angles which can cause fracture because of wedging action.

7. Cementation

1. Apply rubber dam for isolation of tooth.
2. Do pumice prophylaxis to remove any surface deposits.
3. Etch the prepared tooth surface using phosphoric acid for 15 seconds wash and dry it.
4. Apply two thin coats of bonding agents and light cure it.
5. Etch the internal surface of crown with 10% hydrofluoric acid for 1 minute wash and dry it.
6. Apply silane coupling agent on etched surface.
7. Apply luting resin onto the fitting surface of crown and position the crown onto the prepared tooth.
7. Remove excess of cement and light cure the resin cement for 1 minute.
8. Remove small excess using blade or fluted bur. Finish margins of crown and polish using rubber cup/silicon cusp disc and diamond polishing paste.

TECHNIQUES USED FOR FABRICATION OF CERAMIC RESTORATIONS

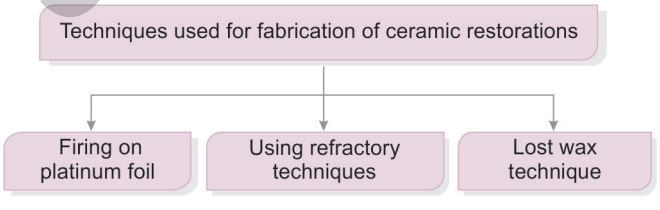

1. Firing on Platinum Foil

Ceramic inlays and onlays are commonly fabricated by firing dental porcelains on refractory dies. Firing is the oldest method among different fabrication techniques. This is no longer preferred nowadays. In this technique, platinum foil is adapted over the die. Feldspathic porcelain is applied over the layer of platinum foil. Then along with foil, porcelain layer is removed from the die and fired in oven. Before cementation, remove the platinum foil.

Advantages	*Disadvantages*
Ease of fabrication	More chances of inaccuracies
Easy accessibility in proximal areas of preparation.	Technique sensitive.

2. Fabrication Using Refractory Die

This is most commonly used method for fabricating inlays, onlays, and veneers.

Steps

1. Complete the tooth preparation, and take the final impression.
2. Pour the impression using type IV stone and prepare "master" working cast.
3. Die is duplicated in refractory investment material which can withstand porcelain firing temperature.
4. Mix the porcelain powder with distilled water or binder provided by manufacturer, pour it in the desired form on the refractory die.
5. Remove the restoration from refractory die and then fit on to master die.
6. Do final adjustments, finishing, and polishing.

Lost Wax Technique

1. Complete the tooth preparation, take the impression, and pour "master" die and cast using die stone.
2. Make a wax pattern and invest it with phosphate bonded investment.
3. Burn out the wax using a wax eliminating furnace.
4. Heat the transparent casting glass at 1,100°C till the casting glass is turned into white, opaque, and semi crystalline material. A special casting machine is used to melt the glass ingot.
5. Molten glass is slowly cast into the mold using centrifugal casting machine. After cooling, clean the restoration of all the investment material.
6. Seat the restoration on master die and working cast for adjustment of contour and finishing.
7. After final fitting is confirmed, final adjustment and finishing procedures are done, shading porcelains are applied, and fired for better color matching and final finishing and glazing is done.

JAYPEE BROTHERS

Machined Restorations Using CAD-CAM

1. After completion of the tooth preparation, a scanning device collects the information on the shape and size of the preparation. This step is called as "optical impression." A video image of the prepared tooth is displayed to ensure proper positioning of the scanning device.
2. The system projects an image of the tooth preparation and surrounding structures on a monitor.
3. Once the restoration has been designed, the computer directs a micromilling device (CAM portion of the system) to mill the restoration out of a ceramic block. These blocks of "machinable ceramics" especially used for CAM devices are fabricated under ideal conditions. The blocks are among the strongest ceramics available for use with physical properties almost similar to that of enamel.
4. The restoration is then removed from the milling device, ready for try-in and cementation.

REPAIR OF VENEERS

Failures of aesthetic veneers occur because of breakage, discoloration, or wear. One should consider conservative repairs of veneers if the remaining tooth and restoration are sound. The material most commonly used for making repairs is light cured composite.

Direct Composite Veneers

For direct composite veneers, repairs should be done with the same material that was used originally. After cleaning the area, select the shade, roughen the damaged surface of the veneer with a coarse, rounded end diamond instrument to form a chamfered cavosurface margin. Apply etchant, rinse and dry the area. Apply bonding agent to existing composite and enamel and cure it. Then place composite material, cure, finish, and polish it.

Indirect Processed Composite Veneers

Indirect processed composite veneers are repaired in a similar manner as direct composite veneers.

Ceramic Veneers

Use 20% buffered concentration of hydrofluoric acid to etch the fractured porcelain. For protection of oral tissues, do not use full strength hydrofluoric acid or do it after applying rubber dam. After this, apply a silane-coupling agent and then resin-bonding agent. Following this, place composite material, cure, and finish it.

Faulty Veneers in Metal Restorations

Clean the teeth with slurry of pumice and select the shade of composite. Old resin material is removed with No. 1558 carbide metal cutting bur. Extend outline of preparation gingivally by removing some of the gold and give chamfer finish line. Give retention grooves of 0.25 mm depth along the line angles by using No. 331/2 carbide bur in the metal. Etch the preparation with acid etchant for 30 seconds, rinse and dry it. The acid is used only to clean the surface, not to etch the metal. Place an opaque resin over prepared metal surface and cure it. Adhesive resins containing 4-META can bond to metal, so, should be used for additional retention and masking effect. Apply composite material at cervical area and cure it. Then place composite increments on middle and incisal thirds, cure and finish the final restoration.

CONCLUSION

Ceramics have been used in dentistry because of their excellent aesthetics, biocompatibility, and durability, though they have problems of being expensive, technique sensitive, and require precise laboratory procedures. In the last few decades, there have been tremendous advances

Differences between direct resin, indirect processed resin, and ceramic veneers.

Considerations	*Direct resin*	*Indirect Processed resin*	*Porcelain indirect*
Indications	1. Need to cover dark shades 2. Patients with financial problems 3. Single tooth treatment	1. Routine veneers for patients which are not deeply stained 2. Patients with parafunctional habits 3. Treatment of multiple teeth	1. Veneers for superficial stains 2. Treatment of multiple teeth
Contraindications	Dentist does not have skills to develop tooth anatomy	Difficult to cover dark stains and striations without placement of underlying opaquer before impression for veneers	1. Difficult to cover dark stains and striations without placement of underlying opaquer before impression for veneers 2. Patients with parafunctional habits
Aesthetics	Good to excellent if clinician can produce it with artistic skills	Good to excellent with high level laboratory and correct patient selection	Excellent with high level laboratory support and correct patient selection

Contd…

JAYPEE BROTHERS

Contd…

Considerations	*Direct resin*	*Indirect Processed resin*	*Porcelain indirect*
Longevity	Atleast 5–7 years with aesthetic acceptability, if placed correctly	At least 5–10 years with aesthetic acceptability if laboratory fabricates it properly and cemented correctly	10 years with aesthetic acceptability if laboratory fabricates it properly and cemented correctly
Strength	Moderate	Moderate	High
Cost to patient	Affordable	Moderately expensive	Expensive
Placement	Placement moderately difficult unless dentist has aesthetic sense for color and contour	Placement not difficult because veneer material is same as cementing medium	Difficult because: 1. Veneer is fragile and can break 2. Selection of cement color 3. Loss of glaze through finishing
Commonly seen failures	1. Incisal edge fracture 2. Discoloration of gingival and proximal margins, if not placed correctly	1. Incisal edge fracture 2. Discoloration of gingival and proximal margins	1. Very little repair needed in 2 years of observation 2. Discoloration of gingival and proximal margins if not placed correctly
Repair difficulty	Simple	Simple	Difficult

in the mechanical properties, methods of fabrication, and their bonding techniques which have increased the range and scope for use of ceramics in dentistry like.

BIBLIOGRAPHY

1. Alhazzani EA, Al-dakheel MD, Aldossary MS. Smile design and porcelain laminate veneers: Clinical aspects and considerations. Int J Oral Health Dent. 2017;3(4):206-9
2. Sailo JL, Bathla N, Thakur P, Nagpal A, Gupta R, Duvedi K. Porcelain veneers vs composite resin veneers: a review. J Adv Med Med Res. 2020;32(24):316-26. https://doi.org/10.9734/jammr/2020/v32i2430784
3. Rashid R, Ayoub WU. Veneers: Modern approach of dentistry-a review. Int J Adv Res Ideas Innov Tech. 2017;3(5):107-11.
4. Noorsaeed AS, Matrood MA, Almutairi MS, Alqarni AN, Alothman KJ, Alshareef AH, et al. Overview on Dental Veneer Placement. J Pharm Res Int. 2021;33(64A):494-501. https://doi.org/10.9734/jpri/2021/v33i64A35812

JAYPEE BROTHERS

for detailed information on dental books, visit our website www.jaypeebrothers.com, for detailed information on dental books, visit our website www.jaypeebrothers.com, for detaile

Textbook of
OPERATIVE DENTISTRY

Salient Features

- **Comprehensive coverage:** This textbook encompasses all essential topics in Operative Dentistry offering the latest techniques and updates crucial for undergraduates, postgraduates, and general practitioners.
- **Syllabus alignment:** Aligned with the prescribed syllabus by the Dental Council of India and other international universities, the text ensures comprehensive learning.
- **Rich visuals:** Enriched with clinical photographs, videos, radiographic images, line diagrams, flowcharts, text boxes, and tables, enhancing the clarity and understanding of core concepts.
- **35 informative chapters:** The book includes 35 chapters that provide the latest clinical information, covering procedures from basic to intricate, catering to a wide spectrum of readers.
- **Examination ready:** Each chapter concludes with the examiner's choice questions from various universities, facilitating effective last-minute preparation for examinations.
- **Updated content:** Stay ahead with the latest definitions and concepts including advancements in diagnostic methods, artificial intelligence, material techniques, indirect aesthetic restorations, smile designing, etc.
- **Universally applicable:** The content is designed to be useful for both undergraduate and postgraduate students, serving as a valuable resource for examination preparation.

In essence, this textbook is a comprehensive, visually enriched guide that aligns with academic requirements, offering the latest insights and aiding in effective examination preparation for dental students and practitioners.

Nisha Garg, a distinguished dental professional, earned her MDS from Government Dental College, Patiala, Punjab, India, and achieved excellence throughout her academic journey. Her consistent merit as a Gold Medalist during BDS earned her the title of the best graduate, securing the highest total marks in graduation. Currently serving as a Professor and PG Guide at Bhojia Dental College, Baddi, Himachal Pradesh, India, her expertise extends her tenure as an Ex-Resident at the esteemed Postgraduate Institute of Medical Education and Research (PGIMER) in Chandigarh, India. With a prolific record, she has published numerous national and international papers, contributing significantly to the dental field.

Amit Garg, holding an MDS from Government Dental College in Rohtak, Haryana, India, brings valuable experience as an Ex-Resident at Pandit Bhagwat Dayal Sharma Post Graduate Institute of Medical Sciences (PGIMS), Rohtak. His keen interest in research is reflected in numerous publications across various journals.

Nisha Garg and Amit Garg manage a successful dental practice at "Perfect Teeth Dental Clinic and Facial Aesthetics" in Mohali, Punjab, India. Their collaborative efforts also extend to authoring globally acknowledged and appreciated textbooks including the *Textbook of Endodontics* and *Textbook of Preclinical Conservative Dentistry*, establishing them as influential figures in the dental education landscape.

Printed in India

Available at all medical bookstores or buy online at www.ejaypee.com

JAYPEE BROTHERS
Medical Publishers (P) Ltd.
EMCA House, 23/23-B, Ansari Road,
Daryaganj, New Delhi - 110 002, INDIA
www.jaypeebrothers.com

Join us on facebook.com/JaypeeMedicalPublishers
Follow us on instagram.com/JaypeeMedicalPublishers

Shelving Recommendation
DENTAL

ISBN 978-93-6616-411-3