ebrothers.com, for detailed information on anatomy books, visit our website www.jaypeebrothers.com, for detailed information on anatomy books

Scan to Download the App

diginerve
A Jaypee Initiative
Your Guide at Every Step
Video Lectures | Notes | Self-Assessment

Early Clinical Exposure
A Case Based Approach in
Clinical Anatomy

As per the Revised Competency-based Medical Education Curriculum (NMC-2024)



Ajay Kumar
Anu Sharma

Foreword
Gurpreet Singh Wander

2nd Edition

JAYPEE

Contents

SECTION I: UPPER LIMB 1–42

Case 1.1: Breast Cancer *3*
Case 1.2: Fracture of Clavicle *5*
Case 1.3: Erb's Palsy *8*
Case 1.4: Klumpke's Paralysis *10*
Case 1.5: Winging of Scapula *12*
Case 1.6: Dislocation of Shoulder *14*
Case 1.7: Nerve Injury due to Intramuscular Injection *16*
Case 1.8: Venipuncture *18*
Case 1.9: Carpal Tunnel Syndrome *19*
Case 1.10: Claw Hand *22*
Case 1.11: Midpalmar Space Infection *25*
Case 1.12: Digital Pulp Space Infection or Felon Finger *27*
Case 1.13: Wrist Drop *29*
Case 1.14: Painful Arc Syndrome or Impingement Syndrome *32*
Case 1.15: Volkmann Ischemic Contracture *35*
Case 1.16: Colle's Fracture *37*
Case 1.17: Scaphoid Fracture *39*
Case 1.18: Rotator Cuff Injury *41*

SECTION II: LOWER LIMB 43–78

Case 2.1: Femoral Hernia *45*
Case 2.2: Psoas Abscess *48*
Case 2.3: Sciatic Nerve Injury *50*
Case 2.4: Trendelenburg's Sign *52*
Case 2.5: Fracture Neck of Femur *54*
Case 2.6: Foot Drop *56*
Case 2.7: Bucket Handle Tear *59*
Case 2.8: Calcaneal Tendon Rupture *61*
Case 2.9: Flat Foot *63*

Case 2.10: Clubfoot *65*
Case 2.11: Case of Metatarsalgia *67*
Case 2.12: Carcinoma of Penis *69*
Case 2.13: Varicose Veins *71*
Case 2.14: Osteoarthritis of Knee *74*
Case 2.15: Deltoid Ligament Injury *76*

SECTION III: THORAX 79–108

Case 3.1: Atrial Septal Defect *81*
Case 3.2: Ventricular Septal Defect *84*
Case 3.3: Tetralogy of Fallot *87*
Case 3.4: Patent Ductus Arteriosus *89*
Case 3.5: Coarctation of Aorta *91*
Case 3.6: Ischemic Heart Disease *94*
Case 3.7: Tracheoesophageal Fistula *97*
Case 3.8: Gastroesophageal Reflux Disease *100*
Case 3.9: Pleurisy *102*
Case 3.10: Carcinoma Esophagus *104*
Case 3.11: Chylothorax *106*

SECTION IV: ABDOMEN AND PELVIS 109–158

Case 4.1: Inguinal Hernia *111*
Case 4.2: Portal Hypertension *115*
Case 4.3: Diaphragmatic Hernia *118*
Case 4.4: Benign Prostatic Hyperplasia *121*
Case 4.5: Prolapsed Uterus *123*
Case 4.6: Hemorrhoids *125*
Case 4.7: Automatic Bladder *127*
Case 4.8: Cryptorchidism *129*
Case 4.9: Ascites *131*
Case 4.10: Subphrenic Abscess *133*
Case 4.11: Anal Fistula *135*
Case 4.12: Perineal Tear *137*
Case 4.13: Perianal Abscess *140*

Case 4.14: Vasectomy and Tubal Ligation *142*
Case 4.15: Spleen Injury and Kehr's Sign *144*
Case 4.16: Cholecystitis *146*
Case 4.17: Renal Colic *148*
Case 4.18: Varicocele *150*
Case 4.19: Phimosis *152*
Case 4.20: Hirschsprung's Disease (Congenital Megacolon) *154*
Case 4.21: Persistent Vitellointestinal Duct *156*

SECTION V: VERTEBRAL COLUMN 159–176

Case 5.1: Scoliosis *161*
Case 5.2: Lordosis *165*
Case 5.3: Spondylolisthesis *167*
Case 5.4: Herniated Disc *169*
Case 5.5: Spina Bifida *171*
Case 5.6: Lumbar Puncture *174*

SECTION VI: HEAD AND NECK 177–212

Case 6.1: Black Eye *179*
Case 6.2: Dangerous Area of Face *181*
Case 6.3: Facial Nerve Palsy *183*
Case 6.4: Frey's Syndrome or Auriculotemporal Syndrome *185*
Case 6.5: Horner's Syndrome *187*
Case 6.6: Cleft Palate *189*
Case 6.7: Pituitary Adenoma *191*
Case 6.8: Oculomotor Nerve Palsy *194*
Case 6.9: Submandibular Stone *196*
Case 6.10: Thyroid Swelling *198*
Case 6.11: Tonsillitis *200*
Case 6.12: Killian's Dehiscence *203*
Case 6.13: Recurrent Laryngeal Nerve Palsy *205*
Case 6.14: Hypoglossal Nerve Palsy *208*
Case 6.15: Cervical Rib *210*

SECTION VII: NEUROANATOMY 213–234

Case 7.1: Hydrocephalus *215*
Case 7.2: Cerebrovascular Accident *218*
Case 7.3: Argyll Robertson Pupil *221*
Case 7.4: Cerebellar Ataxia *224*
Case 7.5: Poliomyelitis *226*
Case 7.6: Medial Medullary Syndrome *228*
Case 7.7: Lateral Medullary Syndrome *230*
Case 7.8: Benedikt's Syndrome *232*

SECTION VIII: GENETICS 235–240

Case 8.1: Neural Tube Defects *237*
Case 8.2: Prenatal Diagnosis *239*

Index **241**

II

SECTION

Lower Limb

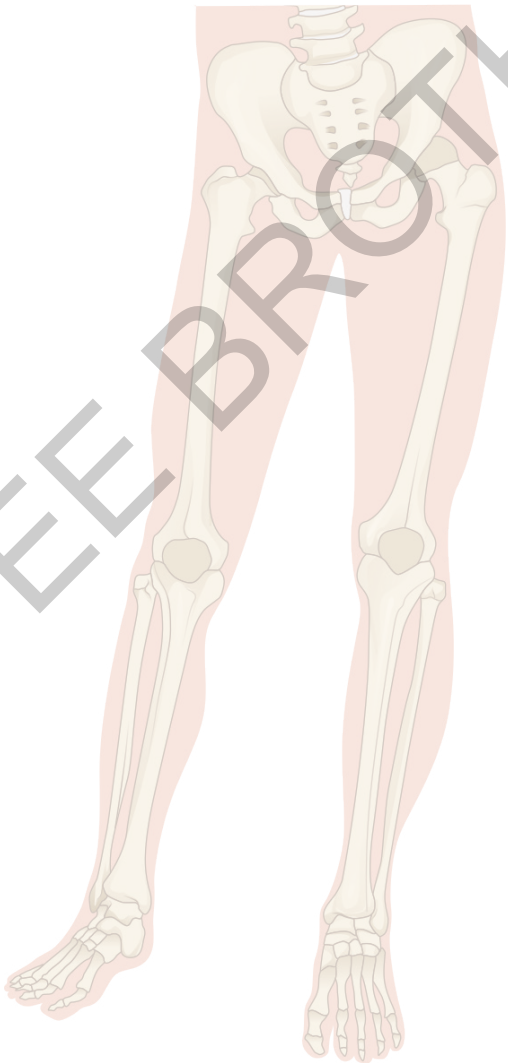

JAYPEE BROTHERS

Case 2.1 Femoral Hernia

A 51-year-old female came to emergency room with a small, tender, and tense swelling. On examination, the swelling was located below and lateral to right pubic tubercle **(Fig. 2.1)**. She was previously diagnosed with right groin hernia and was treated using the mesh plug method one month back at another hospital. Abdominal computed tomography scan revealed small bowel obstruction, incarcerated bowel, and compression of the femoral vein.



Fig. 2.1: Right side femoral hernia (arrow).

Photo courtesy: Dr Ashvind Bawa, Professor, Department of Surgery, DMCH, Ludhiana.

Q1. What is the diagnosis?

Ans: Femoral hernia.

Q2. What are the causes of this condition?

Ans: The hernias are related to chronic conditions where in intra-abdominal pressure gets increased. Some of the common causes are:

- Heavy lifting
- Chronic constipation
- Childbirth
- Obese
- Chronic coughing

JAYPEE BROTHERS

Q3. Explain the anatomical basis of this condition.

Ans: Femoral hernia occurs just below the inguinal ligament, when abdominal contents pass through a naturally occurring weakness in the lower part of the abdominal wall called femoral canal. With conditions that increase intra-abdominal pressure, a patient becomes more prone for hernia as the femoral canal weakness becomes more pronounced.

Femoral hernias can occur both in males and females, but it is commonly found in females because of the following reasons:

- The femoral canal is wider in females
- The size of blood vessels is smaller in females as compared to males
- Wider pelvis in females
- Pregnancy (higher incidence in multiparous women)

Q4. Write a note on femoral canal.

Ans: The femoral canal is the medial compartment of femoral sheath. It is an inverted cone-shaped fascial space which lies medial to the femoral vein within the femoral triangle. It is about 1–2 cm long and opens superiorly as the femoral ring. It serves two purposes:

1. Allows the femoral vein to expand when there is increased venous return from the lower limb.
2. Route for efferent lymphatic drainage from the deep inguinal lymph node (e.g., Cloquet's node) to the external iliac lymph nodes.

The upper end or base of femoral canal is femoral ring. The boundaries of the femoral ring are as follows **(Fig. 2.2)**:

- **Medially:** Lacunar ligament
- **Anteriorly:** Medial part of the inguinal ligament
- **Laterally:** Femoral vein within the intermediate compartment of the femoral sheath
- **Posteriorly:** Pectineal ligament overlying the pectineus muscle and its fascia covering the superior pubic ramus.

The contents of the femoral canal are lymph node of Cloquet or Rosen Muller's (which drains the tip of glans penis), lymphatics and a small amount of areolar tissue.

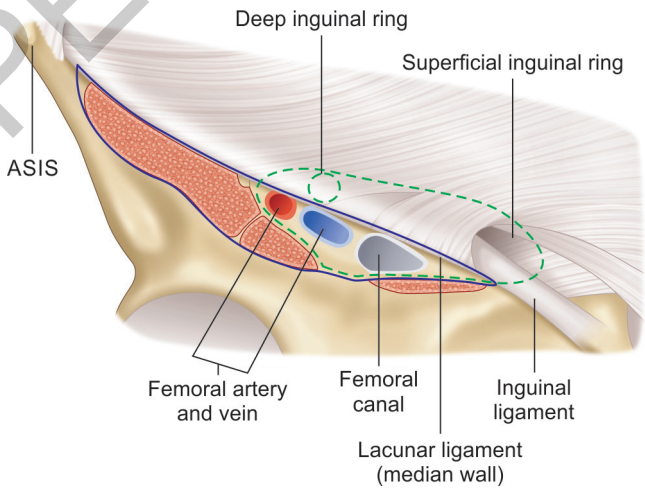

Fig. 2.2: Anatomy of femoral canal.
(ASIS: Anterior superior iliac spine)

JAYPEE BROTHERS

Q5. What are the coverings of femoral hernia?

Ans: The coverings of femoral hernia (from inside out) are as follows:

- Parietal peritoneum
- Femoral septum (composed of extraperitoneal fatty tissue, connective and lymphoid tissue)
- Transversalis fascia
- Cribriform fascia
- Superficial fascia
- Skin

Q6. What is the treatment of femoral hernia?

Ans: The treatment of femoral hernia includes:

- **Conservative treatment:** Remedial measures for conditions causing raised intra-abdominal pressure.
- **Surgical treatment:** The swelling is pushed back into abdomen and the weakness in the wall of the abdomen is strengthened with the mesh and sutures. In obstructed hernia, small necrotic bowel is resected **(Fig. 2.3)** and the femoral ring is repaired.

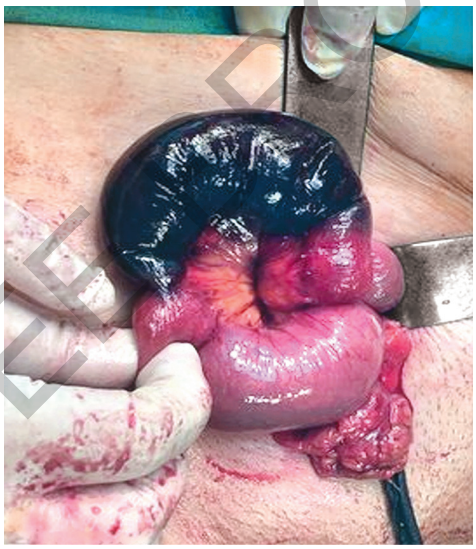

Fig. 2.3: Strangulated loop (black in color) of intestine.

Q7. What are the complications of femoral hernia?

Ans: If the femoral hernia is left untreated, it can lead to obstructed irreducible hernia. Patient complains of nausea, vomiting, and abdominal pain. It may lead to strangulated hernia. It may cause ischemia of herniated loop **(Fig. 2.3)**.

JAYPEE BROTHERS

Case 2.2 Psoas Abscess

A 55-year-old male presents to the emergency department with a two-week history of fever, chills, and right-sided swelling of groin region and lower back pain. The patient reports that the pain has been gradually increasing in intensity and is now radiating to his groin. On examination, he has tenderness and guarding in the right lower back area. MRI of abdomen was done **(Fig. 2.4)**.

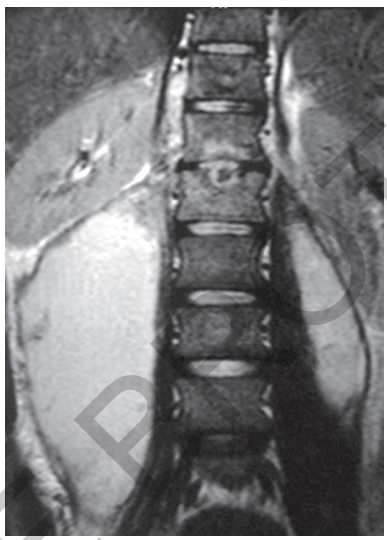

Fig. 2.4: MRI image of right sided psoas abscess (obscuring the view of right kidney).

Q1. What is the diagnosis?

Ans: Psoas abscess.

Q2. What are the causes of psoas abscess?

Ans: Psoas abscess is caused by:

- Tuberculosis of spine
- Hematogenous spread of an infectious process from an occult (hidden) source in the body. It is more common in patient with diabetes mellitus, AIDS, kidney failure, immunosuppression, or intravenous drug use.
- Spread of infection from gastrointestinal diseases such as appendicitis, Crohn disease, diverticulitis, or perforated colon carcinoma.
- **Spondylodiskitis:** It is a combination of diskitis which is inflammation of intervertebral disk spaces and, spondylitis which is inflammation of vertebrae.
- Recent surgery or trauma in the region

JAYPEE BROTHERS

Q3. What is the anatomical basis of this condition?

Ans: Psoas abscess is a serious infection that involves the psoas major muscle. Psoas major muscle is covered by fascial sleeve called as psoas sheath. The psoas sheath is made up of three layers: the posterior layer, which is continuous with the fascia surrounding the quadratus lumborum muscle; the lateral layer, which is continuous with the fascia of the iliacus muscle; and the anterior layer, which is formed by the transversalis fascia.

The psoas sheath has following attachment:

- **Medially:** Body of lumbar vertebrae and intervertebral disc
- **Laterally:** It fuses with the anterior layer of thoracolumbar fascia in upper part.
- **Superiorly:** Upper border of sheath is free and thickened to form medial arcuate ligament
- **Inferiorly:** The fascia fuses with the fascia iliaca and passes deep to femoral artery and blend with the tendon of muscle in thigh. Since the upper border of sheath is free, pus from infection of thoracic and lumbar vertebrae may track down through the psoas sheath into the thigh, producing a soft swelling in the femoral triangle **(Fig. 2.5)**.

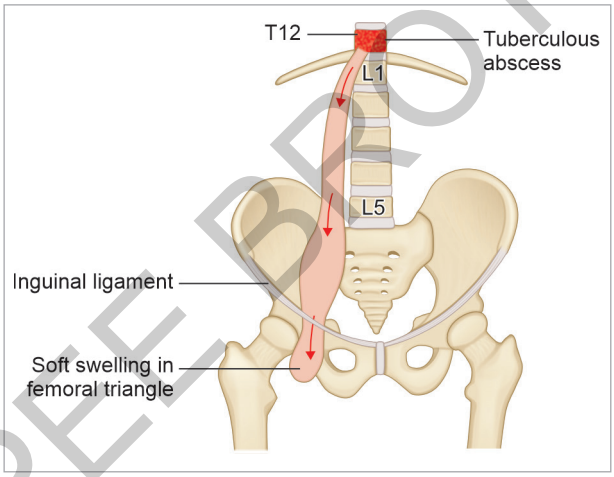

Fig. 2.5: Pathway of psoas abscess.

Q4. What is the treatment for this condition?

Ans: The treatment of psoas abscess involves:

- **Conservative treatment:** Antibiotics and anti-inflammatory drugs
- **Surgical treatment:** Drainage of abscess

JAYPEE BROTHERS

Case 2.3 Sciatic Nerve Injury

A 43-year-old female patient after the operation developed gait disturbance due to weakness of his left leg and foot as well as severe aching and electrical-shooting pain along her left posterolateral thigh, leg, and foot. She had undergone an appendectomy three months back. Postoperatively, she received intramuscular (IM) injection in her left buttock for relief of pain. Three hours later, the patient complained that she could not walk due to weakness in her left foot.

Q1. What is the diagnosis?

Ans: Sciatic nerve injury of left side.

Q2. What are the causes of this condition?

Ans: Sciatic nerve injury occurs when there is pinching or compression of the nerve. The common causes are:

- Herniated or slip disc
- Bone spurs (overgrowth of bone)
- Tumor in surrounding region
- Injection injuries

Q3. Explain the anatomical basis of this condition.

Ans: Sciatic nerve can get affected due to injection injury while giving intramuscular injection at gluteal region. The normal site to give injection is upper outer or lateral quadrant of the gluteal region, as in lower and medial quadrant as close relations of sciatic nerve **(Fig. 2.6)**.

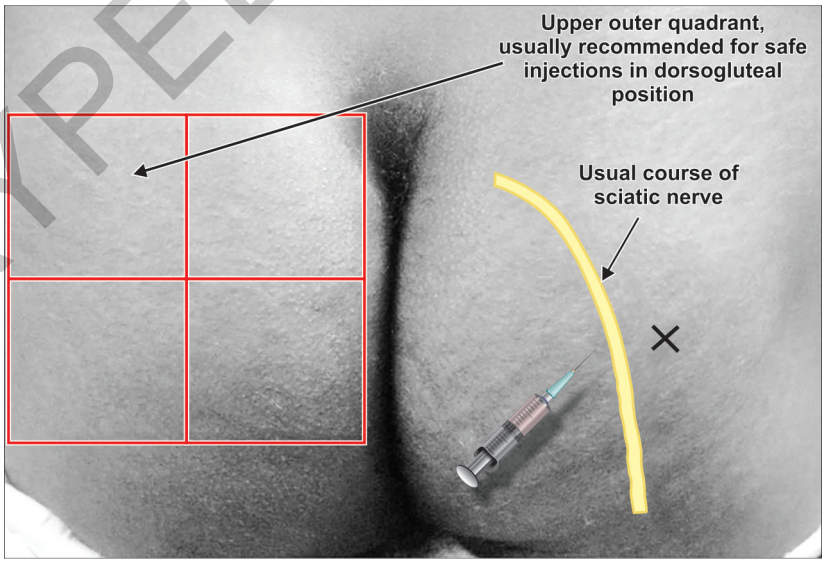

Fig. 2.6: Upper outer quadrant (normal site of intramuscular injection).

JAYPEE BROTHERS

If the injection is given in lower medial quadrant it results in sciatic nerve injury. The neurological presentation may vary from mild pain to severe sensory disturbances and motor loss with poor recovery. In severe cases, there is loss of all the movements below the knee with foot drop. There is sensory loss on the back of the thigh, the whole of the leg and the foot except the area innervated by the saphenous nerve. Motor loss includes paralysis of hamstring muscles including weakness of dorsiflexors, plantar flexors, evertors, and muscles of the sole.

Q4. What is sleeping foot?

Ans: Sleeping foot is a feeling of numbness or tingling known as *temporary paresthesia*. This sensation is sometimes called *pins and needles prickling sensation*. It tends to happen due to irritation or temporary compression of sciatic nerve. The sciatic nerve lies on quadratus femoris and adductor magnus. Between the borders of these two muscles, the nerve lies for short distance on the femur. When a person sits on the edge of a hard table or chair, the nerve gets compressed between the edge of table and femur. As sleeping foot is temporary situation, normal sensations come back when person gets up and walk for a minute.

Q5. How the sleeping foot is different from sciatica?

Ans: Difference between sciatica with sleeping foot is shown in **Table 2.1**.

TABLE 2.1: Difference between sleeping foot and sciatica.

	Sleeping foot	*Sciatica*
Pain	There is no pain. Only feeling of numbness or tingling sensation	Pain radiating along the sciatic nerve, which runs down one or both legs from the lower back
Reason	It is due to irritation and temporary compression of sciatic nerve	It is usually caused when a herniated disc or bone spur in the spine presses on the nerve
Radiation	There is no radiation of pain	Pain originates in the spine and radiates down the back of the leg
Treatment	It is temporary, therefore needs no treatment	Medication for pain and physiotherapy are commonly used treatments

Q6. What is the treatment of sciatic nerve injury?

Ans: The treatment includes:

- **Conservative treatment:** Multivitamins and physiotherapy
- **Surgical treatment:** Nerve grafting and treatment of underlying causes such as tumor and slipped disk

JAYPEE BROTHERS

Case 2.4 Trendelenburg's Sign

A 62-year-old male presented in emergency with complaint of limping on walking. On examination, patient was found to have positive Trendelenburg's sign. Radiographic examination of right hip joint showed Shenton's line was not intact **(Fig. 2.7)**.

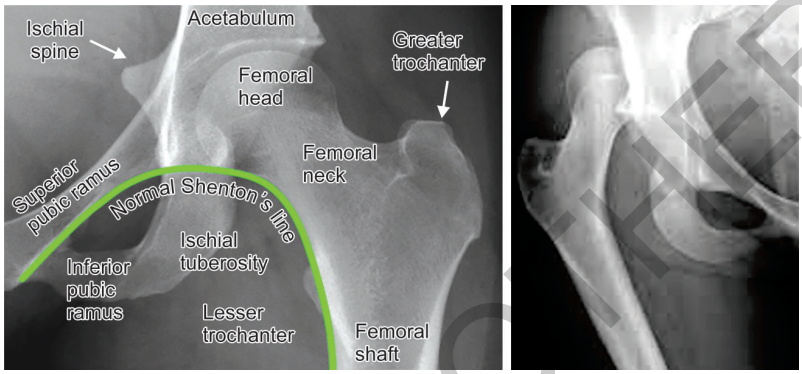

Fig. 2.7: Shenton line and dislocation of right hip joint.

Q1. What is the diagnosis?

Ans: Dislocation of right hip joint.

Q2. What are the causes of positive Trendelenburg Sign?

Ans: The causes of positive Trendelenburg sign:

1. Dislocation of hip joint which can be classified as congenital or acquired:
   - *Congenital:* Sometimes physiologic position of the fetus in utero may press against the abdominal wall of the mother and potentially leading to abnormal development.
   - *Acquired:* Causes for acquired condition may be as follows:
     - Motor vehicle collision
     - Complications after total hip replacement or faulty prosthesis
     - Neuromuscular disorders, e.g., Parkinson disease
     - Old age
2. Injury to superior gluteal nerve leads to paralysis of Gluteus medius and Gluteus minimus.

Q3. What is a Shenton's line?

Ans: Shenton's line is an imaginary curved line drawn along the inferior border of the superior pubic ramus (superior border of the obturator foramen) and along the inferomedial border of the neck of femur **(Fig. 2.7)**. This line should be continuous and smooth. It is used to determine the relationship between the head of the femur and the acetabulum.

JAYPEE BROTHERS

Q4. What is the anatomical basis of this condition?

Ans: A positive Trendelenburg's sign can be seen in following conditions:

1. Paralysis of gluteus medius and gluteus minimus due to superior gluteal nerve injury.
2. Dislocation of hip joint
3. Fracture of neck of femur

Trendelenburg's sign can be explained as shown in **Figures 2.8A and B**. When both feet are supporting the body weight, the pelvis on the two sides lie in same horizontal plane. If the left sided gluteus medius and gluteus minimus are paralysed, the unsupported right side of the pelvis drops **(Fig. 2.8B)**. In the normal circumstances when only left foot is supporting the body weight the unsupported side of the pelvis (right side) is raised by the opposite gluteus medius and gluteus minimus **(Fig. 2.8A).**

In patient with both sided defective mechanism such as in both sided cogenital dislocation of hip joint, patient exhibits waddling gait

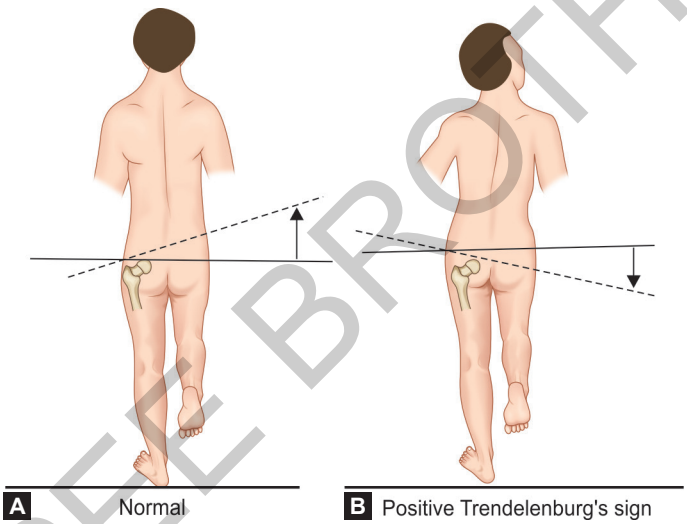

Figs. 2.8A and B: Trendelenburg sign.

Q5. What is the treatment of dislocation of hip joint?

Ans: The treatment of dislocation of hip joint includes:

- **Conservative treatment:**
  - Anti-inflammatory drugs for pain
  - Immobilization
  - Dislocation is reduced by in-line traction and external rotation, with an assistant pushing on the femoral head or pulling the femur laterally to assist reduction.
  - Physiotherapy
- **Surgical treatment:** If the dislocation is associated with fracture, open reduction and internal fixation (ORIF) is the treatment of choice followed by physiotherapy.

JAYPEE BROTHERS

Case 2.5 Fracture Neck of Femur

A 75-year-old Caucasian male presented to the emergency department after a fall. He complained of pain in his left hip and he was unable to bear weight. On examination, the left hip was painful, and the leg was shortened and externally rotated. Radiographs of the pelvis is ordered to make the diagnosis **(Figs. 2.9A and B)**.

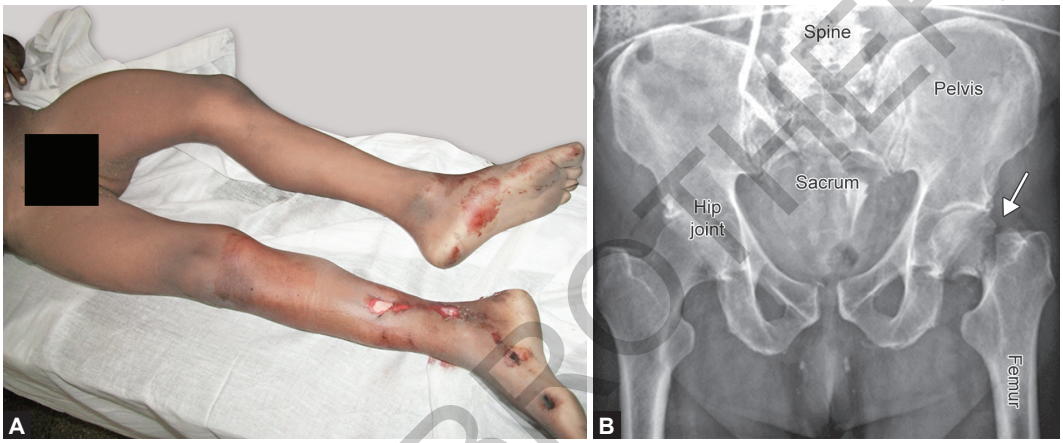

Figs. 2.9A and B: (A) Left Fracture neck of femur. (B) X-ray showing left side fracture neck femur.

Photo courtesy: (Part A) Dr Gautam Biswas, Professor and Head, Forensic Medicine, DMCH, Ludhiana.

Q1. What is the diagnosis?

Ans: Fracture neck left femur.

Q2. What are the causes of this condition?

Ans: The following are the causes of fracture neck femur:

- **Fall:** Even a trivial incidence such as tripping on the pavement or in the bathroom
- Decrease mobility and low bone density, e.g., in case of postmenopausal females
- Road traffic accident

Q3. Explain the anatomical basis of clinical features of this condition.

Ans: Anatomical basis of features in this condition are as follows:

- **Lower limb shortening and externally rotated:** Extremity shortening occurs because the length of muscles acting on the hip joint depend on the continuity of the femur to act, and when this continuity is disrupted, the result is a shorter-appearing leg. The muscle acting on the hip is psoas major and contraction of psoas muscle cause shortening of the leg. The leg is externally rotated due to the pull of the short external rotators (obturator externus and internus, superior and inferior gemelli, and the quadratus femoris).

JAYPEE BROTHERS

- **Avascular necrosis:** The head of femur receives blood supply from a branch of obturator artery along the ligamentum teres. The main supply comes from retinacular arteries which are branches from medial circumflex artery, which in turn is a branch of profunda femoris artery. These arteries get injured in intracapsular fracture neck of femur, leading to avascular necrosis of head of femur.

Q4. What is the treatment of this condition?

Ans: The treatment of fracture neck femur includes:

- **Surgical treatment:** It consists of open reduction and internal fixation of the neck fracture with screws, followed by retrograde nailing of the femoral shaft **(Fig. 2.10)**.
- **Conservative treatment:**
  - Surgical treatment is followed by physiotherapy
  - Pain medication and supportive measures.



Fig. 2.10: Fixation of femoral neck with nailing.

JAYPEE BROTHERS

Case 2.6 Foot Drop

A 24-year-old soldier was admitted to an army hospital with a diagnosis of unilateral foot drop reporting weakness in his feet and difficulty in walking. He had a gunshot injury at knee level one month ago in which a single bullet penetrated the left knee **(Fig. 2.11)**. Numbness over the lower anterolateral aspect of the legs and the dorsum of the feet had immediately developed following the injury. On clinical examination, he had steppage gait, foot is plantarflexed, and eversion was lost. Plantar flexion and inversion were normal.



Fig. 2.11: Left knee-bullet injury.

Q1. What is the diagnosis?

Ans: Foot drop. It is deformity of foot where foot is inverted and plantarflexed. It is a condition characterized by difficulty in lifting the front part of the foot from the ground. This difficulty can cause the foot to drag on the ground while walking, leading to an abnormal gait, often described as a steppage gait.

JAYPEE BROTHERS

Q2. What are the causes of this condition?

Ans: The causes of foot drop can be as follows:

- **Common peroneal nerve injury (Fig. 2.12):** It may be due to the following reasons—
  - Teacher stick injury on later aspect of leg at neck of fibula
  - Leprosy
  - Peripheral neuritis
  - Entrapment syndrome can lead to compressive neuropathy.
  - Stab/Gunshot wound at lateral aspect of leg
- **Deep peroneal nerve injury:** It may be due to the following reasons—
  - Knee or patellar dislocation
  - Direct impact or cut on the fibular neck, and proximal fibula fracture.
  - Injury due to compression, such as a tight plaster cast or compression wrapping.
- **Sciatic nerve injury:** It may be due to the following reasons—
  - Lumbar radiculopathy
  - Sciatic nerve compression between two heads of piriformis
  - Stab/Gunshot wound in gluteal region
  - Diabetic neuropathy

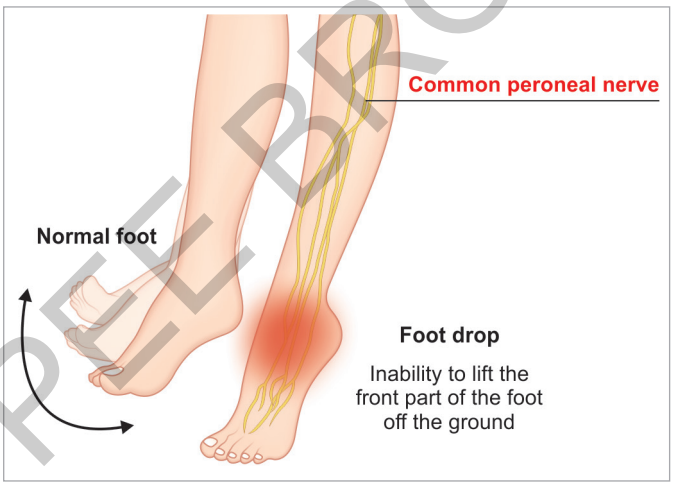

Fig. 2.12: Foot drop.

JAYPEE BROTHERS

for detailed information on anatomy books, visit our website www.jaypeebrothers.com, for detailed information on anatomy books, visit our website

Early Clinical Exposure
A Case Based Approach in
Clinical Anatomy

Salient Features

- The book is based on a new competency-based medical education (CBME) syllabus.
- As the questions are more clinically oriented, the answers are relevant, point-wise, and easily understandable.
- The book includes questions and answers on all aspects of anatomy with simple and easy-to-reproduce figures, tables, and flowcharts.
- Case-based presentations in the book help in understanding of complex topics and facilitate easy retention, application to clinical cases, and easy reproducibility in examination.



Ajay Kumar MBBS MS ACME is currently Professor, Department of Anatomy, Dayanand Medical College and Hospital, Ludhiana, Punjab, India. He did MBBS from Bangalore University in 1996 and MS in Anatomy from BFUHS University, Faridkot (2000–2002). He did Advance Course in Medical Education (ACME) from CMCH, Ludhiana (approved by the Medical Council of India), in 2017. He completed his basic course in biomedical research by NPTEL in 2020 and postgraduate diploma in Bioethics under Israel Haifa Unit of International Chair in Bioethics. He has more than 24 years of teaching experience in teaching anatomy to undergraduate and postgraduate medical and allied courses students. He has a credit of a total number of 22 publications in national and international journals. He has contributed to writing two books. He is a member of Society of Clinical Anatomists, Anatomical Society of India, and North India Anatomist Federation.



Anu Sharma MBBS MS FAIMER (CMCL) MNAMS is currently Professor of Anatomy in Dayanand Medical College and Hospital, Ludhiana, Punjab, India. She did MBBS from Indira Gandhi Medical College, Shimla (HP University), in 1994 and MS in Anatomy from Dayanand Medical College and Hospital (BFUHS University Faridkot) in June 2002. She did a 2-year prestigious fellowship program in Foundation for Advancement of International Medical Education and Research (2013–2015) from CMCH, Ludhiana (under the aegis of FAIMER—Philadelphia). For her active interest in the field of research, she was awarded with the "Best Researcher" award and a position of Editor-in-Chief in "Indian Journal of Clinical Anatomy and Physiology". She is a National Editorial Board member for medical education in "Journal of the Anatomical Society of India". More than 40 publications go to her credit in national and international journals. She is representing curriculum implementation support program for her college (preclinical subjects) in NMC. She has been an accredited faculty of medical education courses (National Medical Council) and bioethics (Department of Education, International Chair in Bioethics, Australia). She completed her basic course in Biomedical Research by NPTEL in 2020. Presently, she is perusing MSc course in Bioethics (International Chair in Bioethics, Portugal). She has more than 25 years of teaching experience in teaching anatomy to undergraduate medical and allied courses students. She has contributed to writing two books. She is a life member of Society of Clinical Anatomists, Anatomical Society of India, National Academy of Medical Sciences, North India Anatomist Federation, Indian Association of Medical Informatics, Indian Medical Association AHPE (Academy of Health Professions Educators), and Innovative Education and Scientific Research Foundation. She is awarded with the prize of commendable editor in chief (IJCAP) and certificates of excellence in serving National Journal of Clinical Anatomists.

Printed in India

Available at all medical bookstores or buy online at www.ejaypee.com

JAYPEE BROTHERS
Medical Publishers (P) Ltd.
EMCA House, 23/23-B, Ansari Road,
Daryaganj, New Delhi - 110 002, INDIA
www.jaypeebrothers.com

Join us on facebook.com/JaypeeMedicalPublishers
Follow us on instagram.com/JaypeeMedicalPublishers

Shelving Recommendation
ANATOMY

ISBN 978-93-6616-489-2