ebsite www.jaypeebrothers.com,for detailed information on dental books, visit our website www.jaypeebrothers.com

Thoroughly revised multiple choice questions and fill in the blanks according to the latest syllabus of DCI

Includes 2025 Papers

Mastering the BDS IIIrd Year

Last 20 Years Solved Questions

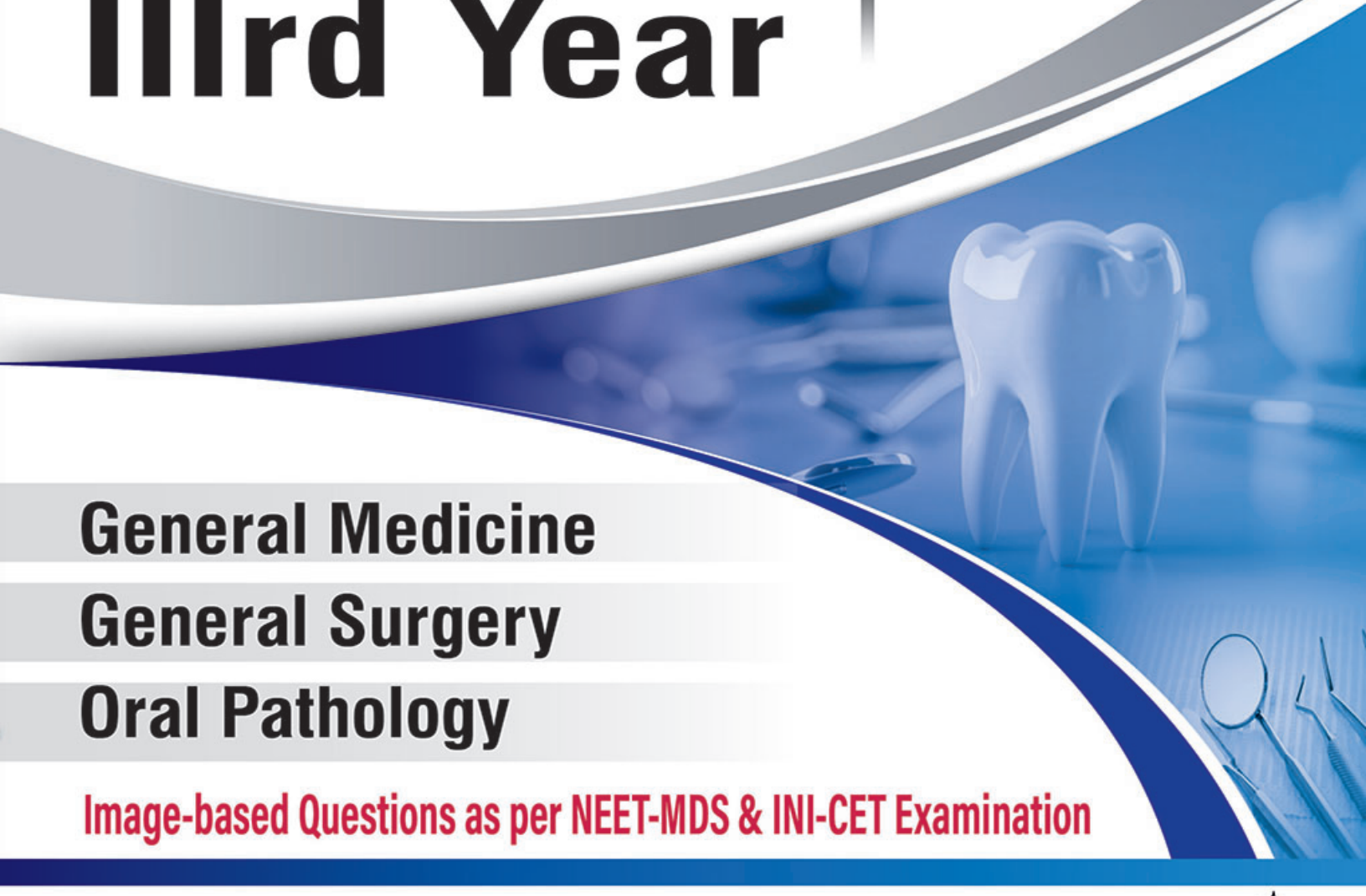

General Medicine
General Surgery
Oral Pathology

Image-based Questions as per NEET-MDS & INI-CET Examination

Hemant Gupta

11th Edition

JAYPEE

Contents

Section 1: General Medicine

1. Introduction 3
2. Diseases of Gastrointestinal Tract 8
3. Diseases of Liver 20
4. Diseases of Cardiovascular System 42
5. Diseases of Respiratory System 84
6. Diseases of Renal System 113
7. Diseases of Blood 125
8. Diseases of Endocrine System 150
9. Nutrition and Metabolic Defects 161
10. Diseases of Nervous System 182
11. Tropical and Infectious Diseases 206
12. Covid-19 (Coronavirus Disease-2019) 239
13. Miscellaneous 242

- **Multiple Choice Questions 264**
- **Fill in the Blanks 288**
- **Viva-voce Questions for Practical Examination 298**
- **Additional Information 301**
- **Classification of Various Pharmacological Drugs 309**
- **One Liners 317**

Section 2: General Surgery

1. Wound, Sinus and Fistula 323
2. Acute Infections 337
3. Specific Infections 346
4. Ulcer 364
5. Lymphatics and Lymph Node Enlargement 372
6. Skin Tumors 383
7. Bleeding Disorders 385
8. Shock 393
9. Burn 408
10. Arterial Diseases 410
11. Venous Diseases 414
12. Reconstruction 418
13. Transplantation 420
14. Cyst 421
15. Oral Cavity, Lip, and Palate 434
16. Maxillary Sinus 455
17. Cleft Lip and Palate 458
18. Oral Cancer 465
19. Neck 482
20. Salivary Gland 489
21. Thyroid and Parathyroid Gland 497
22. Tonsils 518
23. Esophagus and Diaphragm 519
24. Liver 519
25. Gall Bladder 520
26. Spleen 521
27. Stomach 522
28. Small Intestine 523
29. Hernia 524
30. Anesthesia 526
31. Operative Surgery 534
32. Neurological Injuries 541
33. Fractures of Bone 550
34. Advanced Methods of Surgery and Radiology 568
35. Sterilization 571
36. Upper Limb Ischemia 576
37. Intestinal Obstruction 577
38. Appendix 577
39. Rectum and Anal Canal 578
40. Urology 580
41. Miscellaneous 583

- **Multiple Choice Questions 591**
- **Fill in the Blanks 612**
- **Viva-voce Questions for Practical Examination 615**
- **Additional Information 618**
- **One Liners 627**

Section 3: Oral Pathology

1. Developmental Disturbances of Oral and Paraoral Structures 633

2. Cysts of Orofacial Region 655
3. Odontogenic Tumors 665
4. Epithelial Neoplasms of Oral Cavity 673
5. Nonepithelial Neoplasms of the Oral Cavity 690
6. Tumors of Salivary Glands 706
7. Bacterial Infections of Oral Cavity 715
8. Viral Infections 723
9. Mycotic Infections 732
10. Dental Caries 736
11. Diseases of the Pulp and Periapical Tissues 752
12. Periodontal Diseases 756
13. Spread of Oral Infection 761
14. Bone and Joints Diseases 768
15. Hematologic Diseases 777
16. Diseases of Skin 790
17. Diseases of Nerves and Muscles 805
18. Allergic and Immunologic Diseases of Oral Cavity 807
19. Oral Aspects of Metabolic Diseases 810
20. Regressive Alterations of the Teeth 813
21. Physical and Chemical Injuries of the Oral Cavity 822
22. Healing of Oral Wounds 826
23. Forensic Odontology 832
24. Mucosal Response to Oral Prostheses: Some Pathological Considerations 836
25. Routine Staining Procedures 836

❖ **Multiple Choice Questions 839**
❖ **Fill in the Blanks 864**
❖ **Viva-voce Questions for Practical Examination 867**
❖ **Additional Information 871**
❖ **Important Classifications 879**
❖ **One Liners 893**

Image-based Questions 899

Synopsis on COVID-19 915

SECTION 2

General Surgery

1. Wound, Sinus and Fistula
2. Acute Infections
3. Specific Infections
4. Ulcer
5. Lymphatics and Lymph Node Enlargement
6. Skin Tumors
7. Bleeding Disorders
8. Shock
9. Burn
10. Arterial Diseases
11. Venous Diseases
12. Reconstruction
13. Transplantation
14. Cyst
15. Oral Cavity, Lip, and Palate
16. Maxillary Sinus
17. Cleft Lip and Palate
18. Oral Cancer
19. Neck
20. Salivary Gland
21. Thyroid and Parathyroid Gland
22. Tonsils
23. Esophagus and Diaphragm
24. Liver
25. Gall Bladder
26. Spleen
27. Stomach
28. Small Intestine
29. Hernia
30. Anesthesia
31. Operative Surgery
32. Neurological Injuries
33. Fractures of Bone
34. Advanced Methods of Surgery and Radiology
35. Sterilization
36. Upper Limb Ischemia
37. Intestinal Obstruction
38. Appendix
39. Rectum and Anal Canal
40. Urology
41. Miscellaneous

Multiple Choice Questions as per DCI and Examination Papers of Various Universities

Fill in the Blanks

Viva-Voce Questions for Practical Examination

Additional Information

One Liners

JAYPEE BROTHERS

JAYPEE BROTHERS

GENERAL SURGERY

1. WOUND, SINUS AND FISTULA

Q.1. Write short note on lacerated wound.

(Sep 2008, 3 Marks)

Ans. Lacerated wound is an open wound.

- Lacerated wounds are caused by the blunt objects like fall on the stone or due to road traffic accident.
- Edges of lacerated wound are *jagged.
- Injury involves skin or subcutaneous tissue or sometimes deeper structures also.
- In the lacerated wound, there is crushing of tissue due to blunt nature of the object, which results in hematoma, bruising, or even necrosis of tissue.

Management

Ideal form of management of incised or lacerated wound is surgical inspection, cleaning, excision and closure, under appropriate anesthesia and *tourniquet in case of a limb.

- Wound must be thoroughly inspected to ensure that there is no damage to deep structure, or where encountered, there must be repaired.
- All dirt and foreign material must be removed.
- Excision of damage skin, wound margins and excision of devitalized tissue, such as muscle and fascia.
- After excision, wound is irrigated with antiseptic agent and then suturing must be done.
- There are precise suture placement technique for nerves, tendons and blood vessels.
- Muscles can be apposed in layer by mattress suture and fascia and subcutaneous fat should be apposed by interrupted absorbable suture to allow a firm platform for skin closure.
- On the face, fine nylon suture should be placed near to the wound margins, to be removed on the 5th day.
- An alternative to suturing is the application of adhesive tape strips.
- Systemic antibiotics should be given
- Injection tetanus toxoid for prophylaxis against tetanus.

Q.2. Enumerate the various types of surgical wounds and describe their management.

(Apr 2010, 15 Marks) (Apr 2008, 15 Marks)

Ans. Surgical wounds are classified into four categories according to possibility of infection occurring in them.

Management of Surgical Wounds

- Airways should be maintained.
- Bleeding of the patient should be controlled.
- IV fluids should be started.
- If it is an incised wound, then primary suturing is done after thorough cleaning.
- If it is a lacerated wound, then it is excised and primary suturing is done.
- If it is a crushed wound, there will be edema and tension in wound. In such cases, debridement of wound is done and all the devitalized tissues are excised, edema should subside in 5–6 days. Afterwards delayed primary suturing is done.
- If the wound is deep devitalized, debridement of wound is done and it is allowed to granulate completely. If wound is small secondary suturing is done. If wound is large, split skin graft is used to cover the defect.
- If wound is with tension, then fasciotomy is done.
- Antibiotics, fluid and electrolytic balance, blood transfusion, tetanus toxoid or antitetanus globulin injection.

Classification of Surgical Wounds

See Table below:

Wound class	Definition	Examples of typical procedure	Wound infection rate	Usual organism
Clean	Nontraumatic	Mastectomy	2%	*Staphylococcus aureus*
	Elective surgery	Vascular procedure		
	Gastrointestinal, respiratory or genitourinary tract not entered			
Clean contaminated	Respiratory Genitourinary or gastrointestinal tracts entered but minimal contamination	Gastrectomy, hysterectomy, cholecystectomy	<10%	Related to viscous entered
Contaminated	Open, fresh, traumatic wounds. Uncontrolled spillage from an unprepared viscous. Minor break in sterile technique.	Ruptured appendix, resection of unprepared bowel	15–30%	Depend upon underlying causes
Dirty	Open, traumatic dirty wounds. Traumatic perforated viscous. Pus in operative field	Resection of gangrene	40–70%	Depend upon underlying causes

Q1. *Jagged = Unevenly cut or torn.
*Tourniquet = Any constrictor used on an extremity to apply pressure over an artery and thereby control bleeding.

JAYPEE BROTHERS

Q.3. Write short note on keloid.

(Feb 2013, 5 Marks) (Apr 2008, 5 Marks)

Or

Write short answer on keloid. *(Feb 2021, 3 Marks)*

Ans. Keloid means like a claw.

- In keloid, there is defect in maturation and stabilization of collagen fibrils. Normal collagen bundles are absent.
- Keloid is common in blacks.
- It is more common in females.
- It is genetically predisposed, often familial and is very rare in Caucasians.
- Keloid continues to grow even after 6 months, may be for many years. It extends into adjacent normal skin. It is brownish black/pinkish black (due to vascularity) in color, painful, tender and sometimes hyperesthetic; spreads and causes itching.
- Keloid may be associated with Ehlers–Danlos syndrome or scleroderma.
- When keloid occurs following an unnoticed trauma without scar formation is called as spontaneous keloid, commonly seen in Negroes.
- Some keloids occasionally become nonprogressive after initial growth.
- Pathologically, keloid contains proliferating immature fibroblasts, proliferating immature blood vessels and type III thick collagen stroma.
- Keloid is common over the sternum. Other sites are upper arm, chest wall, lower neck in front.

Precipitating Factors

- Negro race
- Tuberculosis patient
- Vaccination site.

Complications

- Ulceration
- Infection.

Treatment

- *Steroid injection:* Intrakeloidal triamcinolone, is injected at regular intervals, may be once in 7–10 days, of 6–8 injections. Its sequence is steroid injection-excision-steroid injection.
- Methotrexate and vitamin A therapy into the keloid.
- Compressive dressings with silicone gel sheets reduce the tendency of keloid to recur.
- Laser therapy can be given.
- Vitamin E/palm oil massage.
- Intralesional excision retaining the scar margin may prevent recurrence. It is ideal and better than just excision.
- Excision and skin grafting may be done.

Q.4 Classify wound and describe in detail the stage of wound healing. *(Sep 2006, 15 Marks)*

Or

Enumerate and describe stages of wound healing.

(May 2021, 3 Marks)

Ans. Wound is discontinuity or break in epithelium.

A wound is break in the integrity of skin or tissues often which may be associated with disruption of the structure and function.

Classification of Wound

- **Rank and Wakefield classification**
  - *Tidy wounds:*
    - They are wounds, such as surgical incisions and wounds caused by sharp objects.
    - It is incised, clean, healthy wound without any tissue loss.
    - Usually, primary suturing is done. Healing is by primary intention.
  - *Untidy wounds:*
    - They are due to crushing, tearing, avulsion, devitalized injury, vascular injury, multiple irregular wounds, burns.
    - Fracture of the underlying bone may be present.
    - Wound dehiscence, infection, delayed healing are common.
    - Liberal excision of devitalized tissue and allowing to heal by secondary intention is the management.
    - Secondary suturing, skin graft or flap may be needed.
- **Classification based on type of wound**
  - Clean incised wound
  - Lacerated wounds
  - Bruising and contusion
  - Hematoma
  - Closed blunt injury
  - Puncture wounds and bites
  - Abrasion
  - Traction and avulsion injury
  - Crush injury
  - War wounds and gunshot injuries
  - Injuries to bones and joints, may be open or closed
  - Injuries to nerves, either clean cut or crush
  - Injuries to arteries and veins (major vessels)
  - Injury to internal organs, may be of penetrating or non-penetrating (blunt) types
  - Penetrating wounds.
- **Classification based on thickness of the wound**
  - Superficial wound
  - Partial thickness wound
  - Full thickness wound
  - Deep wounds
  - Complicated wounds
  - Penetrating wound.
- **Classification based on involvement of structures**
  - Simple wounds
  - Combined wounds.
- **Classification based on the time elapsed**
  - Acute wound
  - Chronic wound.
- **Classification of surgical wounds**
  - Clean wound
  - Clean contaminated wound
  - Contaminated wound
  - Dirty infected wound

Enumeration of Stages of Wound Healing

- Epithelialization
- Wound contraction
- Connective tissue formation
- Scar formation

JAYPEE BROTHERS

Stages of Wound Healing

- **Epithelialization:** Epithelialization occurs mainly from the edges of wound by process of cell migration and multiplication. This is brought about by marginal basal cells. Thus within 48 hours entire wound is re-epithelialized.
- **Wound contraction:** It starts after 4 days and usually complete by 14 days. It is brought about by specialized fibroblasts. Because of their contractile elements, they are called as myofibroblasts. Wound contraction readily occurs when there is loose skin as in back.
- **Connective tissue formation:** Formation of granulation tissue is most important and fundamental step in wound healing. Injury results in release of mediators of inflammation. This result in increased capillary permeability, later kinins and prostaglandin act and play chemotactic role for white cells and fibroblasts. In first 48 hours, polymorphonuclear (PMN) leukocytes dominate. They play role of scavengers by removing dead and necrotic tissue. Between 3rd and 5th day, PMN leukocytes diminished but monocytes increases. By 5th or 6th day, fibroblasts appear which proliferate and eventually give rise to protocollagen, which is converted in collagen in presence of enzyme protocollagen hydroxylase; O2, ferrous ion and ascorbic acid are necessary. The wound is fiber-gel-fluid system.
- **Scar formation:** Following changes takes place during scar formation:
  - *Fibroplasia and lying of collagen is increased.
  - Vascularity becomes less.
  - Epithelialization continues.
  - Ingrowth of lymphatics and nerve fiber takes place.
  - Remodeling of collagen takes place with cicatrization result in scar.

Q.5. Write short note on preauricular sinus.

(Sep 2006, 5 Marks) (Mar 2009, 5 Marks)

Ans. It is a congenital entity occurring due to imperfect fusion of the six tubercles which form ear cartilage.

Clinical Features

- It is seen since childhood.
- It can be unilateral or bilateral.
- Often swelling appears and apparently disappears repeatedly.
- Pain and discharge is common.
- It causes a cosmetic problem in young individual.
- Sinus opening may be seen at the root of the helix or on the tragus.
- Track is quiet deep running backwards, slightly upwards towards the helix. It usually ends blindly.
- Outer opening of the sinus often closed causing formation of a cystic swelling which contains fluid which is often infected.
- Preauricular sinus in no instance will communicate with the external auditory meatus.
- Bursting of this swelling leads into formation of ulcer like lesion.
- Occasionally, multiple sinuses are seen.
- Opening of the sinus occurs in a small triangular area in front of the ear at the level of the tragus.
- Scarring is common around the opening due to repeated infection.

Investigations

- Discharge study should be done.
- Sinusogram is done to assess the track.
- MR sinusogram is beneficial.

Differential Diagnosis

- Cold abscess
- Sebaceous cyst

Treatment

- If sinus is infected antibiotics and drainage are required followed by excision when infection passes off.
- Under general anesthesia complete excision of tract is only recommended.

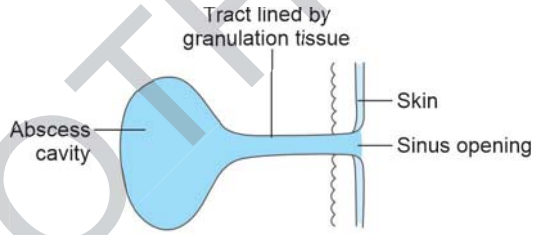

Sinus

Fig. 1: Sinus.

Q.6. Write short note on mental sinus.

(Sep 2006, 5 Marks)

Ans. It is a chronic infective acquired condition, wherein there is infection of roots of one or both lower incisor teeth forming root abscess which eventually tracks down between two halves of lower jaw in the midline presenting as discharging sinus on the point of chin at midline.

Clinical Features

- Usually painless discharging sinus in the midline on the point of chin.
- Often incisor infection may be revealed.
- Osteomyelitis of the mandible is the possible complication.
- Pus discharges through the sinus in center of chin.
- Patient present with recurrent swelling in submental region, which burst, open subcutaneously discharging mucus and seropurulent fluid at times.
- There is repeated history of swelling, discharge and healing which are the common presentations.

Investigations

- Dental X-ray is diagnostic.
- Discharge study should be done.

Differential Diagnosis

- Infected sebaceous cyst
- Tuberculous sinus
- Osteomyelitis

Q4. *Fibroplasia = Developing of fibrous tissue.

JAYPEE BROTHERS

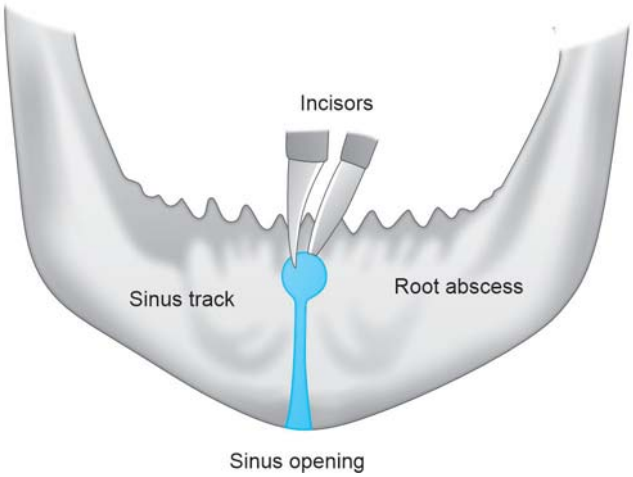

Fig. 2: Mental sinus.

Treatment

- After doing discharge surgery, antibiotics should be given.
- Opening and excision of sinus tract with extraction of incisor tooth/teeth.

Q.7. Write short note on crushed lacerated wound.

(Apr 2007, 10 Marks)

Ans.

- Crushed lacerated wound is caused by road accidents, or a machinery accidents.
- Crushing of the parts with lacerated skin, devitalization or crushing of the musculature is seen. These devitalized tissues must be excised in order to obtain proper healing.
- Damage to blood vessels and nerves with associated profuse bleeding is also observed. The bone or bones are shattered.
- The wound is highly contaminated.
- There can be loss of soft/hard tissue.

Treatment of Crushed Lacerated Wound

- Cleaning of wound
- Removal of foreign bodies
- Debridement
- Hemostasis
- Closure in layers, i.e., primary closure
- Dressing
- Prevention of infection
- Pain control
- Follow up.

Q.8. Write short note on sinus and fistula.

(Jan 2012, 5 Marks) (Dec 2007, 3 Marks)

Or

Write short answer on sinus and fistula.

(June 2018, 3 Marks)

Or

Write brief answer on sinus and fistula.

(Nov 2019, 3 Marks)

Or

Define fistula. Give two examples. *(Apr 2024, 3 Marks)*

Or

Write short answer on fistula and sinus.

(Feb 2025, 3 Marks)

Ans.

Sinus

It is a blind tract leading from the surface down into the tissues. It is lined with a granulation tissue.

Causes

- *Congenital sinus:* Preauricular sinus.
- *Acquired sinus:*
  - *Median mental sinus:* Occurs as a result of tooth abscess.
  - *Pilonidal sinus:* Occurs in the midline in the anal region.
  - *Osteomyelitis:* Gives rise to sinus discharging pus with or without bony spicules.

Fistula

It is an abnormal communication between the lumen of one viscus and the lumen of another (internal) or communication of one hollow viscus with the exterior, i.e., body surface (external fistula).

- *Examples of internal fistula:*
  - Tracheoesophageal fistula
  - Colovesical fistula
- *Examples of external fistula:*
  - Orocutaneous fistula due to carcinoma of the oral cavity infiltrating the skin
  - Branchial fistula
  - Thyroglossal fistula

Clinical Features of Sinus/Fistula

- Discharge from the opening of sinus
- No floor is present
- Raised indurated edge, indurated base and nonmobile
- Often sprouting granulation tissue over sinus opening.
- Bone thickening in osteomyelitis
- Surrounding skin may be erythematous and inflammatory. Bluish in tuberculosis, excoriated in fecal fistula, pigmented in chronic sinuses and fistulas.
- Induration is the feature of all chronic fistulas except tuberculosis.
- Discharge typical of the cause will be evident which will be obvious after applying pressure over surrounding area.
- Thickening of the bone underneath on palpation if sinus is adherent to bone or if there is osteomyelitis.
- Enlargement of regional lymph nodes is present.
- Sinus can be single or multiple.

Investigations

- Fistulogram/Sinusogram using ultra fluid lipiodol or water soluble iodine dye.
- Biopsy from edge for tuberculosis and malignancy
- X-ray of the involved part.
- Proctoscopy of fistula.
- Discharge for C/S, AFB, cytology, staining.
- CT sinusogram
- Probing gently with care
- Digital examination of rectum and proctoscopy in fistula in ano.

JAYPEE BROTHERS

Treatment

- Cause should be treated
- Excision of sinus or fistula and specimen should be sent for histology
- Antibiotics, antitubercular drugs, rest and adequate drainage.

Q.9. Write short note on complication of furunculosis.

(Dec 2007, 3 Marks)

Ans. Furunculosis is the recurring presence of pus-filled sores, known as boils, on the skin.

Following are the complications of furunculosis:

- Carbuncles
- Cellulitis
- Gangrene
- Necrotizing fasciitis
- Hidradenitis suppurativa (infection in group of hair follicles)
- Lymphadenitis
- Cavernous sinus thrombosis.

Q.10. Describe wounds, their classification, wound healing and its treatment. *(Jan 2011, 10 Marks)*

Ans. *For description of wound, its classification and wound healing refer to Ans. 4 of same chapter.*

Treatment

- Wound is inspected and classified as per the type of wounds.
- If it is in the vital area, then:
  - The airway should be maintained.
  - The bleeding, if present, should be controlled.
  - Intravenous fluids are started.
  - Oxygen, if required, may be given.
  - Deeper communicating injuries and fractures, etc., should be looked for.
- If it is an incised wound, then primary suturing is done after thorough cleaning.
- If it is a lacerated wound, then the wound is excised and primary suturing is done.
- If it is a crushed or devitalized wound, then there will be edema and tension in the wound. So after wound debridement or wound excision by excising all devitalized tissue, the edema is allowed to subside for 2–6 days. Then, delayed primary suturing is done.
- If it is a deep devitalized wound, after wound debridement it is allowed to granulate completely. Later, if the wound is small secondary suturing is done.
- In a wound with tension, fasciotomy is done so as to prevent the development of compartment syndrome.
- Antibiotics, fluid and electrolyte balance, blood transfusion, tetanus toxoid (0.5 mL intramuscular to deltoid muscle), or antitetanus globulin (ATG) injection.
- Wound debridement (wound toilet, or wound excision) is liberal excision of all devitalized tissue at regular intervals.

Q.11. Write short note on complications of wounds.

(Dec 2007, 5 Marks)

Ans.

Complications of Wounds

- **Infection:** It is the most important complication which is responsible for delay in wound healing. Bacteria mainly remain endogenous. Based on pus culture and blood report antibiotics should be prescribed.
- **Scar:** Present due to infection.
- Hypertrophic scar and keloid formation due to altered collagen synthesis in wound healing process.
- Skin pigmentation
- **Marjolin ulcer:** As repeated breakdown of hypertrophic scar occurs it becomes Marjolin's ulcer.

Q.12. Write short note on general factors affecting wound healing. *(Feb 2013, 5 Marks)*

Ans.

General Factors

General factors affecting wound healing are as follows:

- Age
- Malnutrition
- Vitamin deficiency (vitamin C, vitamin A)
- Anemia
- Malignancy
- Uremia
- Jaundice
- Diabetes, metabolic diseases
- HIV and immunosuppressive diseases
- Steroids and cytotoxic drugs

Age: In younger age group, wound healing is faster and better while in elderly healing is delayed due to reduction in collagen synthesis, epithelialization, growth factors and angiogenesis. But final scar will be excellent in old individuals.

Malnutrition and vitamin deficiency: Adequate vitamin, trace elements, fatty acids and proteins are essential for wound healing. Vitamin A deficiency affects monocyte activation, inflammatory phase, collagen synthesis and growth factor actions. Vitamin K deficiency affects synthesis of prothrombin (ll), factors VII, IX andX. vitamin E, being an antioxidant stabilizes the cell membrane. Vitamin C deficiency impairs collagen synthesis, fibroblast proliferation and angiogenesis; increases the capillary fragility and susceptibility for infection. Zinc is an essential cofactor for RNA and DNA polymerase; magnesium is a co-factor for synthesis of proteins and collagen; copper is a required co-factor for cytochrome oxidase.

Anemia: Hemoglobin less than 8% causes poor oxygenation of tissues preventing healing of the wounds.

Diabetes mellitus: In diabetic patients, wound healing is delayed because of several factors, such as microangiopathy, atherosclerosis, decreased phagocytic activity, proliferation of bacteria due to high blood sugar etc.

Metabolic causes: Obesity causes hypoperfusion, reduced microcirculation, increased wound tension, and hence prevents wound healing.

Jaundice and uremia: Jaundiced and uremic patients have poor wound healing because fibroblastic repair is delayed.

HIV and immunosuppressive diseases and malignancy: HIV and immunosuppression of varying causes, malignancy leads into poor wound healing.

Drugs: Steroids interfere with activation of macrophages, fibroblasts and angiogenesis in the early phase of healing (proliferative). Nonsteroidal anti-inflammatory drugs (NSAIDs) decrease collagen production. Chemotherapeutic agents used in oncology inhibit cellular proliferation, protein synthesis.

JAYPEE BROTHERS

Alcohol consumption decreases the phagocyte response and proinflammatory cytokine release; diminishes host response and thus increasing the infection rate.

Q.13. Write short note on hypertrophic scar.

(May/June 2009, 5 Marks)

Or

Write short answer on hypertrophic scar.

(June 2022, 3 Marks) (Sep 2018, 3 Marks)

Ans. In hypertrophic scar, there is hypertrophy of mature fibroblasts. Blood vessels are minimum in this condition.

- It can occur anywhere in the body.
- Growth limits up to 6 months.
- Hypertrophic scar is limited to scar tissue and does not extend to normal skin.
- It is pale brown in color and is nontender.
- It is self-limiting.
- It is common in wounds crossing tension lines, deep dermal burns, wounds heal by secondary intension.

Complications

- Scar breaks repeatedly and cause infection and pain.
- After repeated breakdown, it may turn into Marjolin's ulcer.

Treatment

- It is controlled by pressure garments or often revision excision of scar and closure if required with skin graft.
- Triamcinolone injection is second line of therapy.

Q.14. Discuss briefly branchial fistula.

(May/Jun 2009, 5 Marks)

Or

Write in brief on branchial fistula. *(Aug 2011, 5 Marks)*

Or

Write short answer on branchial fistula.

(Apr 2019, 3 Marks)

Ans. Branchial fistula is commonly a congenital lesion.

- It is persistent precervical sinus between 2nd branchial cleft and 5th branchial cleft having opening in the skin at lower l/3rd of neck on the inner margin of sternocleidomastoid muscle, often ends as a sinus just proximal to the posterior pillar of fauces behind tonsil which is also the site of inner opening when presents as a fistula.
- Fistula runs between the structures related to second and 3rd branchial arches. From external opening at skin below, it runs in subcutaneous plane to pierce deep fascia at level of thyroid cartilage; to travel between 2nd arch artery and third arch artery behind posterior digastric belly and stylohyoid; outer to stylopharyngeus, hypoglossal and glossopharyngeal nerves; perforates superior constrictor to reach the internal opening.
- Occasionally, acquired branchial fistula can occur due to rupture of or after drainage of infected branchial cyst or incomplete excision of the cyst tract. This type of fistula is located outside the skin at the level of upper third of sternomastoid muscle.

Clinical Features

- It is a persistent second branchial cleft with a communication outside to the exterior. It is commonly a congenital fistula.
- Occasionally, the condition is secondary to incised infected branchial cyst.
- Often it is bilateral.
- External orifice of the fistula is situated in the lower third of the neck near the anterior border of the sternomastoid muscle.
- Internal orifice is located on the anterior aspect of the posterior pillar of the fauces, just behind the tonsils.
- Sometimes fistula ends internally as blind end.
- It is common in children and early adolescent period. Its occurrence is equal in both sexes.
- External orifice is very small with a dimple which becomes more prominent on dysphagia with tuck in appearance.
- Discharge is mucoid or mucopurulent.

Treatment

Only surgical treatment is the choice.

- Under general anesthesia, methylene blue is injected into the tract. Probe is passed into the fistulous tract. Through circumferential/elliptical incision around the fistula opening, entire length of the tract is dissected until the internal orifice. Care should be taken to safeguard carotids, jugular vein, hypoglossal nerve, glossopharyngeal nerve and spinal accessory nerve. Entire tract should be excised.
- Step-ladder dissection is done using two parallel incisions one below at lower part another above at upper part of the neck, will make dissection easier and complete.

Q.15. Describe briefly primary and secondary healing of wounds. *(Jun 2010, 5 Marks)*

Ans.

Primary Healing of Wound

- In primary healing of wound, edges are approximated by surgical sutures.
  - In the initial phase, there will be formation of blood clot, which helps to hold the parts of the wound together.
- The tissue becomes edematous and an inflammatory process starts, with the infiltration of polymorphonuclear neutrophils (PMN) and lymphocytes into the area.
- The tissue debris collected in the wound are cleared either by the process of phagocytosis or by their lysis with the help of proteolytic enzymes, liberated by the inflammatory cells.
- Once the tissue debris are cleared, granulation tissue forms that replaces the blood clot in the wound, and it usually consists of young blood capillaries, proliferating fibroblasts, PMN and other leukocytes.
- The epithelium at the edge of the wound starts to proliferate and gradually, it covers the entire wound surface.
- Finally, the healing process is complete with progressive increase in the amount of dense collagen bundles and decrease in the number of inflammatory cells in the area.

Secondary Healing of Wound

- When the opposing margins of the wound cannot be approximated together by suturing, the wound fills in from the base with the formation of a larger amount of granulation tissue, such type of healing of the open wound

JAYPEE BROTHERS

is known as healing by "secondary intention" or "secondary healing".
- The secondary healing occurs essentially by the same process as seen in the primary healing, the only difference is that a more severe inflammatory reaction and an exuberant fibroblastic and endothelial cell proliferation occur in the later.
- In secondary healing, once the blood clot is removed, the granulation tissue fills up the entire area and the epithelium begins to grow over it, until the wound surface is completely epithelized.
- Later on, the inflammatory exudates disappear slowly and the fibroblasts produce large amounts of collagen.
- Most of the healing processes occurring due to secondary intention, result in scar formation at the healing site.

However, in the oral cavity these are rare.

Q.16. Write briefly on factors influencing wound healing.

(Aug 2011, 5 Marks)

Ans.

General Factors

General factors affecting wound healing are as follows:
- Age
- Malnutrition
- Vitamin deficiency (vitamin C, vitamin A)
- Anemia
- Malignancy
- Uremia
- Jaundice
- Diabetes, metabolic diseases
- HIV and immunosuppressive diseases
- Steroids and cytotoxic drugs

Age: In younger age group, wound healing is faster and better while in elderly healing is delayed due to reduction in collagen synthesis, epithelialization, growth factors and angiogenesis. But final scar will be excellent in old individuals.

Malnutrition and vitamin deficiency: Adequate vitamin, trace elements, fatty acids and proteins are essential for wound healing. Vitamin A deficiency affects monocyte activation, inflammatory phase, collagen synthesis and growth factor actions. Vitamin K deficiency affects synthesis of prothrombin (ll), factors VII, IX and X. Vitamin E, being an antioxidant stabilizes the cell membrane. Vitamin C deficiency impairs collagen synthesis, fibroblast proliferation and angiogenesis; increases the capillary fragility and susceptibility for infection. Zinc is an essential cofactor for RNA and DNA polymerase; magnesium is a cofactor for synthesis of proteins and collagen; copper is a required cofactor for cytochrome oxidase.

Anemia: Hemoglobin <8% causes poor oxygenation of tissues preventing healing of the wounds.

Diabetes mellitus: In diabetic patients, wound healing is delayed because of several factors, such as microangiopathy, atherosclerosis, decreased phagocytic activity, proliferation of bacteria due to high blood sugar, etc.

Metabolic causes: Obesity causes hypoperfusion, reduced microcirculation, increased wound tension, and hence prevents wound healing.

Jaundice and uremia: Jaundiced and uremic patients have poor wound healing because fibroblastic repair is delayed.

HIV and immunosuppressive diseases and malignancy: HIV and immunosuppression of varying causes, malignancy leads into poor wound healing.

Drugs: Steroids interfere with activation of macrophages, fibroblasts and angiogenesis in the early phase of healing (proliferative). Nonsteroidal anti-inflammatory drugs (NSAIDs) decrease collagen production. Chemotherapeutic agents used in oncology inhibit cellular proliferation, protein synthesis. Alcohol consumption decreases the phagocyte response and proinflammatory cytokine release; diminishes host response and thus increasing the infection rate.

Local Factors

Local factors affecting wound healing are as follows:
- Infection
- Presence of necrotic tissue and foreign body
- Poor blood supply
- Venous or lymph stasis
- Tissue tension
- Hematoma
- Large defect or poor apposition
- Recurrent trauma
- X-ray irradiated area
- Site of wound
- Underlying diseases, such as osteomyelitis and malignancy
- Mechanism and type of wound-incised/lacerated/crush/avulsion
- Tissue hypoxia locally reduces macrophage and fibroblast activity

Wound infection: Infection prolongs inflammatory phase, releases toxins and utilizes vital nutrients thereby prevents wound epithelialization. The β-hemolytic streptococci more than 105 per g of tissue prevent wounds healing. Formation of biofilms on the wound surface by microorganisms prevents wound healing.

Presence of necrotic tissue and foreign body: Necrotic tissue and foreign bodies, such as sutures cause intense inflammatory reaction and infection.

Poor blood supply: Improper blood supply to wound delays wound healing.

Tissue tension: It affects quantity, aggregation and orientation of collagen fibers.

Hematoma: It precipitates infection and delays wound healing.
Hypoxia: Hypoxia prevents fibroblast proliferation and collagen synthesis; it also promotes bacterial invasion into the wound.

Site of wound: Movement of wound area delays wound healing. e.g., wound over the joints and back has poor healing.

X-ray irradiated area: Both external radiotherapy or ionizing radiation cause endarteritis, fibrosis and delay in wound healing. Radiation may itself cause local tissue necrosis, sepsis and hypoxia.

Poor apposition: Poor apposition leads to the infection in the wound area which delays healing.

JAYPEE BROTHERS

Q.17. Define and describe differentiating features of incised wound and lacerated wound. *(Jan 2012, 5 Marks)*

Ans.

Incised wound	Lacerated wound
This wound is caused by sharp objects, such as knife, blade, glass, etc.	They are caused by blunt objects, such as fall on a stone or due to road traffic accidents
Edges of wound are sharp	Edges of wound are jagged
Contamination is less	Contamination is more
Does not involve deeper structures	Involve deeper structures
Crushing of tissue does not occur	Crushing of tissue is present
Only primary suturing is done	Wound excision and primary suturing is done

Q.18. Write short note on causes of delayed wound healing. *(Aug 2012, 5 Marks)*

Or

Write short note on delayed wound healing. *(June 2015, 5 Marks)*

Ans. *For the causes of delayed wound healing refer to Ans. 16 in detail.*

Q.19. Discuss the etiology, clinical features and management of wounds. *(Dec 2012, 10 Marks)*

Or

Write short essay answer on classification and management of wounds. *(Apr 2024, 5 Marks)*

Ans. A wound is the break in the integrity of skin or tissues often which may be associated with disruption of structure and function.

Etiology and Clinical Features

- Tidy wounds:
  - They are wounds, such as surgical incisions and wounds caused by sharp objects.
  - It is incised, clean, healthy wound without any tissue loss.
- Untidy wounds:
  - They are due to crushing, tearing, avulsion, devitalized injury, vascular injury, multiple irregular wounds, burns.
  - Fracture of the underlying bone may be present.
  - Wound dehiscence, infection, delayed healing are common.

Classification Based on Type of Wound

- Clean incised wound: It is a clean cut wound with linear edge.
- Lacerated wounds: The lacerated wounds are caused by the blunt objects, such as fall on the stone or due to road traffic accident.
  - The edges of lacerated wound are *jagged.
  - The injury involves skin or subcutaneous tissue or sometimes deeper structures also.
  - In the lacerated wound there is crushing of tissue due to blunt nature of the object.
- Bruising and contusion: It is a minor soft tissue injury with discoloration and hematoma formation without skin break.
- Hematoma: Caused due to injury. It consists of reddish plasmatic fluid which can be aspirated and if it get infected, then pus is formed.
- Closed blunt injury.
- Puncture wounds and bites.
- Abrasion: Occurs due to shearing of skin where surface is rubbed off.
- Traction and avulsion injury.
- Crush injury: It is caused in wars, road traffic accidents, tourniquet.
  - Muscle ischemia is present.
  - Presence of gangrene and loss of tissue.
- War wounds and gunshot injuries.
- Injuries to bones and joints, may be open or closed.
- Injuries to nerves, either clean cut or crush.
- Injuries to arteries and veins (major vessels).
- Injury to internal organs, may be of penetrating or non-penetrating (blunt) types.
- Penetrating wounds.

Classification Based on Thickness of the Wound

- Superficial wound
- Partial thickness wound
- Full thickness wound
- Deep wounds
- Complicated wounds
- Penetrating wound.

Classification Based on Involvement of Structures

- Simple wounds
- Combined wounds.

Classification Based on the Time Elapsed

- Acute wound
- Chronic wound.

Classification of Surgical Wounds

- Clean wound
- Clean contaminated wound
- Contaminated wound
- Dirty infected wound

Management

- Wound is inspected and classified as per the type of wounds.
- If it is in the vital area, then:
  - The airway should be maintained.
  - The bleeding, if present, should be controlled.
  - Intravenous fluids are started.
  - Oxygen, if required, may be given.
  - Deeper communicating injuries and fractures, etc., should be looked for.
- If it is an incised wound, then primary suturing is done after thorough cleaning.
- If it is a lacerated wound, then the wound is excised and primary suturing is done.
- If it is a crushed or devitalized wound, then there will be edema and tension in the wound. So after wound debridement or wound excision by excising all devitalized tissue, the edema is allowed to subside for 2–6 days. Then delayed primary suturing is done.

Q19. *Jagged = Unevenly cut or torn.

JAYPEE BROTHERS

- If it is a deep devitalized wound, after wound debridement it is allowed to granulate completely. Later, if the wound is small secondary suturing is done. If the wound is large a split skin graft (Thiersch graft) is used to cover the defect.
- In a wound with tension, fasciotomy is done so as to prevent the development of compartment syndrome.
- Vascular or nerve injuries are dealt with accordingly.
- Vessels are sutured with 6-zero polypropylene nonabsorbable suture material. If the nerves are having clean-cut wounds then it can be sutured primarily with polypropylene 6-zero or 7-zero suture material. If there is difficulty in identifying the nerve ends, or if there are crushed cut ends of nerves, then marker stitches are placed using silk at the site and later secondary repair of the nerve is done.
- Internal injuries have to be dealt with accordingly. Fractured bone is also identified and properly dealt with.
- Antibiotics, fluid and electrolyte balance, blood transfusion, tetanus toxoid, antitetanus globulin (ATG) injection.
- Wound debridement is liberal excision of all devitalized tissue at regular intervals until healthy, bleeding, vascular tidy wound is created.

Q.20. Enumerate differences between sinus and fistula. *(June 2014, 2 Marks)*

Or

Write differences between sinus and fistula. *(Mar 2021, 2.5 Marks) (Apr 2017, 2 Marks)*

Or

Differences between sinus and fistula. *(Jan 2017, 10 Marks)*

Or

Write differences between fistula and sinus. *(May 2020, 3 Marks) (Feb 2019, 5 Marks)*

Or

Write difference between sinus and fistula and their management. *(July 2023, 8 Marks)*

Ans.

Sinus	Fistula
It is a blind track-lined by granulation tissue leading from an epithelial surface into the surrounding tissues	It is an abnormal communication between the lumen of one viscus to another or the body surface or between the vessels
Congenital cause is preauricular sinus	Congenital cause is branchial fistula, tracheoesophageal fistula, congenital AV fistula and umbilical fistula
Acquired causes are actinomycosis, tuberculosis, pilonidal sinus, chronic osteomyelitis, medial, mental sinus	Acquired causes are traumatic, inflammatory and malignancy
In this a single epithelialized surface is involved	In this, two epithelialized surfaces are involved.
Extension of sinus is from cavity to cavity	Extension of fistula is from cavity to outside.
In oral cavity, sinus is a drainage passage through bone piercing the oral mucosa, e.g., in infections, such as periapical abscess.	Fistula is a passage between two hollow cavities, e.g., oroantral fistula.
On inspection the location of various sinus is: • Preauricular sinus is at root of helix of ear • Sinus of TB is located at neck	On inspection the location of fistula is: • *Branchial fistula:* Sternomastoid anterior border • *Parotid fistula:* Parotid region
It cannot be surgically created.	It can be surgically created for therapeutic reasons.

Q.21. Describe pathophysiology of primary and secondary healing. Enumerate their clinical advantages and disadvantages in tabular form. List when assault becomes a cognizable offence. *(June 2014, 10 Marks)*

Ans. *Pathophysiology of primary and secondary healing means primary and secondary healing of wounds. For details, refer to Ans. 15 of same chapter.*

Assault is the act of creating apprehension of an imminent harmful or offensive contact with a person. Generally, cognizable offence means a police officer has the authority to make an arrest without a warrant and the police is also allowed to start an investigation with or without the permission of a court.

Following are the cognizable offences:

- All grievous hurts
- Simple hurt by dangerous weapon
- Murder
- Culpable homicide
- Causing death by rash or negligence act.
- Dowry death
- Abetment to suicide
- Attempt to murder
- Attempt to commit suicide
- Rape.

Primary healing	
Advantages	**Disadvantages**
Easy for the patient to manage the wound	Risk of wound infection
Rapid return of function of the wounded part final cosmetic result is superior	
Tissue heal closer to normal length	
Blood supply is restored soon	
Wound infection is virtually impossible	Daily dressing changes are required until the wound is healed, which may take some time, and the final result is a cicatrix that may be unsightly
	Final cosmetic result is poor. Granulation results in a broader scar
	Healing process can be slow due to presence of drainage from infection

JAYPEE BROTHERS

Q.22. Enumerate causes for chronicity of sinus and fistula.
(Feb 2014, 3 Marks)

Ans. Following are the causes for chronicity of sinus and fistula:
- A foreign body or necrotic tissue underneath, e.g., suture, sequestrum.
- Insufficient or nondependent drainage
- Persistent obstruction in lumen, e.g., in fecal fistula, biliary fistula
- Lack of rest, persistent infection
- Wall become lined with epithelium and endothelium
- Dense fibrosis prevents contraction and healing
- Specific infections: Tuberculosis and actinomycosis
- Presence of malignant disease, postirradiation.

Q.23. What is primary and secondary healing, advantage of one over other? What are the injuries that constitute cognizable offence in IPC? *(Apr 2015, 10 Marks)*

Ans. Primary healing: It occurs in a clean incised or surgical wound. Edges of the wound are approximated by sutures. Epithelial regeneration is more as compared to fibrosis. Wound healing takes place rapidly with complete closure. Scar will be linear, supple and smooth.

Secondary healing: It occurs in a wound with extensive soft tissue loss like in major trauma, burn, wound with sepsis. Healing by secondary intention occur slowly with fibrosis. This also leads to the formation of wide scar which is hypertrophied and contracted. This can also lead to disability.

For primary and secondary healing in details, refer to Ans. 15 of same chapter.

For advantages of one another, refer to Ans. 21 of same chapter.

Injuries that Constitute Cognizable Offence in IPC

Cognizable offence means an offence for which a police officer may arrest without a warrant.

Following are the cognizable offences:
- Murder (S.302)
- Causing death by rash or negligent act (S.304A)
- Dowry death (S.304B)
- Abetment of suicide (S.306)
- Attempt to commit suicide (S.309)
- Causing miscarriage without women's consent (S.313)
- Grievous hurt (S.325, 326)
- Rape (S.376)
- Theft (S.379).

Q.24. Write short note on granulation tissue.
(Feb 2015, 5 Marks)

Ans. Granulation tissue is the proliferation of newer capillaries along with fibroblasts which are intermingled with RBCs and WBCs with thin fibrin cover over it.

Types of Granulation Tissue

Following are the types of granulation tissue:
- **Healthy granulation tissue**
  - It results in an healing ulcer.
  - It has got a sloping edge with serous discharge.
  - It bleeds on manipulation.
  - Skin graft takes well with healthy granulation tissue.
  - Healthy granulation tissue consists of 5Ps, i.e., pink, punctuate hemorrhage, pulseful, painless, pinhead
- **Unhealthy granulation tissue**
  - This is pale in color with purulent discharge.
  - Floor of granulation tissue is covered with slough.
  - Its edges are inflamed and edematous.
  - It is a type of a spreading ulcer.
- **Unhealthy, pale, flat, granulation tissue**
  - It is seen in chronic nonhealing ulcer.
  - Exuberant granulation tissue
  - It occurs in sinus where granulation tissue protrude out of orifice of sinus as proliferating mass.
  - Mostly associated with retained foreign body in sinus cavity.
- **Pyogenic granuloma**
  - Here granulation tissue protrudes from an infected wound or ulcer bed and presents a well localized, red swelling which bleed on manipulation.
  - It is treated by surgical excision.

Q.25. Write briefly on cognizable offence.
(Jan 2016, 2 Marks)

Ans. Generally, cognizable offence means a police officer has the authority to make an arrest without a warrant and to start an investigation with or without the permission of a court.
- In cognizable offence, police has to record information in writing.
- The police can file a First Information Report (FIR) only for cognizable offences.
- In cognizable offences, police can start investigation without the order of magistrate.
- Cognizable offence is more serious and carry a sentence of 3 years or more.

Q.26. Write difference between hypertrophic scar and keloid.
(Feb 2019, 5 Marks) (Mar 2016, 3 Marks)

Or

Write difference between scar and keloid.
(May 2020, 3 Marks)

Or

Write difference between keloid and hypertrophic scar.
(Apr 2024, 3 Marks)

Ans. Following are differences between hypertrophic scar and keloid:

Features	Hypertrophic scar	Keloid
Genetic predisposition	Yes	No
Site of occurrence	Chest wall, upper arm, lower neck, ear	Anywhere in the body, common in flexor surfaces
Growth	Continues to grow without time limit. Extends to normal skin	Growth limits for 6 months. Limited to scar tissue only
Treatment	Poor response	Good response to steroids
Recurrence	Very high	Is uncommon
Collagen synthesis	20 times more than normal skin (Type III thick)	3–6 times more than normal skin (Type III fine collagen)

Contd...

JAYPEE BROTHERS

for detailed information on dental books, visit our website **www.jaypeebrothers.com**, for detailed information on denta

Mastering the BDS IIIrd Year (Last 20 Years Solved Questions)

Salient Features

- Written in simple and lucid language.
- Provides broad coverage of all the subjects (General Medicine, General Surgery, and Oral Pathology) of BDS IIIrd year.
- Includes vast topics in simple flowcharts, tables, and diagrammatic forms to make the content easy to understand and recall.
- Supports in quick revision during examinations.
- One weapon, three targets, i.e., BDS examinations, PG entrance, and MDS (Basic Sciences): It is the only book written that can be used to clear university graduation exams, postgraduate entrance exams, and basic sciences exam for postgraduate students.

The earlier editions have been immensely popular among the dental students, postgraduate aspirants, and dental practitioners. Other highlights of the 11th edition are:

- Exam-oriented book with a unique collection of the last 20 years' solved question papers.
- Extensively revised and updated chapters to provide knowledge of present era.
- Questions and Answers related to COVID-19 from university papers are covered.
- In Oral Pathology, all the classification of diseases is mentioned separately at the end of section.
- Various recent advances are updated as per their recent revision.
- Consists of solved Multiple Choice Questions (MCQs) and Fill in the Blanks, which are added by the Dental Council of India (DCI) in the latest curriculum.
- General Medicine, General Surgery, and Oral Pathology are thoroughly revised and various answers of previous editions are changed in the latest edition due to change in various concepts and inculcation of new researches.
- Includes Viva-Voce questions with answers which aid students to enhance their skills in practical examinations.
- One Liners are added for quick revision of dental postgraduate entrance examinations such as NEET, PGI, AIIMS, etc.
- Contains illustrations and high-quality photographs with explanatory legends for easy explanation of text.
- Provides recent and internationally accepted classification systems by eminent professional bodies, WHO, CDC, National Health Programs/Guidelines such as ICMR, NCDC, RNTCP, NACO, etc.
- Includes solved papers of years 2024 and 2025, with better and improved answers.
- Explains questions in a point-wise manner for clear overview and eye-catching remembrance.
- Illustrates H & E stained histological photographs in color plates which help students to understand the Oral Pathology section.
- The text, MCQs, and Fill in the Blanks aid students in preparation of Viva-Voce and provide basics for competitive examination.
- Incorporates a clinical overview in various chapters for highlighting the clinical applications.
- A highly structured, user-friendly, systemic, and attractive layout with enriched illustrations.

Most of the features of previous editions are saved.

- Content is more with less pages—handy look is there which saves the time of student.
- Concise, bullet format and to-the-point text which is easy to read during BDS and MDS basic sciences examination.
- Language is simple and lucid which makes the understanding easy.
- MCQs, Fill in the Blanks, Viva-Voce Q & A, Additional Matter, and One Liners are present at end of each subject.

Hemant Gupta MDS (Oral and Maxillofacial Pathology, Microbiology and Forensic Odontology) has two decades of experience of authorship. He is the CEO of Shivom Multispeciality Dental Clinic, Indore, Madhya Pradesh, India. He is a general practitioner and also a consultant as oral cancer diagnostician at various clinics and hospitals. He is an eminent as well as dedicated clinician, practitioner, instructor, and consultant. He has also specialized in pathology techniques such as immunohistochemistry. He has published research papers in various indexed journals of national repute. He has an experience of coaching dental students at a personal level, which helps them to build up the basics in dentistry and also to clear the various university examinations. His pioneer work in Forensic Odontology is on Ameloglyphics.

Dr Gupta has also authored several other popular books which are extremely appreciated among the BDS and MBBS students:

1. Mastering the BDS Ist year
2. Mastering the BDS IInd year
3. Mastering the BDS final year – Part I
4. Mastering the BDS final year – Part II
5. Mastering the MBBS Ist year

Printed in India

Available at all medical bookstores or buy online at www.ejaypee.com

JAYPEE BROTHERS
Medical Publishers (P) Ltd.
EMCA House, 23/23-B, Ansari Road,
Daryaganj, New Delhi - 110 002, INDIA
www.jaypeebrothers.com

Join us on facebook.com/JaypeeMedicalPublishers
Follow us on instagram.com/JaypeeMedicalPublishers

Shelving Recommendation
DENTISTRY

ISBN 978-93-6616-493-9
9 789366 164939