ebrothers.com, for detailed information on dermatology books, visit our website www.jaypeebrothers.com, for detailed information on dermatology books



IADVL SIG Handbook on Psoriasis

Editors
Sudip Das
Abhishek De

Associate Editors
Konakanchi Venkata Chalam
Saurabh Singh

Forewords
Rajeev Sharma
Vinay Singh

JAYPEE

Contents

1. **Introduction to Psoriasis: Definition, Epidemiology, and Etiology** 1
   Anupama YG

2. **Clinical Manifestations of Psoriasis: Plaque, Guttate, Pustular, Erythrodermic, and Inverse Psoriasis** 7
   Kethireddi Susmitha Divya, Susmitha Meda

3. **Pathophysiology of Psoriasis: Immune System Dysfunction, Genetics, and Triggers** 23
   Bikash Ranjan Kar, Kallolinee Samal

4. **Differential Diagnosis of Psoriasis: Distinguishing Psoriasis from Other Dermatological Conditions** 36
   Rajesh Kumar, Ayesha Merchant, Datta Lokare, Disha Chakraborty

5. **Psoriasis: Relation with Probiotics, Prebiotics, and Gut Dysbiosis** 51
   Sambit Chatterjee, Anupam Das

6. **Comorbidities Associated with Psoriasis: Cardiovascular Disease, Metabolic Syndrome, and Depression** 54
   Sudip Das, Apeksha Singh

7. **Assessment and Scoring of Psoriasis Severity: PASI and Other Scales** 65
   Dipra Biswas, Saurabh Singh

8. **Topical Treatments for Psoriasis** 72
   KA Seetharam, K Venkatesh

9. **Phototherapy in the Management of Psoriasis** 82
   Chinmoy Raj, Debasmita Behera, CR Srinivas

10. **Conventional Systemic Therapies in Psoriasis** 100
    Konakanchi Venkata Chalam, Kavya Baddireddy

11. **Small Molecules in Psoriasis** 114
    Farhat Fatima, SK Shahriar Ahmed, Sudip Das

12. **Use of Biologics in Psoriasis** 121
    Abhishek De, Disha Chakraborty

13. **Combination and Rotational Therapy in the Management of Psoriasis** 139
    Lydia Mathew, Dharshini Sathishkumar

14. Management of Psoriatic Arthritis: Diagnosis and Treatment Options **153**
Ashish Jacob Mathew

15. Pustular Psoriasis **169**
Sudip Das, SK Shahriar Ahmed

16. Special Considerations in Psoriasis Management: Pregnancy, Children, and Elderly Patients **175**
Neena Khanna, Sachin Gupta

17. Psoriasis and Quality of Life: Impact on Patients' Daily Lives and Mental Health **183**
Sanjeev Handa, Sukhdeep Singh, Tarun Narang

18. Psoriasis and Dermatology Practice: Clinical Pearls and Best Practices for Patient Management **189**
Manjeet Naresh Ramteke

19. Patient Education and Support: Strategies for Improving Patient Adherence and Self-management **198**
Satyaki Ganguly, Akshay Sankar Peethambaran

20. Case Studies in Psoriasis Management: Real-World Applications of Psoriasis Diagnosis and Treatment **203**
Shekhar Neema, Siddharth Mani

21. Novel Therapeutic Targets in Psoriasis: Biologics, Small Molecules, and Cell-based Therapies **214**
Shraddha Madanagobalane

22. Overview of Psoriasis Research Trends **234**
Shraddha Madanagobalane

23. Personalized Medicine in Psoriasis **244**
Shraddha Madanagobalane

24. Advances in Psoriasis Research: Genomics, Proteomics, and Bioinformatics **253**
Shraddha Madanagobalane, Madhumitha Venugopal

Index ***261***

15

Pustular Psoriasis

Sudip Das, SK Shahriar Ahmed

JAYPEE BROTHERS

INTRODUCTION

Pustular psoriasis (PP) is a chronic, multisystemic, autoinflammatory disease, which presents with widespread, macroscopic, aseptic pustules. Its clinical course is extremely variable, diverse, and unexpected. Its heterogeneous, cutaneous, and extracutaneous symptoms pose considerable challenges to the timely diagnosis and treatment. It was first reported by Leo Ritter von Zumbusch in 1910.[1] Dysregulation of the interleukin-36 (IL-36) signaling cascade pathway plays a key role in the pathogenesis of PP. The altered expression of various IL-36 pathway constituents has been shown to cause excess production of inflammatory cytokines and neutrophil recruitment in the epidermis.[2] The associated morbidity is high, which can lead to a significant impact on quality of life (QoL) or life-threatening emergencies. In 2017, the European Rare and Severe Psoriasis Expert Network (ERASPEN) defined generalized pustular psoriasis (GPP) as primary, sterile, macroscopically visible pustules on nonacral skin. GPP subclassifiers are (1) with or without systemic inflammation, (2) with or without plaque psoriasis, and (3) either relapsing (>1 episode) or persistent (>3 months).

According to ERASPEN, a diagnosis of GPP can be made only when the condition has relapsed at least once or has persisted for >3 months.[3] There is a dearth of GPP data in India. Nonetheless, GPP is regarded as a rare disease due to its extremely low incidence and frequency. Globally, the prevalence of GPP can be estimated as 1–7 cases per million persons. However, data are variable, and estimations range from 1.76 cases per million in France to 7.46 cases per million in Japan, and 180 cases per million in Italy.[4-6] Although GPP can manifest at any age, from infancy to old age, the typical age at diagnosis is approximately 50 years old. GPP patients generally have a majority of females. Patients with the *IL36RN* mutation are more prone to experience early-onset GPP.[7-10]

EPIDEMIOLOGY

Pustular psoriasis is a rare entity. It shows a bimodal age distribution. The condition typically manifests in the adult age-group between the ages of 40 and 50 years, while in the pediatric age-group, it typically manifests in infancy. Asians tend to be more affected than Caucasians. It is more predominant in the women population. Roughly 1% of all clinical cases of psoriasis are pustular variations.[11,10] The association with plaque psoriasis ranges from 25% to 30% to 65% of cases.[12,13] Genetic studies of the various forms of PP reveal differences from plaque psoriasis. In PP, *IL36RN* mutations are the most frequently observed. The genes encoding the IL-36 family are located in chromosome 2q13. Mutations in the *AP1S3* and *CARD14* genes were found in some patients.

TYPES

Generalized:

- *von Zumbusch subtype*: Diffuse generalized pustular eruption with associated systemic symptoms (fevers, arthralgias, etc.)
- *Annular subtype*: Annular lesions with pustules along the advancing edge
- *Exanthematic subtype*: Acute pustular eruption without systemic symptoms that resolves after a few days
- *Impetigo herpetiformis*: PP occurring during pregnancy

Localized:

- *Acrodermatitis continua of Hallopeau*: Pustules affecting the fingers, toes, and nail beds
- *Palmoplantar psoriasis*: Pustules affecting the palms and soles

PATHOGENESIS

When keratinocyte comes under stress in a genetically predisposed person due to a certain triggering factor, a chain of inflammatory events gets started. Possible triggers for GPP flares include withdrawal of corticosteroids, exposure to certain medications (lithium, iodine, penicillin, interferon-alpha, etc.), stress, infection, pregnancy, phototherapy, vaccination, and hypocalcemia. Loss-of-function mutations have been implicated in *IL36RN*, which encodes an IL-36 receptor antagonist (IL-36Ra).[2] Both PP and chronic plaque psoriasis display overexpression of IL-1, IL-17, IL-23, IL-36, tumor necrosis factor alpha (TNF-α), and interferon gamma (IFN-γ). The expression levels of IL-1, IL-1RN, IL-36, IL-36, IL-36, and IL-36Ra are more intense in the pustular form. IL-36 has four subgroups (IL-36α, IL-36β, IL-36γ, IL-36Ra) and they come under family of IL-1.[14] The corresponding receptors are named as follows: For IL-36 α and β, IL-1Rrp2 and IL-1RAcp receptors, expressed in monocytes, T and B lymphocytes; for IL-36γ, the receptors are the same but expressed in keratinocytes epithelial cells; for IL-36Ra, the receptors are IL-1Rrp2 and SIGIRR, expressed by keratinocytes, monocytes, and dendritic cells.[15] Complexes of host DNA debris, and LL-37 are released from keratinocytes when they come under stress. It triggers the plasmacytoid dendritic cells. IL-36 acts on its receptor and activates intracellular pathways for the transcription of proinflammatory cytokines. It is possible that IL-36-Ser18 induces hyperkeratosis and CXCL8 production and regulates the production of CXCL1, CXCL10, and CCL20 by keratinocytes. Neutrophil elastase, calpain, proteinase-3, and cathepsin G help in the procession and activation of different subgroups of IL-36. In vitro, stimulation of human keratinocytes with different cytokines increases gene expression of several chemokines to T-lymphocytes (CCL20, CCL5, CCL2, CCL17, and CCL22), and neutrophils (CXCL8, CCL20, and CXCL1) and macrophages (CCL3, CCL4, CCL5, CCL2, CCL17, and CCL22). IL-36 has been shown to activate the vascular endothelium, resulting in notable edema of the papillary dermis, red blood cell extravasation, and the extravasation of other cells, including eosinophils.[16]

HISTOPATHOLOGY

Many of the histopathological features of PP mimic that of psoriasis vulgaris, including parakeratosis, hyperkeratosis, elongation of the rete ridges, reduced stratum granulosum, and suprapapillary thinning of epidermis. Neutrophilic infiltration at stratum corneum (Munro's microabscess) and stratum spinosum or granulosum (spongiform pustules of Kogoj) is more prominent in PP than in other variants of psoriasis vulgaris.

CLINICAL FEATURES

According to the 2018 Japanese Dermatological Association (JDA) diagnostic criteria for GPP, patients with all of the following features can

JAYPEE BROTHERS

be definitively diagnosed with GPP, while those with features 2 and 3 would be suspected of having GPP.[17]

- Systemic symptoms such as fever and fatigue
- Systemic or extensive flush accompanied by multiple sterile pustules
- Neutrophilic subcorneal pustules histopathologically characterized by Kogoj's spongiform pustules
- Recurrence of these clinical and histological findings

Numerous isolated or confluent superficial, yellowish pustules on an erythematous background are the hallmarks of PP. Both localized and widespread pustulosis are possible. A thorough examination of the skin on the entire body should be done to rule out any other causes of or plaques that are the initial stage of PP. Symptoms such as fever, headaches, joint discomfort, and leukocytosis are common in the generalized von Zumbusch subtype presentation. However, the exanthematic subtype does not exhibit systemic signs but manifests as an abrupt pustular eruption. The annular subtype is more commonly observed in youngsters around the expanding edge of annular lesions with pustules. The finger, toe, and nailbeds are affected in acrodermatitis continua of Hallopeau. Palmoplantar psoriasis, which can be seen as part of SAPHO syndrome, affects the palms and soles.

DIFFERENTIAL DIAGNOSIS

Differential diagnosis is given as follows:

- Acute generalized exanthematous pustulosis
- Drug eruption reaction
- Impetigo
- Dermatitis herpetiformis
- Infected eczema
- Erythroderma
- Acute cutaneous lupus
- Dyshidrotic eczema
- Disseminated herpes simplex virus
- Pemphigus vulgaris
- Pemphigus foliaceus

COMPLICATION

The complications include:

- Septicemia, commonly in the generalized form
- Dyselectrolytemia
- Hypocalcemia
- Acid–base imbalance
- Hyperthermia
- Acute liver injury
- Acute renal failure
- Malnutrition

MANAGEMENT

The first step in treatment of PP is to identify the cause and address it properly. We have to keep it mind that von Zumbusch subtype is a medical emergency and it requires hospital admission. Proper aseptic environment, maintaining fluid–electrolyte and acid–base balance and thermoregulation are utmost necessary. Systemic symptoms including fever, joint pain, and secondary infection (if any) will require proper treatment with antipyretics, anti-inflammatory medications, and antibiotics.

Complete blood count (CBC), serum calcium level, liver function test, erythrocyte sedimentation rate (ESR), C-reactive protein (CRP), renal function test, blood culture, serology profile, screening for tuberculosis, and punch biopsy are done. Cultures to be done from weeping lesions: To exclude primary or secondary infections. Topical treatments such as steroids, calcipotriene (calcipotriol), and tacrolimus should be considered as maintenance or adjuvant therapy. Methotrexate, cyclosporine, and systemic retinoids (acitretin, isotretinoin) are considered first-line in adult patients. Second-line treatment includes TNF-α inhibitors (e.g.,

JAYPEE BROTHERS

etanercept, adalimumab, and infliximab) and IL-17 inhibitors (ixekizumab, secukinumab, and brodalumab).[18,19]

Biologics may be considered over nonbiologics, as initial therapy, if two of the following three criteria are fulfilled:

1. Patients with a flare affecting ≥5% of the body surface area (BSA)
2. Patients with Generalized Pustular Psoriasis Physician Global Assessment (GPPGA) total score ≥3
3. Patients with significant impact on psychological/social function [e.g., Dermatology Life Quality Index (DLQI) ≥ 10]

Guselkumab, an IL-23 monoclonal antibody, is the first biological therapy to have demonstrated moderate efficacy and a good safety profile in Japanese patients with GPP.[19] TNF-α inhibitor, IL-17 inhibitor have shown mixed results in GPP.[19-21] IL-1 inhibitors anakinra have been proved efficacious in randomized placebo-controlled trials. The novel IL-36 receptor inhibitor spesolimab is an effective treatment of GPP.[2] It was approved in GPP by the Food and Drug Administration (FDA) in March 2024. The efficacy of spesolimab in patients with GPP was demonstrated regardless of the presence of *IL36RN* mutation. However, it is more effective in de novo cases of GPP than PP, which develops from earlier plaque psoriasis. In a phase 2, multicenter, double-blind, placebo-controlled trial done by Bachelez et al. at the end of week 1, total of 54% in the spesolimab group had a pustulation subscore of 0 (complete pustular clearance), as compared to 6% in the placebo group after receiving a single 900-mg intravenous dose of spesolimab. In addition, 43% achieved a GPPGA total score of 0 or 1 in the spesolimab group, compared to 11% in the placebo group. Rapid control of skin symptoms, within a week of treatment, is now a feasible treatment aim based on the recent results with IL-36 inhibitors.[22] Morita et al. aimed to assess the efficacy and safety of spesolimab for GPP flare prevention in a multicenter, randomized, placebo-controlled, phase 2b trial. They found that high-dose (600 mg loading dose followed by 300 mg every 4 weeks) spesolimab is superior to moderate (600 mg loading dose followed by 300 mg every 12 weeks) to low doses (300 mg loading dose followed by 150 mg every 12 weeks) in GPP flare prevention, significantly reducing the risk of a GPP flare and flare occurrence over 48 weeks.[23] Adverse events such as infection, asthenia and fatigue, nausea and vomiting, headache, pruritus, and infusion site hematoma, and bruising were noticed in the spesolimab group.[22] Imsidolimab showed efficacy in an open-label study that involved eight patients experiencing a GPP flare and is presently progressing into a phase 3 clinical trial.[24] There are also case reports of GPP exhibiting a positive response to IL-1 inhibition with anakinra, canakinumab, and gevokizumab.[25,26]

In the second and third trimesters, biologics—apart from certolizumab pegol—are actively transported across the placenta; the effects of this on the development of the newborn have not been well researched. For the first 6 months of life, live vaccinations should not be given to newborns whose mothers are receiving biological therapy after 16 weeks of pregnancy. Systemic steroids could be used in life-threatening emergencies and should be tapered as soon as possible.[25-28]

Treatment for children with GPP involves acitretin, corticosteroids, methotrexate, and cyclosporine and is much the same as for adults **(Flowchart 1)**. Although the safety of biologics in children has not been well established, they can be cautiously considered for severe/refractory cases with switching/discontinuation of biologics at the earliest.[29]

JAYPEE BROTHERS

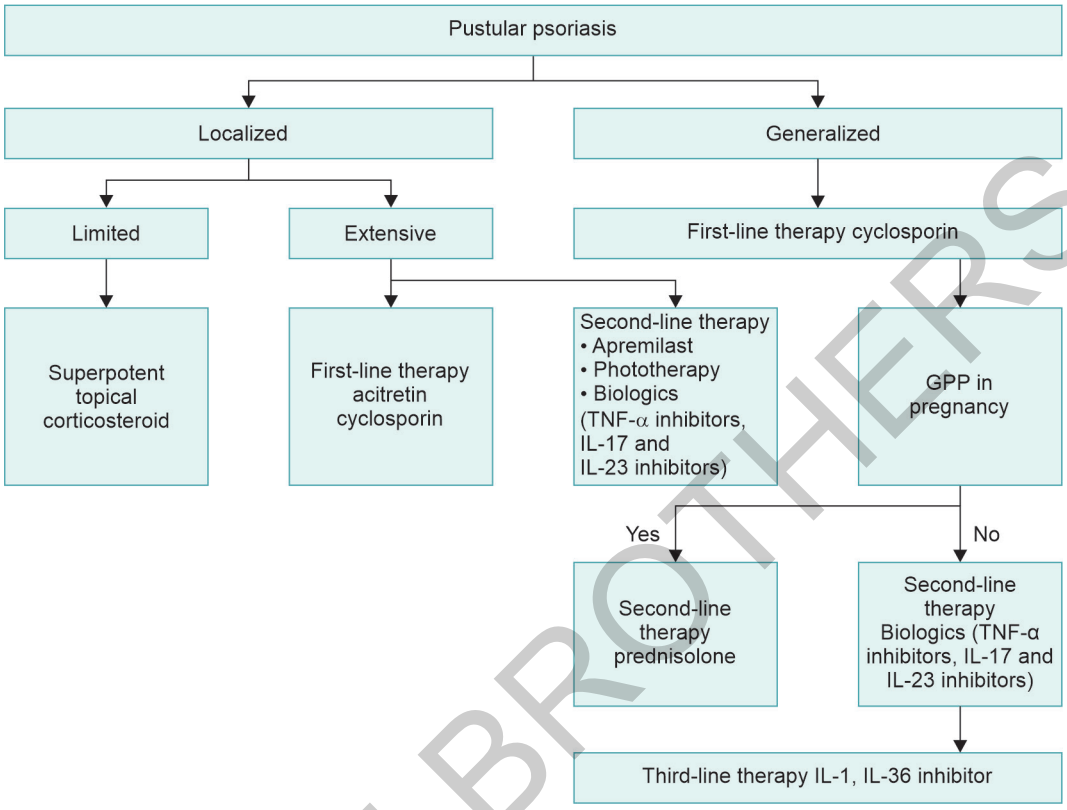

FLOWCHART 1: Treatment algorithm in pustular psoriasis.

(GPP: generalized pustular psoriasis; IL-17: interleukin 17; TNF-α: tumor necrosis factor alpha)

TAKE HOME MESSAGE

- Pustular psoriasis is different from plaque psoriasis, can arise de Novo associated with IL 36 RN gene.
- No prior history of psoriasis is essential.

REFERENCES

1. Zumbusch LR. Psoriasis und pustulöses Exanthem. Archiv für Dermatol Syph. 1910;99:335-46.
2. Bachelez H, Choon SE, Marrakchi S, Burden AD, Tsai TF, Morita A, et al. Inhibition of the Interleukin-36 Pathway for the Treatment of Generalized Pustular Psoriasis. N Engl J Med. 2019;380(10):981-3.
3. Navarini AA, Burden AD, Capon F, Mrowietz U, Puig L, Köks S, et al.; ERASPEN Network. European consensus statement on phenotypes of pustular psoriasis. J Eur Acad Dermatol Venereol. 2017;31(11):1792-9.
4. Ly K, Beck KM, Smith MP, Thibodeaux Q, Bhutani T. Diagnosis and screening of patients with generalized pustular psoriasis. Psoriasis (Auckl). 2019;9:37-42.
5. Zheng M, Jullien D, Eyerich K. The prevalence and disease characteristics of generalized pustular psoriasis. Am J Clin Dermatol. 2022;23(Suppl 1):5-12.
6. Reynolds KA, Pithadia DJ, Lee EB, Clarey D, Liao W, Wu JJ. Generalized pustular psoriasis: a review of the pathophysiology, clinical manifestations, diagnosis, and treatment. Cutis. 2022;110(2 Suppl):19-25.

JAYPEE BROTHERS

7. Marrakchi S, Puig L. Pathophysiology of generalized pustular psoriasis. Am J Clin Dermatol. 2022;23(Suppl 1):13-9.
8. Zhou J, Luo Q, Cheng Y, Wen X, Liu J. An update on genetic basis of generalized pustular psoriasis (Review). Int J Mol Med. 2021;47(6):118.
9. von dem Borne PA, Jonkman MF, van Doorn R. Complete remission of skin lesions in a patient with subcorneal pustular dermatosis (Sneddon–Wilkinson disease) treated with antimyeloma therapy: association with disappearance of M protein. Br J Dermatol. 2017;176(5):1341-4.
10. Boehner A, Navarini AA, Eyerich K. Generalized pustular psoriasis–a model disease for specific targeted immunotherapy, systematic review. Exp Dermatol. 2018;27(10):1067-77.
11. Komatsuda S, Kamata M, Chijiwa C, Namiki K, Fukaya S, Hayashi K, et al. Gastrointestinal bleeding with severe mucosal involvement in a patient with generalized pustular psoriasis without IL36RN mutation. Br J Dermatol. 2019;46(1):73-5.
12. Baker H, Ryan TJ. Generalized Pustular Psoriasis. A clinical and epidemiological study of 104 cases. Br J Dermatol. 1968;80:771-93.
13. Gooderham MJ, Voorhees AS, Lebwohl MG. An update on generalized pustular psoriasis. Expert Rev Clin Immunol. 2019;15:907-19.
14. Twelves S, Mostafa A, Dand N, Burri E, Farkas K, Wilson R, et al. Clinical and genetic differences between pustular psoriasis sub-types. J Allergy Clin Immunol. 2019;143:1021-6.
15. Furue K, Yamamura K, Tsuji G, Mitoma C, Uchi H, Nakahara T, et al. Highlighting Interleukin-36 Signaling in Plaque Psoriasis and Pustular Psoriasis. Acta Derm Venereol. 2018;98:5-13.
16. Gabay C, Towne JE. Regulation and function of interleukin-36 cytokines in homeostasis and pathological conditions. J Leukoc Biol. 2015;97:645-52.
17. Fujita H, Terui T, Hayama K, Akiyama M, Ikeda S, Mabuchi T, et al. Japanese guidelines for the management and treatment of generalized pustular psoriasis: The new pathogenesis and treatment of GPP. J Dermatology. 2018;45(11):1235-70.
18. Terui T, Kobayashi S, Okubo Y, Murakami M, Zheng R, Morishima H, et al. Efficacy and safety of guselkumab in Japanese patients with palmoplantar pustulosis: a phase 3 randomized clinical trial. JAMA Dermatol. 2019;155:1153-61.
19. Mrowietz U, Bachelez H, Burden AD, Rissler M, Sieder C, Orsenigo R, et al. Secukinumab for moderate-to-severe palmoplantar pustular psoriasis: results of the 2PRECISE study. J Am Acad Dermatol. 2019;80:1344-52.
20. Pinter A, Wilsmann-Theis D, Peitsch WK, Mössner R. Interleukin-17 receptor A blockade with brodalumab in palmoplantar pustular psoriasis: report on four cases. J Dermatol. 2019;46:426-30.
21. Bissonnette R, Poulin Y, Bolduc C, Maari C, Provost N, Syrotuik J, et al. Etanercept in the treatment of palmoplantar pustulosis. J Drugs Dermatol. 2008;7:940-6.
22. Bachelez H, Choon SE, Marrakchi S, Burden AD, Tsai TF, Morita A, et al.; Effisayil 1 Trial Investigators. Trial of spesolimab for generalized pustular psoriasis. N Engl J Med. 2021;385(26):2431-40.
23. Morita A, Strober B, Burden AD, Choon SE, Anadkat MJ, Marrakchi S, et al. Efficacy and safety of subcutaneous spesolimab for the prevention of generalised pustular psoriasis flares (Effisayil 2): an international, multicentre, randomised, placebo-controlled trial. Lancet. 2023;402(10412):1541-51.
24. Warren RB, Reich A, Kaszuba A, Placek W, Griffiths CEM, Zhou J, et al. Imsidolimab, an anti-interleukin-36 receptor monoclonal antibody, for the treatment of generalized pustular psoriasis: results from the phase II GALLOP trial. Br J Dermatol. 2023;189(2):161-9.
25. Hüffmeier U, Wätzold M, Mohr J, Schön MP, Mössner R. Successful therapy with anakinra in a patient with generalized pustular psoriasis carrying IL36RN mutations. Br J Dermatol. 2014;170(1):202-4.
26. Skendros P, Papagoras C, Lefaki I, Giatromanolaki A, Kotsianidis I, Speletas M, et al. Successful response in a case of severe pustular psoriasis after interleukin-1β inhibition. Br J Dermatol. 2017;176(1):212-5.
27. Seishima M, Fujii K, Mizutani Y. Generalized Pustular Psoriasis in Pregnancy: Current and Future Treatments. Am J Clin Dermatol. 2022;23(5):661-71.
28. Smith CH, Yiu ZZN, Bale T, Burden AD, Coates LC, Edwards W, et al.; British Association of Dermatologists' Clinical Standards Unit. British Association of Dermatologists guidelines for biologic therapy for psoriasis 2020: a rapid update. Br J Dermatol. 2020;183(4):628-37.
29. Saeki H, Terui T, Morita A, Sano S, Imafuku S, Asahina A, et al.; Biologics Review Committee of the Japanese Dermatological Association for Psoriasis. Japanese guidance for use of biologics for psoriasis (the 2019 version). J Dermatol. 2020;47(3):201-22.

JAPEE BROTHERS

for detailed information on dermatology books, visit our website www.jaypeebrothers.com, for detailed information on dermatology books, visit our website

IADVL
SIG Handbook on Psoriasis

Salient Features

- **Expert contributions:** Authored by over 30 experts with extensive experience in psoriasis, including members of SIG Psoriasis, ensuring comprehensive and authoritative content
- **Comprehensive coverage:** Addresses all aspects of psoriasis, from the latest concepts in etiopathogenesis to emerging therapies, newer molecules, and future directions in research and treatment
- **Practical takeaways:** Each chapter includes concise Take Home Message to aid quick understanding and practical application in clinical settings
- **Patient-centric focus:** Emphasizes improving patient's quality of life, with dedicated discussions on special populations, adherence strategies, and mental health support
- **Systemic perspective:** Explores the connection between psoriasis and its comorbidities, such as cardiovascular diseases, metabolic syndrome, depression, and gut dysbiosis
- **Richly illustrated:** Features numerous flowcharts, tables, and diagrams to simplify complex concepts and enhance readability
- **Comprehensive treatment insights:** Offers a complete guide to topical therapies, phototherapy, systemic treatments, biologics, small-molecule immunomodulators, and combination/rotational therapies
- **Emerging innovations:** Covers AI-driven precision medicine, biologics, cell-based therapies, and the latest trends shaping the future of psoriasis management

This easy-to-read, extensively illustrated handbook is an invaluable resource for clinicians, researchers, and students, blending science and practice to advance the understanding and treatment of psoriasis.

Sudip Das MD(Derm & Ven) AIIMS, New Delhi, FRCP(Edinburgh) is a renowned dermatologist and academician, currently serving as Professor and Head of the Department at Calcutta National Medical College, Kolkata, West Bengal. With an impressive record of 134 publications and 397 presentations, he has made significant contributions to dermatology research and education. Dr Das has been honored with several prestigious awards, including the IADVL Best Teacher's Award (2018), the Ganapati Panja Award (2021), and notable orations like the Dr RK Panja Oration (2023) and the CSRAO Memorial Oration (2024). He has served in various leadership roles, including Vice President of Indian Society for Pediatric Dermatology (ISPD), Past National Coordinator for Psoriasis, and Managing Editor of IJD. His areas of expertise include psoriasis, CADR, vitiligo, chemical peels, hair disorders, and leprosy. A visionary leader, Dr Das continues to inspire through his research, mentorship, and global dermatological collaborations.

Abhishek De MD FAGE SCE(Dermatology) FRCP(Edinburgh) FAAD PhD (Schl) is Associate Professor at Calcutta National Medical College, Kolkata, West Bengal. He specializes in immunodermatological conditions. He serves as Associate Editor for the Indian Journal of Dermatology and the Indian Journal of Skin Allergy. An active member of AAD, EADV, ISD, and EAACI, he contributes to SIG Psoriasis and Biologics and serves as Honorary Secretary of the Skin Allergy Research Society of India. Dr De is an international mentor for EAACI and a counselor for the International Eczema Council. A prolific author, he has co-authored clinical guidelines for urticaria, atopic dermatitis, and psoriasis, advancing care in dermatology globally.

Printed in India

Available at all medical bookstores or buy online at www.ejaypee.com

JAYPEE BROTHERS
Medical Publishers (P) Ltd.
EMCA House, 23/23-B, Ansari Road,
Daryaganj, New Delhi - 110 002, INDIA
www.jaypeebrothers.com

Join us on facebook.com/JaypeeMedicalPublishers
Follow us on instagram.com/JaypeeMedicalPublishers

Shelving Recommendation
DERMATOLOGY

ISBN 978-93-6616-604-9