on dental books, visit our website www.jaypeebrothers.com, for detailed information on dental books, visit our website www.jaypeebrothers.com

6th Edition

Complimentary Online

8 Videos (135 minutes), Review Questions, MCQs & Viva Voce QAs. only with Genuine Book

Textbook of Oral and Maxillofacial Surgery

Neelima Anil Malik

Foreword **Suresh Bhosale**

Dr.Wise AI Chatbot

Scratch the code inside to access **Dr. Wise** your Innovative and Genius AI Chatbot

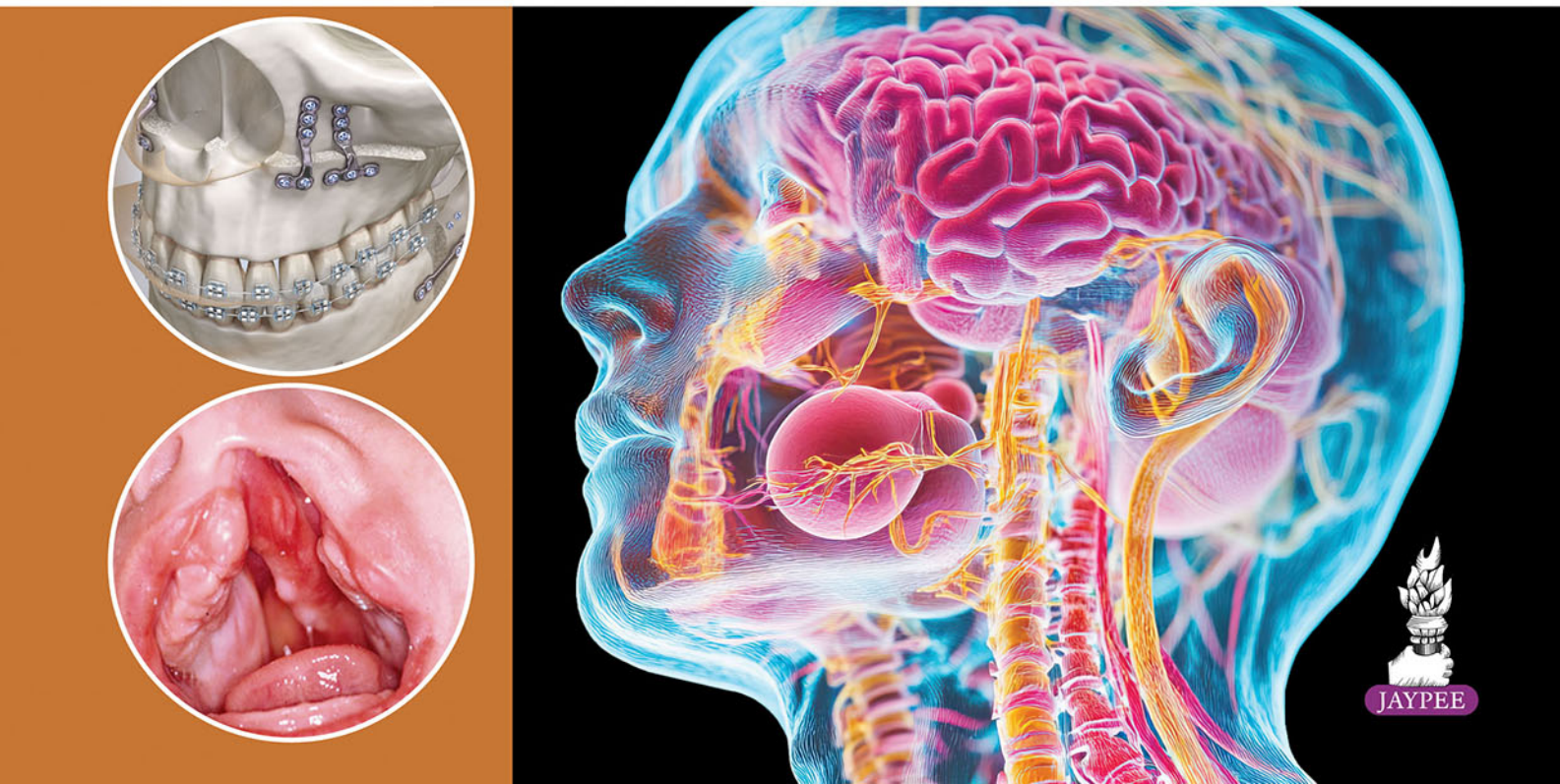

JAYPEE

Contents

Section 1: Principles of Oral and Maxillofacial Surgery

1. **Introduction to Oral and Maxillofacial Surgery** 3
   - Definition *3*
   - Scope *4*
   - Multidisciplinary Team Approach *6*
   - Newer Advances *7*
2. **Art of Diagnosis and Diagnostic Imaging** 9
   - History Taking *9*
   - Clinical Examination *10*
   - Clinical Diagnostic Aids *14*
   - Fundamental Tenet of Imaging Modality *14*
   - Diagnostic Imaging—As Low as Reasonably Achievable Principle *15*
   - Selection of Imaging Modality *15*
   - Radiological Examination *15*
   - Diagnostic Investigations *28*
   - Biopsy *31*
3. **Management of Medically Compromised Patients in Oral Surgery** 39
   - Classification of Physical Status *39*
   - Cardiac (Cardiovascular) Diseases *40*
   - Hypertension *44*
   - Respiratory Diseases *46*
   - Bronchial Asthma *47*
   - Renal Diseases *48*
   - Hepatic Diseases *48*
   - Diabetes Mellitus *49*
   - Thyroid Disorders *50*
   - Assessment of Thyroid Function before Treatment *51*
   - Adrenal Gland Disorders *51*
   - Neurological Disorders *52*
   - Disorders of Hemopoietic System *52*
   - Immunocompromised Patients *54*
   - Autoimmune Disorders *54*
   - HIV Testing and Counseling *55*
   - Management of Occupational Exposure and Postexposure Prophylaxis *56*
   - Risk of Patient to Health Professional Transmission *57*
   - Protocols for Treating HIV Positive Patients *57*
   - Management *60*
4. **Armamentarium Used in Oral and Maxillofacial Surgery** 63
   - Instrument Used for Picking up and for Transfer of Sterile Instruments *63*
   - Instruments Used for Cleaning/Disinfecting the Surgical Field *64*
   - Instruments Used for Holding the Drapes (for Isolation of Surgical Field) *64*
   - Instruments Used for Incising/Dissecting the Soft Tissues *65*
   - Instruments Used for Retracting Soft Tissues *66*
   - Instruments Used for Reflecting/Elevating the Mucoperiosteal Tissue/Flap *68*
   - Instruments Used for Achieving Hemostasis-Controlling Hemorrhage *69*
   - Instruments Used for Holding/Grasping the Soft Tissues *70*
   - Instruments Used to Keep the Mouth Open *72*
   - Instruments Used to Drain an Abscess *72*
   - Instruments Used to Remove Pathological/Soft Tissue from Bony Cavities/Defects *72*
   - Instruments Used to Hold/Grasp the Bone *74*
   - Instruments Used to Cut or Remove Bone *75*
   - Instruments Used to Suture the Soft Tissues: Skin, Mucosa, etc. *78*
   - Miscellaneous Instruments *78*
   - Instruments Used to Maintain a Clean Surgical Field—Aspirators/Suction Machines *78*
   - Instruments Used for the Treatment of Fractures of the Jaw Bones: Maxillofacial Trauma Care *80*
   - Instruments Used during Orthognathic Surgery *85*
   - Surgical Drains Used in Oral and Maxillofacial Surgery *87*
   - Surgical Diathermy (Cautery, Electrocautery) *89*
   - Cryosurgery *90*
5. **Suturing Materials and Techniques** 92
   - Historical Background *92*
   - Principles of Suture Material Selection *96*
   - Natural Nonabsorbable Sutures *98*
   - Natural Absorbable Sutures *99*
   - Synthetic Absorbable Sutures *99*

- Coated VICRYL—Polyglactin 910 Braided Suture Material-Synthetic Absorbable Suture *99*
- Suture Needles *100*
- Suturing Techniques *105*
- Suture Removal *108*
- Mechanical Wound Closure Devices *108*

6. Asepsis and Sterilization 111
- Definitions of Various Terminologies *111*
- Classification of Instruments *112*
- Transfer or Transport of Used Items *112*
- Packaging or Wrapping Instruments for Autoclaving *114*
- Methods of Sterilization *116*
- Storage of Sterile Goods *121*
- Disinfection *122*
- Disinfectants *124*
- Antiseptics *126*
- Operating Room Aseptic Procedures *127*

7. Infection Control 136
- Objective *136*
- Infection *136*
- Infectious Diseases of Concern in Dentistry *138*
- General Principles to Prevent Cross Infection *140*
- Biomedical Waste Disposal *152*

8. Antimicrobial Therapy 157
- Classifications of Antimicrobial Agents *158*
- Principles of Antimicrobial Therapy *159*
- Removal of Source of Infection *163*
- Beta-Lactam Antibiotics *164*
- Antiviral Antimicrobials Drugs *173*
- Aminoglycosides *173*
- Antimycotic Agents *174*
- Lincomycin and Clindamycin *177*
- Guidelines for Antibiotic Prophylaxis *177*

Section 2: Local Anesthesia in Oral and Maxillofacial Surgery

9. Local Anesthesia for Orofacial Region 183
- Theories for Mechanism of Action of Local Anesthetic Agents *184*
- Classifications of Local Anesthetic Agents *184*
- Local Anesthetic Agents in Dentistry *186*
- Toxicity of Lignocaine *188*
- Armamentarium for Achieving Local Anesthesia *193*
- Injection Techniques for Regional Anesthesia *197*

Section 3: General Anesthesia and Sedation in Oral and Maxillofacial Surgery

10. Introduction to General Anesthesia and Sedation 227
- Definition *227*
- Historical Background *228*
- Shortfalls of General Anesthesia in a Dental Chair *229*

11. Preanesthetic Evaluation 230
- Objectives of Preanesthetic Evaluation *230*
- Thyromental Distance Measurement *233*

12. Preanesthetic Preparation and Premedication 238
- Basic Plan of Preanesthetic Preparation *238*

13. Anesthetic Equipment 247
- Anesthesia and Resuscitation Equipment *247*
- Monitoring Equipment *258*
- Oxygen Delivery Equipment *260*
- Intravenous Infusion Equipment *261*
- Newer Advances *263*

14. Pharmacology of Commonly Used Anesthetic Drugs 266
- Muscle Relaxants *268*
- Properties of an Ideal Anesthetic Agent *268*
- Inhalational Induction Agents *269*

15. Sedation Techniques for Dentistry 277
- Levels of Sedation *277*
- Techniques of Sedation *278*
- Challenges in Dental Conscious Sedation *278*

16. Short Anesthesia in a Dental Chair 284
- Indications for General Anesthesia in Dental Chair *284*
- General Principles of Management *285*
- Monitors and Resuscitation Equipment *285*
- Day-Stay Surgery *285*
- Position in Dental Chair: Horizontal/Sitting Position *286*
- Induction of Anesthesia *286*
- Maintenance of Anesthesia *287*
- Endotracheal Anesthesia *287*
- Recovery *288*
- Complications of Dental Anesthesia *288*

17. Tracheal Intubation for a Patient Undergoing Oral and Maxillofacial Surgery 290
- Indications for Tracheal Intubation *290*
- Armamentarium Required for Intubation *291*
- Complications Associated With Endotracheal Intubation *297*

Section 4: Exodontia and Minor Oral Surgical Procedures

18. Exodontia 305
- Techniques of Dental Extractions *305*
- Challenging Factors for Dental Extractions *305*
- Indications for Dental Extraction *305*
- ContraIndications for Dental Extractions *306*
- Armamentarium Used for Exodontia *307*
- Instruments Used to Luxate the Tooth *310*
- Mechanical Work Principles of Forceps and Elevators *312*
- Steps to Carry Out Simple Extraction *317*
- Order of Extractions *318*
- Reasons for Breakage of a Tooth/Incomplete Removal of a Tooth *318*
- Complications of Tooth Extraction *319*
- Postextraction Care *319*

19. Principles of Minor Oral Surgical Procedures and Trans-alveolar Extractions 323
- Basic Purpose of Surgery *323*
- Principles of Oral Surgery *323*

20. Surgical Management of Impacted Teeth 332
- Definition of Impacted Teeth *332*
- Commonly Used Terminologies *333*
- Detailed Information about Impacted Third Molar Teeth *334*
- Risk and Benefits of Nonintervention or Intervention of Surgical Extraction of Impacted Third Molar *337*
- Classification of Impacted Teeth *338*
- Classification of Impacted Third Molars *338*
- Radiological Examination of Impacted Teeth *346*
- Factors Responsible for Increasing the Difficulty Score for Removal of Impacted Teeth *346*
- New Index Proposed by Neelima Malik (2016) *353*
- Surgical Removal of Impacted Teeth *356*
- Tooth/Root Sectioning: Splitting of Tooth/Root Odontectomy *360*
- Early Removal or Germectomy: Lateral Trephination Technique *363*
- Coronectomy *363*
- Complications *364*

21. Surgical Endodontics 366
- Indications *366*
- ContraIndications *367*
- Treatment Planning for Periradicular Surgery *367*
- Periradicular Curettage/Surgery, Root-end Resection Procedure (Apicectomy and Curettage) *367*
- Steps in Endodontic Surgery *367*
- Root-end Cavity Filling/Retrograde Restoration *371*
- Prognosis *372*
- Complications *372*

Section 5: Temporomandibular Joint Disorders

22. Temporomandibular Joint: Afflictions and Management 377
- Surgical Anatomy of the Temporomandibular Joint *377*
- Special Features of TMJ *383*
- Temporomandibular Joint Disorders *383*
- Nonsurgical Management *394*
- Surgical Approaches to Mandibular Condyle and its Neck *399*

23. Ankylosis of the Temporomandibular Joint and its Management 410
- Etiopathology *410*
- Hypotheses for Pathogenesis of TMJ Ankylosis *411*
- Classifications of Ankylosis *411*
- Diagnosis *412*
- Clinical Manifestations *413*
- Imaging Interpretation-based Classifications *415*
- Management of TMJ Ankylosis *417*
- Reconstruction of Ramus-Condyle Unit *426*
- Complications during TMJ Ankylosis Surgery *433*

24. Myofascial Pain Dysfunction Syndrome 439
- History and Different theories for TMJ Disorders *439*
- Clinical Characteristics of Mpds *440*
- Pathophysiology (Etiology) *441*
- Myofascial Pain Dysfunction Syndrome Symptoms *442*
- History of the Patient *442*
- Objectives of Treatment in Myofascial Pain Dysfunction Syndrome *451*
- Orthognathic Surgery *465*

Section 6: Orthognathic Surgery

25. Introduction to Orthognathic Surgery, Diagnosis and Treatment Planning 467
- Types of Skeletal Dentofacial Deformities *467*
- Severe Skeletal Dentofacial Deformities and Associated Problems *476*
- Treatment Options *476*
- Facial Esthetic Analysis *478*
- A "Quick CEPH" Dentofacial Planner for Orthognathic Surgery *482*

26. Presurgical Orthodontic Phase 489
- Presurgical Orthodontics Objectives *490*
- Presurgical Orthodontic Objectives for Three Planes *491*
- Postsurgical Orthodontics Objectives—6–8 Weeks Duration *496*

27. Orthognathic Surgery: Osteotomy Procedures 499
- Historical Development of Orthognathic Surgery *499*
- Protocol for Osteotomies *500*
- Osteotomy Procedures for Maxilla and Mandible *501*
- Maxillary Osteotomy Procedures *519*

28. Distraction Osteogenesis in Oral and Maxillofacial Surgery 537
- Definition *537*
- Historical Background *537*
- Phases of Distraction Osteogenesis *537*
- Biological Aspects of Distraction Osteogenesis *539*
- Types of Distraction Osteogenesis *540*
- Indications for Distraction Osteogenesis *543*
- Mandibular Distraction Osteogenesis *545*
- Maxillary Distraction Osteogenesis *551*
- Transport Disk Distraction Osteogenesis *557*
- Cranial Distraction Osteogenesis *558*

Section 7: Maxillofacial Trauma

29. Basic Principles for the Management of Maxillofacial Injuries 565
- General Care of the Injured Patient *565*
- Basic Principles of Treatment of a Severe Maxillofacial Injury *565*
- Basic ABCs to be Followed for Preservation of Life *566*
- Soft Tissue Injuries/Trauma of the Craniomaxillofacial Region *568*

30. Injuries of the Maxillofacial Skeleton and Basic Principles of Treatment 580
- Etiology of Maxillofacial Injuries *580*
- Comprehensive Maxillofacial Injury Evaluation *581*
- Local Clinical Examination of Maxillofacial Injuries *582*
- Dentoalveolar Fractures *585*
- Fractures of the Jaw Bones *586*
- Internal Osteosynthesis/Fixation *603*
- Applied Anatomy and Biomechanics of the Mandible *606*

31. Fractures of the Middle Third of the Facial Skeleton 616
- Middle Third of the Facial Skeleton *616*
- Classification of Fractures of Middle Third of Facial Skeleton *621*
- Fractures of the Zygomaticomaxillary Complex (ZMC) *627*
- Fracture of the Floor of the Orbit (Blowout Fracture) Applied Anatomy of the Orbit *632*
- Diplopia *634*
- Enophthalmos *637*

32. Principles of Treatment of Midfacial Fractures 640
- Methods of Reduction for Midface Fractures *640*
- Treatment of Fractures of the Zygomatic Bone *644*
- Operative Surgical Techniques *649*
- Fractures of the Nasal Bone and Treatment *656*

33. Applied Surgical Anatomy of the Mandible and Classification of Mandibular Fractures 663
- Anatomy of the Mandible *663*
- Classifications of Mandibular Fractures *666*

34. Management of Mandibular Fractures 671
- Mandibular Fractures in Children *674*
- Management of Mandibular Fractures in Adults *675*
- Surgical Approaches to the Mandibular Fractures *677*
- Bone Plating in Mandibular Fractures *683*

35. Fractures of the Condylar Process of Mandible and its Management 694
- Incidence of Condylar Fractures *694*
- Biomechanics and Patterns of Condyle Fracture *694*
- Applied Surgical Anatomy of Condyle *697*
- Condylar Fractures in Pediatric and Adult Population *701*
- Classification of Condylar Fractures *702*
- Diagnostic Findings of Condylar Fractures *706*
- Radiographic Findings *709*
- Treatment of Condylar Fractures *710*
- Concept of Stable Osteosynthesis *718*

Section 8: Preprosthetic Surgery

36. Preprosthetic Surgery 729
- Preprosthetic Surgery *729*
- Preprosthetic Surgical Procedures *733*
- Alveolar Ridge Correction *733*
- Ridge Extension Procedures *744*
- Ridge Augmentation Procedures *749*

Section 9: Cysts and Tumors of the Orofacial Region

37. Cysts of the Jaws and Oral/Facial Soft Tissues 765
- Cyst for Mation/Pathogenesis *767*
- Incidence *771*
- General Signs and Symptoms of the Cysts *771*
- General Principles of Treatment of Cysts of the oral Cavity *773*
- Odontogenic Cysts *786*
- Developmental Odontogenic Cysts *790*
- Soft Tissue Cysts of the oral Cavity *793*
- Nonodontogenic Nonepithelial Lined Bone Cysts (Cyst-Like Conditions) *809*
- Cysts Associated With the Maxillary Antrum *812*
- Nonodontogenic Fissural Cysts *813*
- Nonodontogenic (Developmental) Cysts of the Soft Tissues *815*
- Lymphoepithelial Cysts *816*

38. Benign Tumors of the Jaw Bones 820
- Introduction to Odontogenic and Nonodontogenic Benign Tumors *820*
- Origin of Benign Odontogenic Tumors *820*
- Latest Modified Classification by WHO-2022 *821*
- Odontogenic Tumors *821*
- Nonodontogenic Tumors *823*
- General Principles of Management of Jaw Lesions *824*
- Clinical Examination of the Lesion *824*
- Principles of Surgical Management of Jaw Tumors *826*
- Odontogenic Tumors of Various origins *836*
- Tumors Arising from Odontogenic Ectomesenchyme with or without Inclusion of Odontogenic Epithelium *850*
- Benign Nonodontogenic Tumors and Fibro-Osseous and Other Lesions of the Maxillofacial Bones *856*
- Benign Maxillofacial Bone and Cartilage Tumors *857*
- Fibro-Osseous and Nonneoplastic Bone Lesions *863*
- Giant Cell Lesions of the Jaw Bones *870*
- Neurogenic Tumors *876*
- Neurofibroma *878*

Section 10: Salivary Gland Disorders

39. Diseases of the Salivary Glands 885

A. Salivary Glands and Diseases *885*
- Salivary Glands: Classification *885*
- Salivary Glands: Anatomy *886*
- Salivary Glands: Physiology and Saliva Content *891*
- Classification of Salivary Gland Diseases/ Disorders *893*
- Clinical Examination: Differential Diagnosis *894*
- Diagnosis of Salivary Gland Disorders and Diagnostic Imaging *895*
- Salivary Gland Dysfunction/Disorders Details *903*

B. Surgical Management of Major Salivary Glands Disorders *923*
- Types of Parotidectomy *923*
- Parotid Gland Surgery: Superficial Parotidectomy *924*
- Complete Excision of Parotid Gland/total Parotidectomy *928*
- Excision of Submandibular Salivary Gland *931*

Section 11: Orofacial Clefts

40. Cleft Lip and Cleft Palate Management 941
- Classifications *946*
- Davis and Ritchie Classification (1922) *948*
- Kernahan and Stark *948*
- Anatomy *952*
- General Management Protocol *955*
- Feeding *956*
- Various Techniques for Bilateral Cleft Lip Closure *960*
- Cleft Palate Repair Rationale *964*
- Speech Therapy *966*
- Alveolar Bone Grafting *966*
- Orthodontic Treatment *969*

Section 12: Maxillary Sinus and its Implications

41. Management of Maxillary Sinus Afflictions 975
- General Considerations *975*
- Clinical Examination of Maxillary Sinus Afflictions *979*
- Radiology and Other Diagnostic Investigations for Maxillary Sinus Afflictions *980*
- Infections of Maxillary Sinus *982*
- Oroantral Communication and Fistula *987*
- Functional Endoscopic Sinus Surgery *998*

Section 13: Orofacial and Neck Infections

42. Orofacial and Neck Infections and their Management 1005
- Etiology *1005*
- Microbiology of Odontogenic Infections *1006*
- Pathways of Odontogenic Infection *1006*
- Spread of Orofacial Infection *1007*
- Factors Influencing Spread of Infection *1007*
- Evaluation of the Patient With Orofacial Infection *1014*
- Involvement of Potential Spaces *1021*
- Classification of Fascial Spaces *1023*
- Possible Untoward or Life-Threatening Complications of Orofacial Infection *1044*

43. Osteomyelitis and Osteoradionecrosis of the Jaw Bones 1059
- Osteomyelitis of the Jaw Bones *1059*
- Tuberculous Osteomyelitis of the Jaw Bones *1081*
- Osteoradionecrosis of the Facial Bones *1087*
- Medication-Related Osteonecrosis of the Jaw (MRONJ) *1097*

Section 14: Facial Neuropathology

44. Trigeminal Neuralgia and its Management 1103
- Definition *1104*
- Etiology and Pathogenesis *1104*
- General Characteristics *1106*
- Clinical Characteristics *1106*
- Diagnosis *1107*
- Treatment Protocols for the Management of TN *1108*

45. Sensory Disturbances of Face and Jaws 1126
- Etiology *1127*
- Incidence *1128*
- Classification of Mechanical Nerve Injuries *1128*
- Management *1139*

46. Facial Nerve and Motor Disturbances of Face and Jaws 1147
- Facial Nerve *1147*

Section 15: Oral Malignancies

47. Potentially Premalignant Oral Epithelial Lesions and Conditions 1163
- Definition and Classification of Potentially Premalignant Oral Epithelial Lesions and Conditions *1163*
- Incidence *1164*
- Leukoplakia *1164*
- Erythroplakia *1168*
- Oral Submucous Fibrosis *1169*
- Oral Lichen Planus *1178*

48. Oral Cancer 1182
- Incidence *1182*
- Anatomical Subsites of Cancer in the Oral Cavity *1183*
- Etiology *1183*
- Spread of Squamous Cell Carcinomas of the Oral Cavity *1184*
- Clinical Features *1184*
- Management *1187*
- Management of the Neck Lymph Nodes *1195*
- Lymph Node Levels *1195*

- Classification of Neck Dissection *1196*
- Survival and Prognosis *1198*
- Role of Dental Practitioner in Oral Cancer Management *1198*

Section 16: Implantology in Oral and Maxillofacial Surgery

49. Dental Implants: An Overview 1203
- History *1203*
- Implantation *1203*
- Osseointegration or Osseous Integration *1204*
- Rationale for Implant Treatment *1205*
- Implant Materials *1209*
- Titanium Implants *1210*
- Advantages of Dental Implants *1210*
- Anatomy or Parts of an Implant System *1210*
- Patient Selection Criteria *1213*
- Computed Tomography *1214*
- Armamentarium for Implant Surgery *1216*
- Basic Factors in Implant Surgery *1216*
- Placement of the Implant in an Acceptable Position *1218*
- Preoperative Care *1218*
- Anesthesia *1218*
- Incisions *1219*
- Different Flap Designs Options for Implant Placement *1219*
- Basic Flap Design and Soft Tissue Handling *1219*
- Postoperative Instructions *1223*
- Abutment Connection *1223*
- Surgical Complications of Implant Therapy *1223*
- Nonsurgical Management of Peri-Implantitis *1229*
- Surgical Management of Peri-Implantitis *1230*
- Absolute Indication for Explantation *1230*
- Long-term Maintenance Protocol for Implants *1230*

Section 17: Management of Medical Emergencies in Dentistry

50. Hemorrhage and Shock: Its Management in Oral Surgery 1235
- Hereditary Coagulopathies Disorders *1245*
- Shock *1249*

51. Management of Medical Emergencies in Dental Clinic 1253
- Recognition of Patient at Risk *1253*
- Drugs and Resuscitation Equipment *1253*
- Basic Life Support *1259*
- Common Medical Emergencies and their Management *1261*
- Conclusion *1266*

52. Cardiopulmonary Resuscitation 1267
- Pathophysiology *1267*
- Treatment of Cardiac Arrest *1268*
- Basic Life Support *1268*

Section 18: Recent Advances in Oral and Maxillofacial Surgery

53. Recent Advances in Oral and Maxillofacial Surgery 1281
- Artificial Intelligence, Machine Learning (ML), Deep Learning (DL) in Oral and Maxillofacial Surgery *1281*
- Intraoperative Navigation and Robotic Surgery *1287*

Section 19: Problem Solving in Oral and Maxillofacial Clinical Practice

54. Medicolegal Dilemma in Oral and Maxillofacial Surgery 1305
- Brief History *1305*
- Few Important Terminologies *1306*
- Types of Medical Negligence in India *1307*
- Who can be Held Liable? *1308*
- Who can be Exempted from Liability in Medical Negligence Cases? *1309*
- Who can Sue a Doctor? *1309*
- When is a Doctor Not Liable for Medical Negligence? *1309*
- Till When can a Patient Sue a Doctor? (Limitation Period for Filing a Complaint) *1309*
- Doctor: Innocent or Guilty? *1310*
- Process of Adjudicating Medical Negligence Liability *1310*
- How to Prevent Medical Negligence in Dental and Medical Practice *1311*
- Consent in Clinical Practice *1312*
- Professional indemnity for Medical Practitioners *1314*

- List of Evidence Required by Patients to Sue a Doctor *1314*
- What Should a Doctor do after Receiving a Notice from the Consumer Court? *1315*
- What is a Medico-legal Case? *1315*
- Medical Record/Documentation *1317*

55. Rational Pharmacotherapy in Dental Practice 1325

- Fixed Dose Drug Combinations 1325

Appendices* *1329

Index* *1347

CHAPTER 23

Ankylosis of the Temporomandibular Joint and its Management

Learning Objectives

After reading this chapter, readers should be able to understand and answer questions related to the following topics:

- Etiopathology of TMJ ankylosis
- Classifications of ankylosis
- Diagnosis
- Clinical manifestations
- Radiographic findings
- Imaging interpretation-based classifications
- Management of TMJ ankylosis
- Complications during TMJ ankylosis surgery

INTRODUCTION

Ankylosis is a Greek terminology meaning "stiff joint or the joint which cannot move". In temporomandibular joint (TMJ) ankylosis, it is basically stiffening/immobility of the joint or pathological intracapsular fusion/union of the disk-condyle complex to temporal articular surface (either of fibrous/fibro-osseous tissue adhesion or bony deposition, between the head of the condyle and glenoid fossa articular area).

Here, because of immobility of the joint, the jaw function gets affected. Hypomobility to immobility of the joint can lead to inability to open the mouth from partial to complete. The incidence of intra-articular TMJ ankylosis is difficult to assess. But, in the western literature it is reported as decreasing, due to better understanding of management of condylar fractures and also to the decreased incidence of middle ear infection following the introduction of antibiotics. But in India, the incidence of TMJ ankylosis is still high. The reported age distribution ranges from 2 to 63 years. Onset is usually seen before the age of 10.

ETIOPATHOLOGY

The definite cause of ankylosis of TMJ is unknown. Two main factors predisposing to the ankylosis are *trauma and infection* in or around the joint region. In 1968, Topazian reported that 26–75% of cases of TMJ ankylosis are seen following trauma, while 44–68% are seen due to infection **(Table 23.1)**. Latest reports state that 13–100%, cases of ankylosis following trauma and 10–49% cases are due to local or systemic infection or systemic diseases around 10%, such as psoriasis, ankylosing spondylitis, etc.

Table 23.1: Etiopathology of ankylosis of TMJ.

Trauma	• Congenital • At birth, forceps delivery • Hemarthrosis (direct/indirect trauma) • Condylar fractures ▪ Intracapsular ▪ Extracapsular • Glenoid fossa fracture (rare)
Infections	• Otitis media • Parotitis • Tonsilitis • Furuncle • Abscess around the joint • Osteomyelitis of the jaw • Actinomycosis
Inflammation	• Rheumatoid arthritis • Osteoarthritis • Septic arthritis—hematogenous spread
Rare causes	• Polyarthritis • Measles
Systemic diseases	• Smallpox • Scarlet fever • Typhoid • Gonococcal arthritis • Scleroderma • Beriberi • Marie-Strümpell disease • Ankylosing spondylitis
Other causes	• Bifid condyle • Prolonged trismus • Prolonged immobilization • Unknown • Burns

JAYPEE BROTHERS

TMJ ankylosis can also occur congenitally or secondary to severe rheumatoid arthritis or to tumors in the area of TMJ. Ankylosis can also occur as a result of TMJ surgery.

Direct spread of infection from adjacent areas may occur in cases of otitis media (infection of middle ear), mastoiditis, osteomyelitis of temporal bone or parotid abscess, soft tissue abscess, skin infections, or severe odontogenic submasseteric, infratemporal abscesses, etc.

Diseases affecting the joints: Such as rheumatoid arthritis, osteoarthritis and ankylosing spondylitis bring about degenerative changes, destruction of the disk followed by the repair process. This can lead to the ankylosis of TMJ. Collagen vascular diseases like scleroderma also can lead to ankylosis.

Any other degenerative disease will also lead towards the destruction of the meniscus along with the narrowing of the joint space, leading to bony contact between the condylar head and roof of the glenoid fossa.

Prolonged immobilization following trauma to the joint area or after facial burns due to extreme scar formation can lead towards ankylosis.

Trauma: A high percentage of TMJ ankylosis are seen following trauma. At birth, TMJ may receive trauma from a forceps delivery. Trauma during intrauterine life may lead to congenital ankylosis.

Ankylosis is also generally associated with some form of facial injury at later date involving fracture of the neck or head of the condyle. Direct blow over the joint or at the chin may also cause bleeding into the joint. Any injury with hemorrhage into the joint space will initiate a progression of undesirable changes (clot organization and deposition of bone). If mandibular movement is not encouraged over a prolonged period of time, fusion will result. Comatose patients with associated condylar fracture are prone to develop ankylosis. Prolonged immobilization of condylar fractures, especially in children, where abundant blood supply is more likely to increase the incidence of hemarthrosis following injury leading to ankylosis. Therefore, a maximum period of immobilization of 3 weeks in the adults and 2 weeks in the children following reduction of condylar fracture is recommended.

HYPOTHESES FOR PATHOGENESIS OF TMJ ANKYLOSIS

True ankylosis caused due to trauma or infection, is a gradual process that is seen over months or years.

The most common etiology of TMJ ankylosis is trauma, mainly condylar fracture. Trauma to the condylar region can cause disruption of the capsular ligament and adjoining periosteum, resulting in extravasation of blood into the joint space called *hemarthrosis*. Bone fragments with very high osteogenic potential and organization of hematoma within the joint cavity leads to conversion to fibrous adhesions. This predisposes to calcification and obliteration of a joint space, where immobility of the joint is maintained over a prolonged period. Many a times initial fibrous bands lead towards bony consolidation to ossification (When the intracapsular/extracapsular hematoma following condylar fracture organizes, bone formation can occur from the disrupted periosteum or from metaplasia of non-osteogenic connective tissue and bony ankylosis eventually develops).

Li et al. (2014) after seeing the radiolucent zones in the CT scan of the ankylosed mass, acquired the histological information of the tissue found in the radiolucent zone during arthroplasty. They found fibrous and cartilaginous tissue in the joint space of fibrous ankylosis. The tissue in the radiolucent zone of bony ankylosis was cartilage and new bone matrix, and bony fusion was formed by new osteophytes progressing towards the center of the ankylotic mass. They suggested the hypothesis that bony ankylosis was formed by the stimulation of periosteal and endochondral ossification and osteophyte proliferation.

Ankylosis due to infection is due to the degenerative changes in the TMJ compartment, which again bring about deterioration of the disk and the ensuing inflammatory changes lead to the formation of granulation tissue within the joint, which subsequently leads to initial fibrosis. Subsequently there will be repair with calcification and obliteration of the joint space with initial fibrosis.

In the both etiological processes, there is flattening of the glenoid fossa and the head of the condyle is deformed and thickened, resulting in narrowing or obliteration of the joint space. Many times, bony fusion may extend well beyond the joint space to involve the cranial base and even the sigmoid notch, zygomatic arch, coronoid process. In the severest form, it may include the lateral pterygoid plate and even the spine of the sphenoid bone.

CLASSIFICATIONS OF ANKYLOSIS

- ***Based on type:*** False ankylosis or true ankylosis (Kazanjian–1938).
- ***Based on extent of ankylotic bone (AB)*** (Topazion–1966)
  - Stage I: AB limited to the condylar process.
  - Stage II: AB extending to the sigmoid notch.
  - Stage III: AB extending to the coronoid process.
- ***Based on the location:*** Extra-articular or intra-articular (Rowe–1986).
- ***Based on type of tissue fusion:*** Fibrous/fibro-osseous (Mixed type) or bony (Rowe–1986).
- ***Based on number of joints involved:*** Unilateral or bilateral.
- ***Based on the extent/severity of fusion:*** Partial or complete (Rowe–1986).

JAYPEE BROTHERS

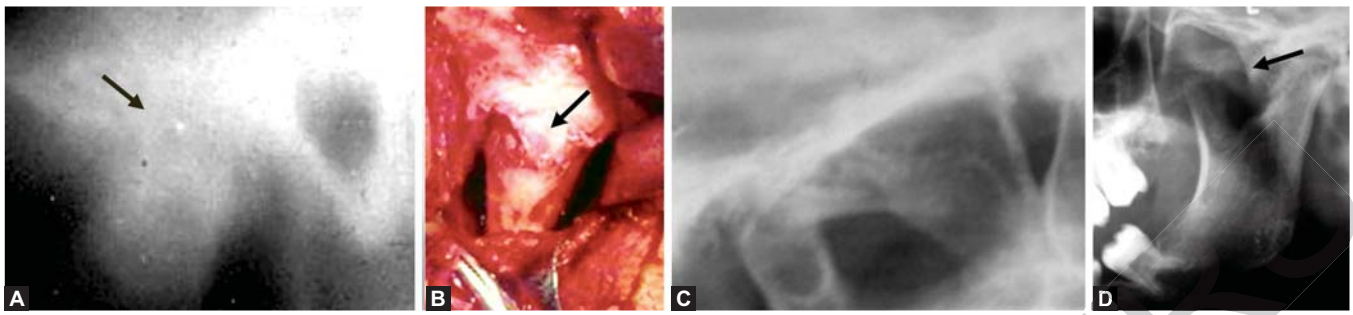

Figs. 23.1A to D: Fibrous ankylosis of TMJ: (A) Tomogram of (L) TMJ showing fibrous fusion at the joint space; (B) Surgical exposure showing fibrous union of (L) TMJ. Note the condylar head is not deformed; (C and D) Right and left TMJs from OPG—fibrous union/ankylosis.

Ankylosis of the TMJ can be secondary to either restrictions of movement by a pathological process within the joint (True/intra-articular ankylosis) or by extra-articular abnormalities (False ankylosis). Intra-articular ankylosis indicates union between the articular surfaces of the TMJ, while extra-articular ankylosis results from lesions involving extra-articular structures.

The fusion or union of the articular surfaces of the head of the condyle with the glenoid fossa may be of fibrous/fibro-osseous or bony, depending on the nature of the tissue **(Figs. 23.1 and 23.2)**.

DIAGNOSIS

Diagnosis of TMJ ankylosis is relatively easy and is dependent more upon careful clinical examination, rather than the diagnostic tests. Restricted oral opening or nil oral opening is seen and patient will complain of difficulty in mastication, swallowing, digestion, and speech.

Protrusive movements are not possible on the involved side. Also, partial mobility or complete immobility of the condyle is readily noticed, when one palpates the joint movements. Pain is totally absent.

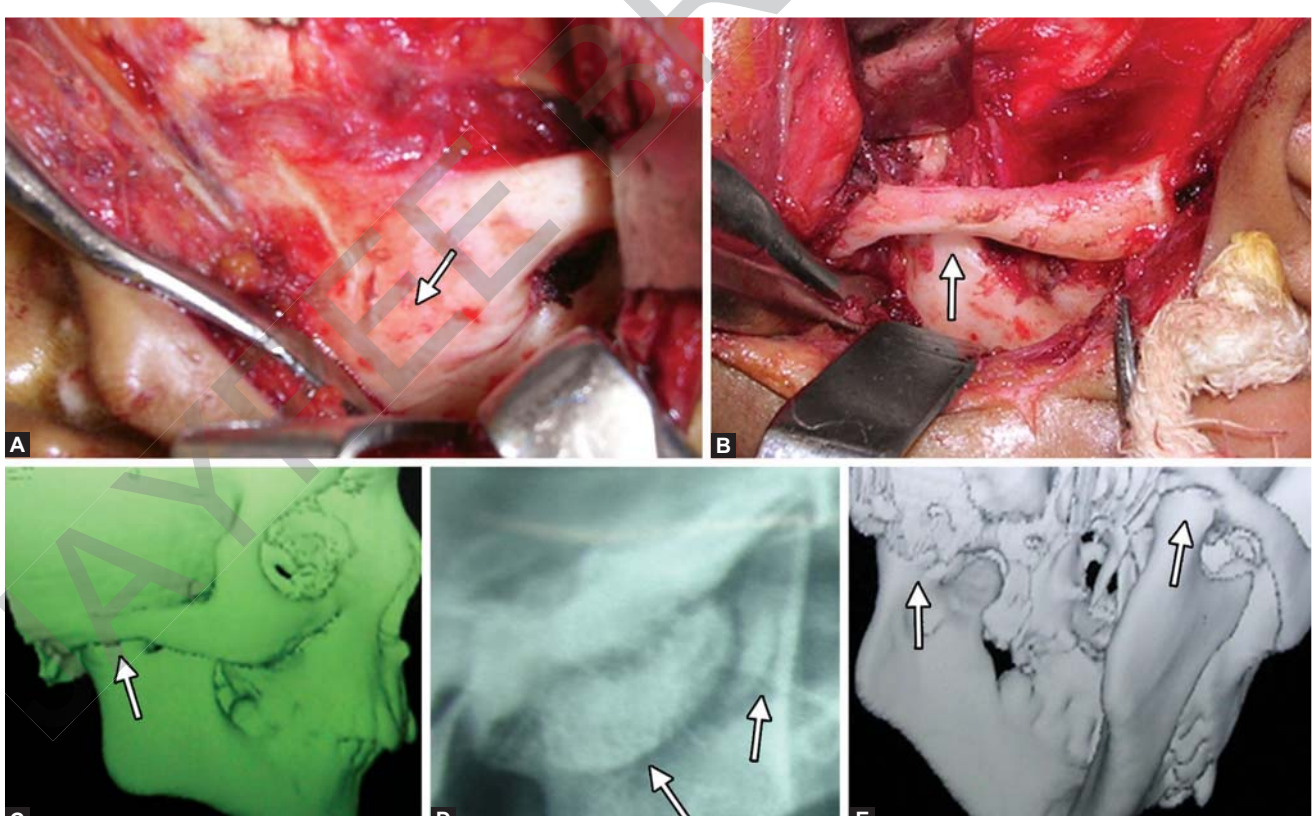

Figs. 23.2A to E: Bony ankylosis: (A and B) Surgical exposure of (R) and (L) TMJs showing the bony ankylosed mass, with deformed head of the condyle, normal TMJ anatomy is totally lost; (C) 3D CT scan showing (R) TMJ bony ankylosis; (D) OPG—(R) Side bony ankylosis and deformed condylar head and elongated coronoid process; (E) Medial rotation 3D scan view showing one side bony ankylosis and other side fibrous ankylosis of TMJ without distortion of condylar head.

JAYPEE BROTHERS

In addition, in a young patient, a nature of facial deformity will help to differentiate between unilateral and bilateral involvement. Facial asymmetry develops in unilateral cases. Disturbances of facial and mandibular growth is noticed in bilateral TMJ ankylosis cases with acute compromise of the airway—obstructive sleep apnea (OSA). It invariably results in physical as well as psychological problems.

The onset of disease usually occurs in children under 10 years with an equal gender involvement. Patient will give history of progressive reduction in the jaw opening. Generally, the formation of bony ankylosis takes a long time, ranging from several months to several years after the occurrence of injury or many times patients are not able to remember the history of trauma in early childhood.

CLINICAL MANIFESTATIONS

Clinical manifestations vary according to: (1) severity of ankylosis, (2) time of onset of ankylosis, and (3) duration.

- ***Early joint involvement—less than 15 years:*** Severe facial deformity and loss of function.
- ***Later joint involvement after the age of 15 years:*** Facial deformity marginal or nil. But, functional loss severe.

Those patients in whom the ankylosis develops after full growth completion have no facial deformity.

Facial asymmetry: It becomes progressively worst, if ankylosis not treated early, due to the hypomobility and abnormal muscle function. Longer the duration, more severe will be muscle atrophy and facial asymmetry. The short ramus-condyle unit (RCU) also restricts midface growth. Secondary hyperplasia and elongation of coronoid process can further restrict the jaw movements.

Unilateral Ankylosis

Seen in a child or in a person where the onset was usually in the childhood.

- Obvious gross facial asymmetry.
- Deviation of the mandible and chin on the affected side.
- The chin is receded with hypoplastic mandible on the affected side.
- Roundness and fullness of the face on the affected side.
- The appearance of the flatness and elongation on the unaffected side.
- The lower border of the mandible on the affected side has a concavity that ends in a well-defined antegonial notch. (Antegonial notch is just anterior to the insertion of masseter muscle. Mylohyoid and digastric muscle pull is thought to be responsible for the formation of marked notching at the inferior border.)
- In unilateral ankylosis, some amount of oral opening may be possible. Interincisal opening will vary depending on whether it is fibrous or bony ankylosis.
- Cross bite may be seen.
- Class II angles malocclusion on the affected side plus unilateral posterior cross bite on the ipsilateral side seen.
- In some cases, the ipsilateral maxillary growth can get affected, resulting in maxillary cant.
- Condylar movements are absent on the affected side **(Figs. 23.3A to H)**.



Figs. 23.3A to H: Unilateral ankylosis: Facial and dental features—partial oral opening. (A to D) Right side ankylosis; (E to H) Left side ankylosis.
Courtesy: Dr Vidya Rattan

JAYPEE BROTHERS

Bilateral Ankylosis

- Inability to open the mouth progresses by gradual decrease in interincisal opening. The mandible is symmetrical, but retrognathic/micrognathic. The patient develops typical "*bird face*" deformity with receding chin. Convex profile. (Facial deformity is also known as "Andy Gump" deformity.)
- The neck chin angle may be reduced or almost completely absent.
- Antegonial notch is well defined/accentuated bilaterally.
- Class II malocclusion can be noticed. Upper incisors are often protrusive with anterior open bite. Maxilla may be narrow. Steep occlusal plane is due to short posterior maxillary height.
- Oral opening will be <5 mm or many times there is nil oral opening. No palpable joint movements.
- Multiple carious teeth with bad periodontal health can be seen.
- Severe malocclusion, crowding can be seen and many impacted teeth may be found on the X-rays. Also elongated coronoid process seen in the X-rays **(Figs. 23.4A to J)**.
- Associated respiratory distress—obstructive sleep apnea (OSA).

Diagnosis

Diagnosis is based on the following:

- History of trauma, infection, duration in reduction of oral opening, etc.
- Clinical findings.
- Radiographic findings—are important in arriving at a final diagnosis **(Figs. 23.5A to F)**.



Figs. 23.4A to J: (A to E) Bilateral ankylosis of TMJ showing typical "bird face" and facial profile features, severe micrognathia in bilateral TMJ ankylosis case, nil oral opening and dental features in bilateral TMJ ankylosis; (F to J) Another patient of bilateral ankylosis and scintigraphy showing increased uptake in TMJ areas, indicating active ankylosis process.

Courtesy: Dr Vidya Rattan

JAYPEE BROTHERS

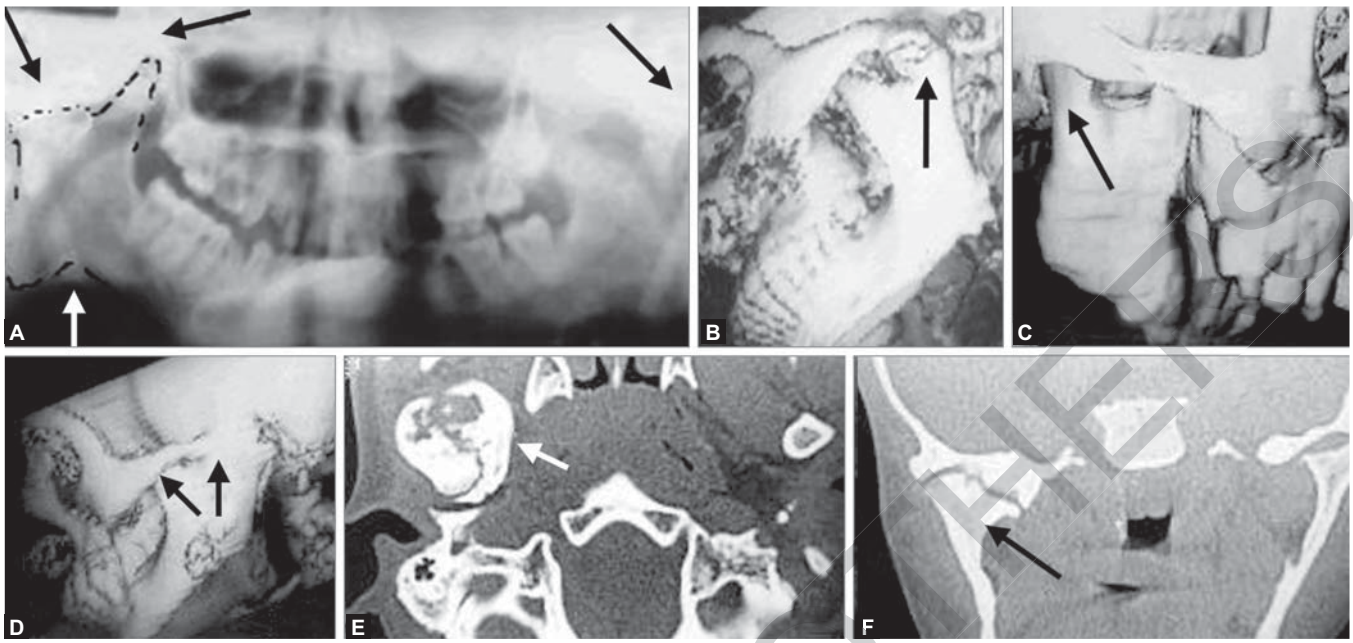

Figs. 23.5A to F: (A) OPG bilateral ankylosis; (B) Unilateral ankylosis—3D scan; (C) Normal TMJ in 3D scan; (D) (L) TMJ ankylosis 3D scan showing bony fusion and elongated coronoid process; (E) Axial scan—bony ankylosis; (F) Coronal scan—bony ankylosis.

- *Orthopantomograph*—will show both the joints picture which can be compared in unilateral cases. Presence of prominent antegonial notch can be appreciated which develops secondary to the contraction of the depressor muscles and their action against elevator group of muscles. The antegonial notch becomes more pronounced in severe cases. It does not reveal the medial extent of bony mass and its relation to surrounding vital structures.
- *Lateral oblique view*—will give anteroposterior dimension of the condylar mass. Elongation of coronoid process can be seen.
- *Cephalometric radiograph*—is taken to evaluate the associated skeletal deformities.
- *Posteroanterior radiograph*—will reveal the mediolateral extent of the bony mass. It will also highlight the facial asymmetry in unilateral cases.
- *CT scan*—very helpful guide for surgery. Relation to the medial cranial fossa, the anteroposterior width, mediolateral depth can be assessed. Any presence of fractured condylar head on the medial aspect of ramus can be located. In cases of reankylosis, the bony fusion can be appreciated. 3D CT scan will give life size picture of all aspects of the deformity **(Figs. 23.6 and 23.7)**.

Details about Radiographic Findings

Fibrous Ankylosis

In fibrous ankylosis, reduced joint space and hazy appearance can be seen. But, still the normal anatomy of the head and glenoid fossa can be appreciated **(Figs. 23.1A to D)**.

Bony Ankylosis

Fusion of the joint with complete obliteration/loss of joint space. Normal TMJ anatomy is distorted. Deformed condylar head or complete bony consolidation replacing the joint space can be seen. Elongation of the coronoid process/hyperplasia on the side of hypomobility will be seen. Prominent antegonial notch also can be seen **(Figs. 23.2C to E)**.

IMAGING INTERPRETATION-BASED CLASSIFICATIONS

Many researchers proposed various classifications based on imaging results, which are helpful in knowing the detailed extent of ankylosis and relations to the adjoining structures. These are helpful in surgical planning also.

1. Sawhney in 1986, graded TMJ ankylosis into four types based on plain radiographs **(Table 23.2)**.
2. In 2002, Hakim and Metwalli proposed that *ankylosed joints can be grouped as per the relation of their ankylosed mass to the surrounding vital structures, especially to the base of the skull*, interpreted from CT scan.
3. Long Xia et al. (2019) proposed a classification based on coronal scans, considering the change in joint space and a radiolucent zone seen, into four types. Coronal and axial CT scan images can be more informative and allow the surgeon to plan the surgery **(Fig. 23.8)**.

Classification of TMJ Ankylosis as per Postcontrast Axial and Coronal CT Scan Interpretation (Hakim and Metwalli)

Class 1: Unilateral/bilateral ankylosis, the condyle and glenoid fossa retain their original shape, and the maxillary artery is in normal anatomic relation to the ankylotic mass.

JAYPEE PROOFS

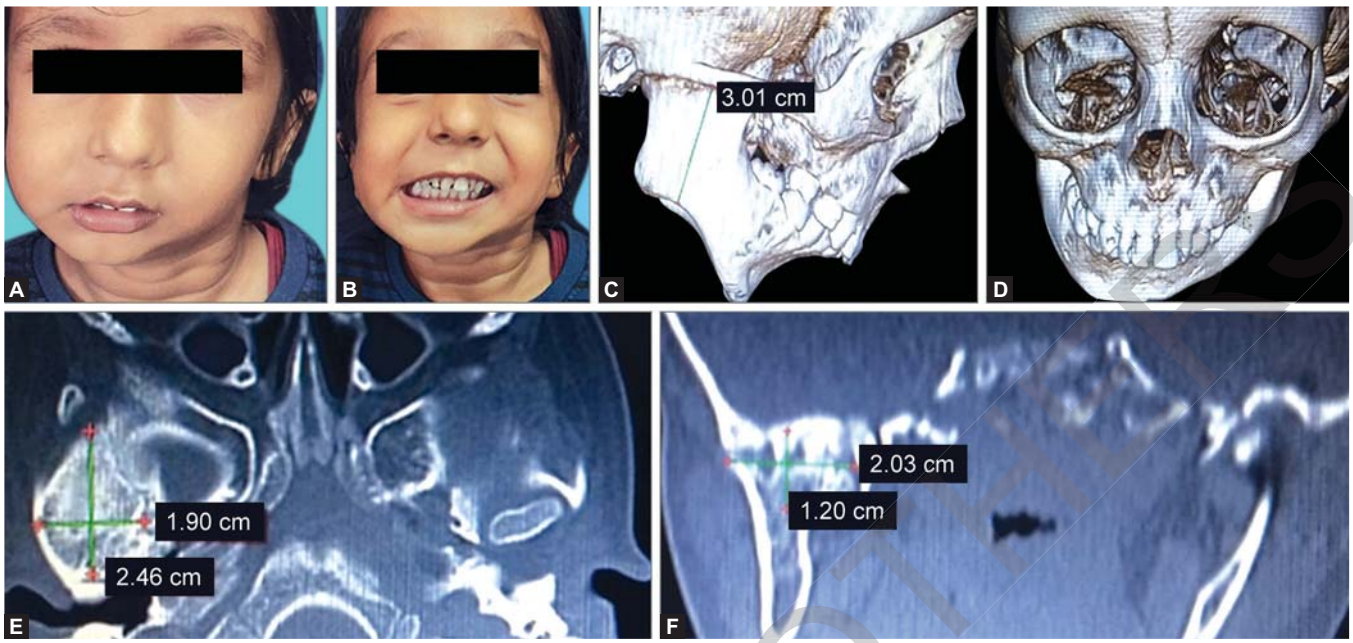

Figs. 23.6A to F: (A) Unilateral ankylosis—frontal face; (B) Unilateral ankylosis—oral opening; (C) Right side TMJ ankylosis in 3D scan, showing bony fusion and elongated coronoid process; (D) R TMJ ankylosis 3D scan in frontal view showing comparison in right and left mandibular growth; (E) Axial scan—right side bony ankylosis; (F) Coronal scan—right side bony ankylosis.

Courtesy: Dr Jotsna Galinde

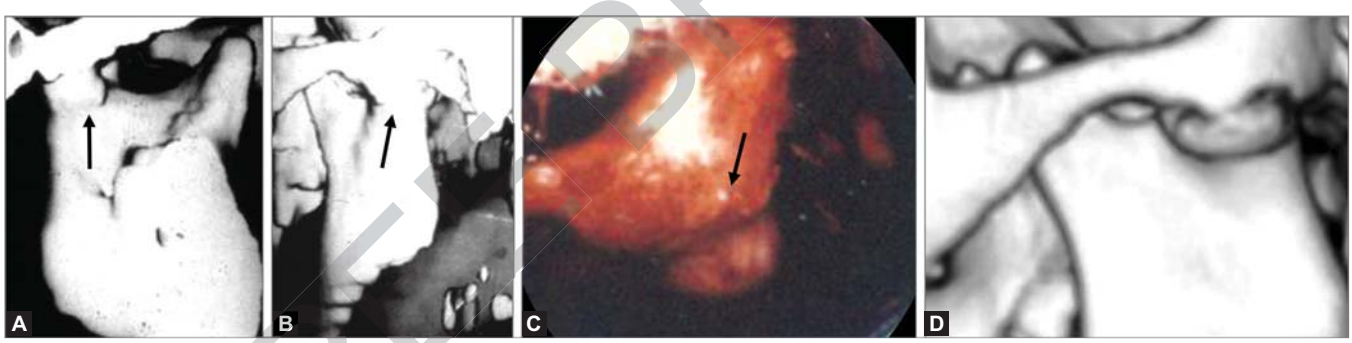

Figs. 23.7A to D: 3D CT scan for (L) TMJ ankylosis: (A) Medial rotation 3D scan with disarticulation; (B) Lateral rotation 3D scan with disarticulation; (C) Intraoperative picture of TMJ ankylosis of the same patient. Appreciate the similarity; (D) 3D CT scan of left side TMJ ankylosis showing the bony block and elongated coronoid process.

Table 23.2: Grading of TMJ ankylosis by Sawhney (1986). Depending on the extent of fusion visualized on tomograms.

Type I	The condylar head is present without much distortion. Fibrous adhesions make movement impossible
Type II	Bony fusion of the mis-shaped head and the articular surface. No involvement of sigmoid notch and coronoid process
Type III	A bony block bridging across the ramus and the zygomatic arch. Medially an atrophic dislocated fragment of the former head of the condyle is still found. Elongation of the coronoid process seen
Type IV	The normal anatomy of the TMJ is totally destroyed by complete bony block between the ramus and the skull base

Class 2: Unilateral/bilateral ankylosis, between the condyle and glenoid fossa/temporal bone, and the maxillary artery is in normal anatomic relation to the ankylotic mass.

Class 3: The distance between the maxillary artery and the medial pole of the condyle is less on the ankylosed side than in the normal side or the maxillary artery runs within the ankylotic bony mass—best seen in coronal CT.

Class 4: The ankylosed mass is fused to the base of the skull with extensive bone formation, especially from the medial aspect of the condyle. The ankylosed bony mass is in close relationship to the pterygoid plates, the carotid and jugular foramina, foramen spinosum. No normal joint anatomy can be seen. Best visualized on axial CT.

JAYPEE PROOFS

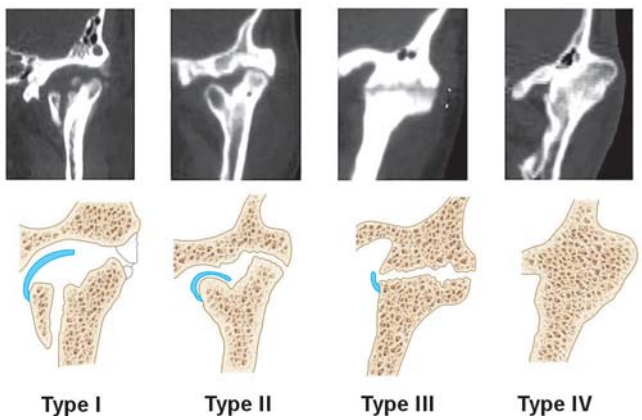

Fig. 23.8: Long Xia et al. classification (2019) based on the findings of coronal CT scan, which helps in Planning the surgery.

Long Xia et al. Classification based on Coronal CT Scan Interpretation

Type I: Non-bony ankylosis, with the condyle and glenoid fossa clearly seen with scattered callus. Almost normal joint space and no radiolucent line.

Type II: Lateral bony ankylosis. The medially displaced condylar fragment, residual disk and fossa form a pseudoarthrosis.

Type III: Complete bony ankylosis of the joint with a radiolucent line inside the fusion but no recognizable condyle or fossa.

Type IV: Extensive bony ankylosis with no radiolucent line and no joint features seen.

Sequelae of Untreated Ankylosis

- Normal facial growth and development affected severely
- Speech impairment
- Nutritional impairment
- Respiratory distress (tongue fall in sleep), especially, in bilateral involvement with severe micrognathia (Obstructive Sleep Apnea syndrome-OSA). This is the triad seen in bilateral ankylosis patients:
  - TMJ ankylosis
  - Severe retrognathia or micrognathia
- Malocclusion
- Poor oral hygiene
- Multiple carious and impacted teeth
- Inability to offer any dental treatment.

MANAGEMENT OF TMJ ANKYLOSIS

The treatment of TMJ ankylosis is always surgical. Early surgical correction of the ankylosed joint is highly desirable, if satisfactory function is to be regained.

Surgical strategy adopted depends on the following:

- Age of onset of ankylosis
- Extent of ankylosis
- Whether there is unilateral or bilateral involvement
- Associated OSA syndrome
- Associated facial deformity.

Aims and Objectives of Surgery

- Release/resection of ankylosed mass and creation of a gap to mobilize the joint.
- Release of all limiting muscular or mechanical forces preventing the full opening of the mouth
- Creation of a ramus-condyle functional joint:
  - To improve patient's nutrition.
  - To improve patient's oral hygiene.
  - To carry out necessary dental treatment.
- To reconstruct the joint and restore the lost vertical height of the ramus
- Allow for normal or near normal movements of the TMJ
- Relieve distress of OSA
- To prevent recurrence—reankylosis
- To restore/promote normal facial growth pattern (based on functional matrix theory/adaptive growth center).
- To improve esthetics and carry out occlusal rehabilitation of the patient (cosmetic surgery may be carried out at a later date or at second phase).

The Internationally Accepted Sequential Protocols for the Management of TMJ Ankylosis

Put forward originally by Kaban, Perrot and Fisher in 1990, which had global approval and later modified in 2009, by Kaban, Bouchard and Troulis. Basically, they suggested this protocol for the management of TMJ ankylosis in children. It was their observation that the common cause of treatment failure was inadequate resection of the ankylotic mass and failure to achieve adequate passive maximal opening intraoperatively on operating table. Now these modified protocols are also followed all over the world.

- **Early surgical intervention**.
- ***Aggressive resection:*** Aggressive excision of the fibrous/bony ankylotic mass. A gap of at least 1–1.5 cm should be created. Special attention should be given to the fusion on the medial aspect of the ramus. Old malunited condylar fractured piece can be seen attached on the medial side.
- ***Ipsilateral coronoidectomy and temporalis myotomy:*** In most of these cases, there is always association of elongated coronoid process. After carrying out gap arthroplasty, the coronoidectomy on the same side should be carried out either separately or in combination with the gap arthroplasty cut from the same extraoral incision. The coronoid process is cut from the level of sigmoid notch till the anterior border of the ramus. The temporalis muscle attachments are severed by carrying out temporalis myotomy. The oral opening is checked after this procedure by

JAYPEE BROTHERS

the assistant. If maximum interincisal opening is >35 mm is obtained, then there is no need to carry out contralateral coronoidectomy.

- ***Contralateral coronoidectomy and temporalis myotomy is necessary:*** If maximum incisal opening is <35 mm after carrying out above steps and if there is dislocation of the unaffected side of the condylar head, while gaining the maximum opening on table. Then uninvolved side coronoidectomy and temporalis myotomy can be carried out through intraoral incision **(Figs. 23.14 and 23.15)**.
- **Lining of the glenoid fossa region** with temporalis myofascial flap, or the native disk, if it can be salvaged.
- **Total joint reconstruction (TJR) of the ramus condyle unit (RCU)** with a costochondral graft (CCG) and rigid fixation or with distraction osteogenesis.

  If distraction osteogenesis is used to reconstruct the RCU, mobilization begins on the day of surgery. In patients who undergo CCG procedure, mobilization is done after 10 days of MMF.
- Early mobilization and aggressive physiotherapy for the period of at least 6 months postoperatively.
- Regular long-term follow-up
- In recurrent ankylosis cases, TJR
- To carry out cosmetic surgery at the later date, when the growth of the patient is completed.

New protocols for treating a triad of TMJ ankylosis, mandibular retrognathia/micrognathia and severe OSA syndrome:

- **Single stage surgery:** Simultaneous release of ankylosis and horizontal mandibular distraction.
  In adult patients with an apnea/hypopnea index (AHI) score is less than 20, single stage surgery can be beneficial.
- **Multistage surgical treatment:** Initial mandibular distraction in first stage to relieve OSA and second stage release of TMJ ankylosis.
  Incidence of reankylosis in the patients with triad of TMJ ankylosis is high due to noncompliance of patients with retrognathia for post-release physiotherapy, mainly due to the bradycardia and respiratory distress developed during physiotherapy. (Choking sensation due to obstruction of the airway) Initial distraction osteogenesis gives relief to respiratory distress by advancing the mandible and improving the airway.

Both above methods bring about successful results. But later on orthodontic treatment followed by various orthognathic surgical procedures are required for complete rehabilitation.

Intubation Techniques for General Anesthesia

- Blind awake nasal intubation
- Retrograde intubation
- Fiberoptic nasoendotracheal intubation—gold standard
- Tracheostomy intubation.

Surgical approaches: Basically, various incisions can be chosen to approach the joint area with the objectives of gaining proper access and proper exposure. One has to take at most care to prevent damage to facial nerve and its branches, to major vessels and parotid gland. The resultant scar also should be as inconspicuous as possible.

- ***Preauricular:*** Al-Kayat and Bramley, Blair and Ivy, Dingman, Thoma, Popowitch and Crane incision:
- ***Endaural incision***
- ***Postauricular incision***
- ***Hemicoronal or Bicoronal incision***
- ***Submandibular incision***
- ***Postramal-Hind's incision.***
- ***Inviscision—new incision with highly cosmetic results.***

Surgical Techniques Options

Number of techniques have been advocated by different surgeons. Critical analysis of all, filters only to four basic methods.

1. Condylectomy
2. Gap arthroplasty
3. Interpositional arthroplasty
4. Total joint reconstruction either with autogenous CCG or sternoclavicular joint graft (SCG) or with distraction osteogenesis or with patient fitted or stock prostheses.

Most surgical procedures can be done through a preauricular incision alone. The Popowich's incision is chosen for its obvious advantages. Whenever required, additional submandibular incision can be used for fixation of the graft, etc.

Condylectomy

Condylectomy is advocated in cases of fibrous ankylosis, where the joint space is obliterated with deposition of fibrous bands, but there is not much deformity of the condylar head **(Figs. 23.9A to F)**. The condylectomy procedure can be carried out via preauricular incision.

Radiologically and clinically after surgical exposure one can see the demarcation between the roof of the glenoid fossa and the head of the condyle. Horizontal osteotomy cut is carried out with the help of the surgical bur at the level of condylar neck. Vital structures on the medial surface of the condylar neck should be protected, by using special condylar retractor, inserted prior to the bony cut. The condylar head, which is sectioned from ramus, then should be separated from the superior fibrous attachments carefully and removed. The rest of the ramal stump should be smoothened out and wound closed in layers. Unilateral condylectomy tends to cause deviation of the mandible towards the operated side on oral opening and if bilateral, anterior open bite will be caused as a result of the loss of height in the vertical rami.

Therefore, when the site of the fused joint is mobilized via condylectomy, then after recontouring by arthroplasty,

JAYPEE BROTHERS

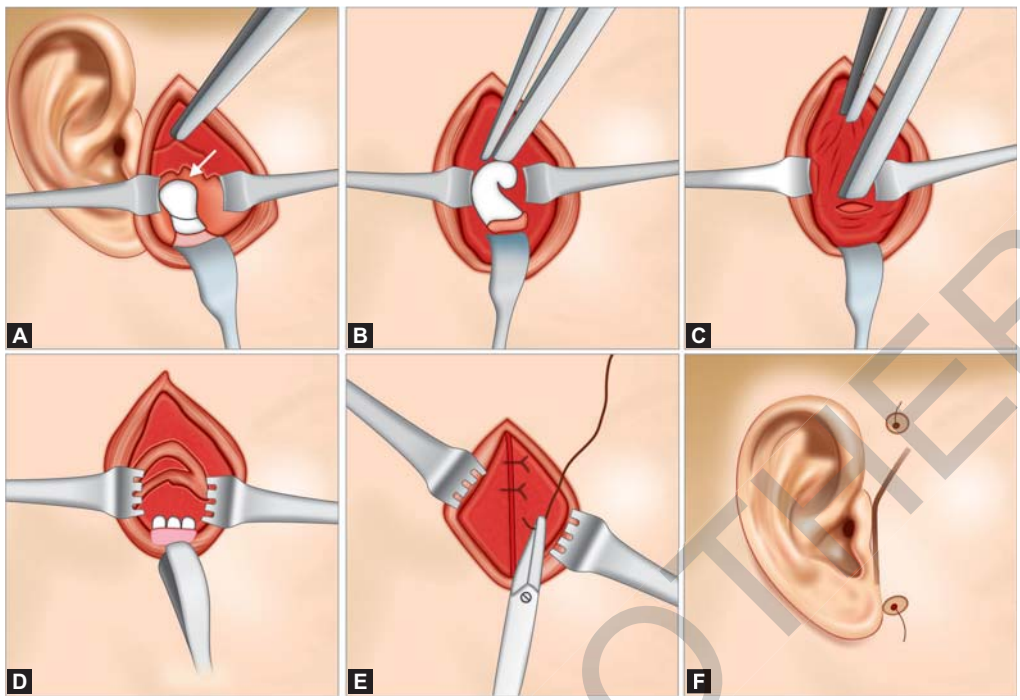

Figs. 23.9A to F: Condylectomy—surgical procedure: (A) Exposure of condylar head via preauricular incision; (B) Sectioning of condylar head; (C) Breaking the fibrous adhesions; (D) Condylectomy complete; (E) Suturing the capsule; (F) Final skin suturing.

an alloplastic material can be used to maintain the joint space, satisfactory occlusion and joint movements.

Gap Arthroplasty/Osteoarthrectomy

In the extensive bony ankylosis, a broad, thick area of bone deposition obliterates the entire joint, sigmoid notch and coronoid process. Identification of the previous joint structure is impossible and mobilization at the level of the joint becomes difficult, if not impossible (one cannot identify the roof of the glenoid fossa, which forms the floor of the middle cranial fossa) **(Figs. 23.10 to 23.12)**.

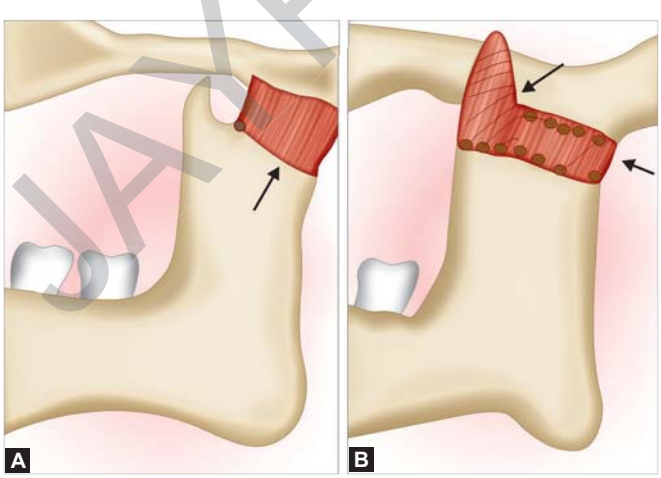

Figs. 23.10A and B: Diagrammatic representation: (A) Gap arthroplasty; (B) Gap arthroplasty with coronoidectomy.

The term *gap arthroplasty* is therefore, used to describe the operation, in which the level of section is below that of the previous joint space and in which, no substance is interposed between the two cut bony surfaces. Resection of the bony mass consists of two horizontal osteotomy cuts and removal of a bony wedge for creation of a gap between the roof of the glenoid fossa and ramus. Here, it is recommended to create a minimum gap of at least 1–1.5 cm to prevent reankylosis. **The width of the bone removed is considered crucial.** It is not usually possible to remove the entire block *in toto*, particularly from the medial aspect, which is in close proximity to the internal maxillary artery. Hence, bone is removed carefully by using a large round bur/saw/piezoelectric unit, until the medial bone is thinned out enough to be readily removed by using hand chisel or osteotome. It is important to create a gap of equal dimension both laterally and medially, so that the possibility of medial reankylosis due to bone contact is avoided. If the disk is identified then, it can be used to line the fossa side. Recurrence rate reported recently in the literature after only gap arthroplasty is around 60%.

Gap arthroplasty offers an advantage of a simple procedure and requires a short surgical time. However, disadvantages include the following: (1) creation of a pseudo-articulation, (2) a short mandibular ramus with anterior open bite in bilateral cases and posterior open bite in unilateral cases, (3) high recurrence rate.

JAYPEE BROTHERS

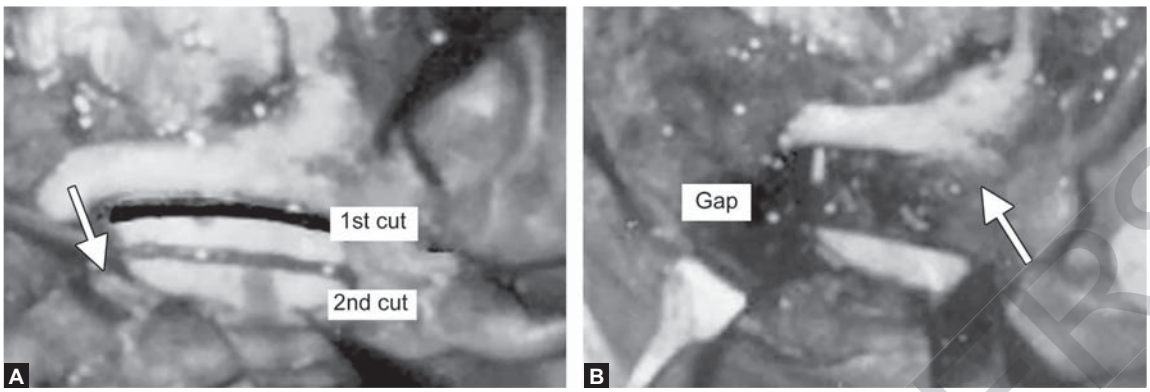

Figs. 23.11A and B: Gap arthroplasty surgery: Intraoperative pictures: (A) Surgical exposure of left ankylosed TMJ. 1st and 2nd bony cuts are seen. The wedge of bone between the two cuts is removed to create a gap and release the ankylosis; (B) Gap arthroplasty completed to achieve the mobility of the joint.

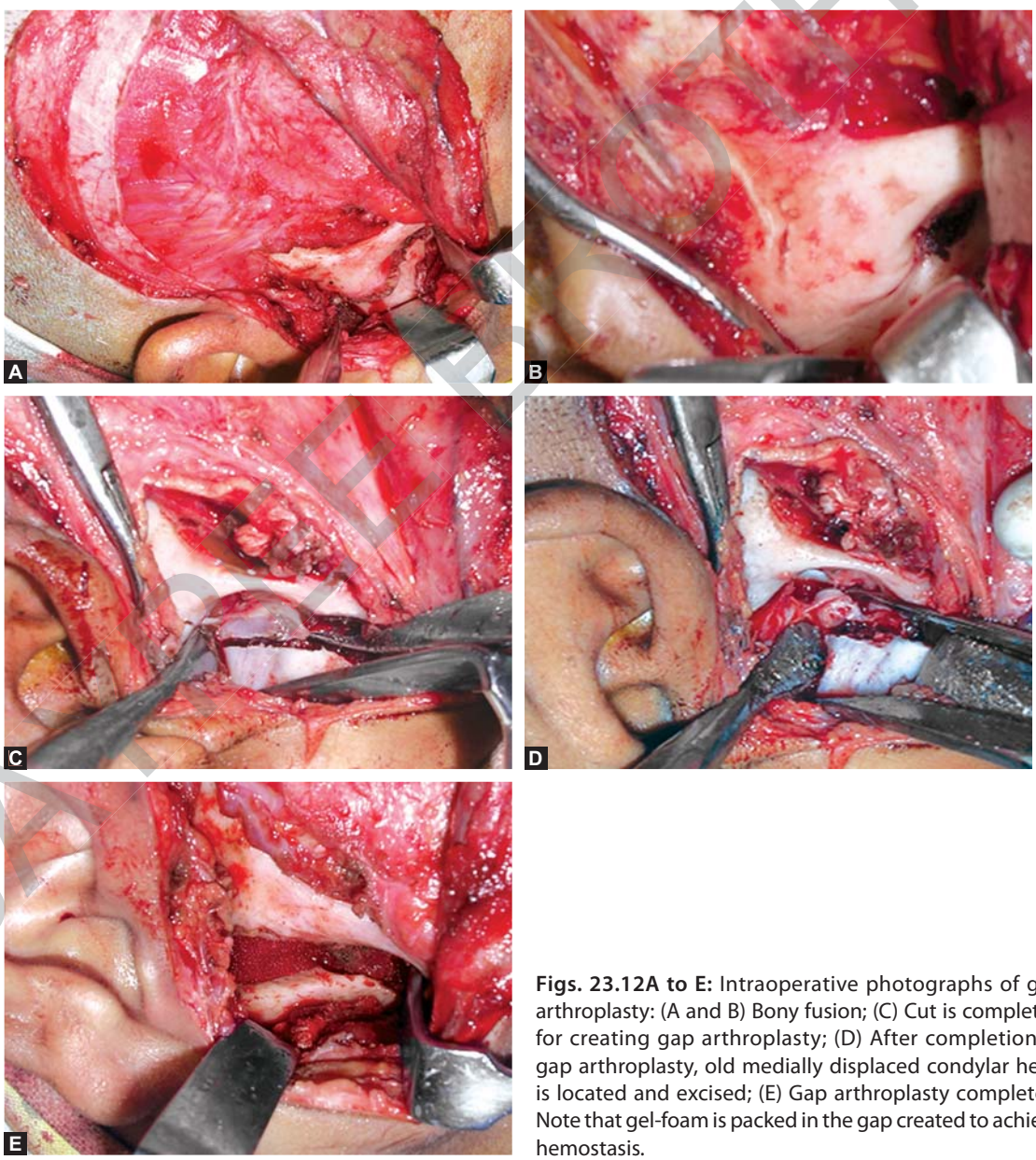

Figs. 23.12A to E: Intraoperative photographs of gap arthroplasty: (A and B) Bony fusion; (C) Cut is completed for creating gap arthroplasty; (D) After completion of gap arthroplasty, old medially displaced condylar head is located and excised; (E) Gap arthroplasty completed. Note that gel-foam is packed in the gap created to achieve hemostasis.

JAYPEE BROTHERS

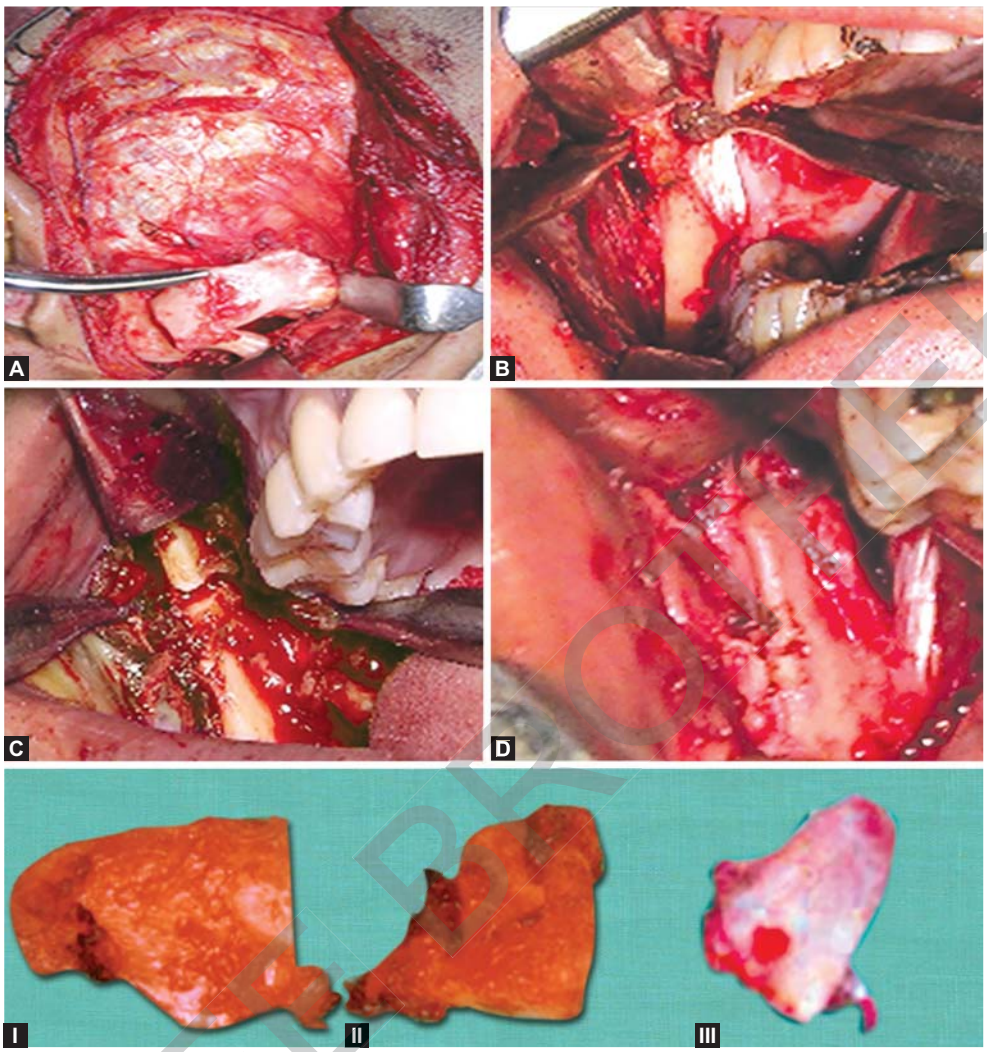

Figs. 23.13A to D: (A) Extraoral coronoidectomy carried out after the release of TMJ ankylosis by gap osteoarthroplasty; (B) Intraoral coronoidectomy surgical procedure for the contralateral side, exposure of coronoid process through intraoral incision; (C) Coronoid tip is released from temporalis muscle by myotomy and coronoidectomy cut is done; (D) Remaining ramus portion, (I and II) Bilateral coronoid processes excised, (III) Unilateral coronoid excision in other case.

Coronoidectomy: The next step as per the established surgical protocols after gap arthroplasty is carry out ipsilateral and contralateral coronoidectomy as per the indications. Ipsilateral procedure can be done through the same external incision. In case of unilateral ankylosis, contralateral procedure can be done through intraoral incision. Release of the jaw movements is quite dramatic, upon completion of coronoidectomy. A hole can be drilled at the tip of coronoid and a wire threaded through it, before the cut to have better control. The osteotomy cut extends from the depth of the sigmoid notch to the junction of the horizontal and vertical rami of the mandible. It is always desirable to excise the coronoid rather than release it and allow it to be pulled up superiorly by the temporalis muscle. Unless the coronoid process is removed, there is potential for reankylosis after reattachment **(Figs. 23.13A to D)**. The assistant is asked to use jaw stretcher intraorally after completion of gap arthroplasty, to check the oral opening **(Fig. 23.14)**.



Fig. 23.14: Checking oral opening with jaw stretcher after gap arthroplasty.

JAYPEE BROTHERS

for detailed information on dental books, visit our website www.jaypeebrothers.com, for detailed information on dental books, visit our website ww

Textbook of
Oral and Maxillofacial Surgery

Salient Features

- Extensive, pointwise, precise coverage of the subject of oral and maxillofacial surgery, following the syllabi of all the universities in India and Asia with simple yet precise presentation in terms of scientific information.
- Includes more than 2,500 well-illustrated pictures, including many line drawings, flowcharts, clinical photographs, radiographs, CT/MRI scans, scintigraphy images, and photographs of latest equipment, along with 1,000 relevant diagrams and more than 150 tables and algorithms.
- Divided into 19 sections with 55 chapters, ranging from basic principles in the subject to complicated surgical procedures, and recent advances have been incorporated to give added edge. Many unique features with international and contemporary approaches are included in this edition, which will be helpful for undergraduates, postgraduates, teachers, and general practitioners.
- Extensive update of each and every chapter with addition of three new chapters: Rational Pharmacotherapy in Dentistry, Medicolegal Dilemmas in Oral and Maxillofacial Surgery, and Recent Advances.
- Comprehensive latest references added in each chapter for additional information based on current clinical trends, research activities, and clinical experience of the authors.
- Provides key guidelines for safe, sound oral and maxillofacial surgical procedures, contributed by reputed teachers from different prestigious institutions all over India (dental as well as medical). Many new contributors have imparted an updated version.

Neelima Anil Malik BDS MDS (Bom) FIAOS is an excellent academician and a popular teacher with teaching experience at prestigious institutions for over 40 years. She is a Consultant Oral and Maxillofacial Surgeon in Mumbai, Maharashtra, India.

She was formerly first lady Vice-Chancellor in India from the dental stream (Oral and Maxillofacial Surgery also) of Health Sciences University at Krishna Institute of Medical Sciences "Deemed to be University", Karad, Maharashtra, India; former recognized PHD guide in the subject of Oral and Maxillofacial Surgery; former Principal and Head, Department of Oral and Maxillofacial Surgery, Krishna Institute of Medical Sciences "Deemed to be University's" School of Dental Sciences and Hospital, Karad; former Dean and Professor and Head and Professor Emeritus, Department of Oral and Maxillofacial Surgery, Nair Hospital Dental College, Mumbai, Maharashtra, India; former recognized undergraduate teacher from 1974 and postgraduate teacher of University at Mumbai from 1980 and Maharashtra University of Health Sciences; and former Honorary Advisor and Consultant, Armed Forces Medical College (Dental Faculty), Pune, Maharashtra. She was Honorary Faculty at Shreemati Nathibai Damodar Thackersey (SNDT) Women's University and Advisor to Mumbai Veterinary College, Parel, Mumbai. She was instrumental in starting dentistry for animals and guided postgraduate theses.

She has been an outstanding meritorious student and is a recipient of several scholarships and awards including Dr VM Desai Gold Medal for securing the highest marks in all four BDS examinations held by Bombay University and also a recipient of Dr Mehta Silver Medal. She is a recipient of Mumbai Mayor's Award, 2006, and recipient of Outstanding Teacher Award, 2011, by BITEIN, a premier portal in Indian Dentistry. She received Lifetime Achievement Award by AOMSI at 40th annual conference held at Amritsar on November 19, 2015. She is a recipient of total four Lifetime Achievement Awards for her exemplary contribution and a recipient of prestigious National Oral Healthcare Sushruta Award on December 23, 2017, in the category of Empowered Woman in Dentistry.

She is also a recipient of Dr R Ahmed Award at the ZEE 24 Taas-DDI-AAROGYA SANMAN—The DDI Healthcare Excellence Award 13th December 2018. She has conducted many hands-on workshops and has been an active member of Association of Oral and Maxillofacial Surgeons of India (AOMSI). She had also been the Executive Committee Member, Scientific Secretary, Vice-President, and First Lady President of Association of Oral and Maxillofacial Surgeons of India, in 2003. She has widely travelled in India and abroad as a guest/keynote speaker and awarded Best Overseas Poster Prize at 14th Australian Orthodontic Conference, held at Adelaide, South Australia. She is a pioneer for Mandibular and Maxillary Intraoral Distraction Osteogenesis Devices in India. She was also one of the early promoters of Surgical Orthodontics and Orthognathic Surgery in India. She has developed many indigenous oral surgical instruments and intraoral mini-distractor device for mandible in 2002 and for maxilla in 2004. She has guided more than 60 dissertations and undertaken and guided many research activities. She is also a motivator to many students and known for helping and shaping the lives of many youngsters.

Printed in India

Available at all medical bookstores or buy online at www.ejaypee.com

JAYPEE BROTHERS
Medical Publishers (P) Ltd.
EMCA House, 23/23-B, Ansari Road, Daryaganj, New Delhi - 110 002, INDIA
www.jaypeebrothers.com

Join us on facebook.com/JaypeeMedicalPublishers
Follow us on instagram.com/JaypeeMedicalPublishers

Shelving Recommendations
ORAL & MAXILLOFACIAL SURGERY

ISBN 978-93-6616-664-3