dics books, visit our website www.ejaypee.com, for detailed information on orthopedics books, visit our website www.ejaypee.com, for detailed information on orthopedics books

Infection *After* Fracture

Viewpoints & Watchpoints







Editors
Vikas M Agashe
Anand J Thakur

Forewords
Rajeev Soman
Mandeep S Dhillon
John Mukhopadhaya

JAYPEE

CONTENTS

CHAPTER 1: **Infection after Fracture: Current Scenario** 1
Vikas M Agashe, Anand J Thakur

CHAPTER 2: **Philosophy of Management of Open Fractures and Infections Following Fractures** 8
Vikas M Agashe, Anand J Thakur

CHAPTER 3: **World of Microbes** 19
Shaoli Basu, Vikas M Agashe, Anand J Thakur

CHAPTER 4: **Prevention of Surgical Site Infection** 37
Netra A Vaidya, Sanjay B Kulkarni, Anand J Thakur, Vikas M Agashe

CHAPTER 5: **ABC of Antimicrobials** 51
Astha Bijwe, Ayesha J Sunavala, Vikas M Agashe, Anand J Thakur

CHAPTER 6: **Infection after Fracture: Doubt to Diagnosis** 73
Aditya Menon, Anand J Thakur, Vikas M Agashe

CHAPTER 7: **Rationalizing and Streamlining Management of Infection after Fracture** 87
Vikas M Agashe, Anand J Thakur

CHAPTER 8: **Soft Tissue Cover in Open Fractures and Infection after Fractures** 96
Bimal Mody, Shivprasad V Date, Vikas M Agashe, Anand J Thakur

CHAPTER 9: **Dead Space Management, Local Antibiotics, and Negative Pressure Wound Therapy** 112
Aditya Menon, Anand J Thakur, Vikas M Agashe

CHAPTER 10: **Open Fractures: Introduction** 129
Vikas M Agashe, Anand J Thakur

CHAPTER 11: **Debridement in Open Fractures** 136
Vikas M Agashe, Anand J Thakur

CHAPTER 12: **Skeletal Stabilization in Open Fractures** 150
Vikas M Agashe, Anand J Thakur

CHAPTER 13: **Stability, Instability, and Infection: Striking a Balance** 169
Vikas M Agashe, Anand J Thakur

CHAPTER 14: **Early Infection after Fracture: Retain or Remove the Implant?** **181**
Vikas M Agashe, Anand J Thakur

CHAPTER 15: **Infected Nonunion** **201**
Vikas M Agashe, Anand J Thakur

CHAPTER 16: **Infection in the Presence of a United Fracture** **220**
Vikas M Agashe, Anand J Thakur

CHAPTER 17: **Persistent and Recurrent Infection Despite Debridement, Antibiotics, and Implant Removal** **227**
Vikas M Agashe, Anand J Thakur

CHAPTER 18: **Compromised Outcomes** **236**
Vikas M Agashe, Anand J Thakur

CHAPTER 19: **Unexpected and Unexplained Union** **247**
Vikas M Agashe, Anand J Thakur

CHAPTER 20: **Host's Health Status** **253**
Anand J Thakur, Vikas M Agashe

CHAPTER 21: **The Role of the Multidisciplinary Team in Orthopedic Infections** **266**
Vikas M Agashe, Anand J Thakur

Index **275**

CHAPTER

14

Early Infection after Fracture: Retain or Remove the Implant?

Vikas M Agashe, Anand J Thakur

"Who DAIRs early and fully, WINS!."*

INTRODUCTION

Postsurgical infection in fracture care remains a significant challenge in orthopedic practice, often jeopardizing the success of fracture fixation and leading to prolonged morbidity. Despite advances in surgical techniques and infection control, the presence of metallic implants can create a favorable environment for bacterial colonization and biofilm formation, making the management a challenge. The DAIR (*D*ebridement, *A*ntibiotic, and *I*mplant *R*etention) protocol has emerged as a pivotal strategy in addressing these infections while preserving implant stability, which is critical for fracture healing. It represents a balance between infection control and implant retention, making it an invaluable tool in the orthopedic surgeon's armamentarium. Understanding the nuances of its application is essential for improving patient outcomes and reducing the burden of fracture-related infections.

TERMINOLOGY AND TIMELINE

DAIR protocol is based on a hypothesis: "Most pathogens and biofilms are accessible and can be removed by surgery"; the remaining minor bacterial load can be neutralized by body's defenses, antibiotics therapy, and will remain subdued till fracture heals. Implant removal after fracture healing is easy on the surgeon and the patient leading to durable infection control.

Early detection and prompt treatment are the key factors in dealing with infection after fracture. In this context, early onset means within 2 weeks, delayed is within 10 weeks while a late onset is >10 weeks; these time zones are arbitrary.

DIAGNOSIS, ASSESSMENT, AND PLANNING

Early diagnosis of infection is challenging for the primary surgeon, as is its treatment. It is often prudent to involve a fellow orthopedist in the management of this complication. Pain, trivial swelling, slight discharge, and increased inflammatory markers are common findings after surgery and in early infection; therefore, some confusion may arise. Ultrasonography may be helpful to understand the nature of the swelling in the early stages.

Suggestive criteria for infection, viz., clinical signs (pain, swelling, and slight discharge), radiological signs (soft tissue swelling), bacteriological findings (identification of pathogen from deep tissue or implant specimen), laboratory investigations [raised erythrocyte sedimentation rate (ESR) and C-reactive protein (CRP)], persistent drainage, joint effusion and *confirmatory* criteria of infection such as fistula, sinus or wound breakdown, positive culture, and histopathological identification have been discussed earlier in details (Chapter 1 page 2).

Assessment starts with evaluating the patient's general condition, habits and comorbidities, and the necessity of an emergent surgery. This is followed by an assessment of location of infected tissues as discussed in Chapter 2. Marking the location with a permanent skin marker helps during surgery. Completeness of soft tissue envelop is considered, and it is best to seek a plastic surgeon's advice at least virtually. Radiographs are repeated, and alignment and stability of the construct are assessed.

Infection control begins the moment the surgeon identifies its suggestive or confirmatory criteria

Infection after a fracture and one after a joint replacement are not alike. In joint replacement, the patient and the soft tissue around the joint are generally in optimal condition at surgery. The implants are there to stay

*Debridement, Antibiotics, and Implant Retention.

JAYPEE BROTHERS

forever and preferably not be removed. In event of a fracture, the host factor may be inadequately controlled, and soft tissue around the injury may be in a precarious state. In open fractures, contaminants and pathogens would have entered the wound before antibiotics administration. However, in an infected fracture, the implants are needed only till the time of fracture union and then may be removed giving an opportunity to surgeon to do excellent source control.

Action Plan

As soon as the surgeon notices signs of the infection, the first reaction is often to adapt compromises—the common practices often adapted but to be discouraged are:

- *Administration of empirical antibiotics:* They must be avoided and deferred till surgical samples are collected for microbial studies. However, if the patient has a significant swelling, running fever, or is in septicemia, broad-spectrum antibiotics may be started even before sample collection. In such cases, blood culture bottles with resins are used for additional sample collection.
- Collect samples for culture by swabbing from the sinus or incision.
- Drain or aspirate the collection.
- Excise the sinus and close the wound.
- Excise the sinus; irrigate through the sinus or opened sutures.
- Exploration is limited only to the part of the plate that appears infected.
- In minimally invasive plate osteosynthesis (MIPO), keep the skin islands intact and explore only the sutured areas.
- Explore by another incision through the healthy skin.

However, such short-term compromises often lead to long-term failures.

The prime strategic action is a good debridement by exposing the part of implant which is expected to be outside the bone. Every attempt is made to remove as much biofilm as possible. It is understood that it is impossible to completely eradicate a biofilm in presence of implant, because a radical or oncological resection cannot be performed while maintaining the implant.

CHALLENGES INVOLVED IN EXECUTING THE PLAN

Patient Counseling

The patient and his family, having just recovered from the initial surgical stress, are generally hesitant about undergoing another surgery. Concerns about additional hospitalization, increased expenses, the risks associated with repeat anesthesia, and the need for re-exploration of the incision weigh heavily on their minds. They often worry about the persistence and recurrence of infection, as well as potential additional complications. Common questions include: Why did this happen? Was there a lapse in healthcare? What are the chances of a successful outcome?

The surgeon and the medical team need to take these concerns into account during discussions with the patient and family. It is essential to have a detailed conversation about the pros and cons of every possible action. This should include the possibility of needing more than one procedure, the potential removal of implants, and in the event of that, possible ways of stabilizing the construct, and the need for a plastic surgical procedure. Involving infectious disease team or a physician in these discussions is desirable. The team should ensure they spend adequate time to address these issues. This is challenging at the easiest and therefore, there is often a tendency to suppress the infection with empirical antibiotics.

PREOPERATIVE PLAN AND DAIR PROCEDURE

The most important question medically, surgically, and socially is whether to retain or remove the implant? **Box 14.1** summarizes factors deciding its fate.

Surgical Aspects

- Excise as much infected tissue as possible
- Maintain/achieve stability
- Collect appropriate samples
- Obtain good soft tissue cover
- Insert local antibiotic when indicated

Addressing Critical Balance

Here fracture union depends on debridement of infected tissue, an adequate soft tissue cover and stability of the fracture. These factors often conflict with one another, and a critical balance between them is needed in IAF at least till fracture union. For instance, thorough debridement is constrained by the presence of an implant; it may require

BOX 14.1 Factors influencing implant retention in DAIR.

- Early infection (No cut-off point can be defined)
- Good fracture alignment and construct stability
- Likelihood of adequate debridement in the presence of an implant
- Feasibility of creating a robust soft tissue cover for the bone and implant at the end of the surgical procedure or within the next 3–4 days
- Offending microbes, "Not difficult" to treat

JAYPEE BROTHERS

implant removal or lead to significant loss of soft tissue cover. While every patient and surgeon prefers to retain the implant in IAF, preoperatively it is difficult to predict its fate. A plan for fracture stabilization is always needed if implant removal is unavoidable.

INFECTION AFTER PLATING

Concepts, planning, and DAIR operative procedure for early infection after plating are discussed here.

CASE REPORT 14.1

A 77-year-old female patient presented with a discharging sinus 3 months after the surgery for a periprosthetic fracture. The infection had persisted in spite of one DAIR by the index surgeon **(Figs. 14.1A to D)**.

The incision shown in **Figure 14.1D** was made and deepened, excising the fascia and muscle to expose the infected granulation tissue, to expose the entire plate **(Figs. 14.2A to C)**.

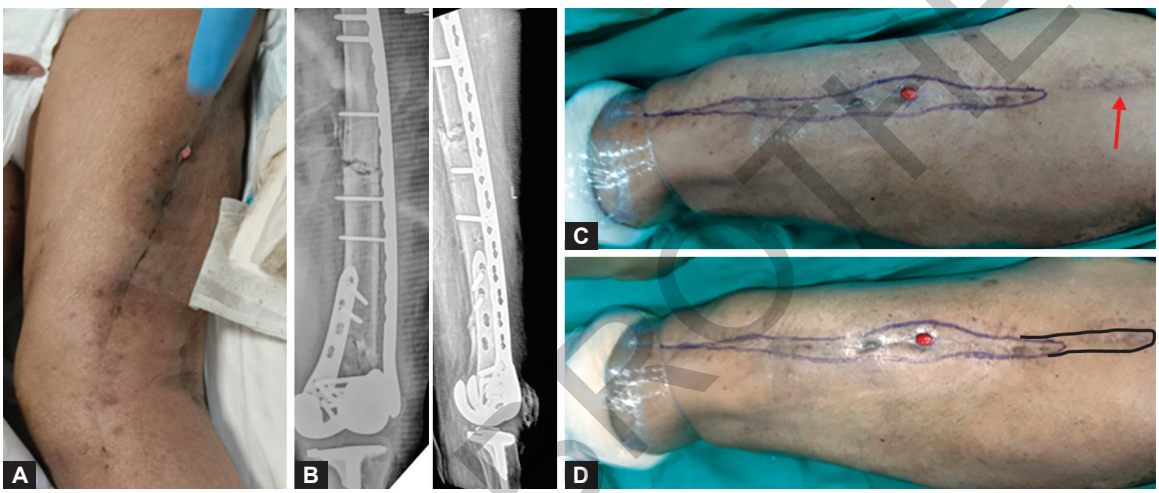

Figs.14.1A to D: At presentation 3 months after the index surgery—(A) Clinical photograph showing scar with a discharging sinus in the middle of the incision; (B) AP and lateral radiographs; (C) Incision if only the previous incision and sinus were to be excised. Red arrow shows area of the drain in previous surgery; (D) Incision must include the drain site and intervening soft tissue tract in addition to the original scar.

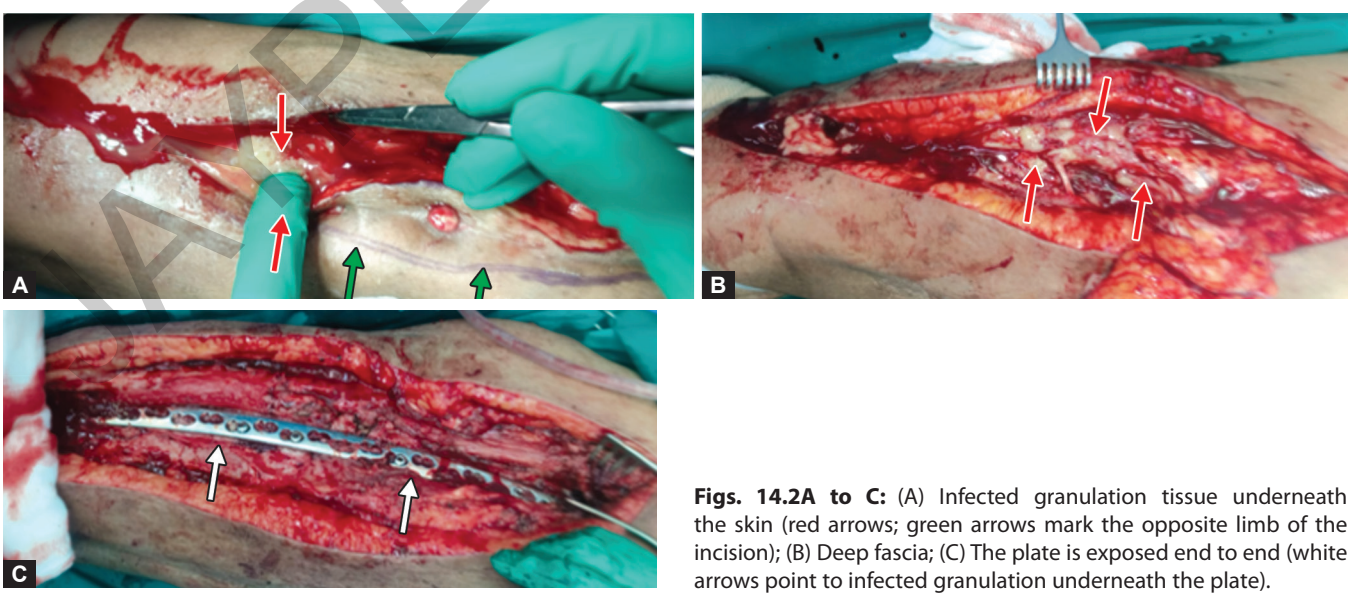

Figs. 14.2A to C: (A) Infected granulation tissue underneath the skin (red arrows; green arrows mark the opposite limb of the incision); (B) Deep fascia; (C) The plate is exposed end to end (white arrows point to infected granulation underneath the plate).

JAYPEE BROTHERS

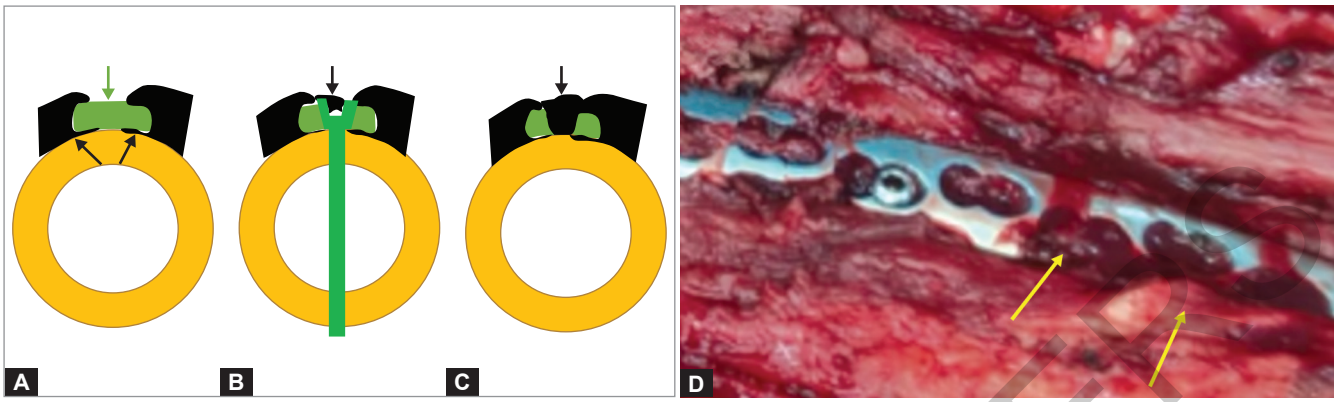

Figs. 14.3A to D: Diagrammatic representation of the infected granulation tissue (colored black) covering different parts of the plate (colored green) (A) Area between the screw holes; (B) Socket for the screwdriver filled with infected tissue; (C) Empty screw hole filled with infected granulation tissue; and (D) Plate covered with infected granulation tissue (yellow arrows).

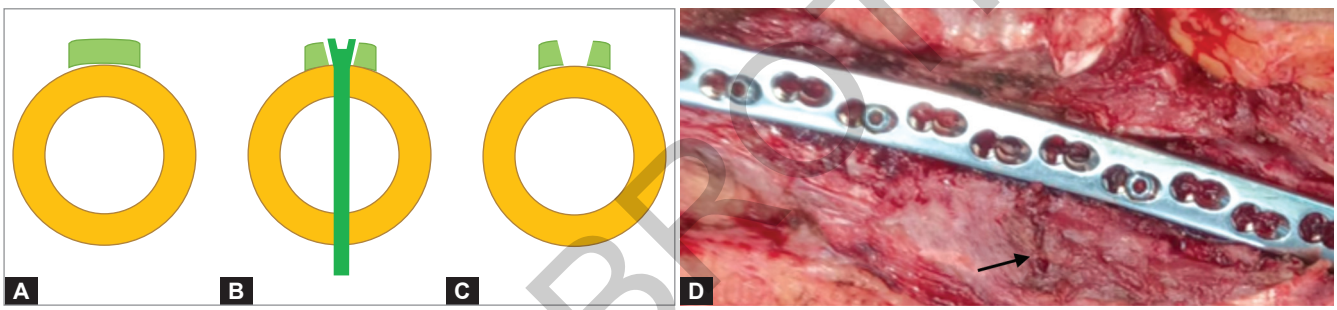

Figs. 14.4A to D: Diagrammatic representation of scrupulous cleaning of the exposed areas of the implants and removal of infected tissue from (A) Under the plate; (B) The screw sockets and screw-plate interface; (C) Empty screw holes of the plate; (D) Plate cleaned from all sides, screws, and empty areas of screw holes. The fracture site was also cleaned of granulation tissue (black arrow).

After preliminary cleaning and a wash, the plate was exposed from all sides **(Figs. 14.3A to D)**. Meticulous debridement involved removal of infected granulation from all screw heads, area around screw heads, plate holes, empty holes, all around plate, and the space between plate and bone, if any **(Figs. 14.4A to D)**. Multiple samples were collected and subjected to tests as per the protocol.

Culture and Antibiotics

The culture grew Methicillin-sensitive *Staphylococcus aureus* (MSSA). The infectious disease consultant (IDC) treated her with injection daptomycin 10 mg/day for 6 weeks. After 10 days of daptomycin, she received oral rifampicin 600 mg for 3 months. After 6 weeks of daptomycin, first-generation cephalosporin-cephalexin was given for over a year as suppressive antibiotic.

Infectious disease consultant saw her regularly and thoroughly assessed her clinical situation.

Two important aspects were considered by the IDC while tailoring the antibiotic therapy:

1. The patient required suppressive antibiotics because we had performed a repeat DAIR procedure 3 months after surgery.
2. The patient also needed biofilm-active antibiotics during the initial months of treatment. Daptomycin, known for its efficacy against biofilm, was administered for the first 6 weeks. After that period, she was transitioned to oral suppressive antibiotics. Rifampicin, an excellent biofilm-active antibiotic, was added to the regimen at 10 days.

We advise orthopedic surgeons not to prescribe suppressive antibiotics on their own and should entrust the task to an IDC.

Follow-up

There was no recurrence of infection. At the last follow-up, 18 months after the second DAIR, the scar was

JAYPEE BROTHERS

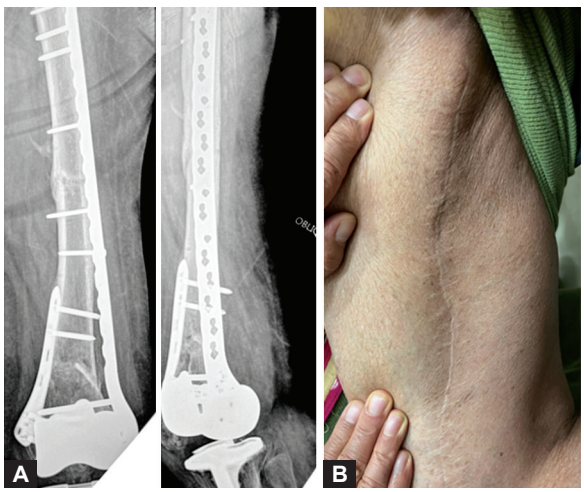

Figs. 14.5A and B: Radiographs: (A) Well healed fracture; (B) Clinical photograph showing excellent scar and no evidence of infection.

supple and clean with no evidence of infection and radiograph showed excellent fracture union **(Figs. 14.5A and B)**.

INFECTION AFTER INTRAMEDULLARY NAILING

Intramedullary (IM) nailing is the most prevalent treatment of diaphyseal and many metaphyseal fractures of the long bones. This technique offers several advantages, including minimal soft tissue trauma and the ability for most patients to bear weight early in their recovery. However, should infection occur, it spreads along the medullary canal, which is difficult to control.

Incidence

In a systematic review of 2,128 cases of IM nailing from 28 studies, the infection rate observed was 7.9%. The infection rate after nailing for humerus was the lowest, and that for the tibial nailing was the highest. In most series, the infection rate after nailing open fractures was much higher than after nailing closed fractures. Similarly, the infection rate after nailing a nonunion was higher than that after nailing a fresh fracture.

Classification

Makridis system is a three-stage classification of infection after IM nailing.[1] It gives leeway to a strict timeline that many classification systems advocate and the timelines do not touch between two stages.

Stage I: The early stage of bacterial cellulitis occurs in the immediate postoperative period, i.e., within 2–6 weeks.

Stage II: 2–9 months. This stage is associated with delayed wound healing, wound necrosis, or discharge from the operative site. An impaired fracture healing response might also be present.

Stage III after 9 months. This represents established IM osteomyelitis. Principles of management include aggressive debridement with nail removal, achieving an aseptic environment, and fracture fixation with the most suitable system.

Contentious Issues in this Classification

Stage I. The authors mention that the preferred treatment at this stage is antibiotics with incision and drainage of pus *when necessary*. Today, most opinion leaders believe that in addition to antibiotics, exploration is mandatory even at this stage. It offers the best opportunity for reducing microbial load, getting appropriate sample for tests, and giving directed antibiotics, retaining the nail and eventually achieving an excellent outcome.

Based on these findings, we propose the following treatment:

- *Stage I:* Exploration, debridement, targeted antibiotics, and implant retention (DAIR)
- *Stage II:* Several methods are in use on a case-to-case basis:
  - Nail retention, suppressive antibiotics, and removal after union
  - Nail removal and antibiotic-eluting nail
  - Nail retention, debridement, and targeted antibiotics
  - Nail retention, antibiotics, nail removal after fracture union and ream out the infected medullary canal as debridement
  - Nail exchange and antibiotics
  - Nail removal and Ilizarov fixator
- *Stage III:* Multiple options are available, but the standard protocol is nail removal, debridement, and targeted antibiotics, followed by reconstruction.

In most of the cases, local antibiotics are extensively used.

Outcome

Results of the DAIR protocol for infected nails are generally poor. In a study of 26 patients who had an infection after nailing the tibia or femur, remission happened only in 42.3% of cases. A significant association existed between Makridis stage 2 subjects and infection recurrence or death. The authors also noted that consolidation of the fracture and infection control did not correlate.[2] Results in infection after nailing of subtrochanteric fractures are also poor. Uncomplicated fracture healing occurred in

JAYPEE BROTHERS

only 2 of the 15 cases and a mortality of 20% was reported in one series.[3]

Surgeon should have a low threshold for nail removal, more so when the nail is loose or infected tissue between the nail and medullary cavity is perceived.

SPECIAL SITUATIONS

Open Fractures

The index wound, additional incisions for osteosynthesis, and the intervening areas should be examined for the presence of infection. Advanced imaging, such as MRI with the MARS protocol and an FDG-labeled leukocyte-PET scan, may be used to locate infected areas. When the fracture site is unquestionably infected, the surgeon should have a low threshold for implant removal.

Minimally Invasive Plate Osteosynthesis

When a fracture plated with a minimally invasive technique is infected, the mini surgical wounds are converted into a single large incision, and the entire plate is exposed for debridement.

Fracture of Both Forearm Bones

When only one bone appears infected, especially in open fractures, both bones are likely to be infected. If exploration of only one side is planned, more imaging, MRI/PET CT is recommended to rule out infection in other bone.

Multiple Incisions and Implants

A cautious presurgery assessment and a vigilant approach during the surgery is warranted; all the implants should be explored in most cases.

Patient's General Health

Most DAIR surgeries take longer than the index procedures. If the patient's condition is unstable, then the procedure is curtailed to the level that the patient can withstand and reduce microbial load; a second go may be attempted when the condition improves.

Considerations about Soft-tissue Cover

DAIR involves excising incisions, drain sites, and entry wounds in open fractures in the early postoperative period, challenging the soft tissue cover. Elevation, negative pressure wound therapy (NPWT), appropriate release incisions, muscle flaps, and skin flaps are planned and judiciously used.

OUTCOME AFTER DAIR

DAIR is successful in 60–90% of the infections, if carried out within the first few weeks of the onset of the infection.

- *Outcome in ideal situations:* In clinical situations where infection was treated within 3 weeks, implant was stable, the soft-tissue had no abscess or sinus tract, the causative pathogen was susceptible to antimicrobial agents with activity against surface-adhering microorganism, the reported cure rate was 90% with surgical debridement and implant-retention along with long-term antimicrobial therapy.[4] A point to note: In this study where 233 patients were involved, the majority had gram-positive infection, with only 5.6% with gram-negative infection.
- *If DAIR is done before 6 weeks:* In another study involving 123 patients, DAIR was performed within 6 weeks. In this series, open fractures and IM nails were the risk factors for implant retention. Thirty percent of them needed implant removal before fracture union because of the persistence of infection.[5] Additionally, 21% of patients required implant removal after fracture union because of recurrence of infection. Implants could be retained long-term in about half the patients.
- *Is earlier better?* While "earlier is considered better," some studies have found similar rates of infection if the DAIR is carried out within 2 or 10 weeks.[6]
- *Local antibiotics:* Most studies suggest that use of local antibiotics is helpful.
- *"Host factors":* A study of 88 patients[7] stressed the importance of "host factors" as well as early DAIR (within 3 weeks). The implant retention rate was 90% in type A hosts and a meagre 20% in type B.

The following case scenarios bring out the intricacies of the surgical procedures and other essential elements of DAIR and related treatment.

CASE REPORT 14.2

A male of 25 years presented 15 days after the surgery with an infected internal fixation for a fracture of the upper end of the left tibia.

Past History

The patient had a fall from a two-wheeler and sustained a displaced comminuted fracture of the upper third of the left tibia with significant soft tissue injury **(Figs. 14.6A to E)**. He did not have neurovascular injury or compartment syndrome in the leg. On the first day, he was treated with a knee-spanning external fixator. CT scan after spanning revealed a markedly comminuted and

JAYPEE BROTHERS

displaced fracture. The soft tissue condition improved after application of external fixation.

Two weeks after the injury, he was operated; open reduction and bipillar plating of the upper tibia and an anteroposterior screw fixation of the tibial tuberosity was performed at Elsewhere hospital. The postoperative radiograph revealed excellent reduction and fixation **(Figs. 14.7A to D)**. Twelve days after the plating the

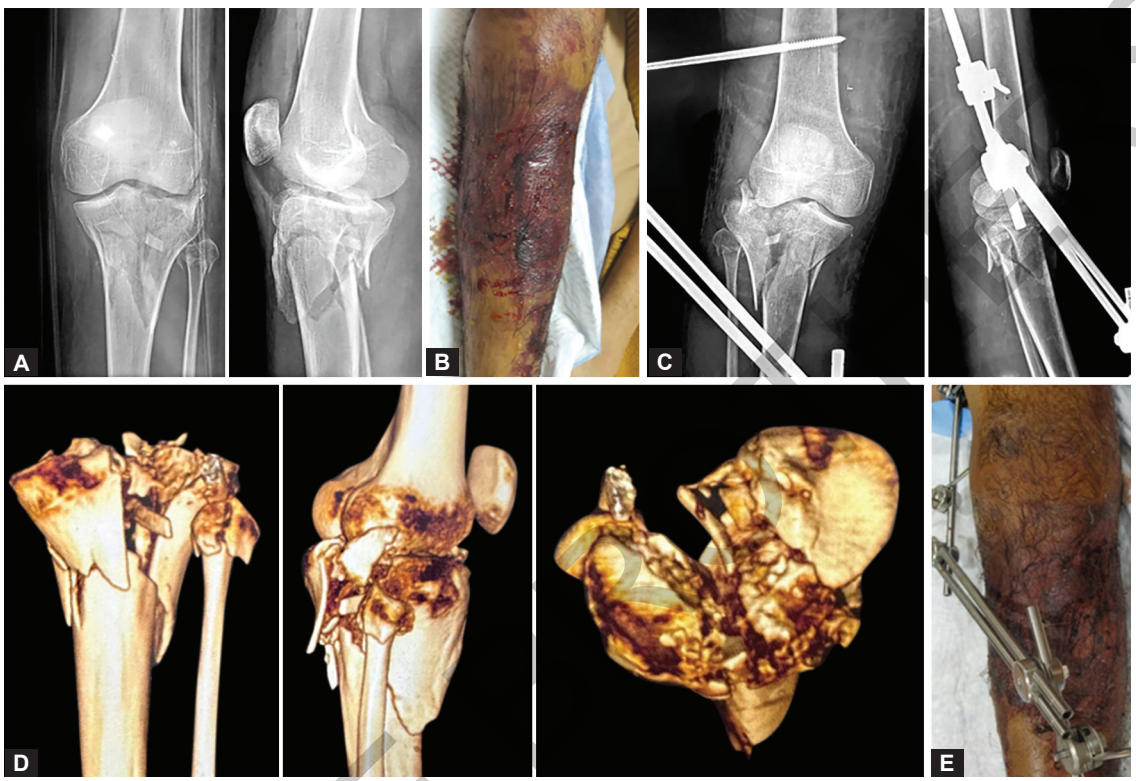

Figs. 14.6A to E: (A) Anteroposterior (AP) and lateral radiographs on the day of injury; (B) Clinical photo showing extensive soft tissue injury. Imaging after external fixation; (C) radiographs; (D) CT scan reconstruction; (E) Clinical photograph of the spanning external fixator.

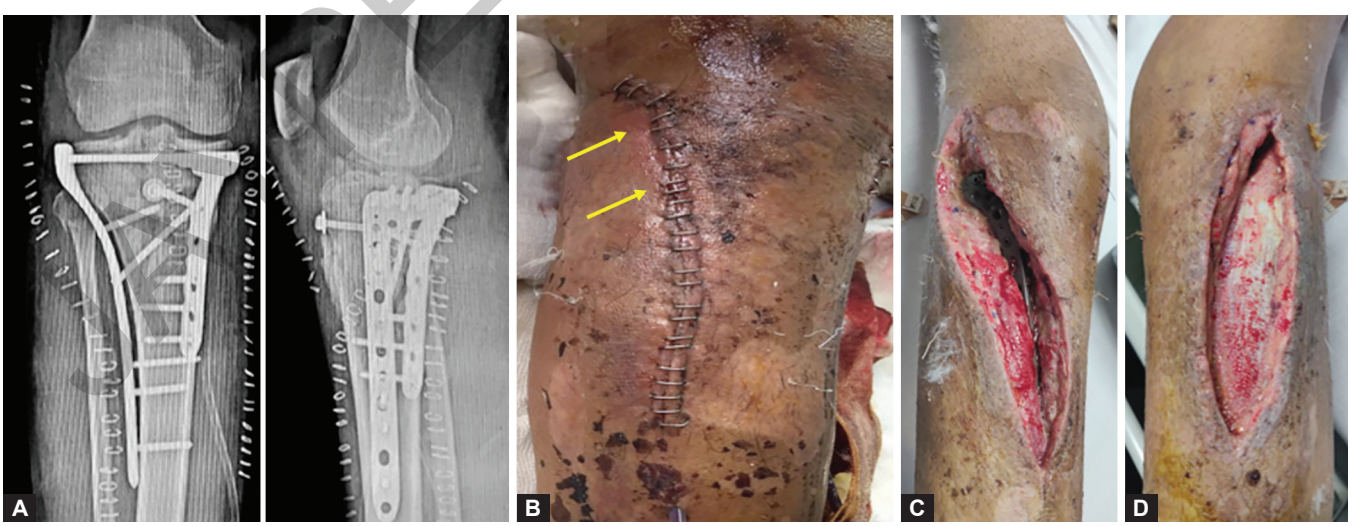

Figs. 14.7A to D: (A) AP and lateral radiographs after bipillar plating and AP screw; (B) Clinical photo showing area of redness and striking tenderness (yellow arrows) close to anterolateral incision which prompted the index surgeon to open the wound and debride; (C) Anterolateral; and (D) Medial incision at presentation to our hospital.

surgeon noted seropurulent discharge and inflamed wound edges along the suture line of the anterolateral incision. The inflammatory markers were raised. In the presence of suggestive criteria for infection after fracture, the index surgeon explored the anterolateral and medial incisions, confirmed the presence of seropurulent discharge, excised infected skin and subcutaneous tissues, muscles, collected samples for culture, washed the wound, and started antibiotics empirically. The pus samples grew carbapenem-resistant *Enterobacter cloacae*, and the index surgeon transferred the patient to our facility.

Assessment at Our Hospital

- Young patient presented 15 days after surgery for upper end of tibia.
- No comorbidities
- Preinjury excellent functional status
- Good reduction, stable fixation with plates and screws performed in Elsewhere Hospital
- Immediate action taken (wound excision, sample collection, lavage, and empirical antibiotics) by the index surgeon
- Likely to get cover
- Initially, extensive soft tissue injury
- Culture—highly resistant gram-negative microbes, resistant to ciprofloxacin. Synergy testing for ceftazidime avibactam and aztreonam was performed by the ID consultant and found to be present. Therefore, he was initiated on the following antibiotics: ceftazidime-avibactam 2.5 g, 8 hourly and aztreonam 2 g, 8 hourly by intravenous route.
- Incisions were open with purulent discharge, and edges were covered with slough.

Our assessment favored retention of implants, and we proceeded with debridement with a positive intent.

First Surgical Procedure at Our Hospital

Slough, hematoma, and necrotic muscle mass on the anterolateral and posteromedial side were excised. The suture line of the anterior midline incision appeared clean. However, it was explored as this was the only opportunity to salvage all the implants. Samples were collected for culture. All the implants were painstakingly washed and cleaned. The spaces between the plates and the cortex were cleaned. All the screws were checked for anchorage and were holding well. The wounds were washed multiple times with normal saline. The surgical attire and draping were changed; the anterior midline incision was closed with a new set of instruments. NPWT was applied for medial and lateral incisions in bridging mode **(Figs. 14.8A to F)**.

Second Surgical Procedure at Our Hospital after 4 Days

The anterolateral wound appeared healthy with good granulation tissues. The plate in the proximal part was covered with skin closure and muscles covered the distal part. The exposed healthy muscle was covered with split-thickness skin grafts (SSG). On the medial side, the plate was already covered with healthy muscle; the clean wound was covered with an SSG **(Figs. 14.9A to E)**. The culture

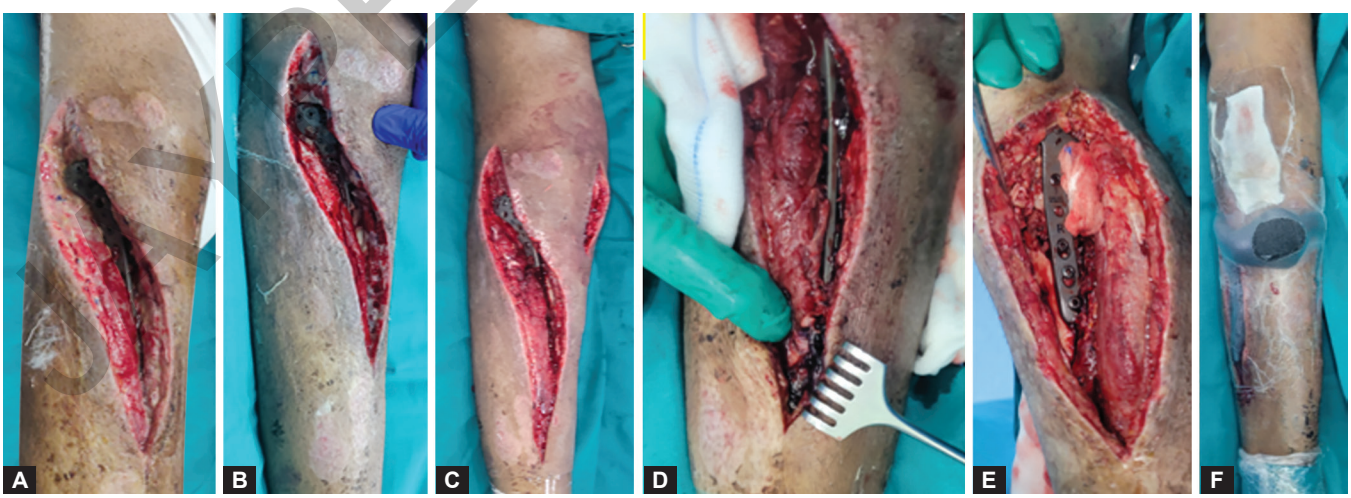

Figs. 14.8A to F: (A) Anterolateral incision before debridement; (B) During debridement; (C) Anterolateral and anterior incisions after debridement; (D) The medial incision during debridement, finger pointing to the hematoma and muscle necrosis; (E) Extent of debridement; (F) NPWT applied in a bridge mode between medial and lateral incisions.

JAYPEE BROTHERS

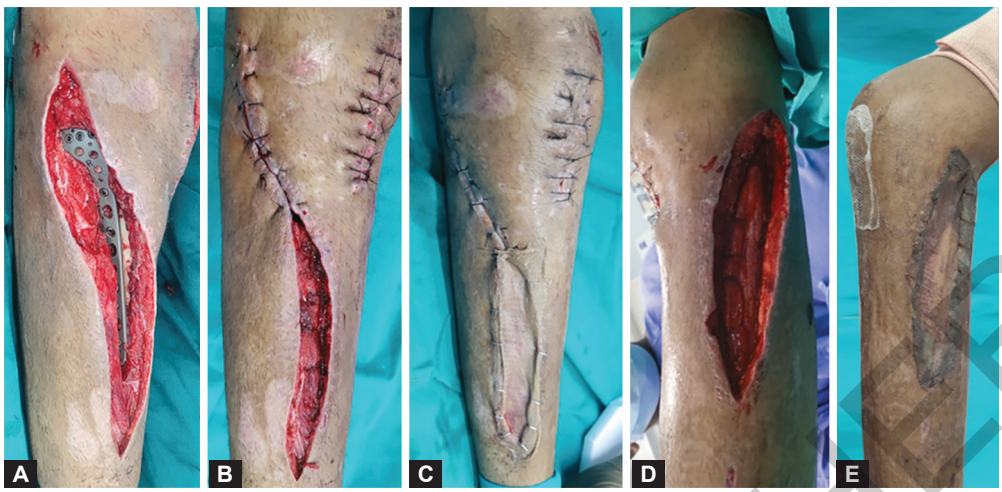

Figs. 14.9A to E: (A) Granulating wound on the anterolateral side; (B) Skin closed over the proximal part of the anterolateral plate; muscles sutured over plates distal part, sutured anterior incision; (C) SSG for distal part of anterolateral incision; (D) Medial plate covered by healthy muscle; (E) SSG for the medial incision.

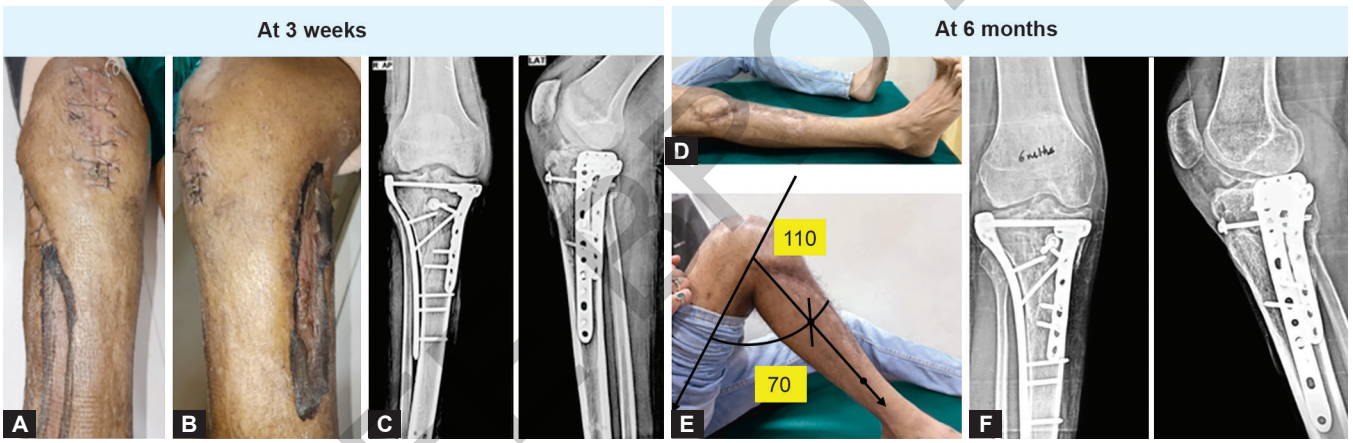

Figs. 14.10A to F: The skin grafts are well settled over (A) anterolateral wound; (B) The medial wound; (C) Radiographs at 3 weeks; (D) Fixed flexion deformity; (E) Knee flexion at 6 months; (F) AP and lateral radiographs at 6 months.

showed carbapenem-resistant *Klebsiella pneumonia*, and the team IDS continued the antibiotic combination.

Postoperative Course

The wound remained healthy, and his blood parameters returned to normal in 8 weeks. His pain VAS decreased from 5/10 to about 1/10 in a month and then became zero by 6 weeks.

- Knee mobilization was started after the skin grafts had settled for 1 week. Three weeks after the surgery, his wounds were dry and the radiographs showed satisfactory alignment and healing **(Figs. 14.10A to F)**.
- Patient was unable to continue IV antibiotics, therefore, based on susceptibility, he was switched to oral Trimethoprim sulfamethoxazole double strength, 2 tablets twice a day to complete 3 months of treatment.
- At 10 weeks postsurgery, he had a flexion deformity of 10° and further flexion up to 90°. He resumed partial weight-bearing after 12 weeks. At 6 months follow-up, he had full knee extension and 110° of flexion. The fracture showed complete union. He could cycle 8–10 km every day and work for 8–10 hours.

At the 11-month follow-up, he had a full range of knee movements and was able to sit cross-legged on the floor **(Figs. 14.11A to C)**. Serial radiographs after the implant

JAYPEE BROTHERS

removal showed a well-healed fracture at 11 months and 28 months.

Learning Points from Case Report 14.2

Several factors contributed to an excellent outcome in this patient, viz.

- A young individual with no comorbidities
- Excellent fixation by index surgeon
- Immediate action on suspecting infection by the index surgeon
- Debrided timely and transferred to a unit specializing in osteoarticular infections
- Debridement was repeated.
- Plates and fracture site could be covered with good soft tissue
- Antibiotics guided by culture and team IDS
- *Mo*tivated patient and excellent postoperative care by multidisciplinary team and physiotherapists

CASE REPORT 14.3

Past History

A 43-year-old male arrived at our clinic 6 weeks after a workplace injury with an infected upper tibia; a forklift had knocked him down in an oilfield in the Arabian Gulf region. He suffered a small wound on the anterior surface of the tibia and a bicondylar fracture of the tibia, as per the notes. Debridement, bicondylar plating and fixation of the tibial tuberosity by AP screw via a midline incision were carried out. He developed infection almost immediately after the surgery. The wound was explored on the 10th day by the index team. Methicillin-resistant coagulase negative *Staphylococci* (MR CoNS) were isolated from the swab sample culture collected in the operation theatre. He received clindamycin for a month after debridement, but the discharge was unabated, and he approached us **(Figs. 14.12A to C)**.

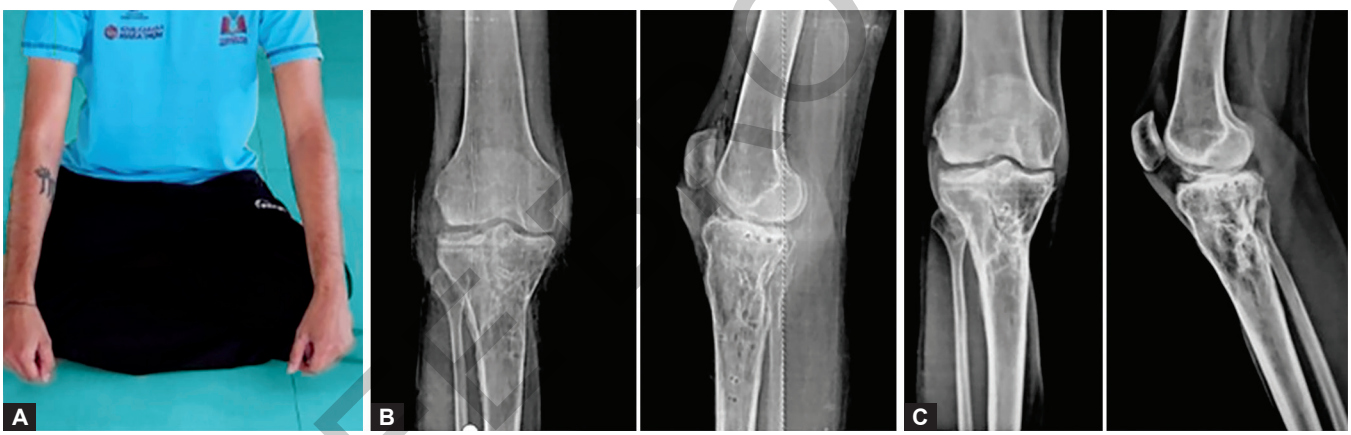

Figs. 14.11A to C: At 11 months. Clinical photograph (A) sitting cross-legged. Radiographs (B) well-healed fracture after implant removal; (C) At 28 months radiographs of a consolidated fracture.

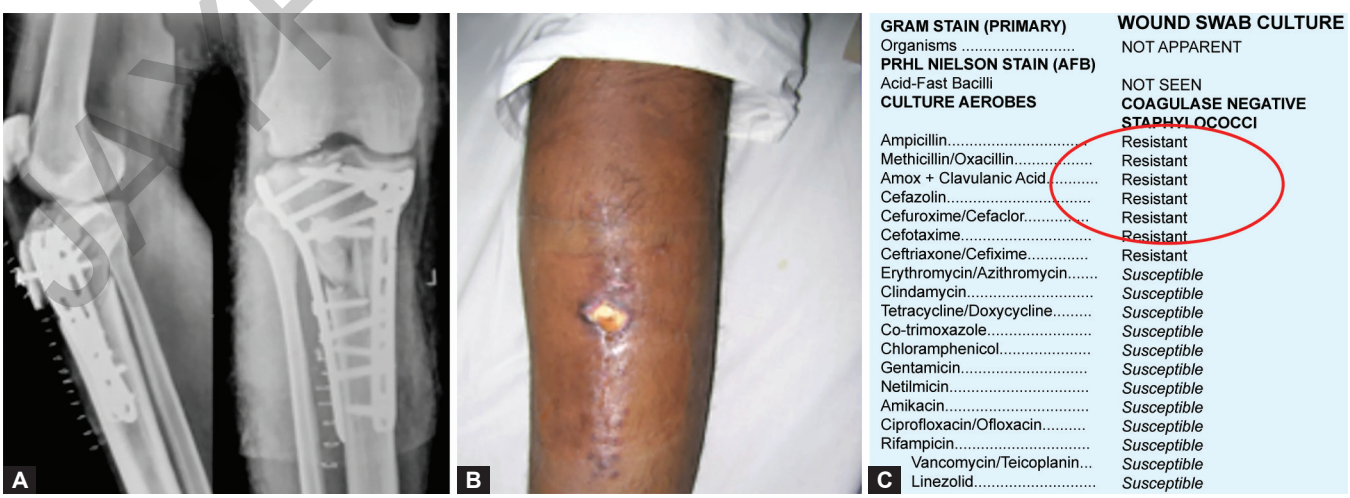

Figs. 14.12A to C: (A) AP and lateral postoperative radiographs; (B) Clinical picture at presentation with exposed tibial tuberosity and screw; (C) Culture report from Elsewhere Hospital; MR CoNS grown.

JAYPEE BROTHERS

Imaging

Fresh radiographs showed a well-reduced and aligned bicondylar fracture of the tibia stabilized by bipillar plating. A screw was inserted in an anteroposterior direction to fix the tibial tuberosity.

Current Situation

The current situation was weighed under four components: Host status, clinical findings, implant and construct stability, and microbial and histopathological diagnosis.

Host Status

The patient was of sound health and worked as an active operative in a high-risk work area. He had no local or systemic comorbidities, no habits, and adequate family support. His inflammatory markers were marginally raised.

Clinical Findings

There was no pain or instability in the affected leg. The central part of the incision was gaping, exposing the tibial tuberosity and a bone screw. The neurovascular systems were normal. He had a fixed flexion deformity (FFD) of 5° and further flexion up to 90°.

Implant and Construct

The fracture was well aligned and the construct was stable. The soft tissue over the screw was necrotic and the surrounding skin was tight. The infection was now established for 6 weeks despite one surgical procedure and attempted DAIR in the index hospital.

Microbial and Histopathological Diagnosis

Methicillin-resistant CoNS bacteria were isolated. The tissue was not sent for histopathology (explored before he approached us).

Assessment

Six weeks old, infected open proximal tibia fracture with stable and well-aligned construct, a discharging wound that exposed bone and a screw. Infection had persisted despite an attempted DAIR and 1 month of culture guided antibiotics.

AIM—What was the Target?

The treatment aimed to control the infection, facilitate soft tissue healing, consolidate fractures in good alignment, prevent chronic infection, and restore full limb function.

Strategy—How do You Get There?

Our surgical team planned a second debridement, retaining the implant and raising a local flap to cover the implants. A change in antibiotic therapy was also proposed; discontinue clindamycin and start vancomycin; after 10 days add rifampicin.

IDS consultant's view was different. He pointed out that CoNS pathogens are skin-based microbes. The injury was in an oilfield where soil or water-based pathogens are more likely to cause the infection. He suggested that the first samples may have been taken from superficial to plate during DAIR. To access infected granulation tissue under the plate he strongly recommended removal of the implant **(Fig. 14.13)**.

Surgery

The surgery started with the intention of retaining the plates. However, the exposed plates were loose, and the infection had eroded the cortex. Both the plates and all of the necrotic and infected bone had to be removed. At the depth of the wound, infected granulation tissue was seen, which was meticulously excised and sent for culture and histopathology **(Figs. 14.14A to F)**. A joint-spanning external fixator was applied. The culture grew *Enterobacter aerogenes,* a gram-negative microbe found in soil as predicted by ID consultant.

Five days after the second debridement, another round of debridement was undertaken and the dead space was packed with antibiotic-laden polymethylmethacrylate (PMMA) balls. The team's plastic surgeon raised a local fasciocutaneous rotation flap **(Figs. 14.15A to D)**. The patient received ciprofloxacin 750 mg for 6 weeks. By the end of 8 weeks, the flap was well settled and there were no tell-tale signs of infection. Radiographs showed bone formation on the posterior, medial and lateral aspects. At

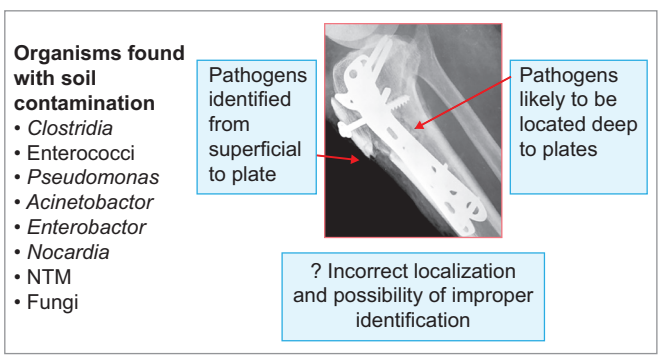

Fig. 14.13: ID consultant's thought process—as the open injury was because of a direct hit by a forklift in an oilfield, infected granulation tissue in the deeper plane was very likely and was the real source of infection. The sample was not collected from the source of infection.

JAYPEE BROTHERS

this stage, the cement balls were removed, and the space was filled with a large tricortical bone graft from the iliac crest.

The external fixator was maintained for a total of 12 weeks. Later, the limb was protected with a knee immobilizer. He was allowed to do toe-touch ambulation and use a walker for additional support. The radiographs at 18 weeks showed adequate bone formation to allow a gradual increase in weight-bearing status. He returned to his original job at 8 months after the injury. Radiographs at 2 year showed excellent consolidation, but the bone had not regained its normal shape. At the final 13-years follow-up, the radiographs show an almost complete remodeling of the bone, and a near complete range of movement. There was excellent active extension without extension lag, which

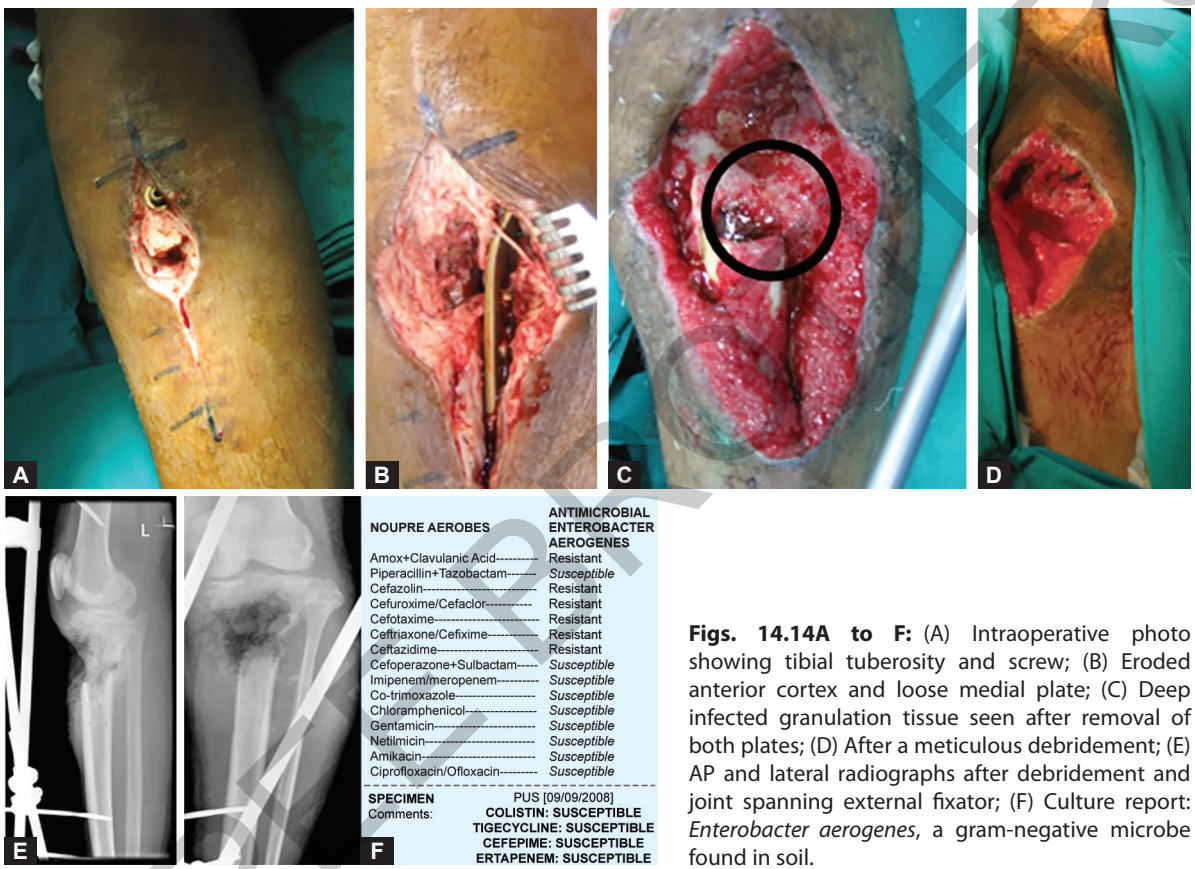

Figs. 14.14A to F: (A) Intraoperative photo showing tibial tuberosity and screw; (B) Eroded anterior cortex and loose medial plate; (C) Deep infected granulation tissue seen after removal of both plates; (D) After a meticulous debridement; (E) AP and lateral radiographs after debridement and joint spanning external fixator; (F) Culture report: *Enterobacter aerogenes*, a gram-negative microbe found in soil.

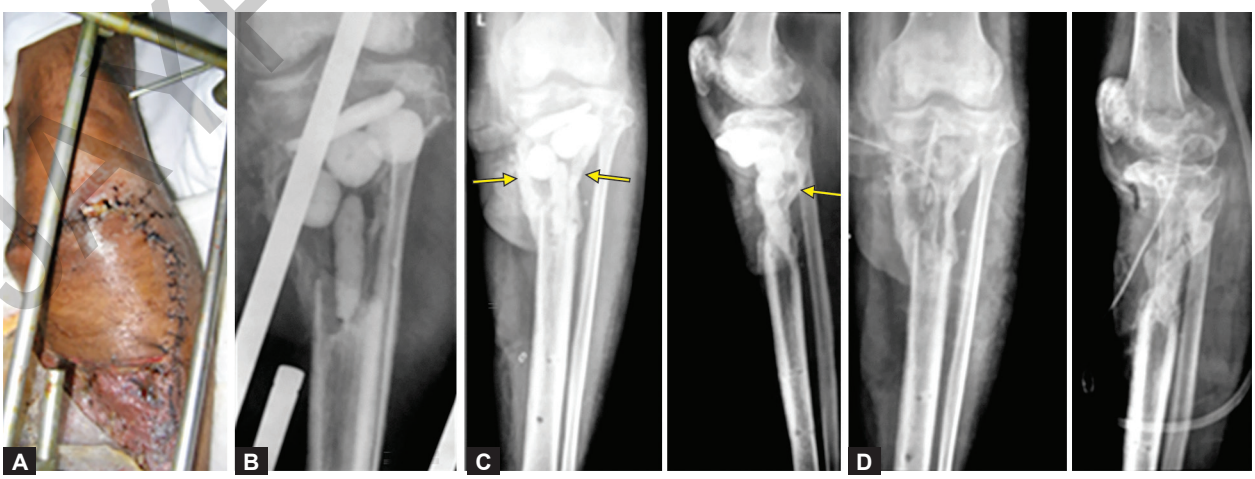

Figs. 14.15A to D: (A) Local rotation flap; (B) Postoperative radiograph showing antibiotic cement balls in the cavity. Radiographs (C) at 8 weeks after skin flap showing bone formation posteriorly and on sides (yellow arrows); (D) After insertion of a tricortical graft from the iliac crest (yellow arrow).

JAYPEE BROTHERS



Figs. 14.16A to F: Radiographs after bone grafting (A) at 18 weeks; (B) At 2 years; Good consolidation seen (C); Clinical photos 13 years after the event: (D) Full knee extension; (E) Almost full flexion; (F) Nearly full active extension.

was a surprise. This is possible only when the patellar tendon or quadriceps expansion is firmly anchored **(Figs. 14.16A to F)**.

Learning Points from Case Report 14.3

- A midline incision at the upper end of the tibia is prone to complications; the medial and the lateral incisions are safer. However, the incision depends on the index entry wound.
- DAIR is less successful in open fractures.
- The role of aggressive debridement/excision in open fractures cannot be overemphasized.
- The culture pattern should be interpreted in the light of clinical scenario; advice of infection disease specialist is invaluable.
- An uninfected soft tissue envelop encourages bone formation.
- A multidisciplinary team improves the outcome.

CASE REPORT 14.4

Management of recurrence of infection after successful DAIR.

Past History

A 63-year-old male diabetic presented at 10 weeks after surgery for a second opinion. He had sustained a displaced fracture of the lower end of the femur. The fracture was open reduced, and fixed with an anatomic lateral distal femoral plate. Four weeks after the surgery, he developed pain and swelling in the thigh and knee. He received an amoxicillin-clavulanic acid combination for 2 weeks to control the situation. The symptoms did not subside, and the surgeon subsequently explored the thigh to execute DAIR **(Figs. 14.17A to C)**. Infected granulation tissue was removed. *MSSA* was cultured, and initially, he received first-generation cephalosporin by intravenous route. Later, oral preparation of clindamycin was given. He had subjectively improved and presented at our clinic 6 weeks after DAIR, i.e., 10 weeks after index surgery for osteosynthesis.

Imaging

Radiographs at 10 weeks revealed a reasonably well aligned and stable osteosynthesis of the distal femoral fracture.

JAYPEE BROTHERS

Host Status

The patient was a diabetic with no other comorbidities and a nonsmoker.

Clinical Situation

He had no pain as he used a walking aid for support and bore partial weight on the limb.

Along the thigh, there was a trivial swelling but no tenderness. The soft tissue cover was satisfactory. The range of knee movement was from 0° to 90°. The inflammatory markers were within normal limits. He neither had neurovascular deficits nor diabetic neuropathy.

Assessment at Presentation

The DAIR performed at the Elsewhere Hospital had suppressed the infection, and it appeared that the implants could be retained until fracture union. He was told to lead normal life. He was seen again at 9 months after the injury; the fracture had healed clinically, and radiographs confirmed it. His functional status was excellent except for terminal restriction of knee flexion.

Two years after the injury, he presented with severe pain and swollen thigh of a month's duration. He has been pain free since the last visit till then. The distal thigh was tumid, and the local temperature was raised. He had an FFD of 10° with further flexion up to 60°. Inflammatory markers were raised; the infection had recurred.

Radiographs showed lytic areas in the healed fracture. Metal artefact reduction sequence (MARS) MRI with contrast revealed signs of extensive infection in the distal femur and all along the plate **(Figs. 14.18A to C)**.

Treatment after the Recurrence of Infection

Exploration of the fracture site, implant removal, and debridement of the infected tissues were planned



Figs. 14.17A to C: Radiographs: (A) AP and lateral views immediately after DAIR surgery at Elsewhere Hospital; (B) At our hospital 10 weeks later; (C) Well-healed fracture at 9 months.

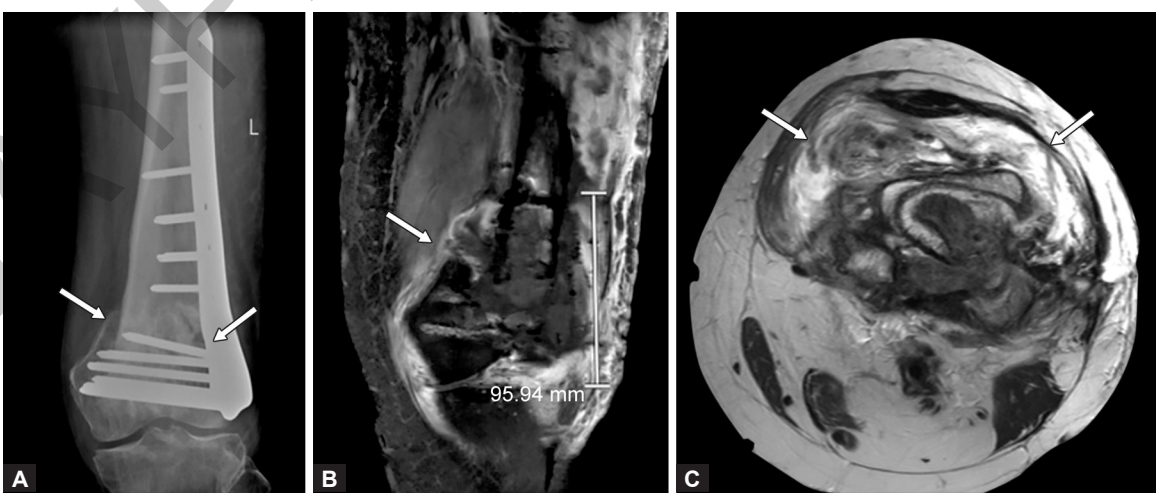

Figs. 14.18A to C: Radiograph 2 years after the index surgery: (A) Osteolytic areas are seen all over the lower end of the femur (white arrow). MRI of the lower end of the femur (B) shows a healed fracture but alludes to osteomyelitis of that bone (white arrow); and (C) Infective effusion in the knee (white arrows).

JAYPEE BROTHERS

and performed. A substantial quantity of infected granulation tissue was removed from the surface and underneath the plate. The bone between the distal block of screw holes was necrotic and was removed. The distal femoral condyle was also filled with infected necrotic tissue which was thoroughly debrided and removed. The wound was clean after copious washes with normal saline and hemostasis was achieved. Biodegradable pellets of calcium sulphate ($CaSO_4$) mixed with cefuroxime were spread along the length of the infected bone and in the cavity **(Figs. 14.19A to F)**. Culture grew MSSA with a similar pattern to that of earlier debridement.

He was treated with IV flucloxacillin 2 g 8 hourly for 2 weeks followed by oral flucloxacillin for 6 weeks. He made an uneventful recovery. Nine months after the implant removal, he had no pain and the infection had not recurred. He had a functional range of knee movement. The radiographs showed a well-consolidated fracture **(Figs. 14.20A to C)**.

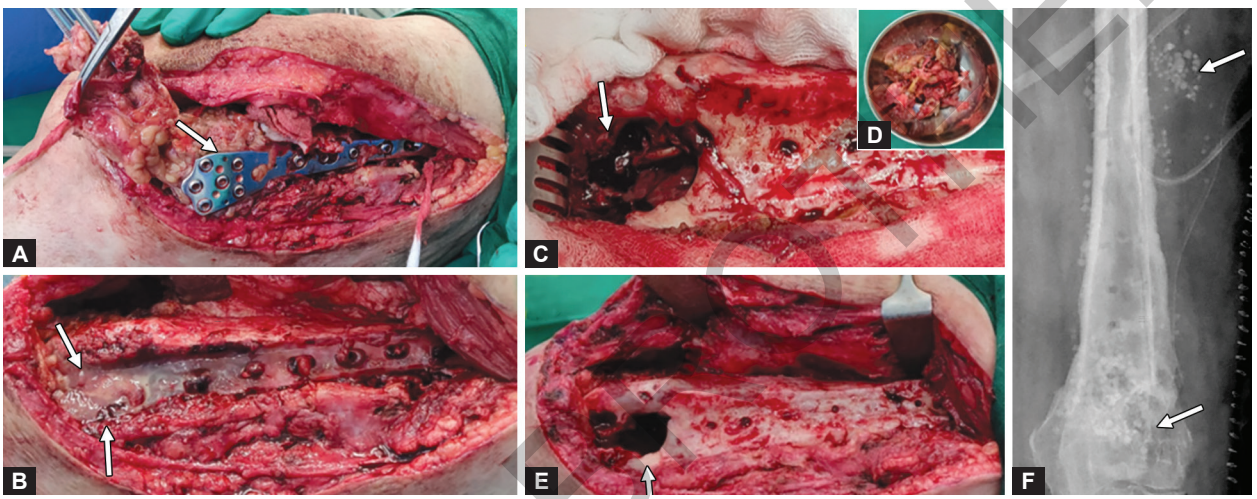

Figs. 14.19A to F: Intraoperative photographs. (A) The plate was exposed (arrow) and (B) removed. A large slimy layer representing biofilm showed up under the plate. The biofilm also covered the area of the condyle where distal screws were inserted (arrow); (C) Void in condyle after removal of necrotic bone and slimy layer of the biofilm (arrow); (D) Inset: the infected necrotic bone cleared away from the condyle; (E) Lower end of femur scrubbed clean of the biofilm and the necrotic bone (arrow); (F) Radiograph after the debridement shows pellets of calcium sulphate ($CaSO_4$) mixed with antibiotics along the femoral shaft and inside the condylar void (arrow).



Figs. 14.20A to C: Nine months after implant removal. Clinical photos (A) and (B) show a functional range of the knee movement; (C) Radiograph revealed a well-consolidated fracture. Blood parameters were within normal limits.

JAYPEE BROTHERS

Learning Points from Case Report 14.4

- Early DAIR can salvage the implant till fracture union.
- Infection often recurs with a vengeance and can be very extensive, especially in diabetic patients.
- Appropriate imaging helps to assess the extent of infection.
- Mere implant removal is inadequate; debridement, far more than anticipated, may be required.

What could have been Done Differently in Case 14.4?

- Rifampicin could have been used for antibiofilm activity after the first DAIR by the index team.
- The edges of the distal window could have been smoothened to eliminate stress risers during implant removal by our team.
- Planned removal of implants could have been done earlier, especially in view of his diabetic state.

CASE REPORT 14.5

Early Infection after Cephalomedullary Nailing for Subtrochanteric Fracture

This case is discussed with the PICCASSO strategy template.

P—Past history. A-69-year-old female sustained an atypical femoral fracture (AFF) while walking at home. She was operated on after routine preoperative investigations, closed reduction, and cephalomedullary nailing (CMN) was done at Elsewhere Hospital **(Figs. 14.21A to C)**. She developed pain and swelling in the upper left thigh at 2 weeks after the surgery. As per the records, she was mildly febrile, and the inflammatory markers were raised. As a result, the primary surgeon aspirated the swelling under aseptic precautions.

Culture grew *Proteus vulgaris*. There was no option for oral antibiotics; she was started on injection meropenem tailored to her body weight.

She presented to us at 6 weeks as the swelling was persistent **(Figs. 14.22A to C)**. She was walking comfortably with the aid of a walker bearing partial weight; her hip movements were painless.

Imaging

She carried three sets of radiographs:

1. *Preoperative:* Revealed displaced subtrochanteric fracture with features of AFFs. It also showed total knee replacement implant.
2. Immediate postoperative radiographs showed a varus reduction of the fracture stabilized with long proximal femoral nail. The blade was placed in superior and posterior quadrant of the head
3. Radiographs at 6 weeks visualized a well maintained position of the fragments and the blade. There was bridging callus indicating fracture healing.

C—Clinical findings. There was a large, warm, and fluctuant swelling over the left thigh around the incisions. Hip movements were pain free, and she was comfortably ambulatory with a walker. There was no pain or swelling in the distal thigh.

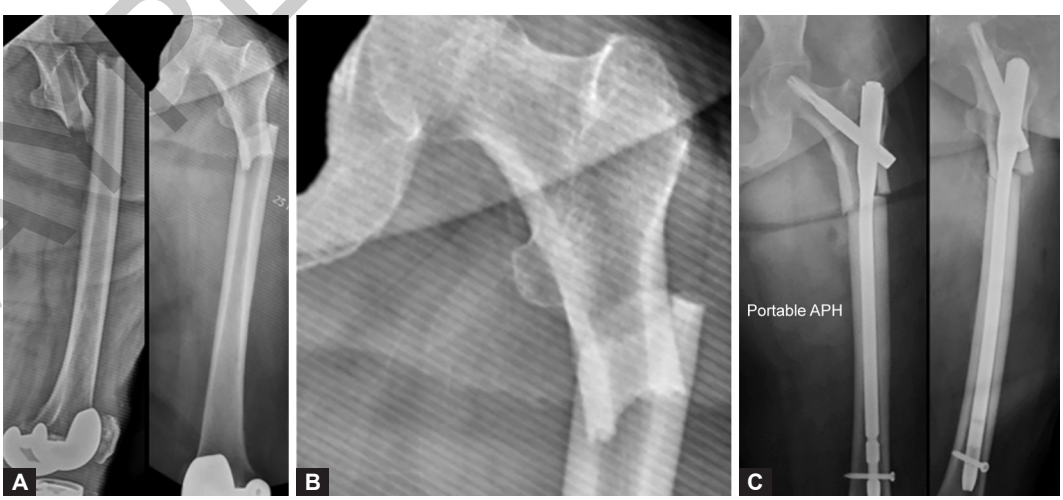

Figs. 14.21A to C: Radiographs—(A) Lateral and AP views immediately after sustaining the fracture; (B) Magnified view of AP radiograph showing features of atypical femoral fracture; (C) Immediate postoperative radiograph showing minimal varus and superior placement of the blade.

JAYPEE BROTHERS

A—Assessment of the case:

- Elderly female with no major co-morbidity
- Postosteosynthesis infection of the left subtrochanteric fracture after CMN fixation of 6 weeks duration
- Distal locking screw site was not infected.
- On antibiotics guided by culture for 4 weeks
- Clinically and radiologically, the *construct was stable* though alignment and position of the implant was suboptimal
- *Comparison of two sets of radiographs:* Immediate postoperative and at 6 weeks revealed unchanged alignment of fracture ends and the implant. There was good bridging callus in AP as well as lateral views **(Fig. 14.23)**.

O—Objectives: What is the aim?

Suppression of infection till fracture union; implant removal after healing, if required.

S—*Strategy*—How to achieve the objective:

- *Source control:* DAIR
- Identification of microbes and appropriate antibiotics
- Local antibiotics

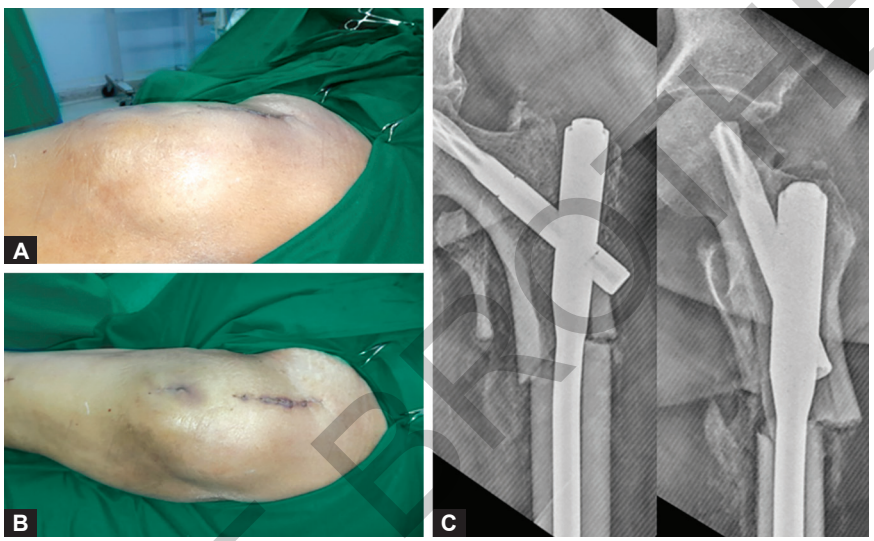

Figs. 14.22A to C: At presentation 6 weeks after surgery. Clinical photos showing swelling over the left thigh and hip (A) superior view; (B) side view; (C) Radiographs at presentation, 6 weeks postsurgery.

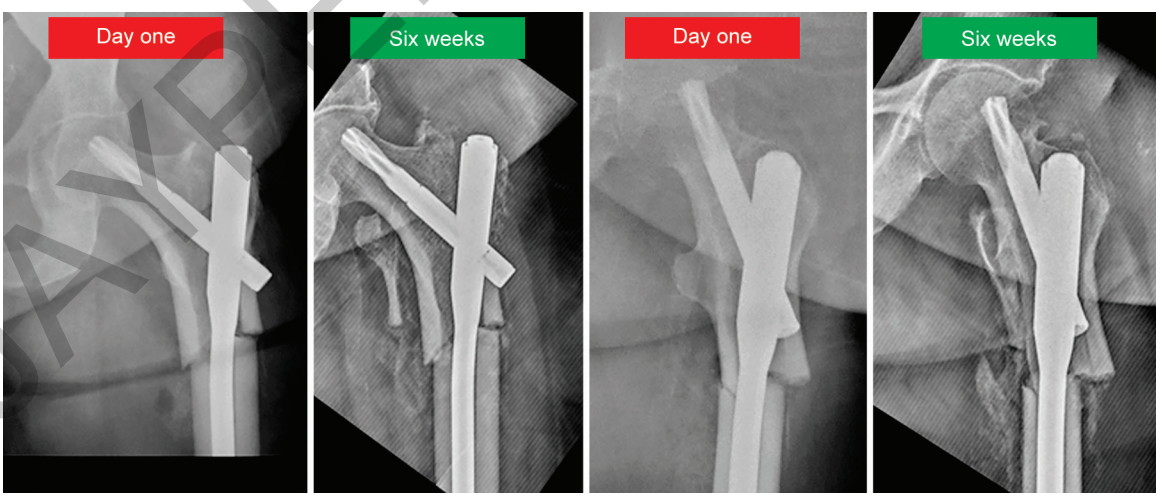

Fig. 14.23: The comparison between immediate postoperative radiographs and radiographs at 6 weeks—there is a distinct bridging callus at 6 weeks in both the views.

JAYPEE BROTHERS

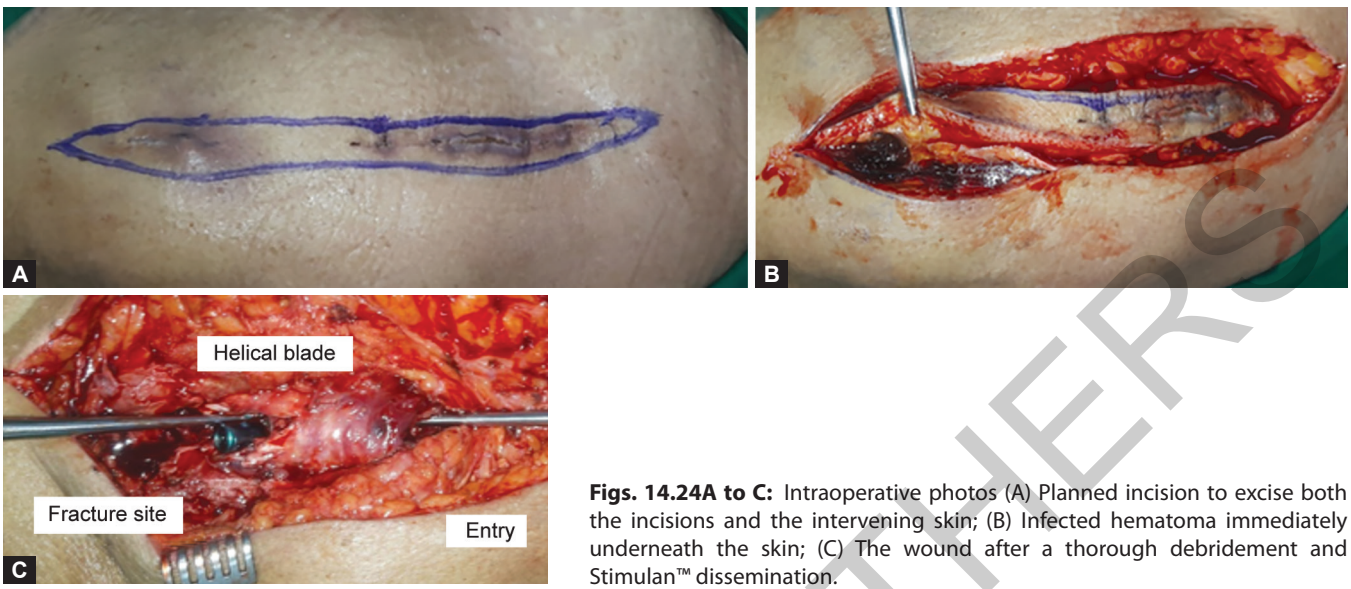

Figs. 14.24A to C: Intraoperative photos (A) Planned incision to excise both the incisions and the intervening skin; (B) Infected hematoma immediately underneath the skin; (C) The wound after a thorough debridement and Stimulan™ dissemination.

Surgery

- Incision made to extend and excise the two previous incisions
- A cavity in proximal thigh lined by infective granulation tissue containing a large quantity of organized hematoma and serosanguinous fluid was opened. Samples were collected for appropriate tests **(Figs. 14.24A to C)**.
- The exposed part of helical blade and the proximal end of nail were covered with infective granulation tissue. The infected tissue was removed and collected for culture and histopathology.
- We checked the fracture site; neither there was a gap nor movement at the fracture site.
- The debridement was suboptimal because almost entire nail was concealed.
- After copious normal saline wash biodegradable $CaSO_4$ with colistin was spread all over the infected cavity and the incision was closed in layers.
- In hindsight, we felt that exploration of the distal interlocking screwsite should havebeen done at this stage.

O—observation and rehabilitation—monitor, antibiotics, and physiotherapy—MAP.

Monitor

1. *Infection status*: She was afebrile immediately after the surgery, and her surgical site pain reduced gradually. Inflammatory markers, too, decreased.
2. All the cultures were negative. Histopathology was suggestive of infective granulation tissue, but no granulomas.
3. Empirical antibiotics; she continued to receive meropenem for 6 more weeks; additionally, she received ciprofloxacin for 12 weeks as a "biofilm active" antibiotic for gram-negative organisms.
4. *Physiotherapy and functional activities*: She was allowed to bear weight, increase the load progressively, as tolerated. She became independent ambulatory in around 4 months after the index surgery.

Follow-up

Clinical examination and radiographs at 3, 10, and 26 months showed excellent fracture consolidation. Her functional status too improved to preinjury level **(Figs. 14.25A to C)**.

Learning Points from Case Report 14.5

- In post-fracture infection, implant stability is the primary determinant of its fate.
- A bridging callus at 6 weeks in a healthy patient prompted us to retain the implant and it worked.
- Culture specific antibiotics initiated by previous team helped.

Complex issue of implant retention or removal is simplified in this algorithm **(Flowchart 14.1)**.

JAYPEE BROTHERS

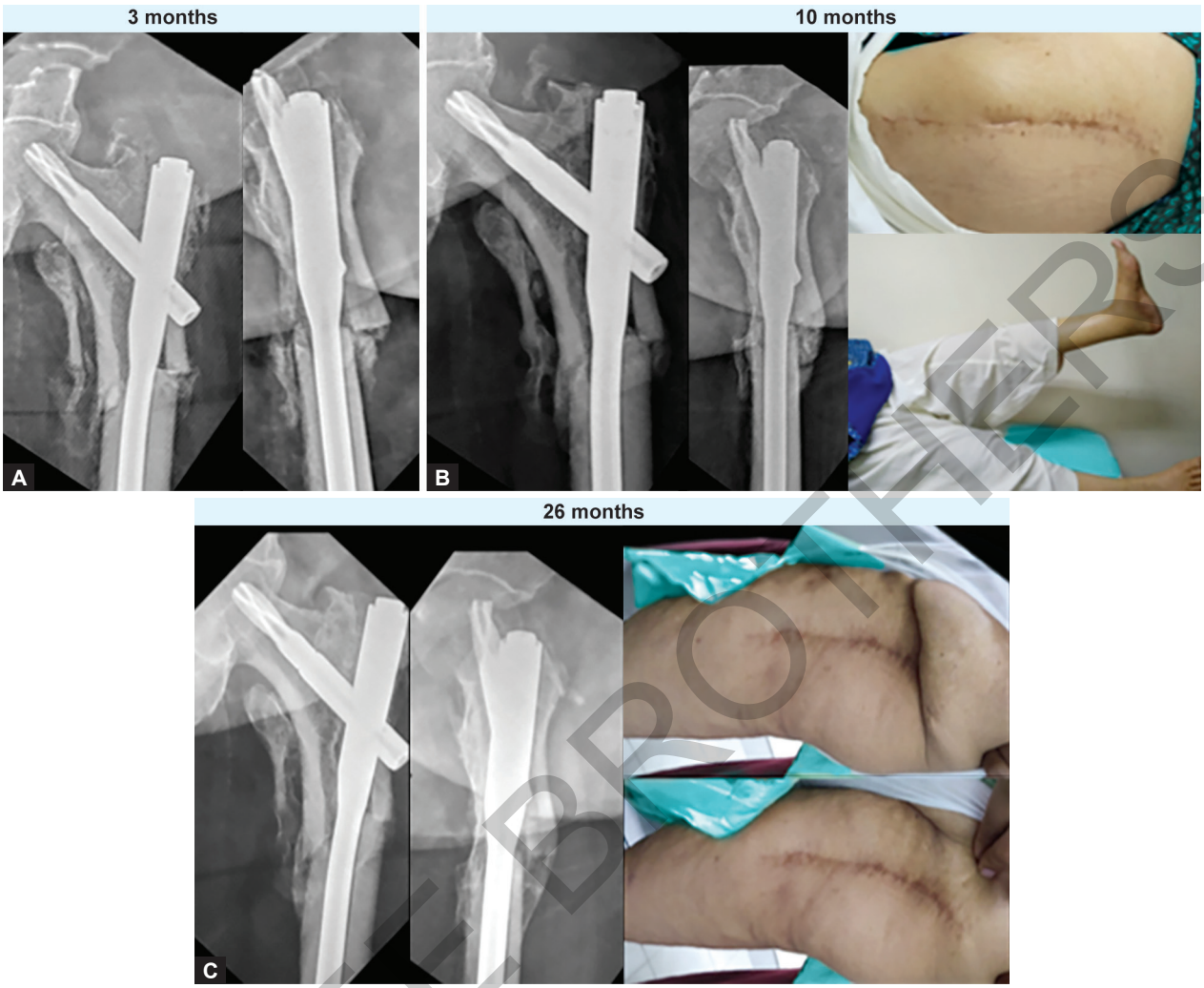

Figs. 14.25A to C: Radiographs—progressive healing (A) at 3 months; (B) at 10 months; Radiographs and clinical photographs; (C) at 26 months. Well-healed fracture, healthy scars, and good function.

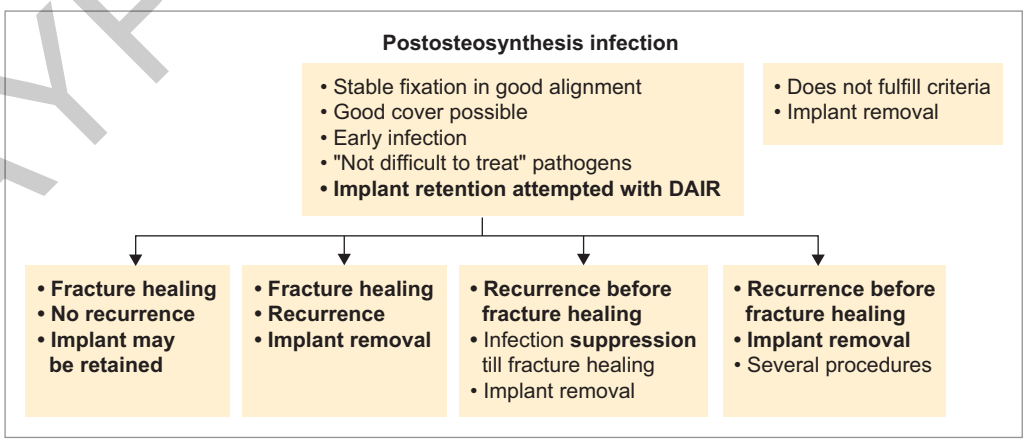

Flowchart 14.1: Decision-making for retaining or removing an implant in infection after fracture.

JAYPEE BROTHERS

POINTS TO PONDER

- Early occurrence of IAF is challenging.
- Appropriate action after diagnosis poses a social, surgical, and medical challenge.
- Debridement performed timely and meticulously, correct identification of the pathogens and administration of appropriate antibiotics in accurate dosage over adequate length of time helps implant retention. *It takes longer to debride an infected fracture than to fix it.*
- For the patient's comfort, we prefer retaining the implant and suppressing the infection untill fracture union over changing the implant or applying external fixation after DAIR.
- Identification of pathogens is the mainstay of DAIR and it is achieved by appropriate sample collection in suitable containers and requesting relevant tests.
- The treating team should optimize the patient's fitness concerning diabetes, steroid intake, and tobacco consumption in any form.
- DAIR is surgery with an uncertain outcome. Close clinical monitoring, regular hematological tests, imaging, and a flexible plan are essential for success.

REFERENCES

1. Makridis KG, Tosounidis T, Giannoudis PV. Management of Infection After Intramedullary Nailing of Long Bone Fractures: Treatment Protocols and Outcomes. Open Orthop J. 2013;7(Suppl 2):219-26.
2. Oliveira PR, Leonhardt MC, Panico CT, Silva JB, Carvalho VC, Kojima KE, et al. Infection after intramedullary nailing of femoral and tibial diaphyseal fractures. Injury. 2023;54: 110821.
3. Panteli M, Vun JSH, West RM, Howard A, Pountos I, Giannoudis PV. Surgical Site Infection Following Intramedullary Nailing of Subtrochanteric Femoral Fractures. J Clin Med. 2021;10: 3331.
4. Tschudin-Sutter S, Frei R, Dangel M, Jakob M, Balmelli C, Schaefer DJ, et al. Validation of a treatment algorithm for orthopaedic implant-related infections with device-retention—results from a prospective observational cohort study. Clin Microbiol Infect. 2016;22:457.e1-9.
5. Berkes M, Obremskey WT, Scannell B, Ellington JK, Hymes RA, Bosse M; Southeast Fracture Consortium. Maintenance of Hardware After Early Postoperative Infection Following Fracture Internal Fixation. J Bone Joint Surg Am. 2010;92:823-8.
6. Sliepen J, Buijs M, Wouthuyzen-Bakker M, Depypere M, Rentenaar R, De Vries J, et al. The effect of duration of infection on the success rate of debridement, antibiotics, and implant retention in patients with a fracture-related infection of the lower leg. Orthop Procs. 2023;105-B(Supp 17):11-11.
7. Gill SPS, Raj M, Singh P, Kumar D, Singh J, Rastogi P. Post-operative infection at fracture site with implant in situ- managed by retention of infected implant till attainment of bony union-our experience. Indian J Orthop Surg. 2015;1(4):205-10.

JAYPEE BROTHERS

for detailed information on orthopedics books, visit our website www.ejaypee.com, for detailed information on orthopedics books, visit our website www.ejaypee.com, for detailed

Infection *After* Fracture
Viewpoints & Watchpoints

Salient Features

- It is a novel work on management of infection after fracture.
- Proposes expansion of the well-established orthoplastic approach as OrthoPlastic MIDASS concept to address contaminated and infected fractures.
- Introduces PICASSO protocol to streamline the process of assessing and management.
- Presents most updated, concise, practical text in clear language, and at affordable price.
- Clinical scenarios and illustrations to serve as blueprint to cure infection and secure union in resource poor and resource-rich establishments.
- Excellent support for a standalone orthopedic surgeon when faced with this problem. Offers authentic guidelines on complete care of infection after fractures.



Vikas M Agashe MS(Orthopedic) D.Ortho, completed his medical graduation in 1974 and his postgraduate degree in "Orthopedics" in 1978 from Seth GS Medical College and KEM Hospital in Parel, Mumbai. He then worked at Dr RN Cooper Hospital in Mumbai until 1983, where he gained valuable experience. Following that, he began practicing at Dr Agashe's Maternity and Surgical Nursing Home in Kurla, Mumbai. Additionally, he joined PD Hinduja Hospital and Research Center, a tertiary referral center located in the heart of Mumbai, Maharashtra, India, as a visiting consultant in 1999. He is currently the Head of the Bone Infection Unit in the Department of Orthopedics at PD Hinduja Hospital. He plays a crucial role in the multidisciplinary team that manages osteoarticular and soft-tissue infections, successfully addressing challenging cases over several years. Additionally, he is a highly respected educator and a lifelong learner, passionate about reading and expanding his knowledge. He has won several awards, the most notable being the Golden Jubilee Oration Award at IOACON 2019 and the Best Paper Award at the World Association against Infection in Orthopedics and Trauma (WAIOT) Congress in Miami, USA, in September 2024. He has been the President of Bombay Orthopedic Society. Dr Agashe has drawn on decades of experience to provide exceptional insights into the management of infections following fractures in his book titled "Infection After Fractures: Viewpoints and Watchpoints."



Anand J Thakur MS(Orthopedic) FCPS D.Ortho has been in orthopedic practice since 1975. He received his MS Ortho degree from the University of Bombay in 1970 and his MBBS degree from Mahatma Gandhi Memorial Medical College, Indore, in 1965. He has worked as a Consultant Orthopedic Surgeon at Cambridge Military Hospital, Aldershot, UK and RN Cooper Municipal General Hospital, Juhu, Mumbai, and was Professor of Orthopedic Surgery at GS Medical College, Parel and University of Mumbai. Currently, he is into private practice in Mumbai and is involved in teaching postgraduate courses in orthopedics. He has authored best sellers, namely "The Elements of Fracture Fixation (5E), Locking Plates: Concepts and Applications (2E), Strategic Radiographic Positioning for Orthopedicians and Radiologists, Tapping the Power of PowerPoint for Medical Posters and Presentations, and Handbook of Fractures. He has also published a number of research papers in indexed journals. He has been the President of Bombay Orthopedic Society. He is a Life Member of Indian Orthopedic Association and Associate Overseas Member of the American Academy of Orthopedic Surgeons. Dr Thakur is also the Chairman of the Ethics Committee at HBT Medical College and RN Cooper Municipal General Hospital, Juhu, Mumbai, Maharashtra, India.

Shelving Recommendation
ORTHOPEDICS

ISBN 978-93-6616-669-8

Buy from ejaypee

JAYPEE BROTHERS