iled information on pathology books, visit our website www.jaypeebrothers.com, for detailed information on pathology books, visit our website www.jaypeebrothers.com

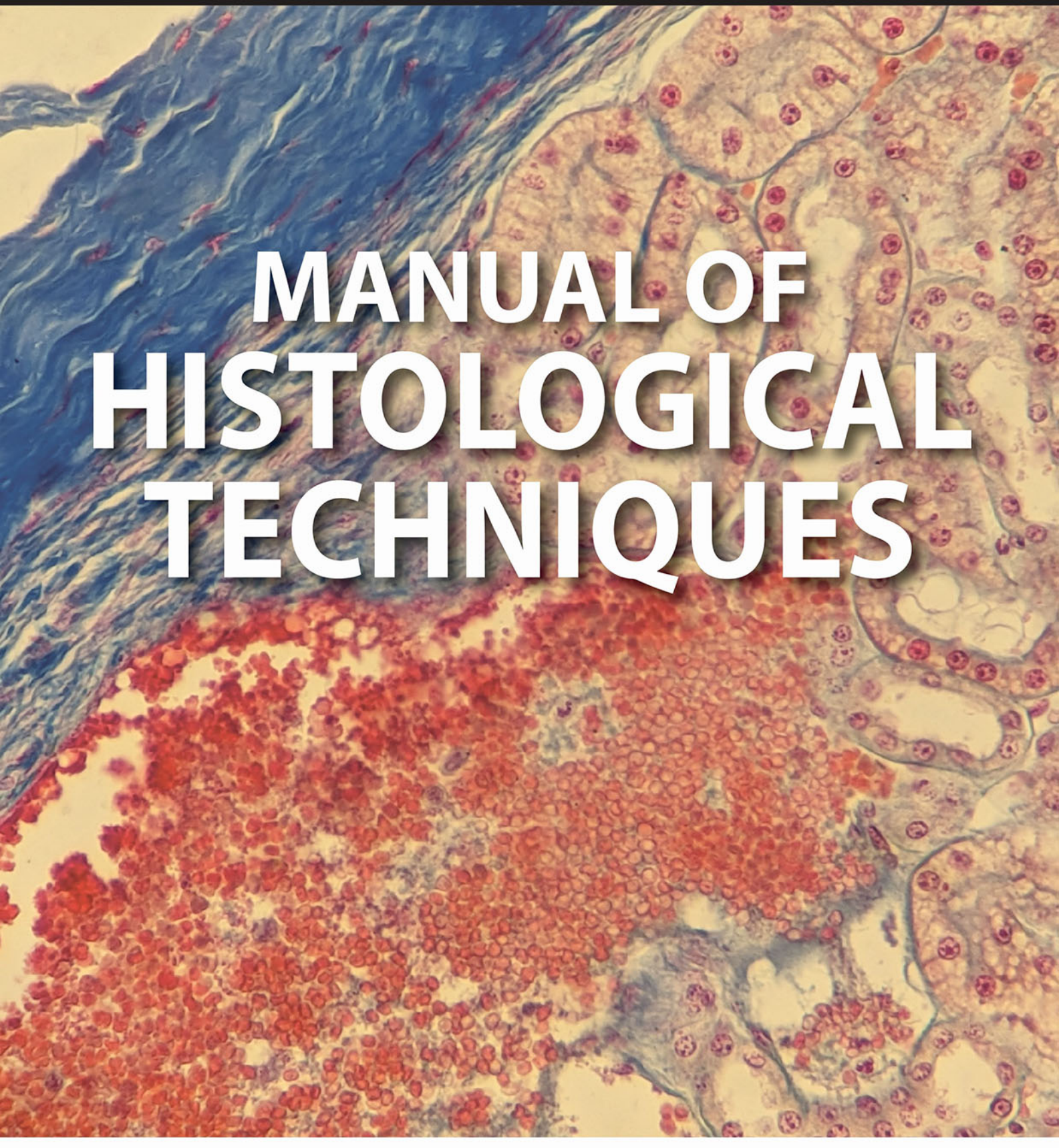

MANUAL OF HISTOLOGICAL TECHNIQUES

Santosh Kumar Mondal

3rd Edition

JAYPEE

Contents

1. Tissue Fixation and Fixatives 1

Classification of Fixatives *1*
Reactions of Fixatives with Proteins *1*
General Principles of Fixation *2*
Aldehyde (Formaldehyde/10% Formalin/ Glutaraldehyde) *2*
Routine Formalin Fixatives *3*
Chemical Composition of Different Formaldehyde Containing Fixatives *3*
Removal of Formalin Pigment *3*
Protein Denaturing Agents as Fixative *4*
Mercury Fixatives *5*
Picric Acid Fixatives *5*
Fixation of Tissues for Electron Microscopy *6*
Factors Involved in Tissue Fixation *6*
Secondary Fixation (Postfixation/Postchromation) *7*

2. Tissue Processing, Microtomy, and Paraffin Sections 8

Dehydration *8*
Clearing *9*
Impregnation *9*
Embedding *10*
Automated Tissue Processing *11*
Microtomy *12*
Rotary Microtome *12*
Microtome Knives *14*
Knife Materials *15*
Knife Sharpening *16*
Paraffin Section Cutting *17*
Section Adhesives *18*
Cutting Hard Tissues *18*
Blocking Out Molds (Shapes, Cups) *18*
Mounting of Sections *19*

3. Cryostat and Frozen Section 22

Brief History *22*
Advantages of Frozen and Cryostat Sections *22*
Suggestions for Intraoperative Frozen Section Consultation *22*
Cryostat (Machine) *23*
Cryostat Sectioning Procedure: An Overview *26*
Frozen Section Procedure: Step By Step *28*
Sampling Errors or Limitations *29*
Technical Problems *29*
Errors during Interpretations of Frozen Section *30*
Contraindications of Frozen Section *30*
Problems and Their Solutions in Frozen Section *30*

4. Staining of Tissues: Basic Concept 33

Factors Contributing to Affinities between Dye and Tissues *33*
Polychromasia *36*
Theory of Staining *36*
Stains and Dyes *37*

5. Routine Hematoxylin and Eosin Stain 39

Principle of Alum Hematoxylin Staining *39*
Iron Hematoxylin *42*
Tungsten Hematoxylin *43*
Counterstains Routinely Used with Hematoxylin Nuclear Stain *45*

6. Carbohydrates 46

Fixative for Mucins *47*
Choice of Staining Method *47*
Metachromasia and Mucin *48*
Glycogen *50*
Use of Enzymes *50*
Periodic Acid-Schiff Reaction and Stain *50*
Southgate's Mucicarmine Method (Mayer, 1896; Modified by Southgate, 1927) *53*

7. Lipids 55

Classification of Lipids *55*
Classification of Lipids Based on Polar and Nonpolar Groups *55*
Fixation of Lipids *56*
Identification of Lipids *56*
Control Sections *57*

8. Proteins and Nucleic Acid Staining 62

Histophysical Methods *62*
Amino Acid Histochemical Methods *62*
Enzyme Histochemical Methods *64*
Immunohistochemical Methods *64*
Fluorescent Methods *64*
Nucleic Acids *64*
Deoxyribonucleic Acid *64*
Ribonucleic Acid *64*
Ribonucleic Acid Staining *66*

9. Connective Tissue Staining 69

Cellular Component *69*
Fibroblasts *69*
Macrophages or Histiocytes *69*
Plasma Cells *70*
Mast Cell *70*
Pigment Cells *70*
Reticular Cells *70*
Fat Cells *70*
Intercellular Substance *70*
Amorphous Element *70*
Fibrous Element *71*
Fibrin and Fibrinoid Materials *72*
Masson Trichrome Stain *72*

10. Pigments and Minerals 78

Hemoglobin *78*
Hemosiderin *78*
Bile Pigments *78*
Porphyrin Pigments *80*
Melanin Pigments *80*
Lipofuscins *80*
Dubin–Johnson Pigments *80*
Pseudomelanosis (Melanosis Coli) *81*
Hamazaki–Wesenberg Bodies *81*
Iron *81*
Calcium *82*
Copper *82*
Lead *82*
Uric Acid and Urates *82*
Carbon *83*
Silica *83*
Asbestos *83*
Silver *83*
Tattoo Pigment *83*
Formalin Pigments *83*
Mercury Pigments *83*
Chromic Oxide *83*
Malarial Pigment (Hemozoin Pigment) *83*
Schistosome Pigment *84*
Perls' Prussian Blue Reaction (for Ferric Iron) *84*
Tirmann-Schmelzer's Turnbull Blue Technique (for Ferrous and Ferric Iron) *84*
Hukill and Putt's Method (for Ferrous and Ferric Iron) *85*
Modified Fouchet Technique for Bile Pigments *85*
Gemelin Technique for Bile Pigments *85*
Masson–Fontana Method for Melanin *86*
Schmorl's Reaction for Melanin *86*
Long Ziehl–Neelsen Method for Lipofuscin *87*
Von Kossa's Technique for Calcium *87*
Alizarin Red S Method for Calcium *87*
Modified Rhodamine Technique for Copper *88*
Mallory and Parker's Method for Lead and Copper *88*

11. Bone and Decalcification 89

Bone Techniques *90*
Specimens and Bone Tissue Biopsies *90*
Fixatives for Bone Specimens *90*
Saws in Bone Cutting *90*
Decalcification *91*
Electrophoretic Method of Decalcification *93*
Microwave (Micro-oven) Technique *94*
Treatment of Hard Tissues *94*
Treatment Following Decalcification *94*
Test for Completion of Decalcification *94*
Surface Decalcification *95*
Factors of Decalcification Process *95*
Plastic or Synthetic Resin Embedding *95*
Methyl Methacrylate Embedding Procedure *95*

12. Nervous System 97

Neurons *97*
Glial Cell *97*
Meninges *97*
Myelin *97*
Nissl Substance (Tigroid or Chromidial Substances) *98*
Cresyl Fast Violet Stain (Nissl Substance) *98*
Luxol Fast Blue–Cresyl Violet for Myelin *98*
Page's Solochrome Cyanine Technique (for Myelin) *100*
Glees and Marsland's Modification of Bielschowsky's Method *100*

Eager's Method for Degenerating Axons *101*
Modified Bielschowsky Method (for Neurofibrillary Tangles and Plaques) *101*

13. Some Special Stains 103

Amyloid *103*
Staining for Amyloid *103*
What is Birefringence? *103*
Alkaline Congo Red Technique *104*
Thioflavin T Method *105*
Lendrum's Technique (Metachromatic Stain) *105*
Gram–Twort Stain *106*
Ziehl–Neelsen Method *107*
Modified Wade–Fite Method for *Mycobacterium leprae* and *Nocardia* *107*
Gimenez Method for *Helicobacter pylori* *108*
Giemsa Stain for Parasites *109*
Phloxine–Tartrazine Technique *109*
Special Stains *110*

14. Enzyme Histochemistry and Histochemical Stains 114

Enzymes *114*
Histochemistry *114*
Enzyme Histochemistry *114*
Principles of Enzyme Histochemistry *114*
Classical Histochemical Reactions *114*
Enzyme Types *114*
Types of Histochemical Reaction *115*
Skeletal Muscle Biopsy *116*
Detection of Nerves and Ganglia in Suspected Hirschsprung's Disease *119*
Conclusion *120*
Argyrophil Staining *123*
Argentaffin Staining (Masson–Fontana Method) *123*

15. Immunohistochemistry 124

Definition *124*
Antigen *124*
Epitopes *124*
Antibody *124*
Short History *124*
Different Techniques *124*
Labeled Direct Method (Traditional Method) *125*
Unlabeled Enzyme-antienzyme Complex Method (Peroxidase-anti-peroxidase Complex Method) *126*
Technical Aspects of Immunohistochemistry *127*
Cytological Preparations *128*
Adhesive for Histologic Sections *128*
Antigen Retrieval Techniques *128*
Heat Mediated Antigen Retrieval *129*
Preparation of Paraffin Wax Sections for IHC *130*
IHC Staining Protocol *131*
Multiple Staining *132*

16. Cell Block and Diagnostic Cytopathology 140

Preparation of Cell Block Using Agar *140*
Preparation of Cell Block Using Thrombin and Plasma *140*
Points to Remember *140*
Use of Cell Block *141*
Normal Saline Rinse Method *141*
Fifty Percent Ethanol Rinse Method *141*
Tissue Coagulum Clot Method *141*
Cellient™ Automated Cell Block System *142*
Shandon Cytoblock Method *142*
Fixatives Used in Cell Blocks *142*
Embedding and Paraffin Sections *145*
Short Schedule for Automatic Tissue Processing for Cell Blocks (13 Hours) *145*
Shidham's Protocol for Cell Block Preparation *146*

17. Plastic/Resin Embedding Media 149

Classification of Plastic Media *149*
Epoxy Resins/Plastics *150*
Acrylic Resins/Plastics *150*
Application of Acrylic Plastics *151*
Polyester Plastics *151*
Processing and Embedding for Methyl Methacrylate *151*
Processing and Embedding for LR White *152*
Processing and Embedding for Glycol Methacrylate *152*
Sectioning Cutting of Acrylic Resin/Plastic Embedded Specimens *152*
Staining of Acrylic Resin/Plastic Sections *152*
Basic Techniques for Embedding and Sectioning Plastics/Resins *153*

18. Electron Microscopy 154

Types of Electron Microscopes *154*
Renal Diseases *155*
Neoplasms *157*
Metabolic Diseases *157*
Infectious Diseases *157*
Genetic Diseases *157*

Skeletal Muscle Biopsy 158
Peripheral Nerve Biopsy 158
Diseases of Obscure Nature 158
Limitations of Electron Microscopy 158

19. Immunofluorescence Techniques 159

Definition 159
Fluorescence 159
Brief History 159
Technical Aspects 161
Procedure for Frozen Tissue Sections 161
Direct Immunofluorescence Staining Method 161
Indirect Immunofluorescence Staining Method 162
Fluorescent Microscope 163
Diagnostic Use of Immunofluorescence 163

20. Museum Technique 174

Reception of the Specimen 174
Preparation of the Specimen 174
Fixation in Fixative 175
Restoration of Color 175
Preservation in Mounting Fluid 176
Presentation of the Specimen 177
Preparation of Museum Jars or Boxes (Perspex) 177
Mounting in Perspex Jars or Routine Mounting 177
Mounting in Glass Jars 178
Gelatin Embedding 178

21. Light Microscopy 179

The Microscope 180
Component of a Light Microscope 180
Light Source 181
Routine Care and Maintenance 181

22. Molecular Diagnostic Techniques and Its Applications 183

Specimen Requirements 184
DNA Analysis 184
RNA Analysis 186
Protein Analysis 186
Interphase Cytogenetics 186
Microdissection 188
Polymerase Chain Reaction 188
Applications of Polymerase Chain Reaction 194
DNA Microarrays 196

23. In Situ Hybridization and Fluorescent In Situ Hybridization 199

In situ Hybridization 199
Methods of in situ Hybridization 199
In situ Hybridization Protocol 201
Result 201
Applications of in situ Hybridization 201

Fluorescent in situ Hybridization **201**
Basic Steps of Fluorescent in situ Hybridization 202
Probes 202
Different Types of Fluorescent in situ Hybridization 205
Labeling in Fluorescent in situ Hybridization 205
Tissue Types 205
Fluorescent in situ Hybridization Procedures (General/Common Things) 206
Reagents 207
Metaphase Scoring Criteria 209
Single-day Fluorescent in situ Hybridization Protocol (Sigma–Aldrich) 210

24. Bone Marrow Trephine Biopsy 214

Procedure of Trephine Biopsy 220
Care of the Trephine Biopsy Site after the Procedure 221
Processing of Trephine Biopsy Specimen (Tissue Sectioning) 223

25. Tru-cut Biopsy or Core Needle Biopsy 226

Core Biopsy 226
Tru-cut Biopsy of Some Organ-specific Lesions 228
Fine Needle Aspiration Cytology or Needle Biopsy, Who is the Boss? 232

26. Diagnostic Use of Immunohistochemistry in Surgical Pathology 234

Some Important Immunohistochemical Markers Used in Surgical Pathology 234
Quality Control Measures for Immunohistochemical 244
Interpretation of Immunohistochemistry 252

27. Microarrays and DNA Sequencing 254

Definition 254
Microarray Technique 256
Microarray Principle 257
Interpretation of Microarrays 258

Glossary of Microarrays *258*
Clinical Applications of Microarrays *259*
Limitations of Microarrays *260*
Deoxyribonucleic Acid Sequencing *260*
Multiple Ligation-dependent Probe Amplification *279*
Polymorphic Markers and Molecular Diagnosis *279*
Glossary *280*

28. Microdissection and Different Types of Polymerase Chain Reaction 282

Laser Capture Microdissection *282*
Multiplex Polymerase Chain Reaction *284*
Nested Polymerase Chain Reaction *285*
Ligase Chain Reaction *286*

29. Quality Control in Histopathology 288

Quality Assurance *288*
Quality Control *288*
National Accreditation Board for Testing and Calibration Laboratories Guidelines for Scope Preparation *293*
Histopathology *293*
Fetal Autopsy *296*
External Quality Assurance Scheme in Histopathology *297*
Postexamination Procedure in Histopathology *299*

30. Digital Pathology 301

Applications of Digital Pathology *301*
From Telepathology to Whole Slide Imaging *304*
Computational Pathology *305*
Validation *306*
Quality Control of Whole Slides Images *307*

31. Laboratory Safety, Waste Disposal, and Management 310

Safety Data Sheets *310*
Universal Precautions *310*
Biomedical Waste Definition *311*
Notification and Amendments in Biomedical Waste Management and Handling Rules *312*
Duties of Operator *312*
Postexposure Management of Needle Stick Injury *315*
Schedule-IV (1978) *317*
Accident Reporting *318*
Annual Report *318*
Segregation *318*
Collection *318*
Local Storage *319*
Transportation to Central Storage Site *319*
Central Storage Area *319*
Transportation to Final Disposal Site *319*
Education and Training *319*
Safety Program *319*
Safety Equipment *319*
Incineration *320*
Nonincineration Methods *320*
Infectious Wastes *320*
Difference between Infectious Waste and Hazardous Waste *321*
Disinfectants *322*

***Index* 325**

CHAPTER 26

Diagnostic Use of Immunohistochemistry in Surgical Pathology

JAYPEE BROTHERS

SOME IMPORTANT IMMUNOHISTOCHEMICAL MARKERS USED IN SURGICAL PATHOLOGY (TABLES 1 TO 4)

- **Actin:** This is a ubiquitous contractile protein responsible for cell motility. This is a useful marker for smooth muscle and myofibroblasts. Also used to evaluate myoepithelial cells in lesions of salivary gland, breast, and sweat glands. Various isoforms exist, e.g., sarcomeric actin used as a marker of rhabdomyosarcoma.
- **Anaplastic lymphoma kinase (ALK):** The *ALK* gene is present on chromosome 2. A hybrid nucleophosphin (NPM) ALK protein is produced when t(2;5) chromosomal translocation leads to fusion of ALK protein with the NPM. This is detected by ALK1 (p80) monoclonal antibody. Mainly used to detect anaplastic large cell lymphoma. Also used in identification of inflammatory myofibroblastic tumor and rare cases of pulmonary adenocarcinoma.
- **Alkaline phosphatase:** These are membrane bound glycoproteins. Four major isotypes—hepatic, osseous, renal, and placental types. Placental alkaline phosphatase (PLAP) used to identify gonadal and extragonadal germ cell tumors (including germ cell neoplasia).
- **Alpha-amylase:** This enzyme is secreted by pancreatic acinar cells and salivary glands and therefore used to identify tumors of these organs.
- **Alpha-fetoprotein:** It is a major glycoprotein of plasma in fetus and major sources are liver and visceral endoderm of the yolk sac. It is used to identify yolk sac (endodermal sinus) tumors, other germ cell tumors (embryonal carcinoma) in hepatic and hepatoid neoplasms and in pancreatic tumors with acinar cell differentiation.
- **Arginase-1:** It is a more sensitive marker for hepatocellular carcinoma (>90%) and has the advantage of being reactive in poorly differentiated carcinomas.
- **B 72.3:** It is a monoclonal antibody which reacts with a high molecular weight glycoprotein 72 (TAG72). It differentiates pulmonary adenocarcinoma (positive) from mesothelioma (negative).

TABLE 1: Organ specific or tumor type specific immunohistochemistry (IHC) markers (Flowchart 1).

Primary site	*IHC markers*
Adrenal cortical tumors	Melan A+, calretinin+, inhibin A+, synaptophysin+, CEA–, SF-1+
Breast carcinoma	ER+/PR+, GATA3+, GCDFP15+/–, MGB +/–, SOX10 (triple negative carcinoma)
Cervix adenocarcinoma	P16+, CEA+, HPV+, PAX8+/–, PR–, PAX2–, HR-HPV DNA, and RNA ISH+
Colorectal carcinoma	CD20+, CD7–, CDX2+, SATB2+, CDH17+
Colon (medullary carcinoma)	SATB2+, CDH17+, CDX2+/–, Calretinin+/–, TFF3+/–
Esophagus (adenocarcinoma)	CDH17+, MUC1+/–, MUC5AC+/–, CDX2+/–
Endometrium	ER+, PAX8+, Vimentin+, PAX2+
Liver	HepPar1+, Glypican3 +, Arginase1 +, CD10+, pCEA(canalicular)+, AFP+
Mesothelioma	Calretinin+, WT1+, CK 5/6 +, TTF-1–, CEA–, BerP4, D2-40+

Continued

Continued

Primary site	IHC markers
Melanoma	Mart 1 (Melan A) +, HMB45+, S100+, SOX10 + Vimentin+
Lung (adenocarcinoma/large cell)	CK7+, CK20–, Napsin A+, TTF-1+, MOC31+, CEA+
Lung (neuroendocrine/small cell)	Chromogranin+, synaptophysin+, TTF-1+, CD56+
Cholangiocarcinoma (extrahepatic)	CK7+, CK20–, cytokeratin +, EMA+, mCEA+, pVHL–
Cholangiocarcinoma (intrahepatic)	CK7+, CK20+, cytokeratin +, EMA+, mCEA+, pVHL+
Germ cell tumors	PLAP+, SALL4+, NANOG+, CD117+, OCT 3/4+, CD30+, Glypican 3+, SOX17+
Pancreas (ductal)	Maspin A+, S100 p(placental)+, MUC3+, MUC4+, MUC1+, CK7+, CK8+
Lung (squamous cell carcinoma)	p63+, CK 5/6+, p40 +, BG8 +, SOX2+, 34βE12+, P63/p40+, CK5/6+
Renal/kidney	CD10+, PAX8+, CAIX+ Vimentin+, pVHL+, Inhibin–, CEA–
Ovary (serous carcinoma)	PAX8+, WT1+, ER+, CK7+ /CK20–, p53 abnormal in high grade tumors
Ovary (mucinous carcinoma)	DPC4+, CA125+, CDX2+/–, EMA, MUC5AC, PAX8+(50%)
Ovary (clear cell carcinoma)	pVHL+, PAX8+, HNF-1β +, KIM-1+, Napsin A+, p53 wild type
NUT midline carcinoma	CK7+/–, CK20+/–, p63/p40+, *NUT* gene
Stomach (adenocarcinoma)	CK7+, CDX2+, MUC1+/–, MUC5AC+/–
Small intestine (adenocarcinoma)	CDX2+, CDH17 +, Villin+/–, MUC5AC+/–, CK20 +
Salivary (ductal)	GATA3+, AR +, GCDFP+,
Thymoma (epithelial)	EMA+, CK+, CEA+
Thymoma (lymphocytic)	TdT+, CD99+, CD5~
Thymic carcinoma	CD5+, CD117+, PLAP+, GLUT1+, p63 +, Bcl-2+, Mcl-1+
Thyroid (papillary/follicular)	TTF-1+, Thyroglobulin+, PAX8+
Thyroid (medullary)	TTF-1+, Calcitonin+, CEA+, Thyroglobulin–
Prostate	PSA+, PSAP+, NKX 3.1+/–, ERG+/–, PSMA+, CK7 and CK20–
Urothelial/urinary bladder	GATA3+, P63+, P40+, S100P+, Uroplakin II+, CK5/6+, CK7 and CK20+
Pancreatic (acinar cell carcinoma)	Glypican 3+, antitrypsin+, BCL-10+, E-cadherin+
Pancreatic (neuroendocrine tumor)	PR+(ER always negative), Syn/Chromo/INSM1+, AE1/AE3+

Abbreviations: AR, androgen receptor; CDH17, cadherin 17; CDX2, caudal type homeobox 2; DPC4, SMAD family member 4; GATA3, GATA binding protein 3; GCDFP15, gross cystic disease fluid protein 15; PAX, paired box gene; S100p, placental S100.

TABLE 2: Tumor specific markers for various biphasic connective tumors.

Type of tumor	Immunohistochemistry (IHC) markers
Synovial sarcoma	AE1/AE3+/–, EMA+/– (epithelial type), S100+ (spindle tumors), CD34+
Dedifferentiated liposarcoma	MDM2+, CDK4+, HMGA2+
Mixed tumor/myoepithelioma of soft tissue	AE1/AE3+, EMA+, S100+, SMA+/–, P63+/–
MPNST	S100+, SOX10+, AE1/AE3-, EMA- (spindle cells)
Biphasic mesothelioma (epithelial component)	AE1/AE3+, CK5/6+, Calretinin+, WT1+
Malignant mixed Mullerian tumors (carcinosarcoma)	AE1/AE3+, PAX8+, WT1+,
Sarcomatoid components	Desmin+, Caldesmon+, S100+

Abbreviations: MPNST, malignant peripheral nerve sheath tumor; PAX, paired box gene.

JAYPEE BROTHERS

TABLE 3: Panel of immunohistochemistry (IHC) markers in some specific tumors.

Type of tumor	*Panel of IHC markers*
Benign fibrous histiocytoma	CD68–, F13a++
Dermatofibrosarcoma protuberans	CD34++, CD68±
Alveolar soft part sarcoma	Desmin+, CMA+, nuclear TFE3+, PAS+/diastase resistant rhomboid crystals
Angiosarcoma of bone	ERG + (ERG is also positive in epithelioid hemangioendothelioma and prostatic carcinoma), CD31+, CD34+
Angiomyolipoma	HMB-45+, Mart1+, SMA+
Chordoma	S100++, Brachyury+, CK++, EMA++
Chondrosarcoma	S100++, CK+/–, EMA+/–
Clear cell sarcoma (malignant melanoma of soft part)	S100++, EMA +/–, HMB45+, Melan A+, NSE+, Vimentin+
Desmoplastic small round cell tumor (DSRCT)	Desmin++, S100, NSE++, CK++, EMA++, WT1+, NSE+, Synaptophysin+
Epithelioid sarcoma	CD34++, NSE+/–, CK++, EMA++, loss of INI1
Enteropathy-associated T-cell lymphoma	CD3+, CD5–, CD103 (marker of intraepithelial lymphocytes)
Fibrosarcoma	CD68+, F13a+
Gastrointestinal stromal tumor (GIST)	CD117+, CD34+, DOG1+, SMA+/–
Inflammatory myofibroblastic tumor	SMA (tram track pattern)+, Desmin–, H-caldesmon–
Low grade fibromyxoid sarcoma	MUC4+
Lipomatous tumor (atypical)	MDM2+ (by FISH is more sensitive and specific), CDK4+
Liposarcoma (myxoid and round cell)	Caveolin+, Leptin+, NY-ESO-1, S100 (focal)
Myoepithelial carcinoma	CK+ and myoepithelial markers (Calponin+, P63+, SMA+)
MPNST	S100+, SOX10+
Nodular fasciitis	SMA++, CMA+/–, CD68+/–
Merkel cell carcinoma	CK20 (Perinuclear dot staining), MCPyV
Synovial sarcoma (biphasic)	CK++, EMA++, Desmin+, Vimentin+, NSE+/–
Synovial sarcoma (monophasic/stromal)	TLE3+ (nuclear), CD99+
Mast cell tumor	CD117+, Tryptase+
Follicular dendritic cell tumor	CD21+, CD35+, CD23+
Solitary fibrous tumor	CD34++, STAT6+
Pigmented neuroectodermal tumor of infancy (melanotic progonoma)	Large cells: CK+, HMB45+, NSE+/–, S100–, small cells: NSE+, S100–

Abbreviations: CMA, common muscle actin (HHF35); MPNST, malignant peripheral nerve sheath tumor; TLE1, transducin like enhancer of split 1.

TABLE 4: Immunohistochemistry (IHC) marker in hematolymphoid disorders/neoplasms.

IHC marker	*Pattern of staining*	*Main diagnostic use*	*Remarks or cautions*
General leukocyte marker CD45 RB	Cell membrane, sometimes Golgi	Lymphomas and leukemias (but anaplastic large cell lymphoma and lymphoblastic lymphoma are -ve)	All leukocytes except plasma cells are +ve. Reed Sternberg cells of classic Hodgkin lymphoma are typically negative
B-lineage associated CD19	Cell membrane	B cell neoplasms including B lymphoblastic lymphomas	B cells except plasma cell are +ve
CD20	Cell membrane	B cell neoplasms, staining can be weak in CLL/SLL. L and H cells of Hodgkin (nodular sclerosis) are +ve	B cells (except pre-pro B cells) and plasma cells are +ve. Excellent marker for B cells

Continued

JAYPEE BROTHERS

Continued

IHC marker	Pattern of staining	Main diagnostic use	Remarks or cautions
CD22	Golgi and/or cell membrane	B cell neoplasms, including B lymphoblastic neoplasms	B cells except plasma cells are +ve
CD23	Cell membrane	CLL/SLL, follicular dendritic cell sarcoma, mediastinal large B cell lymphoma	CD23 is helpful for distinguishing CLL/SLL (+ve) from mantle cell lymphoma (-ve)
CD79a	Diffuse cytoplasmic often with accentuation around nuclear membrane	B cell neoplasms, including plasma cell neoplasms (50%) and B lymphoblastic neoplasms. L and H cell (Hodgkin) are also +ve	B cells including plasma cells are +ve. Some T-lymphoblastic neoplasms can coexpress CD3 and CD79a, so care must be taken for lineage assessment
PAX5 (B cell specific activator protein)	Nuclear	B cell neoplasms, including B lymphoblastic neoplasms, Hodgkin lymphoma (L and H cells, and classic R–S cells)	Plasma cells are -ve, Merkel cell carcinoma, and small cell carcinoma are commonly +ve
OCT2	Nuclear	B cell neoplasms, including plasma cell neoplasms	R-S cells of classic Hodgkin lymphoma usually do not express OCT2
T-lineage associated CD2	Cell membrane ± Golgi	T cell neoplasms, NK cell neoplasms	A very sensitive marker for T and NK lineage
CD3, surface	Cell membrane	T cell neoplasms	Surface CD3 is typically -ve in NK cell neoplasm
CD3, cytoplasmic	Cytoplasmic with perinuclear or Golgi accentuation	T cell neoplasms, NK cell neoplasms	Plasma cells and histiocytes may show faint cytoplasmic staining
CD5	Cell membrane	T cell neoplasms, some B cell neoplasms (CLL/SLL and mantle cell lymphoma)	NK cells are typically -ve
CD7	Cell membrane	T cell neoplasms	This is expressed very early in T cell development
CD8	Cell membrane	Some cases of T cell neoplasms and NK-cell neoplasm	Splenic sinus lining cells are CD8 +ve
CD43	Cell membrane	T cell neoplasms, Myeloid sarcoma, histiocytic and monocytic neoplasms	Aberrant staining of a B cell proliferation foe CD43 can be used to suggest that the lesion is neoplastic
CD45 RO	Cell membrane; rarely Golgi	T cell neoplasms histiocytic neoplasms, Myeloid sarcoma	Diffuse cytoplasmic staining is considered nonspecific staining
αβ TCR	Cell membrane	Most T cell neoplasms	NK cells are typically -ve
γδTCR	Cell membrane	Hepatosplenic T cell lymphoma	NK cell lymphomas are -ve
NK-cell associated CD56	Cell membrane	NK cell neoplasms	NK cells and subpopulation of T cells (NK-like T cells)
CD57	Cell membrane	T cell large granular lymphocyte leukemia	CD57 differentiates nodular lymphocyte predominant Hodgkin lymphoma (many +ve small lymphocytes) from T cell/histiocyte rich large B cell lymphoma
Activated and proliferation associated CD25	Cell membrane	Hairy cell leukemia, adult T cell lymphoma/leukemia, mastocytosis	Activated T cells, B cells, or macrophages are +ve
CD30	Cell membrane and/or Golgi	Classic Hodgkin lymphoma, anaplastic large cell lymphoma	Pure cytoplasmic staining is disregarded, embryonal carcinoma is frequently +ve
Differentiation stage associated TdT	Nuclear	Lymphoblastic neoplasms of B, T, or NK-cell lineage, blastic plasmacytoid dendritic cell neoplasm	TdT is the single most useful marker for distinction of lymphoblastic neoplasm from peripheral T cell lymphoma and mature B cell lymphoma (-ve)

Continued

JAYPEE BROTHERS

Continued

IHC marker	*Pattern of staining*	*Main diagnostic use*	*Remarks or cautions*
CD10	Cell membrane	Follicular lymphoma and B cell lymphoma of follicular origin, Burkitt lymphoma, angioimmunoblastic lymphoma	CD10 recognizes the common acute lymphoblastic leukemia antigen (CALLA)
CD99 (MIC2)	Cell membrane	Lymphoblastic neoplasms	CD99 is typically +ve in Ewing's sarcoma/PNET
BCL-2	Perinuclear space (cytoplasmic)	Follicular lymphoma	*BCL-2* is a major antiapoptotic gene. Burkitt lymphoma is almost always +ve
Bcl-6	Nuclear	Follicular lymphoma, Burkitt lymphoma, anaplastic large cell lymphoma, angioimmunoblastic T cell lymphoma, L and H cells of Hodgkin lymphoma	Follicular center B cell, follicular helper T cells, and CD30+ perifollicular cells are Bcl-6 +ve
CD103	Cell membrane	Enteropathy-associated T cell lymphoma, Hairy cell leukemia	Intestinal intraepithelial lymphocytes are +ve
EMA	Cell membrane and/or Golgi	Anaplastic large cell lymphoma, L and H cell of Hodgkin lymphoma, plasma cell neoplasm	EMA is usually marker of epithelial neoplasm, plasma cells are also +ve
CD138	Cell membrane	Plasma cell neoplasm, plasmablastic lymphoma	CD138 is +ve in normal epithelial cells
MUM1	Nuclear and cytoplasmic	Plasma cell neoplasms, lymphoplasmacytic lymphomas, DLBCL (75% of cases), plasmablastic lymphoma, Hodgkin lymphoma	Plasma cells and small percentage of germinal center B cells (Bcl-6 -ve) and activated T cell are MUM1 +ve. It is also +ve in some cases of melanoma
Follicular T helper cell PD1 (CD279)	Cell membrane	Angioimmunoblastic T cell lymphoma, follicular variant of T cell lymphoma	PD1+ T cell rosette around L and H cells in nodular lymphocyte predominant Hodgkin lymphoma
Lymphoma-associated Cyclin D1	Nuclear	Mantle cell lymphoma, diffuse large B cell lymphoma (rare)	Some cases of CLL/SLL can be cyclin D1 +ve
SOX11	Nuclear	Mantle cell lymphoma, Lymphoblastic lymphoma, T-Prolymphocytic leukemia, Burkitt lymphoma (25% of cases)	Schwann cells and some squamous cells are normally SOX11 +ve
ALK (anaplastic lymphoma kinase)	Nuclear or cytoplasmic	Anaplastic large cell lymphoma, Large B cell lymphoma	Inflammatory myofibroblastic tumor, pulmonary adenocarcinoma with *ALK* gene translocation are ALK +ve
MYC	Nuclear	Burkitt lymphoma, subset of diffuse large B cell lymphoma	Positive staining in most cells (>50%) with high intensity is considered positive result
Histiocytic, dendritic, and myeloid associated CD68	Cytoplasmic, granular	Histiocytic neoplasm and monocytic leukemia, Myeloid sarcoma	Nonhematolymphoid neoplasms like melanoma and granulosa cell tumor are CD68 +ve
CD163	Cell membrane ± cytoplasmic	Histiocytic sarcoma, acute monocytic leukemia	Dendritic cell tumors are -ve
S100	Nuclear, ± diffuse cytoplasmic staining	Langerhans cell histiocytosis, interdigitating dendritic cell tumor	Many nonhematolymphoid neoplasms are +ve (e.g., lipoma, liposarcoma, melanoma, chondroma, chondrosarcoma, chordoma, peripheral nerve sheath tumor)
CD1a	Cell membrane	Langerhans cell histiocytosis, indeterminate dendritic cell tumor	Langerhans cell, indeterminate cells, immature T cells (cortical thymocytes) are +ve

Continued

JAYPEE BROTHERS

Continued

IHC marker	Pattern of staining	Main diagnostic use	Remarks or cautions
Langerin (CD207)	Cell membrane + cytoplasmic (granular)	Langerhans cell histiocytosis	Sinus lining cells of lymph node and liver are commonly positive
CD15	Golgi and/or cell membrane	Classic Hodgkin Lymphoma (R–S cell), Histiocytic neoplasm	CD15 antibody is directed against the carbohydrate X hapten
CD21	Cell membrane	Follicular dendritic cell tumor, Some B cell lymphomas (e.g., endemic Burkitt lymphoma, follicular lymphoma)	Most commonly used follicular dendritic cell marker, CD21 recognizes the EBV receptor
CD35	Cell membrane	Follicular dendritic cell tumors	A useful follicular dendritic cell marker
Clusterin	Cell membrane	Follicular dendritic cell tumors, most cases of anaplastic large cell lymphoma	
CD123	Cell membrane	Blastic plasmacytoid dendritic cell neoplasm	Plasmacytoid dendritic cell are +ve
Lysozyme	Cytoplasm granular	Histiocytic neoplasms, sarcoma	Histiocytes myeloid cells are +ve
Myeloperoxidase	Cytoplasm granular	Myeloid sarcoma and myeloid leukemia	Most sensitive and specific marker for myeloid series

Abbreviations: CLL, chronic lymphocytic leukemia; EBV, Epstein–Barr virus; EMA, epithelial membrane antigen; NK, natural killer; PNET, primitive neuroectodermal tumor; PAX, paired box gene; SLL, small lymphocytic lymphoma.

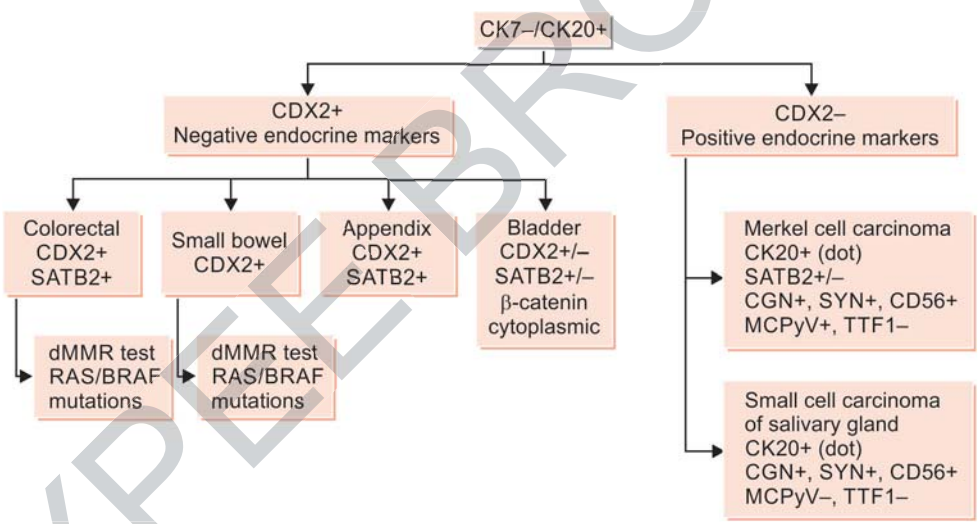

Flowchart 1: The diagnostic algorithm for workup of a CK7–/CK20+ carcinoma.

Abbreviations: CGN, chromogranin; MCPyV, Merkel cell polyomavirus; dMMR test, loss of function of dMMR genes, found in colorectal carcinoma, MMR, mismatch repair gene.

- **BerEP4:** It is used to differentiate adenocarcinoma (positive) from mesothelioma (negative).
- **Beta-catenin:** It is a 90 kDa protein which has a role in wingless type (Wnt) signaling and cell adhesion. Nuclear staining of β-catenin is used to differentiate between fibromatosis (positive) and other spindle cell mesenchymal tumors (negative). Cytoplasmic expression points to a bladder/urothelial origin.
- **CA 19-9:** This is a carbohydrate antigen and has been characterized as a monosialoganglioside related to Lewis A blood group antigen. It is used to identify pancreaticobiliary adenocarcinoma and urothelial carcinomas.
- **CA-125:** It is a cell surface glycoprotein. It is identified in mucinous epithelial ovarian tumors and adenocarcinomas of some other sites such as cervix, endometrium, gastrointestinal tract, thyroid, and breast.
- **Cadherins:** These are transmembrane glycoproteins located in desmosomes. The two types of cadherins are epithelial type (Ecadherin) and neutral type (Ncadherin). They bind to catenin to form complexes.

JAYPEE BROTHERS

Normal pattern of immunostaining is membranous. Its uses are:

- **Breast cancer:** Absent expression in lobular carcinoma and lobular carcinoma in situ (LCIS). But expressed in ductal carcinoma of breast.
- **Stomach:** Signet ring carcinoma is negative for Ecadherin expression. Germline mutation of Ecadherin is seen in hereditary diffuse gastric mutation (*CDH1* gene mutation).
- Colonic adenocarcinoma and invasive bladder carcinoma—reduced expression.

❖ **Calponin:** It is a cytoskeleton-associated actin-binding protein present in myoepithelial cells, smooth muscle cells, and other contractile cells.

❖ **Caldesmon:** H-caldesmon is a cytoskeleton-associated protein similar to calponin and used for similar purposes.

❖ **Calretinin:** It is a 29 kDa calcium binding protein expressed by various types of mesothelial, epithelial, and stromal cells. It is used to differentiate mesothelioma (positive except desmoplastic variant) and pulmonary adenocarcinoma (negative).

❖ **Carcinoembryonic antigen (CEA):** This is a glycoprotein [molecular weight (MW) 200,000] normally detected in the glycocalyx of fetal epithelial cells, particularly those of mucin secreting glandular tissue. It is primarily expressed in fetal tissues and in malignant tumors. Hence, referred to as oncofetal antigen. It is particularly expressed in adenocarcinomas of gastrointestinal tract, lung, and medullary carcinoma of thyroid.

❖ **Caveolin-1:** It is the major structural protein of caveolae in endothelial cells. It is expressed in neoplasms and inflammatory bowel disease and indicates poor prognosis.

❖ **CD10:** It is particularly useful in endometrial stromal tumor **(Fig. 1)**. Positive expressions are also seen in renal cell carcinoma, solid and pseudopapillary carcinoma of pancreas, and myoepithelial tumors. CD10 is also helpful in differentiating trichoepithelioma from basal cell carcinoma (BCC) of skin. CD10 stains the stromal cells but not epithelial cells in trichoepitheliomas, whereas it is positive in epithelial cells of BCC and not in stromal cells.

❖ **CD31:** This is very useful marker of endothelial cells which is identical to the vascular endothelial adhesion molecule PECAM1.

❖ **CD34:** It stains vascular endothelial cells (normal and neoplastic). This is also positive in gastrointestinal stromal tumors (GISTs), variety of peripheral nerve sheath tumors, spindle cell component of adipose tissue neoplasms, and dermatofibrosarcoma protuberans (DFSP).

BROTHERS

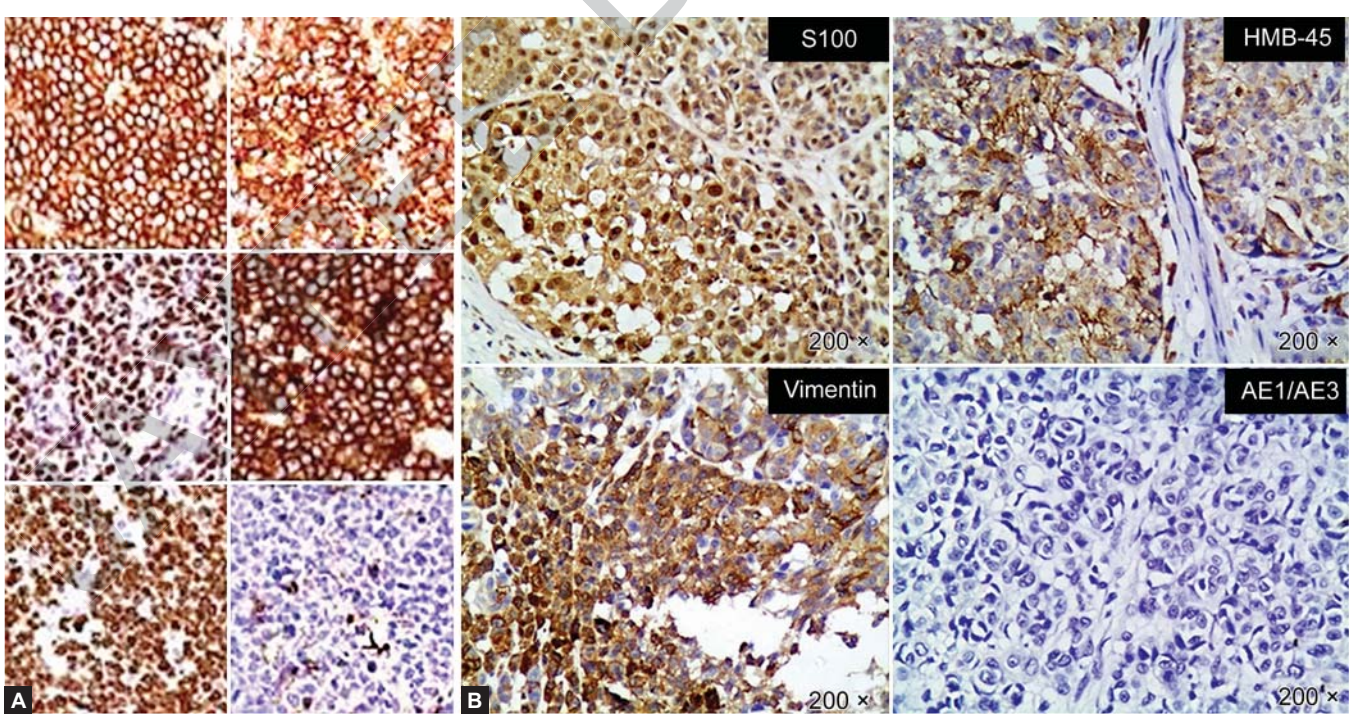

Figs. 1A and B: (A) Burkitt lymphoma immunophenotype (IHC) with—a. CD20+, b. CD10+, c. BCL-6+, d. CD38+, e. MIB-1 (Ki-67) >95%, and f. CD44–. Note the cytoplasmic membrane positivity of CD20, CD10, and CD38. Nuclear positivity of Bcl-6 and MIB-1 (Ki-67). (B) Panel of IHC markers in malignant melanoma. a. S100 positive (both nuclear and cytoplasmic), b. HMB-45 positive (cytoplasmic), c. Vimentin positive (cytoplasmic), and d. AE1/AE3 (carcinoma marker) negative.

- **CD99 (MIC2):** Positive in Ewing's sarcoma/primitive neuroectodermal tumor (PNET). Also expressed in lymphoblastic lymphoma and few cases of retinoblastoma, rhabdomyosarcoma, desmoplastic small cell tumors, ependymoma, synovial sarcoma, solitary fibrous tumor, ovarian granulose cell tumor, and testicular sertoli cell tumor.
- **CD117 (c-KIT):** This antibody identifies a transmembrane tyrosine kinase normally expressed by Cajal interstitial cells, germ cells, melanocytes, and mast cells. It is expressed in GIST, mastocytosis, melanoma, and germ cell tumors (seminoma). In GIST, expression is both membranous and cytoplasmic but in fibromatosis (Desmoid tumor) there is only cytoplasmic expression.
- **CDX2:** It is a homeobox gene which encodes a transcription factor that plays an important role in the differentiation and proliferation of intestinal epithelial cells. It identifies adenocarcinoma of intestinal origin.
- **Chromogranin:** This is composed of acidic glycoproteins and present in the soluble fraction of neurosecretory granules. This is a "pan endocrine" marker and expressed in nearly all types of neuroendocrine tumors.
- **Cyclooxygenase-2 (COX-2):** This is expressed in many carcinomas such as breast, endometrium, head, and neck. Expression indicates poor prognosis.
- **Cytokeratins (keratins):** These are a family of water insoluble intracellular fibrous proteins present in almost all epithelial cells. So, these are good markers to identify different carcinomas.
- **Desmin:** This is an intermediate filament (MW 55,000) of muscle type and is found in smooth and striated muscles and to some extent in myofibroblasts.
- **Epithelial membrane antigen (EMA):** It is a glycoprotein which is present in human milk fat globule membranes. This is a very good marker to identify different carcinomas like cytokeratins. This marker is also expressed in meningiomas, mesotheliomas, and in few malignant lymphomas (like anaplastic large cell lymphomas) and lymphocytic and histiocytic (L&H) cell of nodular sclerosis type of Hodgkin lymphoma.
- **Factor VIII related antigen:** This is synthesized in endothelial cell of blood vessels and is also found in megakaryocytes, platelets and mast cell. This is a marker of endothelial cell differentiation.
- **FLI:** The FLI1 protein is the product of the *FLI1* gene, which is overexpressed in Ewing's sarcoma/PNET because of fusion of *EWS-FLI1* gene. It is a marker of Ewing's sarcoma/PNET and also of most lymphoblastic lymphomas.
- **Galectin:** It belongs to the family of lactosebinding proteins. Its expression is seen in several carcinomas such as thyroid, endometrium, head and neck, bladder, kidney, pancreas, and large bowel. Gal-3 has special importance as it stains thyroid carcinomas in a stronger and more consistent fashion than adenomas.
- **GATA3:** It exhibits nuclear staining with most often diffuse and strong reactivity. It is expressed in 92–100% of ducted and lobular breast carcinomas. It is also expressed in normal urothelial epithelial and 80–90% of urothelial carcinomas.
- **GATA4:** A transcription factor, positive in pediatric yolk sac tumor.
- **Glial fibrillary acidic protein (GFAP):** It is a cytoplasmic intermediate filament. This is present in normal, reactive and neoplastic astrocytes, developing and neoplastic oligodendrocytes, and developing, reactive, and neoplastic ependymal cells. It is also expressed in peripheral nerve sheath tumors and in mixed tumor of salivary glands and sweat glands.
- **Glypican-3 (GPC3):** It is a cell surface proteoglycan which is overexpressed in hepatocellular carcinoma and hepatoblastoma. It is also positive sometimes in malignant melanoma, clear carcinoma of ovary, yolk sac tumor, neuroblastoma, and squamous cell carcinoma.
- **Heat shock proteins (HSPs):** These proteins help in activation and survival of macrophages. Overexpression of HSPs is seen in esophageal, gastric, colonic, and hepatocellular carcinomas.
- **Hepatocyte paraffin 1 (HepPar-1):** This has a coarsely granular cytoplasmic quality and the antibody recognizes an unidentified mitochondrial antigen. This is overexpressed in hepatocellular carcinomas, hepatoblastomas, and hepatoid carcinomas but negative in bile ducts and stromal cells.
- **HER2/neu (ERBB2):** It is a cell surface protein and useful for predicting response to Herceptin (trastuzumab). Positive expression is seen in breast carcinoma (22%), colorectal carcinoma (17%), gastric adenocarcinoma (11%), and in lung squamous cell carcinoma (11%).
- **Human herpes virus type 8 (HHV-8):** It is also known as Kaposi sarcomaassociated herpesvirus (KSHV) associated with Kaposi sarcoma. Expression is also seen in multicentric Castleman disease and primary effusion lymphoma.
- **Human melanoma black (HMB)-45:** It is a very useful marker for malignant melanoma. Also positive in other neural crest derived tumors, angiomyolipoma of kidney, and in other components of tuberous sclerosis complex/perivascular epithelioid cell neoplasms (PECOMAs).
- **hMLH1 and hMSH2:** Human mutL homolog 1 and 2 are mismatch repair genes. Overexpressions are seen in hereditary nonpolyposis colorectal cancer syndrome (Lynch syndrome).

JAYPEE BROTHERS

- **Hu:** It includes HuC, HuD, and HelN1, and is associated with Hu protein family. Its localization is both nuclear and cytoplasmic. Its staining pattern in pulmonary small cell carcinoma is strong.
- **Human chorionic gonadotropin (hCG):** It is secreted by syncytiotrophoblast and is composed of two chains. The α chain has almost similar amino acid sequence to folliclestimulating hormone (FSH), luteinizing hormone (LH), and thyroid stimulating hormone (TSH), and is nonspecific. The β chain is hormone specific and is used to detect trophoblastic differentiation in germ cell tumors (choriocarcinoma, embryonal carcinoma) and ectopic hCG production by other neoplasms.
- **Inhibin:** This peptide hormone is produced by ovarian granulosa cells to inhibit FSH. It is positive in sex cord-stromal tumors of ovary and testis, steroid producing tumors of adrenal cortex and gonads, granulose cell tumors, and hemangioblastomas.
- **Mart-1 (Melan-A):** This melanocyte associated marker is recognized by the antibody A 103. It is positive in melanoma and related melanin producing cells (peripheral nerve sheath tumors, angiomyolipoma) and steroid producing cells of adrenal cortex.
- **Murine double minute type 2 (MDM2):** This protein is a regulator of apoptosis and is related to p53 cycle. Its overexpression is seen in atypical lipomatosis and dedifferentiated liposarcoma.
- **MIB1 (Ki-67) (Fig. 1):** It is antigen which corresponds to a nuclear nonhistone protein expressed by cells in the proliferative phases of G1, G2, M, and S. There is a good correlation between Ki-67 (MIB1) staining and mitotic count. Microscopic scoring of MIB1 (Ki-67) staining is done by the parentage of nuclei with positive staining in tumor cells and considered low (<10%), borderline (10–20%), and high (>20%). There is some variability regarding cutoffs but >20% is unanimously considered high.
- **MOC-31:** It recognizes an epithelial associated transmembrane glycoprotein. Expression is found in all lung adenocarcinoma (but not in mesothelioma) and in 80% of nonpulmonary adenocarcinomas.
- **MUC:** It recognizes glycoproteins (mucins) of glandular epithelium. MUC is useful to recognize different carcinomas. MUC1 is expressed in intestinal type gastric adenocarcinoma, MUC2 for mucinous type gastric carcinoma, MUC5AC for the diffuse type, and MUC5B for the unclassified type. MUC1 is expressed in many other carcinomas like pancreatic duct carcinoma (but absent in adrenocortical and hepatocellular carcinomas). MUC5AC is expressed in pancreatic ductal and endocervical adenocarcinomas. A MUC1+/MUC2/MUC5AC-immunophenotype is observed in most breast, lung, kidney, bladder, endometrial, and ovarian carcinomas. MUC1+/MUC2/MUC5AC+ pattern is characteristic of pancreatic ductal carcinoma and cholangiocarcinoma.
- **MyoD1:** It encodes a nuclear phosphoprotein and is expressed in skeletal muscle. It is positive in various skeletal muscle tumor like rhabdomyosarcoma. But in contrast to myogenin, it stains only in fresh frozen tissue and not in formalin fixed paraffin embedded tissue (a limitation).
- **Myogenin:** This is another myogenic nuclear protein and is used to identify skeletal muscle differentiation. It is strongly expressed in all types of rhabdomyosarcomas, most particularly in the alveolar pattern.
- **NANOG:** This is a transcription factor and is needed for embryonic stem cell selfrenewal and pluripotency. This is an essential factor in germ cell neoplasia. It is positive in seminoma and teratomas. Sacrococcygeal teratomas of the newborn are also NANOG positive as they arise from remnants of the epiblastlike tail bud blastema which contain cells positive for embryonic stem cell markers.
- **Napsin A:** It shows granular cytoplasmic staining. It has slightly higher sensitivity for lung adenocarcinomas compared to thyroid transcription factor1 (TTF1).
- **Notch:** Notch signaling controls cell proliferation, cell fate decision, differentiation, and survival/apoptosis. Several subtypes are present:
  - **NOTCH1:** It is related to breast carcinoma and a predictor of therapeutic failure in head and neck squamous cell carcinoma.
  - **NOTCH3:** It is also involved in breast carcinoma. In cervical cancers, it indicates poor prognosis.
  - **NOTCH4:** It is involved in the pathogenesis of hepatocellular carcinoma.
- **OCT-3/4:** It is a stem cell transcription factor which is present in embryonic and cancer cells but absent in differentiated tissues. Lung nonsmallcell carcinoma, neuroblastoma and ovary/testis (dysgerminoma, embryonal carcinoma, intratubular germ cell neoplasia, seminoma, teratoma, and immature neuroepithelium) are positive. It is negative in yolk sac tumor.
- **Osteocalcin:** It is expressed in osteosarcoma and other osteoid forming tumors. This is more specific than osteonectin.
- **Osteonectin:** It stains osteosarcomas and other tumors like malignant melanoma.
- **Osteopontin:** It is expressed in the early stages of bone formation by osteoblast and some other bone marrow cells. It is positive in benign and malignant bone tumors, gliomas (particularly anaplastic), borderline ovarian surface tumors, and various types of renal tumors.

JAYPEE BROTHERS

- **PAX:** Paired box (*Pax*) genes are tissue specific transcription factor:
  - **PAX2:** It is a pre-B and B-cell marker and is used to identify B-cell neoplasm. Renal cell carcinoma, benign cervical mesonephric, and Mullerian glandular lesions are also positive. So, it identifies metastatic renal cell carcinoma.
  - **PAX5:** Detection of pre-B-cell lymphomas (PAX5+, more sensitive and specific than CD20), diagnosis of Reed–Sternberg cells (PAX5+) versus T/null cell anaplastic large cell lymphoma (PAX5), diagnosis of lymphoplasmacytoid lymphoma/plasmacytoid differentiation in marginal zone lymphoma (PAX5+) versus plasmacytoma (PAX5).
  - **PAX8:** It is a nuclear marker. It differentiates primary or metastatic tumors (kidney, thymic, thyroid, and Müllerian tumors which are PAX8+) from PAX8 tumors [adrenal, breast and most gastrointestinal (GI), lung, and prostate]. Interestingly, it is positive in mesonephric remnant hyperplasia in prostate but negative in prostatic adenocarcinoma.
- **Podoplanin (D2-40):** It is expressed in lymphatic vascular endothelium. It has also been expressed by a variety of lymphovascular and nonvascular neoplasms (epithelioid mesothelioma, seminoma, and hemangioblastoma).
- **Prostate specific antigen (PSA):** PSA is a kallikrein like protease (MW 33,000) which has been extracted from prostatic tissue. This marker is the method of choice for the identification of prostatic adenocarcinoma.
- **Prostatic acid phosphatase (PAP):** This isoenzyme is secreted by the normal hyperplastic, and neoplastic prostatic epithelium. Apart from prostate, it is also positive in carcinomas of the bladder and carcinoid tumors.
- **S100 protein:** It is a family of acidic, dimeric, and calciumbinding proteins (MW 21,000). They are present both in the nucleus and cytoplasm of glial and Schwann cells, melanocytes, adipocytes, chondrocytes, myoepithelial cells, and other cells.
- **SALL4:** This nuclear staining marker is an oncofetal protein expressed in many germ cell tumors (seminoma, embryonal carcinoma, yolk sac tumor, and intratubular germ cell neoplasia).
- **SATB2:** This is also a transcription factor (special AT-rich sequence binding protein 2). This is expressed in all adenocarcinomas if the appendix (including adenocarcinoma ex goblet cell carcinoid) and in over 85% of colon adenocarcinomas.
- **Sex-determining region YHMG box (SOX):** This is a family of transcription factor. Several subtypes are:
  - **SOX2:** Expressed in squamous cell carcinoma of the GI tract and testicular germ cell tumors.
  - **SOX9:** Useful to identify chondrosarcoma (SOX9+). Also, it is expressed in Sertoli cell tumors.
  - **SOX10:** Most sensitive marker for uveal melanoma.
- **Synaptophysin:** It is a major glycosylated transmembrane glycoprotein (MW 38,000). It is expressed in normal, reactive, and neoplastic cells of neuroendocrine and neuroectodermal types, including thyroid medullary carcinoma, carcinoid tumors, and pheochromocytoma.
- **Thrombomodulin:** It is an endothelial cellassociated cofactor located on the cell membrane that forms a 1:1 stoichiometric complex with thrombin. It is expressed in a vascular tumor. It is also expressed in mesothelioma and transitional cell carcinomas (urothelial carcinomas).
- **Thyroglobulin:** It is a large glycoprotein (MW 67,000) and is produced by thyroid follicular cells. This is a specific marker for thyroid differentiation and is used in evaluation of thyroid neoplasms.
- **Thyroid transcription factor-1 (Fig. 2):** This is a nuclear transcription factor necessary for the development of thyroid and pulmonary tissue. Positive expression in all types of thyroid carcinomas (including medullary carcinoma), except for anaplastic carcinoma and mucinous carcinoma. This is also expressed in most lung carcinomas (including small cell neuroendocrine type).
- **Uroplakin:** There are specific differentiation products of terminally differentiated superficial urothelial cells. It is expressed in urothelial tumors of the bladder, pelvis, and ureter as well as urothelial l type tumors of the ovary (like Brenner tumor).
- **Vascular endothelial growth factor (VEGF):** It plays an important role in tumor growth and metastasis, which induces vascular permeability. Positive expression by tumor cells is regarded as poor prognosis.
- **Vimentin:** It is present in mesenchymal cells such as endothelial cells, fibroblasts, and vascular smooth muscle cells. It is a ubiquitous and nonspecific mesenchymal marker.
- **WT1:** This nuclear marker is expressed in Wilms tumor of kidney and also in mesothelioma, Mullerian ovarian neoplasms (notably ovarian serous carcinoma). Cytoplasmic expression is found in rhabdomyosarcoma.

JAYPEE BROTHERS

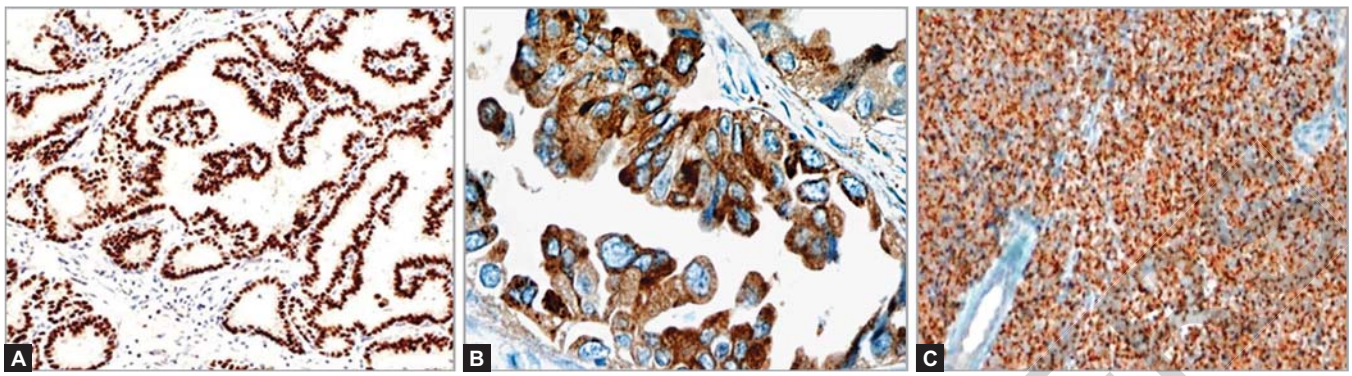

Figs. 2A to C: (A) Thyroid transcription factor-1 positivity (nuclear) in papillary thyroid carcinoma. (B) Napsin A positivity (cytoplasmic) in lung adenocarcinoma. (C) Perinuclear dot like positivity of CD20 in Merkel cell carcinoma.

QUALITY CONTROL MEASURES FOR IMMUNOHISTOCHEMICAL (TABLES 5 TO 7)

To ensure quality in IHC laboratory, measures should be taken in the pre, intra and postanalytical phases. The important factors which determine the quality for IHC are listed in **Table 8**.

Factors determining the quality (Quality controls) in IHC:

- *Preanalytic:*
  - Test selection
  - Specimen type
  - Acquisition, prefixation/transport time
  - Nature of fixative, fixation type, and total time
  - Processing of tissues, temperature
- *Analytic:*
  - Antigen retrieval procedure
  - Selection of "primary" antibodies
  - Protocol; labeling reagents
  - Reagent validation
  - Selection of controls (positive controls and negative controls)
  - Training of technicians/certification
  - Certification of laboratory by authorized body [like National Accreditation Board for Testing and Calibration Laboratories (NABL)]
  - Participation in quality assurance (QA) programs.

TABLE 6: Antigen retrieval methods.

Methods	*Possible mechanisms*
Enzymatic digestion	
Trypsin	Etching effect due to protein cleavage
Pronase	
Pepsin	
Acid treatments	Solubilization of amyloid proteins
Formic acid	
Alkaline hydrolysis	Saponification
Detergent	Solubilization
Urea solution	Protein structural unfolding
Refixation with zinc solution	Protein precipitation
Freeze and thawing	Increase in membrane penetration
Freeze and dying	
Heating	
Simple heating	
High temperature heating	Protein structural unfolding
Microwave	
Autoclave	
Mechanical forces	Unfolding and aggregation
Ultrasound treatment	
Pressure (cooker)	

TABLE 5: Advantages and disadvantages of some embedding resins.

Embedding resins	*Advantages*	*Disadvantages*
Acrylic	• Water compatible • Low temperature is required hence stabilizes antigen • Background labeling is reduced	• Tissue shrinkages • Weak adherence between acrylic resins and tissues
Epoxy resins	• Uniform polymerization • Best morphological tissue pressure and reliable immunostaining	• Highly hygroscopic • Occasionally decreased immunolabeling intensity

JAYPEE BROTHE

❖ *Postanalytic:*
- Assessment of control performance
- Description of results
- Interpretation of results and reporting of results

- Pathologist—experience and participation certificate in Continuing Medical Education (CME) specific to IHC.

TABLE 7: Immunohistochemistry (IHC) in solid tumors.

IHC marker	*Cellular localization*	*Normal tissues stained*	*Use in tumor diagnosis*
Alpha-fetoprotein (AFP)	Cytoplasmic	Fetal liver	• Yolk sac tumor (testes, ovary, etc.) • Hepatocellular carcinoma except fibrolamellar variant
Anaplastic lymphoma kinase (ALK)	Nuclear, cytoplasmic, membranous	Few neuronal cells	• Inflammatory myofibroblastic tumors • Anaplastic large cell lymphoma (ALCL) • Adenocarcinoma of lung with EML4-ALK rearrangement
AMACR (alpha-methylacyl-CoA reductase)	Cytoplasmic	Prostatic cancer (CA) and PIN (normal prostate is –)	• Prostate cancer and PIN is positive • In other CA, it may be positive such as lung, breast, papillary RCC, and clear cell adenocarcinoma of bladder
Androgen receptor (AR)	Nuclear	Prostate, normal apocrine glands	• Salivary duct carcinoma • Juvenile nasopharyngeal angiofibroma
Arginase-1	Cytoplasmic	Normal hepatocytes	Marker for hepatocellular differentiation and positive for HCC
Alpha-thalassemia mental retardation syndrome (ATRX)	Nuclear	Brain/CNS	• Astrocytoma ATRX–, P53+, no 1p/19q co-deletion • Oligodendroglioma ATRX+, P53–, 1p/19q co-deletion
BAP1	Nuclear	All normal cells	In mesothelioma, it is lost vs. benign mesothelial proliferations (retained)
Beta-catenin	Nuclear staining is significant only	Cytoplasm of most cells, endothelial cells serve as good internal positive control	• Colon CA, craniopharyngioma, hepatoblastoma, pancreatoblastoma, pancreatic solid- pseudopapillary neoplasm • FAP associated tumors, nasal angiofibroma, fundic gland polyps, cribriform-morular variant of papillary thyroid CA
B cell lymphoma 2 (Bcl-2)	Membranous and cytoplasmic	Normally present in mantle cell. It inhibits apoptosis	• Follicular lymphoma (+) vs. reactive follicles (–) • Synovial sarcoma and some CD34+ tumors like GIST, SFT
Bcl-10	Cytoplasmic	Pancreas	• Pancreatic acinar cell CA • MALT lymphoma
Brachyury	Nuclear	Expressed in some normal spermatogonia	• Chordoma • Hemangioblastoma
CA IX (Carbonic anhydrase)	Membranous	Ischemic tissues	• Clear cell RCC (diffuse CAIX is very sensitive and specific for CCRCC) • Clear cell papillary RCC **(cup-like staining)**
CA-125	Luminal	Many cell types	Serum marker for ovarian cancer (epithelial malignancies)
CA19-9	Cytoplasmic	Many call types	Serum marker for monitoring pancreatic and GI cancers.
Calcitonin	Cytoplasmic and extracellular	C cells of thyroid	Medullary CA of thyroid
Caldesmon (H-caldesmon)	Cytoplasmic	Smooth muscle and myoepithelial cells	Leiomyosarcoma (+) vs. fibromatosis (–)
Calponin	Cytoplasmic	Smooth muscle and myoepithelial cells, variable in myofibroblasts	Positive in smooth muscle tumor and myoepithelial (same as α actin)
Calretinin	Cytoplasmic and nuclear	Mesothelium, sex- cord stromal cells, some neural and epithelial cells	• Mesothelioma • Sex-cord stromal tumors • Adrenocortical tumors, Olfactory neuroblastoma, adenomatoid tumor, cardiac myxoma

Continued

JAYPEE BROTHERS

Continued

IHC marker	Cellular localization	Normal tissues stained	Use in tumor diagnosis
CD1a	Membranous	Langerhans cells Thymocytes (immature T cells)	• Langerhans cell histiocytosis • Thymocytes in thymoma (CD1a, TdT, CD99+)
CD5	Membranous	T cells and naïve B cells	• CLL/SLL and mantle cell lymphoma • Thymic carcinoma (+ in epithelial cells) • Thyroid CASTLE (+ in epithelial cells)
CD10 or common acute lymphoblastic leukemia antigen (CALLA)	Membranous	Precursor B and T cells, germinal center B cells, liver canaliculi, endometrial stroma	• CD10(+) lymphoma: B-ALL > T-ALL, Follicular lymphoma, Burkitt lymphoma, HCC (+canalicular pattern) vs. cholangiocarcinoma (–) • Sex-cord stromal tumors • Endometrial stromal sarcoma
CD15	Membranous and Golgi (para-nuclear dot-like)	Endothelial cells monocytes, myelocytes granulocytes	• Adenocarcinoma (+) vs. mesothelioma (–) • RS cells in classic Hodgkin lymphoma
CD30 (Ki-1)	Membranous And Golgi (Paranucl-ear dot-like)	Activated B (immunoblasts) and T lymphocytes, plasma cells	• Embryonal carcinoma (+) vs. others germ cell tumor (–) • RS cells in classic Hodgkin lymphoma, ALCL
CD31	Cytoplasmic and membranous	Endothelial cells, megakaryocytes, macrophages	Angiosarcoma, Kaposi sarcoma
CD34	Cytoplasmic and membranous	Endothelial cells, hematopoietic stem cells (blast cells)	• Vascular tumors (angiosarcoma, Kaposi, etc.) • DFSP (+) vs. dermatofibroma (–) • GIST (70%+) vs. fibromatosis (–) • SFT (strong and diffuse+) vs. synovial sarcoma (–) • Epithelioid sarcoma (50%+) • Adipocytic tumors
CD56 [neural cell adhesion molecule (NCAM)]	Membranous	NK cell; Schwann cell, Neuroendocrine cell	• Nasal type NK/T cell lymphoma and neoplastic plasma cells • Neuroendocrine neoplasms particularly SmCC
CD57	Membranous	NK-like T cells, Schwann cells, neuroendocrine cells	• T cell large granular cell leukemia and T-Cell "rosettes" surrounding LP Cells and NLP-HL • Metanephric adenoma of the kidney
CD68	Cytoplasmic, membranous	Histiocytes, Macrophages	• Histiocytic differentiation • Fibrolamellar carcinoma
CD146	Membranous	Intermediate trophoblast	• *Tumors of implantation site intermediate trophoblast*: Exaggerated placental site and placental site trophoblastic tumor • Choriocarcinoma • Melanoma
CDH17	Membranous	Tubular GI tract	Recent marker of adenocarcinoma of lower GI tract, even retained in poorly differentiated adenocarcinoma
Cyclin dependent kinase 4 (CDK4)	Nuclear	Dividing cells	Well and dedifferentiated liposarcoma (CDK4, MDM2+) vs. benign adipocytic tumors (–)
CDX2	Nuclear	Intestine (from duodenum to rectum, appendix)	Strong and diffuse expression in intestinal CA
Carcinoembryonic antigen (CEA)	Cytoplasmic	Glandular epithelium and fetal tissues	• Adenocarcinoma (mCEA+) vs. mesothelioma (mCEA–) • HCC (Canalicular pCEA) • Medullary thyroid CA • mCEA or monoclonal CEA • Adenocarcinoma in general (colon, lung, and pancreas)

Continued

JAYPEE BROTHERS

Continued

IHC marker	*Cellular localization*	*Normal tissues stained*	*Use in tumor diagnosis*
c-KIT (CD117)	Cytoplasmic and membranous	Interstitial cells of Cajal, germ cells	• GIST (95%, diffuse staining) vs. leiomyoma (–) • Thymic carcinoma (+) vs. thymoma (–) • Seminoma(+membranous) • Chromophobe RCC and oncocytoma • Mast cell lesions • Sclerosing mesenteritis
Cytokeratin (i) AE 1/AE3 (Pancyto-keratin cocktail)	Cytoplasmic	Most epithelial cells	All carcinomas except HCC, RCC, and adrenocortical carcinoma
(ii) CK7	Cytoplasmic	LMW cytokeratin	CK7 is usually positive in above the diaphragm carcinomas (lung, breast, and thyroid) and GyN organs
(iii) CK20	Cytoplasmic	LMW cytokeratin	• CK20 is usually positive in below—the diaphragm carcinomas (Colon) and Merkel cell CA • CK7 and CK20 both are positive in peridiaphragmatic organs (stomach, pancreas) and urinary bladder • CK7 and CK20 both are negative in simple visceral organs (liver, kidney, and prostate) • CK7: Barret mucosa (+) vs. intestinal metaplasia in stomach cardia • CK20: Urothelial CIS (+in all layers) vs. reactive urothelium (+ in umbrella cell layer)
(iv) CK5/6	Cytoplasmic	HMW keratins	Squamous cell carcinoma (+), mesothelioma (+) vs. adenocarcinoma (–)
(v) Cyclin D1 (Bcl-1)	Nuclear	Dividing cells	• Mantle cell lymphoma • *Sarcomas*: BCOR-rearranged sarcoma, clear cell sarcoma of the kidney
Desmin	Cytoplasmic	Intermediate filament in smooth, striated and cardiac muscle	• Smooth, skeletal muscle differentiation in tumors • Reactive mesothelial cell (+) vs. mesothelioma (–)
D2-40 (Podoplanin)	Membranous	Marker of mesothelial cells, lymphatic endothelial cells, germ cells	• Mesothelioma (+) vs. adenocarcinoma (–) • Hemangioblastoma (+) vs. RCC (–) • Primary skin adnexal tumor (+) vs. metastatic adenocarcinoma (–) • Dermatofibroma (+) vs. DFSP (–) • Seminoma (100%+)
DPC-4 (Deleted in pancreatic carcinoma)	Nuclear and cytoplasmic	Most normal tissues	• Loss of expression in pancreatic cancer (55%) • Both nuclear and cytoplasmic • Staining must be negative to count
Discovered on GIST-1 (DOG1)	Membranous and cytoplasmic	Interstitial cells of Cajal	• GIST (better than c-KIT) • Acinic cell carcinoma of salivary gland
E-cadherin	Membranous	Normal ductal and lobular cells or breast	• In situ and invasive lobular carcinoma (–) vs. ductal lesions (+) • Pancreatic NET (+) and acinar cell carcinoma (+) vs. solid pseudopapillary neoplasm (–) • Loss of expression also seen in pancreatic • undifferentiated CA and gastric signet ring CA
Epithelial membrane antigen (EMA) (MUC1)	Cytoplasmic or membranous	Epithelial, perineurial, meningothelial cells	• Carcinoma in general, synovial sarcoma, epithelioid sarcoma, chordoma, ALCL, plasma cell neoplasms, LP cells in NLP-HL • Mesothelioma (+) vs. adenocarcinoma (–)

Continued

JAYPEE BROTHERS

Continued

IHC marker	*Cellular localization*	*Normal tissues stained*	*Use in tumor diagnosis*
ER and PR	Nuclear	Breast, ovary, endometrium	• Breast CA (60%) • Uterus and ovarian tumor (endometroid) • Skin adnexal tumor, meningioma (PR+) • PanNET (PR+), pancreatic solid pseudopapillary neoplasm (+)
ERG (ETS-related gene)	Nuclear	Endothelial cells	Sensitive and specific marker of vascular tumors (angiosarcoma, Kaposi sarcoma, epithelioid hemangioendothelioma)
ETV4 (ETS translocation variant-4)	Nuclear	Transcription factor	Round cell sarcoma with CIC rearrangement
Fumarate hydrase (FH)	Cytoplasmic	Kreb cycle enzyme, expressed in all normal epithelial cells	• Hereditary leiomyomatosis and RCC (HLRCC) **loss** by IHC • FH **loss in uterine leiomyoma**
Friend leukemia integration 1 (FLI-1)	Nuclear	Endothelial cells, many other cells	• Ewing sarcoma with EWSR1-FLI1 translocation • Endothelial differentiation
Forkhead box L2 (FOXL2)	Nuclear	Ovarian granulosa cells	• Ovarian sex cord stromal tumors and some testicular granulosa cell tumors • Pituitary adenoma
GAB1	Cytoplasmic	Near ubiquitous expression	Used in conjunction with YAPI and β-catenin
GATA3	Nuclear	Breast, bladder, placental trophoblast	• Breast CA (>90%) • Almost all urothelial carcinoma • Salivary gland and skin adnexal tumors (especially apocrine) • Trophoblastic tumors especially choriocarcinoma • Parathyroid neoplasms
Gross cystic disease fluid protein-15 (GCDFP-15)	Cytoplasmic	Apocrine cells of the breast and sweat glands	• Breast CA (stains lobular carcinoma best) • *Tumors with apocrine differentiation*: Tumors of salivary gland (especially salivary duct carcinoma) and skin adnexa
GFAP	Cytoplasmic	Glial, myoepithelial, and Schwann cells	Glioma (astrocytoma, ependymoma) myoepithelial neoplasms, some schwannomas
GLUT1 (glucose transporter 1)	Membranous	RBCs and many tissues	• Thymic carcinoma (+) vs. thymoma (–) • Mesothelioma (+) vs. reactive mesothelioma (–)
Glypican-3	Cytoplasmic, membranous, and canalicular	Placenta, (syncytiotrophoblast s), embryonic liver	• HCC and hepatoblastoma • Yolk sac tumor • HCC (+) vs. benign hepatic nodule (–)
GRIA2	Cytoplasmic	CNS, skin epithelium, etc.	• Solitary fibrous tumor • Or SFT (New Marker)
HepPar-1	Granular cytoplasmic	Mitochondria in normal hepatocytes	HCC and hepatoblastoma
HER2 (HER2/neu)	Membranous and cytoplasmic	Growth factor receptor which is only weakly expressed	• Overexpression in breast • Carcinoma is a poor prognostic sign
HMB-45 (human melanoma black)	Cytoplasmic	Immature melanocytes	• Melanoma (epithelioid > spindle cell) • Clear cell sarcoma/melanoma of soft parts, melanotic schwannoma, PEComa group tumors, e.g., sugar tumor of lung angiomyolipoma, lymphangioleiomyomatosis • Melanoma vs. nevus
HNF-1B	Nuclear	Hepatocytes	Clear cell carcinoma of urinary bladder and gynecological tract
HSP70 (heat shock protein 70)	Nuclear	Ubiquitous stress induced	HCC (+) vs. FNH (–) and benign hepatocellular nodule (–)

Continued

JAYPEE BROTHERS

Continued

IHC marker	*Cellular localization*	*Normal tissues stained*	*Use in tumor diagnosis*
Human chorionic gonadotropin (HCG +, β chain)	Cytoplasmic	Syncytiotrophoblasts	• Choriocarcinoma, embryonal carcinoma • Seminoma (in syncytiotrophoblastic giant cells)
Human placental lactogen	Cytoplasmic	Trophoblastic	Choriocarcinoma, placental site tumors (tumors of intermediate trophoblasts)
IDH1 RI32H (isocitrate dehydrogenase 1)	Nuclear	Mutated form of IDH1 which is specific for high grade gliomas	Used to diagnose, classify, and prognostic stratification of high-grade gliomas
Immunoglobulin (Ig) G4	Cytoplasmic	Subset of plasma cells	Disease wherein Ig4+ plasma cells are increased, e.g., chronic sclerosing sialadenitis (Kuttner tumor), autoimmune pancreatitis, and sclerosing mesenteritis
Inhibin	Cytoplasmic	Granulosa cells sertoli cells, trophoblasts, adrenal cortical cells	• Granulosa cell tumor, Sertoli- Leydig cell tumor • Hemangioblastoma • Adrenocortical tumor • Granular cell tumor
INT1	Nuclear	Expressed in normal tissues	• Loss of expression (due to gene deletion) in AT/RT, rhabdoid tumor of the kidney, epithelioid sarcoma, epithelioid MPNST • Medullary carcinoma of kidney
INSM1 (Insulinoma associated protein 1)	Nuclear	Neuroendocrine and neural tissues	New marker which is highly sensitive and specific for neuroendocrine differentiation
Ki-67	Nuclear	Any proliferating cell	To gauge mitotic activity for prognosis and classification of some tumors
LEF1 (Lymphoid enhancer binding factor 1)	Nuclear	T Cells and immature pro B cells but not in normal mature B cells	• Basal cell adenoma and basal cell adenocarcinoma of the salivary gland • CLL/SLL
LIN28A	Cytoplasmic	Highly expressed in testis, and human embryonic stem cells	New marker positive in ETMRs (embryonal tumors with multilayered rosettes)
Mammaglobin	Cytoplasmic	Breast epithelium sweat glands	Breast CA (60%) sweat gland tumors, tumors with apocrine differentiation
MART-1	Cytoplasmic	Melanocytes	Melanoma marker (more sensitive than HMB-45)
MDM2 (murine double minute 2)	Nuclear	Oncoprotein	• Well-differentiated liposarcoma • De-differentiated liposarcoma • Low grade osteosarcoma
Melan A (MART 1)	Cytoplasmic	Melanocytes	Melanoma (epithelioid> spindle cells), more sensitive than HMB-45
MLH1, MSH2, MSH6PM S2	Nuclear	DNA mismatch repair (*MMR*) gene is present in most tumor cells, loss of expression due to mutation lead to microsatellite instability (MSI)	Loss of MLH1 is more commonly sporadic whereas loss of MSH2, MSH6, or PMS2 is nearly diagnostic of Lynch syndrome
MUC4	Cytoplasmic	Some glandular epithelial cells express it on surface (transmembrane glycoprotein)	• Low grade fibromyxoid sarcoma • Subset of sclerosis epithelioid fibrosarcoma with *FUS* gene rearrangement • Lung adenocarcinoma or SCC (+) vs. mesothelioma (–)
MyoD1 and myogenin	Nuclear	Transcription factors in regenerating but not in normal skeletal muscle	It is negative in rhabdomyoma like normal mature skeletal muscle but + in rhabdomyosarcoma

Continued

JAYPEE BROTHERS

Continued

IHC marker	*Cellular localization*	*Normal tissues stained*	*Use in tumor diagnosis*
NANOG	Nuclear	Germline stem cells within testis (developing)	Seminoma and embryonal carcinoma (+) vs. spermatocytic seminoma and other
Napsin A	Cytoplasmic (granular)	Preunocytes and renal tubular epithelial cells	• Lung adenocarcinoma • RCC (papillary and clear cell variant • Clear cell carcinoma of GYN tract (100%)
NeuN	Nuclear	Neurons	Neuronal/ganglion cell neoplasms
NSE (neuron specific enolase)	Cytoplasmic	Neuroendocrine cells and neuroectodermal cells	Neuroendocrine and neural different NSE is sensitive for neuroblastoma
NKX 2.2	Nuclear	Highest in brain; GI and GU	New IHC marker for soft tissue and sinonasal Ewing Sarcoma (+)
NKX 3.2	Nuclear	Prostatic tissue (exclusive)	Most sensitive and specific mark for prostatic adenocarcinoma (new marker)
OCT4 (OCT 3/4)	Nuclear	Absent in normal	Seminoma/dysgerminoma, embryonal carcinoma vs. yolk sac tumor (–)
p16	Nuclear and cytoplasmic	Cell with inactivated PRb	• Positive in HPV SCC: SCC, cervix, tonsil/nasopharynx, anus • Serous carcinoma of GYN tract (+) vs. endometroid carcinoma (–)
p40	Nuclear	Variant of P63	• It has the same sensitivity as P63 but more specific • Lung SCC (+) vs. adenocarcinoma (–) • Positive in SCC of any site myoepithelial, basal, and urothelial
p53	Nuclear	Tumor suppressor gene	• Aberrant P53 (mutation) seen in many tumors • Serous carcinoma of endometrium (+) vs. endometroid carcinoma (wild type) • Urothelial carcinoma in situ (+) vs. reactive urothelium • Subset of astrocytoma (+) vs. oligodendroglioma
p57	Nuclear	Trophoblasts	• This gene is paternally imprinted • Partial mole (+) vs. complete mole (–)
p120	Membranous and cytoplasmic	E-cadherin binding protein in breast epithelium	Ductal carcinoma of breast (membranous p120) vs. lobular carcinoma (strong cytoplasmic p120)
Parafibromin	Nuclear	Protein product of tumor suppressor gene *HRPT2*	Loss of expression seen in parathyroid adenomas and parathyroid carcinomas
PAX8 (paired box gene 8)	Nuclear	Normal thyroid follicles, renal epithelial cells, thymic epithelium, Müllerian tissue	• Thyroid CA (follicular origin, most anaplastic carcinomas, negative in medullary carcinoma) • Pan RCC and renal cortical neoplasm • Pan-Müllerian marker (endometrial, endocervical, ovarian) • Pancreatic NETs
PDL1 (programmed death ligand 1)	Membranous	Antigen presenting cells (dendritic cells macrophages)	Predictive marker. Predictive of better response to PD-1 and PDL1 targeted agents
PHOX2B **(new marker)**	Nuclear	Adrenal gland	Neuroblastoma, pheochromocytoma/paraganglioma
Placental alkaline phosphatase (PLAP)	Cytoplasmic	Placenta	Germ cell tumors (negative in spermatocytic seminoma and teratoma)
Prostein	Cytoplasmic (perinuclear dots pattern)	Prostatic epithelium	Prostatic carcinoma. One of the newer prostate markers like NKX3.1 (with high sensitivity and specificity)
PSA (prostatic specific antigen)	Cytoplasmic	Prostatic and salivary gland epithelium	• Prostatic carcinoma • Benign and neoplastic salivary gland duct epithelium (pleomorphic adenoma, mucoepidermoid carcinoma)

Continued

JAYPEE BROTHERS

Continued

IHC marker	Cellular localization	Normal tissues stained	Use in tumor diagnosis
PSMA (prostate specific membrane antigen)	Cytoplasmic membranous	Prostatic epithelium, urothelium	Prostatic carcinoma (remember in contrast to PSA and PSAP), expression does not decrease with tumor grade
S100 (solubility in 100% ammonium sulfate)	Nuclear and cytoplasmic	Schwann cells, melanocytes, histiocytes, Langerhans cell, dendritic, myoepithelial cells	• *Melanocyte*: Melanoma, nevi • *Histiocytes*: Langerhans cell histiocytosis, Rosai Dorfman, histiocytic sarcoma • *Myoepithelial cells*: Myoepithelioma, myoepithelial carcinoma • *Soft tissue*: Lipomatous tumor, chordoma, chondrosarcoma, clear cell sarcoma • *Others*: Granular cell tumor, olfactory neuroblastoma, sustentacular cells in pheochromocytoma
SALL4 (Sal-like protein 4)	Nuclear	Embryonic stem cells	Pan-GCT marker, including spermatocytic tumor
SDHB (succinate dehydrogenase B)	Cytoplasmic	All normal eukaryotic cells	• SDH deficient RCC • SDH deficient GIST (mainly pediatric) • Subset of pheochromocytoma
Smoothelin	Cytoplasmic	Terminally differentiated smooth muscle	Muscularis propria of urinary bladder (+) vs. Muscularis mucosae (negative/weak) to assess invasion and the depth of invasion
SOX2	Nuclear	Fetal CNS Tissue	• SCC of any site • Embryonal carcinoma • Immature component in CNS immature teratoma
SOX9	Nuclear	Normal cartilage	Cartilaginous differentiation (mesenchymal chondrosarcoma)

SOX10	Nuclear	Schwann cells, melanocytes, myoepithelial cells	• Marker of triple negative breast CA
			• SOX10 like S100, is marker of neural crest derived tumor
			  ○ Like S100 melanomas, nerve sheath the granular cell tumor, gliomas
			  ○ *Unlike S100*: Negative in fibrohistiocytic tumor, biphenotypical sinonasal sarcoma, synovial sarcoma

STAT6	Nuclear	Transcription factor	Solitary fibrous tumor (SFT)
Synaptophysin	Cytoplasmic	Neuroendocrine cells, Merkel cells, neuronal cells	Neuroendocrine neoplasms (carcinoid/NET, SmCC, Merkel cell carcinoma, medullary carcinoma of pheochromocytoma)
TdT	Nuclear	Immature B and T lymphocytes	• Precursor B and T leukemia/lymphoma vs. lymphoma of mature cells (–) • Thymoma
TFE3 (transcription factor E 3)	Nuclear	Transcription factor	• Xp11 translocation RCC • Granular cell tumor • Alveolar soft part sarcoma
TEE B (transcription factor E B)	Nuclear	Transcription factor	t(6:11) translocation RCC
Thyroglobulin	Cytoplasmic	Thyroid follicles	Differentiated or well differentiated carcinomas of thyroid (papillary and follicular). Remember medullary and anaplastic carcinomas are negative
TLE1	Nuclear	Transcription factor	• BCOR-rearranged sarcoma (+/–) • Synovial sarcoma
TTF1 (thyroid transcription factor 1)	Nuclear	Developmental transcription factor	Thyroid carcinoma; papillary, follicular and medullary carcinoma (+) vs. anaplastic carcinoma (–)
Vilin	Cytoplasmic (brush border pattern)	Enterocytes	• Colorectal CA • HCC (canalicular pattern)

Continued

JAYPEE BROTHERS

Continued

IHC marker	*Cellular localization*	*Normal tissues stained*	*Use in tumor diagnosis*
Vimentin	Cytoplasmic	Most mesenchymal cells	Sarcoma, melanoma (+) vs. carcinoma and glioma (–)
WT1	Nuclear	Tumor suppressor Gene	• Wilms tumor, mesothelioma, ovarian serous carcinoma • CIC rearranged sarcomas • Desmoplastic small round cell tumor
YAP1	Nuclear	Transcriptional regulator of cell proliferation	Used to molecular subtype of medulloblastoma

Abbreviations: ALK, anaplastic lymphoma kinase; AT/RT, atypical teratoid/rhabdoid tumor; CASTLE, carcinoma showing thymus-like differentiation; CIC, capicua; CIS, carcinoma in situ; CLL, chronic lymphocytic leukemia; CNS, central nervous system; DFSP, dermatofibrosarcoma protuberans; DNA, deoxyribonucleic acid; EML4, echinoderm microtubule-associated protein-like 4; ER/PR, estrogen receptor/progesterone receptor; EWS, Ewing's sarcoma; FAP, familial adenomatous polyposis; FNH, focal nodular hyperplasia; GI, gastrointestinal; GIST, gastrointestinal stromal tumors; HCC, hepatocellular carcinoma; HPV, human papillomavirus; IHC, immunohistochemistry; LMW, low molecular weight; LP, lymphocyte-predominant; MALT, mucosa-associated lymphoid tissue; MDMT, murine double minute type 2; MMR, mismatch repair; MPNST, malignant peripheral nerve sheath tumor; MUC4, mucin 4; NK, natural killer; NLPHL, nodular lymphocyte-predominant Hodgkin lymphoma; PanNET, pancreatic neuroendocrine tumors; PIN, prostatic intraepithelial neoplasia; PRb, retinoblastoma protein; RBC, red blood cell; RCC, renal cell carcinoma; RS, Reed–Sternberg; SCC, squamous cell carcinoma; SDH, succinate dehydrogenase; SFT, solitary fibrous tumors; SLL, small lymphocytic lymphoma; SmCC, small cell carcinoma.

TABLE 8: Pattern of staining of some immunohistochemistry (IHC) markers (cellular location).

Cell membrane	*Cytoplasm*	*Nuclear*	*Both/multiple*
Most cluster differentiation (CD) markers, HER-2/neu, E-cadherin, EMA, MOC31 (basolateral surface), thrombomodulin	Actin, alkaline phosphatase, α-amylase, AFP, B72.3, Ber-EP4, β-catenin (in urothelial tumor), CA19-9, CA125, Calponin, Caldesmon, Calretinin, CEA, Caveolin-1, Chromogranin, Cyclooxygenase 2 (Cox2), cytokeratin, Desmin, GFAP, Heat shock proteins, HepPar-1, HMB-45, hCG, Inhibin, Mart-1 (Melan-A) MUC, Napsin A, Osteocalcin, osteonectin, Osteopontin, Podoplanin (D2-40), PSA, Prostatic acid phosphatase (PAP), Synaptophysin, Thyroglobulin, Uroplakin II and III, Vimentin, Arginase1	β-catenin (in fibromatosis), CDX2, FLI-1, human herpes virus type 8, hMLH1 and hMLH2, MDM2, Mib-1 (Ki-67), Brachyury, MyoD1, Myogenin, NANO G, OCT3/4, PAX2, 5 and 8, SALL4, SOX2, 9 and 10, TTF-1, WT-1, GATA-3, SATB2	ALK (nuclear or cytoplasmic), Galectin (nuclear and cytoplasmic), Glypican 3 (cytoplasmic and membrane). Hu (nuclei and cytoplasm), Notch 1 (nuclear and cytoplasmic), S100 (cytoplasmic and nuclear), VEGF (nuclear membrane, cytoplasmic, cytoplasmic membrane)

Abbreviations: ALK, anaplastic lymphoma kinase; AFP, alpha fetoprotein; CEA, carcinoembryonic antigen; EMA, epithelial membrane antigen; GFAP, glial fibrillary acidic protein; HMB, human melanoma black; hCG, human chorionic gonadotropin; MDM2, murine double minute type 2; SALL4, SAL-like protein 4; TTF-1, thyroid transcription factor1; VEGF, vascular endothelial growth factor.

INTERPRETATION OF IMMUNOHISTOCHEMISTRY

1. Number of immunoreactive cells:

It depends upon the nature of antigen under investigation and the lesion. A percentage of positive cells (stained by IHC immunomarker) should be given in the test result and most IHC laboratories do it. As, e.g., when reporting ER (estrogen receptor) or progesterone receptor (PR) in breast carcinoma, the pathologist should not only report as positive (nuclear stain) or negative but also the percentage of cells showing positivity (e.g., 60% of tumor cells). In some IHC markers, there is a cutoff value of percentage of positive cells. As e.g., for HER2/neu or Cerb2 reporting in breast carcinoma, a cutoff value of 10% positively stained tumor cells is considered test result positive. Likewise, for Ki-67(MIB2) cutoff value is ≥20% (10–20% is borderline). If only some of the cells are positive, then it is focal and most of the cells are positive (50–80%) then it is "diffuse."

2. Intensity:

- Weak (mild)
- Intermediate (moderate)
- Strong

3. Pattern of staining (cellular location):

- Cellular:
  - *Nuclear staining*: ER, PR, MyoD1, TTF1, p53
  - *Cytoplasmic staining*: Cytokeratin, thyroglobulin, synaptophysin
  - *Cell membrane*: Most CD markers, EMA, HER2/neu

False Positive Signals in Immunohistochemistry

The most common causes of falsepositive signals in IHC preparations include nonspecific background staining/signal, endogenous peroxidase, the use of inappropriately high antibody concentrations pigment mistaken for

JAYPEE BROTHERS

true signal, endogenous biotin, drying artifact, and "pseudospecific" signal. Out of these factors, three of them (common problems) will be discussed here.

High nonspecific background generally represents the binding of antibodies by mechanisms other than specific binding of their epitope on the target antigen. This signal can be usually blocked with any protein which does not have an affinity for the target or program components. Normal serum bovine serum almond, gelatin, and dry milk are generally good blocking agents.

Inappropriately *high antibody concentrations* result falsepositive cases in some tumors. As, e.g., papillary lung carcinoma which is known not to express the transcription factor (PAX8) in question, can develop significant nuclear signal by just inappropriately increasing the primary antibody concentration.

A *"pseudospecific" signal* is one which is characterized by a signal that is usually quite restricted in distribution within a cell but actually represents a falsepositive signal. Most of the commonly used immunomarkers in diagnostic surgical pathology have well-defined subcellular localization. As, e.g., with rare exceptions, nuclear factors such as PAX8, CDX2, and TTF1 are found exclusively in the nuclei, IHC marker like chromogranin A and GP100 (the target of antibody HMB-45) localize the granular structure within cell and tumor cytoplasm, in dense core granules (*chromogranin* A) and premelanosomes (GP100), respectively. Pseudospecific signals generally identified by the inappropriate subcellular localization of the signal with the antibodies of synaptophysin should be recognized easily as a falsepositive signal. However, rarely, pseudospecific signals occurring in the same cell compartment may occur. As, e.g., proven progesteronenegative tumor cells may show "pseudospecific" falsepositive cases nuclear signals using the SP2 anti-progesterone receptor monoclonal antibody.

False Negative Signals in Immunohistochemistry

The common causes of false negative immunostaining are poor tissue fixation, antibodies too dilute or not properly optimized, and epitope retrieval method not optimized for individual antibodies. Many laboratories reported such falsenegative immunostaining due to inappropriate calibration and optimization of pan keratin and antilow-molecular weight keratin antibodies. Epitope retrieval buffers, pH, and optimal protocols are important to eliminate falsenegative immunostaining.

JAYPEE BROTHERS

for detailed information on pathology books, visit our website www.jaypeebrothers.com, for detailed information on pathology books, visit our website www.jaypeebrothe

MANUAL OF HISTOLOGICAL TECHNIQUES

Salient Features

- The latest third edition of "Manual of Histological Techniques" is a compilation of the basics and latest advances in this rapidly evolving field of histological techniques.
- Chapters on Molecular Genetics (NGS, SNP, array comparative genomic hybridization or aCGH, DNA sequencing, etc.) are added. Also, genetic alteration in different tumors has been included.
- Chapter on Immunohistochemistry (IHC) has been thoroughly revised. For quick revision, IHC markers have been added in a tabular form.
- Important tumor syndromes associated with different organs have been added in a tabular form along with genetic changes and pathologic features.
- Two new chapters on Digital Pathology and Laboratory Waste Disposal have been added.
- Chapter on Immunofluorescence and FISH are revised and many colored photographs are added. Quality Control in Histopathology has been revised as per NABL requirement of latest ISO 15189: 2022.
- Many colored and BW photographs, tables, and charts have been added for easy understanding.
- This book is meant for faculties of pathology, consultant/specialist histopathologist, MD pathology (PGT), students of DCP, BSc MLT, DMLT, etc.



Santosh Kumar Mondal is currently Professor and Head of Pathology at the All India Institute of Medical Sciences (AIIMS), Kalyani, West Bengal, India. He was Professor and Head of Pathology at Diamond Harbour Medical College, West Bengal, and Professor of Bankura Sammilani Medical College, West Bengal. He obtained MBBS degree from North Bengal Medical College in 1994 and MD (Pathology) from SSKM Hospital, West Bengal, in 2000. He received post-MD training in oncopathology at Tata Memorial Hospital, Mumbai. He has UG and PG teaching experience of 22 years. He has acted as both external and internal examiner of various examinations such as MD (Pathology), DCP, MBBS, BSc MLT, DMLT, etc. He is NABL Assessor and part of Quality Council of India. He has many funded extramural and intramural projects as PI or co-PI. He has published 85 articles in different indexed international and national journals and these publications have 1,705 citations. Besides, he has been selected as a reviewer of many national and international journals. He is a Speaker in different national and international conferences/CMEs/workshops. He is the author of three medical books as single author.

Printed in India

Available at all medical bookstores or buy online at www.ejaypee.com

JAYPEE BROTHERS
Medical Publishers (P) Ltd.
EMCA House, 23/23-B, Ansari Road,
Daryaganj, New Delhi - 110 002, INDIA
www.jaypeebrothers.com

Join us on facebook.com/JaypeeMedicalPublishers
Follow us on instagram.com/JaypeeMedicalPublishers

Shelving Recommendation
PATHOLOGY

ISBN 978-93-6616-670-4