tomy books, visit our website www.jaypeebrothers.com, for detailed information on anatomy books, visit our website www.jaypeebrothers.com, for detailed information on anatomy books

Complimentary Online
Dissection & Model Videos
107 Videos (Duration 3 hours)
only with Genuine Book

diginerve®
A Jaypee Initiative
• Video Lectures • Dr. Wise AI Chatbot
• Question Bank • Notes
Download App

Volume 3

Dissection Manual

With Regions & Applied Anatomy

Head, Neck and Brain

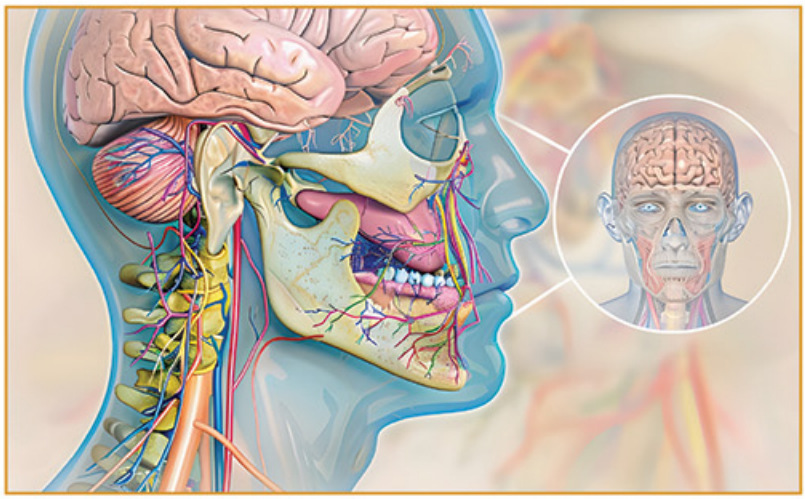



Mercy Navis

Forewords KS Ravindranath • Sriprakash KS

2nd Edition

JAYPEE

CONTENTS

SECTION 1 Head and Neck

Chapter 1 Osteology of Head and Neck 3

- Skull 3
- Bones of Face 8
- Hyoid Bone 12
- Ear Ossicles 12
- Mandible 12
- Cervical Vertebrae 13

Chapter 2 Scalp 16

- Landmarks 16
- Skin Incision 16
- Layers of Scalp 16
- Nerves of the Scalp 17
- Epicranial Aponeurosis 19

Chapter 3 Face 20

- Landmarks 20
- Nose 20
- Mouth 20
- Mandible 21
- Zygomatic Arch 21
- Orbit 21
- Skin Incision 21
- Muscles of the Face 21
- Sensory Nerve Supply of Face 25
- Motor Nerve Supply of the Face 27
- Blood Supply of Face 28
- Veins of the Face 29

Related Videos *(See Page xxi)*

1. Muscles and Nerves of the Face
2. Facial Artery and Vein
3. Facial Nerve and Branches
4. Dissection Video of the Reflection of the Skin
5. Platysma

Chapter 4 Tarsal Plates and Lacrimal Apparatus 30

- Landmarks 30
- Orbital Septum and Tarsal Plates 30
- Lacrimal Apparatus 31
- Nerve Supply of the Lacrimal Gland 32

Chapter 5 Posterior Cervical Triangle of Neck 33

- Landmarks 33
- Skin Incison 33
- Boundaries of Posterior Triangle 36
- Muscles 38
- Nerves 39
- Upper Trunk of Brachial Plexus 41
- Arteries 42
- Important Tips about Posterior Cervical Triangle 42

Chapter 6 Suboccipital Region 43

- Landmarks 43
- Muscles at the Back of Neck 43
- Suboccipital Triangle 45

Related Videos *(See Page xxi-xxii)*

6. External Jugular Vein and Great Auricular Nerve
7. Boundaries of the Posterior Triangle
8. Floor Muscles of the Posterior Triangle
9. Contents of the Posterior Triangle

Chapter 7 Anterior Cervical Triangle 48

- Landmarks 48
- Anterior Cervical Triangle 48
- Submental Triangle 50
- Submandibular (Digastric) Triangle 51
- Carotid Triangle 52
- Muscular Triangle 54

Related Videos *(See Page xxii-xxiii)*

10. Anterior Triangle
11. Carotid Triangle
12. Common Carotid Artery and Sympathetic Trunk
13. Mylohyoid and Digastric
14. Infrahyoid Muscles
15. Anterior and Posterior Triangles

Chapter 8 Parotid Region 57

- Landmarks 57
- Parotid Gland 57

Related Video *(See Page xxiii)*

16. Parotid Region

Chapter 9 Temporal and Infratemporal Fossa 60
- Landmarks 60
- Temporal Region 61
- Masseter 62
- Infratemporal Region 62
- Maxillary Artery 64
- Mandibular Nerve 66

Related Video *(See Page xxiii)*
17. Infratemporal Fossa

Chapter 10 Temporomandibular Joint 69
- Landmarks 69
- Temporomandibular Joint 69

Chapter 11 Submandibular Region 71
- Landmarks 71
- Structures in Submandibular Region 71

Chapter 12 Cranial Cavity and Cranial Meninges 76
- Landmarks 76
- Skin Incision 76
- Contents of Cranial Cavity 77
- Cranial Cavity 81

Related Video *(See Page xxiii)*
18. Dissection of the Cranial Cavity

Chapter 13 Anterior, Middle and Posterior Cranial Fossa 83
- Landmarks 83
- Cranial Fossae 83
- Cranial Nerves 85
- Dural Venous Sinuses 91
- Emissary Veins 93
- Pituitary Gland 93
- Arteries, Nerves and Veins 93
- Veins 95

Chapter 14 Orbit 96
- Landmarks 96
- Contents of the Orbit 96

Related Videos *(See Page xxiv)*
19. Dural Folds and Cranial Nerves
20. Dural Venous Sinuses
21. Cranial Nerves
22. Arteries of Brain
23. Orbit, Cranial Nerves and Dural Venous Sinuses
24. Muscles of the Orbit

Chapter 15 Deep Structures of Neck Thyroid and Parathyroid Glands 104
- Landmarks 104
- Deep Structures in the Neck 104
- Parathyroid Glands 107

Chapter 16 Structures Deep to Sternocleidomastoid Muscle 109
- Landmarks 109
- Arteries and Nerves 109
- Ansa Cervicalis 112
- Laryngeal Nerves 113
- Hypoglossal Nerve 113

Chapter 17 Structures in the Root of Neck 114
- Landmarks 114
- Veins, Arteries and Muscles in the Root of Neck 114
- Neurovascular Bundle of the Neck 117
- Cervical Pleura 119
- Cervical Sympathetic Trunk (Chain) 119
- Cervical Ganglia 119
- Trachea 120
- Esophagus 121

Chapter 18 Prevertebral Region and Cervical Plexus 123
- Landmarks 123
- Prevertebral Muscles 123
- Cervical Plexus 124
- Vertebral Artery and Vein 125

Related Videos *(See Page xxv)*
25. Deep Structures of the Neck
26. Prevertebral Muscles
27. Prevertebral Region

Chapter 19 Pharynx and Palate 127
- Landmarks 127
- Pharynx 128
- Muscles of the Pharynx 131
- Vessels and Nerves of the Pharynx 133
- Palate 133

Chapter 20 Tongue 136
- Landmarks 136
- Structure of the Tongue 136

- Blood Supply 138
- Nerve Supply of the Tongue 139

Related Videos *(See Page xxv)*
28. Coronal Section of the Head
29. Pharynx
30. Nasopharynx

Chapter 21 Nasal Cavity and Paranasal Sinuses 140
- Landmarks 140
- Anatomy of Nose 140
- Boundaries Nasal Cavity 141
- Nerves and Arteries of the Nasal Cavity 142
- Pterygopalatine Fossa 144
- Paranasal Sinuses 147

Related Video *(See Page xxvi)*
31. Nasal Cavity and Paranasal Sinuses

Chapter 22 Larynx 149
- Landmarks 149
- Structure of Larynx 149
- Arteries and Veins of the Larynx 153
- Nerves of the Larynx 153

Related Videos *(See Page xxvi)*
32. Posterior View of Infratemporal Fossa and Larynx
33. Larynx

Chapter 23 Eyeball 155
- Landmarks 155
- Structure of the Eyeball 155

Chapter 24 Ear 160
- Structure of Ear 160
- External Ear 161
- Tympanic Membrane 162
- Middle Ear (Tympanic Cavity) 162
- Internal Ear 165
- Internal Acoustic Meatus 166

Chapter 25 Joints of Neck 167
- Landmarks 167
- Joints of the Neck 167
- Cervical Joints 169

SECTION 2 Brain

Chapter 26 Introduction to the Brain 175
- Nervous System 175
- Classification of Nervous Tissue in CNS 177
- Parts of the Brain 177
- Meninges of the Brain 178

Chapter 27 Blood Vessels of the Brain 180
- Landmarks 180
- Blood Vessels of Brain 181
- Circle of Willis 188

Chapter 28 Base of the Brain 191
- Landmarks 191
- Parts of the Brain 192
- Interpeduncular Fossa 192
- Cranial Nerves 193

Related Videos *(See Page xxvi-xxvii)*
1. Dissection of the Cranial Cavity
2. Base of the Brain
3. Arteries of the Brain
4. Basilar and Internal Carotid Artery
5. Arteries and Cranial Nerves
6. Branches of the Basilar Artery
7. Cranial Nerves in the Cranial Cavity

Chapter 29 Hindbrain: Medulla Oblongata 197
- Landmarks 197
- Structure of Medulla Oblongata 197
- Cranial Nerve Nuclei in Medulla Oblongata 200

Chapter 30 Hindbrain: Pons 202
- Landmarks 202
- Structure of Pons 202
- Cranial Nerve Nuclei in Pons 205

Chapter 31 Hindbrain: Cerebellum 207
- Landmarks 207
- Structure of Cerebellum 207
- Interior of Cerebellum 210

Chapter 32 Midbrain 213
- Landmarks 213
- Structure of the Midbrain 213

Chapter 33 Brainstem 217
- Landmarks 217

Chapter 34 Fourth Ventricle 219
- Landmarks 219
- Boundaries of the Fourth Ventricle 219
- Tela Choroidea and Choroid Plexus 220

Chapter 35 Cerebral Hemispheres 222
- Landmarks 222
- Structure of Cerebral Hemispheres 222
- Arteries of Cerebrum 223
- Sulci, Gyri and Lobes 224
- Lobes of Cerebrum 226
- Temporal Lobe 226
- Parietal Lobe 228
- Occipital Lobe 228
- Insula 229
- Limbic System 229

Chapter 36 White Matter of Cerebrum 231
- Medial Surface of Cerebrum 231
- Commissural Fibers 232

Chapter 37 Lateral Ventricle 234
- Landmarks 234
- Boundaries of Lateral Ventricle 235
- Choroid Fissure 235

Chapter 38 Thalamus, Hypothalamus, Epithalamus and Metathalamus 237
- Thalamus 237
- Structure of Thalamus 238
- Hypothalamus 240
- Subthalamus 242
- Epithalamus 242
- Metathalamus (Geniculate Bodies) 245

Chapter 39 Basal Ganglia (Nuclei) 246
- Deep Nuclei of Telencephalon 246
- Basal Nuclei (Ganglia) 247

Chapter 40 Third Ventricle 250
- Landmarks 250
- Boundaries of Third Ventricle 250

Related Videos *(See Page xxvii)*
8. Medial Surface of the Brain
9. Ventricles of the Brain
10. Third and Fourth Ventricles

Chapter 41 Deep Structures of the Cerebrum 252
- Landmarks 252

Index 255

CHAPTER

4

Tarsal Plates and Lacrimal Apparatus

JAYPEE BROTHERS

LEARNING OBJECTIVES

After reading this chapter, the students will be able to identify the following structures:

1. Layers of eyelids
2. Tarsal plates
3. Orbital septum
4. Medial palpebral ligament
5. Lateral palpebral ligament
6. Conjunctival sac
7. Lacrimal apparatus (lacrimal gland, lacrimal ducts, lacrimal punctum, lacrimal canaliculi, lacrimal sac and nasolacrimal duct)

Introduction

The eyelids protect the eye from injury and excessive light and its margins have the eyelashes (cilia) which contain the ciliary glands (sebaceous glands).

Landmarks

1. Fossa for the lacrimal gland
2. Lacrimal punctum
3. Lacrimal groove for the lacrimal sac
4. Opening of nasolacrimal duct.

Orbital Septum and Tarsal Plates

Dissection

1. Reflect the skin from the eyelids and expose the fibers of orbicularis oculi muscle.
2. Reflect the fibers of the medial angle of the eye.
3. Expose the **orbital septum** and the **tarsal plates** in the upper and lower eyelids.
4. Trace the tarsal plates medially and laterally and identify the **medial** and **lateral palpebral ligaments.**
5. Dissect the **lacrimal gland,** pull it downward and look for the **lacrimal ducts.**
6. Identify the **lacrimal sac** in the medial wall of the orbit and trace the **nasolacrimal duct.**

The **eyelid** consists of skin, superficial fascia, orbicularis oculi muscle, tarsus and orbital septum.

Anatomic structure of eye is shown in Figure 4.1.

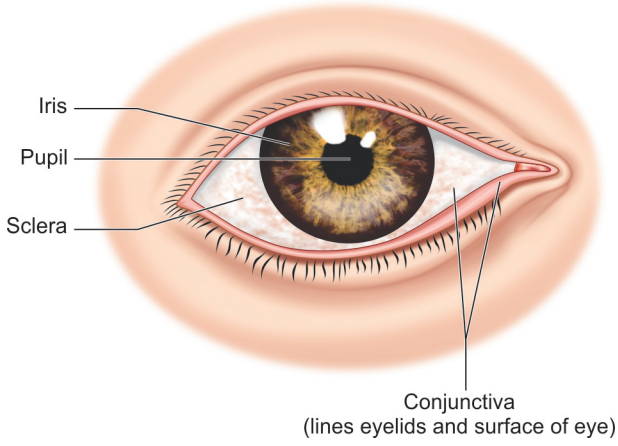

Fig. 4.1: Eyelids

The **upper eyelid** is supplied by supratrochlear, supraorbital (branches of frontal nerve), infratrochlear (branches of nasociliary nerve) and palpebral branches of lacrimal nerve, and the **lower eyelid** is supplied by the infraorbital nerve.

The **motor supply to orbicularis oculi** comes from facial nerve (7th cranial nerve).

The **arterial supply** to the eyelid comes from the branches of lacrimal, ophthalmic and infraorbital arteries.

The **conjunctival sac** is the closed space when the eyelids are closed.

The **tarsal plates** are two, superior and inferior which form the '**skeleton' of the eyelids**' attached to the palpebral fascia, and the **tarsal glands** that lie on the deep surface of the tarsal plates and their ducts open on the margin behind the eyelashes.

The **ciliary glands** lie in rows behind the root of the eyelashes and their ducts open on the margin close to the eyelashes.

The **orbital septum** is formed by the **palpebral fascia,** a fibrous membrane which connects the tarsal plates to the orbital margin.

Palpebral Ligaments

The **medial palpebral ligament** is a strong fibrous band which lies at the medial angle of the eye and connects the two tarsal plates with the medial margin of the orbit and the **lateral palpebral ligament** is a thin, fibrous band which connects the two tarsal plates with the lateral margin of the orbit (Fig. 4.2).

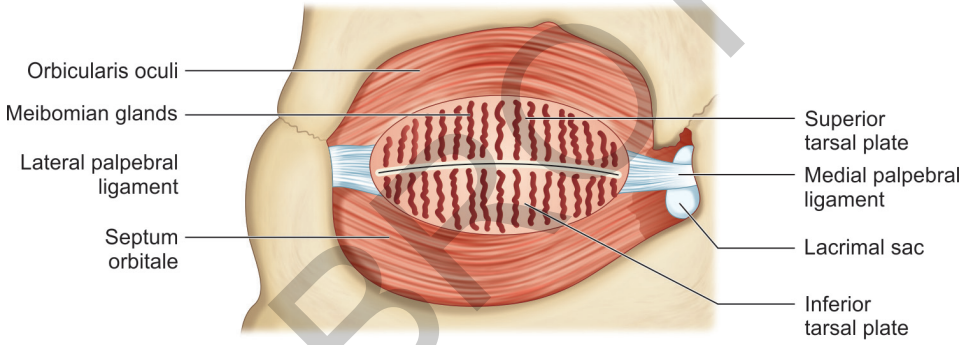

Fig. 4.2: Tarsal plates (front view)

Lacrimal Apparatus

The **lacrimal gland** is a lobulated structure which secretes the lacrimal fluid (tear) and lies on the superolateral angle of the orbit, in a fossa on the medial side of the zygomatic process of the frontal bone and its medial surface rests on the **levator palpebrae superioris** and the **lateral rectus muscles.**

The **lacrimal ducts,** convey the lacrimal fluid from the gland to the conjunctival sac and the **lacrimal canaliculi** begin at the lacrimal punctum which is an opening near the medial angle of the eye.

Lacrimal sac is the dilated superior part of the nasolacrimal duct that lies in a groove on the medial wall of the orbit and the **nasolacrimal duct** conveys the lacrimal fluid to the nasal cavity (inferior meatus of the nose).

The **lacrimal fluid** (tear) flows downwards and medially over the eyeball by the contraction of the **orbicularis oculi** muscle which moves the eyelids medially (Fig. 4.3).

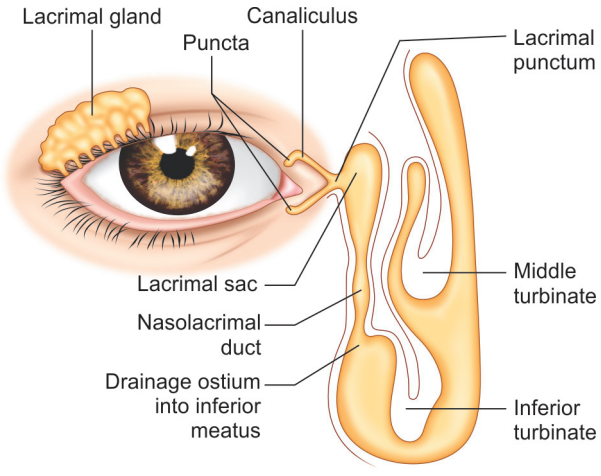

Fig. 4.3: Lacrimal apparatus

The **accessory lacrimal glands** are minute glands that lie near the fornices and become active moistening the conjunctiva when the lacrimal gland is removed.

JAYPEE BROTHERS

Nerve Supply of the Lacrimal Gland

The **presynaptic parasympathetic fibers** are conveyed from the facial nerve by the **greater petrosal nerve** and the postganglionic secretory fibers arise in the **pterygopalatine ganglion.**

The **postsynaptic sympathetic fibers** are brought by the internal carotid plexus and deep petrosal nerve.

Applied Anatomy (Clinical)

In **paralysis of the orbicularis oculi** muscle, the fluid does not spread over the eyes and leads to the drying of the cornea.

Excessive secretion of the lacrimal gland due to the irritation of the conjunctiva, the lacrimal fluid floods the conjunctiva and overflows.

When the ciliary glands get infected, they produce a red swelling of the margin of the eyelid called the **"stye".**

The obstruction of the duct in the tarsal gland produces a **cyst.**

Inflammation of the lacrimal sac causes pain, redness and swelling at the medial angle of the eye.

JAYPE BROTHERS

for detailed information on anatomy books, visit our website www.jaypeebrothers.com, for detailed information on anatomy books, visit our website www.jaypeebrothers.com, for detailed i

Dissection Manual

With Regions & Applied Anatomy

Head, Neck and Brain

Salient Features

- **Fully revised and aligned with the latest CBME guidelines** prescribed by the National Medical Commission (NMC), 2024.
- A comprehensive **three-volume practical guide** meticulously prepared with dedication to serve students and educators in **medical, dental, and allied health sciences**. The content is thoughtfully organized and enriched with numerous **detailed illustrations** to support effective cadaveric dissection.
- Each chapter is structured with **clearly defined Learning Objectives**, followed by **Introduction, Bony Landmarks**, and **Applied (Clinical) Anatomy**, ensuring a concept-based and outcome-driven approach in line with CBME guidelines.
- **Volume III** explains well about the cadaver **dissections of the head, neck, and brain** in a simple format. It explains the different regions, with the osteology, cutaneous nerves, muscles, nerves, blood vessels and joints, neuroglia, different parts of the brain, their relations and functions with **clinical importance.**
- Integrated with **dissection and model demonstration videos**, this edition provides a strong **visual learning aid**, facilitating better understanding of anatomical relationships and dissection techniques.
- Designed to be **student-friendly, exam-relevant**, and clinically oriented, this manual serves as an **indispensable resource** for students to master Gross Anatomy in both academic and practical settings.



Mercy Navis MSc has got her Master's degree in Human Anatomy from Madras Medical College, Chennai, Tamil Nadu, India, and has an extensive teaching experience of more than 38 years. In her career, she has taught undergraduate and postgraduate medical, dental, nursing, pharmacy, physical therapy, and Chiropractic students. Currently, she is working as Associate Professor of Anatomy, Department of Basic Sciences, Life University, Atlanta, USA. She was teaching for the past 25 years, in USA, Chiropractic students, both in Sherman College, South Carolina, and in Life University, Atlanta. She has also taught the premedical and predental students in the University of South Carolina and nursing students in Spartanburg Technical College. In the past, she has worked as Assistant Professor in MS Ramaiah Medical College, Bengaluru, Karnataka, for 16 years and also Sri Krishna Medical College, Muzaffarpur, Bihar, for 3 years. She has prepared several museum specimens and created the Anatomy Museum for Sri Krishna Medical College, Muzaffarpur. Life University has awarded her as the "Teacher of the Year 2011–2012" and she was also recognized by the graduating class of March 2014 as the "Faculty of the Basic Sciences". She has conducted Dissection Seminars for the Doctors of Chiropractic and Chiropractic Diplomats from Japan. She has already published the book in USA *Gross Anatomy Dissection Manual* in August 2013 by Kendall Hunt Publishing Company.

Printed in India

Available at all medical bookstores or buy online at www.ejaypee.com

JAYPEE BROTHERS
Medical Publishers (P) Ltd.
EMCA House, 23/23-B, Ansari Road,
Daryaganj, New Delhi - 110 002, INDIA
www.jaypeebrothers.com

Join us on facebook.com/JaypeeMedicalPublishers
Follow us on instagram.com/JaypeeMedicalPublishers

Shelving Recommendation
ANATOMY

ISBN 978-93-6616-707-7