r website www.jaypeebrothers.com, for detailed information on ophthalmology books, visit our website www.jaypeebrothers.com

JAYPEE

Recent Advances in OPHTHALMOLOGY

17

Editor
Nitin Nema

Contents

1. **Prevention and Management of Childhood Myopia 1**
   Vinay Gupta, Abhyuday Saxena, Rohit Saxena

2. **Bioengineered Cornea..... 19**
   Abha Gour, Mehak Vohra, Virender Singh Sangwan

3. **Diagnosis and Management of Pediatric Keratoconus 33**
   Neet Mehta, Sunita Chaurasia, Muralidhar Ramappa

4. **Lamellar Keratoplasty 53**
   Shreesha Kumar Kodavoor, Tasneem Neemuchwala, KS Siddharthan, Arnav Singh Saroya, Ramamurthy Dandapani

5. **Integrated Intraoperative Optical Coherence Tomography in Anterior Segment Surgeries 88**
   Deeksha Thorat, Somasheila I Murthy, Aafreen Bari, Namrata Sharma

6. **Advances in Medical Management of Glaucoma 97**
   R Ramakrishnan, Madhavi Ramanatha Pillai, Devendra Maheshwari

7. **Management of Noninfectious Uveitis 115**
   Dipankar Das, Jessica Basumatary, Himanshu Garkoti, Rajendra Prakash Maurya

8. **Polymerase Chain Reaction in Uveitis..... 128**
   Anshukita, L Dhanurekha, A R Anand, Jyotirmay Biswas

9. **Management of Hard Cataracts..... 141**
   Raksheeth Nathan Rajagopal, Ramamurthy Dandapani

10. **Management of Retinopathy of Prematurity 152**
    Tapas Ranjan Padhi, Akash Belenje, Saurabh Kumar, Inderjeet Kaur, Sameera Nayak, Bhavik Panchal, Subhadra Jalali

11. **Management of Age-related Macular Degeneration..... 162**
    Kiran Chandra Kedarisetti, Raja Narayanan

12. **Diagnosis and Management of Diabetic Macular Edema 176**
    Samya Singh, Shilpi Arya, Sandeep Saxena

13. **Pachychoroid: The Disease Spectrum 199**
    Anand Rajendran, Aditya Maitray, Ritesh Chainani, Debolina Deb

14. Integrated Intraoperative Optical Coherence Tomography During Posterior Segment Surgeries.....215
Lingam Gopal, Chetan Rao, Su Xinyi

15. Recent Updates in Understanding and Management of Optic Neuritis.....224
Abhipsa Sharma, Amol Bansal, Virender Sachdeva

16. Management of Orbital Hemangioma.....260
Rajendra Prakash Maurya, Sneha Gupta, Dipankar Das, Abdullah S Al-Mujaini

17. Imaging and Artificial Intelligence in Strabismus.....291
Abinaya Valliappan, Sumita Agarkar

18. ChatGPT in Ophthalmology: Application and Future.....306
Divyansh K Mishra, Mahesh P Shanmugam

Index.....313



CHAPTER

Lamellar Keratoplasty

Shreesha Kumar Kodavoor, Tasneem Neemuchwala, KS Siddharthan, Arnav Singh Saroya, Ramamurthy Dandapani

JAYPEE BROTHERS

ABSTRACT

Lamellar keratoplasty (LK) has undergone significant advancements in recent years, revolutionizing the field of corneal transplantation. This chapter highlights the latest developments and techniques in LK, focusing on both anterior and posterior lamellar procedures. Anterior lamellar keratoplasty (ALK) techniques, such as deep anterior lamellar keratoplasty (DALK), have gained popularity due to their ability to preserve the healthy endothelial layer. Improved instrumentation and surgical expertise have led to enhanced outcomes, including faster visual recovery, reduced risk of graft rejection, and improved graft survival rates. Moreover, the advent of femtosecond laser-assisted techniques has enabled precise dissection, facilitating smoother graft–host interface and minimizing intraoperative complications. Posterior lamellar keratoplasty (PLK), particularly Descemet's stripping endothelial keratoplasty (DSEK) and Descemet membrane endothelial keratoplasty (DMEK), has witnessed remarkable advancements in donor tissue preparation, surgical instrumentation, and surgical techniques. Novel approaches, such as preloaded donor tissue insertion systems and intraoperative optical coherence tomography (OCT) guidance, have contributed to improved surgical efficiency and enhanced outcomes. Furthermore, innovations in tissue storage and transportation have extended the viability of donor tissue, widening the donor pool and reducing waiting times for patients. The advent of tissue engineering and regenerative medicine holds promise for developing bioengineered corneal substitutes, offering a potential solution to the global shortage of donor corneas.

Keywords: Lamellar keratoplasty, Bowman's layer transplant, deep anterior lamellar keratoplasty, sutureless femtosecond laser-assisted anterior lamellar keratoplasty, Descemet membrane endothelial keratoplasty, ultrathin Descemet's stripping endothelial keratoplasty, descemetorhexis without endothelial keratoplasty

INTRODUCTION

The landscape of corneal transplantation has been profoundly reshaped by the emergence of lamellar keratoplasty (LK). Recent years have witnessed

significant strides in LK, ushering in a new era of enhanced outcomes and broader treatment options for individuals with corneal diseases. This transformative progress is dedicated to the preservation of healthy corneal tissue, mitigating complications, and optimizing visual results. Within this chapter, we delve into the cutting-edge advancements that characterize the latest breakthroughs in lamellar keratoplasty techniques.

Lamellar keratoplasty can be broadly categorized into two distinct approaches: Replacement of epithelium and stroma, known as *anterior lamellar keratoplasty (ALK)*, and replacement of Descemet's membrane (DM), termed *posterior lamellar keratoplasty (PLK)*.

Anterior lamellar keratoplasty comprises various procedures which include:

- Bowman's layer transplantation (BLT)
- Deep anterior lamellar keratoplasty (DALK)

There are various techniques of DALK which are as follows:

- Sutureless femtosecond laser-assisted anterior lamellar keratoplasty (FALK)
- Tuck in femtosecond laser-assisted anterior lamellar keratoplasty (T-FALK)
- Double docking procedure for DALK (DD-DALK)

Posterior lamellar keratoplasty includes:

- Descemet's stripping endothelial keratoplasty (DSEK)/Descemet's stripping automated endothelial keratoplasty (DSAEK)
- Pre-Descemet's endothelial keratoplasty (PDEK)
- Descemet membrane endothelial keratoplasty (DMEK)

ADVANCEMENTS IN ANTERIOR LAMELLAR KERATOPLASTY

Isolated Bowman's Layer Transplantation

This is an emerging and evolving method, although not routinely practiced. Its primary applications include serving as an inlay graft into the mid-stroma of the cornea for managing keratoconus **(Figs. 4.1A to C)** and as an onlay graft to address persistent subepithelial haze observed in some cases following excimer laser surface ablation.[1]

One study shows the potential use of femtosecond laser (FSL) technology for harvesting the donor Bowman's layer. Initial feasibility analysis has indicated compelling outcomes, showcasing the creation of a thick and relatively smooth posterior cut edge in the FSL group. In contrast, the manually dissected group exhibited a virtually isolated Bowman's layer, with irregular remnants of dispersed stroma.[2]

JAYPEE BROTHERS

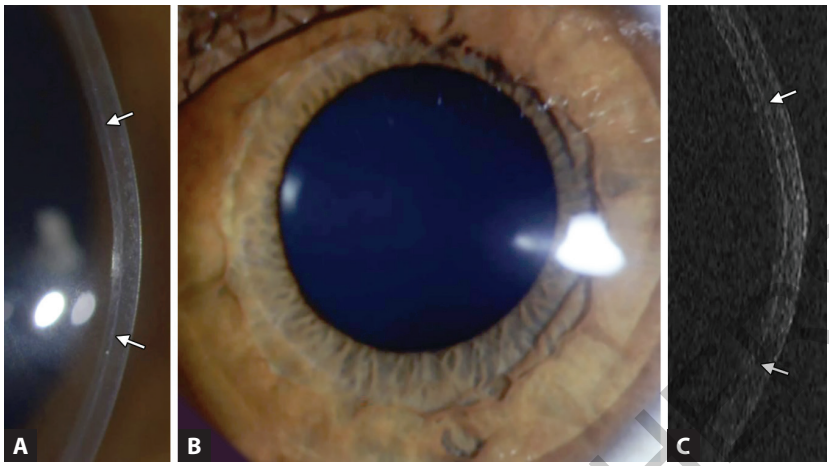

Figs. 4.1A to C: Slit-lamp images and optical coherence tomography (OCT) image after Bowman layer transplantation. The (A, B) slit-lamp images and (C) OCT images were obtained 6 months after Bowman layer transplantation. The Bowman layer transplant (white arrows) is visible as a thin, white line within the recipient stroma (A and C), whereas the cornea is clear and without any interface haze or stromal reaction (B).

Sutureless Femtosecond Laser-assisted Anterior Lamellar Keratoplasty

The depth of the pathology is measured by anterior segment OCT (ASOCT). The procedure employs a FSL to create a lamellar cut in the recipient's cornea, precisely matched with donor corneal tissue. The thickness of the donor cut is adjusted based on the depth of the lesions, with an additional 10–20% thickness allowance to compensate for potential donor tissue swelling. Subsequently, the scarred corneal tissue in the recipient is carefully removed and replaced by the corneal donor lenticule **(Figs. 4.2 and 4.3)**. After the replacement, the incision is dried, and the adhesion of the flap is checked to ensure proper alignment and attachment. A bandage soft contact lens is finally placed over the cornea.[3]

A variation of the FALK method was documented by Bonfadini et al., employing the Ziemer FSL from Ziemer Ophthalmic Systems AG, Port, Switzerland. This modification introduces two distinct dissection depths: Midstromal (exceeding 250 µm of posterior residual corneal bed thickness) and pre-Descemet (approximately 50 µm of posterior residual corneal bed thickness). The foundational principles of this modified approach align with those previously described for the conventional FALK method.[4]

Tuck in Femtosecond Laser-assisted Anterior Lamellar Keratoplasty

It is a sutureless and glueless technique, offering a novel and effective alternative for managing superficial anterior corneal scars. The depth of

JAYPEE BROTHERS

the anterior corneal scar is assessed using ASOCT. The procedure involves the precise preparation of both donor and recipient lenticules through the application of FSL technology. Following the removal of the recipient's anterior scarred lenticule, the donor lenticule is positioned onto the recipient's bed. The margins of the donor lenticule are tucked in beneath the recipient cornea **(Figs. 4.4A to C)**, creating a secure fit.[5]

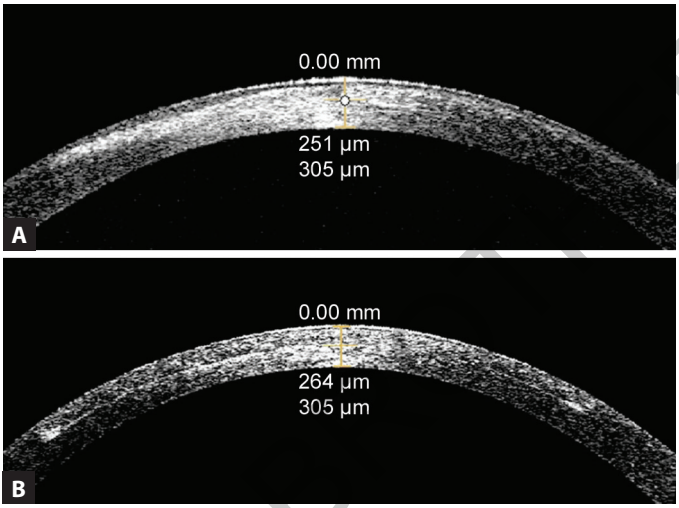

Figs. 4.2A and B: Anterior segment noncontact optical coherence tomography for corneal scarring depth evaluation reveals the depth of the lesion-scarring (A) preoperatively and (B) after femtosecond laser-assisted sutureless anterior lamellar keratoplasty.

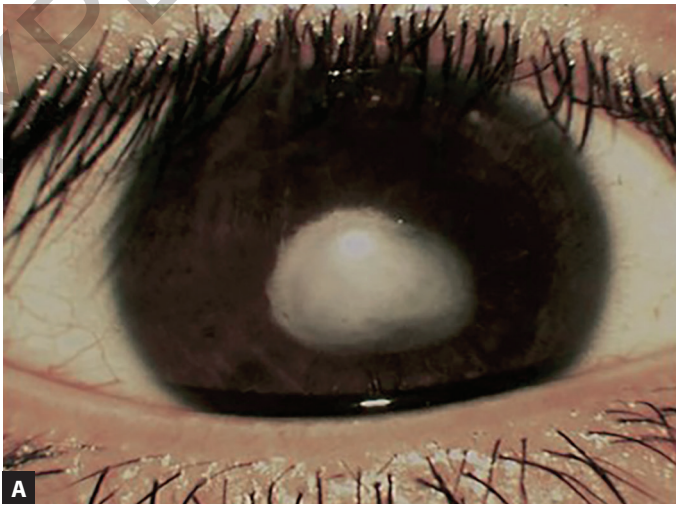

Fig. 4.3A

JAYPEE BROTHERS

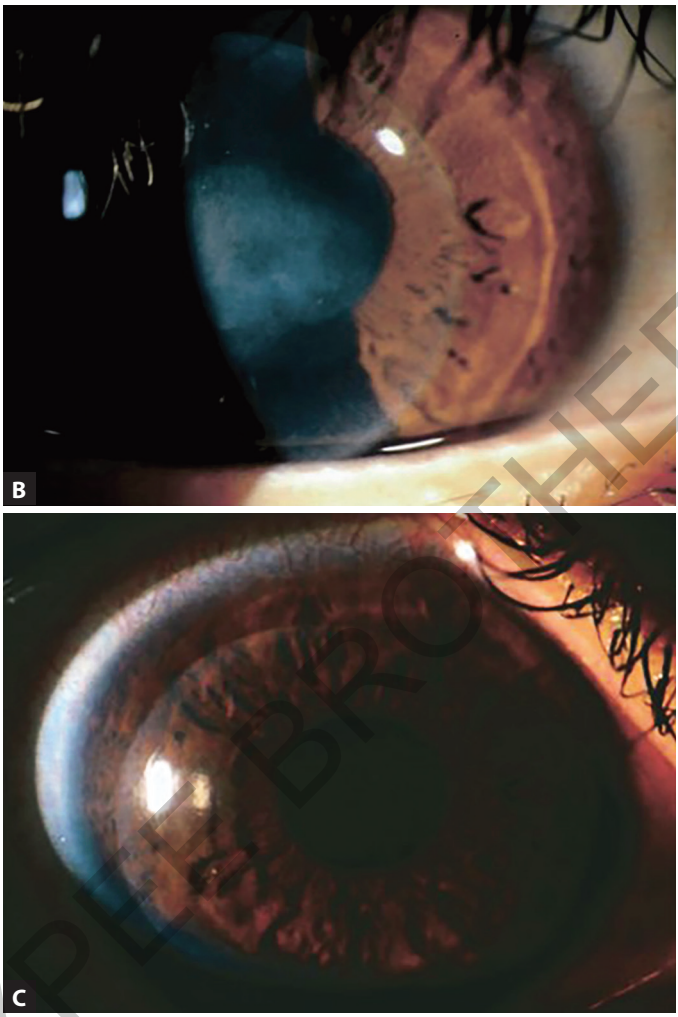

Figs. 4.3B and C

Figs. 4.3A to C: (A) Corneal slit-lamp photograph of a 19-year-old male with a paracentral scar and best-corrected visual acuity (BCVA) of 20/60. (B) 10 months after femtosecond laser-assisted sutureless anterior lamellar keratoplasty, there was residual corneal scarring. (C) Phototherapeutic keratectomy was performed after lifting the anterior lamellar graft, with a complete restoration of corneal clarity and improvement in BCVA to 20/25.

JAYPEE BROTHERS

Double Docking Procedure for Deep Anterior Lamellar Keratoplasty

It represents a secure surgical technique utilizing the precision of FSL technology and intraoperative optical coherence tomography (iOCT). In this procedure, the FSL and iOCT work in tandem to provide direct visual control during the first lamellar resection, often referred to as the *first docking*. This initial step is crucial for minimizing the risk of corneal perforation,

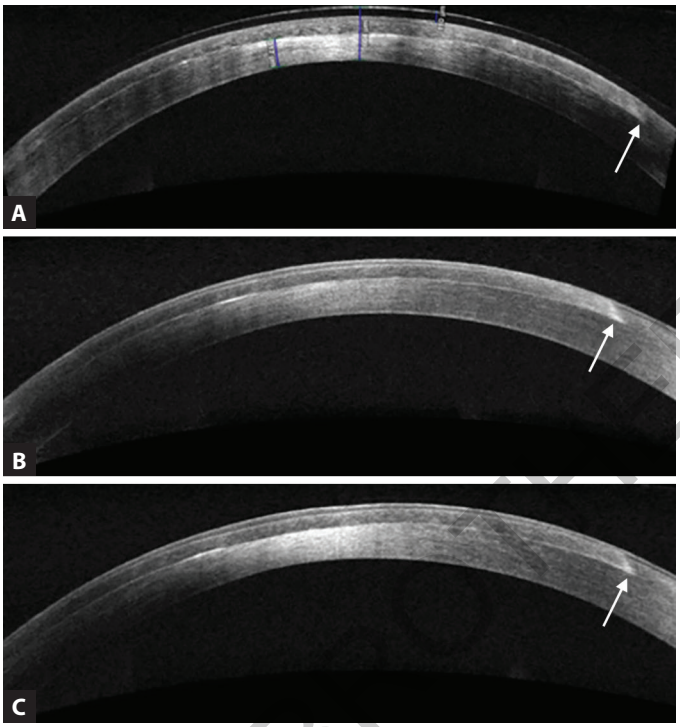

Figs. 4.4A to C: ASOCT images of a patient who underwent T-FALK showing good healing at the graft–host junction at (A) 1 day, (B) 1 month, and (C) 3 months. Also note the angle of 45° that allows good apposition of the graft–host junction after the T-FALK procedure. (ASOCT: anterior segment optical coherence tomography; T-FALK: tuck in femtosecond laser-assisted anterior lamellar keratoplasty)

particularly in comparison to the use of a manual trephine. The lamellar resection performed during the first docking is instrumental in positioning the needle or cannula close to the Descemet membrane, a prerequisite for the successful formation of a big bubble (BB). Following the BB formation, a second docking is done to cut the residual irregular posterior stroma using the FSL. Subsequently, the residual stroma is removed using forceps **(Figs. 4.5A to L)**. This second docking to eliminate the residual stroma minimizes the need for extensive surgical dissection, thereby enhancing the learning curve associated with this intricate and challenging technique. The DD-DALK method ensures a safe and controlled approach to deep anterior lamellar keratoplasty.[6]

Algorithm for Performing DALK Using Preoperative OCT in Keratoconus Eyes

Through the application of ASOCT, a noncontact method rooted in low-coherence interferometry principles, Sandali and colleagues introduced a novel classification system delineating structural corneal alterations observed

JAYPEE BROTHERS

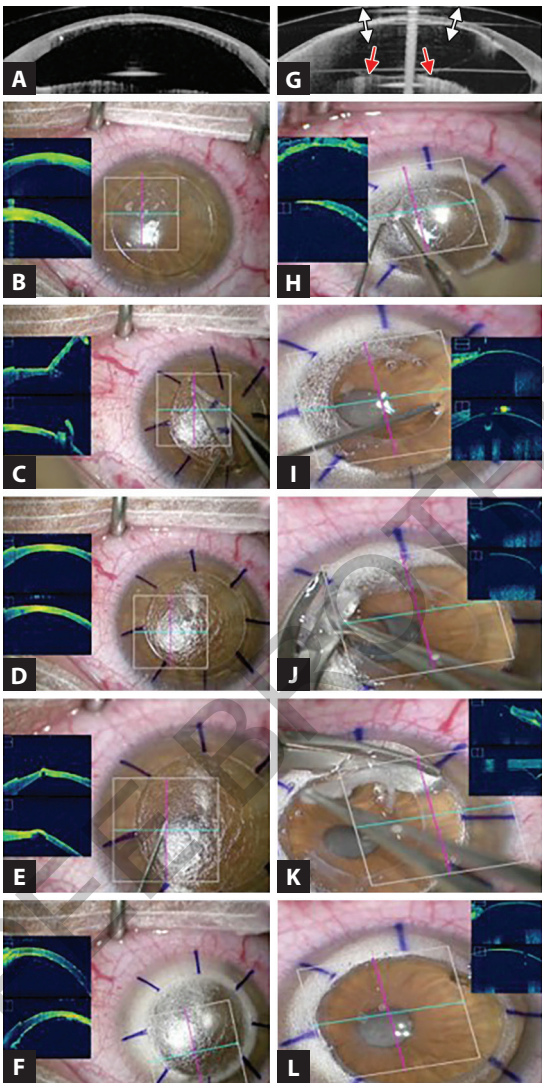

Figs. 4.5A to L: FSL-assisted DALK with the double-docking technique. After the first docking, an FSL-assisted anterior lamellar cut is performed (A). Under an operative microscope with integrated OCT, the lamellar cut is checked (B) and then the anterior stromal lamella is removed using the spatula and forceps (C, D). A 30-G needle is inserted in the residual stroma under OCT guidance (E) and then air is injected to create the BB (F). After the second docking, DM is visible with the FSL integrated OCT (G, red arrows). The cylindrical vertical cut is set and performed on the residual stroma (G), the white arrows indicating the vertical cut setting. Then, the residual stroma is peeled off with forceps (H), and the viscoelastic substance is used to push back DM (I). The residual peripheral stroma is removed using scissors (J, K). The stroma has been fully removed and bare DM was preserved before grafting the donor's anterior stroma (L). (BB: big bubble; DALK: deep anterior lamellar keratoplasty; DM: Descemet membrane; FSL: femtosecond laser; OCT: optical coherence tomography)

JAYPEE BROTHERS

during the progression of keratoconus. This classification system, informed by the corneal microarchitecture changes characteristic of keratoconus eyes, facilitates the assessment and grading of disease severity.[7]

The classification is as follows:

- *Stage 1:* Thinning of epithelial and stromal layers at the conus; corneal layers with normal aspect
- *Stage 2A:* Hyper-reflective anomalies at the Bowman's layer level with epithelial thickening
- *Stage 2B:* Stage 2A + stromal opacities
- *Stage 3A:* Posterior displacement of the hyper-reflective structures at the Bowman's layer level with increased epithelial thickening + stromal thinning
- *Stage 3B:* Stage 3A + stromal opacities
- *Stage 4:* Pan stromal scar
- *Stage 5A:* Acute onset with Descemet membrane rupture with dilacerations of collagen lamellae, large fluid-filled intrastromal cysts, and epithelial edema formation
- *Stage 5B:* Healing stage of 5A with pan stromal scarring with the remaining aspect of Descemet membrane rupture

Based on this classification, an algorithm for performing DALK using preoperative OCT of the recipient cornea has been made **(Flowchart 4.1)**:[8]

Flowchart 4.1: Algorithm for performing DALK using preoperative OCT of the recipient cornea.

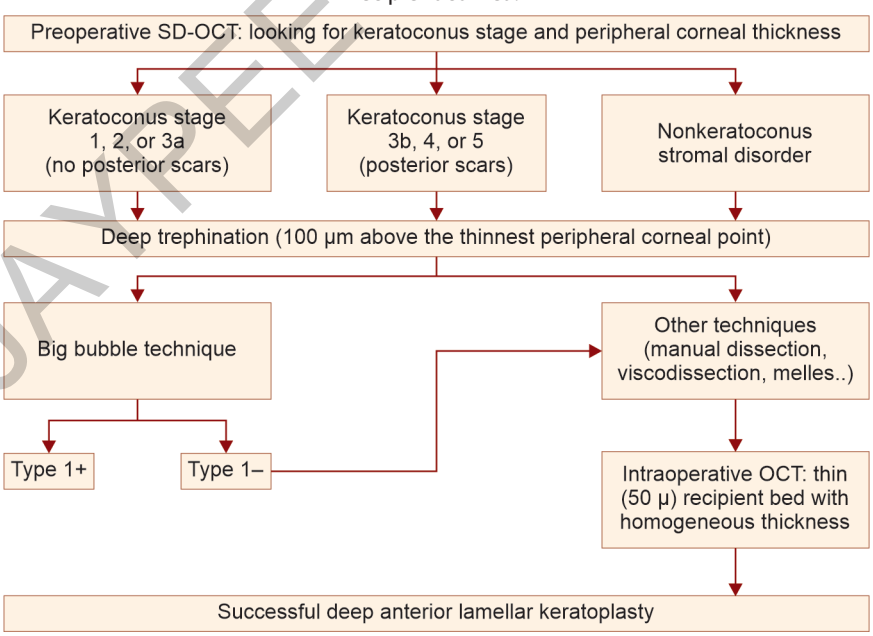

(DALK: deep anterior lamellar keratoplasty; OCT: optical coherence tomography)

JAYPEE BROTHERS

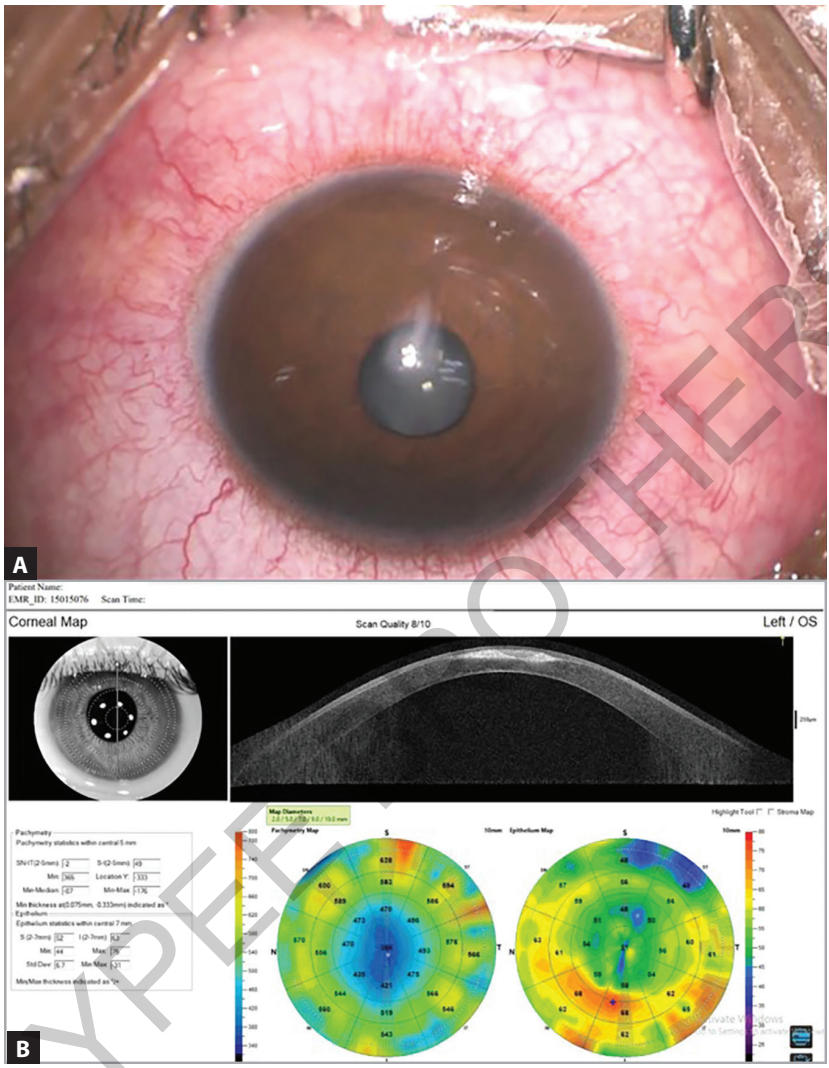

Figs. 4.6 A and B: (A) Superficial stromal scar in a case of keratoconus; (B) ASOCT image of the same eye. (ASOCT: anterior segment optical coherence tomography)

Recent advances in lamellar keratoplasty techniques suggest that OCT assessment of eyes prior to DALK is proving to be a valuable tool. It aids in determining the optimal trephination depth, advocating for a depth as profound as feasible, and enables the identification of scars within the posterior stroma. Specifically in cases of keratoconus with posterior scarring, surgical strategies must be tailored accordingly. While the big bubble technique remains an option, its suitability in such cases may be questioned.

During the execution of DALK procedures targeting superficial scars in keratoconus patients **(Figs. 4.6 A and B)**, the surgical objective is to attain

JAYPEE BROTHERS

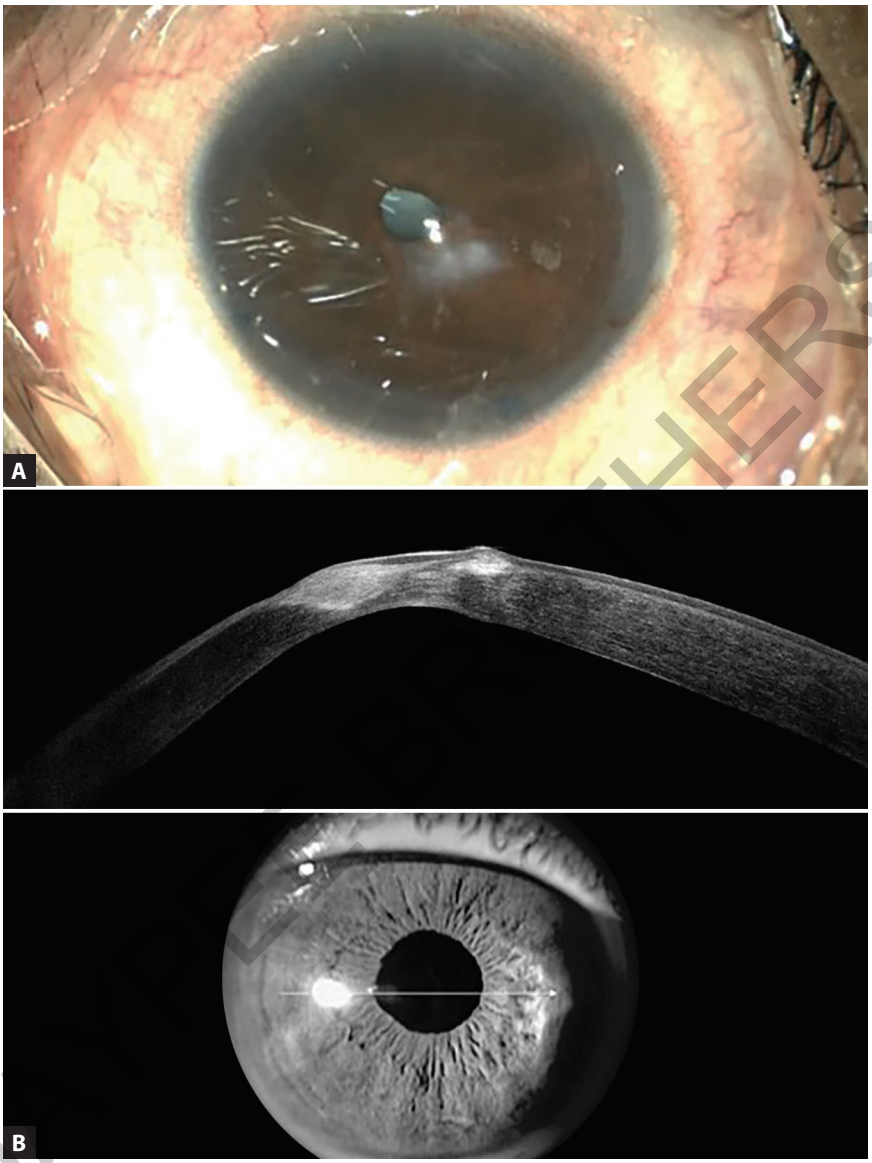

Figs. 4.7 A and B: (A) Deep stromal scar in a case of keratoconus; (B) ASOCT images of the same eye. (ASOCT: anterior segment optical coherence tomography)

a type-1 big bubble, a goal that can be successfully achieved. In cases of deep stromal scars **(Figs. 4.7A and B)**, although type-2 or type-3 big bubble can be achieved, the chances of perforation are high. Therefore, in such cases, dissection with a manual layer-by-layer technique is preferable, as it prevents the chances of perforation intraoperatively and gives better postoperative outcomes. In eyes with healed hydrops **(Figs. 4.8 A and B)**,

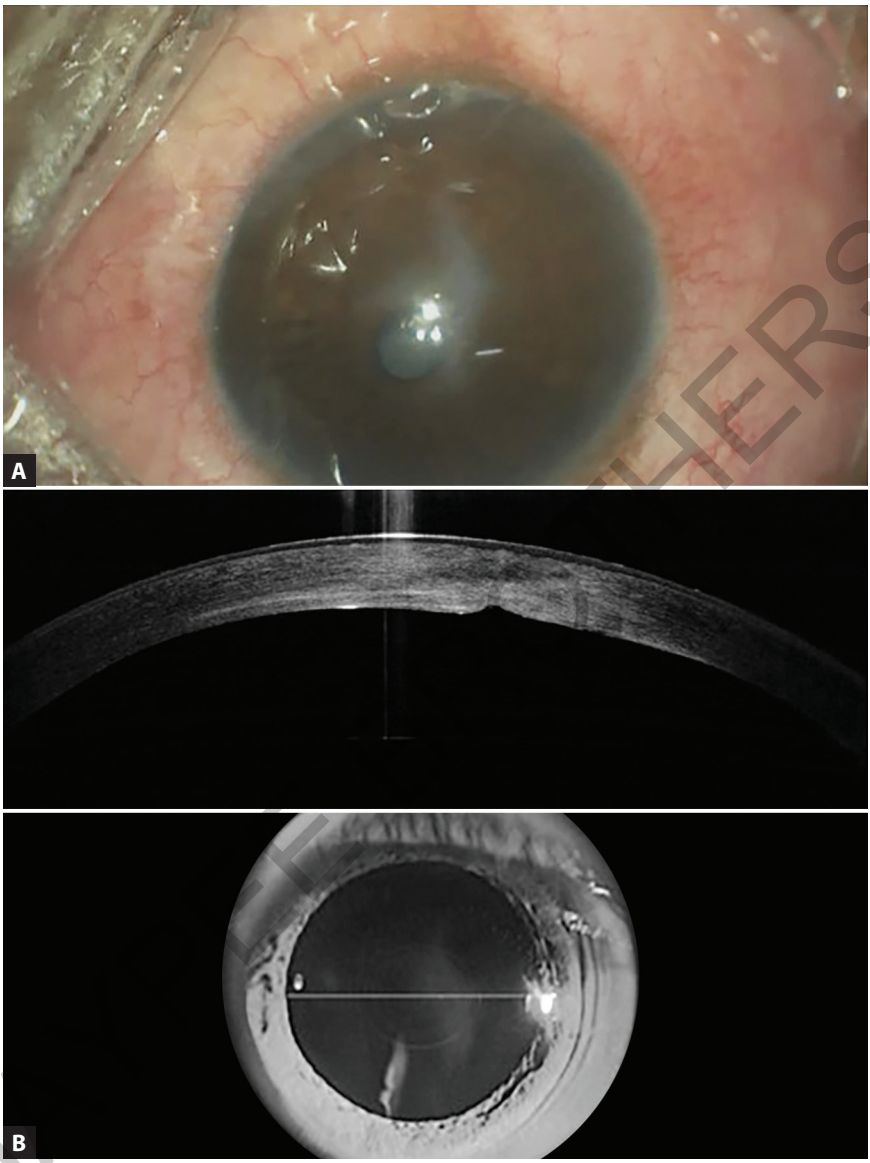

Figs. 4.8 A and B: (A) Healed hydrops scar in a case of keratoconus; (B) ASOCT images of the same eye. (ASOCT: anterior segment optical coherence tomography)

achieving big bubble is not the goal. Intrastromal air is injected to achieve emphysema, which aids in dissection.

Further exploration is warranted to ascertain whether commencing the procedure directly with an alternative lamellar technique or employing the big bubble technique followed by conversion to another lamellar method is preferable. Encouragingly, findings from a 3-year patient follow-up do

not advocate for mandatory conversion to penetrating keratoplasty in instances where a type-1 big bubble cannot be achieved. Likewise, there is no compelling evidence supporting the prioritization of penetrating keratoplasty as the initial approach for eyes with posterior stromal scars. These insights mark significant strides in refining and individualizing lamellar keratoplasty procedures, underscoring the importance of precise preoperative assessment and adaptable surgical techniques.[8]

Artificial Corneal Grafts

A growing advancement in vision correction, FALK with bioengineered collagen corneal (LinkCor) implantation stands as a novel approach aimed at enhancing visual quality in cases of anterior stromal opacities **(Figs. 4.9 and 4.10)**.

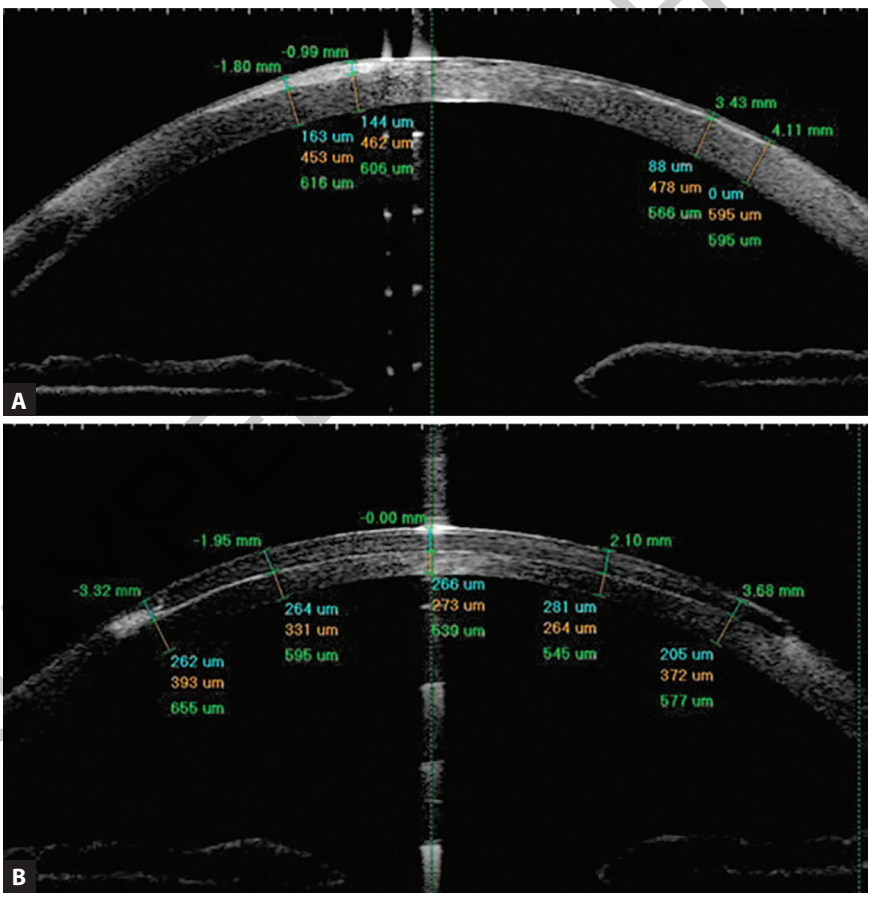

Figs. 4.9A and B: ASOCT images showing (A) corneal scar depth evaluation preoperatively and (B) after implantation of the bioengineered implant using sutureless FALK. (ASOCT: anterior segment optical coherence tomography; FALK: femtosecond laser-assisted anterior lamellar keratoplasty)

for detailed information on ophthalmology books, visit our website www.jaypeebrothers.com, for detailed information on ophthalmology

Recent Advances in OPHTHALMOLOGY 17

Salient Features

- Focuses on the application of technological advancements in ophthalmology—integrated intraoperative optical coherence tomography, artificial intelligence, and ChatGPT
- Describes regenerative approaches in corneal bioengineering
- Covers topics on latest developments in pediatric ocular disorders—Prevention and Management of Childhood Myopia, Pediatric Keratoconus, and Management of Retinopathy of Prematurity
- Includes newer techniques of lamellar keratoplasty
- Provides review on management of noninfectious uveitis and application of polymerase chain reaction in uveitis

Nitin Nema MS DNB is Professor of Ophthalmology and Convener of National Medical Commission Regional Training Center for Medical Education Technologies at Sri Aurobindo Medical College and Postgraduate Institute of Medical Sciences, Indore, Madhya Pradesh, India. He has completed his undergraduate studies from Institute of Medical Sciences, Banaras Hindu University, Varanasi, Uttar Pradesh, and postgraduation in ophthalmology from the same college. He has done the Vitreoretinal Fellowship from Aravind Eye Hospital and Postgraduate Institute of Ophthalmology, Madurai, Tamil Nadu. He was in University of Illinois at Chicago and University of Wisconsin at Madison in the USA as a Clinical Research Fellow. He was awarded GK Saraf Fellowship by the All India Ophthalmological Society to work on a project on uveitis in the Department of Uveitis and Ocular Pathology at Sankara Nethralaya, Chennai, Tamil Nadu. He has received the prestigious Dr Mohan Lal Gold Medal for the best paper from the UP State Ophthalmological Society. He has authored a textbook, *Basic and Clinical Ophthalmology (2nd edition)*, and two books in collaboration with (Late) Dr HV Nema—*Anatomy of Eye and Its Adnexa (3rd edition)* and *Textbook of Ophthalmology (6th edition)*. Moreover, he has edited *Recent Advances in Ophthalmology-16* and coedited 15 volumes of *Recent Advances in Ophthalmology* and four editions of *Diagnostic Procedures in Ophthalmology, Eye in Systemic Disorders, Ocular Tumors,* and *Genetics of Ocular Diseases.*

Printed in India

Available at all medical bookstores or buy online at www.ejaypee.com

JAYPEE BROTHERS
Medical Publishers (P) Ltd.
EMCA House, 23/23-B, Ansari Road,
Daryaganj, New Delhi - 110 002, INDIA
www.jaypeebrothers.com

Join us on facebook.com/JaypeeMedicalPublishers
Follow us on instagram.com/JaypeeMedicalPublishers

Shelving Recommendation
OPHTHALMOLOGY

ISBN 978-93-6616-723-7