etailed information on dermatology books, visit our website www.ejaypee.com, for detailed information on dermatology books, visit our website www.ejaypee.com

2nd Edition

Ward Rounds in DERMATOLOGY

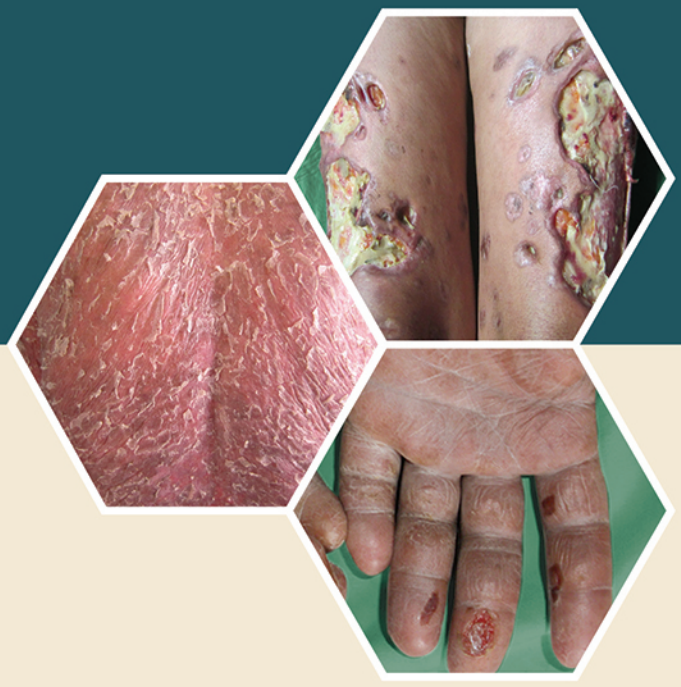

Bela J Shah
Santosh Rathod

Foreword
Sudhir Pujara

JAYPEE

Contents

SECTION 1: INPATIENT MANAGEMENT OF MAJOR CASES IN DERMATOLOGY

CHAPTER 1: **Autoimmune Vesiculobullous Disorders** 3

CHAPTER 2: **Drug Reactions** 22

CHAPTER 3: **Systemic Lupus Erythematosus** 42

CHAPTER 4: **Systemic Sclerosis, Dermatomyositis, and Other Connective Tissue Diseases** 65

CHAPTER 5: **Erythroderma** 102

CHAPTER 6: **Lepra Reactions** 112

CHAPTER 7: **Cutaneous T-cell Lymphoma** 121

CHAPTER 8: **Short Cases: Infantile Hemangioma and Bullous Pyoderma Gangrenosum** 135

SECTION 2: THERAPEUTICS

CHAPTER 9: **Immunosuppressants in Dermatology** 157

CHAPTER 10: **FAQs on Biologics and JAKis** 187

CHAPTER 11: **Antihistamines** 205

CHAPTER 12: **Antibiotics in Dermatology** 210

SECTION 3: MISCELLANEOUS

CHAPTER 13: **Bedside Tests in Dermatology** 221

CHAPTER 14: **Signs in Dermatology** 254

CHAPTER 15: **Frequently Asked Questions in Dermatology** 257

Index 269

CHAPTER 3

Systemic Lupus Erythematosus

INTRODUCTION

Among autoimmune connective disorders, systemic lupus erythematosus (SLE) remains the leading cause of admission in the ward.

CLINICAL HISTORY

A 22-year-old female, college student, presented with *chief complaints of:*

- Recurrent skin lesions over face and bilateral arms for 4 year
- Low grade fever, joint pains for 4 years
- Hair loss for 1 year
- Aggravation of skin lesions since past 1 month

ORIGIN, DURATION, AND PROGRESS

Patient was relatively asymptomatic 4 years ago when she started to develop reddish skin lesions first over the face followed by bilateral arms, which aggravated on sun exposure. The lesions were initially transient and gradually they turned persistent. She had been suffering from diffuse hair fall since the past 1 year. She was experiencing body ache and fatigue for 4 years.

The patient was apparently well before 1 year, when she noticed reddish lesions over her central face that were associated with burning, tingling sensation, and redness, which increased on exposure to sun. The patient also developed reddish lesions over her forearms and hands since last 6 months that gradually developed a central area of white discoloration. These lesions were associated with burning sensation on sun exposure. Since 10 months, the patient started experiencing more pain over small joints of both hands and knees that is present throughout the day and restricts her daily routine but denied any history of associated joint swelling and any deformity. 4 months back, patient developed shortness of breath on climbing stairs. Now she had such episodes more frequently including her daily chores at times. Patient gave history of low-grade fever, easy fatigability, non-productive cough with chest pain, vague abdominal pain, and diffuse hair loss **(Figs. 1 and 2)**.

NEGATIVE HISTORY

There was no history of seizures, loss of consciousness/concentration, mood changes, difficulty in oral opening/swallowing, chest pain, palpitation, heartburn, postprandial abdominal pain, blood

JAYPEE BROTHERS

in urine/frothy urine, decreased urine output, difficulty in getting up from sitting position/climbing stairs/combing hair, tingling or numbness in the extremities associated with color change on exposure to cold, dryness of mouth and eyes, fluid filled lesions, or antecedent drug intake.

- It is important to consider the patient's history of drug use, as drug-induced lupus, which is reversible, accounts for approximately 10% of cases and is more commonly seen in older individuals, particularly males.
- Systemic lupus erythematosus (SLE) have a higher frequency of allergic reactions to sulfa drugs compared to the general population with over 30% of SLE patients reportedly experiencing such reactions, including a potential worsening of their lupus symptoms.
- Burning sensation in mouth associated with difficulty in eating
- Frothy urine or decreased urine output, swelling over face
- Headache, seizures, or altered behavior
- Bluish discoloration of fingers on cold exposure
- Palpitation
- Difficulty in getting up from squatting position or raising arms
- Tightness of skin over both the hands and face
- Dryness in mouth and eyes
- Vesiculo-bullous lesions

PERSONAL HISTORY

The patient experienced decrease in her appetite and sleep. Bowel and bladder movements were unaltered. She had no addictions.

PAST HISTORY

There was no past history of diabetes, hypertension, thyroid disorder, tuberculosis, blood transfusion, and surgical illness.

FAMILY HISTORY

The patient was younger one of two siblings, elder sister being 25 years old. There was no history of similar illness in any family member.

OBSTETRIC/MENSTRUAL HISTORY

The patient had achieved menarche at 15 years of age. Her cycles were painless, regularly spaced at 28–30-day intervals, and were 3–5 days long.

GENERAL EXAMINATION

The patient was moderately built and nourished.

She was vitally stable. There was no evidence of jaundice, pallor, cyanosis, clubbing, edema, or lymphadenopathy.

JAYPEE BROTHERS

SYSTEMIC EXAMINATION

Summary of systemic examination is given in **Table 1**.

TABLE 1: Summary of systemic examination in case of systemic lupus erythematosus (SLE).

System	Finding	Inference
Musculoskeletal	Tender, swollen joints (especially, bilateral knees, wrists, PIP, and MCP joints)	Nonerosive, nondeforming, and symmetric arthropathy
	Difficulty in combing hair, climbing stairs or getting up from sitting position with or without elevated muscle enzymes	Proximal muscle inflammation
Gastrointestinal	Oral ulcers (painless)	Flare of disease
	Abdominal pain	Steroid-induced gastritis, pancreatitis, ischemic bowel perforation, or mesenteric vasculitis
	Rebound tenderness, fever, nausea, vomiting, and diarrhea	Lupus panniculitis (due to mesenteric ischemia/ bowel perforation)
Cardiovascular	Chest pain that eases when sitting upright and intensifies when leaning backward, with or without the presence of a pleural or pericardial rub	Pericarditis
	Fever, conduction abnormalities, elevated serum creative phosphokinase (CPK), skeletal myositis, and serositis	Myocarditis
	Systolic cardiac murmurs; usually over mitral and aortic areas	Libman–Sachs endocarditis (APLA associated); anemia, hypoxemia, and fever
	Tachycardia	Autonomic dysregulation
	Loud P2 with or without elevated aPTT	Pulmonary hypertension (usually with APLA)
Pulmonary	Pin pricking chest pain worsened by lying in ipsilateral position and on deep breaths	Pleuritis and pleural effusion (usually exudative—protein >3 g)
	Hemoptysis	• Pneumonitis • Pulmonary embolus
	Shrinking lung	Diaphragmatic weakness/paralysis
Central nervous system	Seizures (MC: GTCS)	• Lupus vasculitis • Acute thrombosis • Hypertension due to steroid therapy • Uremia
	Lack of sleep, concentration mood changes, and depression	Disease itself
	Intracranial hemorrhage and chorea	APLA syndrome

(ALPA: antiphospholipid antibody; aPTT: activated partial thromboplastin time; GTCS: generalized tonic–clonic seizure; MC: myoclonic)

JAYPEE BROTHERS

CUTANEOUS EXAMINATION



FIG. 1: Multiple discrete erythematous papules and plaques present over bilateral malar area and forehead.

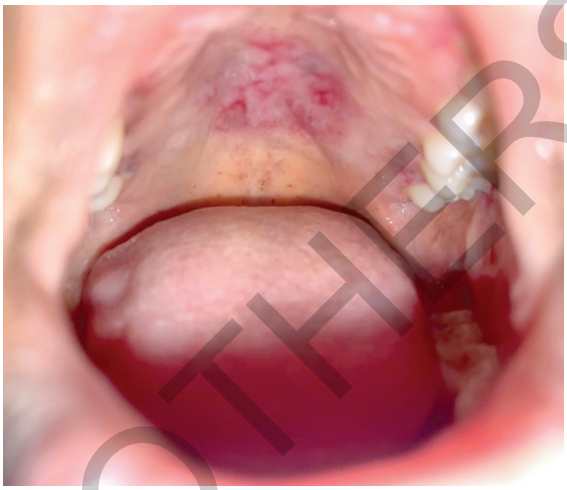

FIG. 2: Oral ulcer over hard palate.

Questions and Answers

Q.1. What are the risk factors for SLE?

Ans.

- *Gender:* Women with SLE outnumber men by 9:1 whereas women with only cutaneous lesions have a predominance of 3:1.
- *Age:* Lupus is uncommon in prepubertal children; most commonly affects women during their child-bearing age.
- *Hormonal susceptibility:* Early menarche, pregnancy, estrogen-containing pills, and hyperprolactinemia
- *Ethnicity:* African American women have a fourfold higher risk
- *Genetics: HLA-DR, PTPN22, STAT4, IRF5, TREX1, C1Q*
- Ultraviolet (UV) radiation (UVB > UVA)
- Cigarette smoking
- Drugs
- *Viruses:* Epstein–Barr virus (EBV)
- Mental/Physical stress

Q.2. Discuss the Gilliam and Sontheimer classification of cutaneous lupus erythematosus.

Ans. Gilliam and Sontheimer classification of cutaneous lupus erythematosus is given in **Flowchart 1**.

JAYPEE BROTHERS

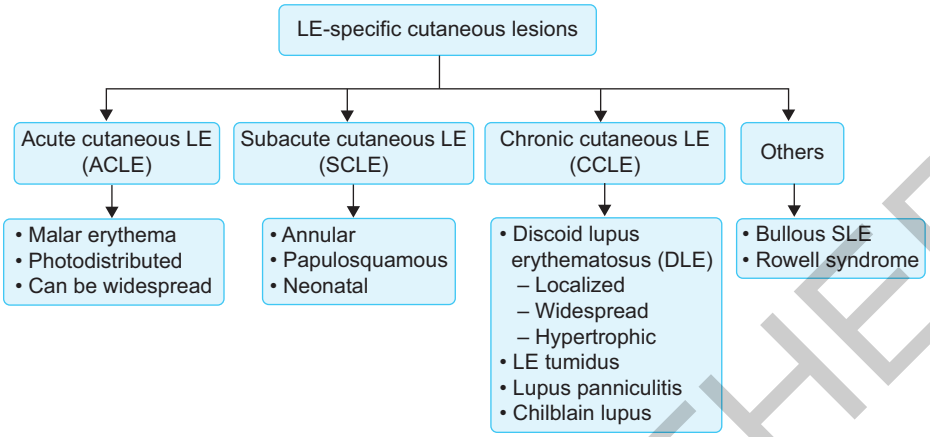

FLOWCHART 1: Gilliam and Sontheimer classification of cutaneous lupus erythematosus.
(LE: lupus erythematosus; SLE: systemic lupus erythematosus)

Q.3. Which cutaneous lesions are nonspecific markers of SLE?

Ans. Nonspecific markers of SLE are listed in **Box 1**.

BOX 1 **Nonspecific cutaneous lesions of systemic lupus erythematosus (SLE).**

- Diffuse nonscarring alopecia
- Raynaud phenomenon
- Nail fold (periungual) telengiectasias and erythema
- *Vasculitis:*
  - Urticarial vasculitis
  - Small-vessel vasculitis (palpable purpura)
  - Polyarteritis nodosa like lesions
  - Ulcerations
- *Cutaneous signs of antiphospholipid syndrome*:
  - Livedo reticularis
  - Ulcerations
  - Acrocyanosis
  - Atrophie blanche-like lesions
  - Degos-like lesions
  - Livedoid vasculopathy
- Palmar erythema
- Papular and nodular mucinosis
- Sweet syndrome-like neutrophilic dermatoses

Q.4. How would a patient of acute cutaneous lupus erythematosus (ACLE) commonly present?

Ans.

- *Localized ACLE:* A butterfly-shaped rash or distinct maculopapular eruption with fine scaling or edema on the butterfly area of cheeks, typically sparing the nasolabial folds.

JAYPEE BROTHERS

- *Generalized lupus erythematosus (LE):* A widespread or papular erythema on the face, upper trunk, and limbs resembling a viral exanthem or drug-induced eruption **(Fig. 3A)**.
- *Toxic epidermal necrolysis (TEN)-like lupus erythematosus (LE) or acute syndrome of apoptotic panepidermolysis (ASAP):* Clinically and histopathologically indistinguishable from drug-induced TEN **(Fig. 3B)**.

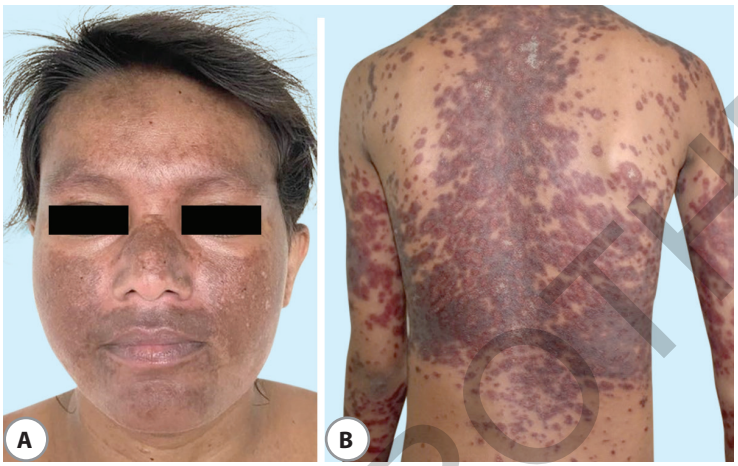

FIGS. 3A AND B: (A) Acute cutaneous LE; (B) Toxic epidermal necrolysis (TEN)-like presentation of lupus erythematosus (LE) over bilateral malar area (in butterfly pattern) in back.

Q.5. How would a patient of subacute cutaneous lupus erythematosus (SCLE) present?

Ans. A patient with SCLE may present with:

- Non-scarring papulo-squamous eruptions in about two-thirds of cases
- Annular polycyclic lesions in approximately one-third of cases
  The borders of the lesions may display vesiculation, crusting, and occasionally bullae. As they heal, they often leave behind grey–white hypopigmentation and telangiectasia. Erythroderma, pityriasiform, and poikilodermatous lesions have also been observed **(Figs. 4A and B)**.

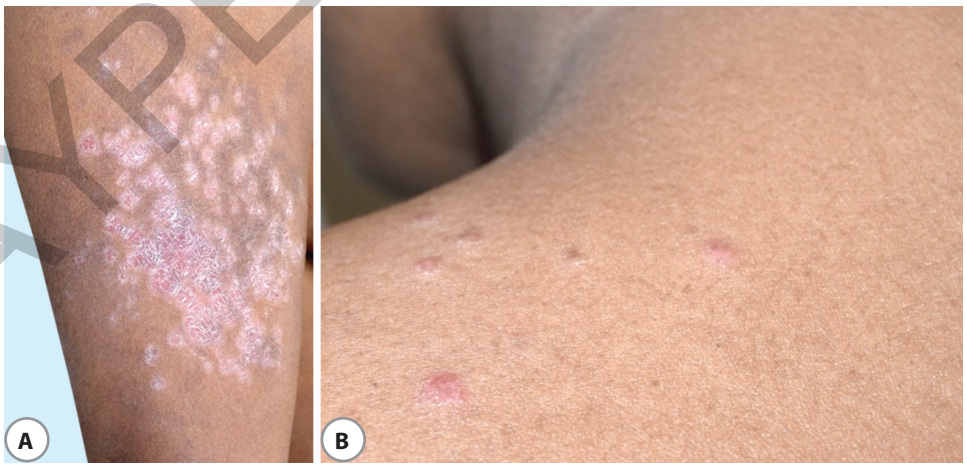

FIGS. 4A AND B: Erythematous scaly annular polycyclic plaques in subacute cutaneous lupus erythematosus (SCLE).

JAYPEE BROTHERS

Q.6. How do you evaluate neonatal LE?

Ans. History, review of systems and physical examination, and regular monitoring of growth and head circumference are essential to check for macrocephaly/hydrocephalus.

- *Laboratory studies:* Initial tests may include an electrocardiogram (ECG), echocardiogram, complete blood count (CBC) with differential and platelet count, and liver function tests. If these tests are normal and the infant shows no signs or symptoms, they should be repeated every 2–3 months for 2–3 cycles, or more frequently, if abnormalities are present.
- *Family counseling and care coordination:* It is important to discuss the risk of neonatal lupus erythematosus (NLE) in future pregnancies, the potential for autoimmune connective tissue disease (AI-CTD) in the mother, and possibly the child.

Pre-emptive treatment: For mothers of infants with cardiac NLE, consider prescribing hydroxychloroquine during subsequent pregnancies.

Long-term follow up the child with neonatal LE:

- *History and physical examination:* Periodic follow-ups as per pediatrician's recommendation
- *Laboratory studies:* If tests remain normal and the child remains healthy, further testing may not be necessary. However, monitoring for the potential development of AI-CTD during adolescence or adulthood is important.

Q.7. Describe the characteristic lesion of discoid lupus erythematosus (DLE).

Ans. It appears as single or multiple well demarcated red, scaly patch, or plaque of varying sizes, which eventually heal with atrophy, scarring, and pigmentation.

Presentation:

- *Localized DLE:* It is limited to the head and neck.
- *Disseminated DLE:* It is much more extensive disease, potentially affecting any area of the skin **(Figs. 5 and 6)**.



FIG. 5: Erythematous scaly plaque with surrounding hyperpigmentation.



FIG. 6: Hyperpigmented thick scaly plaques.

JAYPEE BROTHERS

Q.8. What is the tin-tack/cat tongue sign?

Ans. When the adherent scale is lifted, the surface beneath displays keratinous plugs that have filled the expanded pilosebaceous follicles. It is seen in DLE as well as pemphigus foliaceous.

Q.9. What is Shuster sign?

Ans. In patients with DLE, wide follicular pits are found in the concha or triangular fossa of the ear **(Fig. 7)**.



FIG. 7: Shuster sign of discoid lupus erythematosus (DLE) (wide follicular pits in concha).

Q.10. What is the risk of progression from DLE to SLE?

Ans. 5% cases of DLE whereas 20% cases of diffuse discoid lupus erythematosus (DDLE) show progression to SLE.

Q.11. What are dermoscopic findings in the lesion of DLE?

Ans. Branching and linear blood vessels, keratin plugging, perifollicular whitish halo, rosettes, and structureless brown and white areas are the dermoscopic findings in the lesion of DLE.

Q.12. How does tumid LE present?

Ans. Tumid LE presents as firm erythematous, indurated plaque resembling urticarial vasculitis typically lacking scale or follicular plugging on the face and trunk. Surface changes are minimal.

Q.13. When do you suspect lupus panniculitis?

Ans. It appears as indurated erythematous plaques on the face, scalp, upper arms, upper trunk, breasts, buttocks, and thighs, which may progress into disfiguring, depressed areas **(Fig. 8)**.

JAYPEE BROTHERS



FIG. 8: Lupus panniculitis.

Q.14. What is lupus profundus?

Ans. Discoid lesions overlying the panniculitis are referred to as lupus profundus.

Q.15. What is lupus pernio?

Ans. Chilblains lupus manifests as red or purplish papules and plaques on the toes, fingers, and occasionally on the nose, elbows, knees, and lower legs. These lesions are triggered or worsened by cold, especially cold moist environments.

Q.16. What is Aicardi Groutières syndrome?

Ans. Aicardi Groutières syndrome is a primarily autosomal recessive autoinflammatory disorder characterized by recurrent sterile fevers, progressive developmental delay, and chilblains due to mutations in *TREX1*, *SMAHD1*, *ADAR1*, *IFIH1*, and *RNASEH2A/B/C* genes.

Q.17. What is Rowell syndrome?

Ans. Rowell's syndrome refers to the occurrence of erythema multiforme-like lesions in conjunction with distinctive immunological features, such as a speckled pattern of antinuclear antibodies (ANA), the presence of anti-Ro or anti-La antibodies, and a positive rheumatoid factor in lupus patients. Major criteria include (1) LE—SLE, DLE, and SCLE; (2) erythema multiforme-like lesions (with/without involvement of the mucous membranes); (3) speckled pattern of ANA. Minor criteria were (1) chilblains, (2) anti-Ro antibody or anti-La antibody, and (3) positive RF. All three major criteria and at least one minor criterion is required for a diagnosis of RS **(Figs. 9A and B)**.

JAYPEE BROTHERS



FIGS. 9A AND B: (A) Acute cutaneous lupus erythematosus (ACLE) rash with lesions on palms hemorrhagic cheilitis and (B) erythematous.

Q.18. Discuss Kikuchi–Fujimoto disease.

Ans. Kikuchi–Fujimoto disease is a benign and typically self-limiting condition characterized by histiocytic necrotizing lymphadenitis of unknown etiology. The condition typically presents with tender lymphadenopathy, most often affecting the cervical lymph nodes, with fever, weight loss, and night sweats in more severe cases. Skin manifestations are usually nonspecific and may include erythematous papules, patches, plaques, and less commonly, nodules, bullae, or acneiform eruptions.

Q.19. What is Sneddon syndrome?

Ans. Sneddon syndrome is characterized by widespread livedo racemosa or livedo reticularis, accompanied by cerebrovascular lesions that lead to focal neurological symptoms or signs.

Q.20. How do you assess photosensitivity in the patient?

Ans. The American College of Rheumatology (ACR) defines photosensitivity as an atypical response to sunlight, as noted by the patient's history or the physician's observation. Photosensitivity does not strongly correlate with disease activity and may be linked to lower mortality rates. The severity of a photosensitive rash is assessed based on four factors: (1) The extent of the rash, (2) the degree of erythema, (3) the thickness of the lesions, and (4) the presence of scarring.

Q.21. What is the significance of fatigue in a patient with SLE?

Ans. Fatigue or reduced stamina is almost universally experienced by individuals with active lupus. It can often be the earliest sign of an impending flare and is frequently the first symptom to improve once the flare is managed. Fatigue that limits the ability to perform daily tasks or engage in recreational activities is considered severe fatigue. In SLE, a distinct pattern of fatigue is observed compared to other connective tissue diseases. In SLE, fatigue tends to be milder in the morning and worsens in the evening, whereas in conditions like scleroderma, the reverse is true.

JAYPEE BROTHERS

Q.22. What is the significance of weight loss in a patient with SLE?

Ans. Significant weight loss (greater than 10% of body weight over the past 6 months or 5% over the last 3 months, not related to dieting) is uncommon, even in patients with active disease, likely due to the use of steroids, which can increase appetite and weight. As a result, substantial weight loss should not be primarily attributed to SLE, but rather prompt investigation for other potential causes, such as hyperthyroidism, chronic infection, malabsorption, or inadequate food intake, malignancy, etc., should be done.

Q.23. What is the significance of fever in a patient with SLE?

Ans. Lupus-related fever is typically low-grade and rarely exceeds 102°F. A temperature above 102°F should prompt investigation for possible infection. In patients taking immunosuppressive medications, fever should be approached with caution, as these drugs may mask or reduce the fever. Additionally, infections are more likely to occur in immunosuppressed individuals, requiring special attention and management.

Q.24. What is lupus hair?

Ans. Broken and unruly hair along the front hairline, known as lupus hair, is a characteristic feature of nonscarring alopecia in SLE. This pattern of hair loss may be visible upon examination, even if the patient does not report any hair loss.

Q.25. Describe alopecia in SLE.

Ans. Alopecia in SLE may be *scarring* as in DLE or *nonscarring* as in telogen effluvium **(Fig. 10)**.

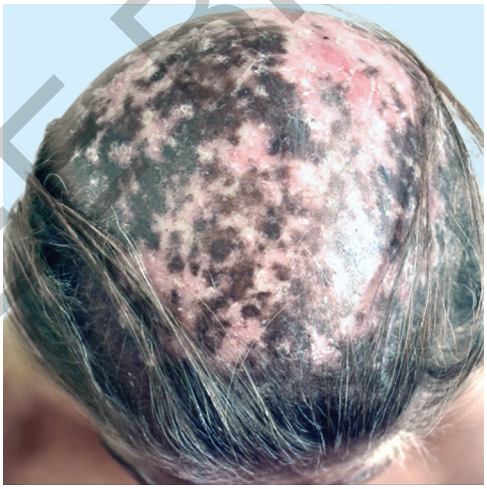

FIG. 10: Scarring alopecia in discoid lupus erythematous (DLE).

Q.26. Discuss mucosal lesions in SLE.

Ans. Painless oral, nasal, or genital ulcers may develop. They indicate a flare of disease activity **(Fig. 11)**.

JAYPEE BROTHERS

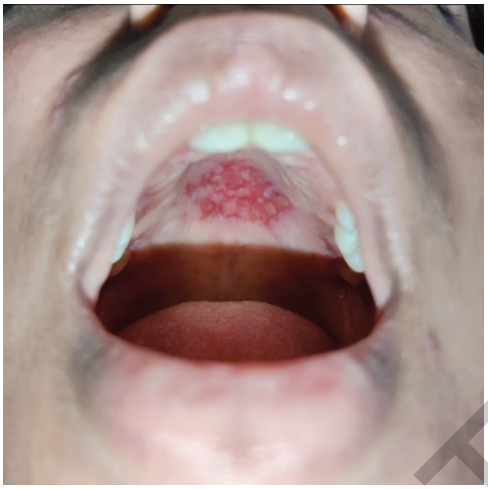

FIG. 11: Mucosal lesions of systemic lupus erythematosus (SLE) (erythematous erosions over hard palate).

Q.27. How does vasculitis present in SLE?

Ans. Vasculitis typically presents as small-vessel leukocytoclastic vasculitis, characterized by palpable petechiae or purpura in dependent areas. When medium **(Figs. 12A and B)** or large vessels are involved, it may appear as retiform or stellate purpura, with or without necrosis and ulceration or as subcutaneous nodules. Additional symptoms may include gangrene, periungual infarcts, splinter hemorrhages, as well as urticarial and bullous lesions **(Table 2)**.

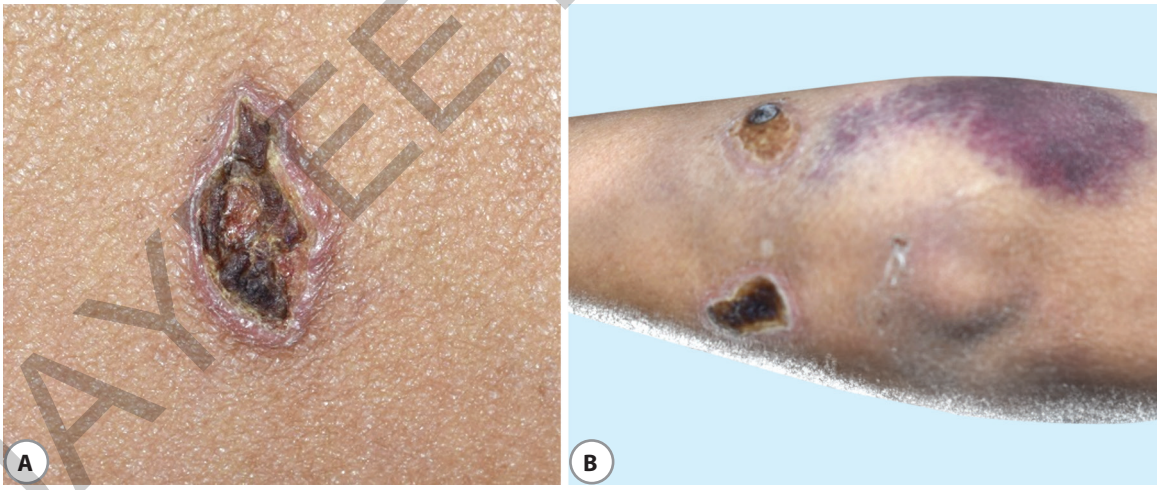

FIGS. 12A AND B: Medium vessel vasculitis: Irregularly shaped punched out ulcers with necrotic base and ecchymosis over leg.

JAYPEE BROTHERS

TABLE 2: Vascular manifestations of systemic lupus erythematosus (SLE).	
Manifestations	**Vessel involved and site**
Leukocytoclastic angitis (urticaria and palpable purpura)	Postcapillary venules and upper dermis
Atrophie blanche	Small vessels, middle and lower dermis
Subcutaneous nodules	Medium-sized arteries, panniculitis, and lower dermis
Livedo reticularis	Medium-sized arteries, panniculitis and lower dermis
Coronary arteritis	Coronary arteries
Mononeuritis multiplex	Vasa nervorum
Cerebral infarcts	Primary small vessels
Mesenteric infarcts	Small and medium-sized arteries
Retinopathy	Arterioles and venules

Q.28. How to differentiate drug-induced SCLE from drug-induced LE?

Ans. Differences between drug-induced SCLE and drug induced LE are given in **Table 3**.

TABLE 3: Differences between drug-induced (DI) subacute cutaneous lupus erythematosus (SCLE) and drug induced lupus erythematosus (LE).		
	DI-SCLE	**DI-SLE**
Drugs responsible	Terbinafine, griseofulvin, proton pump inhibitors (such as omeprazole, lansoprazole, and pantoprazole), ranitidine, thiazide diuretics (like hydrochlorothiazide), calcium channel blockers (e.g., diltiazem, nifedipine, and verapamil), ACE inhibitors (e.g., enalapril and lisinopril), β-blockers, statins, antiepileptics (e.g., carbamazepine), and TNF-α inhibitors	Hydralazine, procainamide, isoniazid, quinidine, methyldopa, chlorpromazine, minocycline, and TNF-α inhibitors
Cutaneous findings	++	+/-
Systemic findings	Usually absent, athralgias	Serositis (arthralgia, pleuritis, and pericarditis) Fever, weight loss, and myalgia
Associated auto-antibodies	Anti Ro/SSA	• Anti-histone, • Anti-dsDNA (reported with TNF-α inhibitor)

(ACE: angiotensin-converting enzyme; DNA: deoxyribonucleic acid; TNF: tumor necrosis factor)

Q.29. Discuss laboratory evaluation of patient with SLE.

Ans. Laboratory evaluation of patient with SLE is given in **Table 4**.

TABLE 4: Laboratory evaluation of patient with systemic lupus erythematosus.	
Parameter	**Alteration**
• Hemoglobin—anemia • DCT, and ICT	• Anemia of chronic disease • Iron deficiency anemia • Autoimmune hemolytic anemia • Drug-induced myelotoxicity

Continued

JAYPEE BROTHERS

Continued

Parameter	Alteration
	• Anemia of chronic renal disease • Pure red cell aplasia • Aplastic anemia • Reactive hemophagocytic syndrome
White blood cells	• Leukopenia • Lymphopenia
Platelets	Thrombocytopenia
ESR and CRP	Raised
• RFT with electrolytes • Urine protein to creatinine ratio • 24-hour urinary protein	>100 mg/24 hours
LFT	Hypoproteinemia
URM (3 or more days prior to or after cessation of menstrual periods)	• Proteinuria, hematuria • Dysmorphic (irregular or fragmented) erythrocytes suggest inflammatory glomerular or tubulointerstitial disease, while monomorphic (normal) erythrocytes point to bleeding in the lower urinary tract, such as from infection, urolithiasis, or tumors. Granular and fatty casts are typically seen in proteinuric conditions, while red blood cells (RBCs), white blood cells (WBCs), and mixed cellular casts are associated with inflammatory (nephritic) states. Broad and waxy casts are indicative of chronic renal failure
Immunoglobulins	Polyclonal gammopathy
C3, C4	Hypocomplementemia
CXR	
ECG, 2D echocardiogram	
Biopsy and direct immunofluorescence	
Fundoscopy, perimetry, and visual acuity assessment	Ophthalmological screening before starting hydroxychloroquine

(CRP: C-reactive protein; CXR: chest X-ray; DCT: direct Coombs test; ECG: electrocardiogram; ESR: erythrocyte sedimentation rate; ICT: indirect Coombs test; LFT: liver function test; RFT: renal function test)

Q.30. Discuss the various stages of lupus nephritis.

Ans. The various stages of lupus nephritis are given in **Table 5**.

TABLE 5: Characteristic features and clinicopathological correlations in lupus nephritis.

	World Health Organization (WHO) class of lupus nephritis					
	I. Minimal	**II. Mesangial**	**III. FPLN**	**IV. DPLN**	**V. Membranous**	**VI. Sclerosing**
Normal urine	X					
Hematuria		X	X	X	+	
Cellular casts			X	X		
Broad, waxy casts			+	+	+	X

Continued

JAYPEE BROTHERS

Continued

	World Health Organization (WHO) class of lupus nephritis					
	I. Minimal	**II. Mesangial**	**III. FPLN**	**IV. DPLN**	**V. Membranous**	**VI. Sclerosing**
Proteinuria		+	X	X	X	+
Nephrotic syndrome				X	X	
Azotemia				X	+	X
Hypertension				X	+	X

(FPLN: focal proliferative lupus nephritis; DPLN: diffuse proliferative lupus nephritis)

- *Normal or minimal glomerular abnormality:* No glomerular changes were observed under light microscopy.
- *Mesangial nephropathy:* It features mesangial expansion, including increased cellularity, matrix, and immune complex deposits.
- *Focal proliferative glomerulonephritis:* It is characterized by segmental hypercellularity and necrosis affecting <50% of glomeruli, leading to compromised capillary loop circulation and mesangial and subendothelial immune complex deposits.
- *Diffuse proliferative glomerulonephritis:* Typically, it exhibits global yet irregular hypercellularity, necrosis, and possible cellular crescents in >50% of glomeruli; may include sclerosis, atrophy, and fibrosis, with mesangial, subendothelial, and sometimes subepithelial immune complex deposits.
- *Membranous nephropathy:* It is marked by diffuse thickening of capillary loops, with immune complex deposits in the mesangium and subepithelial regions.
- *Sclerosing nephropathy:* It predominantly involves hyalinized glomeruli, tubular atrophy, and interstitial fibrosis, with little to no immune complex deposits.

Q.31. What are extractable nuclear antigens (ENAs)?

Ans. Extractable nuclear antigens are soluble cytoplasmic and nuclear components that are antibody targets with over 100 different antigens described.

Extractable nuclear antigen-4 and its importance: The concept of "ANA-negative lupus" originated from older, less sensitive testing methods and cross-sectional studies, where ANA titers can fluctuate over time and may become negative with treatment. Modern assays using human epithelial cells show that nearly all patients with clinical SLE test positive for ENAs, even if their ANA is negative, and most ANA-negative individuals will have had a positive ANA at some point. However, once ANA levels are documented, tracking titers is not useful for monitoring disease activity. Similarly, specific antibodies such as anti-Ro (anti-SSA), anti-La (anti-SSB), anti-SM, anti-RNP, and anticardiolipin (ACL) antibodies can aid in diagnosis but do not provide insight into whether the disease is currently active.

Q.32. What is ANA-negative lupus?

Ans. A positive ANA test is essential for diagnosing SLE. "ANA-negative lupus", previously thought to represent up to 5% of SLE cases, refers to clinical lupus without typical autoantibodies. In the past, sera from SLE patients could test negative on rodent cells, particularly when the predominant antibodies were those associated with anti-Ro/SSA, seen in conditions such as SCLE and Sjögren's syndrome (SIS). However, with the use of human Hep-2 cells for testing, only about 1–2% of SLE patients now show negative ANA results. As a result, "ANA-negative SLE" is largely considered a historical concept.

JAYPEE BROTHERS

Q.33. What is relevance of ANA-titer?

Ans. Relevance of ANA-titer is given in **Tables 6 and 7**.

TABLE 6: Antinuclear antibody (ANA) titers and their clinical significance.

Titer	Significance
<1:40–1:80	Insignificant
1:160 or greater	AI-CTD, 5% of normal individuals
Negative	1-2% cases of SLE

(AI-CTD: autoimmune connective tissue disease; SLE: systemic lupus erythematosus)

TABLE 7: Correlation of antinuclear antibody (ANA) titers and pattern with autoimmune connective tissue disease.

ANA pattern	Disease
Peripheral/Rim	SLE
Homogenous	SLE
Nucleolar	PSS
Fine speckled	SLE, PSS, MCTD, Sjögren's
Coarse speckled	CREST

(CREST: calcinosis, Raynaud's phenomenon, esophageal dysmotility, sclerodactyly, and telangiectasia; MCTD: mixed connective tissue disease; PSS: progressive systemic sclerosis; SLE: systemic lupus erythematosus)

Q.34. Discuss relevance of various ANAs.

Ans. The relevance of various ANAs is given in **Table 8**.

- *Anti-deoxyribonucleic acid (DNA) antibodies:*
  - These are the most well-known specific autoantibodies identified in patients with SLE.
  - Antibodies targeting DNA can be classified into two main types: (1) Those that react with denatured (single-stranded) DNA and (2) those that bind to native (double-stranded) DNA.
  - They are relatively specific (97%) for SLE, making them very useful for diagnosis.
  - *Titers rise when disease is active* and usually fall (generally into the normal range) when the flare subsides.
  - High levels of IgG anti-dsDNA titers are known to be associated with active *glomerulonephritis*; there also appear to be highly enriched amounts of anti-dsDNA antibodies in the glomerular deposits of immune complexes found in patients with lupus nephritis.
- *Anti-Smith antibodies:*
  - The Smith antigen, a nuclear nonhistone protein, was identified in 1966 and was the first nuclear protein autoantigen associated with SLE.
  - Complexes formed by nuclear proteins and RNAs are known as small nuclear ribonucleoprotein particles (snRNPs), which play a crucial role in the splicing of precursor messenger RNA, an essential step in RNA processing from DNA.
  - Anti-Sm antibodies are not highly sensitive (18–30%, depending on the assay) but are highly specific for SLE. These antibodies typically remain detectable even when anti-DNA antibody levels return to normal and the clinical activity of SLE diminishes. Therefore, measuring anti-Sm titers can be diagnostically useful, especially when DNA antibodies are no longer detectable.

JAYPEE BROTHERS

- *Antihistone antibodies*: Up to 80% of individuals with SLE and as many as 95% of those with drug-induced lupus erythematosus (DIL) exhibit autoantibodies against histone proteins. The presence of antihistone antibodies provides strong, statistically significant evidence that a patient's symptoms are attributable to DIL.
- *Anti-RNP antibodies:*
  - These antibodies target proteins that contain only U1-RNA. The U1-RNP particle plays a key role in splicing heterogeneous nuclear RNA into messenger RNA.
  - While anti-RNP antibodies are not specific to SLE, they are a hallmark of the related condition known as mixed connective tissue disease.
- *Anti-Ro/Anti-SSA antibodies*: These antinuclear antibodies target cellular proteins with molecular weights of approximately 52 and 60 kDa. The 60 kDa protein is associated with the HY1-5 species of small nuclear RNAs.
  They are frequently found in patients with SLE as well as those with Sjögren's syndrome.
- *Antibodies to ribosomal P proteins:*
  - The targets of these antibodies are three phosphoproteins phloem-specific protein (P proteins) located on the 60S subunit of ribosomes.
  - These antibodies are believed to play a role in protein synthesis, particularly in the interaction between EF-1α, EF-2, and ribosomes.
  - *Ribosomal P protein antibodies and lupus cerebritis:* The presence of ribosomal P protein antibodies has been strongly linked to lupus cases involving psychosis and/or depression.
  - *Antibodies to ribosomal P protein and non-CNS lupus–renal disease:* Some studies have found an association between anti-ribosomal P antibodies and lupus nephritis, including fluctuations in antibody levels corresponding to changes in renal disease activity. However, other studies have not observed such a connection.
  - An association between anti-ribosomal P protein antibodies and antibodies to cardiolipin has been reported, though it remains unclear whether the co-occurrence of these antibodies increases the risk of neuropsychiatric symptoms.
- *Antiphospholipid*: Antiphospholipid antibodies, such as lupus anticoagulants (LAS), ACL antibodies, and β_2 glycoprotein I antibodies are known causes of thromboembolic phenomenon, thrombocytopenia, and several adverse obstetrical outcomes.

TABLE 8: Antinuclear antibody (ANA) in various autoimmune connective tissue disease.

Antibodies to	SLE	Sjögren's	SS	DM-PM	MCTD
Ds DNA	+	–	–	–	–
U1RNP	+	–	+	+	+
Sm	+	–	–	–	–
SS-A/Ro	+	+	–	–	–
SS-B/La	+	+	–	–	–
Scl-70	–	–	+	–	–
Centromere	–	–	+	–	–
DM/PM antigens (Jo-1, Mi2, and PI-7)	–	–	–	+	–

(SLE: systemic lupus erythematosus; SS: systemic sclerosis; DM: dermatomyositis; PM: polymyositis; MCTD: mixed connective tissue disease)

JAYPEE BROTHERS

Q.35. What are "LE cells"?

Ans.

- LE cells are polymorphonuclear leukocytes that have engulfed nuclear material from disintegrating white blood cells in the presence of antibodies against deoxyribonucleoprotein. This is also referred to as the "LE phenomenon".
- LE cells are found in SLE, chronic DLE, systemic sclerosis, rheumatoid arthritis, DIL.

Q.36. What is lupus band test?

Ans. Deposition of immunoglobulin generally IgM and IgG and/or complement at the dermoepidermal junction in patient with LE is known as lupus band test **(Table 9)**.

- *IgG, IgM, IgA, and C3:* Most common
- *85%:* Multiple immune deposits
- *45%:* IgG and lg M+/-C3
- *Patterns:* Linear, granular, and shaggy
- The intensity of fluorescence is directly related to the levels of dsDNA antibodies and thus reflects the activity of the disease.

TABLE 9: Lupus band test in various subtypes of lupus.

Subtype	Lesional	Nonlesional sun exposed	Nonlesional nonsun exposed
SLE	++	++	++
SCLE	+	+/–	–
DLE	+	–	–

(DLE: discoid lupus erythematosus; SCLE: subacute cutaneous lupus erythematosus; SLE: systemic lupus erythematosus)

Q.37. What are the 2019 EULAR criteria for the diagnosis of SLE?

Ans.

Entry criterion: ANA of ≥ 1;80 on Hep-2 cells or an equivalent positive test

- *If absent:* Do not classify as SLE.
- *If present:* Apply additive criteria.

Additive criteria:

- Occurrence of a criterion at any one occasion is sufficient.
- Criteria need not occur simultaneously.
- SLE classification requires at least one clinical criterion and a score of >10.
  Classify as SLE if the entry criterion is fulfilled and there is a score of 10 or more **(Tables 10 and 11)**.

TABLE 10: Criteria and weighting system for clinical domains in systemic lupus erythematosus (SLE) diagnosis.

Clinical domain	Criteria	Weight
Constitutional	Fever	2
Hematological	• Leukopenia • Thrombocytopenia • Autoimmune hemolysis	3 4 4
Neuropsychiatric	• Delirium • Psychosis • Seizures	2 3 5

Continued

JAYPEE BROTHERS

Continued

Clinical domain	Criteria	Weight
Mucocutaneous	• Nonscarring alopecia • Oral ulcers • SCLE/DLE • ACLE	2 2 4 6
Serositis	• Pleural/Pericardial effusion • Acute pericarditis	5 6
Musculo-skeletal	Joint involvement	6
Renal	• >0.5 g/24 hours proteinuria • Renal biopsy class II or V nephritis • Renal biopsy class III or IV nephritis	4 8 10

(ACLE: acute cutaneous lupus erythematosus; DLE: discoid lupus erythematosus; SCLE: subacute cutaneous lupus erythematosus)

TABLE 11: 2019 EULAR criteria for the diagnosis of systemic lupus erythematosus (SLE).[1]

Immunological domain	Criteria	Weight
Antiphospholipid antibodies	• Anticardiolipin • Anti-beta-2 glycoprotein-1 • Lupus anticoagulant	2
Complement proteins	• Low C3 or low C4 • Low C3 and low C4	3 4
SLE-specific antibodies	• Anti-ds-DNA antibody or • Anti-Smith antibody	6

(DNA: deoxyribonucleic acid; EULAR: The European Alliance of Associations for Rheumatology)

Q.38. What are clinical and immunologic criteria used in the Systemic Lupus International Collaborating Clinics (SLICC) classification system?

Ans.

Clinical criteria:

- *ACLE, including*:
  - Lupus malar rash (do not count if malar discoid)
  - Bullous lupus
  - Toxic epidermal necrolysis variant of SLE
  - Maculopapular lupus rash
  - Photosensitive lupus rash in the absence of dermatomyositis
- SCLE (nonindurated psoriasiform and/or annular polycyclic lesions that resolve without scarring, although occasionally with postinflammatory dyspigmentation or telangiectasias)
- *Chronic cutaneous lupus, including*:
  - Classic discoid rash
  - Localized (above the neck)
  - Generalized (above and below the neck)
  - Hypertrophic (verrucous) lupus
  - Lupus panniculitis (profundus)
  - Mucosal lupus
  - Lupus erythematosus tumidus

JAYPEE BROTHERS

- Chilblains lupus
- Discoid lupus/lichen planus overlap

- *Oral ulcers*:
  - Palate
  - Buccal
  - Tongue
  - Nasal ulcers in the absence of other causes, such as vasculitis, Behçet's disease, infection (herpes virus, inflammatory bowel disease, reactive arthritis, and acidic foods
- Non-scarring alopecia (diffuse thinning or hair fragility with visible broken hairs) in the absence of other causes such as alopecia areata, drugs, iron deficiency, and androgenic alopecia
- Synovitis involving two or more joints, characterized by swelling or effusion or tenderness in two or more joints and at least 30 minutes of morning stiffness
- *Serositis*:
  - Typical pleurisy for >1 day; or pleural effusions; or pleural rub
  - Typical pericardial pain (pain with recumbency improved by sitting forward) for more than 1 day pericardial effusion; or pericardial rub; or pericarditis by electrocardiography in the absence of other causes, such as infection, uremia, and Dressler's pericarditis
- *Renal:*
  - Urine protein-to-creatinine ratio (or 24-hour urine protein) representing 500 mg protein/24 hours
  - Red blood cell casts
- *Neurologic:*
  - Seizures
  - Psychosis
  - Mononeuritis multiplex (In the absence of other known causes such as primary vasculitis)
  - Myelitis
  - Peripheral or cranial neuropathy the absence of other known causes such as primary vasculitis, infection, and diabetes mellitus
  - Acute confusional state
  - In the absence of other causes, including toxic/metabolic, uremia, and drugs
- Hemolytic anemia
- Leukopenia (–4,000/mm^3 at least once) in the absence of other known causes such as Felty's syndrome, drugs, and portal hypertension
- Lymphopenia (–1,000/mm^3 at least once) in the absence of other known causes such as corticosteroids, drugs, and infection.
- Thrombocytopenia (–100,000/mm^3) at least once in the absence of other known causes such as drugs, portal hypertension, and thrombotic thrombocytopenic purpura.

Immunologic criteria:

- ANA level above laboratory reference range
- Anti-dsDNA antibody level above laboratory reference range or 2-fold the reference range if tested by enzyme-linked immunosorbent assay (ELISA)
- *Anti-Sm:* Presence of antibody to Sm nuclear antigen
- *Antiphospholipid antibody positivity as determined by any of the following*:
  - Positive test result for lupus anticoagulant
  - False-positive test result for rapid plasma regain
  - Medium- or high-titer ACL antibody level (IgA and IgG) or IgM
  - Positive test result for anti-beta-2 glycoprotein I (IgA, IgG, or IgM)

JAYPEE BROTHERS

- *Low complement*:
  - Low C3
  - Low C4
  - Low CH50
- Direct Coombs test positive in the absence of hemolytic anemia

Note: The patient must satisfy *at least 4 criteria*, including at least one clinical criterion and one immunologic criterion or the patient must have biopsy-proven lupus nephritis in the presence of ANA or anti-dsDNA antibodies.[2]

Q.39. What are the differences between pediatric and adult SLE?

Ans. The clinical presentation, progression, and treatment are similar to those in adults; however, children generally experience a more acute and severe form of the disease.

Onset of pediatric SLE is described even in children younger than 2 years of age.

- The F/M ratio with pediatric SLE ranges from 4:3 with disease onset during the first decade of life to 4:1, during the second decade, to 9:1 in adult SLE, and decreases to 5:1 in SLE commencing after the age of 50 years.
- At disease onset, fever, malar rash, vasculitis, and arthralgia are found more common in childhood LE.
- Lupus nephritis, hematological disorders, photosensitivity, butterfly rash, and mucosal ulceration are more common in pediatric LE.
- Childhood SLE is more frequently associated with neurological symptoms, renal involvement is more severe, and also enlargement of the liver, spleen, and lymph nodes is frequent.
- Cardiovascular mortality is more prevalent in adult SLE, and in children, mortality is more due to renal cause.
- Anti-SSA, anti-SSB, and antiphospholipid antibodies are found at notably higher levels in adults with SLE compared to pediatric patients.
- Children are more frequently treated with high-dose intravenous immunoglobulin and mycophenolate mofetil than adults.
- These differences highlight that pediatric and adult-onset lupus exhibit distinct characteristics, underscoring the need to recognize these variations to ensure the best treatment and prognosis for each group.

Q.40. What are the causes of death in systemic lupus erythematosus?

Ans. Deaths related to SLE often occur within the first 5–10 years after the onset of symptoms.

- During the early stages of the disease, mortality is typically due to severe SLE manifestations, such as central nervous system (CNS), renal, or cardiovascular involvement, or complications from infections caused by immunosuppressive treatments.
- In contrast, later deaths, typically after age 35 years, are usually linked to myocardial infarction or stroke, which are a result of accelerated atherosclerosis. The presence of lupus nephritis may further elevate these risks.

Q.41. What are the predictors of systemic disease in patients with DLE?

Ans.

- Generalized DLE lesions, i.e., DDLE
- Palmoplantar DLE
- DLE in setting of genetic complement deficiencies

JAYPEE BROTHERS

- DLE associated with constitutional symptoms
- DLE associated with acute phase reactants or complement activation
- DLE with an ANA at significant titers (fine speckled >1:320)
- DLE with a specific ANA (anti-Sm and Ro)
- DLE in male patients

Q.42. How to differentiate CNS lupus flare from corticosteroid-induced psychiatric reactions?

Ans. Differences between CNS lupus flare and corticosteroid-induced psychiatric reactions are given in **Table 12**.

TABLE 12: Difference between central nervous system (CNS) lupus flare and corticosteroid-induced psychiatric reaction

	CNS lupus flare	Corticosteroid-induced psychiatric reactions
Onset	After decrease in steroid-dose or ongoing low-dose treatment	Generally, 2 weeks after corticosteroid dosage
Corticosteroid dosage (mg/kg of prednisolone)	Variable	• Common if ≥ 60 mg/day • Rare if <40 mg/day
Psychiatric manifestations	Psychosis, delirium, mood disorders, and cognitive impairment (new onset)	Mania, mixed states, depression (often with mood disorders and psychotic features), psychosis, and delirium
Systemic SLE symptoms	Often present, coincide with onset of psychiatric symptoms	Often present, but precede onset of psychiatric symptoms
Laboratory evaluation	Indices of inflammation	No specific lab findings
Quantitative brain MRI	White matter changes, micro-infarcts, and cortical atrophy	No specific findings
Response to corticosteroid trial	Improvement	Exacerbation or persistence of symptoms

Q.43. Explain lupus foot.

Ans. Lupus foot is a deforming arthropathy of the feet in SLE.

- It includes hallux valgus, subluxation of the metatarsophalangeal joints, and widening of the forefoot.

Q.44. How will you evaluate pregnant women with autoimmune disorders?

Ans. Initial screening is done by ELISA in first trimester **(Flowchart 2)**.

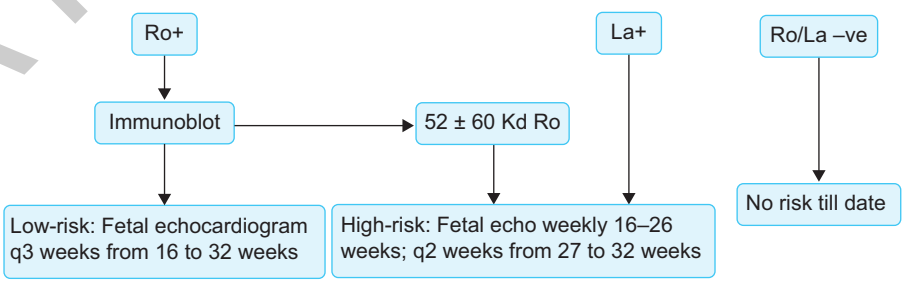

FLOWCHART 2: Evaluation of pregnant women with autoimmune disorders.

JAYPEE BROTHERS

REFERENCES

1. Fanouriakis A, Kostopoulou M, Andersen J, Aringer M, Arnaud L, Bae SC, et al. EULAR recommendations for the management of systemic lupus erythematosus: 2023 update. Ann Rheum Dis. 2024;83:15-29.
2. Petri M, Orbai AM, Alarcón GS, Gordon C, Merrill JT, Fortin PR, et al. Derivation and validation of the Systemic Lupus International Collaborating Clinics classification criteria for systemic lupus erythematosus. Arthritis Rheum. 2012;64(8):2677-86.

JAYPEE BROTHERS

for detailed information on dermatology books, visit our website www.ejaypee.com, for detailed information on dermatology books, visit our website www.ejaypee

Ward Rounds in DERMATOLOGY

Salient Features

- *Student-friendly approach:* Cases are presented in an easy-to-read format, with a special emphasis on history-taking and clinical examination, followed by a Q & A discussion.
- It is a complete guide for junior residents attending to in-patient department (IPD) patients.
- The book is a ready reckoner for long case presentation in practical examination.
- *Enhanced visual learning:* It includes clinical photographs and tables that provide visual insights, concise information making complex concepts more clear and easy to understand.
- *Ideal for viva preparation:* It is an excellent companion for students preparing and revising for viva voce examinations, helping them to consolidate key concepts efficiently.
- *Expanded case collection:* A wider range of clinical cases has been added, enriching the material from the previous edition and providing a broader learning experience.
- *Updated management strategies:* Features the latest advancements in medical management and therapy, along with relevant clinical cases to ensure the information is recent and practical as well.
- *Comprehensive clinical guidance:* Designed to serve as an enriching tool for understanding how to approach clinical cases, while reinforcing core clinical concepts for students and professionals alike.
- *Rapid revision tool:* It is a useful guide for quick revision of essential topics and treatment protocols, and is suitable for both students and consultants.

Bela J Shah MD is a Professor at GCS and RC Medical College, Ahmedabad (Gujarat) and formerly served as a Professor and Head, Department of Dermatology, Sexually Transmitted Infections (STIs), and Leprosy at BJ Medical College and Civil Hospital, Ahmedabad, Gujarat, India. With over 36 years of teaching experience, she has made significant contributions to clinical dermatology, medical education, and research. She has authored textbooks titled—An Atlas Illustrating HIV in Dermatology, An Atlas on Dermatophytoses, Comprehensive Textbook on Acne, and Textbook on Psoriasis. She has published more than 350 national and 9 international research articles, and has presented her work at global conferences including EADV (Vienna, 2007), the World Congress of Dermatology (Vancouver, 2015), and the International Congress of Dermatology (New Delhi, 2013). She has been reviewer for the Indian Journal of Dermatology, Venereology, and Leprology (IJDVL), Indian Dermatology Online Journal (IDOJ), and other prominent journals. Her clinical research includes over 50 investigator-initiated and industry-sponsored clinical trials on acne, vitiligo, psoriasis, urticaria, leprosy, atopic dermatitis, and HIV-related dermatological disorders. Her key areas of interest include immuno-dermatology, leprosy, and targeted therapies.

Santosh Rathod MD(Skin & VD) DNB is a Professor, Department of Dermatology, Venereology and Leprosy, at Smt NHL Municipal Medical College, Ahmedabad (Gujarat) and Deputy Medical Superintendent of SCL General Hospital, Ahmedabad, Gujarat, India. He is a Gold Medalist in Dermatology, Venereology, and Leprosy from Gujarat University. He has received prestigious Professor Emrich Sarkany Scholarship from European Academy of Dermatologists and Venereologists (EADV) and Dr PB Haribhakti Oration for his work in leprosy. He is currently Honorary Secretary of Indian Association of Leprologists (IAL). He is the co-author of the book titled "Ward Rounds in Dermatology" 1st edition, "Atlas of Leprosy" by CRC Press, and Associate Editor of "IADVL Practical Manual of leprosy". He has keen interest in clinical dermatology, "autoimmune connective tissue diseases" and teaching clinical methods to the students.

Shelving Recommendation
DERMATOLOGY

ISBN 978-93-6616-772-5

9 789366 167725

Buy from ejaypee

JAYPEE BROTHERS