r detailed information on anatomy books, visit our website www.ejaypee.com, for detailed information on anatomy books, visit our website www.ejaypee.com,

HISTOLOGY
PRACTICAL WORKBOOK

(Comparative Microscopic Features Included)

As per the Revised Competency-based Medical Education Curriculum (NMC)

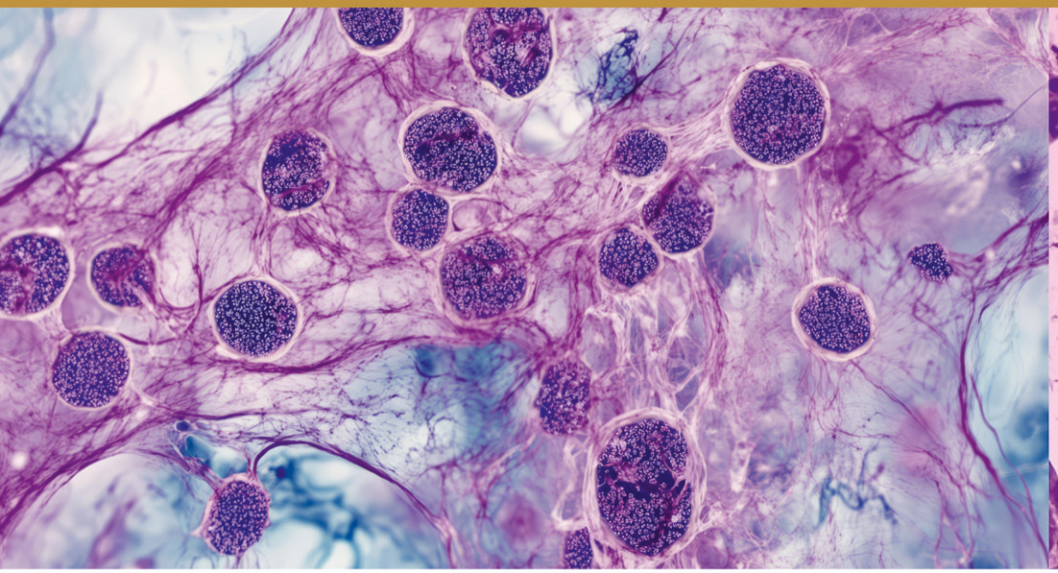

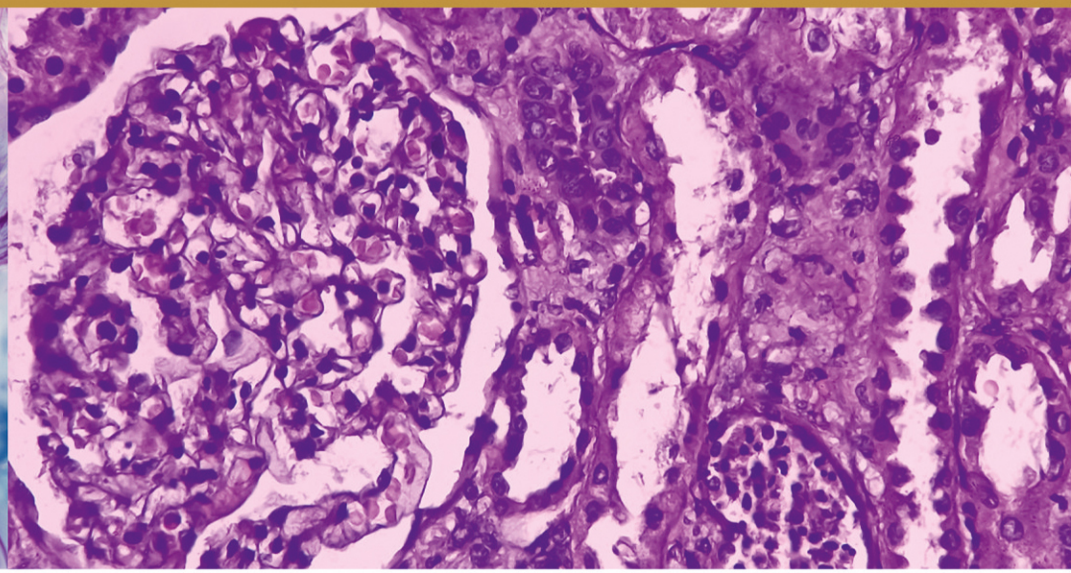

Balakrishna Shetty
Sweekritha H Poonja

Foreword
Chitra Prakash Rao

JAYPEE

CONTENTS

1. Simple Epithelium **1–4**
2. Stratified Epithelium **5–16**
   - A. Stratified Squamous (Non-Keratinized)
   - B. Stratified Squamous (Keratinized)
   - C. Transitional Epithelium
3. Connective Tissue **17–20**
4. Connective Tissue Fibers **21–24**
5. Adipose Tissue **25–28**
6. Hyaline Cartilage **29–32**
7. Elastic Cartilage **33–36**
8. White Fibrocartilage **37–40**
9. Bone—Transverse Section **41–44**
10. Bone—Longitudinal Section **45–48**
11. Cancellous Bone **49–52**
12. Skeletal Muscle **53–56**
13. Cardiac Muscle **57–60**
14. Smooth Muscle **61–64**
15. Peripheral Nerve—Transverse Section **65–68**
16. Peripheral Myelinated Nerve **69–72**
17. Optic Nerve—Transverse Section **73–76**
18. Sympathetic Ganglion **77–80**
19. Dorsal Root Ganglion/Spinal Ganglion **81–84**
20. Large Artery/Elastic Artery **85–88**
21. Medium-sized Artery/Muscular Artery **89–92**
22. Large Vein **93–96**
23. Medium-sized Vein **97–100**
24. Capillaries and Sinusoids **101–104**
25. Lymph Node **105–108**
26. Spleen **109–112**
27. Tonsil **113–116**
28. Thymus **117–120**
29. Serous Salivary Gland **121–124**
30. Mucus Salivary Gland **125–128**
31. Mixed Salivary Gland **129–132**
32. Thick Skin **133–136**
33. Thin Skin **137–140**
34. Hair **141–144**
35. Trachea **145–148**
36. Lung **149–152**
37. Epiglottis **153–156**
38. Lip **157–160**
39. Tongue **161–168**
    - A. Filiform and Fungiform Papillae
    - B. Circumvallate Papillae
40. Tooth **169–172**
41. Esophagus **173–176**
42. Stomach: Fundus and Body **177–180**
43. Stomach: Pylorus **181–184**
44. Duodenum **185–188**
45. Jejunum **189–192**
46. Ileum **193–196**
47. Large Intestine **197–200**
48. Appendix **201–204**
49. Liver **205–208**
50. Gallbladder **209–212**
51. Pancreas **213–216**
52. Kidney **217–220**
53. Ureter **221–224**
54. Urinary Bladder **225–228**
55. Prostatic Urethra **229–232**

56. Testis **233–236**
57. Epididymis **237–240**
58. Ductus Deferens/Vas Deferens **241–244**
59. Prostate **245–248**
60. Seminal Vesicle **249–252**
61. Ovary **253–256**
62. Uterus **257–264**
    A. Proliferative
    B. Secretory
63. Fallopian Tube **265–268**
64. Mammary Gland **269–280**
    A. Inactive Stage
    B. In Pregnancy
    C. In Lactation
65. Umbilical Cord **281–284**
66. Placenta **285–288**
67. Pituitary Gland **289–292**
68. Suprarenal/Adrenal Gland **293–296**
69. Thyroid and Parathyroid **297–300**
70. Cornea **301–304**
71. Corneoscleral Junction **305–308**
72. Retina **309–312**
73. Eyelid **313–316**
74. Organ of Corti **317–320**
75. Cerebrum **321–324**
76. Cerebellum **325–328**
77. Spinal Cord **329–332**

2. STRATIFIED EPITHELIUM

2(A): Stratified Squamous

– Non-keratinized

Contains many layers of cells with basal layer resting on a basement membrane

Stratified squamous non-keratinized—contains basal layer of columnar cells, middle layers of polygonal cells and superficial layers of flattened cells.

Example: Mucosal lining of esophagus and oral cavity.

JAYPEE BROTHERS

2(A). STRATIFIED SQUAMOUS (NON-KERATINIZED)

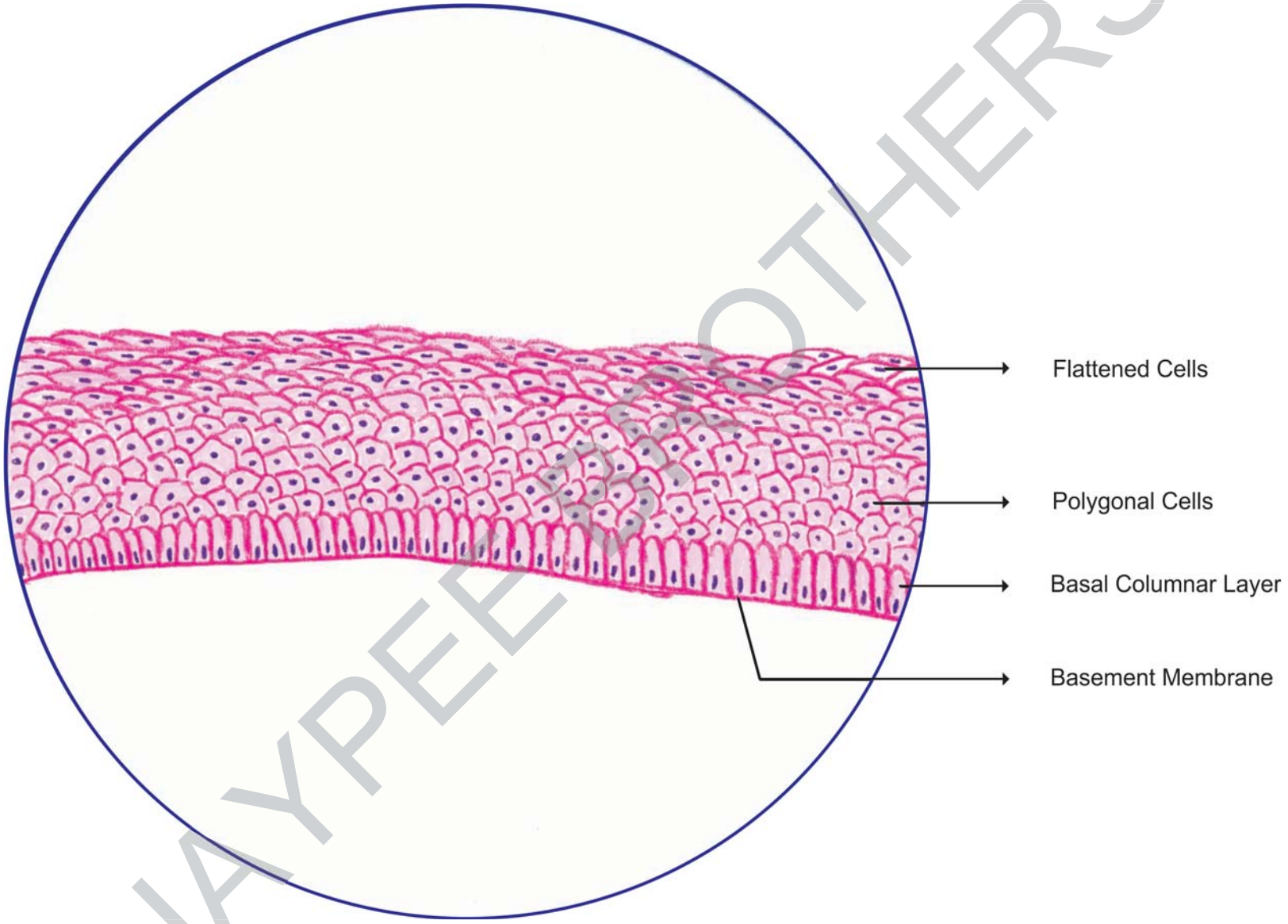

JAYPEE BROTHERS

JAYPEE BROTHERS

JAYPEE BROTHERS

2. STRATIFIED EPITHELIUM

2(B): Stratified Squamous

– Keratinized

Stratified squamous keratinized—contains basal layer of columnar cells, middle layers of polygonal cells and superficial layers of flattened cells which are keratinized. Topmost layer contains dead cells without nucleus filled with keratin.

Example: Skin.

JAYPEE BROTHERS

2(B). STRATIFIED SQUAMOUS (KERATINIZED)

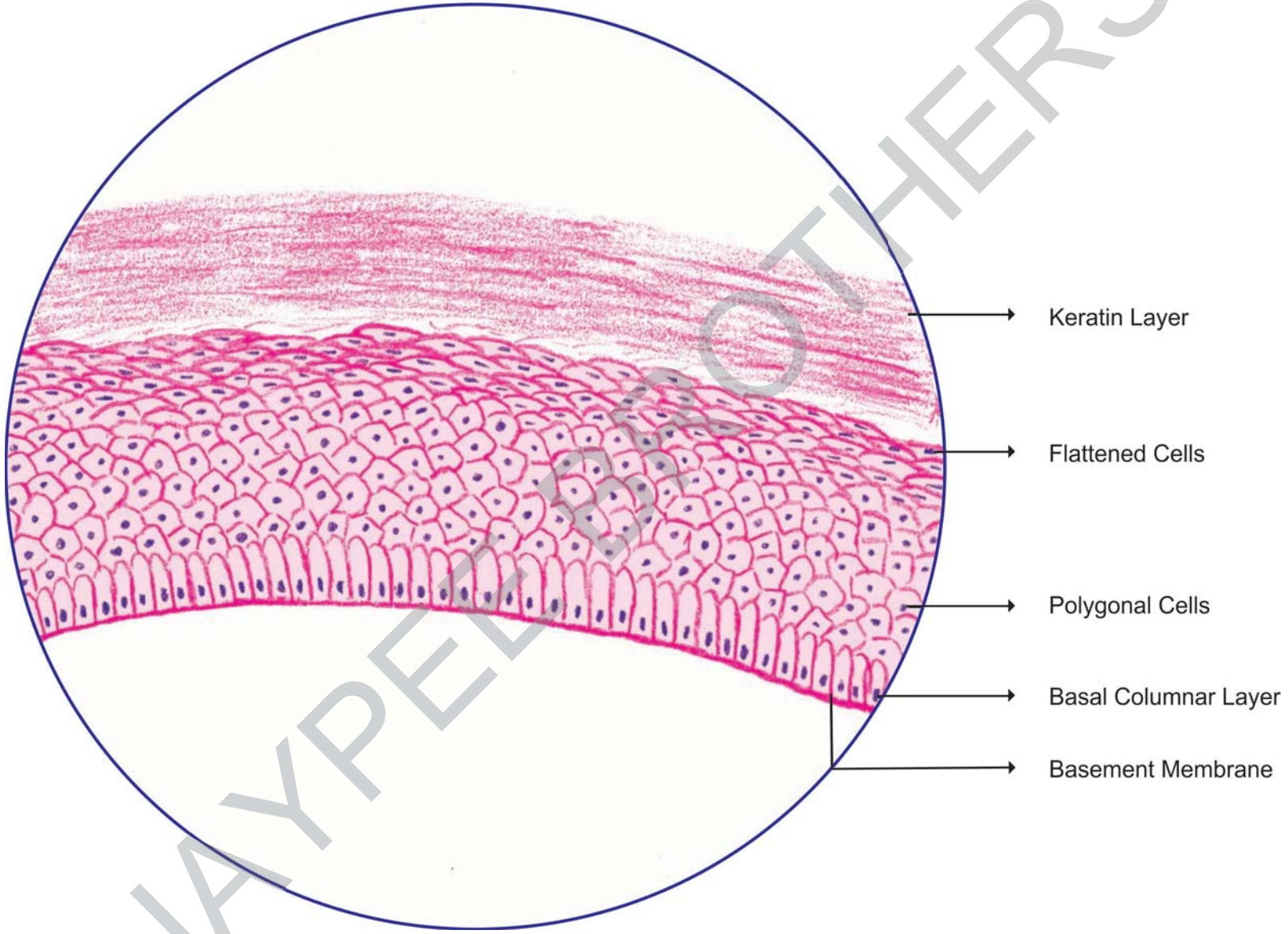

JAYPEE BROTHERS

JAYPEE BROTHERS

JAYPEE BROTHERS

2. STRATIFIED EPITHELIUM

2(C): Transitional Epithelium

Transitional Epithelium

- Five to six layers thick.
- Basal layer of cuboidal cells, middle layers of polygonal cells, superficial layer is made of large dome-shaped or umbrella-shaped cells with single nucleus.
- Unique feature of this epithelium is stretchability and impermeability.

Example: Urothelium—lining of urinary bladder and ureter.

JAYPEE BROTHERS

2(C). TRANSITIONAL EPITHELIUM

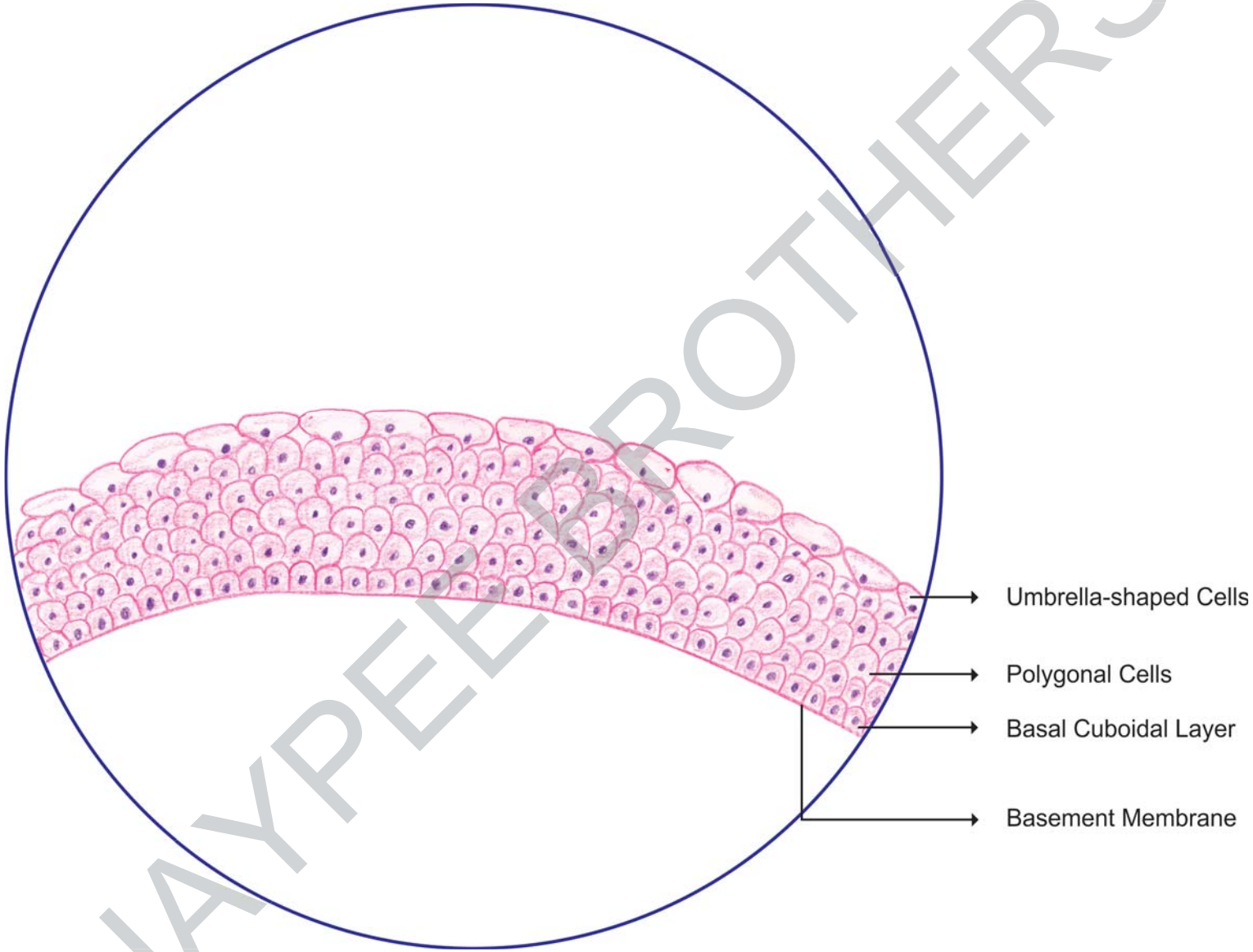

JAYPEE BROTHERS

JAYPEE BROTHERS

JAYPEE BROTHERS

for detailed information on anatomy books, visit our website www.ejaypee.com, for detailed information on anatomy books, visit our website www.ejaypee.co

diginerve®
A Jaypee Initiative
• Video Lectures • Dr. Wise AI Chatbot
• Question Bank • Notes
Download App

HISTOLOGY
PRACTICAL WORKBOOK
(Comparative Microscopic Features Included)

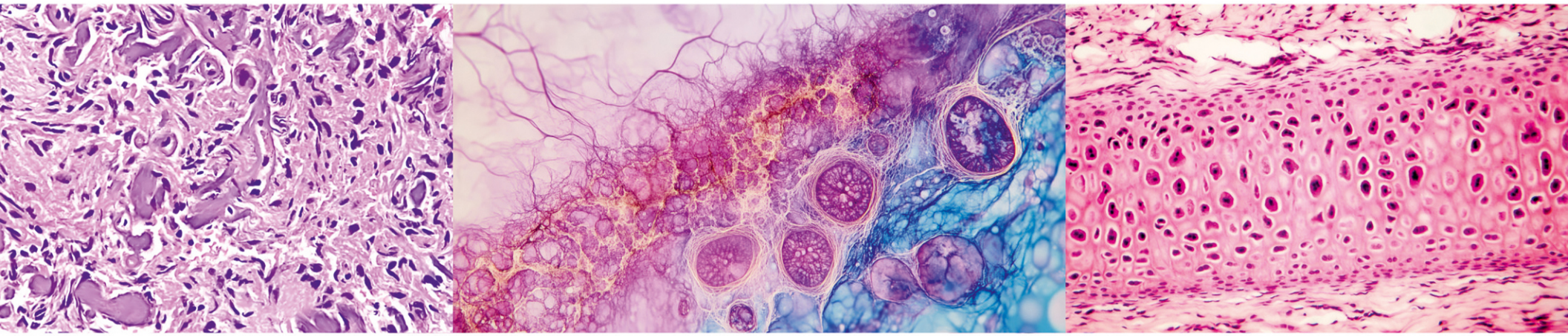

Printed in India

Available at all medical bookstores
or buy online at www.ejaypee.com

JAYPEE BROTHERS
Medical Publishers (P) Ltd.
EMCA House, 23/23-B, Ansari Road,
Daryaganj, New Delhi - 110 002, India
www.jaypeebrothers.com

Join us on facebook.com/JaypeeMedicalPublishers

Shelving Recommendation
ANATOMY

ISBN 978-93-6616-823-4