logy books, visit our website www.ejaypee.com, for detailed information on ophthalmology books, visit our website www.ejaypee.com, for detailed information on ophthalmology books

Available only with *Genuine Book*

Complimentary Online Resources
- *Clinical Skill Videos*
- *Surgical Videos*

10th Edition

Revised Reprint

Comprehensive
OPHTHALMOLOGY

Including Practical Manual and Logbook

As per the Competency-Based Medical Education Curriculum (NMC)

COMPREHENSIVE COVERAGE
Concise, exam-oriented and clinically relevant

PRACTICAL APPROACH
Focused on clinical skills and real-life practice

OPHTHALMOLOGY LOGBOOK
Structured logbook to record and track clinical experience

AK Khurana



Genuine?
Scratch, Scan & Validate

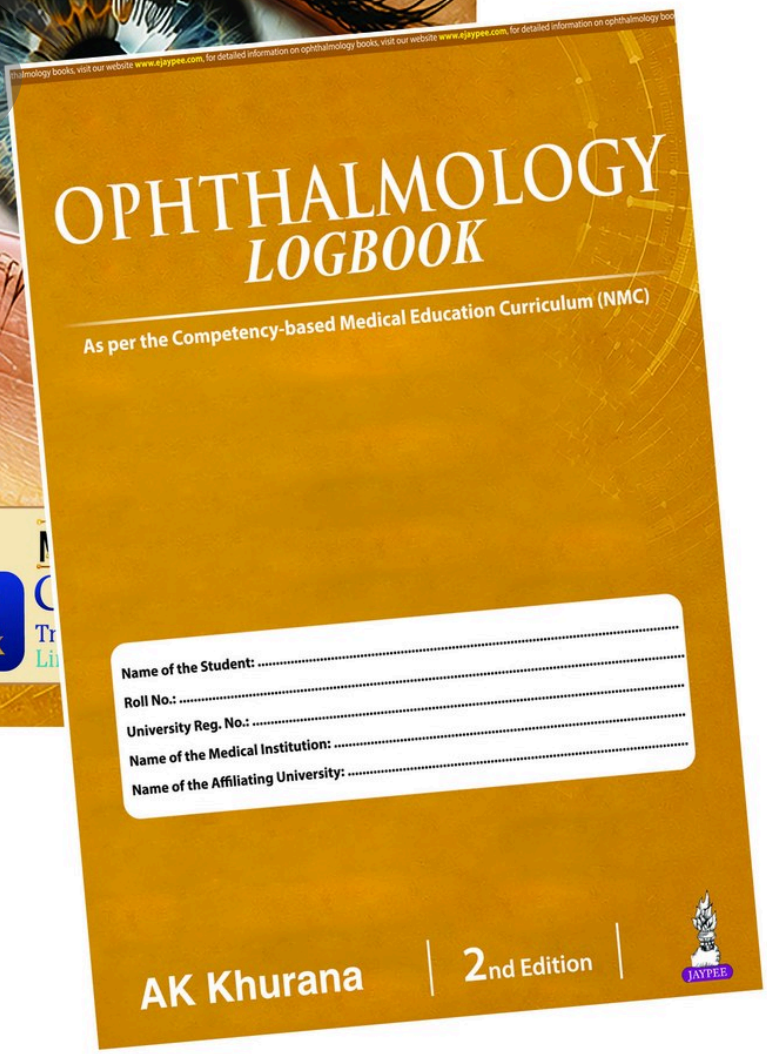

JAYPEE BROTHERS

Contents

Preface *vii*
Contents—As per Competency-Based Medical Education (CBME) Curriculum of Ophthalmology *xiii*

Section I: Anatomy and Physiology of Eye

1. Anatomy and Development of Eye 03
2. Physiology of Eye and Vision 14

Section II: Optics and Refraction

3. Elementary and Physiological Optics 23
4. Errors of Refraction, Accommodation and Asthenopia 34

Section III: Diseases of Eye and Ocular Adnexa

5. Diseases of Conjunctiva 59
6. Diseases of Cornea 93
7. Diseases of Sclera 137
8. Diseases of Uveal Tract 143
9. Diseases of Lens 175
10. Glaucoma 215
11. Diseases of Vitreous 248
12. Diseases of Retina 254
13. Neuro-ophthalmology 302
14. Ocular Motility and Strabismus 330
15. Disorders of Eyelids 356
16. Diseases of Lacrimal Apparatus 382
17. Diseases of Orbit 396
18. Ocular Injuries 420

Section IV: Ocular Therapeutics

19. Ocular Pharmacology 437
20. Lasers and Cryotherapy in Ophthalmology 456

Section V: Systemic and Community Ophthalmology

21. Systemic Ophthalmology 463
22. Community Ophthalmology 473

Section VI: Practical Ophthalmology

23. Practical Ophthalmology and Related AETCOM Modules 491
24. Clinical Methods and Skill Exercises in Ophthalmology 494
25. Clinical Ophthalmic Cases, OSCE and Viva Questions 528
26. Darkroom Procedures 573
27. Ophthalmic Instruments and Operative Ophthalmology 595
28. Ophthalmology Logbook: Concepts and Templates 615
Annexure: *NMC Guidelines for Eligibility to Appear in Examination* *623*
Index *627*

Online Contents

PART A: QUICK TEXT REVIEW WITH MULTIPLE CHOICE QUESTIONS—NEET/ NEXT PATTERN

Section I: Anatomy and Physiology of Eye

1. Anatomy and Development of Eye
2. Physiology of Eye and Vision

Section II: Optics and Refraction

3. Elementary and Physiological Optics
4. Errors of Refraction and Accommodation

Section III: Diseases of Eye and Ocular Adnexa

5. Diseases of Conjunctiva
6. Diseases of Cornea
7. Diseases of Sclera
8. Diseases of Uveal Tract
9. Diseases of Lens
10. Glaucoma
11. Diseases of Vitreous
12. Diseases of Retina
13. Neuro-ophthalmology
14. Diseases of Ocular Motility
15. Disorders of Eyelids
16. Diseases of Lacrimal Apparatus
17. Diseases of Orbit
18. Ocular Injuries

Section IV: Ocular Therapeutics

19. Ocular Pharmacology
20. Lasers and Cryotherapy in Ophthalmology

Section V: Systemic and Community Ophthalmology

21. Systemic Ophthalmology
22. Community Ophthalmology

Section VI: Practical Ophthalmology

23. Clinical Methods in Ophthalmology

PART B: CLINICAL SKILL VIDEOS

Contributors: Dr Ashwani Ghai, Miss Nikita Sethi

1. Distant Visual Acuity
2. Near Visual Acuity
3. Pin-hole Vision Test
4. Colour Vision Test
5. Menace Reflexes
6. Evaluation of Pupillary Reflexes
7. Confrontation Test for Peripheral Visual Field Charting
8. Digital Tonometry
9. Indentation Tonometry
10. Technique for Distant Direct Ophthalmoscopy
11. Technique for Direct Ophthalmoscopy
12. Indirect Ophthalmoscopy
13. Testing of Uniocular Eye Movements
14. Testing of Binocular Eye Movements
15. Eversion of Upper Eyelid
16. Epilation
17. Lacrimal Regurgitation Test
18. Lacrimal Sac Massage Technique for Congenital Dacryocystitis
19. Instillation of Eye Medications
20. Eye Irrigation
21. Ocular Bandaging

PART C: SURGICAL VIDEOS

Contributors: Dr Suneeta Dubey, Dr Pradeep Mohanta, Dr Santosh Honavar, Dr Vikas Mittal

1. Entropion Correction—Fox Techniques
2. Entropion Correction—Jones Procedure
3. Entropion Correction—Marginal Rotation
4. Entropion Correction—Tarsal Wedge Resection
5. Eyelid Reconstruction—Direct Closure
6. Ptosis Correction—Levator Resection

7. Ptosis correction—Tarsofrontalis Sling with Silicone Rod
8. Enucleation—Myoconjunctival Technique
9. Tarsorrhaphy
10. External Dacryocystorhinostomy (DCR)
11. Divide and Conquer Technique of Phacoemulsification
12. Stop and Chop Technique of Phacoemulsification
13. Trabeculectomy
14. Pterygium Excision with Conjunctival-limbal Autograft
15. Corneal Scraping
16. Fibrin Glue Application
17. Corneal Tear Repair
18. Penetrating Keratoplasty
19. Therapeutic Penetrating Keratoplasty
20. Squint Surgery

III

SECTION

DISEASES OF EYE AND OCULAR ADNEXA

SECTION OUTLINE

5. Diseases of Conjunctiva
6. Diseases of Cornea
7. Diseases of Sclera
8. Diseases of Uveal Tract
9. Diseases of Lens
10. Glaucoma
11. Diseases of Vitreous
12. Diseases of Retina
13. Neuro-ophthalmology
14. Ocular Motility and Strabismus
15. Disorders of Eyelids
16. Diseases of Lacrimal Apparatus
17. Diseases of Orbit
18. Ocular Injuries

JAYPEE BROTHERS

5 CHAPTER Diseases of Conjunctiva

CHAPTER OUTLINE

APPLIED ANATOMY
- Parts
- Structure
- Glands

INFLAMMATIONS OF CONJUNCTIVA
- Infectious conjunctivitis
  - Bacterial
  - Chlamydial
  - Viral
  - Granulomatous
- Allergic conjunctivitis
- Cicatricial conjunctivitis
- Toxic conjunctivitis

DEGENERATIVE CONDITIONS
- Pinguecula
- Pterygium
- Concretions
- Amyloid degeneration

SYMPTOMATIC CONDITIONS OF CONJUNCTIVA
- Hyperaemia
- Chemosis
- Ecchymosis
- Xerosis
- Discoloration

CYSTS AND TUMOURS
- Cysts of conjunctiva
- Tumours of conjunctiva

Subject Competencies: *The student should be able to*

OP3.1 : Elicit, document and present an appropriate history in a patient presenting with a "red eye" including congestion, discharge, pain.
OP3.2 : Demonstrate, document and present the correct method of examination of a "red eye" including vision assessment, corneal lustre, pupil abnormality, ciliary tenderness.
OP3.4 : Describe the etiology, pathophysiology, ocular features, differential diagnosis, complications and management of trachoma.
OP3.5 : Describe the etiology, pathophysiology, ocular features, differential diagnosis, complications and management of vernal catarrh.
OP3.6 : Describe the etiology, pathophysiology, ocular features, differential diagnosis, complications and management of pterygium.

APPLIED ANATOMY

Conjunctiva is a translucent mucous membrane which lines the posterior surface of the eyelids and anterior aspect of the eyeball. The name conjunctiva (conjoin: to join) has been given to this mucous membrane owing to the fact that it joins the eyeball to the lids. It stretches from the lid margin to the limbus, and encloses a complex space called *conjunctival sac* which is open in front at the palpebral fissure.

PARTS OF CONJUNCTIVA

Conjunctiva can be divided into three parts (Fig. 5.1):

1. ***Palpebral conjunctiva.*** It lines the lids and can be subdivided into marginal, tarsal and orbital conjunctiva.

i. *Marginal conjunctiva* extends from the lid margin to about 2 mm on the back of lid up to a shallow groove, the *sulcus subtarsalis*. It is actually a transitional zone between skin and the conjunctiva proper.

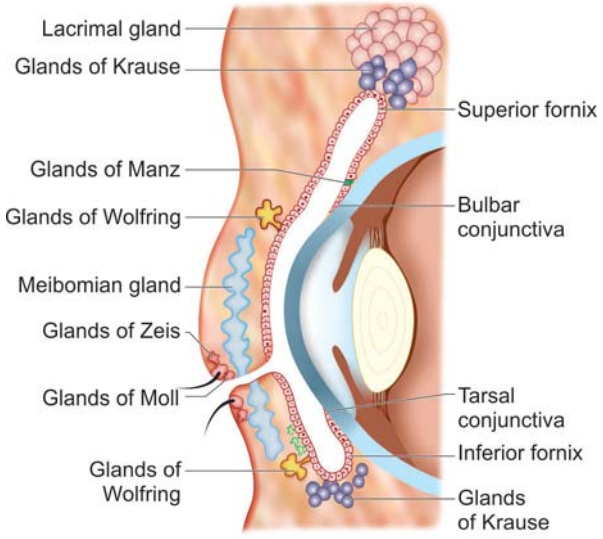

Fig. 5.1 *Parts of conjunctiva and conjunctival glands*

JAYPEE BROTHERS

- Sulcus subtarsalis is a common site for foreign body lodgment
- Marx line refers to a physiological line of vital dye stainable conjunctival epithelium just posterior to the mucocutaneous junction

ii. *Tarsal conjunctiva* is thin, transparent and highly vascular. It is firmly adherent to the whole tarsal plate in the upper lid. In the lower lid, it is adherent only to half width of the tarsus. The tarsal glands are seen through it as yellow streaks. *Follicular and papillary conjunctional responses*—most commonly occur in the tarsal conjunctiva.

iii. *Orbital part* of palpebral conjunctiva lies loose between the tarsal plate and fornix. Orbital conjunctiva has shallows and grooves known as *Stieda's plateau*.

2. *Bulbar conjunctiva.* It is thin, transparent and lies loose over the underlying structures and thus can be moved easily. It is separated from the anterior sclera by episcleral tissue and Tenon's capsule.

A 3 mm ridge of bulbar conjunctiva around the cornea is called *limbal conjunctiva*. In the area of limbus, the conjunctiva, Tenon's capsule and the episcleral tissue are fused into a dense tissue which is strongly adherent to the underlying corneoscleral junction. At the limbus, the epithelium of conjunctiva becomes continuous with that of cornea.

3. *Conjunctival fornix.* It is a continuous circular cul-de-sac which is broken only on the medial side by caruncle and the plica semilunaris. Conjunctival fornix joins the bulbar conjunctiva with the palpebral conjunctiva. It can be subdivided into superior, inferior, medial and lateral fornices.

Structure of conjunctiva

Histologically, conjunctiva consists of three layers namely, epithelium, adenoid layer, and fibrous layer (Fig. 5.2).

1. *Epithelium.* This is a 2–5 layered, non-keratinized epithelium. It also contains goblet cells which constitute about 10% of epithelium. The layer of epithelial cells in conjunctiva varies from region to region and in its different parts as follows (Fig. 5.2B):

- *Marginal conjunctiva* has 5-layered stratified squamous type of epithelium.
- *Tarsal conjunctiva* has 2-layered epithelium: superficial layer of cylindrical cells and a deep layer of flat cells.
- *Fornix and bulbar* conjunctiva have 3-layered epithelium: a superficial layer of cylindrical cells, middle layer of polyhedral cells and a deep layer of cuboidal cells.
- *Limbal conjunctiva* has again many layered (5–6) stratified squamous epithelium. Limbal stem cells are present in basal layer of this part.
- Limbal epithelial basal cells form *'Palisades of Vogt'* which contain stem cells which are useful in corneal epithelial regeneration. These cells do not express corneal epithelial specific markers such as K3, K12m S100A12, instead express ABCG2 and enolase as limbal epithelial stem cell markers. Other stem cell markers are: CD34, CD44 and CD133 (Prominin-1).
- *Epithelium also contains:* Melanocytes and Langerhans and Goblet cells, which secrete mucin (which forms the innermost layer of the tear film). They are located most densely inferonasally in the bulbar and tarsal conjunctiva.

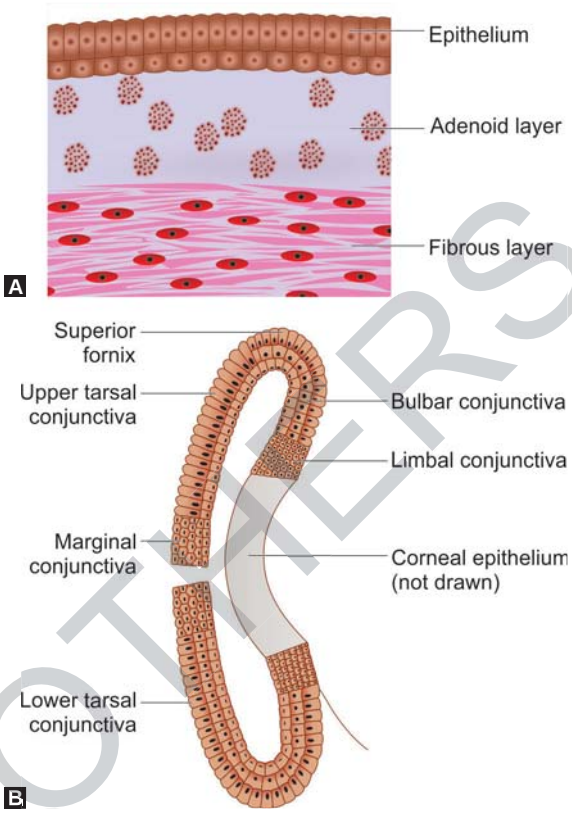

Fig. 5.2 *Microscopic structure of conjunctiva showing three layers (A) and arrangement of epithelial cells in different regions of conjunctiva (B). Note. Number of layers of epithelial cells are shown in brackets*

2. *Adenoid layer.* It is also called *lymphoid layer* and consists of fine connective tissue reticulum in the meshes of which lie lymphocytes. Mast cells are also present in the layer. This layer is most developed in the fornices. It is not present since birth but develops after 3–4 months of life. For this reason, conjunctival inflammation in an infant does not produce follicular reaction.

3. *Fibrous layer.* It consists of a meshwork of collagenous and elastic fibres. It is thicker than the adenoid layer, except in the region of tarsal conjunctiva, where it is very thin. This layer contains vessels, nerves and accessory lacrimal glands of Krause and Wolfring of conjunctiva. It blends with the underlying Tenon's capsule in the region of bulbar conjunctiva.

Glands of conjunctiva

The conjunctiva contains *two types* of glands (*See* Fig. 5.1)

1. *Mucin secretory glands.* These include:

- *Goblet cells,* the unicellular glands located within the epithelium,
- *Crypts of Henle,* present in the tarsal conjunctiva, and
- *Glands of Manz,* found in limbal conjunctiva. These glands secrete mucus which is essential for wetting the cornea and conjunctiva.

2. *Accessory lacrimal glands.* These are:

- *Glands of Krause,* present in subconjunctival connective tissue of fornices, about 42 in the upper fornix and 8 in the lower fornix, and
- *Glands of Wolfring,* present along the upper border of superior tarsus and along the lower border of inferior tarsus.

JAYPEE BROTHERS

Plica semilunaris

It is a pinkish crescentic fold of conjunctiva, present in the medial canthus. Its lateral free border is concave. It is a vestigial structure in human beings and represents the nictitating membrane (or third eyelid) of lower animals.

Caruncle

The caruncle is a small, ovoid, pinkish mass, situated in the inner canthus, just medial to the plica semilunaris. In reality, it is a piece of modified skin and so is covered with stratified squamous epithelium and contains sweat glands, sebaceous glands and hair follicles.

Blood supply of conjunctiva

Arteries supplying the conjunctiva are derived from three sources (Fig. 5.3): (1) peripheral arterial arcade of the eyelid; (2) marginal arcade of the eyelid; and (3) anterior ciliary arteries.

▪ *Palpebral conjunctiva and fornices* are supplied by branches from the peripheral and marginal arterial arcades of the eyelids.

▪ *Bulbar conjunctiva* is supplied by two sets of vessels:

- *Posterior conjunctival arteries* which are branches from the arterial arcades of the eyelids; and
- *Anterior conjunctival arteries* which are the branches of anterior ciliary arteries. Terminal branches of the posterior conjunctival arteries anastomose with the *anterior conjunctival arteries* to form the pericorneal plexus.

Veins from the conjunctiva drain into the venous plexus of eyelids and some around the cornea into the anterior ciliary veins.

Lymphatics of the conjunctiva are arranged in two layers: a superficial and a deep. Lymphatics from the lateral side drain into *preauricular lymph nodes* and those from the medial side into the *submandibular lymph nodes*.

Nerve supply of conjunctiva

A circumcorneal zone of conjunctiva is supplied by the branches from long ciliary nerves which supply the cornea.

Rest of the conjunctiva is supplied by the branches from *ophthalmic and maxillary nerves* as below:

- *Ophthalmic nerve branch,* the nasociliary nerve supplies bulbar conjunctivae and the frontal nerve and lacrimal nerves supply superior palpebral and superior forniceal conjunctiva.
- *Maxillary nerve branch*, the infraorbital nerve supplies inferior palpebral and inferior forniceal conjunctiva.

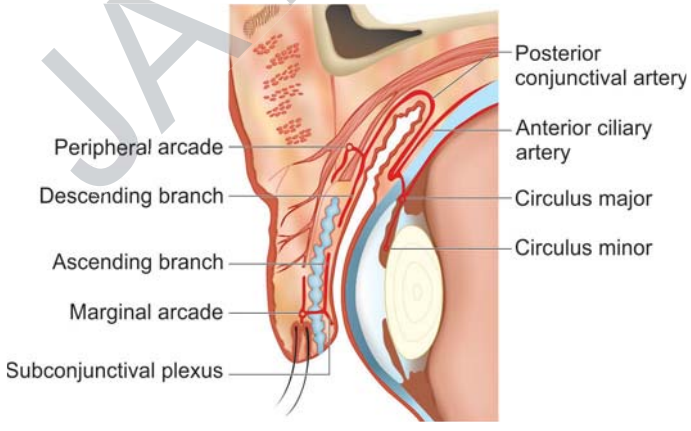

Fig. 5.3 *Blood supply of conjunctiva*

INFLAMMATIONS OF CONJUNCTIVA

GENERAL CONSIDERATIONS

Inflammation of the conjunctiva (conjunctivitis) is classically defined as conjunctival hyperaemia and conjunctival tissue reaction associated with a discharge which may be watery, mucoid, mucopurulent or purulent.

TYPES OF CONJUNCTIVITIS

Common types of conjunctivitis include:

A. Infectious conjunctivitis

1. Bacterial conjunctivitis

- Acute bacterial conjunctivitis
- Hyperacute bacterial conjunctivitis
- Chronic bacterial conjunctivitis
- Angular bacterial conjunctivitis

Chlamydial conjunctivitis

- Trachoma
- Adult inclusion conjunctivitis
- Neonatal chlamydial conjunctivitis

2. Viral conjunctivitis

- Adenovirus conjunctivitis
  - Epidemic keratoconjunctivitis
  - Pharyngoconjunctival fever
- Enterovirus conjunctivitis
- Molluscum contagiosum conjunctivitis
- Herpes simplex conjunctivitis

3. Ophthalmia neonatorum (a separate entity)

4. Granulomatous conjunctivitis

- Parinaud oculoglandular syndrome.

B. Non-infectious conjunctivitis

I. Allergic conjunctivitis

1. Simple allergic conjunctivitis

- Hay fever conjunctivitis (rhino-conjunctivitis)
- Seasonal allergic conjunctivitis (SAC)
- Perennial allergic conjunctivitis (PAC)

2. Vernal keratoconjunctivitis (VKC)

3. Atopic keratoconjunctivitis (AKC)

4. Giant papillary conjunctivitis (GPC)

5. Phlyctenular conjunctivitis (PKC)

6. Contact dermoconjunctivitis (drop conjunctivitis).

II. Cicatricial immune-mediated conjunctivitis

- Ocular mucous membrane pemphigoid (OMMP),
- Stevens Johnson syndrome (SJS),
- Toxic epidermal necrolysis (TeN), and
- Secondary cicatricial conjunctivitis.

III. Mechanical/irritative/toxic conjunctivitis

- Medication induced keratoconjunctivits
- Molluscum contagiosum related toxic conjunctivitis
- Floppy eyelid syndrome
- Giant fornix syndrome
- Contact lens related keratoconjunctivitis
- Superior limbic keratoconjunctivitis

JAYPEE BROTHERS

IV. Neoplastic conjunctivitis
- Sebaceous carcinoma
- Ocular surface squamous neoplasia (OSSN)
- Melanoma

INFLAMMATORY RESPONSES IN CONJUNCTIVITIS

1. *Vascular response.* It is characterized by congestion and increased permeability of the conjunctival vessels associated with proliferation of capillaries.

2. *Conjunctival oedema* (Chemosis). It occurs due to exudation from abnormally permeable capillaries. It is particularly prominent in loosely attached bulbar and forniceal conjunctiva. The conjunctiva becomes swollen and gelatinous in appearance.

3. *Conjunctival discharge.* It consists of tears, mucus, inflammatory cells, desquamated epithelial cells, fibrin and bacteria. If the inflammation is very severe, diapedesis of red blood cells may occur and discharge may become blood stained. Conjunctival discharge is a prominent feature of all types of conjunctivitis and may be watery, mucoid, mucopurulent:
- *Watery discharge: It comprises serous exudates and tears and occurs in catarrhal conjunctivitis, e.g. viral conjunctivitis and acute allergic conjunctivitis.*
- *Mucoid discharge: It mainly occurs in vernal conjunctivitis and dry eye.*
- *Mucopurulent discharge: It is seen in mild bacterial infections and chlamydial infections and give rise to gluing up of eyelids in the morning.*
- *Purulent discharge: It is seen in acute bacterial infections.*

4. *Conjunctival tissue responses.* These include formation of papillae, follicles, membrane, pseudomembrane, Xerosis and raised areas of subconjunctival scarring.
- *Papillae:* These are folds of hypertrophic epithelium, with a central vascular core and subepithelial infiltration of lymphocytes and plasma cells. Usually flat topped, but can be dome shaped also.
- *Follicles:* These are subepithelial lymphoid aggregates which appear as elevated whitish dots resembling sago grains.
- *Pseudomembrane* is formed when the coagulated exudates adhere to the inflamed conjunctival epithelium. Therefore, it can be easily peeled off with a wet cotton bud or plain forceps leaving the underlying epithelium intact. Common cause is severe adenoviral conjunctivitis.
- *True membrane* is formed due to permeation of inflammatory exudates into the superficial layers of conjunctival epithelium. So, attempts to remove the membrane tears off the epithelium and results in bleeding. True membrane is a feature of the conjunctivitis caused by *Corynebacterium diphtheriae*.

A. INFECTIOUS CONJUNCTIVITIS

Infectious conjunctivitis, i.e. inflammation of the conjunctiva caused by micro-organisms is the commonest variety. This is in spite of the fact that the conjunctiva has been provided with *natural protective mechanisms* in the form of:
- Low temperature due to exposure to air,
- Physical protection by lids,
- Flushing action of tears,
- Antibacterial activity of tear lysozymes, beta-lysin, lactoferrin, and
- Humoral protection by the tear immunoglobulins (IgA).

BACTERIAL CONJUNCTIVITIS

There has occurred a relative decrease in the incidence of bacterial conjunctivitis in general and those caused by *Gonococcus* and *Corynebacterium diphtheriae* in particular. However, in developing countries, it still continues to be the commonest type of conjunctivitis. It can occur as sporadic and epidemics cases. Outbreaks of bacterial conjunctivitis, epidemics are quite frequent during monsoon season.

Etiology

A. *Predisposing factors* for bacterial conjunctivitis, especially epidemic forms, are flies, poor hygienic conditions, hot dry climate, poor sanitation and dirty habits. These factors help the infection to establish, as the disease is highly contagious.

B. *Causative organisms.* It may be caused by a wide range of organisms in the following approximate order of frequency:
- *Staphylococcus aureus* is the most common cause of bacterial conjunctivitis and blepharoconjunctivitis.
- *Staphylococcus epidermidis* is an innocuous flora of lid and conjunctiva. It can also produce blepharoconjunctivitis.
- *Streptococcus pneumoniae* (*Pneumococcus*) produces acute conjunctivitis usually associated with petechial subconjunctival haemorrhages. The disease has a self-limiting course of 9–10 days.
- *Streptococcus pyogenes* (*haemolyticus*) is virulent and usually produces pseudomembranous conjunctivitis.
- *Haemophilus influenzae* (*aegyptius*, Koch-Weeks Bacillus). It classically causes epidemics of mucopurulent conjunctivitis, known as 'red-eye' especially in semitropical countries.
- *Moraxella lacunata* (Moraxella Axenfeld Bacillus) is most common cause of angular conjunctivitis and angular blepharoconjunctivitis.
- *Pseudomonas pyocyanea* is a virulent organism, which readily invades the cornea.
- *Neisseria gonorrhoeae* typically produces acute purulent conjunctivitis in adults and ophthalmia neonatorum in newborn. It is capable of invading intact corneal epithelium.
- *Neisseria meningitidis* (*Meningococcus*) may produce mucopurulent conjunctivitis.
- *Corynebacterium diphtheriae* causes acute membranous conjunctivitis. Such infections are not known nowadays.

C. *Mode of infection.* Conjunctiva may get infected from three sources, viz, exogenous, local surrounding structures and endogenous, by following modes:

1. *Exogenous infections* are the commonest and may spread:
- *Directly* through close contact, as airborne infections or as waterborne infections;
- *Vector transmission* (e.g. flies);
- *Material transfer* such as infected fingers of doctors, nurses, common towels, handkerchiefs, and infected tonometers.

JAYPEE BROTHERS

2. *Local spread* may occur some times from neighbouring structures such as infected lacrimal sac, lids, and nasopharynx. In addition to these, a change in the character of relatively innocuous organisms present in the conjunctival sac itself may cause infections.
3. *Endogenous infections* may occur very rarely through blood, e.g. gonococcal and meningococcal infections.

Pathology

Pathological changes of bacterial conjunctivitis consist of:

1. *Vascular response.* It is characterised by congestion and increased permeability of the conjunctival vessels associated with proliferation of capillaries.
2. *Cellular response.* It is in the form of exudation of polymorphonuclear cells and other inflammatory cells into the substantia propria of conjunctiva as well as in the conjunctival sac.
3. *Conjunctival tissue response.* Conjunctiva becomes oedematous. The superficial epithelial cells degenerate, become loose and even desquamate. There occurs proliferation of basal layers of conjunctival epithelium and increase in the number of mucin-secreting goblet cells.
4. *Conjunctival discharge.* It consists of tears, mucus, inflammatory cells, desquamated epithelial cells, fibrin and bacteria. If the inflammation is very severe, diapedesis of red blood cells may occur and discharge may become blood stained.

Severity of pathological changes varies depending upon the severity of inflammation and the causative organism. The changes are thus more marked in purulent conjunctivitis than mucopurulent conjunctivitis.

Clinical types of bacterial conjunctivitis

Depending upon the causative bacteria and the severity of infection, bacterial conjunctivitis may present in following clinical forms:

- Acute bacterial conjunctivitis,
- Hyperacute bacterial conjunctivitis,
- Chronic bacterial conjunctivitis, and
- Angular bacterial conjunctivitis.

ACUTE BACTERIAL CONJUNCTIVITIS

Acute bacterial conjunctivitis is characterised by marked conjunctival hyperaemia and mucopurulent discharge from the eye. So, clinically, it is called *acute mucopurulent conjunctivitis*. It is the most common type of bacterial conjunctivitis.

Common causative bacteria are: *Staphylococcus aureus, Koch-Weeks Bacillus, Pneumococcus* and *Streptococcus*.

Clinical features

Symptoms

- *Discomfort, foreign body sensation, grittiness, blurring and redness* of sudden onset (due to engorgement of vessels) are the usual presenting symptoms.
- *Mild photophobia*, i.e. difficulty to tolerate light.
- *Mucopurulent discharge* from the eyes.
- *Sticking together of lid margins* with discharge during sleep.
- *Slight blurring* of vision due to mucous flakes in front of cornea.

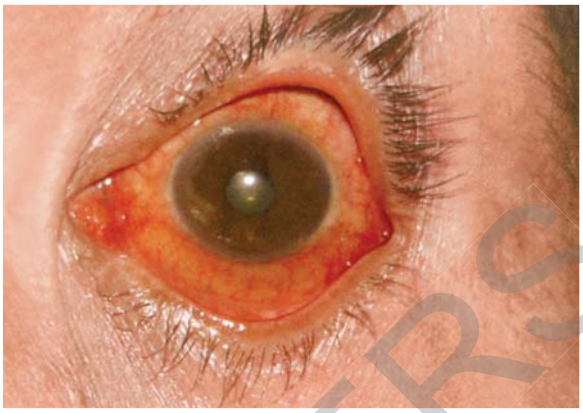

Fig. 5.4 *Signs of acute mucopurulent conjunctivitis*

- *Coloured halos*, may be complained by some patients due to prismatic effect of mucus present on cornea.

Signs (Fig. 5.4)

- *Flakes of mucopus* seen in the fornices, canthi and lid margins is a critical sign.
- *Conjunctival congestion*, which is more marked in palpebral conjunctiva, fornices and peripheral part of bulbar conjunctiva, giving the appearance of 'fiery red eye'. The congestion is typically less marked in circumcorneal zone.
- *Chemosis*, i.e. swelling of conjunctiva.
- *Papillae* of fine type may be seen.
- *Petechial haemorrhages* are seen when the causative organism is *Pneumococcus*.
- *Cilia are usually matted* together with yellow crusts.
- *Eyelids* may be slightly oedematous.

Clinical course. Mucopurulent conjunctivitis is usually bilateral, although one eye may become affected 1–2 days before the other. The disease usually reaches its height in three to four days. If untreated, in mild cases the infection may be overcome and the condition is cured in 10–15 days; or it may pass to less intense form, the 'chronic catarrhal conjunctivitis.'

Complications. Occasionally, the disease may be complicated by superficial punctate epitheliopathy, marginal corneal ulceration, superficial keratitis, blepharitis, or dacryocystitis.

Differential diagnosis

1. *Differential diagnosis of acute bacterial conjunctivitis with other types of conjunctivitis.* It is made out from the typical clinical feature of disease and is confirmed by conjunctival cytology and bacteriological examination of secretions and scrapings (Table 5.1).
2. *Differential diagnosis of common causes of acute red eye* (*See* page 155 and Table 8.1).

Acute red eye

Acute red eye is a common presenting symptom in many conditions such as:

- Acute conjunctivitis
- Acute keratitis (*See* page 97)
- Injuries to conjunctiva and cornea, commonly by foreign body (*See* page 421)
- Acute iridocyclitits
- Acute glaucoma

JAYPEE BROTHERS

Table 5.1: Differentiating features of common types of conjunctivitis

	Bacterial	*Viral*	*Allergic*	*Chlamydial (TRIC)*
(A) **Clinical signs**				
1. Congestion	Marked	Moderate	Mild to moderate	Moderate
2. Chemosis	++	±	++	±
3. Subconjunctival haemorrhages	±	±	–	–
4. Discharge	Purulent or mucopurulent	Watery	Ropy/watery	Mucopurulent
5. Papillae	±	–	++	±
6. Follicles	–	+	–	++
7. Pseudomembrane	±	±	–	–
8. Pannus	–	–	– (Except vernal)	+
9. Preauricular lymph nodes	+	++	–	±
(B) **Cytological features**				
1. Neutrophils	+	+ (Early)	–	+
2. Eosinophils	–	–	+	–
3. Lymphocytes	–	+	–	+
4. Plasma cells	–	–	–	+
5. Multinuclear cells	–	+	–	–
6. Inclusion bodies:				
Cytoplasmic	–	+ (Pox)	–	+
Nuclear	–	+ (Herpes)	–	–
7. Micro-organisms	+	–	–	–

JAYPEE BROTHERS

• Subconjunctival hemorrhage (*See* page 87), and
• Acute endophthalmitis (*See* page 166)

So differential diagnosis need to be made for accurate diagnosis and instituting proper treatment in a case of acute red eye.

Treatment

1. ***Topical antibiotics*** to control the infection constitute the main treatment of acute bacterial conjunctivitis. Ideally, the antibiotic should be selected after culture and sensitivity tests but in practice, it is difficult. However, in routine, most of the patients respond well to broad-spectrum antibiotics. Therefore, treatment may be started with tobramycin 0.3% or ciprofloxacin (0.3%), ofloxacin (0.3%), gatifloxacin (0.3%) or moxifloxacin (0.5%) eye drops 3–4 hourly in day and ointment used at night will not only provide antibiotic cover but also help to reduce the early morning stickiness.
2. ***Irrigation of conjunctival sac*** with sterile luke warm saline once or twice a day will help by removing the deleterious material. Frequent eyewash (as advocated earlier) is, however, contraindicated as it will wash away the lysozyme and other protective proteins present in the tears.
3. ***Dark goggles*** should be used to prevent photophobia.
4. ***No bandage*** should be applied in patients with mucopurulent conjunctivitis. Exposure to air keeps the temperature of conjunctival cul-de-sac low which inhibits the bacterial growth; while after bandaging, conjunctival sac is converted into an incubator, and thus infection flares to a severe degree within 24 hours. Further, bandaging of eye will also prevent the escape of discharge.
5. ***No steroids*** should be applied, otherwise infection will flare up and bacterial corneal ulcer may develop.
6. ***Anti-inflammatory and analgesic drugs*** (e.g. ibuprofen and paracetamol) may be given orally for 2–3 days to provide symptomatic relief from mild pain especially in sensitive patients.

Preventive measures to reduce risk of transmission to the close contacts include:
• Frequent handwashing, and
• Avoidance of sharing towel, handkerchief and pillow with others.

HYPERACUTE BACTERIAL CONJUNCTIVITIS

Hyperacute bacterial conjunctivitis also known as acute purulent conjunctivitis or *acute blenorrhea* is characterised by a violent inflammatory response.

It occurs in two forms:
1. Adult purulent conjunctivitis, and
2. Ophthalmia neonatorum in newborn (*See* page 75).

HYPERACUTE CONJUNCTIVITIS OF ADULTS (GONOCOCCAL CONJUNCTIVITIS)

Etiology

The disease affects adults, predominantly males. Gonococcal infection directly spreads from genitals to eye. Presently, incidence of gonococcal conjunctivitis has markedly decreased.

Clinical feature

Onset is hyperacute (12–24 hours).

Symptoms include:
- *Pain* which is moderate to severe,
- *Purulent discharge,* which is usually copious, and
- *Swelling of eyelids,* which is usually marked.
- *Mild photophobia,* i.e. difficulty to tolerate light.
- *Sticking together of lid margins* with discharge during sleep.
- *Slight blurring* of vision due to mucous flakes in front of cornea.

Signs are as follows (Fig. 5.5):
- *Eyelids* are tense and swollen.
- *Tenderness* is marked.
- *Discharge* is thick purulent, copious trickling down the cheeks.
- *Conjunctiva shows* marked chemosis, congestion and papillae, giving bright red velvety appearance. Frequently, a *pseudomembrane* may be seen on the conjunctival surface (Fig. 5.6). Pseudomembrane can be pealed off with a wet cotton bud or plain forceps. It is not possible to remove the true membrane easily and separation may lead to bleeding. True membrane is a feature of diphtheric conjunctivitis, which is almost eradicated.
- *Preauricular lymph nodes* are usually enlarged and tender.

Associations. Gonococcal conjunctivitis is usually associated with urethritis and arthritis.

Complications

1. *Corneal involvement* is quite frequent as the *Gonococcus* can invade the normal cornea through an intact epithelium. It may occur in the form of diffuse haze and oedema, central necrosis, corneal ulceration or even perforation.



Fig. 5.5 *Hyperacute conjunctivitis*

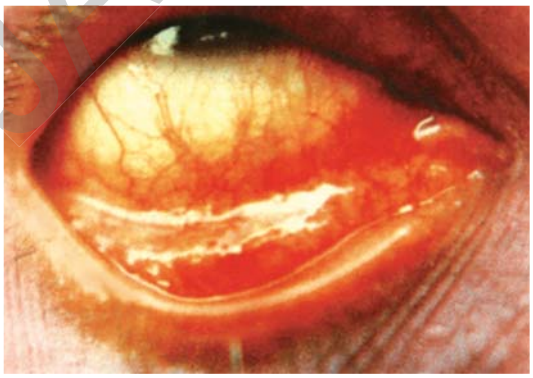

Fig. 5.6 *Pseudomembranous conjunctivitis*

2. *Iridocyclitis* may also occur, but is not as common as corneal involvement.
3. *Systemic complications*, though rare, include gonorrhoea arthritis, endocarditis and septicaemia.

Treatment

1. *Systemic therapy* is far more critical than the topical therapy for the infections caused by *N. gonorrhoeae*. Any of the following regimes can be adopted:
- *Third generation cephalosporin* such as ceftriaxone 1 gram IM as a single dose is sufficient for treatment of adult gonococcal conjunctivitis without septicemia. However, if there is corneal involvement, the treatment should be given for 5 days, or cefotaxime 1 gram IV four times daily for 5 days alternatively.
- *Quinolones* such as norfloxacin 1.2 g orally qid for 5 days, or
- *Spectinomycin* 2.0 g IM for 3 days, may be used alternatively.

All of the above regimes should then be followed by a one week course of either doxycycline 100 mg bid or erythromycin 250–500 mg orally qid.

2. *Topical antibiotic therapy*, presently recommended includes ofloxacin (0.3%), ciprofloxacin (0.3%) or tobramycin (0.3%) eye drops or erythromycin eye ointment every 2 hours for the first 2–3 days and then 5 times daily for 7 days.

3. *Irrigation* of the eyes frequently with sterile saline is very therapeutic in washing away infected debris.

4. *Other general measures* are similar to acute mucopurulent conjunctivitis.

5. *Topical atropine* 1% eye drops should be instilled once or twice a day if cornea is involved.

Note. Sexual partner should also be treated with systemic antibiotics. Further, both the patient and the sexual partner should be referred for evaluation of other sexually transmitted diseases.

CHRONIC BACTERIAL CONJUNCTIVITIS

Chronic bacterial conjunctivitis also known as '*chronic catarrhal conjunctivitis*' or '*simple chronic conjunctivitis*' is characterised by mild catarrhal inflammation of the conjunctiva.

Etiology

A. *Predisposing factors*

1. *Chronic exposure* to dust, smoke, and chemical irritants.
2. *Local cause of irritation* such as trichiasis, concretions, foreign body and seborrhoeic scales.
3. *Eye strain* due to refractive errors, phorias or convergence insufficiency.
4. *Abuse of alcohol*, insomnia and metabolic disorders.

B. *Causative organisms*
- *Staphylococcus aureus* is the commonest cause of chronic bacterial conjunctivitis.
- *Gram-negative rods* such as *Proteus mirabilis, Klebsiella pneumoniae, Escherichia coli* and *Moraxella lacunata* are other rare causes.

C. *Source and mode of infection.* Chronic conjunctivitis may occur:

1. *As continuation of acute mucopurulent conjunctivitis* when untreated or partially treated.

JAYPEE BROTHERS

2. *As chronic infection* from associated chronic dacryocystitis, chronic rhinitis or chronic upper respiratory catarrh.
3. *As a mild exogenous infection* which results from direct contact, airborne or material transfer of infection.

Clinical features

Symptoms of simple chronic conjunctivitis include:
- *Burning and grittiness* in the eyes, especially in the evening.
- *Mild chronic redness* in the eyes.
- *Feeling of heat and dryness* on the lid margins.
- *Difficulty in keeping the eyes open.*
- *Mild mucoid discharge* especially in the canthi.
- *Watering,* off and on is often a complaint.
- *Feeling of sleepiness* and tiredness in the eyes.

Signs. Grossly the eyes look normal but careful examination may reveal following signs:
- *Congestion* of posterior conjunctival vessels.
- *Mild papillary hypertrophy* of the palpebral conjunctiva.
- *Sticky look* of surface of the conjunctiva.
- *Lid margins* may be congested.

Treatment

1. *Eliminate predisposing factors* when associated.
2. *Topical antibiotics* such as, tobramycin (0.3%) or moxifloxacin (0.5%) should be instilled 3–4 times a day for about 2 weeks to eliminate the mild chronic infection.
3. *Astringent eye drops* such as zinc-boric acid drops provide symptomatic relief.

ANGULAR BACTERIAL CONJUNCTIVITIS

It is a type of chronic conjunctivitis characterised by mild grade inflammation confined to the conjunctiva and lid margins near the angles (hence the name) associated with maceration of the surrounding skin.

Etiology

1. *Predisposing factors* are same as for 'simple chronic conjunctivitis'.
2. *Causative organisms. Moraxella Axenfield* (MA) is the commonest causative organism. MA bacilli are placed end to end, so the disease is also called 'diplobacillary conjunctivitis'. Rarely, staphylococci may also cause angular conjunctivitis.
3. *Source of infection* is usually nasal cavity.
4. *Mode of infection.* Infection is transmitted from nasal cavity to the eyes by contaminated fingers or handkerchief.

Pathology

The causative organism, i.e. MA bacillus produces a proteolytic enzyme which acts by macerating the epithelium. This proteolytic enzyme collects at the angles by the action of tears and thus macerates the epithelium of the conjunctiva, lid margin and the skin, the surrounding angles of eye. The maceration is followed by vascular and cellular responses in the form of mild grade chronic inflammation. Skin may show eczematous changes.

Clinical features

Symptoms include:
- Irritation, burning sensation and feeling of discomfort in the eyes.

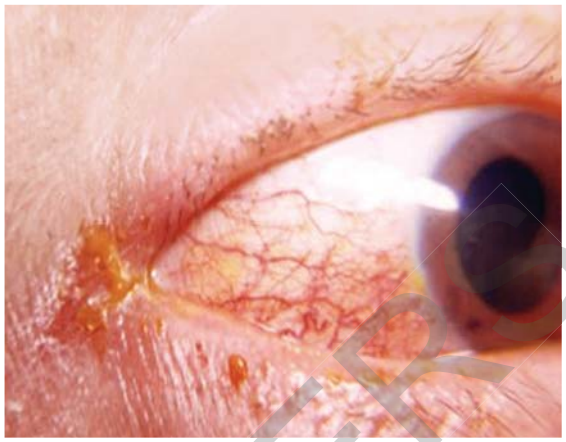

Fig. 5.7 *Signs of angular conjunctivitis*

- History of collection of dirty-white foamy discharge at the angles.
- Redness in the angles of eyes.

Signs include (Fig. 5.7):
- *Hyperaemia of bulbar conjunctiva* near the canthi.
- *Hyperaemia of lid margins* near the angles.
- *Excoriation of the skin* around the angles.
- *Foamy mucopurulent discharge* at the angles is usually present.

Complications include: blepharitis and shallow marginal catarrhal corneal ulceration.

Treatment

A. *Prophylaxis* includes treatment of associated nasal infection and good personal hygiene.

B. *Curative treatment* consists of:
1. *Oxytetracycline* (1%) eye ointment, 2–3 times a day for 9–14 days will eradicate the infection.
2. *Zinc lotion* instilled in day time and zinc oxide ointment at bed time inhibits the proteolytic ferment and thus helps in reducing the maceration.

CHLAMYDIAL CONJUNCTIVITIS

Chlamydia, earlier classified as a separate organism in between bacteria and viruses, has now been classified as bacterium belonging to the family Chlamydiaceae having two genera Chlamydia and Chlamydophilia.

Characteristics of Chlamydia are:
- Small, obligate intracellular, gram-negative bacteria.
- Possess both RNA and DNA, ribosomes and cell wall similar to that of gram-negative bacteria.
- Differ from most of the true bacteria in not having peptidoglycan.
- Lack the ability to produce their own ATP, therefore, use host's ATP (energy parasites).
- Multiply by binary fission.
- Inclusion bodies are basophilic in nature.
- Multiply in the cytoplasm of the host cell forming microcolonies or inclusion bodies which drape around the nucleus like a cloak or mantle (chlamys means mantle).
- Possess a genus-specific lipopolysaccharide-protein complex antigen.

JAYPEE BROTHERS

- Exist in two morphologically distinct forms namely elementary body (EB) and reticulate body (RB).

Life cycle of Chlamydia

Chlamydiae exists in two morphological forms: the elementary body (EB) and reticulate body (RB). Life cycle of Chlamydia is summarised below (Fig. 5.8):

- *Elementary bodies* (EB) are extracellular infectious particles (Fig. 5.8A). These initiate infection by attaching to the susceptible host cells (Fig. 5.8B). After attachment, the EB enters the cytoplasm of the host cells within a vesicle (Fig. 5.8C), where it increases in size and differentiates into reticulate body (RB) (Fig. 5.8D).
- *Reticulate body* (RB) is thus intracellular, metabolically active form that divides by binary fission (Fig. 5.8E). Soon there occurs condensation of DNA within the RBs, disulphide bonds are formed in the outer membrane proteins and new EBs develop within the enlarging vesicle. The developing chlamydiaceal microcolony within the vesicle is termed inclusion body which is typically perinuclear and may contain 100–500 EBs (Fig. 5.8F).
- *Release of new* EBs into the extracellular space occurs following rupture of the inclusion body (Fig. 5.8E). The liberated EBs then infect the new cells where the whole cycle is repeated (Fig. 5.8).

Ocular infections produced by chlamydia in human beings are summarised in Table 5.2.

TRACHOMA

Trachoma (previously known as *Egyptian ophthalmia*) is a chronic keratoconjunctivitis, primarily affecting the superficial epithelium of conjunctiva and cornea simultaneously. It is characterised by a mixed follicular and papillary response of conjunctival tissue, pannus formation and in late stages cicatrization giving rough appearance. The word 'trachoma' comes from the Greek word for 'rough' which describes the surface appearance of the conjunctiva in chronic trachoma. It is still one of the leading causes of preventable blindness in the world. Though many countries including India are now free from active cases of trachoma.

Etiology

A. *Causative organism.* Trachoma is caused by the bacterium *Chlamydia trachomatis,* biovar TRIC. The organism is epitheliotropic and produces intracytoplasmic inclusion bodies called *HP bodies (Halberstaedter Prowazek bodies).*

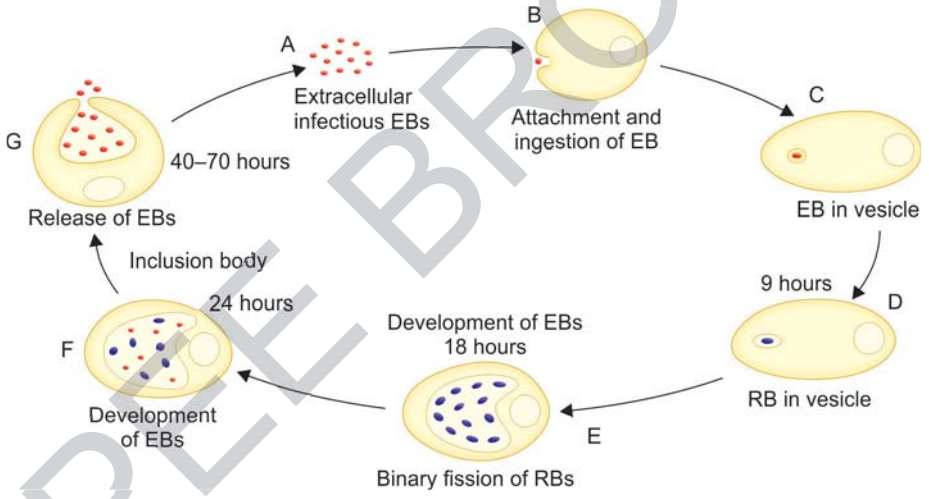

Fig. 5.8 *Life cycle of Chlamydia*

Table 5.2: Summary of ocular infections caused by Chlamydia

Family	Chlamydiaceae				
Genra	Chlamydia			Chlamydophila	
Biovar	*C. trachomatis* (TRIC agent) (Humans)		*C. lymphogranulomatis* (Humans)	*C. psittacosis* (Animals)	*C. pneumoniae* (Human)
Serovar	A, B, Ba, C	D to K	L1, L2, L3	–	–
Ocular disease	Hyperendemic trachoma	Paratrachoma (neonatal and adult inclusion conjuctivitis)	Lymphogranuloma venereum conjunctivitis	–	–
Transmission	Eye to eye	Genitals to eye	Genitals to eye	–	–

JAYPEE BROTHERS

Presently, 12 serovars of *Chlamydia trachomatis* biovar TRIC (A, B, Ba, C, D, E, F, G, H, J and K) have been identified using microimmunofluorescence techniques.

- *Serovars A, B, Ba and C* are associated with hyperendemic (blinding) trachoma.
- *Serovars D to K* are associated with inclusion conjunctivitis (oculogenital chlamydial disease).

B. *Predisposing factors* include:

- *Age.* The infection is usually contracted during infancy and early childhood. Otherwise, there is no age bar.
- *Sex.* As far as sex is concerned, there is general agreement that preponderance exists in the females both in number and in severity of disease.
- *Race.* No race is immune to trachoma, but the disease is very common in Jews and comparatively less common among Negroes.
- *Climate.* Trachoma is more common in areas with dry and dusty weather.
- *Socioeconomic status.* The disease is more common in poor classes owing to unhygienic living conditions, overcrowding, unsanitary conditions, abundant fly population, paucity of water, lack of materials like separate towels and handkerchiefs, and lack of education and understanding about spread of contagious diseases.
- *Environmental factors* like exposure to dust, smoke, irritants, sunlight, etc. increase the risk of contracting disease. Therefore, outdoor workers are more affected in comparison to office workers.

C. *Source of infection.* In trachoma endemic zones, the main source of infection is the conjunctival discharge of the affected person. Therefore, superimposed other bacterial infections help in transmission of the disease by increasing the conjunctival secretions.

D. *Modes of infection.* Infection may spread from eye to eye by any of the following modes:

1. *Direct spread* of infection may occur through contact by airborne or waterborne modes or contaminated fingers of doctors, nurses.
2. *Vector transmission* of trachoma is common through *flies*.
3. *Fomites (Material transfer)* play an important role in the spread of trachoma. Material transfer can occur through contaminated tonometers and other objects used for eye examination. Other sources of material transfer of infection are use of common towel, handkerchief, bedding and *surma*-rods.

Prevalence

Trachoma is a worldwide disease, but it is highly prevalent in North Africa, Middle East and certain regions of South-East Asia. It is believed to affect some 500 million people in the world. There are about 150 million cases with active trachoma and about 30 million having trichiasis, needing lid surgery. Trachoma is responsible for 15–20% of the world's blindness, being second only to cataract.

Clinical and pathological features

Repeated episodes associated with secondary bacterial infection (most commonly by *Hemophilus aegypitus*) incite type IV hypersenstivity reaction and causes. Clinical features of trachoma which can be described into two phases:

I. *Phase of active inflammatory trachoma*

Phase of active inflammatory trachoma usually occurs during childhood due to active chlamydial infection.

- *Incubation period* of active trachoma varies from 7 to 14 days.
- *Onset of disease* is usually insidious (subacute), however, rarely it may present in acute form.

Symptoms

Symptoms of active trachoma are determined by the absence or presence of secondary other bacterial infection (a very common situation).

▪ *In the absence of secondary infection,* a pure trachoma is characterized by following symptoms:

- Mild foreign body sensation,
- Occasional lacrimation,
- Slight stickiness of the lids, and
- Scanty mucoid discharge.

Note. The above symptoms are so mild that the disease is usually neglected so, the term *trachoma dubium* was suggested.

▪ *In the presence of secondary other bacterial infection,* typical symptoms of acute mucopurulent conjunctivitis develop (*See* page 62).

Signs

A. *Conjunctival signs*

1. *Congestion* of upper tarsal and forniceal conjunctiva.
2. *Conjunctival follicles.* Follicles (Fig. 5.9) look like boiled sago-grains and are commonly seen on upper tarsal conjunctiva

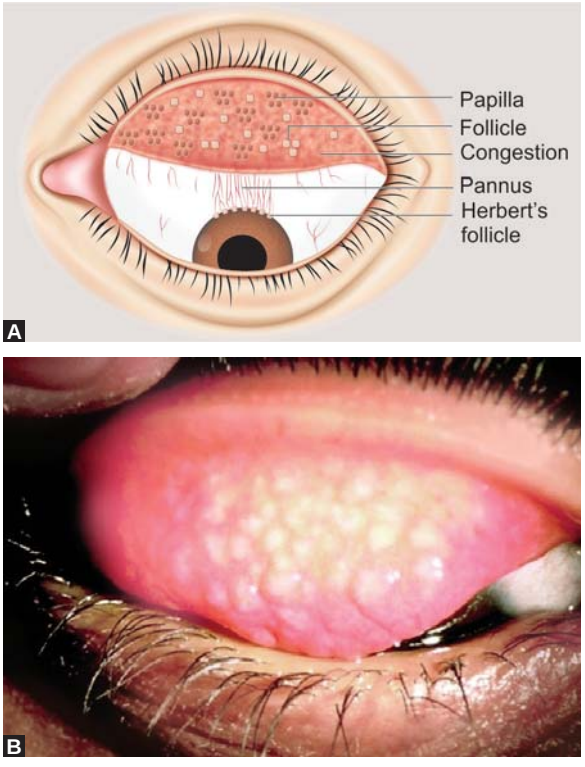

Fig. 5.9 *Signs of active trachoma: A, Diagrammatic; B, Clinical photograph of trachomatous inflammation follicular (TF)*

JAYPEE BROTHERS

for detailed information on ophthalmology books, visit our website www.ejaypee.com, for detailed information on ophthalmology books, visit our website www.ejaypee.com, for detailed

Comprehensive

OPHTHALMOLOGY

The 10th edition of Comprehensive Ophthalmology reflects a thorough revision to align with the evolving Competency-Based Medical Education (CBME) curriculum, addressing the need for updated content to support modern medical education. This edition incorporates the latest advances across all sections, ensuring relevance and accuracy.

Thoroughly Updated for the NMC-CBME Curriculum
Revised and updated in accordance with the latest Competency-Based Medical Education (CBME) curriculum prescribed by NMC, ensuring focused and relevant learning for undergraduate students.

Structured into Five Well-Defined Sections
The content is systematically organized into five sections, providing a logical flow from fundamental concepts to clinical and practical ophthalmology for easier understanding and revision.

Strong Focus on Practical Ophthalmology
A dedicated practical ophthalmology section equips students with essential examination techniques, clinical skills, case-based learning, and practical competencies required for university examinations and clinical practice.

Complimentary Ophthalmology Logbook
Includes a structured logbook to help students record learning activities, clinical skills, competencies, procedures, and practical experiences in accordance with competency-based training requirements.

ConceptRx—Your Digital Companion for All Your Exam Needs
Get anytime access to a powerful exam-preparation digital companion featuring exam-oriented notes, high-yield questions, MCQs, Mind Maps, and quick summaries—designed for smarter learning and faster revision.

Exclusive Clinical and Surgical Video Content
Enhance clinical understanding through Clinical Skill Videos and Surgical Videos, providing visual, step-by-step reinforcement of important ophthalmic procedures and techniques for undergraduates and postgraduates.

AK Khurana MS FAICO CTO (London) worked as Professor and Head, Department of Ophthalmology, SGT Medical College, Hospital and Research Institute, Gurugram, Haryana, India. He was Former Senior Professor and Head, Regional Institute of Ophthalmology, Postgraduate Institute of Medical Sciences (PGIMS), University of Health Sciences, Rohtak, Haryana. He had been teaching ophthalmology for the last more than four decades. In addition to this book, he had authored other books namely *Anatomy and Physiology of Eye, Theory and Practice of Squint and Orthoptics, Ophthalmic Nursing* and *Modern System of Ophthalmology (MSO) Series*, which have also been well received.

He had published more than 250 scientific papers in national and international journals of repute. He had also contributed several chapters for postgraduate reference books published in India and abroad. He had also been Editor of Haryana Journal of Ophthalmology, Indian Journal of Strabismus and Pediatric Ophthalmology (IJSPO), and North Zone Journal of Ophthalmology. He was awarded WHO Fellowship for higher studies at Moorfields Eye Hospital, London. He was also selected for a course and awarded Certificate in Tropical Ophthalmology at International Centre for Eye Health, Institute of Ophthalmology, University of London, UK. He was honored with Distinguished Author Award by the Federation of Educational Publishers of India, HOS Award for Excellence in Ophthalmology, Excellence Award by Strabismological Society of India, Gold Medal by Intraocular Implant, Refractive Society of India, Lifetime Achievement Award by HOS, Uttarakhand State Ophthalmological Society (UKSOS), North Zone Ophthalmological Society, and International Society for Manual Small Incision Cataract Surgery. He had also been honoured with PN Sinha Oration Award by Bihar Ophthalmological Society (BOS) and Fellowship of All India Collegium of Ophthalmology (FAICO).

JAYPEE BROTHERS

Shelving Recommendation
OPHTHALMOLOGY

ISBN 978-93-6616-878-4
9 789366 168784

Buy from ejaypee

JAYPEE BROTHERS