e.com,, for detailed information on otorhinolaryngology books, visit our website www.ejaypee.com,, for detailed information on otorhinolaryngology books

diginerve®
A Jaypee Initiative
• Video Lectures • Dr. Wise AI Chatbot
• Question Bank • Notes
Download App

Complementary Videos
Access by Scanning QR code inside

GOLDEN NOTES IN ENT

Previously Known as
Exam Preparatory Manual for
Undergraduates Otorhinolaryngology (ENT)

As per the Revised Competency-based Medical Education Curriculum (NMC)



Nilam Uttam Sathe

Forewords
D S Grewal
Sanjay N Oak

2nd Edition

JAYPEE

Contents

Part 1: Diseases of ENT, Head and Neck

Section 1: Basic Sciences

Chapter 1: Anatomy and Physiology of Ear 3
Chapter 2: Anatomy and Physiology of Nose and Paranasal Sinuses 15
Chapter 3: Anatomy and Physiology of Oral Cavity and Pharynx 27
Chapter 4: Anatomy and Physiology of Larynx and Esophagus 33

Section 2: Otology

Chapter 5: History Taking and Examination of Ear 41
Chapter 6: Diseases of the External Ear 55
Chapter 7: Diseases of Middle Ear 64
Chapter 8: Eustachian Tube and its Disorders 68
Chapter 9: Chronic Suppurative Otitis Media 73
Chapter 10: Complications of Chronic Suppurative Otitis Media 82
Chapter 11: Otosclerosis 92
Chapter 12: Meniere's Disease 95
Chapter 13: Hearing Loss 99
Chapter 14: Tinnitus 105
Chapter 15: Assessment and Disorders of Vestibular System 108
Chapter 16: Deaf Child and Rehabilitation of Hearing Impaired 120
Chapter 17: Facial Nerve and its Disorders 127
Chapter 18: Benign Conditions and Malignant Tumors of External Ear and Middle Ear 133
Chapter 19: Vestibular Schwannoma 143

Section 3: Rhinology

Chapter 20: History Taking and Examination of Nose and Paranasal Sinuses 147
Chapter 21: Diseases of External Nose 154
Chapter 22: Nasal Septum and its Diseases 158
Chapter 23: Acute and Chronic Rhinitis and Sinusitis and its Complications 163
Chapter 24: Allergic, Vasomotor Rhinitis and Nonallergic Rhinitis 173
Chapter 25: Nasal Polyp 177
Chapter 26: Epistaxis 179
Chapter 27: Facial Trauma 183
Chapter 28: Granulomatous Diseases of Nose 192
Chapter 29: Neoplasms of the Nasal Cavity and Paranasal Sinuses 202

Section 4: Laryngology, Head and Neck

Chapter 30: History and Examination of Oral Cavity, Throat, Head and Neck 210
Chapter 31: Disorders and Tumors of Oral Cavity 219
Chapter 32: Disorders and Tumors of the Salivary Glands 229
Chapter 33: Acute and Chronic Tonsillitis 237
Chapter 34: Adenoiditis (Nasopharyngeal Tonsil) 243
Chapter 35: Acute and Chronic Pharyngitis 246
Chapter 36: Head and Neck Space Infections 248
Chapter 37: Tumors of Nasopharynx, Hypopharynx, Oropharynx and Pharyngeal Pouch 256
Chapter 38: Laryngotracheal Trauma 266
Chapter 39: Acute and Chronic Inflammation of Larynx 270
Chapter 40: Congenital Lesions of Larynx 284
Chapter 41: Laryngeal Paralysis 287
Chapter 42: Stridor and Stertor 291
Chapter 43: Benign Tumors of Larynx 295
Chapter 44: Carcinoma Larynx (Malignant Tumors of Larynx) 299
Chapter 45: Voice and Speech Disorders 304
Chapter 46: Snoring and Sleep Apnea 308
Chapter 47: Foreign Bodies in Air and Food Passages 315
Chapter 48: Disorders of Esophagus and Dysphagia 320
Chapter 49: Human Immunodeficiency Virus in Ear, Nose, and Throat 335

Part 2: Operative Procedures

Section 1: Ear

Chapter 50: Tympanoplasty 357
Chapter 51: Mastoidectomy 360
Chapter 52: Myringotomy 364
Chapter 53: Wax Removal 367

Section 2: Nose

Chapter 54: Septoplasty and Submucous Resection of Septum 369
Chapter 55: Polypectomy 373

Chapter 56: Functional Endoscopic Sinus Surgery 375
Chapter 57: Endoscopic Septoplasty 379
Chapter 58: Nasal Packing 381

Section 3: Throat

Chapter 59: Tonsillectomy 384
Chapter 60: Adenoidectomy 389
Chapter 61: Thyroidectomy 391
Chapter 62: Tracheostomy 394
Chapter 63: Cricothyroidotomy 404

Section 4: Various Scopy

Chapter 64: Laryngoscopy 406
Chapter 65: Microlaryngoscopy 409
Chapter 66: Esophagoscopy 411
Chapter 67: Bronchoscopy 413

Section 5: Recent Advances

Chapter 68: Laser in ENT 417
Chapter 69: Coblation 420
Chapter 70: Radiofrequency 423
Chapter 71: Cryosurgery 425
Chapter 72: Robotics in ENT 427
Chapter 73: Chemotherapy in ENT 429
Chapter 74: Radiotherapy in ENT 434

Part 3: Miscellaneous Topics

Chapter 75: Instruments in ENT 441
Chapter 76: Radiology in ENT (X-rays) 473
Chapter 77: CT Scan and MRI 491
Chapter 78: Anesthesia in ENT 499
Chapter 79: Pure Tone Audiogram and Impedance Audiometry 503

Part 4: Questions

Chapter 80: Objective Structured Clinical/Practical Examination (OSCE) 513
Chapter 81: Operative Specimens in ENT 520
Chapter 82: Mock Question Papers 529
Chapter 83: Multiple Choice Questions (MCQs) 532
Chapter 84: Case Presentation 538

Index *553*

Chapter

7

Diseases of Middle Ear

EN4.3: Elicit document and present a correct history, demonstrate, and describe the clinical features, choose the correct investigations and describe the principles of management of acute suppurative otitis media (ASOM).

ACUTE SUPPURATIVE OTITIS MEDIA

Q. Write a short note/essay on acute suppurative otitis media.

It is an acute infection of the mucosa of the middle ear cleft by pyogenic organisms.

Causative Organisms

- *Streptococcus pneumoniae*
- *Haemophilus influenzae*
- *Staphylococcus aureus*
- *Pneumococcus*
- *Moraxella catarrhalis*
- *Pseudomonas aeruginosa*

Etiology

- **Age:** More common in infants and children as the Eustachian tube is shorter, wider, and more horizontal.
- Commonly bilateral
- **Sex:** No gender predilection
- Recurrent attacks of upper respiratory tract infections and exanthematous fevers such as measles, diphtheria, or whooping cough.
- Infections of tonsils and adenoids
- Obstruction of the Eustachian tube by nasopharyngeal tumors
- Swimming
- Cleft palate
- **Iatrogenic:** Scarring of the Eustachian tube orifice during surgical procedures like adenoidectomy can damage the Eustachian tube.

Stages

Stage of Tubal Occlusion

There is edema and inflammation of the Eustachian tube causing a tubal obstruction which causes absorption of air in the middle ear cleft and negative intratympanic pressure. There is irritation of the middle ear mucosa and the tympanic membrane is retracted due to the negative pressure.

Patient complains of aural fullness and pain in the ear (otalgia).

On examination, the tympanic membrane is congested "cartwheel appearance." There is a loss of cone of light, the drum looks dull and is retracted.

JAYPEE BROTHERS

Stage of Exudation

If occlusion persists, there is an exudation from capillaries in the middle ear due to congestion **(Fig. 1)**. There is a collection of seromucinous exudate in the middle ear causing the tympanic membrane to bulge.

There is a marked throbbing type of earache with deafness and tinnitus. There is a high-grade fever and malaise.

The tympanic membrane is congested and bulged. A pressure point may be seen as a yellow nipple at one spot on the drum.

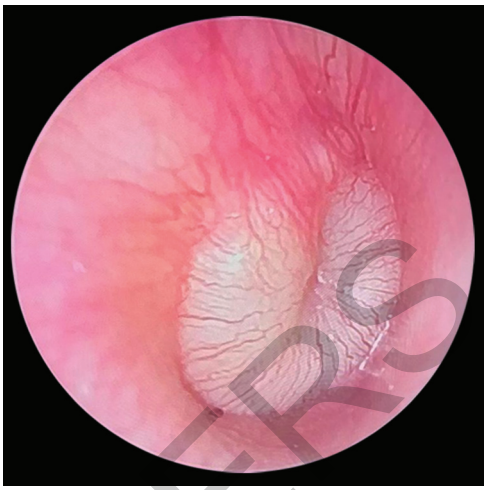

Fig. 1: Bulging and congested tympanic membrane in exudation stage.

Stage of Suppuration

The middle ear cavity is invaded by pyogenic organisms causing pus formation. Tension in the middle ear increases and ultimately leads to tympanic membrane perforation.

There is a mucopurulent otorrhea. Pain and fever reduce while deafness and tinnitus persist.

Tympanic membrane shows perforation usually in the anteroinferior quadrant with a pulsatile discharge "lighthouse sign".

Stage of Resolution

The infection resolves with the release of pus and subsidence of symptoms. It depends on the immunity of the host, virulence of organisms, and efficacy of antibiotics.

This stage can begin after any stage. Earache, fever, and malaise are relieved. If it occurs after suppuration, there may be a small perforation in the anteroinferior quadrant of the drum or may heal completely with a small scar formation or tympanosclerosis.

Stage of Complications

If the infection remained untreated or virulence of the organism is high or the immunity of the patient is low, the disease spreads beyond the middle ear cleft. It may lead to acute mastoiditis, subperiosteal postaural abscess, zygomatic abscess, Luc's abscess, Citelli's abscess, Bezold's abscess, facial paralysis, labyrinthitis, petrositis, extradural abscess, meningitis, brain abscess, or lateral sinus thrombophlebitis.

Investigations

- Tuning fork tests (Rinne's and Weber's tests) show a conductive hearing loss.
- **Tympanometry/impedance audiometry:** "C" type of curve in tubal occlusion/Eustachian catarrh stage
- Pus for culture and antibiotic sensitivity is done.
- **X-ray mastoid Schuller's view and high resolution computed tomography (HRCT) temporal bone:** Usually is normal. In cases of coalescent mastoiditis, there is a ground-glass appearance.
- **Pure tone audiogram:** It is not possible to perfume in the initial stage of the disease due to severe pain.
- It reveals conductive hearing loss. In cases of labyrinthitis due to complications, there is sensorineural hearing loss.

Treatment

Conservative Management

It consists of:

- **Systemic antibiotics:** Broad-spectrum antibiotics, mostly ampicillin and amoxicillin are given. Those allergic to penicillin may be given cefaclor, cotrimoxazole, or erythromycin.
- Anti-inflammatory analgesics to decrease inflammation and pain.
- Nasal decongestants to decrease Eustachian tube edema and promote ventilation of the middle ear.
- Antihistaminics
- Local antibiotics ear drops if there is perforation of the tympanic membrane.

Surgical Management

Myringotomy: An incision is made on the tympanic membrane to evacuate pus and to improve the middle ear cleft.

JAYPEE BROTHERS

ACUTE NECROTIZING OTITIS MEDIA

Q. Write a short note on acute necrotizing otitis media.

It is a variety of acute suppurative otitis media, caused by β-hemolytic ***Streptococcus***.

There is rapid destruction of the tympanic membrane with its annulus, mucosa of the promontory, ossicular chain, and mastoid air cells.

It heals by fibrosis with ingrowth of squamous epithelium into the middle ear cleft leading to secondary cholesteatoma formation.

Treatment

Antibacterial therapy for at least 7–10 days.

Cortical mastoidectomy may be indicated if medical treatment fails or there is acute mastoiditis.

EN4.4: Elicit document and present a correct history, demonstrate, and describe the clinical features, choose the correct investigations and describe the principles of management of otitis media with effusion.

OTITIS MEDIA WITH EFFUSION

Q. Write a short note on otitis media with effusion.

Also known as:

Serous otitis media, Secretory otitis media, Mucoid otitis media, Glue ear, Catarrhal otitis media.

It is characterized by nonpurulent effusion in the middle ear. The effusion is often thick and viscid but may be thin and serous.

Etiology

- **Age:** It is commonly seen in children, especially those below the age of 10 years.
- **Climate:** It is common in winter.
- **Eustachian tube obstruction:** Adenoid hypertrophy, nasopharyngeal tumors, scarring due to surgical procedure, chemoradiation.
- **Eustachian tube dysfunction:** Chronic rhinitis and sinusitis, patulous Eustachian tube.
- **Allergy:** It causes Eustachian tube obstruction along with the increased secretory activity of middle ear mucosa.
- **Viral infections:** Viral organisms of the upper respiratory tract may invade middle ear mucosa and stimulate it to increase secretory activity.
- **Barotrauma:** Sudden change in atmospheric pressure leads to negative intratympanic pressure and leads to serous effusion in the middle ear.
- Cleft palate, palatal paralysis.
- Impaired mucociliary clearance such as Young's syndrome and Kartagener's syndrome.
- Inadequate treatment of acute suppurative otitis media.

Clinical Features

Symptoms

- **Decreased hearing**: This is the most common presenting symptom. It is insidious in onset and usually bilateral.
- **Tinnitus**: It may present as a bubbling or whistling type.
- **Delayed and defective speech:** Due to hearing loss, there may be delayed or defective speech development.

Clinical Examination (Signs) and Investigations

- **Tympanic membrane:** Intact, dull, and maybe bulging **(Fig. 2)**. A cone of light is absent and sometimes fluid level or air bubbles may be seen behind an intact eardrum.
- Tuning fork test reveals conductive hearing loss.

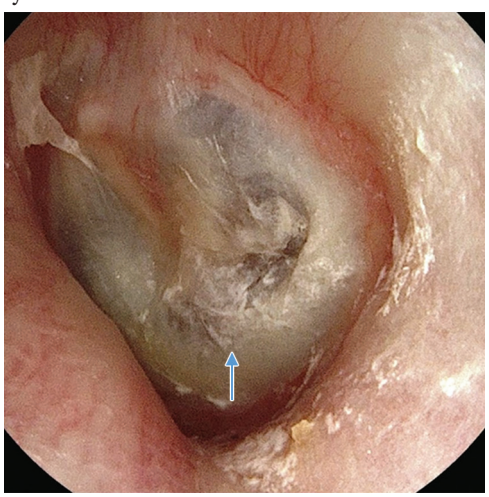

Fig. 2: Bulging and dull tympanic (arrow) membrane.

JAYPEE BROTHERS

- Pure tone audiometry reveals a conductive hearing loss of 20–40 dB. Sometimes a sensorineural component of hearing loss may be present.
- **Impedance audiometry**: It shows a flat "type B" curve.
- **X-ray mastoid Schuller's view:** Clouding of air cells due to fluid.

Treatment

Medical

- Nasal decongestants to decrease Eustachian tube edema.
- Antihistaminics to decrease allergic rhinitis.
- Antibiotics are helpful in cases of upper respiratory tract infections or unresolved acute suppurative otitis media.
- Valsalva maneuver, politzerization, or Eustachian tube catheterization to improve middle ear ventilation.

Surgical

- **Myringotomy and aspiration of fluid:** An incision is made in the tympanic membrane to drain the effusion. Radial incision is made in the anterosuperior quadrant of pars tensa.
- **Grommet insertion:** A grommet can be inserted through a myringotomy incision to provide prolonged aeration of the middle ear.
- **Tympanotomy or cortical mastoidectomy:** It is indicated in cases of recurrence or the presence of sequelae.
- **Surgical management of causative factor:** In children, adenoid hypertrophy is the most common cause of secretory otitis media (SOM), so **adenoidectomy is useful in most cases.**

Prophylaxis

- All children who seem inattentive should be investigated for middle ear effusion.
- Prompt treatment of rhinitis and upper respiratory infection.
- Proper treatment of acute suppurative otitis media.

Sequelae of Chronic Secretory Otitis Media

Q. What is the sequelae of chronic secretory otitis media?

- **Atelectasis**: It is characterized by medial retraction of the pars tensa **(Fig. 3)**. Due to prolonged effusions, the tympanic membrane becomes thin, atrophic, and retracts into the middle ear.
- **Tympanosclerosis:** It is characterized by chalky calcareous plaques in the subepithelial layer of the tympanic membrane **(Fig. 4).** There is hyaline degeneration of the fibrous layer with calcifications in the tympanic membrane or around the ossicular chain.
- **Ossicular necrosis**: A long process of incus is most commonly necrosed. If ossicular necrosis is present, the conductive hearing loss is >45 dB.

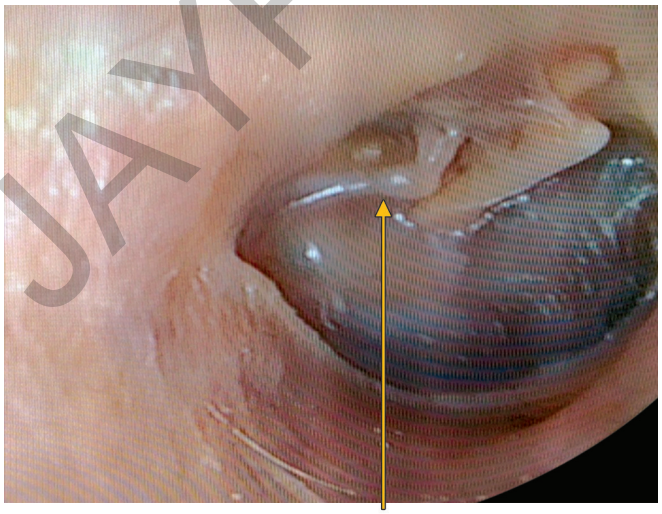

Draping of tympanic membrane over incudostapedial joint and prominent anterior and posterior malleolar folds

Fig. 3: Atelectasis (adhesive otitis media).



Fig. 4: Tympanic membrane with tympanosclerosis (arrows).

JAYPEE BROTHERS

for detailed information on otorhinolaryngology books, visit our website www.ejaypee.com, for detailed information on otorhinolaryngology books, visit our

GOLDEN NOTES IN ENT

Salient Features

- The book is thoroughly updated as per revised CBME curriculum by NMC.
- Theory and practical chapters are given in a question-answer format as per competencies.
- All the chapters are powered by tables, flowcharts, and clinical photographs.
- Video links for various procedures prepared by our team are a novel feature for better understanding of students, which would not be seen in many other ENT textbooks.
- In practical section, chapters consisting of sample long case and short case presentation along with frequently asked questions with clinical pictures are given. Also, chapters of history taking and examination are added with self-explanatory photographs.
- This is for the first time that chapters on instruments, radiology, pure tone audiogram and impedance audiometry, recent advances, and operative specimens with viva questions are covered.
- New chapters such as objective structured clinical/practical examination (OSCE) and mock question papers have also been added to accustom the students with exam patterns.
- Video demonstration of various procedures and audiology has been added for the first time.

Nilam Uttam Sathe MBBS MS (ENT) FCPS DORL is Associate Professor and Head of Unit, Department of Otorhinolaryngology at Seth GS Medical College (GSMC) and King Edward Memorial (KEM) Hospital, Mumbai, Maharashtra, India. She has also joined Wockhardt Hospital, Mumbai Central, and Fortis Hiranandani Hospital, Navi Mumbai, as a part time consultant ENT surgeon. She stood first with distinction in Mumbai University and is a Gold Medalist in MS (ENT) exams. She was awarded international scholar surgeon by the American Academy in October 2010 at Boston, USA. She was also awarded the best dissertation award and best consultant paper presentation award. She has got special nasal endoscopic sinus surgery fellowship training from Singapore and robotic surgeries in ENT and salivary endoscopy training from New Orleans, USA. She had launched the latest ear surgery, BAHA club "HEAR FOR ALL" on November 14, 2011. She is a recognized teacher for MBBS as well as MS (ENT) students approved by the Maharashtra University of Health Sciences (MUHS), Nashik, Maharashtra. She is also MS (ENT), PhD (ENT), Fellowship Otology, Rhinology and Laryngology, and MBBS examiner. She has been doing various ENT surgeries including rhinoplasty and cochlear implant surgeries since 25 years. She has published over 100 articles in various international and national ENT journals as an author.

Buy from ejaypee

JAYPEE BROTHERS

Shelving Recommendation
OTORHINOLARYNGOLOGY

ISBN 978-93-6616-908-8

9 789366 169088