ed information on otolaryngology books, visit our website www.jaypeebrothers.com, for detailed information on otolaryngology books, visit our website www.jaypeebrothers.com

Clinical Methods in ENT

With QR Codes for Examination and Procedure Videos

As per the Competency-based Medical Education Curriculum (NMC)



PT Wakode

Foreword
John Carruth

diginerve®
A Jaypee Initiative
• Video Lectures • Dr. Wise AI Chatbot
• Question Bank • Notes
Download App

3rd Edition

JAYPEE

Contents

PART I: Basics of History Taking

CHAPTER 1: Introduction **3**

- Bull's Eye Lamp *3*
- Head Mirror *4*
- Aural Speculum *5*
- Nasal Speculum *5*
- Laryngeal Mirrors *5*
- Post-Nasal Mirrors *6*
- Siegel's Pneumatic Speculum *6*
- Uses *6*
- Tuning Forks *7*
- Wire Vectis with Cerumen Spud *7*
- Tongue Depressor *7*
- Cotton Wool Carrier *8*
- Nasal Packing Forceps *8*
- Suction Cannula *9*
- Spirit Lamp *9*
- Sitting Arrangement *9*
- ENT OPD Workstation *9*
- Otoscope *10*

CHAPTER 2: History Taking **11**

- Name *11*
- Age *11*
- Gender *11*
- Occupation *11*
- Residence *12*
- Complaints *12*
- History of Present Illness *12*
- Past History *13*
- Personal History *13*
- Family History *13*
- Physical Examination *13*

CHAPTER 3: Examination of Swelling, Ulcer and Fistula **14**

- History *14*
- General Examination *15*
- Local Examination *15*

PART II: Otology

CHAPTER 4: Examination of Ear **25**

- Otorrhea *25*
- Hearing Loss *27*
- Tinnitus *28*
- Otalgia *28*
- Giddiness *29*
- Itching in the Ear *29*
- Blocking/woolly or FB Sensation in Ear *30*
- Autophony and Hyperacusis *30*
- Swelling in pre- and post-auricular Area *30*
- Bleeding from the Ear *30*
- Past History (History of Major Illnesses) *31*
- Family History *31*
- Personal History *31*
- General Examination *31*
- Local Examination *32*
- Weber Test *39*
- Systemic Examination *41*
- Radiological Examination of the Ear *42*
- Audiometry *44*
- Few Ear Conditions *47*
- Common Conditions of Middle Ear *52*
- Few Common Procedures *56*
- Caloric Test *57*

PART III: Rhinology

CHAPTER 5: Examination of Nose and Paranasal Sinuses **61**

- Nasal and Paranasal Sinuses Symptoms *61*
- Clinical Examination of Nose and PNS *67*
- Examination of External Nose and Face *67*
- Anterior Rhinoscopy *69*
- Posterior Rhinoscopy *71*
- Sinus Tenderness *72*
- Cold Spatula Test *72*
- Transillumination Test *73*
- Nasal Endoscopy *73*
- Advantages of Diagnostic Nasal Endoscopy *75*
- Atrophic Rhinitis *81*
- Rhinolith *82*
- Adenoiditis *82*
- Sinusitis *83*
- Deviated Nasal Septum *83*
- Nasal Polyps *84*
- CT Paranasal Sinuses *95*

PART IV: Head and Neck

Section A

CHAPTER 6: Oral Cavity and Oropharynx **101**
- Examination of Oral Cavity and Oropharynx *104*

CHAPTER 7: Examination of Larynx and Laryngopharynx **116**
- Change in Voice *116*
- Difficulty in Breathing *116*
- Stridor *117*
- Difficulty in Swallowing *117*
- Pain in Throat *118*
- Foreign Body *118*
- Cough *119*
- Neck Swelling *119*
- Indirect Laryngoscopy *119*
- Direct Laryngoscopy *120*
- Common Conditions Involving Larynx and Laryngopharynx *121*

CHAPTER 8: Thyroid Gland **127**
- History Taking *127*
- General Examination *128*
- Swelling in Thyroid Region *129*
- Examination of Thyroid Gland *129*
- Eye Signs *131*
- Systemic Examination *131*
- Types of Goiter *132*

Section B

CHAPTER 9: Examination of Neck **135**
- CECT Neck *147*

CHAPTER 10: Examination of Salivary Glands **150**
- Parotid Gland *150*

Section C

CHAPTER 11: Diseases of Esophagus **155**
- Dysphagia *155*
- Regurgitation *155*
- Bleeding *156*
- Respiratory Symptoms *156*
- Foreign Body in Esophagus *156*

CHAPTER 12: Tracheobronchial Tree **162**
- Anatomy *162*
- Examination of Trachea and Bronchi *162*
- Diseases of Trachea and Bronchi *163*

PART IV: Examination of Cranial Nerves

CHAPTER 13: Examination of Cranial Nerves **171**
- Olfactory Nerve *171*
- Optic Nerve *172*
- Oculomotor Nerve *173*
- Trochlear Nerve *174*
- Trigeminal Nerve *174*
- Facial Nerve *177*
- Vestibulocochlear Nerve *179*
- Glossopharyngeal Nerve *182*
- Vagus Nerve *183*
- Spinal Accessory Nerve *183*
- Hypoglossal Nerve *184*

CHAPTER 14: Facial Trauma **186**
- Examination of Facial Trauma Cases *186*
- Structures to be Seen and Examined *186*
- Nasal Bone and Nasal Septum Fracture *187*
- Nasomaxillary Complex (Lefort Fractures) *188*
- Clinical features *188*
- Zygoma Fracture (Tripod Fracture) *188*
- Orbital Fracture *189*
- Fractures of Mandible *190*

Case Studies *193*

OSCE Questions *215*

OSCE Answers *231*

Index *237*

3 CHAPTER

Examination of Swelling, Ulcer and Fistula

INTRODUCTION

You must have learnt by heart the methods of examining swelling, ulcers and fistula during your posting in general surgery. In ENT, the basic pattern remains the same, with little modifications here and there. Examination of these lesions is so important that even with the charge of repetition I would like to discuss it.

HISTORY

Duration

The patient should be asked, *how long he is having the swelling?* The swelling may be there for a long, but the patient may not have noticed it or being painless might have neglected it. Swellings of acute onset may be inflammatory or post-traumatic in origin. Swellings of very long duration are usually benign.

Mode of Onset

Ask the patient *how the swelling progressed?* A swelling may progress very fast in traumatic conditions or may progress very slowly in benign conditions. Certain swellings are slow in progress for a long period and then suddenly they increase in size or initiate pain. This is usually seen with a malignant change in mixed parotid tumor or sudden hemorrhage in the thyroid.

Associated Symptoms

Swellings in the head and neck region due to their anatomical location may cause a change in voice. A peritonsillar abscess may give rise to a plummy voice. A large tumor over the neck may compress the vessels and nerves of the neck and may cause loss of function of the nerves involved. Say, for example, there may be 9, 10, 11 or 12th cranial nerve palsy when a large tumor compresses over the nerve trunk, giving rise to various symptoms. Compression over the cervical sympathetic chain may result in *Horner's syndrome*. Compression over the trachea/esophagus may cause respiratory distress or dysphagia. Dysphagia of long duration may cause weight loss in a patient. All these symptoms need to be analyzed properly. Swelling may be associated with pain. In that case, details of pain like the nature of pain, site, time of onset, severity, spread, aggravating factors, and ameliorating factors all should be asked in detail. At times, it may be fever with/without rigor. And details of it should be taken.

JAYPEE BROTHERS

At times, a patient's main concern is swelling in the neck. But he may have primary malignancy somewhere in the nose/nasopharynx or laryngopharynx. And this possibility should always be kept in mind while examining a patient and relevant symptoms should be asked.

Exact Site

To begin with, swelling may be very small arising from one site and then gradually enlarges to cover up a large area. The patient should be asked about the exact site where from the swelling started. This may give information about the tissue of origin of the swelling.

Other Swellings Over Body

A patient may be asked whether there is any swelling elsewhere on the body. Examples include multiple neurofibromas, Hodgkin's disease, and lipomas may be seen at more than one place on the body.

GENERAL EXAMINATION

The build, attitude and look of the patient may be given proper attention in addition to vital parameters like temperature, pulse, respiration, BP, pallor, edema feet, etc.

LOCAL EXAMINATION

Local examination of swelling is very important, and it helps the clinician to come to a clinical diagnosis. Hence, this part of the examination should be done very carefully and meticulously. The number of swellings should be noted. The pattern of examining a swelling is universal and is followed here with relevance to otolaryngology.

Examination of swelling is done in the following manner:

A. Inspection
B. Palpation
C. Percussion
D. Auscultation.

Inspection

Site

The site of the swelling may give you a clue about its origin and hence, careful inspection of the exact location of the swelling is a must.

Size

The size of the swelling should be noted down in vertical and horizontal directions. Say, for example, the swelling is 4 cm × 4 cm located between the tragus and the angle of mouth in a horizontal direction and between zygomatic arch to the lower alveolus in a vertical direction.

Shape

The swelling may be spherical, ovoid, or irregular. Shape may not be clear in some swellings where it is called diffuse.

JAYPEE BROTHERS

Surface

The surface of the swelling may be smooth, globular or irregular.

Margins

Margins of a swelling may be well-defined or poorly defined.

Skin Over Swelling

The skin overlying the swelling may be red, edematous in inflammatory swellings. It may be tense glossy with prominent blood vessels over it, in case of sarcoma. A punctum may be seen on the skin in the sebaceous cyst. Scar mark over the swelling indicates previous operation or application of irritants to the swelling or burst abscess.

Pulsations

Swellings that arise from arteries may be pulsatile. The swelling that is in close vicinity of blood vessels may transmit vascular pulsations.

Color

Hemangiomas give a reddish color to the tumor mass and black color may be imparted by melanoma.

Change in Size of Swelling on Coughing/Straining or Valsalva

Few swellings do change in size on coughing/straining or after performing a Valsalva maneuvers. Examples *are* Meningocele and Laryngocele.

Palpation

In palpation, the findings noted down in inspection are confirmed and additional findings are searched, if any.

- **Local temperature:** This is the first thing to be noted in palpation of swelling. It should be done by the dorsum of the hand. Local temperature is raised in inflammatory swellings.
- **Tenderness:** When a patient experiences pain on pressing the swelling gently it is known as tenderness. It is usually seen in inflammatory swellings.
- **Size:** The size of the swelling observed in inspection is confirmed by palpation and dimensions in vertical and horizontal direction are noted down.
- **Shape:** Shape can be better delineated by palpation.
- **Surface:** The surface of swelling may be smooth (e.g., cyst) lobular (e.g., lipoma) or nodular (multinodular goiter) or irregular (malignancy). The pulp of fingers/palms is used to know the surface of swelling.
- **Margins:** Margins of swelling may be well-defined or poorly defined and should be palpated with tips or margins of fingers. Inflammatory and neoplastic swellings may have poorly defined margins.
- **Consistency:** The consistency of a swelling is:
  - *Soft:* when it is comparable to the consistency of your lips.
  - *Firm:* When it is comparable to the consistency of the tip of the nose.
  - *Hard:* When it is comparable to the consistency of your forehead.
  - *Cystic:* When it is comparable with water water-filled balloon.

JAYPEE BROTHERS

❖ The consistency of a swelling may be homogenous throughout the swelling or may change at different places. This variable consistency may be seen in malignancy.

Fixity to Skin

Some of the swellings do arise from skin appendages itself, like a sebaceous cyst. One cannot move the overlying skin in such lesions. However, overlying skin can be moved when the swelling is deeply situated. If the overlying skin is involved in a malignant process, it cannot be moved.

Mobility of Swelling

Swelling should be grasped in the hand and moved in vertical and horizontal directions to see whether it is mobile or fixed to deeper structures. Fixity is an important feature of advanced malignancy, which may contraindicate surgical intervention.

Then there are certain signs, which can be elicited to get additional information about the swelling.

These signs are:

Fluctuation (Figures 3.1A and B)

The sign of fluctuation is an important clinical sign, which can be elicited as follows:

Fix both the poles of the swelling between the thumb and fingers of both hands and press one pole of swelling with an index finger. The fingers used to fix the swelling appreciate the change in the pressure. In case of a very small swelling, it is pressed at the center and pressure changes are felt at the periphery of the swelling. Example, neck abscess, or any swelling containing fluid.

Transillumination Test (Figure 3.2)

This test can be carried out when you suspect fluid in the swelling. It should preferably be done in a dark room. The clinician should sit in the dark room with his eyes closed for 10 minutes to get a 'dark adaptation.' A small pencil torch is applied close to the swelling at one end and swelling is observed through a paper roll at the other end. If the swelling contains clear fluid, it would be brightly transilluminated. If the fluid inside the swelling is turbid or thick, the swelling may be translucent or opaque. *Swellings in the head and neck region that are brilliantly transilluminant are cystic hygroma and ranula.*

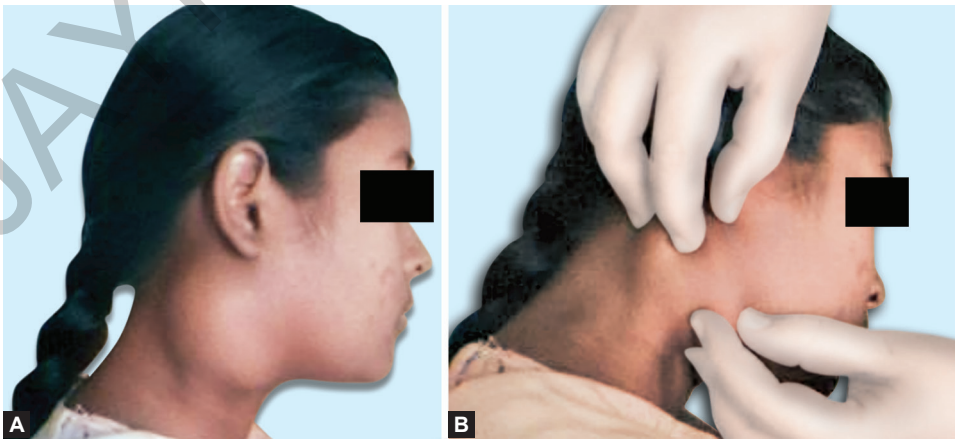

Figures 3.1A and B: (A) Swelling on right side of neck, and (B) How to elicit fluctuation.

JAYPEE BROTHERS

Reducibility

The reducible swelling disappears completely or partly on compression. This happens because the swelling has a connection with the body cavity. And on compression swelling gets pushed into the cavity. Examples are external laryngoceles and meningocele.



Figure 3.2: How to elicit transillumination test.

Compressibility (Figures 3.3A and B)

Swellings, which decrease in size on firm pressure or compression, are called compressible swellings. For example, lymphangioma/hemangioma. This happens due to squeezing out of the blood collected in the tumor mass.

Pulsatile Swelling

A swelling in close vicinity of an artery or arising from the wall of the artery may transmit pulsations of the underlying vessel or may itself be expansible. If you keep two fingers on such a swelling as wide apart as possible, the fingers are lifted up with every stroke of a pulse (e.g., carotid body tumor). When the swelling is expansible the fingers are not only lifted up, but they are also separated from each other with every stroke of a pulse (e.g., aneurysm).

Percussion

This may not be that useful in the examination of swellings.

Auscultation

Bruit may be heard over the swellings arising from a blood vessel or a highly vascular lesion or when the swelling compresses the blood vessel. For example, thyroid nodule.

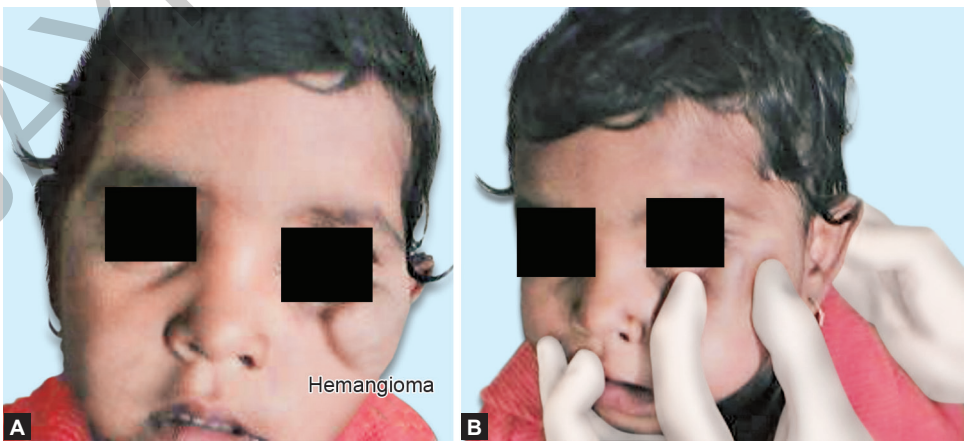

Figures 3.3A and B: Compressibility in hemangioma.

JAYPEE BROTHERS

Regional Lymph Nodes

In any head and neck swelling, the regional lymph nodes should be palpated to know whether they are enlarged, tender or otherwise. If one group of lymph nodes is affected the other groups of nodes should also be examined.

Examination of Sinus or Fistula

Sinus

A blind tract lined by epithelium that communicates the inner tissues with skin. For example, tuberculous neck sinus.

Fistula (Figure 3.4)

A fistula is an open tract communicating two epithelial surfaces, e.g., oroantral fistula.

While examining a fistula or sinus following aspects do need attention:



Figure 3.4: Multiple fistulae over face. A probe entering in oral cavity through fistula.

- **Position:** Many sinuses or fistulae have a typical position and thus help in diagnosis.
  - *The branchial fistula* is usually situated at the lower third of the neck in front of the sternomastoid muscle.
  - *Thyroglossal fistula* is located in the midline.
  - *The preauricular sinus* is located at the root of the helix.
- **Number:** Usually fistula is single in number. But may be multiple in tuberculosis and actinomycosis.
- **Discharge:** The character of the discharge may be noted. It may be thin whitish discharge in tuberculosis, frank pus in osteomyelitis, or 'Sulphur granules' in case of actinomycosis.
- **Surrounding skin:** May show scarring in case of tuberculous fistula. Repeated infections in the sinus may cause scarring and thinning of surrounding skin.
- The sinus or fistula should be palpated for tenderness. The thickness of the wall should be noted down. *Probing* of the sinus/fistula may be done to know the depth and direction of the tract.
- **Fistulography:** Radio-opaque dye may be injected into the fistula and X-rayed to delineate the tract.

At times, the opening of the sinus may be closed and form a cystic swelling.

Examination of Ulcer (Figure 3.5)

Definition: Ulcer is a breach in the continuity of skin or mucous membrane.

History

Ask the patient, *How the ulcer started?*

Is there any history of trauma or surgery or did it develop spontaneously?

Is there a history of local pain, or fever before ulcer formation?

Are there patches of hypoesthesia over the body?

JAYPEE BROTHERS

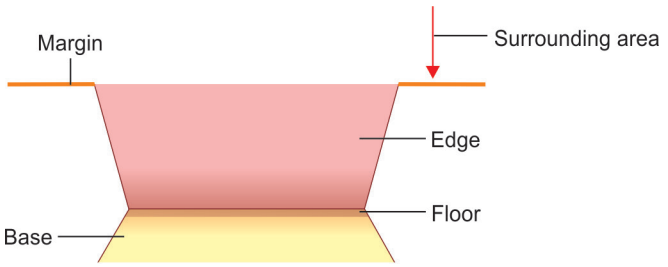

Figure 3.5: A diagrammatic representation of an ulcer.

Is there a history of diabetes, tuberculosis or malnutrition?

How long the ulcer is there? This would tell you whether the ulcer is acute or chronic in nature. Aphthous ulcers and traumatic ulcers are examples of acute ulcers. However, ulcers due to tuberculosis and malignancy may be chronic in nature.

Is the ulcer painful? Aphthous ulcers are highly painful, while malignant ulcers may not be painful.

Is ulcer discharging? The nature of discharge should be enquired.

"Are the ulcers increasing in number or size?"

"Are there ulcers over other parts of the body, e.g., genitals?"

Examination of Ulcer

- **Inspection:**
  - *Number*—Note whether the ulcer is single or multiple.
  - *Site*—Note down where the ulcer is located. It would give you an idea about the tissue of origin.
  - *Size*—Note down the vertical and horizontal dimensions of the ulcer.
  - *Shape*—Aphthous ulcers are oval or round. Syphilitic ulcers are serpiginous and malignant ulcers are irregular.
  - *Discharge:*
    - Serous discharge may be seen in nonhealing ulcers.
    - Serosanguinous discharge may be seen in healing ulcers or at times in malignant ulcers.
    - Purulent discharge may be seen in spreading ulcers.
    - 'Sulphur Granules' discharge may be seen in actinomycotic ulcers.
  - *Floor:* This part of the ulcer contains granulation tissue, discharge and/or slough. Granulation tissue may be pink (pinhead size) in healing ulcers. Pale flat granulation tissue in chronic nonhealing ulcers and unhealthy granulation tissue with slough in spreading ulcers.
  - *Edges:* Edge is the type of union between the floor and the margin of the ulcer **(Figure 3.6)**.
    - Punched out edges, e.g., syphilitic ulcers.
    - Undermined edges, e.g., tuberculous ulcers.
    - Everted edges, e.g., malignant ulcer.
    - Slopping edges, e.g., healing ulcer.
  - *Margin:*
    - *Healing margin:* This may show the outer white zone of epithelization. Middle blue zone of regenerating epithelium and inner red zone of healthy granulation tissue.

JAYPEE BROTHERS

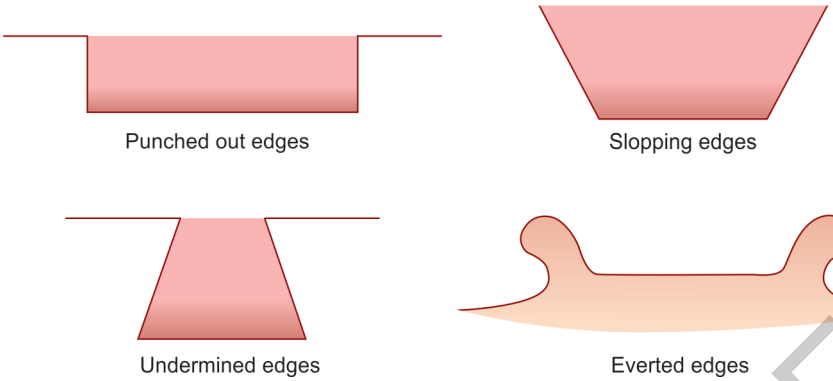

Figure 3.6: Type of edges.

- *Inflammed margin:* It shows signs of inflammation and is seen in spreading ulcers.
- *Fibrotic margin:* This ulcer shows evidence of fibrotic tissue in the margin. It is seen in chronic nonhealing ulcers.

- *Surrounding area:* The area surrounding the ulcer should be inspected for any scar, excoriation of skin, oedema, sinus formation, dilated blood vessels, etc.

❖ **Palpation:** Palpation of the ulcer should be done carefully for

- Local temperature
- Tenderness
- The edges of the ulcer should be palpated, and the findings of the inspection are confirmed.
- The base of the ulcer should be palpated for any induration. It should be noted whether the ulcer bleeds on touch or not. And fixity of the ulcer to the structures down below may be tested by *mobility test*. Moving the base of the ulcer in two directions checks the mobility of the ulcer. One along the direction of the underlying muscle and one perpendicular to it. This mobility may be tested by contracting the underlying muscle against resistance and without contracting the muscle.

Note: If the ulcer moves freely before and after contracting the underlying muscle, it is superficial. If the mobility is reduced after contracting the muscle, the ulcer has infiltrated the muscle. If the ulcer is immobile even without contracting the muscle, it is fixed to the underlying bone.

JAYPEE BROTHERS

JAYPEE BROTHERS

for detailed information on otolaryngology books, visit our website www.jaypeebrothers.com, for detailed information on otolaryngology books, visit our website www.jaypeebroth

Clinical Methods in ENT

Salient Features

- Handbook for undergraduate students, interns, and postgraduate students with an emphasis on clinical-based medical education, as prioritized by the National Medical Commission.
- 38 QR codes added, which equate to hand-holding for the students.
- Chapter on "Facial Injury", Case studies and OSCE added, which will give more comprehensive information to learners.
- Clinical photographs, radiological images, and explanatory notes are added wherever necessary.

PT Wakode, Dean, Shri Shankaracharya Institute of Medical Sciences, Bhilai, Chhattisgarh, India, has more than 40 years of experience as a medical teacher. After retiring from Government of Maharashtra as Joint Director, Medical Education, he joined the present Institute. He was an awardee of Commonwealth Medical Fellowship to UK in 1988 and served in Faculty Development Program for 3 years in Nepal.

Printed in India

Available at all medical bookstores or buy online at www.ejaypee.com

JAYPEE BROTHERS
Medical Publishers (P) Ltd.
EMCA House, 23/23-B, Ansari Road,
Daryaganj, New Delhi - 110 002, INDIA
www.jaypeebrothers.com

Join us on facebook.com/JaypeeMedicalPublishers
Follow us on instagram.com/JaypeeMedicalPublishers

Shelving Recommendation
OTOLARYNGOLOGY

ISBN 978-93-6616-938-5