detailed information on nursing books, visit our website www.ejaypee.com, for detailed information on nursing books, visit our website www.ejaypee.com,



NURSING

Solved Question Papers for BSc Nursing

2025–2021

Semester I

As Per Revised INC Syllabus

I Clement

JAYPEE

Contents

SECTION I: Applied Anatomy

Applied Anatomy: 2025 1
Applied Anatomy: 2024 11
Applied Anatomy: 2023 18
Applied Anatomy: 2022 24
Applied Anatomy: 2021 36

SECTION II: Applied Physiology

Applied Physiology: 2025 50
Applied Physiology: 2024 58
Applied Physiology: 2023 66
Applied Physiology: 2022 73
Applied Physiology: 2021 80

SECTION III: Applied Sociology

Applied Sociology: 2025 88
Applied Sociology: 2024 95
Applied Sociology: 2023 101
Applied Sociology: 2022 108
Applied Sociology: 2021 114

SECTION IV: Applied Psychology

Applied Psychology: 2025 130
Applied Psychology: 2024 138
Applied Psychology: 2023 144
Applied Psychology: 2022 151
Applied Psychology: 2021 165

APPLIED ANATOMY

2023

LONG ESSAY

1. Explain the structure of circle of Willis with neat diagram.

SHORT ESSAYS

2. Explain about thoracic duct.
3. Explain the structure of biceps brachii muscle.
4. Describe neuromuscular junction with a neat, labelled diagram.

SHORT ANSWERS

5. List the properties of muscle.
6. Name the muscles of pharynx.
7. Draw the diagram of gross structure of Kidney.

JAYPEE BROTHERS

LONG ESSAY

1. Explain the structure of circle of Willis with neat diagram.

A The circle of Willis (circulus arteriosus) is an anastomotic arterial ring located at the base of the brain **(Fig. 1)**. It provides a connection between the four main arteries that supply the brain (two vertebral and two internal carotid arteries), protecting against ischemia in the event of single vessel occlusion.

Structure

The circle of Willis is located in the subarachnoid space at the base of the brain. It lies in close proximity to the optic chiasm. It is pentagonal-shaped and formed by the following vessels:

- **Anterior communicating artery**—a short vessel which connects the two anterior cerebral arteries.
- **Anterior cerebral arteries**—branches of the internal carotid artery.
- **Internal carotid arteries**—continues after the contributing to the circle of Willis as the middle cerebral artery.
- **Posterior communicating arteries**—connects the internal carotid and posterior cerebral arteries.
- **Posterior cerebral arteries**—terminal branches of the basilar artery (which is formed by the union of the vertebral arteries).

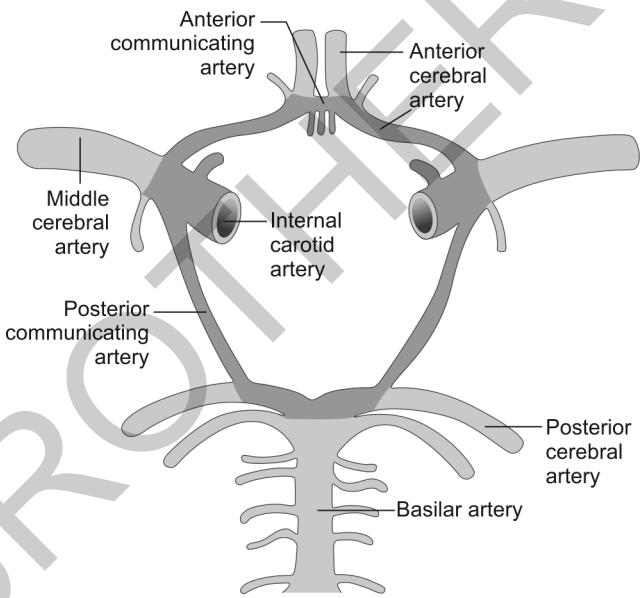

Fig. 2: Anterior and posterior circulation.

Supply

The circle of Willis gives rise to numerus vessels which supply the cerebrum and cerebellum. This can broadly be divided into the anterior circulation and posterior circulation **(Fig. 2)**.

Anterior Circulation (Internal Carotid System)

- Anterior cerebral arteries.
- Anterior communicating artery.
- Middle cerebral arteries.

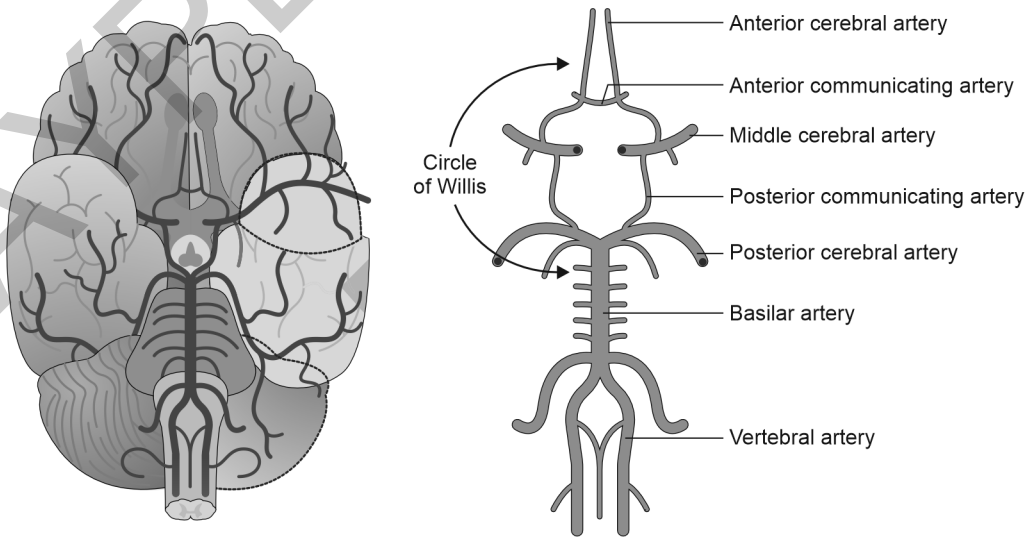

Fig. 1: Circle of Willis.

JAYPEE BROTHERS

Posterior Circulation (Vertebrobasilar System)

- Posterior cerebral arteries.
- Posterior communicating arteries.
- Numerous small branches arise from these vessels (and from the circle of Wilis itself) to supply the brain.

Applied Anatomy

- **Stroke:** The structure and function of the circle of Willis may protect against stroke in people who have a complete circle of Willis. The complete circle allows blood to go from one side of the brain to the other, even when blockages or thinning vessels occur.
- **Aneurysms:** The circle of Willis is a very common place for intracranial aneurysms to occur. Aneurysms refer to arteries that bulge or balloon out. The major risk with aneurysms is rupturing, which causes bleeding in the brain.
- **Subclavian steal syndrome:** It occurs when there is not enough blood supply to an arm through the subclavian artery. When this happens, extra blood flows through the circle of Willis to make up for the lack of blood supply, but this may result in insufficient blood going to the brain.

SHORT ESSAYS

2. Explain about thoracic duct.

A The thoracic duct is the largest lymphatic vessel in the human body. Around 75% of the lymph from the entire body (aside from the right upper limb, right breast, right lung and right side of the head and neck) passes through the thoracic duct.

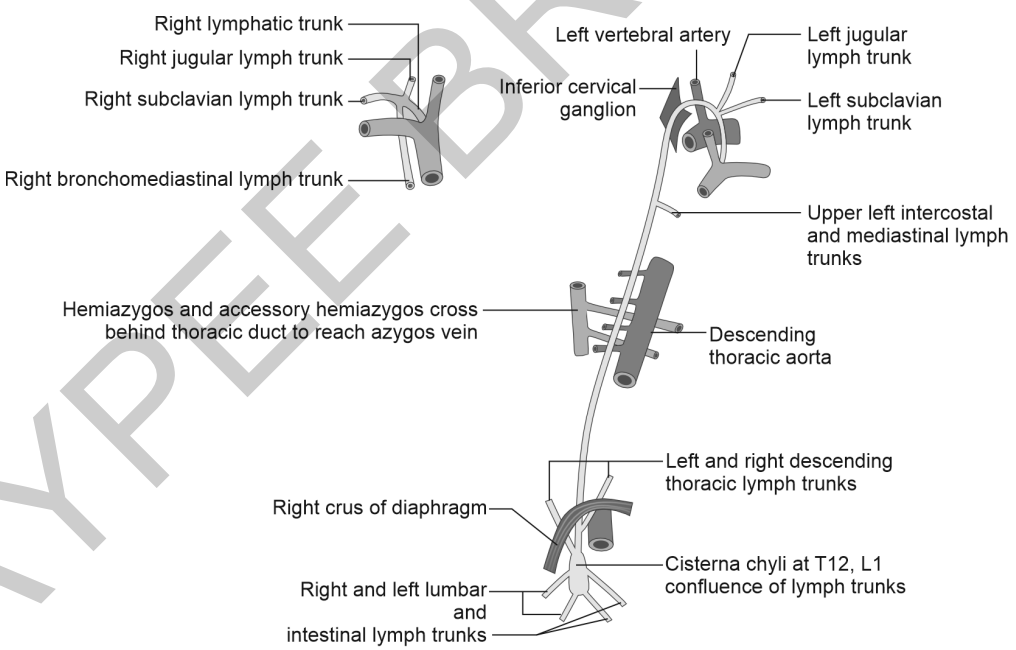

Thoracic duct
45 cm long (see also spinal cord, femur, vas, transverse colon, teeth/cardia)
Several terminal branches. Many valves in the system
Drains all lymph below diaphragm, left head/neck and left thorax
Commences at T12, ascends behind right crus, to right of aorta and oesophagus, then behind oesophagus, crosses midline at T5
Lies superficial (anterior) to posterior intercostal arteries and the crossing azygos systems, over the dome of the pleura, over (anterior) to left vertebral and left subclavian arteries, into confluence of left subclavian and left internal jugular veins

Fig. 3: Thoracic duct.

JAYPEE BROTHERS

Table 1: Thoracic duct.

Anatomy	**Location:** Paravertebral from T12 to the root of the neck
Tributaries	**Main tributaries:** Left and right lumbar lymph trunks, left and right intestinal lymph trunks (their confluence is called cisterna chyli) **Additional tributaries:** Mediastinal lymph trunks, left jugular trunk, left bronchomediastinal trunk, left subclavian trunk
Drainage	**Drains from:** 75% of the body → all region except for the right arm, right breast, right lung, right side of the head and neck (which are drained by the right lymphatic duct) **Drains to:** Venous angle (Pirgoff's angle) between left subclavian vein and left internal jugular vein
Clinical relations	Chylothorax, Virchow's node, thoracic duct fistula

Applied Anatomy

- **Chylothorax:** Rupture of the thoracic duct causes chyle to leak into the pleural cavity. The etiology of this condition includes traumatic and nontraumatic causes. Traumatic causes can be either iatrogenic (e.g., surgery, radiation) or non-iatrogenic (e.g., penetrating or blunt trauma to the chest wall, forceful emesis or cough).
- **Virchow's node:** Virchow's node is a large lymph node in the left supraclavicular area that drains the lymph from the gut. When it is enlarged (positive Troisier's sign), it can be one of the earliest signs of intra-abdominal malignancy, usually a gastric carcinoma following migration of tumor emboli through the thoracic duct.
- **Thoracic duct fistula:** This commonly occurs when surgery takes place in the lower part of the left side of the neck. It can lead to prolonged hospital stay, due to protein, electrolyte and fluid imbalances. Presentation will be leakage of milky white fluid from the neck following the incision.

3. Explain the structure of biceps brachii muscle.

A The biceps brachii (BB), commonly known as the biceps, is a large, thick muscle on the ventral portion of the upper arm. The muscle is composed of a short head and a long head. The long head is located on the lateral side of the biceps brachii while the short head is located on the medial side. The biceps brachii works across three joints, and is able to generate movements in glenohumeral, elbow and radio-ulnar joints.

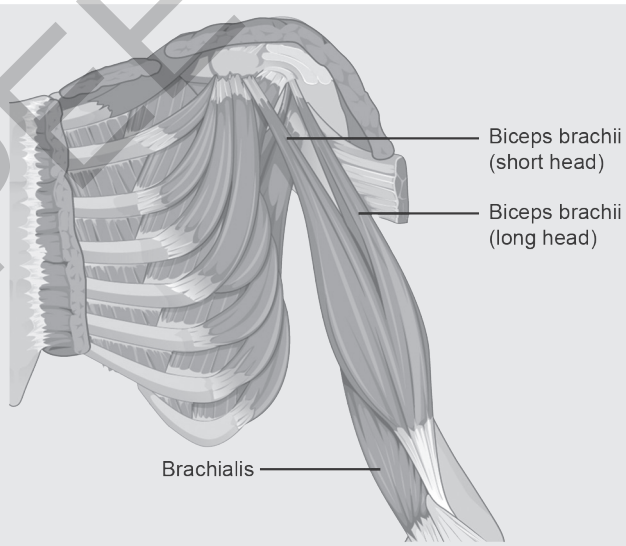

Biceps brachii muscle

Origin	• **Short head:** Apex of the coracoid process of the scapula • **Long head:** Supraglenoid tubercle of the scapula • **Mnemonic:** 'You walk shorter to a street corner. You ride longer on a superhighway'

Contd...

JAYPEE BROTHERS

Contd...

Insertion	Radial tuberosity of the radius Deep fascia of forearm (insertion of the bicipital aponeurosis)
Innervation	Musculocutaneous nerve (C5–C6)
Blood supply	Branches of brachial artery
Function	Flexion and supination of the forearm at the elbow joint, weak flexor of the arm at the glenohumeral joint

Applied anatomy: Biceps tendinitis is an inflammation of the long biceps tendon often caused by a bursitis or other tendinitides involving the rotator cuff, more rarely through overuse. In severe cases the tendon can even tear apart completely (biceps tendon rupture).

4. Describe neuromuscular junction with a neat, labelled diagram.

A The neuromuscular junction (NMJ) is a synaptic connection between the terminal end of a motor nerve and a muscle (skeletal/smooth/cardiac). It is the site for the transmission of action potential from nerve to muscle **(Fig. 4)**.

The neuromuscular junction is composed of three major structures. The presynaptic vesicles, the synaptic cleft, sometimes called the synaptic junction, and the post-synaptic membrane of the skeletal muscle cell containing neurotransmitter receptors.

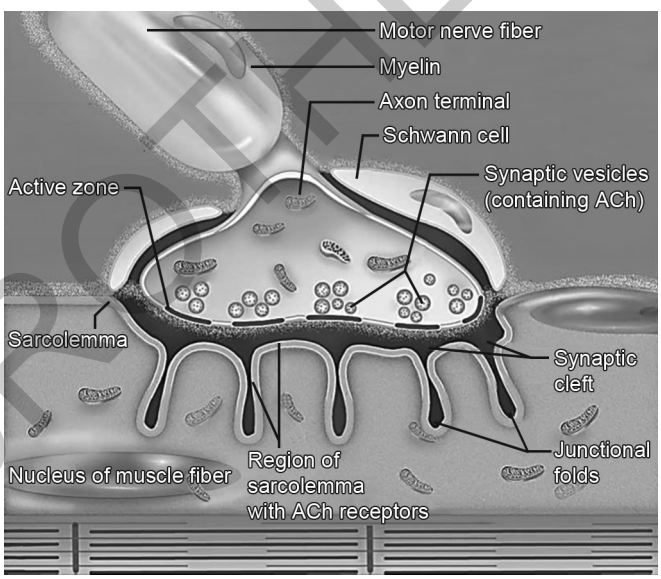

Fig. 4: Neuromuscular junction.

Structure

Skeletal muscle fibers are innervated by the motor nerve fibers. Each nerve fiber (axon) divides into many terminal branches. Each terminal branch innervates one muscle fiber through the neuromuscular junction.

- **Axon terminal and motor endplate:** Terminal branch of nerve fiber is called axon terminal. When the axon comes close to muscle fiber, it loses the myelin sheath. So, the axis cylinder is exposed. This portion of the axis cylinder is expanded like a bulb, which is called motor endplate. The Axon terminal contains mitochondria and synaptic vesicles. Synaptic vesicles contain the neurotransmitter substance, acetylcholine (Ach). The Ach is synthesized by mitochondria present in the axon terminal and stored in the vesicles. Mitochondria contain ATP, which is the source of energy for the synthesis of acetylcholine.
- **Synaptic trough or gutter:** Motor endplate invaginates inside the muscle fiber and forms a depression, which is known as synaptic trough or synaptic gutter. The membrane of the muscle fiber below the motor endplate is thickened.
- **Synaptic cleft**
  - Membrane of the nerve ending is called the presynaptic membrane. Membrane of the muscle fiber is called postsynaptic membrane. Space between these two membranes is called synaptic cleft.
  - Synaptic cleft contains basal lamina. It is a thin layer of spongy reticular matrix through which the extracellular fluid diffuses. An enzyme called acetylcholinesterase (AchE) is attached to the matrix of basal lamina, in large quantities.
- **Subneural clefts:** Postsynaptic membrane is the membrane of the muscle fiber. It is thrown into numerous folds called subneural clefts. Postsynaptic membrane contains the receptors called nicotinic acetylcholine receptors.

Applied Anatomy

- **Myasthenia gravis:** Myasthenia gravis is an autoimmune disorder of neuromuscular junction caused by antibodies to cholinergic receptors. Refer Chapter 34 for details.
- **Eaton–lambert syndrome:** Eaton–Lambert syndrome is also an autoimmune disorder of neuromuscular junction. It is caused by antibodies to calcium channels in axon terminal.

JAYPEE BROTHERS

SHORT ANSWERS

5. List the properties of muscle.

All muscle cells share several properties: Contractility, excitability, extensibility, and elasticity:

- **Contractility** is the ability of muscle cells to forcefully shorten. Contractility allows muscle tissue to pull on its attachment points and shorten with force (muscles can only pull, never push.)
- **Excitability** is the ability to respond to a stimulus, which may be delivered from a motor neuron or a hormone.
- **Extensibility** is the ability of a muscle to be stretched or extended.
- **Elasticity** is the ability to a muscle to return to its original length when relaxed.

6. Name the muscles of pharynx.

The three paired muscles of the inner pharynx act as a group in order to elevate the larynx, shorten the pharynx and act during swallowing and speaking. These muscles are known as the stylopharyngeus, the palatopharyngeus and the salpingopharyngeus.

7. Draw the diagram of gross structure of kidney.

Each kidney weighs about 125–175 g in males and 115–155 g in females. They are about 11–14 cm in length, 6 cm wide, and 4 cm thick, and are directly covered by a fibrous capsule composed of dense, irregular connective tissue that helps to hold their shape and protect them **(Fig. 5)**.

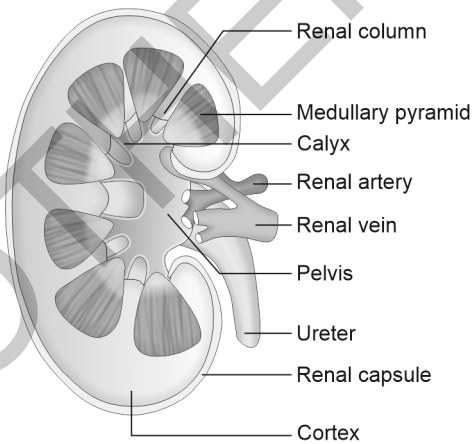

Fig. 5: Structure of kidney.

MULTIPLE CHOICE QUESTIONS

1. The neck is referred to as:
a. Cervical region
b. Gluteal region
c. Lumbar region
d. Pelvic region

2. Raising the lateral border of the foot is:
a. Eversion
b. Inversion
c. Pronation
d. Supination

3. The hormone which increases the water re-absorption and produces concentrated urine is:
a. Anti-diuretic hormone (ADH)
b. Adrenocorticotropic hormone (ACTH)
c. Follicular stimulating hormone (FSH)
d. Somatotrophic hormone

4. Semicircular cells are present in:
a. Cochlea
b. Internal ear
c. Middle ea
d. Outer ear

5. Cervix is supplied by:
a. Pelvic splanchnic nerve
b. Pudendal nerve
c. Lumbar-5
d. Sacral nerve

6. Lateral corticospinal tract transmits at:
a. Anterior horn cells of spinal cord
b. Clarke's column
c. Substantia gelatinosa
d. Lateral nucleus of thalamus

ANSWERS

1. a	**2. a**	**3. a**	**4. b**
5. a	**6. a**		

JAYPEE BROTHERS

detailed information on nursing books, visit our website www.ejaypee.com, for detailed information on nursing books, visit our website www.ejaypee

NURSING

Solved Question Papers for BSc Nursing

Salient Features

- *First-year subjects such as:* Applied Anatomy and Applied Physiology and Applied Sociology and Psychology.
- *Comprehensive Coverage:* Offers in-depth coverage of subjects for Semester I: Applied Anatomy and Applied Physiology and Applied Sociology and Psychology aligning with Indian Nursing Council (INC) syllabi.
- *Diagrams and Tables:* This book contains many tables and diagrams. The diagrammatic and tabular presentation of the content helps to facilitate quick review and recall of the important concepts.
- *Exam Preparation:* Familiarizes students with exam formats, question types (MCQs, short/long answers), and typical question patterns from previous years (e.g., 2025–2021 papers).
- *Develops Critical Thinking:* Exposure to varied question formats challenges students to apply knowledge, enhancing critical thinking and problem-solving skills.
- *Self-Assessment:* Provides a tool for self-evaluation, helping students gauge their understanding and identify weaknesses before exams.

I Clement MA MSc (N) PhD (N) is currently working as Dean and Professor in St Benedict's Institute of Nursing, Bengaluru, Karnataka, India. He has obtained Doctorate in Nursing from Sri Ramachandra Institute of Higher Education, Chennai, and postgraduation from The Tamil Nadu Dr MGR Medical University, Chennai (Annai JKK Sampoorani Ammal College of Nursing, Erode), Tamil Nadu. He has an experience of 8 years after PhD and 17 years after postgraduation. He has a very long professional journey (36 years), from Axillary Nurse to Doctorate in Nursing (1986–2022). General education is part and parcel of his professional journey—MBA in Education (2019); Madras University (2017); MA in Education, Alagappa University (2015); MSc General Psychology, Madras University (2013); MSc Counseling and Psychotherapy (2022); Master of Social Work (MSW 2020) from The Tamil Nadu Open University, Chennai; MPhil, Education, Alagappa University (2006); MA, Child Care and Education, Alagappa University (2004); and MA, Sociology, Annamalai University (1995). He is PhD-guide, co-guide, examiner, tool validator, and thesis evaluator (MGM University, Aurangabad, Sri Balaji University, Puducherry, Rajiv Gandhi University of Health Sciences, Bengaluru). He has published 70 nursing textbooks for nursing and paramedical courses including solved question papers. He is the Editor and National Editorial Board Member for national and international journals. He has also published 90 scientific and research articles in national and international journals, Publisher (IC Publications). He has presented 60 scientific and research papers in national and international conferences and organized workshops, seminars, symposiums and panel discussions, state- and national-level geriatric health camps, eye camps, blood donation camps, health awareness programs, community development programs, and national health activities. He is a research guide and co-guide for PhD and PG students in various Indian universities. Professional membership includes TNAI, ISPN, CMAI, NRSI, Red Cross, St John's Ambulance, Society of Indian Neuroscience Nurse, and PhD Society of India University.

Scan for more nursing titles...

Buy from ejaypee

JAYPEE BROTHERS

ISBN 978-93-6616-942-2